COLUMBIA LIBRARIES OFFSITE
HEALTH SCIENCES RESTRICTED
HR01093924

SERIAL

V.34

J

1916

Columbia University
in the City of New York

College of Physicians and Surgeons

Reference Library

Digitized by the Internet Archive
in 2014

https://archive.org/details/journalofcutaneo3419amer

THE JOURNAL OF CUTANEOUS DISEASES

INCLUDING SYPHILIS

Official Organ of

The American Dermatological Association

GEORGE M. MACKEE, M.D., New York
Editor

FRED WISE, M.D., New York
Associate Editor

Vol. XXXIV

1916

BOSTON, MASS.
W. M. LEONARD, PUBLISHER
1916

Copyrighted, 1916
by
W. M. Leonard

INDEX TO VOLUME XXXIV

Compiled by William H. Baughman, M.D., New York.

LIST OF ORIGINAL COMMUNICATIONS ARRANGED BY NAMES OF AUTHORS

PAGE

Alderson, Harry E.—Rhinoscleroma: Progress Notes on a Case Previously Reported 198

Beck, W. M.—Treatment of Tinea Barbae 606

Blaisdell, J. Harper.—Trichotillomania. A Report of Two Cases of This Rare Neurodermatosis 363

Corlett, William Thomas.—The Present Status of Dermatology in South America 23

Culver, George D.—An Instance of Verrucae Planae Juveniles Complicated with Lichen Planus 502

Davidson, A.—Argyria from an Unusual Source 605

De Tarnowsky, George.—The Modern Treatment of Burns..... 191

Engman, Martin F., and **Weiss, Richard S.**—The Exudative Diathesis, and a Study of Acetone Bodies in the Blood of Nine Cases..739, 804

Foerster, O. H.—The Relation of Internal Secretions to Cutaneous Diseases 1

Fordyce, John A.—Syphilis of the Nervous System..... 713

Foster, Burnside.—The Importance of Visceral Symptoms in Dermatoses of the Exudative Erythema Type 808

Freeman, Nathan.—Preparation of Skin for Microscopical Study..... 541

Gilchrist, T. Casper, and **Ketron, Lloyd W.**—Report of Two Cases of Idiopathic Haemorrhagic Sarcoma (Kaposi), One Presenting Unusual Features, with Special Methods of Treatment and Investigation 429

——— and **Ketron, L. W.**—A Unique Case of Atrophy of the Fatty Layer of the Skin, Preceded by the Ingestion of the Fat by Large Phagocytic Cells—Macrophages 429

Haase, Marcus.—Keratosis Blennorrhagica, with Report of a Case 817

Hartzell, M. B.—Acrodermatitis Hiemalis 791

Hazen, H. H.—A Hitherto Undescribed Superficial Atrophy of the Mucous Membranes of the Tongue and Mouth 801

Heidingsfeld, M. L.—Formalin Urticaria..... 303

Heimann, Walter J.—Histopathology 30, 108, 203, 366, 528, 664

——— **Schwartz, Hans J.**, and **Mahnken, Harry C.**—The Sugar Content of the Blood in Various Diseases of the Skin 159

PAGE

——— ——— ———A Critical Review of Eczema and Dermatitis, with an Analysis of a Group of Cases 259

Hutchins, M. B.—Should All Pre-Cancerous or Cancerous Lesions of the Skin be Excised? 27

Ketron, Lloyd W.—See Gilchrist, T. Casper 429

——— See Gilchrist, T. Casper 728

Kolmer, John A.—See Strickler, Albert 166

Lane, John E.—A Case of Postvaccinal Psoriasis 201

——— Naevus Anaemicus 602

MacKee, George M.—The Coolidge Tube and the Corbett Radiometer... 296

——— and **Rosen, I.**—Monilethrix. A Clinical and Histological Study, with a Report of Six Cases and a Review of the Literature.444, 506

Matsumoto, Shin-Ichi.—A Peculiar Form of Porokeratosis..... 489

McBride, William L.—Erythematous and Urticarial Eruptions Resulting from Sensitization to Certain Foods 70

McEwen, Ernest L.—The Relation of Internal Secretions to Cutaneous Diseases 15

Mahnken, Harry C.—See Heimann, Walter J. 159

Montgomery, Douglass W.—Immunity from Scabies 90

——— Deep Transverse Furrowing of the Finger Nails Following Local Asphyxia 285

———Diffuse Pigmentation of the Scrotum in Lichen Planus 499

——— Pastes 596

——— Lichen Planus Accompanied by Bleb Formation 748

——— The Relation of Diets to Seborrhoea 829

Nakano, H.—The Value of Various Diagnostic Methods for the Cerebrospinal Fluid 179

Newman, E. D.—Actinomycosis; Cutaneous and Systemic. Report of a Case 290

Olson, George Manghill.—A Tabulation of the Layers of the Skin..... 528

Pollitzer, S.—Leprosy, a National Problem 55

——— The Principles of the Treatment of Syphilis 633

Post, Abner.—The Bones in Congenital Syphilis 351

——— Congenital and Bone Syphilis 589

Pusey, William Allen.—Calamine Liniment 826

Ravogli, A.—Gangraenous Syphilitic Gumma of the Thigh 353

PAGE

Remer, John.—See MacKee, George M. 296

Rosen, L.—See Wise, Fred 95

——— See MacKee, George M. 444, 506

Satenstein, D. L.—Physical Diagnosis in Dermatology..... 545

Schamberg, Jay F.—See Strickler, Albert 166

Scheer, Max.—A Case of Darier's Disease in Its Early Stages 837

Schorer, Edwin Henry.—See McBride, William L. 70

Schwartz, Hans J.—See Heimann, Walter J. 159

Sharpe, Charles T.—Meningococcus Meningitis with Unusual Purpuric Manifestations; Demonstration of the Diplococcus in the Skin. 659

Stokes, John H.—Clinical and Experimental Observations on a case of Pityriasis Lichenoides Chronica (Juliusberg) 343

Strickler, Albert; Kolmer, John A., and **Schamberg, Jay F.**—Complement Fixation in Acne Vulgaris 166

——— ——— ——— Differential Blood Counts in Parasitic Skin Diseases and Their Possible Significance 752

Sutton, Richard L.—An Unusual Variety of Vitiligo (Leucoderma Acquisitum Centrifugum) 797

Wallhauser, H. J. F.—Dermatitis Repens; Report of Two Rare Cases.... 187

Weiss, Richard S.—See Engman, Martin F. 739, 804

White, Charles J.—Poisoning by Crude Coal Tar 497

———The Anaphylactic Phenomenon in Eczema and the Recent Progress in Our Knowledge of the Aetiology and Treatment of the Disease 57

——— The Use of Mercury in Verrucae Planae Juveniles 361

——— Presidential Address. Fortieth Annual Meeting of the American Dermatological Association 415

Wile, Udo J.—Some Observations on the Transmission of Syphilis; with Particular Reference to a Paternal Source of Infection..... 645

Winfield, James MacFarlane.—Psoriasis as a Sequel to Acute Inflammations of the Tonsils 441

Wise, Fred, and **Rosen, Isadore.**—A Case of Early Mycosis Fungoides Clinically Indistinguishable from Parapsoriasis of Brocq 95

Zeisler, Joseph.—The Dermatologist, the Proper Teacher of Syphilis.... 583

ALPHABETICAL LIST OF AUTHORS WHOSE WORKS ARE PUBLISHED OR ANALYZED IN THIS VOLUME

Abbe, 787.
Abbott, 52.
Abramowitz, 397.
Abramson, 480.
Adamson, 629, 858.
Alderson, 49, 198, 408.
Alderton, 50.
Anders, 330, 709.
Anderson, E. A., 410.
Anderson, H. M., 411.
Anderton, 393.
Antonelli, 569.
Armstrong, 621.
Arnold, 45.
Arrowsmith, 782.
Ayer, 703.

Baldwin, 573.
Balzer, 569, 624, 625.
Banker, 574.
Barach, 148.
Barber, 144.
Barthélemy, 569.
Baughman, 392.
Baum, 873.
Bazeley, 411.
Beatty, 143, 145.
Bechet, 124, 134, 383, 393, 397, **401**, 472, 473, 559, 678, 684, 685, 689, 690, 693.
Beck, 606, 627.
Becker, 325.
Beebe, 486.
Bel, 862.
Bendig, 322, 325.
Benians, 144, 478.
Berger, 401.
Bernheim, 580.
Bernstein, E. P., 780.
Bernstein, R., 156.
Bertels, 777.
Best, 579.
Bettman, 320.
Biné, 868.
Bizard, 569, 624, 625, 626, 857.
Bizzozero, 40.
Blaisdell, 363, 867.
Blancard, 396.
Bloch, 237, 239.
Blum, 327.
Bobovitch, 328.
Bockhart, 37.
Bogrov, 44, 243, 329.
Bond, 331, 710.
Bosellini, 572.
Bouveyron, 143.
Bralez, 569, 625, 626, 856, 857.
Brand, 381, 405, 406.
Brault, 143.
Bristol, 576.
Brocq, 857.
Brooks, 704.
Brown, 151.
Bruck, 237.
Brush, 700.
Bucky, 325.
Bufford, 334.
Bulkley, 413, 577.
Bunker, 869.
Burnier, 141.
Buswell, 334, 410.
Butler, 621.

Castellani, 151.
Chalmers, 152, 331, 332.
Chargin, 464, 557, 695, 814.
Chase, 868.
Cheney, 50.
Chipman, 48.
Chiu, 482.
Christen, 855.
Clark, A. S., 117, 122, 127, 561, 696, **761**, 767, 769, 815.
Clark, W. L., 780, 848.
Collier, 705.
Cole, 482.
Collin, 143.
Collins, 482, 575.
Copelli, 38.
Corlett, 23, 150.
Coues, 252.
Courcoux, 141.
Cox, 484.
Culver, 502.
Cummer, 483.
Cunningham, 148, 248, 870.

Dade, 54, 861.
Dagave, 44.
Davenport, 861.
Davidson, 605.
Davis, 231, 466, 698, 849, 850, 852.
De Aja, 571.
De Laviergne, 580.
Dearborn, 395, 396.
Delcamp, 624.
Dennie, 334.
De Tarnowsky, 191.
Dexter, 483.
Dickson, 483.
Dietsch, 567.

Dogny, 46.
Dombrovski, 777.
Dore, 708.
Draper, 866.
Drew, 331.
Dreyfus, 142.
Druelle, 327.
Dyer, 150.

Early, 703.
Eastman, 410.
Easton, 248.
Ebbecke, 245.
Eberly, 147.
Elliott, 46.
Emsheimer, 701
Engman, 247, 739, 804.
Eysell, 43.

Fabry, 235, 322, 774.
Falls, 701.
Felton, 700.
Field, 337.
Filho, 244.
Fischer, A., 406.
Fischer, E. D., 786.
Fischer, W., 235.
Foerster, 1.
Force, 333.
Fordyce, 119, 120, 149, 317, 382, 384, 391, 393, 396, 397, 400, 401, 402, 403, 404, 405, 554, 555, 610, 713.
Foster, 620, 808.
Fox, G. H., 115, 129, 394.
Fox, H., 124, 220, 221, 222, 226, 308, 311, 313, 390, 392, 394, 395, 398, 401, 404, 472, 473, 477, 556, 558, 560, 678, 680, 684, 695, 697, 758, 759, 761, 762, 764, 765, 766, 768, 769, 770, 771, 773, 844, 845, 847.
Foy, 699.

Garrison, 863, 864.
Gaskill, 231, 232, 233, 336, 464, 465, 466, 467, 468, 562, 563, 564, 565.
Gastinel, 856.
Gate, 569.
Gaucher, 569, 624, 625, 626, 857.
Gennerich, 42.
Gerbay, 46.
Geyser, 225, 226.
Gilbert, 152.
Gilchrist, 157, 377, 392, 429, 728.
Gillette, 250.
Gilmour, 560.
Gilpin, 703.
Goddard, 581.
Goodman, 780.
Goldberg, 703.
Goldberger, 485.
Goldenberg, 384, 385, 387, 401, 464, 557, 560.
Goldkraut, 235.
Gordon, 145.
Gottheil, 130, 131, 133, 222, 224, 383, 393, 471, 475, 476, 686, 687, 689, 693, 782, 845, 871.
Gougerot, 625.
Græser, 560.
Grann, 856.
Gray, A. L., 780.
Gray, C. D., 784.
Groigoryev, 626, 776.

Haase, 817.
Hailperin, 391.
Haines, 702.
Haller, 863.
Hammers, 700.
Hanawa, 240.
Hanes, 330.
Harris, 615, 616.
Hartzell, 230, 232, 467, 562, 697, 698, 791, 848, 851.
Haslund, 324.
Hassan, 574.
Hazen, 51, 408, 712, 789, 801, 872.
Hecht, 408, 623.
Heidingsfeld, 303, 576.
Heimann, 30, 109, 159, 201, 259, 366, 379, 383, 399, 402, 403, 528, 556, 560, 664, 758, 763, 770.
Heiser, 486.
Hesse, 567.
Higgins, 330.
Hirose, 240.
Hirschler, 565, 697.
Hoffmann, 40, 41, 326.
Holzknecht, 240, 855.
Hopkins, 152, 153, 631.
Horiuchi, 240.
Horner, 412.
Howard, 710.
Howland, 703.
Hoyne, 147.
Hubert, 568.
Hugo, 154.
Hunt, 866.
Hutchins, 27, 485.

Ijiri, 240.
Imbert, 141.
Immellmann, 854.
Ireland, 49.

Jackson, 54, 253, 306.
Jamieson, 858.
Jampolsky, 244.
Janus, 324.
Jenkins, 145.
Jerusalemy, 142.

Jimeno, 571.
Johnston, 870.
Joly, 155.
Jones, F. S., 479.
Jones, J. P., 783.
Josephovitch, 480.

Kaestle, 326.
Kafka, 235.
Kaplan, 255.
Kartaskeyski, 45.
Karuskin, 328, 627.
Kaufman, 782.
Kellogg, 703.
Kempster, 154.
Kennedy, 872.
Kerr, 581.
Ketron, 151, 429, 728.
Keyes, 149.
Kholevo, 778.
Kienbock, 854.
Kingsbury, 379, 383, 393, 401, 558, 611, 691.
Klausner, 140.
Klein, 42, 857.
Knack, 234.
Knapp, 868.
Knowles, 468, 702, 850.
Koch, 712.
Kock, 237.
Koefod, 411, 412.
Kolmer, 166.
Kondoléon, 42.
Kottmaier, E., 775.
Kottmaier, J., 775.
Kreibich, 776.
Kudish, 43.
Kurita, 240.
Kyrle, 39, 774.

Lacapère, 142.
La Fetra, 581.
Lain, 408.
Landis, 46.
Lane, 146, 201, 484, 557, 561, 602.
Landouzy, 142.
Lapeyre, 141.
Lapowski, 463, 464, 812, 813, 814.
Larkin, 630.
Lavinder, 250.
Le Damany, 141.
Lee, 48, 249.
Lenorment, 142.
Leschcziner, 235.
Levchenkow, 479.
Leviseur, 397, 398.
Levy, F., 43.
Levy, I. J., 630.
Levy-Bing, 46.
Levy-Franckel, 143.
Lewis, 46.
Likes, 784.
Lisser, 153.
Little, 487, 706, 707.
Lloyd, 335.
Loeffler, 321.
Lube, 327.
Lyon, 869.

MacDonald, 152, 700.
MacKee, 118, 120, 127, 136, 220, 296, 316, 382, 391, 397, 401, 404, 408, 414, 444, 464, 469, 506, 550, 554, 555, 560, 617, 618, 619, 677, 684, 685, 688, 690, 695, 696, 841, 842, 846, 847.
Mackinney, 251.
MacNeal, 863, 864.
Mahnken, 159.
Maki, 627.
Manugarianz, 777.
Markley, 47.
Marsh, 581.
Marshall, 332.
Martinet, 141.
Marx, 38.
Massia, 569.
Matsumoto, 242, 489.
Mayer, 240, 856.
McAuliff, 701.
McBride, 70.
McBurney, 631.
McCaskey, 582, 784.
McDonagh, 705, 788, 859.
McEwen, 15.
McPhedran, 334, 410.
Medalia, 52.
Mentberger, 39.
Merritt, 413.
Mescherski, 244, 328.
Michælis, 237.
Miescher, 140.
Miles, 51.
Miller, 700.
Montgomery, 48, 51, 90, 249, 285, 335, 497, 577, 596, 748, 829, 871.
Montpellier, 143.
Moore, 573.
Moran, 570.
Moriata, 578.
Morris, 779.
Morrow, 48.
Morse, 332.
Mott, 869.
Munk, 240.
Munsey, 708.
Munson, 708.

Nabarro, 480.
Nakano, 179, 240.
Nakayama, 240.
Nelson, 410.
Newman, 290, 399.

Nicholas, 569.
Nobl, 323.
Noguchi, 632.
Nonne, 874.

Ochs, 220, 221, 222, 225, 226, 227, 394, 397, 398, 404, 465, 680, 686, 687, 689, 844, 845.
O'Donovan, 144.
Oliver, 780.
Olson, 543, 621.
Ormsby, 146, 613, 614.
Ordway, 701.
Orton, 582.
Ostroumov, 45.
Oulmann, 137, 402, 618, 846.

Page, 249.
Pamment, 705.
Pardee, 614.
Parhon, 247.
Park, 338.
Parounagian, 692, 694, 697.
Partilla, 571.
Paul, 870.
Pels, 574.
Perkel, 320.
Pernet, 488.
Perry, 484.
Pershing, 246.
Petrov, 243.
Pfahler, 466, 848, 849, 852.
Pfeiffer, 250.
Philip, 567.
Pillon, 569.
Pisko, 401, 472, 473, 474, 845.
Pollitzer, 56, 381, 396, 400, 404, 462, 633, 704.
Pospielov, 778.
Post, 334, 351, 411, 589.
Potter, 306, 399, 402, 549, 550.
Pusey, 53, 616, 826.

Radonicic, 246.
Rapchevski, 777.
Rasch, 321, 628, 860.
Ratera, 414, 571.
Ravogli, 353, 408.
Reasoner, 333, 410.
Recque, 403.
Remer, 296, 401, 464.
Ribbert, 853.
Robinson, A. R., 318, 388.
Robinson, D. M. O., 395, 398, 812.
Rohdenburg, 486.
Rolleston, 859.
Rosen, 95, 132, 136, 382, 444, 506, 681, 682, 683.
Rost, 326.
Rostenberg, 403, 484, 786.
Rothwell, 394, 558, 559, 814.
Russ, 154.

Sæves, 321.
Sakamura, 240.
Salinger, 236.
Sallis, 329.
Samberger, 138, 139, 149, 624.
Sasakawa, 242.
Satenstein, 396, 400, 404, 545, 942.
Satini, 247.
Savill, 155.
Schaffner, 710.
Schamberg, 166, 466, 467, 468, 563, 564, 565, 816, 848, 849, 852.
Schanz, 236.
Scheer, 402, 837.
Scherber, 39.
Schmidt, 855.
Schoenrich, 784.
Schorer, 70.
Scott, 632.
Schultze, 854.
Schumacher, 38.
Schwartz, 159.
Schwarzman, 142.
Seifert, 139.
Sellards, 152.
Semon, 50.
Sequeira, 153, 488, 630, 708.
Seuffert, 236.
Sezary, 143.
Shaffner, 710.
Shanahan, 708, 778.
Sharkey, 579.
Sharpe, 659.
Shaw, A. L., 708.
Shaw, T., 785.
Sherwell, 771.
Shohan, 869.
Sibley, 487, 488.
Sicilia, 572.
Siler, 863, 864.
Simmonds, 245.
Simpson, 614.
Smith, 413.
Snyder, 402.
Sobotka, 321.
Sodachev, 778.
Solomon, 411, 412.
Southard, 412.
Speare, 143.
Spiethoff, 775.
Spence, 705.
Starr, 411.
Stelwagon, 228, 231, 232, 233, 464, 466, 468, 562, 849.
Stern, 141.
Stetson, 400.
Stevens, 384, 405.
Stillians, 615.
Stoerzer, 568.

Stokes, 343, 616.
Stoll, 46.
Stone, 865.
Strandberg, 40.
Strauss, 563.
Strickler, 166, 565, 703, 752.
Strong, 152.
Strousse, 851.
Stuempke, 41, 624, 775.
Sugai, 240.
Sutton, 702, 797.
Sweitzer, 621.
Symmers, 865.

Takano, 864.
Tamura, 241.
Teleghe, 327.
Theodoresco, 327.
Thibierge, 858.
Thomas, 622.
Tiéche, 234.
Tousey, 783.
Tracy, 869.
Trimble, 117, 118, 123, 125, 304, 308, 309, 312, 381, 382, 389, 390, 391, 392, 394, 396, 397, 398, 399, 400, 401, 405, 406, 551, 556, 559, 610, 762, 763, 766, 768, 813, 815.
Troitzki, 44.
Trotter, 488.
Turnbull, 50, 479.
Turner, 582.
Tyzzer, 152.

Uhle, 251.

VanDungern, 566.
Vedder, 779, 862.
Voegtlin, 712.
Vogel, 249.
VonBeuren, 702.
Voorhees, 50.

Wachtel, 240, 855.
Wade, 862.
Walker, 229, 231, 413, 697, 863.
Wallace, 865.
Wallhauser, 187, 379, 389, 395, 469, 678, 695, 843, 844.
Walsh, 248, 335. a
Walter, 329.
Ward, 707.
Waring, 485.
Washburn, 149.
Weber, 145, 629, 707.
Weiss, L., 135, 136, 225, 393, 394, 404, 470, 471, 618, 620, 680, 693, 842, 845, 847.
Weiss, R. S., 739, 804.
Weissenberg, 240, 855
Welles, 411, 412.
Wheeler, 485.
White, C. J., 361, 415, 497, 868.
White, J. C., 54, 339.
Whitehouse, 54, 317, 381, 394, 405, 553, 767.
Whitney, 573.
Wichmann, 853.
Wile, 46, 247, 481, 645.
Winfield, 307, 404, 441, 781.
Winkler, 775.
Willetts, 485.
Williams, C. M., 128, 309, 314, 315, 317, 380, 552, 607.
Williams, L. R., 872.
Wilson, 49.
Wise, 95, 123, 127, 136, 148, 220, 225, 227, 378, 392, 396, 401, 469, 472, 550, 555, 560, 610, 617, 618, 619, 677, 684, 685, 690, 695, 696, 841, 846, 847.
Wolbarst, 785.
Wolff, 873.
Woolley, 332.
Wright, 622.
Wright, H. M., 334.

Zaucilov, 777.
Zeisler, 583.
Zelenev, 242.
Zinger, 580.
Zinsser, 152, 153, 631.

ALPHABETICAL INDEX OF SUBJECTS

A

Abderhalden dializing reaction, results in the field of dermatology, obtained by means of, Stuempke (Abs.), 41.

Acanthosis nigricans as an indication of internal malignancy, Markley (Abs.), 47.

Acarus, the artful, scabies exposed, Cunningham (Abs.), 148.

Acetone bodies in the blood of nine cases, the exudative diathesis and a study of, Engman and Weiss (O.), 739.

Acidosis, dermatoses of, Cunningham (Abs.), 870.

Acne.
bacillus.
staphylococcus albus and the, the relations of, to the epidermis and the excretions of the skin; with special reference to the lesions of acne vulgaris, Benians (Abs.), 144, 478.
of unusual severity, Williams (S. Tr.), 314.
varioliformis, case of, Ochs for Fox (S. Tr.), 226.
vulgaris.
complement fixation in, Strickler, Kolmer and Schamberg (O.), 166.
furunculosis and, vaccine therapy in, Manugarianz (Abs.), 777.
lesions of, the relations of the Staphylococcus albus and the acne bacillus to the epidermis and the excretions of the skin; with special reference to the, Benians (Abs.), 144, 478.
with keloid formation, Lapowski (S. Tr.), 464.
with unusual scarring, Trimble (S. Tr.), 766.

Acnitis, case of, report of a, with a study of the point of origin of the pathological process, Ketron (Abs.), 151.

Acrodermatitis.
chronica.
atrophicans.
case of, Rosen (S. Tr.), 683; H. Fox (S. Tr.), 770; Heimann (S. Tr.), 770; Kingsbury and Bechet (S. Tr.), 383; Wise for Fordyce (S. Tr.), 392.

Acrodermatitis.
hiemalis, Hartzell (O.), 791.
morphoea and, Bechet (S. Tr.), 690.

Actinomycosis.
cutaneous and systemic, report of a case, Newman (O.), 290.
of the neck, Harris (S. Tr.), 616.
Sibley (Abs.), 488.

Addison's disease.
case of, Gottheil, (S. Tr.), 224.
diffuse pigmentation of the skin following gunshot injuries in the neighborhood of the adrenals, Fischer and Leschcziner (Abs.), 235.
of syphilitic origin, Schaffner and Howard (Abs.), 710.
treated with x-ray, a case of, Ratera (Abs.), 414.

Address, presidential, White, C. J. (O.), 415.

Adenitis.
cervical.
gummatous.
its relation to, and mistaken diagnosis for, tuberculous cervical adenitis, Coues (Abs.), 252.

Adenoma.
sebaceum, Bechet (S. Tr.), 689; Gottheil (S. Tr.), 393; MacKee and Wise (S. Tr.), 695.

Adenopathy, epitrochlear, following syphilis, Levy-Franckel (Abs.), 143.

Adrenalin.
use of, following injections of salvarsan, notes on the, Schwarzman (Abs.), 142.

Adrenals.
diffuse pigmentation of the skin following gunshot injuries in the neighborhood of the, (traumatic Addison's disease), Fischer and Leschcziner (Abs.), 235.
in congenital syphilis, Simmonds (Abs.), 245.
thyroid and, general pathology of pellagra; with special reference to findings in the, Morse (Abs.), 332.

Agar, reaction of skin to injections of, Stokes (S. Tr.), 616.

Agglutination, Treponema pallidum, antibody formation against, Zinsser, and Hopkins (Abs.), 153.

Albuminuria, orthostatic, and its relationship to skin diseases, particu-

Albuminuria.
larly of tuberculous and syphilitic origin, Arnold (Abs.), 45.
Allergy, in relation to certain eruptions of microbic origin, or specific hypersensitiveness, Adamson (Abs.), 629.
Alopecia.
areata.
case of exophthalmic goitre followed by, Jenkins (Abs.), 145.
ichthyosis and, Jackson (S. Tr.), 306.
maligna, of nervous origin, a case of, Teleghe (Abs.), 327.
case of generalized syphilitic leucoderma with, Bobovitch (Abs.), 328.
contra-lateral, concerning, after gunshot injuries of the head, Klausner (Abs.), 140; Knack (Abs.), 234.
syphilitica, Montgomery (Abs.), 335.
total, a case of, Kartashevski (Abs.), 45.
universalis, Parounagian (S. Tr.), 130.
Alopecias, diagnosis of the, in children, Burnier (Abs.), 141.
American Dermatological Association.
clinical session of, 39th annual meeting, New York, May 13 and 14, 1915, 377.
fortieth annual meeting of the, presidential address, White (O.), 415.
Analgesia, syphilitic, secondary, case of Fournier's, Rasche (Abs.), 860.
Anaphylactic phenomenon in eczema and the recent progress in our knowledge of the aetiology and treatment of the disease, White (O.), 57.
Angiokeratoma, corporis, diffusum, case of, Stuempke (Abs.), 775.
Angioma, case of, Gottheil and Ochs (S. Tr.), 686.
cavernous.
of hard palate, Weiss (S. Tr.), 393.
of the lower lip, Weiss (S. Tr.), 393.
Angiomata, with hyperkeratoses, a study of the, Matsumoto (Abs.), 242.
Announcements.
Klotz resigned from German Hospital, 158.
on publishing articles in the Journal, 158.
Rogers appointed editor of American Journal of Orthopedic Surgery, 158.
Anthrax.
specimens of, Wallhauser (S. Tr.), 695.
with special reference to its suppression, Washburn (Abs.), 149.
Antibodies, spirochaeticidal, against Treponema pallidum, studies on Treponema pallidum and syphilis, McBurney (Abs.), 631.
Antibody formation, against Treponema pallidum agglutination, Zinsser and Hopkins (Abs.), 153.
Aorta, heart and, certain syphilitic affections of the, Anders (Abs.), 330.
Aortitis.
syphilitic.
aetiology of, Symmers and Wallace (Abs.), 865.
and its serology, a pathological study of, Larkin and Levy (Abs.), 630.
Argulan, a new organic mercurial, Mentberger (Abs.), 39.
Argyria, from an unusual source, Davidson, (O.), 605.
Arsenic.
compounds, microchemical studies of, Tamura (Abs.), 241.
therapy, specific, lesions produced by arsenicals and their bearing on the problem of, Brown (Abs.), 151.
treatment, intraspinal, of syphilis, Hassan (Abs.), 574.
Arsenical pigmentation and keratosis, Fox (S. Tr.), 124.
Arsenicals, lesions produced by, and their bearing on the problem of specific arsenic therapy, Brown (Abs.), 151.
Arsenobenzol.
resolution by the council of the American Dermatological Association, 632.
treatment.
of gangraene with, Lacapère and Lenorment (Abs.), 142.
intravenous.
report on the clinical symptomatology and laboratory findings in three cases of general paresis under, Mott and Bunker (Abs.), 869.
Arteries, syphilitic disease of the, McPhedran (Abs.), 334, 410.
Arthritis, psoriasis and, Bogrov (Abs.), 243.
Arthropathies, luetic, Higgins (Abs.), 330.
Asphyxia, local, deep transverse furrowing of the finger nails following, Montgomery (O.), 285.
Atrophy.
pressure, Anderton for Fordyce (S. Tr.), 393.

Atrophy.
hemi, recurrent herpes zoster of the face with, Trotter (Abs.), 488.
macular, Ochs (S. Tr.), 844.
macular and striated, general, with teleangiectases of the skin, associated with infantilism and imperfect development of the bones, Gottheil (S. Tr.), 133.
of the fatty layer of the skin, preceded by the ingestion of the fat by large phagocytic cells—macrophages, a unique case of, Gilchrist and Ketron (O.), 728.
of the liver, acute yellow, during syphilis, Bendig (Abs.), 325.
of the mucous membranes of the tongue and mouth, a hitherto undescribed superficial, Hazen (O.), 801.
reticulated, of the skin of the face, Parounagian (S. Tr.), 463.
Atrophodermia, biotriptica in natives in Anglo-Egyptian Soudan, Chalmers and Drew (Abs.), 331.
Auto-inoculation, see inoculation.
Autolysin, Beebe (Abs.), 486.
Autoserum, see serum.
Axilla, papillary dermatitis of, Trimble (S. Tr.), 382.

B

Bacilli, tubercle, toxicity of, to lepers Lugai (Abs.), 240.
Bacillus, acne, Staphylococcus albus and the, the relations of, to the epidermis and the excretions of the skin; with special reference to the lesions of acne vulgaris, Benians (Abs.), 144.
Bacteria, the treatment of eczema with special reference to the use of vaccines and the part played by, in its aetiology, Medalia (Abs.), 52.
Bacterin treatment of certain pyogenic dermatoses, Dennie and Bufford (Abs.), 334.
Baths, tar-chrysophanic, in the treatment of psoriasis, Karuskin (Abs.), 328.
Bazin's disease, scrofuloderma and, Parounagian (S. Tr.), 558.
Bichloride, poisoning, mercury elimination in, Vogel and Lee (Abs.), 249.
Blastomycosis.
case of, Kingsbury and Bechet (S. Tr.), 393.
Blastomycosis.
systemic.
critical consideration of, Wade and Bel (Abs.), 862.
Blood.
cerebrospinal fluids and, in the diagnosis of syphilis of the nervous system, what is the position today as to the value of, Fisher (Abs.), 786.
counts, differential, in parasitic skin diseases and their possible significance, Strickler (O.), 752.
fresh, treatment of scarlet fever with, convalescent patients, Zinger (Abs.), 580.
spinal fluid and the, including the luetin reaction, the diagnosis of syphilis from the, Kafka (Abs.), 235.
sugar content of, in various diseases of the skin, Schwartz, Heimann, and Mahnken (O.), 159; Pels (Abs.), 574.
trichophytin reaction in the, Miescher (Abs.), 140.
whole, injections of, in the treatment of purpura haemorrhagica, Emsheimer (Abs.), 701.
Boils, Nile, in the Anglo-Egyptian Soudan, Chalmers and Marshall (Abs.), 332.
Bones.
imperfect development of the, general macular and striated atrophy with teleangiectases of the skin, associated with infantilism and, Gottheil (S. Tr.), 133.
in congenital syphilis, Post (O.), 351.
skin and, tuberculosis of the, Steinke for Fordyce (S. Tr.), 404.
Book reviews.
Cancer of the skin, Hazen, 712.
Chemical changes in the central nervous system in pellagra, Koch and Voegtlin, 712.
Diseases of the skin, Hazen, 789.
Diseases of the skin and the eruptive fevers, Schamberg, 816.
Outline of common skin diseases, including eruptive fevers, Gilchrist, 157.
Serology of nervous and mental diseases, Kaplan, 255.
Solidified carbon-dioxide in the successful treatment of cutaneous neoplasms and other skin diseases, with special reference to angioma, epithelioma and lupus erythematosus, Bernstein, 156.

Book reviews.
Syphilis as a modern problem, Pusey, 53.
Syphilis und Nerven System, Nonne, 874.
The principles of bacteriology, a practical manual for students and physicians, Abbott, 52.
Treasury Department, United States Public Health Service, Hygienic Laboratory Bulletin, No. 103, February, 1916, 712.
Bouba, see yaws.
Brain, syphilis of the, a preliminary report of the use of mercuric chloride intradurally, Ireland and Wilson (Abs.), 49.
Breast, uterus and, the lasting results of the combined treatment of carcinoma of the, Klein (Abs.), 42.
Bromoderma, Lapowski, (S. Tr.), 464.
Buboes.
chancroidal.
without a primary lesion, Gougerot (Abs.), 625.
chronic, Gougerot (Abs.), 625.
Burn, electrical, two cases of, successfully treated by ionization, MacGregor (Abs.), 156.
Burns.
treatment of, modern, De Tarnowsky (O.), 191.
treatment of, Ravogli (Abs.), 408; Beck (Abs.), 627.
Bursitis, syphilitic, with report of a case, Scott (Abs.), 632.

C

Calcium chloride, compressed tablets of, contributions to the treatment of urticaria, Seifert (Abs.), 139.
Calomel
precipitation.
reaction.
Photo-chemical methods in general and, measuring Roentgen rays with the, Grann (Abs.), 856.
Cancer.
aetiology.
enzyme theory of, Bristol (Abs.), 576.
skin.
and its treatment, Dyer (Abs.), 150.
of the extremities, Hazen (Abs.), 408.
superficial.
treatment of, use of steam in, Gillette (Abs.), 250.
Cancer.
treatment of, dietetic and medical, Bulkley (Abs.), 413.
treatment of, principles and practice in, Hutchins (Abs.), 485.
tuberculosis and, of the back of the hand, Lapeyre (Abs.), 141.
Cancerous.
pre-cancerous or, lesions of the skin, should all be excised?, Hutchins (Abs.), 27.
Carbon dioxide snow.
treatment of lupus vulgaris by, Livchenkow (Abs.), 479.
Carcinoma.
deep raying by means of Roentgen ray machines, Seuffert (Abs.), 236.
deep raying by means of the Roentgen ray machine, Kock (Abs.), 237.
histogenesis of Roentgen and tar carcinomas, Ribbert (Abs.), 853.
lupus, and Roentgen rays, Stümpke (Abs.), 624.
of the uterus and breast, the lasting results of the combined treatment of, Klein (Abs.), 41.
Roentgen and tar, histogenesis of, Ribbert (Abs.), 853.
Cardiovascular.
disease, hypertensive, the rôle of syphilis in, Stoll (Abs.), 46.
system.
renal and, syphilis of the, Barach (Abs.), 148.
Case reports.
erythema multiforme?, H. Fox (S. Tr.), 477.
from the Dermatological Clinic of the Leland Stanford, Jr., University School of Medicine, Alderson (Abs.), 408.
tertiary circinate syphiloderm, with negative Wassermann and with nodules and breaking down in the scar, Gottheil (S. Tr.), 476.
Causation.
of pyogenic onychia and paronychia from auto-infection of a patient suffering from sycosis, Troitzki (Abs.), 44.
of sarcoma cutis idiopathicum multiplex haemorrhagicum (Kaposi), Dagave (Abs.), 44.
treatment and, of pellagra, Bond (Abs.), 331.
Cell, living, action of light on the, Schanz (Abs.), 236.

Cellular content of cerebrospinal fluid in neurosyphilis, the significance of, Solomon and Koefod (Abs.), 412.
Cerebrospinal.
fluid.
blood and, in the diagnosis of syphilis of the nervous system, what is the position to-day as to the value of?, Fisher (Abs.), 786.
drainage of, as a factor in the treatment of nervous syphilis, Gilpin and Early (Abs.), 703.
practical method for estimating the protein content of, Pfeiffer (Abs.), 250.
value of various diagnostic methods for the, Nakano (O.), 179.
meningitis.
skin manifestations, especially herpes, in, Scherber (Abs.), 39.
syphilis.
treatment of; the Ogilvie technique, Eastman (Abs.), 410.
Chancre, see syphilis.
Cheeks, internal surface of the, leucoplakia of the, Landouzy (Abs.), 142.
Cheilitis.
exfoliativa, H. Fox (S. Tr.), 474.
exfoliativa, Gilmour (S. Tr.), 560.
Chicago Dermatological Society, Dec. 21, 1915, 613.
Chickenpox, see varicella.
Chilblains.
gangraene and, from congelation, Imbert (Abs.), 141.
treatment of, Courcoux (Abs.), 141.
Child, syphilitic, tuberculous dactylitis in a, H. Fox and Ochs (S. Tr.), 404.
Children.
alopecias in, diagnosis of the, Burnier (Abs.), 141.
diseases of, serum and vaccine therapy in, Nabarro (Abs.), 480.
feeble-mindedness in the, syphilis in the parents as a cause of, Goddard (Abs.), 581.
hereditary syphilis in, later manifestations after the age of one year, La Fetra (Abs.), 581.
ringworm in, the problem of, Oliver (Abs.), 780.
Chloride, calcium, compressed tablets of, contributions to the treatment of urticaria, Seifert (Abs.), 139.
Cicatrices.
of body and scalp from tuberculosis, Trimble (S. Tr.), 763.
of body and scalp from tuberculosis, Rothwell (S. Tr.), 814.
Circumcision, infection with tuberculosis from, Kudish (Abs.), 43.
Clavus, pathology of, Chase (Abs.), 868.
Clinical reports.
psoriasis, postvaccinal, a case of, Lane, 201.
rhinoscleroma: progress notes on a case previously reported, Alderson, 198.
Colloid degeneration of the skin, Cunningham (Abs.), 870.
Colloidal sulphur, when why and how to administer, Martinet (Abs.), 141.
Comedo, reticulated scarring followed by, MacKee for Fordyce (S. Tr.), 382.
Complement fixation in acne vulgaris, Strickler, Kolmer and Schamberg (O.), 166.
Congelation, chilblains and gangraene from, Imbert (Abs.), 141.
Constrictor as an aid in the diagnosis of typhus, Dietsch (Abs.), 567.
Contagion in syphilitic chancres and individual prophylaxis in syphilis, notes on the mode of, Balzar and Barthélemy (Abs.), 569.
Creeping eruption of the skin, particularly in regard to its histologic features, including the demonstration of the burrow and the larva in the epidermis, Knowles (Abs.), 702.
Cure of syphilis, observations on the, Reasoner (Abs.), 410.
Cutaneous.
diseases.
relation of internal secretions to, Foerster (O)., 1.
relation of internal secretions to, McEwen (O.), 15.
reactions, local vaso-motor, Ebbecke (Abs.), 245.
tuberculosis, MacKee for Fordyce (S. Tr.), 391.
Cutis tuberculosis, Winfield (S. Tr.), 404.
Cyst, dermoid, case of, at first mistaken for a swelling due to the injection of paraffin, Kholevo (Abs.), 778.
Cysts, hydatid, multiple, in the subcutaneous tissue, a notable case of, Jimeno (Abs.), 571.

D

Dactylitis, tuberculous, in a syphilitic child, H. Fox and Ochs (S. Tr.), 404.

Darier's disease, see keratosis follicularis.

Deaths following salvarsan, Lube (Abs.), 327.

Death.
from injections of gray oil, Gaucher (Abs.), 625.
from salvarsan, a new cause of, Dreyfus (Abs.), 142.

Degeneration, colloid, of the skin, Cunningham (Abs.), 870.

Delinquents, juvenile, syphilis among: its relation to mental status, the incidence of, Haines (Abs.), 702.

Depilation, X-ray, second, in a case of tinea tonsurans, MacKee (S. Tr.), 118.

Dermatitis.
eczema and, a critical review of, with an analysis of a group of cases, Heimann (O.), 259.
exfoliativa, Wise (S. Tr.), 610.
exfoliative.
with multiple large ulcerations, Pollitzer (S. Tr.), 462.
following neosalvarsan injections, Biné (Abs.), 868.
factitia, Gaskill (Abs.), 336.
herpetiformis.
(pemphigus prurigineux, Hardy), Winfield (S. Tr.), 307.
(Duhring), pemphigus chronicus and, contribution to the therapy of, Fischer (Abs.), 407.
Hartzell (S. Tr.), 562.
case of, Stelwagon (S. Tr.), 228.
lymphatic leukaemia with, Parounagian (S. Tr.), 692.
medicamentosa.
a case of, Walsh (Abs.), 335.
Kingsbury (S. Tr.), 611.
occupational, Davis (S. Tr.), 849.
papillary, of axilla, Trimble (S. Tr.), 382.
psoriasiformis nodularis, Jadassohn, and parapsoriasis, Brocq, contribution to the study of, Hanawa and Nagai, (Abs.), 240.
repens, report of two rare cases, Wallhauser (O.), 187.

Dermatology.
anaphylactic food reactions in: preliminary report, Strickler and Goldberg (Abs.), 703.
heliotherapy in, Partilla (Abs.), 571.
in South America, the present status of, Corlett (O.), 23.
results in the field of, obtained by means of the Abderhalden dialyzing reaction, Stuempke (Abs.), 41.

Dermatomycoses.
knowledge of, experimental contributions to the, Saeves (Abs.), 321.
some general pathological and therapeutical problems in the domain of the, Bloch (Abs.), 237, 239.

Dermatomyoma, multiple, Abramson (Abs.), 480.

Dermatoses.
certain chronic pyogenic, bacterin treatment of, Dennie and Bufford (Abs.), 334.
factitious, Ormsby (Abs.), 146.
of acidosis, Cunningham (Abs.), 870.
of the exudative erythema type, the importance of visceral symptoms in, Foster (O.), 808.
war, treatment of, Bruck (Abs.), 237.

Dermatosis.
hysterical, a case of so-called, Rasch (Abs.), 321.
occupational, Heimann (S. Tr.), 556.

Dermatitis.
herpetiformis.
Bechet (S. Tr.), 134.
in lymphatic leukaemia, Parounagian (S. Tr.), 126.

Desiccation, naevus treated by, Pfahler (S. Tr.), 466.

Diagnosis, alopecias, in children, of the, Burnier (Abs.), 141.

Diagnosis, case for, Bechet (S. Tr.), 124; Bechet, (S. Tr.), 678; Bechet (S. Tr.), 682; melanosarcoma?, Bechet (S. Tr.), 472; parapsoriasis?, Brand for Trimble (S. Tr.), 381; Brand for Trimble (S. Tr.), 405; psoriasis or lichen planus?, Brand for Trimble (S. Tr.), 405; parapsoriasis?, Brand for Trimble (S. Tr.), 406; Clark (S. Tr.), 122; Clark (S. Tr.), 769; Gaskill (S. Tr.), 467; pemphigus foliaceus?, Gilchrist (S. Tr.), 377; sarcoid of Boeck or naevus?, Goldenberg (S. Tr.), 385; morphoea?, Gottheil and Ochs (S. Tr.), 689; Hailperin for Trimble (S. Tr.), 391; Hartzell (S. Tr.), 467; tuberculosis of the skin?, Hartzell (S. Tr.), 230; Hirschler (S. Tr.), 565; Hirschler (S. Tr.), 697; Kingsbury and Heimann (S. Tr.), 379; mycosis fungoides?, Kingsbury (S. Tr.), 611; Lapowski (S. Tr.), 813; premycotic stage of mycosis fungoides?, Lapowski (S. Tr)., 812; lichen planus?, Little (Abs.), 487; MacKee and Wise (S. Tr.), 469; MacKee and Wise (S. Tr.), 841; MacKee and Wise (S. Tr.), 677; pityriasis rosea?, MacKee and Wise

Diagnosis.
(S. Tr.), 227; purpura?, MacKee and Wise (S. Tr.), 619; naevus lympangiectodes?, MacKee and Wise (S. Tr.), 677; Pollitzer (S. Tr.), 381; atrophic lichen planus and scleroderma?, Robinson (S. Tr.), 318; Rothwell for Trimble (S. Tr.), 559; Schamberg (S. Tr.), 563; Schamberg (S. Tr.), 852; nodules on the face of a negro, Shaffner (S. Tr.), 615; tumor formation with hyperpigmentation over malar prominences, Sherwell (S. Tr.), 771; tuberculosis?, Sibley (Abs.), 487; Stelwagon and Gaskill (S. Tr.), 231; Stelwagon and Gaskill (S. Tr.), 233; Stelwagon and Gaskill (S. Tr.), 464; bullous eruption, Stevens for Fordyce (S. Tr), 384; bullous eruption, Stevens for Fordyce (S. Tr.), 405; Trimble (S. Tr.), 125; Trimble (S. Tr.), 305; Trimble (S. Tr.), 309; Trimble (S. Tr.), 312; Trimble (S. Tr.), 768; lichen ruber acuminatus?, Trimble (S. Tr.), 388; lupus erythematosus?, Weiss (S. Tr.), 470; fibroma cutis?, Weiss (S. Tr.), 842; Whitehouse (S. Tr.), 405; erythema multiforme or haemorrhagic erythema nodosum?, Whitehouse (S. Tr.), 317; Williams (S. Tr.), 315; Williams (S. Tr.), 552; epithelioma or tuberculosis?, Wise for Weiss (S. Tr.), 225; pityriasis rubra, Hebra?, Wise (S. Tr.), 378; bromide eruption?, Clark (S. Tr.), 696; Davis (S. Tr.), 698; Davis (S. Tr.), 850; Dore (Abs.), 708; H. Fox (S Tr.), 766; H. Fox (S. Tr.), 768; erythema multiforme?, Fox, H., and Ochs (S. Tr.), 221; bullous eruption in a young child, H. Fox (S. Tr.), 392; bullous eruption in a child, H. Fox (S. Tr.), 390; persistent erythematous patches of trunk, H. Fox (S. Tr.), 758; lupus erythematosus or vulgaris?, Fraser for Trimble (S. Tr.), 397.
case shown for, note on a, Little (Abs.), 707.
tricho-epithelioma or lupus erythematosus?, Gottheil (S. Tr.), 130.
parapsoriasis lichenoides chronica, MacKee for Fordyce (S. Tr.), 120.
syphilis or tuberculosis, Trimble (S. Tr.), 117.
keratodermia blenorrhagica?, Fordyce (S. Tr.), 119.

Diagnosis.
ulerythema ophryogenes, Clark (S. Tr.), 117.
bromoderma, Clark (S. Tr.), 127.
laboratory, and aetiology of smallpox and chickenpox, Force (Abs.), 333.
of spotted fever, Fraenkel (Abs.), 239.
of tertiary and latent syphilis, the luetin reaction in the, Hanes (Abs.), 330.
of typhus, the contsrictor as an aid to the, Diesch (Abs.), 567.
symptoms and, of leprosy, with report of cases, Morrow and Lee (Abs.), 48.
treatment and, of syphilitic nephritis, Munk (Abs.), 240.
differential.
of verruga peruviana, Strong, Tyzzer, and Sellards (Abs.), 152.
physical.
in dermatology, Satenstein (O.), 545.

Diagnostic methods, various, the value of, for the cerebrospinal fluid, Nakano (O.), 179.

Diarsenol, syncope immediately after the administration of, Likes and Schoenrich (Abs.), 784.

Diathesis.
exudative.
and a study of acetone bodies in the blood of nine cases, Engman and Weiss (O.), 739.
exudative, Engman and Weiss (O.), 804.

Diet.
restricted.
experimental pellagra in the human subject brought about by a, Goldberger and Wheeler (Abs.), 485.
rice.
use and abuse of the, Bulkley (Abs.), 477.

Diets.
relation of, to seborrhoea, Montgomery (O.), 829.

Diphtheria, pseudo, of the skin, case report, Gottheil (S. Tr.), 475.

Diphtheritic, whitlow, Rolleston (Abs.), 859.

Discussion, of paper by Drs. Gilchrist and Ketron, 439; following the symposium on internal secretions, 459.

Disease.
hypertensive cardiovascular, the rôle of syphilis in, Stoll (Abs.), 46.
of the arteries, syphilitic, McPhedran (Abs.), 334.

Disease.
syphilitic.
of the arteries, McPhedran (Abs.), 410.
Diseases.
skin and venereal, on the treatment of, in the field, Gennerich (Abs.), 42.
skin.
particularly of tuberculosis and syphilitic origin, orthostatic albuminuria and its relationship to, Arnold (Abs.), 45.
Dosimeter, comparisons, proceedings of the special commission for (German Roentgen Society), 855.

E

Eczema.
with marked follicular involvement, Stelwagon (S. Tr.), 849.
acute, Williams (S. Tr.), 314.
aetiology and treatment of the disease, the anaphylactic phenomenon in, and the recent progress in our knowledge of the, White (O.), 57.
anaphylactic phenomenon in, and the recent progress in our knowledge of the aetiology and treatment of the disease, White (O.), 57.
after the use of pellidol salve, Stoerzer (Abs.), 568.
case of, Gaskill for Stelwagon (S. Tr.), 562.
dermatitis and, a critical review of, with an analysis of a group of cases, Heimann (O.), 259.
erythematosum, Weiss (S. Tr.), 620.
generalized vaccinia and, from autoinoculation, Potter (S. Tr.), 549.
infantile, Cheney (Abs.), 50.
nature of, Samberger (Abs.), 624.
of the legs, Williams (S. Tr.), 552.
seborrhoeic.
circinate, Fox, H. (S. Tr.), 678.
Trimble (S. Tr.), 556.
seborrhoeicum.
with some lesions resembling premycotic granuloma fungoides, Trimble (S. Tr.), 762.
treatment of, with special reference to the use of vaccines and the part played by bacteria in its aetiology, Medalia (Abs.), 52.
treatment and aetiology of the disease, the anaphylactic phenomenon in, and the recent progress in our knowledge of the disease, White (O.), 57.

Ear.
helix.
nodular condition of the, Winkler (Abs.), 775.
keloid of the, H. Fox and Ochs (S. Tr.), 394.
Ecthyma.
case of, Lapowski (S. Tr.), 463.
case of, Pusey (S. Tr.), 616.
Editorial.
leprosy a national problem, Pollitzer, 55.
Elephantiasis.
case of, H. Fox (S. Tr.), 697, 762.
syphilitic, Petrov (Abs.), 243.
Elimination, mercury, in bichloride poisoning, Vogel and Lee (Abs.), 249.
Energy, radiant, in the treatment of diseases of the skin, Lain (Abs.), 409.
Enlargement, splenic, a study of, in early syphilis, Wile and Elliott (Abs.), 47.
Enzyme, theory, of cancer aetiology, Bristol (Abs.), 576.
Epidermis, excretions of the skin and the, the relations of the Staphylococcus albus and the acne bacillus to the; with special reference to the lesions of acne vulgaris, (Abs.), 144.
Epidermolysis bullosa.
Trimble (S. Tr.), 389.
Trimble (S. Tr.), 551.
acquisita, Ochs (S. Tr.), 394.
Epilepsy.
syphilis in, Shanahan, Munson and Shaw (Abs.), 708.
syphilis as an aetiological factor in, Shanahan (Abs.), 778.
Epithelioma.
basal-celled, of abdomen, Trimble (S. Tr.), 118.
case of, Bechet (S. Tr.), 685.
case of, Chargin (S. Tr.), 814.
case of, Pfahler (S. Tr.), 848.
cured by X-ray, two cases, Geyser (S. Tr.), 225.
lupus vulgaris and, Schamberg (S. Tr.), 565.
of lower lip, H. Fox (S. Tr.), 771.
of the mouth, Weiss (S. Tr.), 680.
of the palate, Oulmann (S. Tr.), 846.
of the penis, Fox, H., and Ochs (S. Tr.), 680.
of the tongue, MacKee and Wise (S. Tr.), 841.
radium treatment of, Kennedy (Abs.), 872.
Epitrochlear adenopathy following syphilis, Levy-Franckel (Abs.), 143.

Eruption.
creeping.
of the skin, particularly in regard to its histologic features, including the demonstration of the burrow and the larva in the skin, Knowles (Abs.), 702.
bullous and haemorrhagic, beneath the nails, H. Fox (S. Tr.), 764.
erythematous and urticarial, resulting from sensitization to certain foods, McBride and Schorer (O.), 70.
erythematous, following dermatitis herpetiformis, Hartzell (S. Tr.), 232.
haemorrhagic and bullous, beneath the nails, H. Fox (S. Tr.), 764.
urticarial and erythematous, resulting from sensitization to certain foods, McBride and Schorer, (O.), 70.
Erysipelas.
clinical observations of 800 cases of, Bogrov (Abs.), 329.
tattooing and, Mescherski (Abs.), 328.
treatment of, Bogrov (Abs.), 44.
Erythema.
iris.
and multiforme, MacKee and Wise (S. Tr.), 846.
multiforme.
and iris, MacKee and Wise (S. Tr.), 846.
multiforme.
iris, Weiss (S. Tr.), 394.
papulosum, Weiss (S. Tr.), 394.
perstans, Robinson (S. Tr.), 388.
perstans, MacKee and Wise (S. Tr.), 617.
perstans, MacKee and Wise (S. Tr.), 685.
nodosum.
recent attack, and tuberculide, congenital syphilis with, Heimann (S. Tr.), 403.
of iris type, Hartzell (S. Tr.), 851.
Erythrodermia congenitale ichthyosiforme.
Rosen (S. Tr.), 132.
Rosen for Fordyce (S. Tr.), 382.
Erythromelalgia, Raynaud's disease and, the combination of, Radonicic (Abs.), 246.
Examination, prophylaxis and, for syphilitic patients and their families: methods of investigation at the Psychopathic Hospital, Boston, Mass., 1915, Wright (Abs.), 334.
Extracts, glandular, experimental cutaneous reactions with, Parhon and Santini (Abs.), 247.
Extremities.
lower, peculiar purpuric condition of the, Trimble (S. Tr.), 308.
skin cancer of the, Hazen (Abs.), 408.
Eye.
affections of the, should salvarsan be used in syphilis in the presence of?, Ostroumov (Abs.), 45.

F

Face.
paraffinoma of the, Goldenberg (S. Tr.), 401.
recurrent herpes zoster of the, with hemiatrophy, Trotter (Abs.), 488.
reticulated atrophy of the skin of the, Parounagian (S. Tr.), 463.
ulcer of the (self-induced), in an hysterical woman, Marx (Abs.), 38.
Fat hypertrophy on the back of the hand, concerning, Hoffmann (Abs.), 40.
Favus.
endogenous, in Germany, Goldkraut (Abs.), 235.
ringworm and, of the scalp, the prevention and treatment of, Lane (Abs.), 146.
Feeble-mindedness in the children, syphilis in the parents as a cause of, Goddard (Abs.), 581.
Feet.
hands and, ringworm of the, Lane (Abs.), 484.
soles of the, morpheosclerodermia with recent acute symmetrical involvement of the, Pernet (Abs.), 488.
Ferments, proteolytic, of the blood serum in tabes dorsalis and general paresis, Falls (Abs.), 701.
Fibroma.
molluscum, Rothwell for Trimble (S. Tr.), 394.
Recklinghausen's disease, Fox, H. (S. Tr.), 313.
(von Recklinghausen's disease), Ormsby (S. Tr.), 613.
Filters.
X-ray, some experiments with, Sequeira (Abs.), 153.
the Sabouraud pastille and, Saville (Abs.), 155.
Finger nails, deep transverse furrowing of, following local asphyxia, Montgomery (O.), 285.
Fistulas, tuberculous, scrofuloderma and, cured by radiotherapy, two cases of, Ratera (Abs.), 571.

Fluid.
cerebrospinal.
the value of various diagnostic methods for the, Nakano (O.), 179.
a practical method for estimating the protein content of, Pfeiffer (Abs.), 250.
cellular content of, in neurosyphilis, the significance of changes in, Solomon and Koefod (Abs.), 412.
pathognomonic changes of the, in syphilis of the nervous system, Collins (Abs.), 482.
Follicular involvement, eczema with marked, Stelwagon (S. Tr.), 849.
Folliculitis.
decalvans.
G. H. Fox (S. Tr.), 394.
lichen spinulosus et, a case of, with report on microscopical findings, Beatty and Speare (Abs.), 143.
Food products, reaction of, Strickler (S. Tr.), 565.
Foods, sensitization to certain, erythematous and urticarial eruptions resulting from, McBride and Schorer (O.), 79.
Foot, sole of, lupus vulgaris on the, Kurita (Abs.), 240.
Formalin urticaria, Heidingsfeld (O.), 303.
Furrowing of the finger nails, deep transverse, following local asphyxia, Montgomery (O.), 285.
Furunculosis, acne vulgaris and, vaccine therapy in, Manugarianz (Abs.), 777.

G

Galyl in the treatment of syphilis, Mescherski (Abs.), 244.
Gangraene.
chilblains and, from congelation, Imbert (Abs.), 141.
praesenile thromboangeitis obliterans, Goodman and Bernstein (Abs.), 780.
symmetrical Raynaud's disease, report of a case, of unusual severity, Hoyne (Abs.), 147.
treatment of, with arsenobenzol, Lacapère and Lenorement (Abs.), 142.
Gastro-intestinal manifestations in syphilis, Bushwell (Abs.), 334, 410.
German Dermatological Society, 1889-1914, Bettmann (Abs.), 320.
German measles, see rubeola.
Gland.
suprarenal, and syphilis, Sezary (Abs.), 143.
sweat, tumors, two cases of, Alderton and Turnbull (Abs.), 50.
Glossitis, Möller's, Heimann (S. Tr.), 560.
Goitre, exophthalmic, case of, followed by alopecia areata, Jenkins (Abs.), 145.
Grafting, skin, with an unusual result, a case of, Strandberg (Abs.), 40.
Granuloma.
annulare.
Goldenberg and Chargin (S. Tr.), 464.
with widespread follicular eruption, Little (Abs.), 487.
coccidioidal, oidiomycosis in California, with especial reference to, Dickerson (Abs.), 483.
fungoides, premycotic, eczema seborrhoeicum, with some lesions resembling, Trimble (S. Tr.), 762.
malignum, Bertels (Abs.), 777.
pyogenicum, Butler (S. Tr.), 621.
Granulosis rubra nasi, Trimble (S. Tr.), 394.
Graves' disease with sclerodermia, Sequeira (Abs.), 708.
Gray oil, death from injections of, Gaucher (Abs.), 625.
Growths.
horny, of penis, Lane (S. Tr.), 557.
malignant, inhibitive effect of X-rays upon, Kempster (Abs.), 154.
Gum, upper, syphilitic chancre of the, in a woman, Sicilla (Abs.), 572.
Gumma, see syphilis.
Gummata, see syphilis.

H

Hair follicles, in psoriasis, increased radio-sensitiveness of the, Kienböck (Abs.), 854.
Hand.
back of the.
concerning fat hypertrophy on the, Hoffmann (Abs.), 40.
cancer and tuberculosis of the, Laperye (Abs.), 141.
feet and, ringworm of the, Lane (Abs.), 484.
Head.
injuries of the.
gunshot, concerning contra-lateral alopecia after, Klausner (Abs.), 140.
gunshot, concerning contra-lateral alopecia following, Knack (Abs.), 234.

Headache, syphilitic, intrathecal intracranial injection of autoneosalvarsanized serum for, Gordon (Abs.), 145.
Heart, aorta and, certain syphilitic affections of the, Anders (Abs.), 330.
Heliotherapy in dermatology, Partilla (Abs.), 571.
Herpes.
tonsurans, see tinea tonsurans.
zoster, see zoster.
High frequency, muffled, as a scar-softening agent, Becker (Abs.), 325.
Histogenesis of Roentgen and tar carcinomas, Ribbert (Abs.), 853.
Histopathology, Heimann (O.), 30, 109, 201, 366, 528, 664.
History of pellagra, Lavinder (Abs.), 250.
Hodgkin's disease, lymphogranulomatosis with pemphigoid ex- and enanthemata in connection with granulomatous skin nodules, Hoffmann (Abs.), 41.
Hospital, Psychopathic, syphilis and the, notes on medical and social progress, especially in neurosyphilis; Boston, Mass., 1915, Southard (Abs.), 412.
Hydroa vacciniforme, Whitehouse (S. Tr.), 381.
Hyperkeratoses, angiomata with, a study of the, Matsumoto (Abs.), 242.
Hyperkeratosis subungualis, Weiss (S. Tr.), 847.
Hypersensitiveness, specific, or allergy, in relation to certain eruptions of microbic origin, Adamson (Abs.), 629.
Hypertrichosis.
congenital, H. Fox (S. Tr.), 560.
of the sacral region, H. Fox (S. Tr.), 761.
treatment, X-ray, Pfahler (S. Tr.), 849.
variations in female secondary sexual characteristics, and internal secretions, McAuliff (Abs.), 701.
Hypertrophy.
fat, on the back of the hand, concerning, Hoffmann (Abs.), 40.
unilateral, or trophoedema of limbs, Pershing (Abs.), 246.

I

Ichthyosis.
alopecia areata and, Jackson (S. Tr.), 303.
Ichthyosis.
hystrix, H.Fox (S. Tr.), 695, 761.
Trimble (S. Tr.), 815.
Immunity.
scabies, from, Montgomery (O.), 90.
smallpox, duration of, after successful vaccination, Park (Abs.), 338.
Infantilism, and imperfect development of the bones, associated with, general macular and striated atrophy with teleangiectases of the skin, Gottheil (S. Tr.), 133.
Infection.
extragenital, and its prognosis, two notable cases of syphilis, with reference to, K. and E. Kottmaier (Abs.), 775.
latent syphilitic, of the lungs, Landis and Lewis (Abs.), 46.
syphilitic, among the general population, the value of the history, the clinical findings and the Wassermann reaction in the detection of, Hubert (Abs.), 568.
with tuberculosis from circumcision, Kudish (Abs.), 43.
Injections.
bacterial studies of the Taege method of sterilizing water for, with special reference to water errors and salt fever, Loeffler (Abs.), 321. (See salvarsan).
concentrated neosalvarsan and salvarsan sodium, Schumacher (Abs.), 38.
insoluble mercurial salt, study of the vehicles for, de Aja (Abs.), 571.
intracranial, intrathecal, of autoneosalvarsanized serum for syphilitic headache, Gordon (Abs.), 145.
intradural (old salvarsan), further studies in the treatment of syphilis of the nervous system by, Wile (Abs.), 247.
intramuscular.
of mercury salicylate in the treatment of syphilis, Best (Abs.), 579.
of whole blood in the treatment of purpura haemorrhagica, Emsheimer (Abs.), 701.
intraspinous.
of mercurialized auto-serum, treatment of cerebrospinal syphilis by, McCaskey (Abs.), 582.
intravenous, of benzoate of mercury in syphilis, Bizard and Klein (Abs.), 857.
intra-ventricular, of diarsenolized serum, treatment of paresis by, with presentation of cases, Knapp (Abs.), 868.

Injections.
morphine, multiple scarring from, (blue atrophy of the skin), Scheer for Fordyce (S. Tr.), 402.
neosalvarsan, exfoliative dermatitis following, Biné (Abs.), 868.
gunshot
of the head, concerning contra-lateral alopecia after, Klausner (Abs.), 140.
of the head, concerning contralateral alopecia following, Knack (Abs.), 234.
in the neighborhood of the adrenals, diffuse pigmentation of the skin (traumatic Addison's disease) following, Fischer and Leschcziner (Abs.), 235.
occupational, due to radium; report of cases, Ordway (Abs.), 701.
Inoculation.
animal.
of trichophyton discoides Sabouraud, Chalmers and MacDonald (Abs.), 152. (See tinea.)
auto.
eczema and generalized vaccinia from, Potter (S. Tr.), 549.
Intensimeter.
Furstenau, absorption measurements with the, Immelmann and Schutze (Abs.), 854.
Intradurally, mercuric chloride, a preliminary report on the use of, treatment of syphilis of the brain, Ireland and Wilson (Abs.), 49.
Iodide of potassium in syphilis, Montgomery (Abs.), 249.
Ionic medication, treatment of onychia by, Hugo (Abs.), 154.
Ionization, two cases of electrical burn successfully treated by, McGregor (Abs.), 156.
Irritation, as a factor in malignant tumor development, Rohdenburg (Abs.), 486.

K

Keloid.
after X-ray treatment, Geyser (S. Tr.), 226.
case of, Oulmann (S. Tr.), 618.
formation, acne with, Lapowski (S. Tr.), 464.
of the ears, H. Fox and Ochs (S. Tr.), 394.
Keratodermia, palmaris and plantaris, Wallhauser (S. Tr.), 395.
Keratohyaline, Kreibich (Abs.), 776.
Keratoses, arsenical, after salvarsan, Philip (Abs.), 567.
blennorrhagica, with report of a case, Haase (O.), 817.
follicularis.
Darier, Robinson (S. Tr.), 395. (See psorospermosis.)
case of, Ochs for Fox (S. Tr.), 222. (See psorospermosis.)
Darier, Trimble (S. Tr.), 395. (See psorospermosis.)
Darier, Whitehouse (S. Tr.), 394. (See psorospermosis.)
Darier, H. Fox and Ochs (S. Tr.), 395.
in its early stages, case of, Scheer (O.), 837.
palmaris et plantaris, Parounagian (S. Tr.), 697.
pigmentation and, arsenical, Fox (S. Tr.), 124.
Kerion.
celsi.
secondary lichenoid trichophytides in association with (lichen spinulosus trichophyticus), Rasch (Abs.), 628.
of the wrist, Fox H. (S. Tr.), 684.
Koilonychia, case of, Ochs (S. Tr.), 225.
Kromayer.
light applications, a case of ulerythema ophryogenes markedly improved by, Clark (S. Tr.), 608.
light, therapy, experiences with, Fujitani, Hirose and Nakayama (Abs.), 240.

L

Larva migrans, see creeping eruption.
Legs, eczema of the, Williams (S. Tr.), 552.
Leishmaniosis, cutaneous, two cases of, from Peru, Moran (Abs.), 570.
Lepers, toxicity of tubercle bacilli to, Sugai (Abs.), 240.
Lepra.
maculo-anaesthetic, Trimble (S. Tr.), 123.
Gottheil (S. Tr.), 693.
Rothwell (S. Tr.), 814.
Leprosy.
aetiology and treatment of, Chipman (Abs.), 49.
a national problem, Pollitzer (Ed.), 55.
case of, Blancard for Fordyce (S. Tr.), 396.
mixed type.
case of, Dearborn (S. Tr.), 396.
nodular type.
case of, Dearborn (S. Tr.), 395, 396.

Leprosy.
case of, Trimble (S. Tr.), 396.
illustrations of the history of, Montgomery (Abs.), 48.
its relation to Massachusetts, Honeij (Abs.), 51.
myxoedema and, Jerusalemy (Abs.), 142.
symptoms and diagnosis of, with report of cases, Morrow and Lee (Abs.), 48.
treatment, with cyanocuprol, Takano (Abs.), 864.
treatment of, recent developments in the, Heiser (Abs.), 486.
Lesions produced by arsenicals and their bearing on the problem of specific arsenic therapy, Brown (Abs.), 151.
Leucoderma.
acquisitum, centrifugum, vitiligo, an unusual variety of, Sutton (O.), 797.
palpebrarum, Bechet (S. Tr.), 559.
syphilitic, generalized, with alopecia, a case of, Bobovitch (Abs.), 328.
syphiliticum, Gottheil (S. Tr.), 133.
Leucoplakia, cheeks, of the internal surface of the, Landouzy (Abs.), 142.
Leukaemia.
lymphatic.
dermatitis herpetiformis in, Parounagian (S. Tr.), 126.
dermatitis herpetiformis with, Parounagian (S. Tr.), 692.
Leukonychia totalis, MacKee and Wise (S. Tr.), 690.
Lice, see pediculosis.
Lichen.
acuminatus, Heimann (S. Tr.), 763.
annularis, Whitehouse (S. Tr.), 553.
atrophicus et sclerosus, Sweitzer (S. Tr.), 621.
hypertrophicus, MacKee and Wise (S. Tr.), 560.
planus, Parounagian (S. Tr.), 697.
planus.
accompanied by bleb formation, Montgomery (O.), 748.
annularis, limited to the penis, Wise (S. Tr.), 396.
atrophicus, Robinson (S. Tr.), 812.
diffuse pigmentation of the scrotum in, Montgomery (O.), 499.
histopathology of, Heimann (O.), 528.
hypertrophicus, H. Fox and Pisko (S. Tr.), 473.
lichen ruber acuminatus associated with, Goldenberg (S. Tr.), 385.
Lichen.
of mouth and tongue, Pollitzer and Satenstein (S. Tr.), 396.
of the palms and soles, MacKee for Fordyce (S. Tr.), 317.
of penis and tongue, MacKee for Fordyce (S. Tr.), 397.
of unusual distribution, Wise (S. Tr.), 472.
simulating pityriasis rosea, Weiss (S. Tr.), 845.
treated with X-rays, MacKee for Fordyce (S. Tr.), 554.
universalis, Gottheil (S. Tr.), 471.
verrucae planae juveniles complicated with, an instance of, Culver (O.), 502.
verrucosus, Bechet (S. Tr.), 397.
ruber, acuminatus, associated with lichen planus, Goldenberg (S. Tr.), 385.
scrofulosorum, Clark (S. Tr.), 561.
spinulosus, folliculitis decalvans et, a case of, with report on microscopical findings, Beatty and Speare (Abs.), 143.
sclerosus et atrophicus, Sweitzer (S. Tr.), 621.
sclerosus, scleroderma circumscriptum and its relation to, Bizzozero (Abs.), 40.
Light.
action of, on the living cell, Schanz (Abs.), 236.
ultra-violet, studies on the effect of experimentally changed local conditions on the reaction of human skin to, Sobotka (Abs.), 321.
Limbs, unilateral hypertrophy or trophoedema of, Pershing (Abs.), 246.
Liniment, calamine, Pusey (O.), 826.
Lip.
gumma of the, MacKee for Fordyce (S. Tr.), 554.
lower, cavernous angioma of, Weiss (S. Tr.), 393.
ulcer of the, MacKee and Remer (S. Tr.), 464.
Liver.
acute yellow atrophy of, during syphilis, Bending (Abs.), 325.
Locomotor ataxia.
tabes and large serpiginous syphilide, Armstrong (S. Tr.), 621.
tabes dorsalis, broader view of, Sharkey (Abs.), 479.
treatment of, particularly the pains and paraesthesia, Bogrov (Abs.), 329.
Lousiness, see pediculosis.

Luetic, see syphilitic.
Luetin.
Noguchi's, in syphilis, on the intradermal reaction with, Perkel (Abs.), 320.
reaction, diagnosis of syphilis from the blood and the spinal fluid, including the, Kafka (Abs.,) 235.
Lungs.
latent syphilitic infection of, Landis and Lewis (Abs.), 46
syphilis of the, Easton (Abs.), 248.
Lupus.
carcinoma and Roentgen rays, Stümpke (Abs.), 624.
follicularis disseminatus, Nobl (Abs.), 323.
erythematosus.
acute, a case of, Barber (Abs.), 144.
blood picture in acute and chronic forms of, Spiethoff (Abs.), 775.
acutus, disseminatus, three cases of, Sjiri (Abs.), 240.
case of, Bechet (S. Tr.), 473.
Clark (S. Tr.), 848.
Gilchrist (S. Tr.), 392.
Hartzell (S. Tr.), 697.
extensive case of, Hartzell (S. Tr.), 230.
Knowles (S. Tr.), 850.
of mucous membrane of the mouth, Leviseur (S. Tr.), 397.
MacKee and Wise (S. Tr.), 136, 220.
MacKee and Satenstein (S. Tr.), 842.
Pardee (S. Tr.), 614.
Schamberg (S. Tr.), 467.
Stelwagon and Gaskell (S. Tr.), 468.
Strousse (S. Tr.), 851.
Weiss (S. Tr.), 471.
Weiss (S. Tr.), 618.
disseminatus, Abramowitz for Fordyce (S. Tr.), 397.
disseminatus, a case of, Sasakawa (Abs.), 242.
with psoriasis, Gottheil and Ochs (S. Tr.), 845.
other tuberculous skin diseases and, artificial sunlight treatment of, Rost (Abs.), 326.
pernio, Clark (S. Tr.), 761.
vulgaris.
case of, Bechet (S. Tr.), 693.
Goldenberg (S. Tr.), 560.
Gottheil (S. Tr.), 131.
Hailperin for Trimble (S. Tr.), 398.
disseminate, MacKee and Wise (S. Tr.), 847.
Ochs (S. Tr.), 845.
Parounagian (S. Tr.), 560.
Potter (S. Tr.), 550.
Lupus.
Schamberg (S. Tr.), 849.
Strauss (S. Tr.), 563.
Trimble (S. Tr.), 398.
case of, Walker (S. Tr.), 229.
Weiss (S. Tr.), 471.
Wise for Fordyce (S. Tr.), 610.
epithelioma and, Schamberg (S. Tr.), 565.
hypertrophicus, serpiginosus, H. Fox and Ochs (S. Tr.), 398.
on the sole of the foot, Kurita (Abs.), 240.
serpiginosus, H. Fox (S. Tr.), 398, 558.
treatment of, by carbon dioxide snow, Levchenkow (Abs.), 479.
Lymphangioma.
cavernous, combined with a cutaneous papillary lymphangioma, Leviseur (S. Tr.), 398.
circumscriptum, Clark (S. Tr.), 815.
circumscripum, Robinson (S. Tr.), 398.
cutaneous, papillary, cavernous lymphangioma combined with a, Leviseur (S. Tr.), 398.
Lymphoedema, elephantiasis-like, the lasting results of the surgical treatment of, Kondoléon (Abs.), 42.
Lymphogranulomatoses, Hodgkin's disease with pemphigoid ex- and enanthemata in connection with granulomatous skin nodules, Hoffman (Abs.), 41.

M

Manhattan Dermatological Society, Oct. 8, 1915, 128; Nov. 12, 1915, 220; Dec. 17, 1915, 469; Jan. 14, 1916, 617; Feb. 11, 1916, 677; Mar. 10, 1916, 685; Apr. 14, 1916, 841.
Manifestations.
gastro-intestinal, in syphilis, Bushwell (Abs.), 334, 410.
skin, herpes especially, in cerebrospinal meningitis, Scherber (Abs.), 39.
Malignancy, internal, acanthosis nigricaus as an indication of, Markley (Abs.), 47.
Malignant.
growths, inhibitive effect of X-rays upon, Kempster (Abs.), 154.
pustule, notes on three cases of, Miles (Abs.), 51.
Medication, ionic, treatment of onychia by, Hugo (Abs.), 154.
Medicine, internal, syphilis and, Banker (Abs.), 574.

Melanose en grains, Newman (S. Tr.), 399.
Melano-sarcoma, of the thumb, Oulmann (S. Tr.), 402.
Meningitis.
cerebrospinal, skin manifestations, especially herpes, in, Scherber (Abs.), 39.
meningococcus, with unusual purpuric manifestations; demonstration of the diplococcus in the skin, Sharpe (O.), 659.
Mental.
diseases, relation of syphilis to, Orton (Abs.), 582.
features, of congenital syphilitics, Bazeley and Anderson (Abs.), 411.
Mercurial, argulan, a new organic, Mentberger (Abs.), 39.
Mercuric chloride, intradurally, a preliminary report of the use of, treatment of syphilis of the brain, Ireland and Wilson (Abs.), 49.
Mercury.
augmenting the efficacy and tolerance of, in syphilis, Bouveron (Abs.), 143.
benzoate of, intravenous injections of, in syphilis, Bizard and Klein (Abs.), 857.
elimination in bichloride poisoning, Vogel and Lee (Abs.), 249.
intravenous administration of, in syphilis, Shaw (Abs.), 785.
salicylate.
in syphilis, the use of, a record of its influence on the Wassermann reaction in fifty cases, Nelson and Anderson (Abs.), 410.
intramuscular injections of, in the treatment of syphilis, Best (Abs.), 579.
salvarsan and, the treatment of recently acquired syphilis with, Montgomery (Abs.), 51.
salvarsan and sodium salvarsan, combined, treatment, Hoffmann (Abs.), 326.
salvarsan derivatives and, epifascial method of injecting, Wolbarst (Abs.), 785.
use of, in verrucae planae juveniles, White (O.), 361.
Mesothorium, radium and, preparations, instrumentarium for the application of highly active, Wichmann (Abs.), 853.
Method for estimating the protein content of cerebrospinal fluid, a practical, Pfeiffer (Abs.), 250.
Methods, of teaching syphilis, Corbett (Abs.), 150.
Mikulicz's, disease and syphilis, Theodoresco (Abs.), 327.
Minnesota Dermatological Society, Apr. 11, 1916, 620.
Molluscum.
contagiosum, Hartzell (S. Tr.), 698.
contagiosum, Potter (S. Tr.), 399.
contagiosum, Trimble (S. Tr.), 610.
Monilethrix.
a clinical and histological study, with a report of six cases and a review of the literature, MacKee and Rosen (O.), 444, 506.
Rosen (S. Tr.), 132.
Rosen for Fordyce (S. Tr.), 382.
Morpheosclerodermia, with recent acute symmetrical involvement of the soles of the feet, Pernet (Abs.), 488.
Morphoea.
acrodermatitis and, Bechet (S. Tr.), 690.
case of, Heimann (S. Tr.), 399.
Parounagian (S. Tr.), 400.
Trimble (S. Tr.), 399.
Weiss (S. Tr.), 135.
facial, O'Donovan (Abs)., 144.
white spot disease and, Pollitzer and Satenstein (S. Tr.), 400.
Mouth.
mucous membrane of the, lupus erythematosus of, Leviseur (S. Tr.), 397.
tongue and, lichen planus of, Pollitzer and Satenstein (S. Tr.), 396.
tongue and, a hitherto undescribed atrophy of the mucous membranes of the, Hazen (O.), 801.
Mucous membrane, of the mouth, lupus erythematosus of, Leviseur (S. Tr.), 397.
Mucous membranes, of the tongue and mouth, a hitherto undescribed superficial atrophy of the, Hazen (O.), 801.
Mumps, see parotiditis.
Mycetoma pedis, Semon (Abs.), 50.
Mycosis.
fungoides?, Fordyce (S. Tr.), 555.
fungoides.
Foster (S. Tr.), 620.
case of, Gottheil (S. Tr.), 222.
Kingsbury (S. Tr.), 691.
case of, Rosen (S. Tr.), 136.
Thomas (S. Tr.), 622.
early, clinically indistinguishable from parapsoriasis of Brocq, a case of, Wise and Rosen (O.), 95.
premycotic stage, Trimble (S. Tr.), 400.

Myxoedema.
leprosy and, Jérusalemy (Abs.), 142.
sclerodermia occurring in a case of, while under thyroid treatment, Sequeira (Abs.), 488.

N

Naevus.
anaemicus, Lane (O.), 602.
combined port wine and cavernous type of, Gaskill (S. Tr.), 564.
flammeus (port-wine mark), treatment of, and allied conditions, by filtered ultra-violet rays, employing the compression method of application, report of ten cases with two illustrations, Clark (Abs.), 780.
pigmentosus unius lateralis, Gaskill (S. Tr.), 232.
treated by desiccation, Pfahler (S. Tr.), 466.
unilateralis, H. Fox and Pisko (S. Tr.), 845.
verrucosus.
linearis, Wise (S. Tr.), 123.
linearis, MacKee and Wise (S. Tr.), 696.
Neoplasms, cutaneous, anatomic distribution of, VanBeuren (Abs.), 702.
Nails.
bullous and haemorrhagic eruption beneath the, H. Fox (S. Tr.), 764.
scaphoid, cured, Harris (S. Tr.), 615.
Negro.
psoriasis in a full-blooded, H. Fox (S. Tr.), 847.
Neosalvarsan, see salvarsan.
Nephritis, syphilitic, diagnosis and treatmen of, Munk (Abs.), 240.
Nervous system.
syphilis of the, what is the position to-day as to the value of blood and cerebrospinal fluids in the diagnosis of, Fisher (Abs.), 786.
syphilis of the, Fordyce (O.), 713.
central, syphilis of the, treatment of, Pamment (Abs.), 705.
syphilis of the, notes of a conference on the medical and social aspects of, Post (Abs.), 334.
syphilis of the, further studies in the treatment of, by intradural injections (old salvarsan), Wile (Abs.), 247.
central, syphilis, treatment of, Walker and Haller (Abs.), 863.
syphilis of the, treatment of, intraspinal administration of mercurialized serum in the treatment of, Hunt (Abs.), 866.
Neurasthenia, syphilitic, and its results, Gaucher (Abs.), 857.
Neurodermatitis.
lichen chronicus (Vidal), Trimble (S. Tr.), 400.
nodulosa, two cases of, Fabry (Abs.), 774.
verrucosa, Kreibich (Abs.), 776.
Neurodermatosis.
trichotillomania, report of two cases of this rare, Blaisdell (O.), 363.
Neurofibromatosis, Knowles (S. Tr.), 468.
Neurology, unsuspected syphilis in, Collins (Abs.), 575.
News item.
Clark, appointment, professor of dermatology at New York Post-Graduate Medical School and Hospital, 54.
Whitehouse, appointment, professor of dermatology at New York Post-Graduate Medical School and Hospital, 54.
Radium Sanitarium of New York, 365.
Heimann appointed adjunct attending dermatologist, Mt. Sinai Hospital, 365.
Simpson appointed associate dermatologist to Geo. Washington University Medical School and to Washington City Orphan Asylum, and dermatologist to Geo. Washington University Hospital Dispensary, 365.
Pollitzer appointed honorary physician to German hospital, 632.
Fox, H., appointed visiting dermatologist to German hospital, 632.
Graeser appointed assistant visiting dermatologist to German hospital, 632.
See also notices.
New York.
Academy of Medicine, Section on Dermatology, Oct. 5 and Nov. 8, 1915, 123; Dec. 7, 1915, 462; Feb. 1, 1916, 557; April 4, 1916, 695; May 2, 1916, 812.
Dermatological Society, Oct. 26, 1915, 114; Nov. 23, and Dec. 21, 1915, 305; Jan. 24, 1916, 549; Feb. 15, 1916, 607; March 29 and April 25, 1916, 758.
Nodules, granulomatous skin, lymphogranulomatoses (Hodgkin's disease) with pemphigoid ex- and enanthemata in connection with, Hoffmann (Abs.), 41.
Notice.
abstract department, 790.
send matters of personal interest to

Notice.
Dr. H. Fox, 616 Madison Ave., New York.

O

Obituary.
Henry Clay Baum, 873.
Charles Townshend Dade, 253.
George Thomas Jackson, 253.
Albert Neisser, 711.
James Clarke White, 339.
Bernard Wolff, 873.
Oidiomycosis, in California, with especial reference to coccidioidal granuloma, Dickerson (Abs.), 483.
Onychia.
paronychia and, pyogenic, from autoinfection of a patient suffering from sycosis, the causation of, Troitzki (Abs.), 44.
paronychia and, following salvarsan, Stetson for Fordyce (S. Tr.), 400.
treatment of, by ionic medication, Hugo (Abs.), 154.
Onychomycosis, case of, Ochs (S. Tr.), 222.

P

Paget's disease, extra-mammary, Potter (S. Tr.), 303.
Palate, hard, cavernous angioma of, Weiss (S. Tr.), 393.
Palms, soles and, lichen planus of the, MacKee for Fordyce (S. Tr.), 317.
Pancreas, syphilis of the, Walter and Sallis (Abs.), 329.
Paraffinoma, H. Fox (S. Tr.), 758.
of the face, Goldenberg (S. Tr.), 401.
Parakeratosis.
and its physicotherapy, three interesting cases of, Maki (Abs.), 627.
variegata, Wallhauser (S. Tr.), 843.
Paralysis.
general, see syphilis.
of arm, herpes zoster with, Weber (Abs.), 145.
Parapsoriasis.
Brocq and dermatitis psoriasiformis nodularis, Jadassohn, contribution to the study of, Hanawa and Nagi (Abs.), 240.
clinical and diagnostic standpoint, the disease from the; a brief report of five cases, Wise (Abs.), 148.
en gouttes, Lane (S. Tr.), 561.
in patches,
Wallhauser (S. Tr.), 389, 844.
Weiss (S. Tr.), 136.
Wise for Fordyce (S. Tr.), 401.
Parapsoriasis.
lichenoid type, Wise for Fordyce (S. Tr.), 401.
of Brocq, a case of mycosis fungoides clinically indistinguishable from, Wise and Rosen (O.), 95.
Parents, syphilis in the, as a cause of feeble-mindedness in the children, Goddard (Abs.), 581.
Paresis, see syphilis.
Paronychia.
after operation, H. Fox (S. Tr.), 765.
onychia and, following salvarsan, Stetson for Fordyce (S. Tr.), 400.
onychia and, pyogenic, from autoinfection of a patient suffering from sycosis, the causation of, Troitzki (Abs.), 44.
Parotiditis.
chickenpox, German measles and, a study of the fatality of, Williams (Abs.), 872.
Parotitis, syphilitica, Haslund (Abs.), 324.
Paste, bismuth, Beck's, employment of sterilized vaseline instead of, Dombrovski (Abs.), 777.
Pastes, Montgomery (O.), 596.
Pastille, Sabouraud, X-ray filters and, Savill (Abs.), 155.
Pathology, of syphilis, Fordyce (Abs.), 149.
Pediculosis.
corporis, different chemical means for the destruction of body lice, Rapchevski (Abs.), 777.
lousiness and its consequences, a simple preventive of, Eysell (Abs.), 43.
pubis.
Montgomery (Abs.), 871.
report of a case of invasion of the scalp by, Brault and Montpellier (Abs.), 143.
Pellagra.
Collier (Abs.), 705.
aetiology of, Page (Abs.), 249.
causation and treatment of, Bond (Abs.), 331, 710.
clinical report on the state of New York, Winfield (Abs.), 781.
dietary deficiency as the aetiological factor in, Vedder (Abs.), 862.
experimental, in the human subject brought about by a restricted diet, Goldberger and Wheeler (Abs.), 485.
general pathology of; with special reference to findings in the thyroid and adrenals, Morse (Abs.), 332.

Pellagra.
hereditary factor in, Davenport (Abs.), 861.
heredity of, a study of the, in Spartanburg County, South Carolina, Muncey (Abs.), 861.
history of, Lavinder (Abs.), 250.
incidence of, in Spartanburg County, South Carolina, and the relation of the initial attack to race, sex and age, Siler, Garrison and MacNeal (Abs.), 863.
its history, symptoms, causes, treatment, prevention, Cox (Abs.), 484.
notes on, McDonald (Abs.), 700.
prevention of, Goldberger, Waring, Willets (Abs.), 485.
review of the subject, with report of a case, Howland (Abs.), 703.

Pellagrins, who survived the initial attack, the subsequent history of, in Spartanburg County, South Carolina, Siler, Garrison and MacNeal (Abs.), 864.

Pemphigoid, ex- and enanthemata in connection with granulomatous skin nodules, lymphogranulomatoses (Hodgkin's disease) with, Hoffmann (Abs.), 41.

Pemphigus.
Potter (S. Tr.), 550.
Wallhauser (S. Tr.), 678.
chronicus, dermatitis herpetiformis (Duhring) and, contribution to the therapy of, Fischer (Abs.), 407.
foliaceus, clinical manifestations and pathology of, addition to my study of the, Fabry (Abs.), 322.
prurigineux, Hardy (dermatitis herpetiformis), Winfield (S. Tr.), 307.
vegetans, Hartzell (S. Tr.), 848.

Penis.
chancrellous ulceration of the, in an old syphilitic treated with neosalvarsan, possible confusion with a reinfection, Gastinel (Abs), 856.
horny growths of, Lane (S. Tr.), 557.
lichen planus limited to the, Wise (S. Tr.), 396.
tongue and, lichen planus of, MacKee for Fordyce (S. Tr.), 397.

Periostitis, syphilitic, H. Fox and Pisko (S. Tr.), 474.

Phimosis, chancre of the prepuce with, Gaucher, Bizard and Bralez (Abs.), 625.

Philadelphia Dermatological Society, Oct. 18, 1915, 228; Nov. 15, 1915, 464; March 20, 1916, 562; Feb. 21, 1916, 697; Apr. 17 and May 15, 1916, 848.

Phlebitis, luetica, Olson (S. Tr.), 621.

Phlegmasia alba dolens, syphilitic, Druelle and Blum (Abs.), 327.

Photo-chemical methods, calomel precipitation reaction and, measuring Roentgen rays with the, Grann (Abs.), 856.

Physicotherapy, parakeratosis and its, three interesting cases of, Maki (Abs.), 627.

Pigmentation.
diffuse, of the scrotum, in lichen planus, Montgomery (O.), 499.
keratosis and, arsenical, Fox (S. Tr.), 124.
of the skin, diffuse, following gunshot injuries in the neighborhood of the adrenals (traumatic Addison's disease), Fischer and Leschcziner (Abs.), 235.
scleroderma with unusual, MacKee and Wise (S. Tr.), 136.
unilateral, H. Fox and Ochs (S. Tr.), 689.
localized scleroderma, Fox, H. (S. Tr.), 308.

Pituitary, gumma of the, associated with lesions in the spinal cord which may represent early lesions of syringomyelia, Woolley (Abs.), 332.

Pityriasis.
lichenoides chronica (Juliusberg), clinical and experimental observations on a case of, Stokes (O.), 343.
rosea.
Bechet (S. Tr.), 684.
Oulmann (S. Tr.), 137.
Williams (S. Tr.), 309.
lichen planus simulating, Weiss (S. Tr.), 845.
rubra.
pilaris, Berger for Trimble (S. Tr.), 401.
Heimann (S. Tr.), 556.
in a colored boy, H. Fox and Pisko (S. Tr.), 401.

Poisoning.
bichloride, mercury elimination in, Vogel and Lee (Abs.), 249.
by crude coal tar, White (O.), 497.
from the prophylactic use of sulphur, and its prevention, Hesse (Abs.), 567.
pyrogallol, prophylaxis of, Bockhart (Abs.), 37.
resorcin, produced through external

Poisoning.
applications of the drug, Kyrle (Abs.), 39.
salvarsan, an unusual case of, Eberly (Abs.), 147.
Porokeratosis, peculiar form of, Matsumoto (O.), 489.
Postvaccinal psoriasis, a case of, Lane, 201.
Potassium, iodide of, in syphilis, Montgomery (Abs.), 249.
Pre-cancerous.
cancerous or, lesions of the skin, should all be excised?, Hutchins (O.), 27.
conditions of the skin, Engman (Abs.), 247.
Prepuce, chancre of the, with phimosis, Gaucher, Bizard and Bralez (Abs.), 625.
Program, American Dermatological Association, meeting of 1916, 477.
Prophylaxis.
examination and, for syphilitic patients and their families: methods of investigation at the Psychopathic Hospital, Boston, Mass., 1915, Wright (Abs.), 334.
in syphilis, individual, notes on the mode of contagion in syphilitic chancres and, Balzer and Barthélemy (Abs.), 569.
of pyrogallol poisoning, Bockhart (Abs.), 37.
Protein content of cerebrospinal fluid, a practical method for estimating, Pfeiffer (Abs.), 250.
Prurigo.
nodularis, Fox, G. H. (S. Tr.), 129.
Schamberg (S. Tr.), 564.
Williams (S. Tr.), 380, 607.
Pruritus.
ani, treatment for, Stone (Abs.), 865.
linguae et mucosae oris, Zelenev (Abs.), 242.
Psoriasis.
Whitehouse (S. Tr.), 767.
arthritis and, Bogrov (Abs.), 243.
as a sequel to acute inflammations of the tonsils, Winfield (O.), 441.
in a full blooded negro, H. Fox (S. Tr.), 847.
lichenoides, Lapowski (S. Tr.), 814.
lupus erythematosus with, Gottheil and Ochs (S. Tr.), 845.
postvaccinal, case of, Lane, 201.
treatment of.
tar-chrysophanic baths in the, Karuskin (Abs.), 328.
with horse serum, Perry (Abs.), 484.
Pubis pediculus, report of a case of invasion of the scalp by the, Brault and Montpellier (Abs.), 143.
Purpura.
MacKee and Wise (S. Tr.), 688.
haemorrhagica, MacKee and Wise (S. Tr.), 550.
(morbus maculosus Werlhofii): report of a fatal case of unknown origin, Kellogg (Abs.), 703.
treatment of, injections of whole blood in the, Emsheimer (Abs.), 701.
of several years' duration, Parounagian (S. Tr.), 131.
Purpuric condition, peculiar, of the lower extremities, Trimble (S. Tr.), 308.
Pyrogallol poisoning, prophylaxis of, Brockhart (Abs.), 37.

Q.

Quartz-lamp, see Kromayer light.

R.

Radiometer.
Corbett, Coolidge tube and the, MacKee and Remer (O.), 296.
values.
realization of, Kienböck (Abs.), 854.
some remarks on Kienböck's article, Schmidt (Abs.), 855.
Radiotherapy, see Roentgen ray.
Radium.
Field (Abs.), 337.
Tousey (Abs.), 783.
efficiency in non-malignant surgical conditions, Abbe (Abs.), 787.
mesothorium and, preparations, instrumentarium for the application of highly active, Wichmann (Abs.), 853.
occupational injuries due to: report of cases, Ordway (Abs.), 701.
recognition of its efficiency and a plea for more thorough investigation, Moriarta (Abs.), 578.
treatment.
at the Royal Infirmary, Edinburgh, during the year 1915, report on the, Turner (Abs.), 582.
of epithelioma, Kennedy (Abs.), 872.
Ravaut method, a modification of the technique in the injection of neosalvarsan by the, (Abs.), 141.
Ray, ultra-violet filtered, treatment of naevus flammeus (port wine

Ray.
mark) and allied conditions by, employing the compression method of application, report of ten cases with two illustrations, Clark (Abs.), 780.
Raying.
deep, of carcinoma.
by means of the Roentgen ray machine, Kock (Abs.), 237.
by means of Rontgen ray machines, Seuffert (Abs.), 236.
Raynaud's disease.
Ormsby (S. Tr.), 614.
disease, erythromelalgia and, the combination of, Radionicic (Abs.), 246.
report of a case of symmetrical gangraene of unusual severity, Hoyne (Abs.), 147.
secondary syphilis and, Gaucher, Bizard and Bralez (Abs.), 569.
syndrome of, and syphilis, Nicholas, Massia, Gate and Pillon (Abs.), 568.
syphilis and, Lisser (Abs.), 153.
Reaction.
Abderhalden dialyzing, results in the field of dermatology obtained by means of, Stuempke (Abs.), 41.
calomel precipitation, photo-chemical methods in general and, measuring Roentgen rays with the, Grann (Abs.), 856.
"cerebrospinal syphilitic" type, the development of the gold sol. "paretic" reaction as compared with the, considered from the time necessary to form a completed reaction, Solomon and Welles (Abs.), 412.
coagulation serodiagnosis of syphilis with chemical substances, von Dungern (Abs.), 566.
colloidal gold, a further study of the diagnostic value of the, together with a method for the preparation of the reagent, Miller, Brush, Hammers and Felton (Abs.), 700.
cutaneous.
experimental, with glandular extracts, Parhon and Santini (Abs.), 247.
local vaso-motor, Ebbecke (Abs.), 245.
food, anaphylactic in dermatology; preliminary report, Strickler and Goldberg (Abs.), 703.
gold sol. "paretic," as compared with the "cerebrospinal syphilitic" type, considered from the time necessary to form a completed reaction, the development of the, Solomon and Welles (Abs.), 412.
intradermal, with Noguchi's luetin in syphilis, on the, Perkel (Abs.), 320.
luetin, in the diagnosis of tertiary and latent syphilis, Hanes (Abs.), 330.
of food products, Strickler (S. Tr.), 565.
of human skin to ultra-violet light, studies on the effect of experimentally changed local conditions on the, Sobotka (Abs)., 321.
of skin to injections of agar, Stokes (S. Tr.), 616.
of the skin to stroking, the normal, a description of the phenomena and an explanation of its causation based on reason and experiment, Tracy (Abs.), 869.
skin, the inflammatory and urticarial, a clinical study, Samberger (Abs.), 138, 139, 140.
trichophytin, in the blood, Miescher (Abs.), 140.
Wassermann.
among hospital patients, the occurrence of the, Horner (Abs.), 412.
as a sign of cure, a case illustrating the fallibility of the provocative, Hazen (Abs.), 872.
concerning the diagnostic value of the, Bendig (Abs.), 322.
in fifty cases, the use of mercury salicylate in syphilis, a record of its influence on the, Anderson and Nelson (Abs.), 410.
influence of antisyphilitic treatment, particularly neosalvarsan, on the, Levy-Bing, Dogny and Gerbay, (Abs.), 46.
Recklinghausen's disease, see fibroma molluscum.
Rectum, buttocks and, syphilitic serpiginous ulceration of the, Merritt (Abs.), 413.
Reinfections.
syphilitic.
problems of, Parounagian (Abs.), 336.
pseudo-reinfection or, following salvarsan and mercury therapy, two cases of, Tieche (Abs.), 234.
study of thirty-one cases, de Laviergne (Abs.), 580.
Renal system, cardiovascular and, syphilis of the, Barach (Abs.), 148.
Resorcin poisoning produced through external applications of the drug, Kyrle (Abs.), 39.

Retractor for nail operations, H. Fox (S. Tr.), 766.
Rheumatism and the skin, Cunningham (Abs.), 248.
Rhinophyma after operation, H. Fox (S. Tr.), 556.
Rhinoscleroma.
case of.
Chargin (S. Tr.), 695.
Fox, G. H. (S. Tr.), 115.
Remer for Fordyce (S. Tr.), 401.
progress notes on a case previously reported, Alderson, 198.
Rice diet, use and abuse of the, Bulkley (Abs.), 577.
Ringworm, see tinea.
Roentgen.
carcinomas, tar and, histogenesis of, Ribbert (Abs.), 853.
dose, erythema, instrumental determination of the, Wachtel (Abs.), 855.
practical use of the selenium cell and the avoidance of some of its errors, Mayer (Abs.), 856.
radio-sensitiveness of the hair follicles in psoriasis, increased, Kienböck (Abs.), 854.
rays, absorption of, recording the, by a new graphic method, Weissenberg (Abs.), 855.
ray.
Addison's disease treated with X-ray, a case of, Ratera (Abs.), 414.
cooling of Roentgen therapy tubes with boiling water, Bucky (Abs.), 325.
depilation, second, in a case of tinea tonsurans, MacKee (S. Tr.), 118.
epithelioma cured by X-ray, two cases, Geyser (S. Tr.), 225.
filters.
Sabouraud pastille and X-ray filters, Savill (Abs.), 155.
some experiments with X-ray filters, Sequeira (Abs.), 153.
hard and soft X-rays, Russ (Abs.), 154.
heterogeneous, measuring, Christen (Abs.), 855.
inhibitive effect of X-rays upon malignant growths, Kempster (Abs.), 154
keloids after X-ray treatment, Geyser (S. Tr.), 226.
lichen planus treated with X-rays, MacKee for Fordyce (S. Tr.), 554.
lupus carcinoma and, Stümpke (Abs.), 624.
machine, deep raying of carcinoma by means of the, Kock (Abs.), 237.
Roentgen.
machines, deep raying of carcinoma by means of, Seuffert (Abs.), 236.
measurements.
technical, Holzknecht and Weissenberg (Abs.), 855.
with the selenium cell, Grann (Abs.), 856.
measuring with the calomel precipitate reaction and photo-chemical methods in general, Grann (Abs.), 856.
pastille, Sabouraud, and X-ray filters, Savill (Abs.), 155.
rays.
penetration of, measuring the, Kienböck (Abs.), 854.
ray.
radio-therapy, contribution to the knowledge of, Horiuchi and Sakamura (Abs.), 240.
radiotherapy.
its scientific basis and its teaching, Joly (Abs.), 155.
two cases of scrofuloderma and tuberculous fistulas cured by, Ratera (Abs.), 571.
treatment for hypertrichosis, Pfahler (S. Tr.), 849.
therapy in large measured doses, Hazen (Abs.), 51.
treatment.
tinea tonsurans showing peculiar effect of, MacKee and Wise (S. Tr.), 137.
of skin diseases, MacKee (Abs.), 408.
therapy.
an observation in connection with, Janus (Abs.), 324.
an observation in connection with, Kaestle (Abs.), 326.
dose measurement in, Schmidt (Abs.), 855.
massive dose, method of, Gray (Abs.), 780.
some theoretical considerations in the present status of, Shohan (Abs.), 869.
tube, gas free, of J. E. Lilienfeld, Holzknecht, Wachtel, Weissenberg and Mayer (Abs.), 240.
Roseola, syphilitic, limited to the soles, Montgomery (Abs.), 577.
Rubeola, chickenpox, mumps and, a study of the fatality of, Williams (Abs.), 872.

S.

Salvarsan.
a simple method of administering, Schumacher (Abs.), 38.

Salvarsan.
accidents after "606," recurrent specific, Bralez (Abs.), 856.
arsenical keratoses after, Philip (Abs.), 567.
death, a new cause of, from, Dreyfus (Abs.), 142.
deaths following, Lube (Abs.), 327.
derivatives. . mercury and, epifascial method of injecting, Wolbarst (Abs.), 785.
discussion of American, Canadian and French salvarsans (S. Tr.), 622.
in primary syphilis, Uhle and Mackinney (Abs.), 251.
injection, intravenous, apparatus for, Kauffman (Abs.), 782.
injections, notes on the use of adrenalin following, Schwarzman (Abs.), 142.
mercury and, the treatment of recently acquired syphilis with, Montgomery (Abs.), 51.
natrium, a new salvarsan preparation, Fabry and Fischer (Abs.), 235.
neo.
auto, intrathecal intracranial injection of autoneosalvarsanized serum for syphilitic headache, Gordon (Abs.), 145.
chancrellous ulceration of the penis in an old syphilitic treated with, possible confusion with a reinfection, Gastinel (Abs.), 856.
influence of antisyphilitic treatment on the Wassermann reaction, particularly, Levy-Bing, Dogny and Gerbay (Abs.), 46.
injections, exfoliative dermatitis following, Biné (Abs.), 868.
injection of, by the Ravaut method, a modification of the technique in the, Le Damany (Abs.), 141.
salvarsan sodium and, injections, concentrated, Schumacher (Abs.), 38.
neosalvarsan and, a comparison between, in relation to their efficacy in experimental syphilis, Copelli (Abs.), 38.
neosalvarsan and, the experimental study of, Nakano (Abs.), 240.
neosalvarsan.
technique, concerning the, of administering, Stern (Abs.), 141.
salvarsan and, a comparison between, in relation to their efficacy in experimental syphilis, Copelli (Abs.), 38.
onychia and paronychia following, Stetson for Fordyce, (S. Tr.), 400.

Salvarsan.
poisoning, case of, an unusual, Eberly (Abs.), 147.
regarding supply of, 632.
should salvarsan be used in syphilis in the presence of affections of the eye?, Ostroumov (Abs.), 45.
sodium.
and the combined mercury-salvarsan treatment, Hoffman (Abs.), 326.
neosalvarsan and, injections, concentrated, Schumacher (Abs.), 38.
sterilizing water for injections, with special reference to water errors and salt fever, bacterial studies of the Taege method of, Loeffler (Abs.), 321.

Salve, pellidol, eczema after the use of, Stoerzer (Abs.), 568.

Sarcoid.
Boeck, MacKee for Fordyce (S. Tr.), 391.
Boeck, MacKee for Fordyce (S. Tr.), 401.

Sarcoma.
cutis idiopathicum multiplex haemorrhagicum (Kaposi), Dagave (Abs.), 44.
idiopathic haemorrhagic.
(Kaposi), one presenting unusual features, with special methods of treatment and investigation, report of two cases of, Gilchrist and Ketron (O.), 429.
multiple, of the skin, Groigoryev (Abs.), 776.
(Kaposi), MacKee and Wise (S. Tr.), 684.
idiopathic multiple pigment, of Kaposi (acro-sarcoma multiplex cutaneum teleangiectodes of Unna), Weber (Abs.), 707.
inoperable, treatment of, Pfahler (S. Tr.), 852.
Kaposi, Kingsbury and Bechet (S. Tr.), 401.
Kaposi, Potter (S. Tr.), 402.
Kaposi, Snyder for Fordyce (S. Tr.), 402.
of the skin, multiple idiopathic haemorrhagic (Kaposi), Groigoryev (Abs.), 626.
of the toe, Ochs (S. Tr.), 227.
(perithelioma), Baughman for Trimble (S. Tr.), 392.

Scabies.
exposed, the artful acarus, Cunningham (Abs.), 148.
immunity from, Montgomery (O.), 90.
Norwegian, a second case of, Beatty (Abs.), 145.

Scalp.
body and, cicatrices of, from tuberculosis, Rothwell (S. Tr.), 814.
chronic inflammatory condition of the, Williams (S. Tr.), 317.
report of the invasion of the, by the pediculus pubis, Brault and Montpellier (Abs.), 143.
ringworm and favus of the, the prevention and treatment of, Lane (Abs.), 146. (See tinea.)

Scar, softening agent, muffled high frequency as a, Becker (Abs.), 325.

Scars, painful contractile, treatment of, Michaelis (Abs.), 237.

Scarlet fever, treatment of, with fresh blood from convalescent patients, Zinger (Abs.), 580.

Scarring.
multiple, from morphine injections (blue atrophy of the skin), Scheer for Fordyce (S. Tr.), 402.
reticulated, followed by comedo, MacKee for Fordyce (S. Tr.), 382.

Sclerodactylia, sclerodermia circumscripta, Rostenberg (S. Tr.), 403.

Sclerodermia associated with disease of the thyroid gland, four cases of, Sequeira (Abs.), 630.

Scleroderma.
Butler (S. Tr.), 621.
Gaskill (S. Tr.), 465.
Gottheil (S. Tr.), 383.
Heimann (S. Tr.), 402.
MacKee for Fordyce (S. Tr.), 120.
Recque for Fordyce (S. Tr.), 403.
case of, Walker (S. Tr.), 231.

Sclerodermia.
circumscripta; sclerodactylia, Rostenberg (S. Tr.), 403.

Scleroderma.
circumscriptum and its relation to lichen sclerosus, Bizzozero (Abs.), 40.
hemi, Josephovitch (Abs.), 480.
localized, unilateral pigmentation, Fox, H. (S. Tr.), 308.
with unusual pigmentation, MacKee and Wise (S. Tr.), 136.

Sclerodermia.
occurring in a case of myxoedema while under thyroid treatment, Sequeira (Abs.), 488.
with Graves' disease, Sequeira (Abs.), 708.

Scrofuloderma.
tuberculous fistulas and, cured by radiotherapy, two cases of, Ratera (Abs.), 571.
Bazin's disease and, Parounagian (S. Tr.), 558.

Scrotum, diffuse pigmentation of, in lichen planus, Montgomery (O.), 499.

Seborrhoea, relation of diets to, Montgomery (O.), 829.

Secretions.
internal, the relation of, to cutaneous disease, Foerster (O.), 1.
internal, the relation of, to cutaneous diseases, McEwen (O.), 15.

Selenium cell.
practical use of, and the avoidance of some of its errors, Mayer (Abs.), 856.
Roentgen ray measurements with the, Grann (Abs.), 856.

Sensitization to certain foods, erythematous and urticarial eruptions resulting from sensitization to certain foods, McBride and Schorer (O.), 79.

Serodiagnosis, of syphilis with chemical substances (coagulation reaction), von Dungern (Abs.), 566.

Serology.
diagnosis of syphilis and, Heidingsfeld (Abs.), 576.
syphilitic aortitis and its, a pathological study of, Larkin and Levy (Abs.), 630.

Serum.
auto, mercurialized, intraspinous injections of, treatment of cerebrospinal syphilis by, McCaskey (Abs.), 582.
autoneosalvarsanized, intrathecal intracranial injection of, for syphilitic headache, Gordon (Abs.), 145.
autoserum injections in skin diseases, the value of, Gottheil (Abs.), 782.
blood, proteolytic ferments of the, in tabes dorsalis and general paresis, Falls (Abs.), 701.
diarsenolized, intraventricular injections of, treatment of paresis by, with presentation of cases, Knapp (Abs.), 868.

Serum.
mercurialized, intraspinal administration of, in the treatment of syphilis of the nervous system, Hunt (Abs.), 866.
horse, treatment of psoriasis with, Perry (Abs.), 484.
immune, differences in behavior of, between cultivated non-virulent Treponema pallidum and virulent Treponema pallidum from lesions, Zinnser, Hopkins and McBurney (Abs.), 631.

Serum.
therapy, vaccine and, in diseases of children, Nabarro (Abs.), 480.
Sign, in diagnosing latent syphilis, a helpful, Voorhees (Abs.), 50.
Skin.
basal cell tumors of the, contribution to the question of, Kyrle (Abs.), 774.
bones and, tuberculosis of the, Steinke for Fordyce (S. Tr.), 404.
cancer and its treatment, Dyer (Abs.), 150.
cancer, of the extremities, Hazen (Abs.), 408.
certain surface affections of the, on sprays and spraying in the treatment of, Jamieson (Abs.), 858.
clinic of Leland Stanford, Jr., University School of Medicine, cases from the, Anderson (Abs.), 49.
colloid degeneration of the, Johnston and Paul (Abs.), 870.
diseases.
autoserum injections in, the value of, Gottheil (Abs.), 782.
roentgen-ray treatment of, MacKee (Abs.), 408.
treatment, intelligent, of the, Walsh (Abs.), 248.
tuberculous lupus and other, artificial sunlight treatment of, Rost (Abs.), 326.
excretions of the, the relations of the Staphylococcus albus and the acne bacillus to the epidermis and the, with special reference to the lesions of acne vulgaris, Benians (Abs.), 144.
particularly of tuberculous and syphilitic origin, orthostatic albuminuria and its relationship to, Arnold (Abs.), 45.
parasitic, differential blood counts in, and their possible significance, Strickler (O.), 752.
sugar content of the blood in various diseases of the skin, Schwartz, Heimann, and Mahnkin (O.), 159.
treatment of, calcium, a contribution to the, Hecht (Abs.), 408.
treatment of, progress in the, MacKee (Abs.), 414.
certain, of the, sugar content of the blood in, Pels (Abs.), 574.
of the, certain occupations as contributing factors to, White (Abs.), 868.
of the, radiant energy in the treatment of, Lain (Abs.), 409.
fatty layer of the, a unique case of atrophy of the, preceded by the ingestion of the fat by large phagocytic cells—macrophages, Gilchrist and Ketron (O.), 728.
grafting with an unusual result, a case of, Strandberg (Abs.), 40.
human, studies on the effect of experimentally changed local conditions on the reaction of, to ultraviolet light, Sobotka (Abs.), 321.
layers of the, a tabulation of the, Olson (O.), 543.
lesions.
cancerous or pre-cancerous, should all be excised?, Hutchins (O.), 27.
syphilitic and tuberculous, differentiation and treatment of, Gottheil (Abs.), 871.
tuberculous and syphilitic, differentiation and treatment of, Gottheil (Abs.), 871.
manifestations, herpes especially, in cerebrospinal meningitis, Scherber (Abs.), 39.
multiple idiopathic haemorrhagic sarcoma of the (Kaposi), Groigoryev (Abs.), 626.
nodules, granulomatous, lymphogranulomatoses (Hodgkin's disease) with pemphigoid ex- and enanthemata in connection with, Hoffmann (Abs.), 41.
pigmentation of the, diffuse, following gunshot injuries in the neighborhood of the adrenals (traumatic Addison's disease), Fischer and Leschcziner (Abs.), 235.
precancerous conditions of the, Engman (Abs.), 247.
preparation of, for microscopical study, Freeman (O.), 541.
reaction, the inflammatory and urticarial, a clinical study, Samberger (Abs.), 138, 139, 140.
reaction of, to injections of agar, Stokes (S. Tr.), 616.
reaction of, to stroking, the normal, a description of the phenomena and an explanation of its causation based on reason and experiment, Tracy (Abs.), 869.
resistance of the, diminished, Brocq (Abs.), 857.
rhemuatism and the, Cunningham (Abs.), 248.
venereal and, diseases, on the treatment of, in the field, Gennerich (Abs.), 42.
Smallpox.
chickenpox and, aetiology and laboratory diagnosis of, Force (Abs.), 333.

Smallpox.
immunity, duration of, after successful vaccination, Park (Abs.), 338.
inoculation of, as a prophylactic measure, as practiced by the natives at Djen in Nigeria, Foy (Abs.), 699.
Soles.
palms and, lichen planus of the, MacKee for Fordyce (S. Tr.), 317.
syphilitic roseola limited to the, Montgomery (Abs.), 577.
Spinal cord, lesions in the, which may represent early lesions of syringomyelia, gumma of the pituitary associated with, Woolley (Abs.), 332.
Spinal fluid, blood and the, including luetin reaction, the diagnosis of syphilis from the, Kafka (Abs.), 235.
Spinal manifestations of syphilis, Starr (Abs.), 411.
Spine, syphilis of the: its frequency and the value of its characteristic lesions as a diagnostic sign of syphilis, Whitney and Baldwin (Abs.), 573.
Spirochaetae.
certain alterations in biological properties of, through artificial cultivation, Noguchi (Abs.), 632.
pallidae.
agglutination, antibody formation against Treponema pallidum agglutination, Zinsser and Hopkins (Abs.), 153.
and syphilis, studies on, spirochaeticidal antibodies against Treponema pallidum, McBurney (Abs.), 631.
chemical aid in securing the, from syphilitic lesions, Lloyd (Abs.), 335.
culture of Treponema pallidum, notes on the, Zinsser, Hopkins, and Gilbert (Abs.), 152.
differences in behavior of immune serum between cultivated non-virulent Treponema pallidum and virulent Treponema pallidum from lesions, Zinnser, Hopkins and McBurney (Abs.), 631.
individual fluctuation in virulence and comparative virulence of Treponema pallidum strains passed through rabbits, Zinnser, Hopkins and McBurney (Abs.), 631.
Spotted fever, diagnosis of, Fraenkel (Abs.), 239.
treatment of, Levy (Abs.), 43.
Splenic enlargement, a study of, in early syphilis, Wile and Elliott (Abs.), 47.
Sprays, spraying and, in the treatment of certain surface affections of the skin, Jamieson (Abs.), 858.
Spraying, sprays and, in the treatment of certain surface affections of the skin, Jamieson (Abs.), 858.
Staphylococcus albus, acne bacillus and the, the relations of, to the epidermis and the excretions of the skin; with special reference to the lesions of acne vulgaris, Benians (Abs.), 144, 478.
Steam, use of, in the treatment of superficial cancer, Gillette (Abs.), 250.
Sterilizing water, Taege method of, bacterial studies of the, for injections, with special reference to water errors and salt fever, Loeffler (Abs.), 321.
Stomatitis, aphthous, persistent, H. Fox (S. Tr.), 474.
Sugar.
content, of the blood in certain diseases of the skin, Pels (Abs.), 574.
content of the blood in various diseases of the skin, Schwartz, Heimann, and Mahnken (O.), 159.
Sulphur.
colloidal, when, why and how to administer, Martinet (Abs.), 141.
poisoning from the prophylactic use of, and its prevention, Hesse (Abs.), 567.
Sycosis.
causation of pyogenic onychia and paronychia from autoinfection of a patient suffering from, Troitzki (Abs.), 44.
vulgaris, Stelwagon and Gaskill (S. Tr.), 466.
vulgaris, extensive case of, Gaskill (S. Tr.), 564.
vulgaris on upper lip of woman, Trimble (S. Tr.), 608.
Symptoms.
diagnosis and, of leprosy, with report of cases, Morrow and Lee (Abs.), 48.
visceral, in dermatoses of the exudative erythema type, the importance of, Foster (O.), 808.
Syncope, immediately after the administration of diarsenol, Likes and Schoenrich (Abs.), 784.
Syndrome, polyglandular, Goldenberg (S. Tr.), 387.

Synovitis, symmetrical, in hereditary syphilis, Post (Abs.), 411.
Syphilide.
annular macular, Fox, H. (S. Tr.), 311.
papulo-squamous, MacKee and Wise (S. Tr.), 560.
papular.
miliary, H. Fox (S. Tr.), 769.
miliary, H. Fox and Ochs (S. Tr.), 844.
serpiginous, tabes and large, Armstrong (S. Tr.), 621.
tertiary, case of, Ward (Abs.), 707.
zosteriform, Gaucher, Bizard and Bralez (Abs.), 626.
Syphilis.
a specific case given energetic persistent antisyphilitic treatment with no effect on the blood test, Fuller (Abs.), 484.
acquired, treatment of, with mercury and salvarsan, recently, Montgomery (Abs.), 51.
acute yellow atrophy of the liver during, Bendig (Abs.), 325.
Addison's disease of syphilitic origin, Shaffner and Howard (Abs.), 710.
chancres, a few typical, Bizard and Bralez (Abs.), 857.
adenopathy, epitrochlear, following, Levy-Franckel (Abs.), 143.
alopecia syphilitica, Montgomery (Abs.), 335.
among juvenile delinquents: its relation to mental status, the incidence of, Haines (Abs.), 702.
annular, case of, Ochs for Fox, H. (S. Tr.), 220.
as an aetiological factor in epilepsy, Shanahan (Abs.), 778.
bone, congenital and, Post (O.), 589.
cardiac, treatment of, Anders (Abs.), 709.
cardiovascular and renal systems, of the, Barach (Abs.), 148.
cerebral, treatment of, by prolonged intraspinal injection of serum under high pressure, a method of, Ayer (Abs.), 703.
cerebrospinal.
reactions and results of treatment in, Draper (Abs.), 866.
results and reactions of treatment in, Draper (Abs.), 866.
treatment of, by intraspinous injections of mercurialized auto-serum, McCaskey (Abs.), 582.
treatment of: the Ogilvie technique, Eastman (Abs.), 410.
chancre.
carunculi lacrimalis, Jampolsky (Abs.), 244.
Syphilis.
extragenital, Schamberg (S. Tr.), 848.
of the prepuce with phimosis, Gaucher, Bizard and Bralez (Abs.), 625.
of tongue, Davis (S. Tr.), 698.
chemical aid in securing Spirochaeta pallida from syphilitic lesions, Lloyd (Abs.), 335.
circinate, MacKee and Wise (S. Tr.), 618.
coagulation test for, as devised by Hirschfeld and Klinger, Cole and Chiu (Abs.), 482.
congenital.
Jones (Abs.), 783.
Walker (S. Tr.), 697.
adrenals in, Simmonds (Abs.), 245.
and its modern diagnosis, the present conception of, Rostenberg (Abs.), 786.
bone and, Post (O.), 589.
bones in, Post (O.), 351.
congenital? with tuberculide and recent attack of erythema nodosum, Heimann (S. Tr.), 403.
cure of, observations upon the, Reasoner (Abs.), 333, 410.
dermatologist, the proper teacher of, Zeisler (O.), 583.
diagnosis.
of, from the blood and the spinal fluid, including the luetin reaction, Kafka (Abs.), 235.
of, serology and the, Heidingsfeld (Abs.), 576.
experimental, a comparison between salvarsan and neosalvarsan in relation to their efficacy in, Copelli (Abs.), 38.
early, a study of splenic enlargement in, Wile and Elliott (Abs.), 47.
experimental, in the rabbit, produced by the brain substance of the living paretic, Wile (Abs.), 481.
gastro-intestinal manifestations in, Bushwell (Abs.), 334, 410.
generalized teleangiectasia with, Goldenberg (S. Tr.), 384.
gumma.
gangraenous syphilitic, of the thigh, Ravogli (O.), 353.
multiple, Bechet (S. Tr.), 684.
of the lip, MacKee for Fordyce (S. Tr.), 554.
of the pituitary associated with lesions in the spinal cord which may represent early lesions of syringomyelia, Wooley, (Abs.), 332.
of the tongue in a hereditary syphi-

Syphilis.
litic, nine years of age, presenting widely separated median superior incisors, Gaucher, Bizard and Balzer (Abs.), 625.
over clavicle, H. Fox, and Pisko (S. Tr.), 472.
multiple, Parounagian (S. Tr.), 694.
subcutaneous, Graeser (S. Tr.), 560.
heart in, Brooks (Abs.), 704.
hereditary.
early manifestations: from intrauterine life to one year of age, Kerr (Abs.), 581.
in children: later manifestations after the age of one year, LaFetra (Abs.), 581.
symmetrical synovitis in, Post (Abs.), 411.
virulent, occurring twenty years after syphilization of the mother, Gaucher, Bizard, Balzer and Delcamp (Abs.), 624.
incubation in, the length of the period of, from a medico-legal standpoint, Thibierge (Abs.), 858.
in epilepsy, Shanahan, Munson and Shaw (Abs.), 708.
in hypertensive cardiovascular disease, the rôle of, Stoll (Abs.), 46.
in the parents as a cause of feeblemindedness in the children, Goddard (Abs.), 581.
internal medicine and, Banker (Abs.), 574.
intravenous administration of mercury in, Shaw (Abs.), 785.
iodide of potassium in, Montgomery (Abs.), 249.
latent.
helpful sign in diagnosing, Voorhees (Abs.), 50.
tertiary and, the luetin reaction in, Hanes (Abs.), 330.
leucoderma syphiliticum, Gottheil (S. Tr.), 133.
marital reinfection in, Wright (S. Tr.), 622.
menace of, today to the family of tomorrow, Blaisdell (Abs.), 867.
mercury, augmenting the efficacy and tolerance of, in, Bouveyron (Abs.), 143.
Mikulicz's disease and, Theodoresco (Abs.), 327.
nervous, drainage of cerebrospinal fluid as a factor in the treatment of, Gilpin and Early (Abs.), 703.
neuro.
cellular content of cerebrospinal fluid in, the significance of changes in, Solomon and Koefod (Abs.), 412.
latent, the question of general paresis sine paresi, Southard and Solomon (Abs.), 412.
syphilis and the psychopathic hospital; notes on medical and social progress, especially in; Boston, Mass., 1915, Southard (Abs.), 412.
of the brain, treatment of, a preliminary report of the use of mercuric chloride intradurally, Ireland and Wilson (Abs.), 49.
of the central nervous system, the intraspinal treatment of, according to the method of Swift and Ellis, Dexter and Cummer (Abs.), 483.
of the central nervous system, treatment of, Pamment (Abs.), 705.
of the central nervous system.
treatment of, Walker (Abs.), 413.
treatment of, Walker and Haller (Abs.), 863.
of the lung, Easton (Abs.), 248.
of the nervous system.
Fordyce (O.), 713.
notes of a conference on the medical and social aspects of, Post (Abs.), 334.
intraspinal administration of mercurialized serum in the treatment of, Hunt (Abs.), 866.
pathognomonic changes of the cerebrospinal fluid in, Collins (Abs.), 482.
what is the position to-day as to the value of blood and cerebrospinal fluids in the diagnosis of, Fisher (Abs.), 786.
of the pancreas, Walter and Sallis (Abs.), 329.
of the spine: its frequency and the value of its characteristic lesions as a diagnostic sign of syphilis, Whitney and Baldwin (Abs.), 573.
of the stomach, Morris (Abs.), 779.
palmar and plantar syphiloderm, Parounagian (S. Tr.), 137.
paralysis, general, what clinical form of, most frequently ends in, Collins (Abs.), 143.
paresis.
general
sine paresi, latent neurosyphilis and the question of, Southard and Solomon (Abs.), 412.
tabes dorsalis and, proteolytic ferments of the blood in, Fall (Abs.), 701.
under intravenous arsenobenzol treatment, report on the clinical

Syphilis.
symptomatology and laboratory findings in three cases of, Mott and Bunker (Abs.), 869.
what form of syphilis most frequently ends in, Collins (Abs.), 143.
treatment of, by intra-ventricular injections of diarsenolized serum, with presentation of cases, Knapp (Abs.), 868.
parotitis syphilitica, Haslund (Abs.), 324.
pathology of, Fordyce (Abs.), 149.
phlebitis luetica, Olson (S. Tr.), 621.
prevalence of, Vedder (Abs.), 779.
primary.
late, Zelenev (Abs.), 480.
lesion, Wassermann reaction in the, Hecht (Abs.), 623.
salvarsan in, Uhle and Mackinney (Abs.), 251.
stage in, the treatment of, Keyes (Abs.), 149.
prophylaxis in, individual, notes on the mode of contagion in syphilitic chancres and, Balzer and Barthélemy (Abs.), 569.
psychopathic hospital and; notes on medical and social progress, especially in neurosyphilis; Boston, Mass., 1915, Southard (Abs.), 412.
pulmonary tuberculosis and, contact points between, Lyon (Abs.), 869.
Raynaud's disease and, Lisser (Abs.), 153.
reaction, intradermal, with Noguchi's luetin in, Perkel (Abs.), 320.
recurrent specific accidents after "606," Bralez (Abs.), 856.
relation of, to mental diseases, Orton (Abs.), 582.
renal and cardiovascular systems, of the, Barach, (Abs.), 148.
secondary.
case of, Davis (S. Tr.), 231.
Gottheil and Ochs (S. Tr.), 687.
Schamberg (S. Tr.), 563.
Raynaud's disease and, Gaucher, Bizard and Bralez (Abs.), 569.
treatment of, in the, Pollitzer (Abs.), 704.
serodiagnosis of, with chemical substances (coagulation reaction), von Dungern (Abs.), 566.
should salvarsan be used in syphilis in the presence of affections of the eye?, Ostroumov (Abs.), 45.
spinal manifestations of, Starr (Abs.), 411.
statistical study of, as seen in the outpatient department of the University of California hospital, Whitney (Abs.), 573.
studies, familial, the syphilis we see but do not recognize, and the importance of, Stoll (Abs.), 150.
suprarenal glands and, Sezary (Abs.), 143.
symposium on, discussion of the, 653.
syndrome of Raynaud's disease and, Nicholas, Massia, Gate and Pillon (Abs.), 569.
Tabes dorsalis and general paresis, proteolytic ferments of the blood in, Fall (Abs.), 701.
teaching, methods of, Corlett (Abs.), 150.
tertiary.
Gaskill (S. Tr.), 563.
Schamberg (S. Tr.), 466.
case of, Stelwagon and Gaskill (S. Tr.), 232.
latent and, the luetin reaction in, Hanes (Abs.), 330.
test for, a new and simple, McDonagh (Abs.), 788.
test for, urinary, and its comparison with the Wassermann reaction, Gray (Abs.), 784.
therapy, salvarsan and mercury, two cases of syphilitic reinfection or pseudo-reinfection following, Tiéche (Abs.), 234.
tracheobronchial, Arrowsmith (Abs.), 782.
transmission of, some observations on the; with particular reference to a paternal source of infection, Wile (O.), 645.
treatment.
galyl in the, Mescherski (Abs.), 244.
in the primary stage, Keyes (Abs), 149.
Smith (Abs.), 413.
intravenous injections of benzoate of mercury in, Bizard and Klein (Abs.), 857.
of, a preliminary report of the results of one hundred and five cases of syphilis, Marsh (Abs.), 581.
a rapid and successful, Bernheim (Abs.), 580.
by injections of strong solutions of bichloride of mercury, Karkushkin (Abs.), 627.
intradural injections (old salvarsan), further studies in the treatment of syphilis of the nervous system by, Wile (Abs.), 247.
intramuscular injections of mercury salicylate in the, Best (Abs.), 579.

Syphilis.
intraspinal arsenic, Hassan (Abs.), 574.
principles of the, Pollitzer (O.), 633.
three cases of, treated by "intramine" (di-ortho-amino-thio-benzine), McDonagh and Spence (Abs.), 705.
Treponema pallidum and, studies on, spirochaeticidal antibodies against Treponema pallidum, McBurney (Abs.), 631.
test for, (the emulsoid-gelatin, or the "gel" test), a new, McDonagh (Abs.), 859.
two notable cases of, with reference to extragenital infection and its prognosis, J. and E. Kottmaier (Abs.), 775.
ulceration, chancrellous, of the penis in an old syphilitic treated with neosalvarsan, possible confusion with a reinfection, Gastinel (Abs.), 856.
unsuspected, in neurology, Collins (Abs.), 575.
use of mercury salicylate in, a record of its influence on the Wassermann reaction in fifty cases, Anderson and Nelson (Abs.), 410.
we see but do not recognize, and the importance of familial studies, Stoll (Abs.), 150.

Syphilitic.
affections of the heart and aorta, certain, Anders (Abs.), 330.
analgesia, secondary, case of Fournier's, Rasch (Abs.), 860.
aortic disease, McCaskey (Abs.), 784.
aortitis.
aetiology of, Symmers and Wallace (Abs.), 865.
and its serology, a pathological study of, Larkin and Levy (Abs.), 630.
arthropathies, Higgins (Abs.), 330.
bursitis, with report of a case, Scott (Abs.), 632.
chancre.
notes on the mode of contagion in, and individual prophylaxis in syphilis, Balzer and Barthélemy (Abs.), 569.
of the upper gum in a woman, Sicilla (Abs.), 572.
chancres, notes on the mode of contagion in, and individual prophylaxis in syphilis, Balzer and Barthélemy (Abs.), 569.
child, tuberculous dactylitis in a, H. Fox and Ochs (S. Tr.), 404.

Syphilitic.
disease of the arteries, McPhedran (Abs.), 334, 410.
elephantiasis, Petrov (Abs.), 243.
gumma of the thigh, gangraenous, Ravogli (O.), 353.
headache, intrathecal intracranial injection of auto-neosalvarsanized serum for, Gordon (Abs.), 145.
hereditary, gumma of the tongue in a, nine years of age, presenting widely separated median superior incisors, Gaucher, Bizard and Balzer (Abs.), 625.
infection.
among the general population, the value of the history, the clinical findings and the Wassermann reaction in the detection of, Hubert (Abs.), 568.
latent, of the lungs, Landis and Lewis (Abs.), 46.
leucoderma, generalized, with alopecia, a case of, Bobovitch (Abs.), 328.
nephritis, diagnosis and treatment of, Munk (Abs.), 240.
neurasthenia and its results, Gaucher (Abs.), 857.
origin, tuberculous and, orthostatic albuminuria and its relationship to skin diseases, particularly of, Arnold (Abs.), 45.
patients and their families, examination and prophylaxis for; methods of investigation at the Psychopathic Hospital, Boston, Mass., 1915, Wright (Abs.), 334.
periostitis, H. Fox and Pisko (S. Tr.), 474.
phlegmasia alba dolens, Druelle and Blum (Abs.), 327.
reinfections.
problems of, Parounagian (Abs.), 336.
or pseudo-reinfection following salvarsan and mercury therapy, two cases of, Tiéche (Abs.), 234.
reinfections, study of thirty-one cases, de Laviergne (Abs.), 580.
roseola, limited to the soles, Montgomery (Abs.), 577.
serpiginous ulceration of the rectum and buttocks, Merritt (Abs.), 413.
therapy, the present condition of, Rostenberg (Abs.), 484.
tuberculous and, skin lesions, differentiation and treatment of, Gottheil (Abs.), 871.
ulceration, bilateral, of the tonsils, MacKee and Wise (S. Tr.), 555.

Syphilitics, congenital, mental features of, Bazeley (Abs.), 411.
Syphiloderm.
palmar and plantar, Parounagian (S. Tr.), 137.
tertiary, circinate, with negative Wassermann and with nodules and breaking down in the scar, case report, Gottheil (S. Tr.), 476.
Syringocystadenoma, MacKee for Fordyce (S. Tr.), 404.
Syringoma, case of, Paul and Adamson (Abs.), 858.
Syringomyelia, gumma of the pituitary associated with lesions in the spinal cord which may represent early lesions of, Woolley (Abs.), 332.

T.

Tabes dorsalis, see locomotor ataxia.
Tar.
carcinomas, Roentgen and, histogenesis of, Ribbert (Abs.), 853.
crude coal, poisoning by, White (O.), 497.
Tar-chrysophanic.
baths in the treatment of psoriasis, Karuskin (Abs.), 328.
Tattooing, erysipelas and, Mescerski (Abs.), 328.
Teaching, syphilis, methods of, Corlett (Abs.), 150.
Technique, Ogilvie, treatment of cerebrospinal syphilis, Eastman (Abs.), 410.
Teleangiectasia, generalized, with syphilis, Goldenberg (S. Tr.), 384.
Teleangiectases of the skin, associated with infantilism and imperfect development of the bones, general macular and striated atrophy with, Gottheil (S. Tr.), 133.
Test.
coagulation, for syphilis, as devised by Hirschfeld and Klinger, Cole and Chiu (Abs.), 482.
emulsoid-gelatin (or the "gel" test), for syphilis, a new, McDonagh (Abs.), 859.
for syphilis, (the emulsoid-gelatin, or the "gel" test), a new, McDonagh (Abs.), 859.
"gel," or the emulsoid-gelatine, a new test for syphilis, McDonagh (Abs.), 859.
Lange gold sol., diagnostic value of, based on 500 examinations of the spinal fluid, Solomon, Koefod and Welles (Abs.), 411.
urinary, for syphilis and its comparison with the Wassermann reaction, Gray (Abs.), 784.
Therapy.
arsenic, specific, lesions produced by arsenicals and their bearing on, Brown (Abs.), 151.
of herpes tonsurans, Salinger (Abs.), 236. (See tinea.)
of pemphigus chronicus and dermatitis herpetiformis (Duhring), contribution to the, Fischer (Abs.), 407.
quartz-lamp, experiences with, Fujitani, Hirose and Nakayama (Abs.), 240. (See Kromayer light.)
radio-, contribution to the knowledge of, Horiuchi and Sakamura (Abs.), 240.
Roentgen.
an observation in connection with, Janus (Abs.), 324.
an observation in connection with, Kaestle (Abs.), 326.
ray in large measured doses, Hazen (Abs.), 51.
some theoretical considerations in the present status of, Shohan (Abs.), 869.
serum and vaccine, in diseases of children, Nabarro (Abs.), 480.
syphilitic, the present condition of, Rostenberg (Abs.), 484.
vaccine, in acne vulgaris and furunculosis, Manugarianz (Abs.), 777.
Thigh, gumma of the, gangraenous syphilitic, Ravogli (O.), 353.
Thromboangeitis obliterans, presenile gangraene, Goodman and Bernstein (Abs.), 780.
Thumb, melano-sarcoma of the, Oulmann (S. Tr.), 402.
Thyroid.
adrenals and, general pathology of pellagra; with special reference to findings in the, Morse (Abs.), 332.
gland, sclerodermia associated with disease of the, four cases of, Sequeira (Abs.), 630.
treatment, sclerodermia occurring in a case of myxoedema while under, Sequeira (Abs.), 488.
Tinea.
barbae, treatment of, Beck (O.), 606.
capitis, see tinea tonsurans.
circinata of tropical origin, case of very extensive, Little (Abs.), 706.
problem of ringworm in children, Oliver (Abs.), 780.
ringworm of the hands and feet, Lane (Abs.), 484.

Tinea.
tonsurans.
bald ringworm, MacKee and Wise (S. Tr.), 127.
prevention and treatment of ringworm and favus of the scalp, Lane (Abs.), 146.
second X-ray depilation in a case of, MacKee (S. Tr.), 118.
showing peculiar effect of X-ray treatment, MacKee and Wise (S. Tr.), 137.
treatment and prevention of ringworm and favus of the scalp, Lane (Abs.), 146.
treatment of herpes tonsurans, Salinger (Abs.), 236.
Tissue, subcutaneous, multiple hydatid cysts in the, a notable case of, Jimeno (Abs.), 571.
Toe, sarcoma of, Ochs (S. Tr.), 227.
Tongue.
gumma of the, in a hereditary syphilitic, nine years of age, presenting widely separated median superior incisors, Gaucher, Bizard and Balzer (Abs.), 625.
mouth and.
a hitherto undescribed atrophy of the mucous membranes of the, Hazen (O.), 801.
lichen planus of, Pollitzer and Satenstein (S. Tr.), 396.
penis and.
lichen planus of, MacKee for Fordyce (S. Tr.), 397.
Tonsils.
acute inflammations of the, psoriasis as a sequel to, Winfield (O.), 441.
bilateral syphilitic ulceration of the, MacKee and Wise (S. Tr.), 555.
Treponema pallidum, see spirochaetae.
Trichokyptomania, Sutton (Abs.), 702.
Trichophytides, lichenoid, secondary, in association with kerion celsi (lichen spinulosus trichophyticus), Rasch (Abs.), 628.
Trichophytin, reaction in the blood, Miescher (Abs.), 140.
Trichophyton.
discoides, Sabouraud, animal inoculation of, Chalmers and MacDonald (Abs.), 152.
violaceum, varietas Khartoumense, Chalmers and MacDonald (Abs.), 152.
Trichotillomania, report of two cases of this rare neurodermatosis, Blaisdell (O.), 363.
Trophoedema, unilateral hypertrophy or, of limbs, Pershing (Abs.), 246.
Tube.
Coolidge, Corbett radiometer and the, MacKee and Remer (O.), 296.
Roentgen, gas free, of J. E. Lilienfeld, Holzknecht, Wachtel, Weissenberg and Mayer (Abs.), 240.
Tubercle bacilli, toxicity of, to lepers, Sugai (Abs.), 240.
Tuberculide.
case of, Parounagian (S. Tr.), 618.
Wallhauser (S. Tr.), 469.
erythema nodosum, recent attack, and congenital syphilis? with, Heimann (S. Tr.), 403.
papulo-necrotic, Pollitzer and Satenstein (S. Tr.), 404.
Tuberculoma, hypertrophic, diffuse, primitive elephantiasic tuberculosis or, Bosellini (Abs.), 572.
Tuberculosis.
cancer and, of the back of the hand, Lapeyre (Abs.), 141.
cicatrices of body and scalp from, Rothwell (S. Tr.), 814.
cicatrices of body and scalp from, Trimble (S. Tr.), 763.
cutaneous, MacKee for Fordyce (S. Tr.), 391.
cutis.
case of, Hartzell (S. Tr.), 230.
case of, Walker (S. Tr.), 229.
Winfield (S. Tr.), 404.
orificialis, Bechet (S. Tr.), 693.
verrucosa, Rothwell (S. Tr.), 814.
elephantiasic, primitive, diffuse hypertrophic tuberculoma or, Bosellini (Abs.), 572.
infection with, from circumcision, Kudish (Abs.), 43.
of the skin and bones, Steinke for Fordyce (S. Tr.), 404.
papulo-necrotic, Chargin for Goldenberg (S. Tr.), 557.
pulmonary, syphilis and, contact points between, Lyon (Abs.), 869.
verrucosa cutis.
Davis (S. Tr.), 852.
Weiss (S. Tr.), 404.
Tuberculous.
dactylitis in a syphilitic child, H. Fox and Ochs (S. Tr.), 404.
syphilitic and, skin lesions, differentiation and treatment of, Gottheil (Abs.), 871.
Tumor, malignant, irritation as a factor in development, Rohdenburg (Abs.), 486.
Tumors.
basal cell of the skin, contribution to the question of, Kyrle (Abs.), 774.
of the skin, multiple pigmented, Simpson (S. Tr.), 615.

Tumors.
sweat gland, two cases of, Alderton and Turnbull (Abs.), 50.
Typhus, diagnosis of, the constrictor as an aid to the, Dietsch (Abs.), 567.

U.

Ulcer.
of the face (self induced) in an hysterical woman, Marx (Abs.), 38.
of the lip, MacKee and Remer (S. Tr.), 464.
Ulceration.
bilateral, syphilitic, of the tonsils, MacKee and Wise (S. Tr.), 555.
chronic, in a boy, case of, Little (Abs.), 707.
of the rectum and buttocks, syphilitic serpiginous, Merritt (Abs.), 413.
Ulcus molle ani, in a boy, Pospielov (Abs.), 778.
Ulerythema.
ophryogenes, markedly improved by Kromayer light applications, a case of, Clark (S. Tr.), 608.
reticulated.
atrophy of the skin of the face, Parounagian (S. Tr.), 463.
scarring followed by comedo, MacKee for Fordyce (S. Tr.), 382.
Urticaria.
formalin, Heidingsfeld (O.), 303.
general acute, rare case of, Sodachev (Abs.), 778.
pigmentosa.
case of, Bechet (S. Tr.), 685.
Clark (S. Tr.), 767.
Clark for Whitehouse (S. Tr.), 767.
case of, MacKee for Fordyce, S. Tr.), 120.
Rothwell for Kingsbury (S. Tr.), 558.
Stillians (S. Tr.), 615.
Trimble (S. Tr.), 405.
treatment of, contributions to the, compressed tablets of calcium chloride, Seifert (Abs.), 139.
Uterus, breast and, the lasting results of the combined treatment of carcinoma of the, Klein (Abs.), 42.

V.

Vaccinia, generalized eczema and, from auto-inoculation, Potter (S. Tr.), 549.
Vaccination, duration of smallpox immunity after successful, Park (Abs.), 338.
Vaccine, serum and, therapy in diseases of children, Nabarro (Abs.), 480.
Vaccines, the treatment of eczema with special reference to the use of, and the part played by bacteria in its aetiology, Medalia (Abs.), 52.
Varicella.
mumps, German measles and, a study of the fatality of, Williams (Abs.), 872.
smallpox and, aetiology and laboratory diagnosis of, Force (Abs.), 333.
Vaseline, sterilized, employment of, instead of Beck's bismuth paste, Dombrovski (Abs.), 777.
Vehicles for insoluble mercurial salt injections, study of the, de Aja (Abs.), 571.
Venereal, skin and, diseases, on the treatment of, in the field, Gennerich (Abs.), 42.
Vermin, destruction of, among the masses and militia, Zaucilow (Abs.), 777.
Verrucae.
planae juveniles.
complicated with lichen planus, an instance of, Culver (O.), 502.
the use of mercury in, White (O.), 361.
Verruga peruviana, differential diagnosis of, Strong, Tyzzer, and Sellards (Abs.), 152.
Vitiligo.
Gaskill (S. Tr.), 565.
unusual variety of (leucoderma acquisitum centrifugum), Sutton (O.), 797.

W.

Wassermann.
negative, tertiary circinate syphiloderm, with nodules and breaking down in the scar and with, case report, Gottheil (S. Tr.), 476.
reaction.
among hospital patients, the occurrence of the, Horner (Abs.), 412.
as a sign of cure, a case illustrating the fallibility of the provocative, Hazen (Abs.), 872.
in fifty cases, the use of mercury salicylate in syphilis, a record of its influence on the, Anderson and Nelson (Abs.), 410.
in the detection of syphilitic infection among the general population, the value of the history, the clinical findings and the, Hubert (Abs.), 568.

Wassermann.
in the primary lesion of syphilis, Hecht (Abs.), 623.
influence of antisyphilitic treatment, particularly neosalvarsan, on the, Levy-Bing, Dagny and Gerbay (Abs.), 46.
urinary test for syphilis and its comparison with the, Gray (Abs.), 784.
test, in the medical dispensary, Moore (Abs.), 673.

Water.
sterilizing, Taege method of, bacterial studies of the, for injections, with special reference to water errors and salt fever, Loeffler (Abs.), 321.

White spot disease.
case of, Heimann (S. Tr.), 383, 758.
Trimble (S. Tr.), 813.
morphoea and, Pollitzer and Satenstein (S. Tr.), 400.

Whitlow, diphtheritic, Rolleston (Abs.), 859.

X.

Xanthoma.
Trimble (S. Tr.), 405.

Xanthoma.
planum diabeticorum, Wallhauser (S. Tr.), 379.
tuberosum et planum et linearis, Rosen (S. Tr.), 681.

Xeroderma pigmentosum, Ochs (S. Tr.), 405.

X-ray, see Roentgen ray.

Y.

Yaws.
bouba, Filho (Abs.), 244.
familial, Davis (S. Tr.), 466.
treatment of, internal, notes on the, Castellani (Abs.), 151.

Z.

Zoster herpes.
associated with a generalized eruption of varicella-like spots; one of the cases followed by oculomotor paresis; mydriasis and frontal anaesthesia, Weber (Abs.), 629.
femoralis, Parounagian (S. Tr.), 685.
following osteopathic manipulation of the spine, H. Fox (S. Tr.), 773.
recurrent, of the face with hemiatrophy, Trotter (Abs.), 488.
with paralysis of arm, Weber (Abs.), 145.

THE JOURNAL OF
CUTANEOUS DISEASES

VOL. XXXIV. JANUARY, 1916 No. 1.

THE RELATION OF INTERNAL SECRETIONS TO CUTANEOUS DISEASE.*

BY O. H. FOERSTER, M.D., MILWAUKEE.

FOR many years the ductless glands have engaged the speculative interest of numerous investigators. The relation of these organs to the rest of the body in health and in disease was but vaguely understood until two decades ago, since which time they have assumed a position of continually increasing importance. It has been established that practically all activities of the human body are intimately associated with the functions of the ductless glands, and it follows that without an understanding of their physiology and pathologic physiology an intelligent interpretation of the body functions in health and in disease is not possible. As a result of the mass of facts now available, many insufficiently founded, though time-honored, conceptions of human physiology will have to be discarded, perhaps chief among which is the "reflex" theory of nervous activity in its relation to the causation of disease. Dermatology has been handicapped by the assumption that, as Pollitzer[1] well puts it, "in some obscure and anatomically impossible way" an internal disorder "was supposed to cause a skin disease through the medium of the nervous system." Similarly, the changes observed in the organism consequent upon the cessation of the secretion of the sexual organs, as the result of their removal or physiologic suppression at the climacteric, were ascribed to nervous reflex action. As long as the only known organic relationships were those effected by means of the nervous system, such hypotheses were allowable, but in the light of recent knowledge concerning the ductless glands and their interrelated actions, we must revise our conceptions to accord with the facts.

* Read before the 39th Annual Meeting of the American Dermatological Association, New York City, May 13-15, 1915, as part of a symposium. This paper is concerned with a general consideration of the subject and with the thyroid and parathyroid glands in particular.

It has long been known that the various organs of the body are in reciprocal relation with each other through the agency of the nervous and circulatory systems. For many years it was believed that the nervous system alone was concerned in the control and regulation of the coördinated activities of the organs necessary to maintain their interbalance and the functional equilibrium of the entire organism. The part played by the blood stream began to be dimly realized when Claude Bernard, in 1855, expressed the view that every organ of the body, by a process of internal secretion, contributed its products to the blood and thereby determined its composition, and under certain conditions could modify or change it.[2] Bernard showed that the liver, in addition to producing an external secretion of bile, also possessed glycogenic function in that it contributed sugar to the blood stream. Brown-Sequard developed the view of Bernard and, in 1869, gave definite expression to the doctrine of "internal secretions," although he was not able to substantiate his views until twenty years later. The well known experiments with subcutaneous injections of testicular extract performed on himself, not only proved the existence of a process of internal secretion. which is in the nature of a chemical interchange between the different organs, but were the first applications of a new method of treatment. An extensive field for physiologic research was hereby opened, and a path provided for the proper interpretation of many pathologic derangements.[3]

Animal experiments of recent date, and investigations and observations in the human being, have greatly increased our knowledge concerning the activity of the ductless glands. The existence of an interrelationship between these glands and other organs has been established, compensatory actions of the glands have been proven, and the knowledge concerning the chemistry of the secretions themselves has been applied.

Certain functions of organs are excited by definite chemical substances which, as products of other organs, gain access to the activated organ by means of the blood stream. The production of these chemical substances and their discharge into the circulation constitute the process which has been termed "internal secretion."[4] Biedl says that, "Each organ, each tissue, and even each cell, by means of its specific secretory products, acting through the agency of the blood stream, is enabled to exert a definite influence upon other parts of the body."

The actual existence of an intermediary agent in the functional corelation of the various organs was definitely established by the classical experiments of Bayliss and Starling,[5] in 1902. It had been shown that the introduction of acid into the small intestine is followed by an increase

in the secretion of pancreatic juice, even when all nerve connections have been destroyed, and further, that acid introduced into the blood stream has no effect on the secretion. From this, Bayliss and Starling concluded that an activating substance is produced by the acid in the intestinal mucosa, and is then conveyed by the blood to the pancreas. A saline extract of the intestinal mucosa was treated with hydrochloric acid and injected into the blood stream of an animal,whereupon an immediate and copious secretion of pancreatic juice was produced. To the specific intermediary agent or chemical stimulant concerned in this process, Bayliss and Starling gave the name "secretin," and they further proposed that the name "hormone" should be given to those physiologic substances which act as chemical stimuli and serve as intermediaries between different parts of the body. By this experiment the existence of a hormone formed in the alimentary tract was definitely establishd for the first time, and it has proved to be the foundation upon which has since been erected the entire subject of hormones and the essential part played by them in the functions of the body.

All organs which produce substances capable of exciting or in any way affecting the functions of other organs, are described as "hormone-producing," organs of internal secretion, or endocrinous organs. These do not include, however, the organs concerned in producing the morphologic elements of the blood (as the spleen, lymph glands, and bone marrow), for the changes in the blood produced by them are not of an internal secretory nature.[6]

There is a division of opinion as to which organs are to be properly designated as organs of internal secretion. From the strictly morphologic viewpoint, only those tissues are regarded as possessing a true secretory value which are composed of histologically differentiated epithelial cells, whether present singly or in groups, and the term "internal secretory gland" is considered as applicable only if the excretory duct is absent. A division on this basis is impracticable, for in following out this idea certain structures would be excluded, such as the chromaffin tissue, which is neither epithelial nor glandular, but which is, nevertheless, known to have an internal secretory activity.[6] In the present state of the subject, it appears advisable to do no more than give a list of the internal secretory organs, which, according to Biedl, includes: the thyroid gland, the parathyroid, the thymus, the two suprarenal systems, with the carotid and coccygeal glands, the pituitary gland with the pineal gland, the spleen, the sexual glands and other tissues concerned in the process of reproduction, the pancreas, the intestinal and gastric mucosa and the kidneys. The liver, although forming many intracellular fer-

ments and several antitoxic substances, does not appear to form hormones in the strict sense of the word.

Under the strict conception of internal secretion there cannot be included a large group of chemical adjustments which occur in response to the introduction of drugs or poisons into the body, or to the measures adopted by the organism to guard against auto-intoxication. Neither is the term applicable to the processes by which antitoxines and antibodies are formed, although these are the result of a modification of the chemical activity of the tissues, in which the most important part is played by the internal secretion of the cells (Biedl).

According to the manner in which their secretions act, the internal secretory organs have been divided into two principal groups: the nutritive and the regulatory or stimulatory (Gley[7]). The nutritive, or productive, internal secretions "are the nutritive material of the organs and are derived by the chemical agency of the intestinal wall from the foodstuffs. A large number of these substances act also as hormones and exert a modifying influence upon the very processes by which they are changed and consumed" (Biedl). The second group, or true hormones, are either assimilatory or disassimilatory (anabolic or katabolic) in function, and all the known hormones can be included in one of these two classes. "The promotion of growth supplies an example of an assimilatory hormone, which, at the same time, exerts an inhibitory influence upon disassimilation. In the case of retardation of growth, the process is reversed. Every increase in normal activity, whether this be an improved secretion, a stronger muscular action, or any other augmented performance, is always associated with an increased disassimilation, which is the work of a disassimilatory hormone" (Biedl). Hormone action is, in general, therefore concerned with the increase or diminution of function, and the alteration of nutrition or rate of growth. Undoubtedly a specific selective attraction is manifested by certain organs for the hormones which activate them; and it is quite reasonable to imagine the blood-serum as a far more complex solution than has hitherto been presumed, containing, in addition to its cells, salts, opsonins, and other related substances, scores of hormones at one time, each of which is appropriated by the cells of those organs which are specifically stimulated by it."[8]

The origin of the hormone is not entirely clear. Certain end-products of metabolism, such as carbon dioxide, are known to play an important part in the accomplishment of chemical correlations, and act as hormones. Others are originated as a result of complex synthetic processes. Starling has indicated that hormones are crystalloid rather than colloid, and that

they are thermo-stabile, differentiating them from ferments and enzymes. They are not antigens, though active in minimal quantities, and they never provoke the formation of antibodies. It is readily seen that these negative properties are essential in an agent, such as the hormone, concerned in the production of rapid adjustments and the frequent repetition of the same form of activity.[9]

The interrelation existing between the internal secretions, or the hormone balance, is vitally concerned with the maintenance of the functional equilibrium of the body. A physiologic balance, which may be readily disturbed, is maintained between the activities of the different glands. There may, however, be a hypersecretion and a hyposecretion indicative of quantitative hormone change, and a dyssecretion or perversion of any hormone, each exerting a specific effect upon metabolism. Furthermore, it has been shown that certain of the secretions are antagonistic in their action, while others are synergists. The internal secretions of the pancreas and thyroid gland are antagonists, and "in hyperthyroidism the function of the pancreas is depressed and alimentary glycosuria is easily brought about. On the other hand, in atrophy or hyperplasia of the thyroid gland the pancreatic powers are increased, and patients suffering from these disorders—for instance, myxœdema—can take large quantities of glucose without the slightest glycosuria."[10] When the pancreas is removed the thyroid function predominates. The adrenals, through the chromaffin hormone, stimulate the sugar-producing mechanism of the liver and act as antagonists to the pancreas, while adrenals and thyroid mutually stimulate each other.

The functional relationship of organs may be expressed in compensatory hypertrophy produced by vicarious intervention, even of entirely different tissue structures, consequent upon under-activity of the related organ. Such is the case in the hypertrophy of the pituitary, as not infrequently found at autopsy, accompanying thyroid atrophy in myxœdema, or occurring after thyroid extirpation. It is generally believed that the thyroid normally exerts an inhibitory effect upon the pituitary, especially its posterior lobe, and that the cessation of this influence results in the hypertrophy described.

The reproductive organs are in close relationship with the thyroid, thymus, pituitary and adrenal glands, and there is a further complicated interaction between the hormones produced by these and other glands. As familiar expressions of these interrelations there need be cited only the thyroid enlargement occurring during pregnancy and menstruation, the sex depression observed in myxœdema, and the persistence of the thymus in eunuchs and its atrophy at puberty.

A marked influence is likewise exerted by the ductless glands upon the neuromuscular system, which is stimulated by one group,— the thyroid, testicles, pituitary and adrenals,—and depressed by another,—the pancreas, parathyroids and thymus. Although hormone production is not under control of the will, the production of adrenalin may be stimulated by psychic states, such as rage, fear or pain, as has been established experimentally by Cannon.[11]

A most important interrelation and one of especial interest to the dermatologist, is that existing between the sympathetic system and the ductless glands. The connecting link is found in the chromaffin tissue, which is widely distributed,—in the medulla of the adrenals, in the sympathetic ganglia and plexuses, aortic and carotid bodies, prostate, ovary, kidney, ureter. This chromaffin system is intimately allied to the sympathetic system in embryologic derivation and in location, and through its secretion has a specific action solely on tissues innervated by the sympathetic system, that is, on non-striped muscle fibres. This tissue, under normal conditions of secretion, is thereby kept in a normal state of tone. If the adrenal secretion is defective or excessive, there is a corresponding loss or pathologic increase of sympathetic tone. The action of adrenin is on sympathetic end-mechanism and not on centres, and its action is antagonized, neutralized or compensated by other substances normally produced in the organism, such as cholin, which act preferably on the autonomous or aprasympathetic system.[12]

Through their sympathetic nerve supply the other organs of internal secretion are subject to control by the internal secretion of the chromaffin system. For example, the thyroid is supplied with vaso-constrictor and vaso-dilator nerves, and on these, whichever is the sympathetic group, adrenin has a stimulating action. Similarly, an intimate relation is known to exist between the adrenals and the pancreas.[12]

The close association of the sympathetic and the ductless gland system is well expressed from the dermatologic viewpoint in the group of angioneurotic diseases. Disorders of sympathetic innervation of the vascular system are obviously present in such conditions as Raynaud's disease, local asphyxia, symmetrical gangræne, scleroderma, acroparæsthesia, angioneurotic œdema, menstrual urticaria and herpes, dermatographism and others, and it is at least suggestive that affections of one or other internal secretory glands are frequently observed in connection with these conditions.

Disease of the thyroid is noted frequently in scleroderma. Cold, dry skin, a condition of constant chilliness, and a malar flush are observed in myxœdema. Local asphyxia, or "dead finger," is noted especially in

women with disordered thyroid function, and vasomotor irritability is a constant accompaniment of hyperthyroidism. The involution of ovarian activity at the climacteric is often accompanied by marked vasomotor disturbances in the skin, which may favor the development of rosacea, and aggravate an existing erythematous lupus and other cutaneous conditions.

The employment of organic extracts in a therapeutic way was the logical sequel of experimental animal research and found its first application in 1891 in myxœdema. Success in this field led to their use in physiologic experiments in the belief that study of the physiologic aspects of organic extracts would reveal the specific properties of the internal secretions. But this method contains sources of error, inasmuch as an organic extract is a mixture of substances, the chemical properties of which are by no means clearly defined. Conclusions as to the physiologic activity of any organic extract are to be based upon the recognition of the exact chemical character of its specific active principle, and of its presence in the tissue as well as in the venous blood of the gland. Only when these conditions are met can it be stated that the substance in question is the product of the internal activity of a certain organ.[13] "The number of substances of the presence of which in the venous blood incontrovertible proof has been obtained, is only four," according to Gley[7]; namely, "the pancreatic element which regulates normal glycæmia, hepatic antithrombine, secretin and adrenalin." But there are some who hold that the specificity of iodothyrin and hypophysin is likewise established. In contrast with the small number of "proved" hormones, there are an indefinite number of "hormones of unknown composition which have been either proved or assumed to exist, and which are held responsible for certain well known correlations of function." Among these are "a hormone produced in the thymus, which controls, possibly, in some way, the development of the reproductive organs; a hormone produced in the fœtus in utero, which stimulates the growth of the mammary glands; a hormone in the ovary, which controls the growth of the uterus and the processes of menstruation" (Howell, quoted by Harrower[8]), and many others.

It is apparent from what has thus far been learned in regard to the internal secretions, that a rich field for investigation has been barely opened, the further development of which will exert a profound influence on every phase of medicine. Dermatology has already experienced this influence, as is witnessed by the more or less empirical use of organic extracts in dermatologic therapeutics, but much still remains to be done

in the application of the doctrine of internal secretions to clinical dermatology.

The thyroid gland has been called the "keystone of the endocrinous system," which well epitomizes its intimate relation to the numerous hormone-producing glands. The end-product of its secretory activity is supplied to the blood as an iodized albuminoid, named iodothyrin, which acts as a hormone. Iodine is the most characteristic and important chemical constituent of the thyroid, and the therapeutic activity of thyroid extracts varies directly with their iodine content. Iodine is not the active principle, however, and it cannot be used as a substitute for the thyroid hormone. The thyroid secretion promotes katabolism and increases normal function. The disassimilatory action principally affects the metabolic processes, the cardiac activity, parts of the sympathetic system, and the pituitary and suprarenal glands. In addition it exerts an inhibitory function, as is evidenced by the promotion of skeletal growth, the development of the sexual glands, and the limitation of the internal secretory function of the pancreas. Opinions are divided as to whether this antagonistic action of the thyroid secretion is due to the action of two different hormones, or to a single hormone capable of producing two opposite sets of effects, according to the apparatus influenced. The final solution of this problem demands a considerably greater knowledge of the internal secretions than we possess at present.[14]

As our interest in hormonology is more especially concerned with its relation to cutaneous diseases, the question arises as to the possibility of identifying any of the dermatoses as of definite internal secretory origin. The two antagonistic conditions of hyperthyroidism resulting in Graves' disease, and athyrea or myxœdema are accompanied by certain well marked changes in the skin and its appendages. In Graves' disease the skin is thinned and stretched, readily congested, perspires freely, especially on the palms, soles, and in the axillæ. Occasionally the hyperidrosis is followed by a hyperkeratosis palmaris. Pigmentary changes are frequent and there may also be pruritus, factitious urticaria, ordinary dermatitis, alopecia and disorders of the nails. These cutaneous changes in exophthalmic goitre are not specific, and are pathognomonic only when considered as parts of the general symptom-complex. There is no dermatosis known at present which can be considered as ætiologically expressly connected with hyperthyroidism.[4] Pruritus, various more or less extensive ordinary forms of dermatitis, pigmentations, and disorders of keratinization are not necessary consequences of hyperthyroidism, although their frequent occurrence in this connection is evidence that they are not merely coincidental. In 111 cases of exophthal-

mic goitre observed by Hyde and McEwen,[15] there were 49 with hyperidrosis, 15 with pigmentary changes, 5 with diffuse scleroderma and many with extensive alopecia, urticaria, vitiligo and erythema. Instances of alopecia are not infrequent, and Sabouraud regards some chronic alopecias as directly produced by hyperthyroidism. In women with Graves' disease a form of alopecia has been noted which is considered characteristic by some, in that the hair over the vertex and temporal regions is diffusely thinned, though complete baldness does not occur.

The fugitive erythemas often observed are an expression of the general vasomotor instability in this disease, and sugillations may occur either spontaneously or as a result of slight traumata. Patches of solid œdema have been noted, and also a peculiar thickening of the skin at the calves of the legs, without increase in the musculature. The pigmentation which is rarely absent from complete Graves' disease, and the nature of that pigmentation, suggests a possible association with the suprarenal glands.

Much more characteristic than the cutaneous changes in Graves' disease are those encountered in genuine athyrea, or myxœdema, and in cachexia are those encountered in genuine athyrea, or myxœdema, and in Hertoghe's chronic benign hypothyroidism, and in the so-called abortive forms of myxœdema (Saenger[16]). In developed instances of myxœdema the skin is pallid, cold, dry and wrinkled, and peculiarly infiltrated though not actually œdematous. There are local tumefactions, particularly in the supraclavicular regions, and the features are coarse and broad. In the malar regions, and at times on the nose, there is a reddish patch. The hair is thin, dry and lustreless, and may be prematurely gray. The hair of the scalp becomes scanty, and that in the pubic and axillary regions, and the eyelashes and eyebrows often fall out. Nail changes also occur. In many cases the teeth are brittle and carious, and the sweat glands cease their function. Pigmentations and chronic dermatitis are not unusual associated conditions.

The histology of the myxœdematous skin discloses a peculiar degenerative process in the cutis, with changes in the elastin and collagen elements. The elastic fibres are swollen, the collagenous bundles are attenuated or may almost disappear, and both are transformed into a homogeneous, hyaline-like mass. An obliterating endarteritis is also observed, which is similar to that found in the atrophic thyroid gland. The epithelium of the coil and sebaceous glands is swollen and proliferates, and occludes the lumen of the glands.

From the development of these clinical and histologic alterations in

the skin following atrophy or extirpation of the thyroid gland, and their disappearance upon administration of thyroid extract, we can conclude that they result from a deficiency in thyroid secretion. Poor[4] has recently attempted to correlate on clinical and histologic resemblances, the three conditions of myxœdema, senile atrophy of the skin, and xeroderma pigmentosum, and ascribes their origin to morphologic or functional anomalies of the internal secretory organs, especially the thyroid. Although there is a similarity between the changes of senile decay and the symptoms of myxœdema, with thyroid atrophy common to both conditions, there is no proof of an ætiologic relationship between senile cachexia and the retrograde changes of the endocrinous organs observed in old age. "The possibility suggests itself that these changes are not the cause, but the consequence of the general nutritional disturbance which occurs in old age. As Ewald rightly points out, the atrophy of the intestinal tract, which is an invariable and characteristic feature of senile cachexia, is absent in myxœdema" (Biedl).

A pathogenic relationship to the thyroid gland has been ascribed by some to adiposis dolorosa, or Dercum's disease. This condition in some respects resembles myxœdema, and is characterized by the presence of circumscribed and painful fatty tumors, situated in the connective tissue. In addition, there are diffuse fatty deposits and at times the subjects are very obese. In five of six cases the autopsy disclosed pathologic changes of the thyroid gland, and in one the thyroid was normal, but there was an adeno-carcinoma of the hypophysis.

Many dermatologists consider scleroderma as genetically related to anomalies of the thyroid gland, and numerous observations apparently uphold this view. The association of scleroderma and Graves' disease has been repeatedly observed, and pathologic reports are not wanting in which disease of the thyroid has been demonstrated. Among the more recent reports are those of Singer,[17] Hektoen and Wells,[18] and Notthafft.[19] In Singer's case the left lobe of the thyroid was of normal size, the right lobe was atrophied, and both showed marked connective tissue proliferation, especially extensive in the right lobe. In Hektoen and Wells' case of diffuse scleroderma, the thyroid was found atrophied and its stroma diffusely sclerosed. In addition to marked cystic changes, there was an extensive endarteritis obliterans of the thyroid vessels, and the pituitary was found hypertrophied. The iodine content of the thyroid was also found to be greatly diminished. Notthafft reports a diffuse scleroderma accompanied by an atrophied thyroid gland, in which there was found normal glandular epithelium, round cell infiltration of the connective tissue, and thickening of the septa. He is opposed to

assuming a causal connection between scleroderma and thyroid anomalies, on the ground that extensive thyroid changes are observed without a scleroderma following, and because postmortem findings show the connective tissue change is not limited to the skin and thyroid gland but affects all the organs, and that therefore the scleroderma cannot be attributed only to the interstitial processes occurring in the thyroid.[4]

Other writers, however, are of the opinion that not alone Graves' disease, but every alteration in the thyroid gland, be it simple goitre, Graves' disease, or atrophy, can cause scleroderma. Hektoen assumes that altered thyroid function on the basis of arteriosclerosis of the thyroid vessels, as found by him, causes the cutaneous affection, and that the changes in the pituitary gland are an expression of compensatory hypertrophy.

The successful therapeutic use of thyroid extract in scleroderma, as reported by a number of observers, has been offered as ætiologic evidence in this connection, but these reports are more than counterbalanced by accounts of its unsuccessful employment. Although the relative frequency with which scleroderma is found in association with Graves' disease is greater than can be accounted for by mere coincidence, this does not definitely establish a causal relationship. As Poor points out, it is noteworthy, in this connection, that in the cases reported by Singer, Hektoen and Notthafft the thyroid gland was found atrophic in one or both lobes,—a condition not in accord with the thyroid changes of Graves' disease, but with those of myxœdema. In the discussion of his case, Singer has drawn an interesting parallel between scleroderma and myxœdema, and a certain clinical resemblance between the œdematous stage of scleroderma and myxœdema doubtless exists. In the attempt to correlate the pathologic findings with the clinical symptoms in these cases, if we cannot assume the existence of compensating accessory thyroid structures of normal functionating ability, we may accept the view of Poor, who, on the basis of the marked connective tissue changes found in these cases, believes that the thyroid was primarily enlarged or even hypertrophic, and that the secreting structure atrophied at a later period, in consequence of the action of the proliferating connective tissue. In an early stage the symptoms are therefore those of Graves' disease, while later the changes incident to hypothyroidism appear. In support of this view, Poor cites the case of Schaeffer-Neisser in which scleroderma developed coincidently with the disappearance of the struma.

On these premises it is conceivable that the conflicting results of thy-

roid therapy in scleroderma may find an explanation in the varying conditions of the pathologic thyroid gland at different periods.

Several observations are of interest which tend to show that alterations in the secretory function of other endocrinous organs than the thyroid may play a part in the production of scleroderma. As indicative of this is its relatively frequent appearance in the menopause, and as Luithlen[20] has shown, there are instances in which menstruation has been arrested or has ceased coincidently with the appearance of scleroderma.

A review of the various observations just recorded leads to the conclusion that there are reasonable grounds for attributing an important part in the ætiology of scleroderma to morphologic and functional changes in the internal secretory organs, and especially in the thyroid gland. This newer conception would seek to displace the at present widely accepted view that scleroderma is an "angiotrophoneurosis," and it appears even now to have much of evidence in its favor.

There is doubtless a direct influence of deranged hormone action on the part of the thyroid upon the coil glands of the skin, resulting in the hyperidrosis incident to Graves' disease, and the anhidrosis in myxœdema. A similar disturbing influence is apparently exerted at times upon the process of keratinization and thereby favors the occurrence of dermatitis and chronic eczemas in Graves' disease and myxœdema.

In this connection ichthyosis is of interest, and especially because of its favorable response to thyroid therapy in some instances.

Several cases of ichthyosis have been recorded (Colcott Fox, Weill and others) in which there was disease or atrophy of the thyroid gland, with improvement in the ichthyotic condition after thyroid therapy. Winfield[21] described ichthyosis in a child which lived for two and a half weeks, and at autopsy was found to have no thyroid. On the other hand, Rion[22] recorded a case of fœtal ichthyosis in which a normal gland was found at autopsy.

There is no evidence, other than that indirectly provided by organotherapy, of a definite relation between ichthyosis and disordered thyroid function. A similar verdict of "not proven" must be rendered in regard to numerous other dermatoses, the association of which, with deranged hormone action of the thyroid, has been claimed periodically, and is based usually on the results of thyroid therapy. In this group are found such diverse conditions as keloid, pélade, verrucæ, Darier's disease, pruritus and others. It is conceivable that changes in the hormone-producing organs resulting in disorder of the general nutrition, may influence the clinical evolution of such common dermatoses as ec-

zema and psoriasis, without, however, being genetically related to them. Psoriasis may occur in a subject with thyroid insufficiency, and may rapidly disappear under thyroid therapy. Such an occurrence does not, however, justify the belief of several writers (Bramwell, Hertoghe, quoted by Grosz[23]) that some cases of psoriasis appear as a special form of hypothyroidism.

The parathyroid glands are of interest in dermatology in connection with the changes observed in the epithelial structure as the result of disease of these organs, or their extirpation. They are directly concerned in the production of tetany, which results from insufficiency of the parathyroid secretion, and they apparently control, in some way, the distribution of calcium in the body. Individuals affected with chronic tetany frequently show changes in the development of the ectodermal structures. The hair may cease to grow for months, without, however, becoming scant, or there may be alopecia, the nails and teeth undergo dystrophic changes, and pigment anomalies and chronic ulcerations occur in the skin. There is, however, no characteristic dermatosis associated with parathyroid pathology.

No definite relationship has thus far been established between cutaneous disease and absence of disease of the thymus gland. Its function is exercised only for a short period, as its involution begins at about the second year of life and is completed normally with adolescence. During its period of activity the thymus is an important factor in maintaining the hormone balance. There appears to be a close relation between the thymus and the reproductive glands, for the latter do not undergo full development until the thymus has atrophied. The thyroid and adrenal glands are also interrelated with the thymus, although in a manner not well understood at present. Its influence on the integument is demonstrated in the thymo-lymphatic status, in which anomalies of the skin and its appendages are frequent; the skin is pale, there may be a heterosexual growth of hair, and in some cases a decreased hair growth. The cessation of thymus activity at puberty suggests that its internal secretion is concerned in the inhibition of sexual development with its associated hair growth, and that through its influence the scalp is made susceptible for the growth of the ringworm fungus (Macleod[24]).

From this outline of that part of the subject of "the internal secretions and their relation to cutaneous disease" which has been assigned to me, it is evident that the subject is one of no little difficulty in the present state of our knowledge. A very large part still remains unrevealed, and it is hoped that with the further development of the doctrine of internal secretion, many of the problems of dermatology will find their final solution.

REFERENCES.

[1] POLLIZER. *N. Y. Med. Jour.*, Oct. 5, 1912, p. 669.
[2] BIEDL. Internal Secretory Organs, 1913, p. 3.
[3] BIEDL. *Loc. cit.*, p. 4.
[4] POOR. *Dermat. Wchnschr.*, 1913, No. 27.
[5] BAYLISS AND STARLING. Lancet, 1902, 1, p. 813.
[6] BIEDL. *Loc cit.*, p. 6.
[7] GLEY. *Practitioner*, Jan., 1915, p. 9.
[8] HARROWER. Practical Hormone Therapy, p. 15.
[9] BIEDL. *Loc. cit.*, p. 12.
[10] HARROWER. *Loc. cit.*, p. 31, quoting VON NOORDEN.
[11] CANNON. *Jour. A. M. A.*, 1911, vi, p. 742.
[12] WILSON. *Brit. Med. Jour.*, 1913, 1, p. 1257.
[13] BIEDL. *Loc. cit.*, p. 22.
[14] BIEDL. *Loc. cit.*, p. 110.
[15] HYDE AND MCEWEN. *Am. Jour. Med. Sci.*, 1903, cxxv, p. 1000.
[16] SAENGER. *Dermat. Wchnschr.*, 1913, vi, p. 358.
[17] SINGER. *Berl. klin. Wchnschr.*, 1895, p. 226.
[18] HEKTOEN AND WELLS. *Jour. A. M. A.*, 1897, xxviii. p. 1240.
[19] NOTTHAFFT. *Centralbl. f. allg. Path.*, 1898, p. 870; *Centralbl. f. inn. Med.*, 1898, p. 353.
[20] LUITHLEN. Mraçek's Handbuch, 1904, iii.
[21] WINFIELD. *Jour. Cutan. Dis.*, 1897, p. 516.
[22] RION. Thése de Lyon, 1908.
[23] GROSZ. Mraçek's Handbuch, ii, p. 128.
[24] MACLEOD. *Practitioner*, Feb., 1915, p. 298.

A general review of the subject is given in the articles by SIR MALCOLM MORRIS, *Brit. Med. Jour.*, 1913, i, p. 1037, and by AXEL GEDERCREUTZ, *Prakt. Ergeb. a. d. Geb. d. Haut u. Geschl.*, 1914, iii.

THE RELATION OF INTERNAL SECRETIONS TO CUTANEOUS DISEASES.*†

By Ernest L. McEwen, M.D., Chicago.

While the subject of this discussion is of great importance and interest, it is not one free from difficulties. The literature with reference to internal secretions in general is enormous, and the task of selecting from this massive array the facts which bear upon dermatology requires time and judgment. One soon discovers that the relationship between these internal secretions and diseases of the skin is less frequently direct than indirect, and therefore may not be apparent upon the surface. The actual connections very often have to be searched for, and for this reason it is doubtful whether a mere recital of instances of association contributes much to our knowledge of the subject.

To uncover these more or less obscure relationships a method of procedure must be followed which will reveal as far as possible the *modus operandi* by which the causal factors on the part of the endocrinous glands are connected with the effects upon the skin. This can best be accomplished by considering the glands from the viewpoint of their normal and pathologic physiology; we may then deduce from the findings whatever there may be which is valid and of interest and use to the dermatologist.

* Read before the 39th Annual Meeting of the American Dermatological Association, New York City, May 13-15, 1915, as a part of a symposium. This paper has to deal with the suprarenals, the pituitary, the pineal gland, the pancreas, the gastric, and intestinal mucosa, the gonads, and the interrelation of all the endocrinous glands.

† The following works are recommended as containing exhaustive studies of the internal secretions, in general and in particular, together with very complete bibliographies:

Biedl, A. Innere Sekretion, 2te Auflage, Berlin, 1913.
Vincent, Swale. Internal Secretions and the Ductless Glands. London, 1912.
Paton, Noël. The Nervous and Chemical Regulators of Metabolism. London, 1913.
Thaon, Paul. L'Hypophyse. Paris, 1907.
Cushing, H. W. The Pituitary Body and its Disorders. Philadelphia and London, 1912.
Jauregg und Bayer. Lehrbuch der Organotherapie. Leipzig, 1914.
Sajous. The Internal Secretions and the Principles of Medicine. 4th Ed. Philadelphia, 1911.

A distinction has been made between *direct* and *indirect* relation. Addison's disease may be taken as an instance of the former, since the pigmentation in that disorder is believed to arise within the skin as an immediate consequence of a deficiency in the active principle of the suprarenal glands. On the other hand, all the dermatoses due to the diabetic state may in a roundabout way be secondary to endocrinous gland disorders, since these in certain instances may be the cause of the hyperglycæmia and glycosuria.

The usual classification of these glands is open to criticism. A much clearer conception of their action is possible if they are grouped according to their embryonic derivation, since this seems to determine, in great measure, their function.

New growths constitute the most common source of disturbance of these glands. While the ultimate result is deficiency or total cessation of function, a preliminary effect in certain instances may be functional hyperactivity of the structure involved. Obviously, in these cases, the clinical picture would change gradually from the hyper- to the hypo-extreme, the first and last symptom-groups being more or less opposite in character.

Classified on the basis of their embryonic origin there remain for our consideration the following structures with internal secretion:

(1) From the neural canal:
- The chromaffin system.
- The hypophysis, or posterior lobe of the so-called pituitary gland.
- The epiphysis, or pineal body.

(2) From the buccal cavity:
- The true pituitary, or the anterior and middle portions of the so-called pituitary.

(3) From the alimentary tract:
- The pancreas.
- The gastric and intestinal mucosa.

(4) From the genital ridge:
- The interrenal system, forming the cortex of the suprarenals.
- The gonads, or male and female sex glands, including the corpus luteum.

This classification, it will be noted, separates certain structures which in the human are found in most intimate anatomical relation, namely, in the suprarenals, the cortex, or interrenal body, from the medulla, a chromaffin structure; and in the so-called pituitary body, the posterior portion, or hypophysis, of neural origin, from the anterior and middle

portions or true pituitary derived from the embryonic buccal cavity. It will, of course, be impossible to maintain a strict separation of these structures in our discussion, yet the clarity imparted by a recognition of origins will be apparent as we proceed.

The chromaffin system comprises the suprarenal medulla and the two small bodies found at the bifurcation of the carotids, known as the carotid glands. These structures are essentially the same; the carotid bodies are to be regarded merely as extracapsular chromaffin tissue. The term chromaffin is used because it is descriptive of the marked staining affinity which certain groups of constituent cells show for the salts of chromic acid; these pigment granules supposedly representing a prostadium of the active principle elaborated by the cells. The medulla represents about ten per cent. of the total volume of the suprarenals, and is derived, in common with the ganglia of the sympathetic, from neuroblasts which wander from the neural tube in early embryonic life. It is, therefore, epiblastic in origin and intimately related to the sympathetic nervous structures.

The cortex, or interrenal body, forming ninety per cent. of the total gland, is mesoblastic, springing from the genital ridge, and having therefore a common origin with the sexual glands. In higher animals the medulla and cortex are in such close anatomic relation as to be practically inseparable, a fact which renders difficult the experimental work of determining the true function of each part. In certain of the fishes, however, the medulla and cortex are entirely separated structures.

It has been abundantly established that the substance adrenalin is a product of the medulla, and is a true internal secretion. Experimentation has also proven that its essential physiologic action is to stimulate the terminations of the thoracico-abdominal sympathetic system. Through this functional power it maintains the tonicity of the walls of the blood vessels. This property of producing vascular tonicity and contraction has given adrenalin a therapeutic value in dermatology which has been utilized with more or less success in a number of conditions, notably, purpura hæmorrhagica, pruritus vulvæ, rosacea, urticaria, erythema multiforme and verruca; it has also been used to assist the action upon the skin of the Finsen light and Roentgen rays.

It has been proven that injections of adrenalin cause glycosuria. This is explained as follows: excess of adrenalin in the blood, by stimulation of the sympathetic terminations in the liver, causes a liberation of carbohydrate from the glycogen store in that organ. Adrenalin, therefore, has the power of mobilising sugar, and becomes a possible factor in the development of diabetes.

Opinion is not settled as to the pathogenesis of the pigmentation in Addison's disease, a condition generally accepted as due to suprarenal insufficiency. The following theories have been proposed:

(1) That the dyschromia is due to an increase of physiologic pigmentation. Normally, pigment is brought to the rete mucosum by the chromatophores, and the number of these carriers increases with the intensity of the color. Presumably these cells are under the control of the sympathetic nervous system which, in Addison's disease, is not operating normally.

(2) That the matrix of adrenalin is found in tyrosin and allied products of proteid decomposition; that in disease of the suprarenals, adrenalin is no longer elaborated from the mother substances. These accumulate in the tissues, and in the skin, especially where exposed, are converted by oxydases (tyrosinase) into a dark-colored pigment body of the melanin group. It is generally conceded that much work needs yet to be done in this field. That chloasma uterinum, including the "mask of pregnancy," is related to suprarenal conditions seems very probable, but the exact mode of connection has not been determined.

The hypophysis, or posterior lobe of the so-called pituitary body may, to avoid confusion, be designated the neural-pituitary Like the chromaffin system, it is nervous in origin, and very largely nervous in structure. By use of extracts the presence of an active principle has been shown, but this has not been isolated. It has been established that this principle, while not identical with adrenalin, has a very similar physiologic action. Injected into the tissues, it produces, like adrenalin, hyperglycæmia and glycosuria. The same result is obtained by direct stimulation of the gland. Loss of function leads to an opposite state, namely, increased assimilative power for sugar, with accumulation of fat in the tissues. This fact makes possible a relationship between the neural pituitary and certain conditions which concern the dermatologist through the medium of local or general adiposity.

The anterior and middle portions of the so-called pituitary, originating as they do from the buccal cavity of the embryo in common with the thyroid, may, in the interest of clearness, together be termed the buccal-pituitary. The functions of this structure are in many respects similar to those of the thyroid. Partial removal in animals, causing deficiency of function, has been followed by impairment of growth, atrophy of the sex glands, and increase of body fat. Hyperactivity is followed by increase of tissue growth and is supposedly the factor which begins the body changes leading to gigantism in adolescents and acro-

megaly in adults. In this latter condition there is a diffuse increase of the soft tissues of the face, hands and feet, with hypertrophy of the papillæ and glands of the skin. A physiologic hypertrophy of the buccal pituitary is said to occur in pregnancy, to which is attributed the thickening of the subcutaneous tissues of the nose, lips and hands, sometimes observed in that state.

With respect to this structure the rule especially holds, that the pathologic factor which produces increase of function may sooner or later cause decrease or cessation of function, and thus bring to the fore symptoms more or less the contrary of those first observed. This fact greatly complicates the correct estimate of the significance of symptoms of buccal pituitary involvement. A further difficulty arises in the close anatomical proximity of the neural pituitary, which structure may react in the same manner to the disturbing element, that is, by acceleration, followed by decrease of function.

Cushing sums up the cutaneous and subcutaneous changes in dyspituitarism,—the neural and buccal pituitaries being included,—as follows:

In hyperpituitarism:

- Increase of size of hair follicle.
- Hypertrophy of papillæ.
- Enlargement and activation of the secretory glands, causing a moist and greasy skin.
- Increase of connective tissue in the subcutis, giving skin a dense, boggy feel, with increase of depth of furrows of hands and face.
- Hypertrichosis.

These manifestations may change very gradually to those of hypopituitarism, namely:

- Smooth, transparent skin, free from moisture, almost infantile in character.
- Failure of axillary and pubic hair, with feminine distribution of latter in males.
- Head hair may remain intact, though when condition develops in adult life, thinning may occur.
- Pigmentation is often a conspicuous feature.

He considers that adiposity, including increase of subcutaneous fat, is due to insufficiency of the neural-pituitary.

The pineal gland, a small nervous structure, found beneath the posterior portion of the corpus callosum, resting upon the anterior quadragemmate bodies, must be credited with an internal secretion if the

results obtained by feeding the fresh gland to growing animals are to be accepted. While it is true that the findings of different investigators are not always in harmony, and that much needs to be done to establish the exact status of the gland, it seems very probable that its principal function has to do with the normal development of the growing individual. Hyperactivity leads to premature overgrowth of body and to precocity of mental and sexual development; never, however, beyond the limits of adult life.

The pancreas concerns the dermatologist because of its relation to diabetes. Removal of this organ produces marked hyperglycæmia and glycosuria. Experimentation has proven that the pancreas elaborates an internal secretion, the nature of which is not known, and that loss of this secretion brings on the diabetic condition. There follows a rapid mobilization of sugar from the glycogen of the liver, and the muscles lose some of their power to assimilate the carbohydrates. The evidence seems to be that this secretion acts by inhibiting the sympathetic terminations in the liver, thereby opposing the action of adrenalin and the active principle of the neural-pituitary.

Secretin, the name given the internal product of the intestinal mucosa, is said to be the best example of a true internal secretion that can be named. Its function is to excite the external secretion of the pancreas. As there is no evidence of an action upon the pancreatic internal secretion, it is not apparent how this hormone touches the field of the dermatologist. It is claimed, and apparently correctly so, that a similar substance is formed in the pyloric portion of the gastric mucosa, the function of which is to stimulate the secretion of the gastric juices. If hypersecretion of this hormone leads to excess of gastric acidity, a relationship to skin disturbance is conceivable, since hyperacidity is very often a factor in acne rosacea.

Comparatively little is known of the functions of the interrenal bodies. That they are essential to life has been shown by the work of Biedl on fishes. That they stand in very close relation to the gonads, is indicated by their common embryonic origin, by the finding of interrenal rests in the genital tract of the male and female, by the morphologic similarity between the cells of the suprarenal cortex and the interstitial cells of the testes and corpus luteum, by the sexual precocity in children with tumors of the cortex, and by the hypertrophy of that structure in pregnancy. It has been suggested, but not proven, that the cortex in some way is connected with the pigmentation of the skin in pregnancy. Deficiency of sex characters has been known to be associated with deficiency of interrenal tissue; hyperplasia leads to sexual prematurity and, in the female, to the development of male sex characters.

The cells of the interrenals are heavily loaded with lipoid substances, but these cannot be regarded as constituting an internal secretion. That they—the lipoids—have a great deal to do with the functions of the cortex is believed. The theory has been advanced that the principal task of the interrenals is the neutralization of body toxines, since lipoids and cholesterins are known to have this power. This theory might bring the interrenals into relationship with a number of infectious skin disorders, among them syphilis; however, as this antitoxic action has not been proven, the idea of this relationship must be accepted as suggestive only.

The gonads exert an influence upon the body tissues which is both profound and complicated, and in considering them it would be easy to go beyond the limits of this discussion. The facts which have bearing may be presented briefly as follows:

In both sexes the gonads produce an internal secretion which determines specifically in each the development of the secondary sex characters. This determination concerns the growth of muscle, bone and other connective tissue, and the cutaneous appendages. Removal in the male favors the persistence of infantile characteristics; hair growth is scanty and fat accumulates in the subcutaneous tissue. In the female, removal or destruction by disease often is followed by the appearance of male characteristics, such as facial hypertrichosis. Involution of the gonads with age is accompanied by wrinkling and atrophy of the skin, with loss of the panniculus adiposus and thinning of the hair. Sexual precocity, with premature development of axillary, pubic and facial hair (in the male) has been observed in tumors of the testes and ovaries. It is interesting to note that this internal secretion, which acts so powerfully upon the whole physical organism, is known to be the product of the so-called interstitial cells which, as mentioned before, very closely resemble the cellular elements of the suprarenal cortex.

The hormone of the corpus luteum has to do with the preparation of the uterine mucosa for the ovum, and with the nutritional welfare of the early embryo. Its relation to skin conditions is not apparent.

The interrelation of the endocrinous glands is an extremely complex and in many respects an undetermined subject. An exhaustive consideration of this phase is not demanded by the discussion in hand. The following tabulation, adapted from Paton, will give, in a compact way, certain facts relative to polyglandular activity and interrelationship which are of interest to the dermatologist:

(1) Mobilization of sugar from the glycogen of the liver is stimulated by the
Neural-pituitary,
Thyroid and
Chromaffin System.
It is inhibited by the
Parathyroids and
Pancreas.

(2) The growth of muscle, bone and connective tissues generally, is stimulated by the
Buccal-pituitary,
Thyroid,
Thymus and the
Gonads.

(3) The glandular interrelations which are fairly well established are as follows:

(a) The thyroid exerts a stimulating action upon the chromaffin system and the gonads. It inhibits and is itself inhibited by the buccal-pituitary and the parathyroids.

(b) The buccal-pituitary stimulates the gonads, inhibits the thyroid and is itself inhibited by the gonads and thyroid.

(c) The thymus inhibits and is itself inhibited by the gonads.

(d) The gonads inhibit the buccal-pituitary and the thymus; they probably stimulate the interrenal system; they are stimulated by the buccal-pituitary, the thyroid, and probably by the interrenals.

(e) The parathyroids are inhibitory to the thyroid.

(f) The interrenal system probably stimulates the gonads, and in return is stimulated by them.

To summarize, a direct or indirect relationship may be considered as existing, or possible of existence, between the endocrinous glands mentioned in this paper and the following skin diseases:

The pigmentation of Addison's disease; very probably the pigmentation from pregnancy and pelvic tumors; and pigmented new growths of the skin.

The dermatoses which are persistently associated with diabetes.

The dermatoses which are secondary to excess of body fat, both local and general.

The skin disturbances which are characteristic of puberty in both sexes as well as those which attend the involution of the sex life.

Hypertrichosis in women.

Alopecia, in certain instances in both sexes.

Dermatoses which are ætiologically related to hypo- and hyperactivity of the glands of the skin.

It is evident from this last that the glands of internal secretion deserve the frequent attention of the dermatologist. We are reminded again that the successful practice of our specialty entails upon us not only the necessity, but the duty, of studying the internal conditions of the cases in our charge. Dermatology is notoriously deficient in facts bearing on the causation of skin disease; may this not be due in part to our failure at times to appreciate fully the value of the complete history and the thorough physical examination?

THE PRESENT STATUS OF DERMATOLOGY IN SOUTH AMERICA.*

By William Thomas Corlett, M.D., Cleveland.

At a time when industrial and commercial organizations of North America are looking to their twin-sister of the South, realizing that closer relations and more intimate acquaintance might work to the advantage of both, it seems opportune that science and literature might likewise to a certain degree assume closer relations to their mutual advantage.

While material plenty in baser minds may tend to riotous living and deterioration of the race, education and the cultivation of the intellect must with equal certainty result in a higher degree of civilization when material prosperity abounds.

In the present imperfect inventory of the status of dermatology in South America, the writer feels his observations were not sufficiently long nor his data sufficiently explicit to enable him to give more than a casual summary of what is being done in this field of medicine.

* Read before the 39th Annual Meeting of the American Dermatological Association, New York City, May 13-15, 1915.

To better understand the conditions which influence medicine as a whole in South America, it may be well to bear in mind that while vast areas of land show the evidences of the hand of man less, the cities are older and show the process of completion more than we are accustomed to see in this country.

Lima has the oldest university on the American continent, being founded in 1551. It has, however, been interrupted in its work several times by war and the medical school was devastated in a neighboring invasion as late as 1881. Since then the instability of the government has greatly hampered the progress it doubtless otherwise would have made. The largest of the three hospitals is connected with the University; it has about 500 beds and seems to be fairly well equipped. The tuberculosis wards, which are located in a special building, seemed well adapted for the purpose and carried out the open-air treatment by large windows in which slats of glass were placed at an angle of about 45 degrees. There was no special ward for skin diseases as such, but wards were established for some of the native contagious and infectious diseases such as verruga Peruana, sporotrichosis and Leishmaniasis in its various forms (Kala-azar, oriental sore and espundia) as here recognized,—all of which are prevalent. The first named is especially common in the Andean valleys of the interior, notably at Verruga, which for a time delayed the construction of the Oroya railroad at that place. In the ward for this class of affections I saw a boy of about seventeen years, covered with what appeared to be pea-sized warts, flat-topped and confluent. I was told they were common verucca and were not supposed to have any relation to the incipient Leishmaniasis, I think it was, for which he was admitted. While the material presented some unusual cases, on the whole I did not think it well worked up, although it was their summer and therefore vacation-time, nor did I see any evidences of an organized department for skin diseases. I know of no city of equal size, about 120,000 inhabitants, in this country, in which the material both in patients and buildings for their accommodation offers a more promising field of labor in cutaneous medicine than does the capital of Peru.

Santiago is the second medical centre, if such a term be permissible, west of the Andes, and possesses a University with a medical school. The Chilian capital is the fourth in size of the cities of South America and has between three and four hundred thousand inhabitants, with three hospitals. Many of the leading men were on vacations at the time of my visit and the impression gained may not be as favorable as a more propitious time might give. As in Lima, I found here that higher medical education was dependent on the opportunities offered in Paris and

Berlin, rather than to well organized instruction at home. The medical course extends over a period of seven years, and a degree in arts is necessary for admission. In studying the curricula it seemed to me that the work required for the former corresponded to that leading to our high-school graduation, and some of the subjects in the medical course were those usually taken in the work for our degree in arts and sciences. Dermatology is taught one hour a week in the last half of the fifth and all of the sixth year, and an examination is required at the end of each. I found the loose way of grouping skin and venereal diseases and syphilis together which formerly obtained here, and none of the men I met confined his work exclusively to dermatology. At the same time, they were well equipped with modern appliances and were familiar with their use. In the treatment of syphilis modern ideas prevailed. The general impression from a practical point of view was favorable; at the same time, they did not impress one as working wholly from altruistic motives, nor alone for the rewards which science bestows on her faithful few.

Buenos Aires, the largest city (1,400,000), may well be called the medical centre of South America, with its fine buildings, surpassed on the American continent only by those of Harvard, and its ample hospital facilities (5000 beds) and the high grade of the work done by a half dozen or more men places it, I believe, foremost in the field of dermatology in Latin America. The course of study is here, likewise, seven years of eight months each, but like the schools of North America, sufficient time is not given to what they call *dermato-sifilografica.* The official course to which each student must subscribe consists of clinics and from 30 to 40 lectures. Attendance is, however, not strictly compulsory, although examinations in these subjects are held before graduation. To those who wish to further pursue the subject, an excellent opportunity is offered in the Hospital Ramos Mejia (formerly called San Roque) under the direction of Baldomero Sommer and his able assistant and indefatigable co-worker, Nicolas Greco. In this hospital the department of *dermato-sifilografica* forms a distinct unit or department with wards and a few rooms for special cases and a well equipped laboratory, together with an amphitheatre, artist's room for making wax models, plates, etc., of which they are collecting instructive material. The hospital records show that in 1914 there were entered for hospital care 498 patients and 2455 were registered for the first time in the out-patient department. The laboratory record shows that 368 examinations and analyses were made during the same year.

Another fertile field for clinical study is offered in the National Hospital for Contagious and Infectious Diseases. Admirably planned and

constructed with wide air spaces, the various pavilions of this hospital contain almost everything from varicella and measles to leprosy.

A more certain index to the status of dermatology may be obtained, especially in a short visit from the work done outside of college walls by various members of the profession. In 1907 there was founded in this city the Dermatological Society of Argentine, with Drs. Sommer and Diaz as president and vice-president, respectively, and Dr. Pedro L. Baliña as secretary. This organization meets monthly and has about 23 active members. The average attendance in 1911, the last report I saw, was eleven. A perusal of the work done by members of this Society will show that it compares favorably with that of the dermatological associations with which we are better acquainted.

In Brazil there are three universities where medicine is taught. The course of study in medicine is six years, and some preliminary work corresponding to our high school course, is required for admission. Unlike the other countries of South America, where a knowledge of Spanish is a prerequisite, Portuguese is required in Brazil. The examinations in South America are almost wholly oral. Two or three foreign physicians, in both Argentine and Brazil, with whom I spoke, said their examinations were held separately from those of the native students. None of them complained of any unfairness shown them. In Rio de Janeiro, and I think the same applies to other cities of South America, the internes do not reside in the hospital, but come during regular hours or when called for. Much latitude I found in the amount of work done by various students. During the fifth and sixth years the highest grade students are appointed as internes, or more correctly, externes. Some of them elect to do research or other extra work and prepare a thesis of decided merit on receiving their diploma. I saw a number of hospitals, notably the Miseracordia in Rio de Janeiro, in which excellent clinical and laboratory work was being done by undergraduates. The clinical material is abundant, and while there were 1400 beds in this hospital, there were at the time of my visit in March last, 1800 patients. Accommodation was easily made by placing mattresses on the floor. This overflowing of hospitals seemed quite general in Latin America. Of the three medical schools in Brazil, the smallest one at Cordova was not visited. In Rio de Janeiro, dermatology is not specialized as in Buenos Aires, and no organized teaching is done in this department. In Bahia the same holds true. In the latter city, while the college buildings, containing a valuable library and accommodations for various elementary departments, seemed beyond the general development of the town, its hospitals were less of a surprise and seemed to be indigenous.

In taking a personal inventory of the trip, I believe the three months well spent, if from no other than a medical point of view, and that mutual benefit to us and to them will accrue from a more frequent exchange of visits and a personal study of each other's ideals and methods of attaining them.

DISCUSSION.

DR. PUSEY said that his interest in the subject of the effect of tropical sunlight upon Caucasians, to which Dr. Corlett had referred, had been awakened by the book of Dr. Underwood upon this subject. At first he had been very much impressed by the views of Dr. Underwood, but latterly he had come to doubt the great effect of sunlight, as such, in the reduction in vigor on Caucasians in the tropics. He also could but question the marked darkening of the skin which was said to result in Caucasians who resided in the tropics. He doubted if the period of historical time, in America at least, was long enough to account for any marked darkening of the skin of Caucasians, and his mind reverted to another possibility to account for the darkening of the dominant races who had lived in southern and Central American colonies. He called attention to the fact that it was not uncommon to see pure blooded Spaniards from Costa Rica, for example, some whose families had lived there longer than we had here, and who were yet quite at fair as we. There had been no evidence of the conversion of the Caucasians into a darker race in southern California or Arizona where there was as much sunlight as there was in a twelve hour day under the equator.

He had been much interested in Dr. Towle's work on heliotherapy, and hoped that Dr. Towle would give more of his technique. He, himself, had been using the highly actinic rays of light, and had been impressed with the fact that they were of great therapeutic value and worthy of use in many cutaneous conditions.

SHOULD ALL PRE-CANCEROUS OR CANCEROUS LESIONS OF THE SKIN BE EXCISED?

By M. B. HUTCHINS, M.D., ATLANTA.

MANY of the ablest surgeons, some of them experts in the treatment of cancer, surgically, calmly advise excision as the only treatment of pre-epitheliomatous or epitheliomatous lesions. The mental attitude of the surgeon towards the dermatologist is just about as pleasingly complimentary as the feeling of a cowboy for a sheep-herder. It is true that much of our cutaneous work is piddling or piffling, our most formidable instrument an electrolytic needle or a curette.

There are many dermatologists who by preference are medical men, but others of us recognize the specialty as more surgical than medical, and have felt competent to extend our activities into the field of major operations for cancer—as of face, mouth, jaws, breast, groin, uterus, in fact every accessible part.

Years of anatomical and operative training, together with observation and study of all forms of malignant growth should have qualified the surgeon-dermatologist the better to discriminate between methods of treatment.

As to small lesions potentially malignant, early epitheliomata, and the basal celled types in particular, however great our preference for excision, such procedure does not conform fully to the old motto, "*cito, tuto, juncunde!*" Why excise a mole when electrolysis, a caustic or one of the "high potential" treatments leaves as good cosmetic result without bleeding and danger of infection? Why shock a patient prejudiced against and fearful of cutting instruments? Hyperkeratotic, premalignant lesions often yield to carbon dioxide freezing or light applications of caustic potash or trichloracetic acid, or full strength salicylic acid—a few even to the action of simple adhesive plaster.

The cure of epithelioma depends upon removal or destruction of all disease. If the lesion is on the face, especially about the eyes or nose. or on the ear, surgical intervention may offer the least hope of success because there is not space for wide enough excision, unless plastic work is done. This involves a needlessly extensive operation, and more disfigurement than would follow other treatment. In the event of incisions coming too close to the disease there is not only the certainty of leaving malignant cells, but the danger of their instrumental transplantation.

The most beautiful lines of primary union often gradually widen or thicken. Of course any frankly metastatic case must be treated by excision, *en bloc,* of all disease-bearing or metastasis-favoring tissues. If an early destruction or operation is done for even a lower lip disease, mostly squamous in type, it will not be necessary to make the submental and submaxillary dissection.

As my records show, practically all the early cases escaped metastasis, whether treated by caustics, radiation or excision, though every patient was warned of the possible need of later operation. Only two required it —one a physician who chose the caustic potash treatment, and some months later returned with a submental walnut-sized gland mass. Clean removal of this completed his cure. The other passed into surgical hands and died with brain involvement following operations.

Many patients with this disease come prejudiced against one treatment

or another and we may often give them choice of method. A lower lid carcinoma with involvement of the preauricular gland could have no choice; the lid was excised, edges stitched, leaving a closable eye, and the involved node removed. Some months later I dissected out the lower end of the parotid gland with its diseased lymph nodes. Three years have passed without return of disease.

The entire left side cartilage of the nose of a man had been removed by a surgeon, for epithelioma. The recurrence brought to me was a fungating mass the size of a tangerine orange, more than filling the anterior nasal cavity, and growing entirely from the upper and outer incisions. It was necessary to break away the mass and thoroughly treat the wound of attachment with stick caustic potash.

An external ear case had a partial destruction from epithelioma. Curette and caustic potash did not, as final and permanent healing showed, leave any more loss of ear than the disease had induced, which end could not have been attained by proper excision.

I have seen but two epitheliomata of the tongue early enough for cure—both yielding to the actual cautery. What advantage would primary excision and then cautery have offered? The brief interval between excision, if imperfect, and cauterization would have been sufficient for absorption of disease cells.

Caustics, cautery, radiation or other treatment must be sufficient to destroy all disease, particularly the active basal and peripheral part. Otherwise the latter is but stimulated to more rapid growth, a result, however unexpected, that will bring the physician and the treatment into disrepute.

I am in full sympathy with the altruistic work being done for the prevention of cancer and towards the education of the people as to dangers of procrastination, but am sure that the general surgeons' insistence on excision in all cases will retard success in the propaganda.

Better to stand on the wide principle of thorough destruction or removal, the form of treatment being adapted to the case. Contracted views never make for real progress, nor do medical and surgical self-sufficiency conduce to the fruition of high endeavor.

A broad and unselfish discrimination, a recognition of other branches of practice, and acceptance of principles and proven results characterize the truly great in the medical field.

Special Article.

HISTOPATHOLOGY.*

By Walter J. Heimann, M.D., New York.

(From the Department of Dermatology and Pathology, Cornell Medical School.)

Introduction.

In the days of Attic Greece dermatoses were explained as expressions of humoral pathology, and this bias limited the views of European dermatologists, until lepra invaded the continent with the ever-widening circles of Byzantine influence. In the Fifteenth and Sixteenth centuries, however, as it became clear that lepra could be controlled only by isolation and quarantine, a new shaft of light penetrated the dusk of medicine, and it was vaguely realized that not all diseases were of humoral origin, but that outside influences might play an ætiological rôle. Thus, a conception of the infectious origin of diseases arose, which received further support after the Renaissance, when syphilis swept over Europe. In the Eighteenth century, and from then on, serious efforts were made to understand dermatoses in a sense approximating that in which we know them to-day. In France, Lorry (*Tractatus de morbis cutaneis*, Paris, 1777) first advanced the theory of arthritism as an important cause of skin diseases, a direct manifestation of the Hellenic influence. Retz (*Maladies de la peau*, 1775) recognized that certain plants produced rashes. Willan, however, and Bateman, in England, in 1798, actually introduced into dermatology a clinical classification which, though inadequate from our standpoint, was sound enough for a century ago. Biett was a follower in France of Willan's thought, to which Alibert and Rayer were opposed. They classified dermatoses according to alleged internal causes, always with a strong leaning toward Lorry's and the Greek ideas. In 1839 Schoenlein described the achorion, and in 1853 Gruby isolated the microsporon, while Eichstedt discovered the microsporon furfur, and Baerensprung, the microsporon mimutissimum some years later.

Strange to say, the contemporary influence upon dermatology of these momentous revelations was slight, and dermatologists continued to

* This is the first installment of an important series of articles which will appear regularly each month in The Journal.

classify on the basis of clinical characteristics, and to explain, by vague internal theories, until Hebra, whose zenith of influence extended from 1869 to 1880, brought a certain degree of common sense to bear upon the subject. His pendulum swung too far, however, in that he tended to regard all dermatoses as diseases of the skin *per se,* and the integument as a more or less independent organ, uninfluenced by metabolism. He did clear up the ætiology of scabies, and rendered lichen a harmless instead of fatal disease by the use of arsenic in its treatment. This shows that, while he definitely understood the influence of outside agencies as ætiological factors in dermatoses, he must also have attained some realization, without grasping its significance, of the interdependence of the skin and the rest of the human body.

Hebra rendered dermatology another service. Though not a pathologist, he fathered skin pathology by enlisting the aid of his old master, Rokitansky. At about this time, Virchow contributed to this field in his studies on lepra and molluscum contagiosum, and Unna, in 1894, published his extensive work on cutaneous histopathology. The study of bacteriology had also been seriously commenced at this period. These two subjects were ardently pursued, and have continued to interest many investigators both in Europe and America, and to-day nearly every dermatologist, whether trained in the laboratory or not, has a better conception of the broad aspects of histopathology and bacteriology than was the case twenty years ago.

We are on the verge of a new era in dermatology. Studies in internal secretions, anaphylaxis and biochemistry point definitely to the fact that the skin, as all other organs, must participate in general morbid processes. Histopathology has but partly explained the causation of dermatoses. Moreover, we have been disappointed in finding that not every skin lesion possesses a special microscopic picture. In fact, very few do. In other words, histopathology as an infallible guide to diagnosis, is deficient. We have successively attempted to explain skin diseases by classifying them on humoral grounds, on clinical, bacteriological and histological grounds. No one method alone has sufficed. We must not, however, because of this, neglect any of them, and there are three good reasons why every dermatologist should endeavor to understand the broad facts of skin pathology. In the first place, a few of the microscopic pictures are pathognomonic. In the second place, they often are sufficiently characteristic to aid in the diagnosis of doubtful cases when taken into consideration with other features. Finally, a knowledge of the microscopic appearance of skin lesions favors clearness in our clinical conceptions, and hence increases our ability as therapeutists.

Chapter I.

General Considerations.

Although students of cutaneous pathology must be familiar with the structure of the normal skin, the number of good articles on the latter subject renders its inclusion in the present work unnecessary. The last serious contribution, however, on skin pathology as a whole, was Unna's, published about twenty years ago, but which is both too subjective and too exhaustive for practical use. Of our older concepts, many have undergone simplification, while new ones have arisen. Thus, the present volume will seek to review the entire field anew. The microscopic pictures of cutaneous lesions will be described, either according to their histological groupings or according to their pathogenesis, so far as this is understood. Certain technical terms will have to be defined for the sake of subsequent clearness and brevity.

Abnormal processes in the skin may be confined to the epidermis, corium or subcutaneous fat, but most commonly are found in the first two together. Those which develop in the epidermis may involve any or all of its layers, the latter usually being the case. Processes in the corium occur both in the papillary body and lower levels, and are extremely varied. In general, the morbid changes in the skin can be classified under the same heads as those taking place in other tissues, as for example, inflammations, dystrophies, necroses, ulcers, congenital malformations, atrophies, hypertrophies and neoplasms. The individual characteristics of such changes are determined rather by the anatomy of the skin than by the nature of the process. Just as a nephritis and hepatitis differ as the kidney differs from the liver, so does a dermatitis differ from both. This is simply an example of the anatomic modification of universal processes.

In the epidermis, thickening, thinning, exfoliation, vesiculation and obliteration of, or increase in the size of, the rete pegs take place. It must, however, be remembered in this connection, that there are wide variations in the depth of the epidermis and in the development of the rete pegs in the normal skin, in different regions of the body surface. On the palms, soles and face the epidermis is thick and the pegs pronounced and fairly uniform in contour. On the chest, belly, back and flexor surfaces of the extremities, the epidermis is thin and the pegs shallower and less regular. Thickening of the epidermis occurs in any or all of its component strata. In the horny stratum, thickening is called hyperkeratosis (Fig. 1). Under normal conditions, the cells of

Plate I.—To Illustrate Article on Histopathology, by Walter J. Heimann, M.D.

Fig. 1.

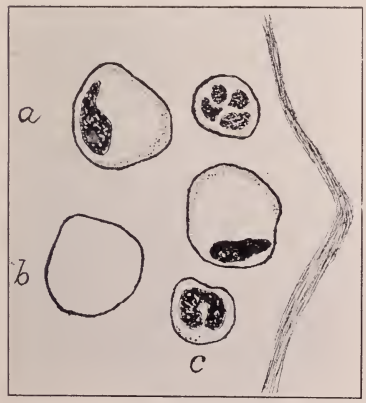

Fig. 2.

Fig. 1.—Semi-diagramatic. Epidermis from a prurigo nodule.

a. Hyperkeratosis.
b. Parakeratosis.
c. Stratum granulosum enlarged.
d. Slightly acanthotic Malpighian stratum.

Fig. 2.—From a herpes vesicle, showing ballooning degeneration.

a. Epidermis cell with eccentric nucleus and very little cytoplasm.
b. Epidermis cell with only cell membrane remaining.
c. Pus cell.

Plate II.—To Illustrate Article on Histopathology, by Walter J. Heimann, M.D.

Fig. 3.

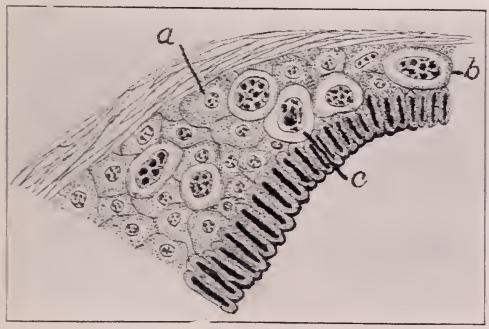

Fig. 4.

Fig. 3.—Semi-diagramatic. Epidermis from lichenified skin showing:
a. Slight hyperkeratosis.
b. Thickening of the stratum granulosum.
c. Intercellular œdema.
d. Acanthosis.

Fig. 4.—Semi-diagramatic. From a case of eczema, showing various stages of "alteration cavitaire."
a. Perinuclear hydrops.
b. Medium state.
c. Advanced state.

Plate III.—To Illustrate Article on Histopathology, by Walter J. Heimann, M.D.



Fig. 7.

Microphotograph of Darier's disease, from the collection of Drs. Fordyce and MacKee.

A. Hyperkeratotic stratum corneum.

B. Malpighian layer thickened and rete pegs enlarged in all diameters (acanthosis). Note the numerous, clear, white, swollen cells with sharp nuclei (alteration cavitaire). Between the horny and Malpighian strata is the granular layer, two or three tiers deep. Some of the clear areas are psorosperms.

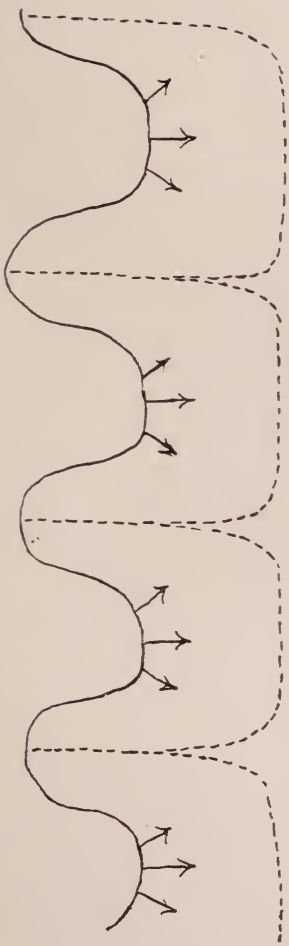

FIG. 5.
Diagram showing obliteration of papillary body by downward and lateral growth of rete pegs (marked acanthosis)—arrows show direction of growth.

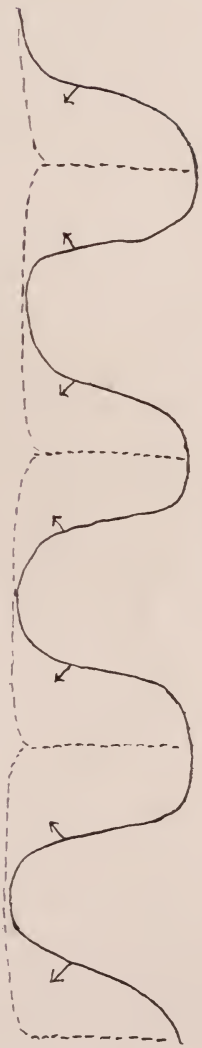

FIG. 6.
Diagram showing obliteration of rete pegs by upward and lateral growth of papillary body—arrows show direction of growth.

this stratum are devoid of nuclei. Should the cells be proliferated so fast as to be unable to mature perfectly, the nuclei remain. This condition is known as parakeratosis (Fig. I). Either of these two processes is found in exfoliative diseases. When the granular layer increases beyond its normal depth of from one to three layers, the process is termed thickening of the stratum granulosum (Fig. III). To cell proliferation in the Malpighian rete, causing increase in the length, breadth or depth of the pegs, is applied the designation acanthosis (Figs. I, III and VII). Thinning of the epidermis is produced at the expense of any or all of the strata except the basal or germinative layer, which never consists of more than one row of cells. In this condition, a few corneous and rete cells always remain, but the rete pegs are usually entirely wanting or only imperfectly constructed in atrophied epidermis.

Obliteration of the rete pegs is the result either of epidermal atrophy, as just mentioned, or of hypertrophy or stretching of the epidermis. When the epidermis hypertrophies with marked acanthosis (Fig. V) the pegs may become laterally confluent, thus obliterating the papillary body so that the entire epidermis is demarcated from the corium by a straight or slightly wavy line, a condition at times seen in the lichens and similar diseases. It may here be stated that the converse may also happen, namely, that the papillary body may so hypertrophy as to obliterate the pegs, producing a like result with a thinning of the epidermis (Fig. VI). This also occurs in lichen, in instances in which the degree of infiltration exceeds that of the acanthosis. Stretching of the epidermis through the upward growth of infiltrations or neoplasms tends to straighten out the rete pegs mechanically, by first stretching the papillary body. This picture is found in the smooth granulomata, xanthoma tuberosum and the like.

Another group of epidermal abnormalities arises by the accumulation of fluid within the confines of this stratum. This process results in the formation of vesicles or bullæ, as the case may be. Vesicles develop in one of two ways, starting either with œdema in the cells or in the intercellular spaces. The mechanism of intracellular œdema was first incorrectly explained by Ranvier and Cornil (*Manuel d'histologie pathologique*, 1884, p. 67, second edition). These observers located the œedema in the nuclei, designating the process as a nuclear hydrops, a hypothesis for many years accepted. In 1878 and 1880, however, Leloir (*Archives de physiologie*) had studied the question and had reached other views. His conclusions were decisive and proved that the œdema was in the perinuclear space, whence it spread to the adjacent cytoplasm, causing the latter to degenerate, and converting the diseased cell into a

sac of fluid in which the nucleus, for a time surviving, was crowded aside. At first the epithelial threads remained intact, radiating from the rounded cell until they, too, finally disappeared, leaving the cell a simple sphere. When two or more contiguous cells were involved, their common walls broke down and a minute space developed which was a vesicle. This is the process known as "alteration cavitaire" (Figs. IV and VII). The margins of the vesicles are formed by a wall of neighboring intact cells. Unna (*Histopathologie der Hautkrankheiten,* p. 156) explained the same phenomenon in an essentially similar manner, under the title of ballooning degeneration. To understand his point of view it is necessary simply that Leloir's be predicated, and to realize that the œdema does not go on with like rapidity in all the cells involved. Those which succumb slowly will remain for a time within the vesicle as rounded bodies (balloons) (Fig. II), and tend to gravitate to the bottom.

In intercellular œdema the process obviously starts in the intercellular spaces. It crowds the walls from without, dilating the lymphatic channels. The cytoplasm takes basic stains weakly and finally a nuclear degeneration sets in. The epithelial threads hold together tenaciously in places, while in others they disintegrate. By virtue of the former fact, however, the entire vesicle becomes reticular or even trabeculated, and hence multilocular, as will be seen in the study of herpes and variola. Unna believes that this method favors old epithelial cells, while Leloir's favors the young (Unna, *Histopathologie,* p. 158). In the early stages of reticular or colliquative vesiculation, in which there is intercellular œdema and beginning cell degeneration, the interlacing canals impart a spongy appearance to the epidermis which Unna calls spongiosis, a condition which will be discussed further and illustrated in connection with eczema.

Bullæ arise either between the stratum granulosum and the stratum corneum above, or in the rete below, or anywhere in the rete, or, finally, between the epidermis and papillary body. These phenomena may be better elaborated in connection with diseases of which they are salient features. In general, however, the process is very similar to that of vesiculation. One further group of epidermal changes, dyskeratoses, must be included at this point, although these changes will require further particularization in discussing the disease which they characterize. Rete cells are capable of undergoing distinctive and curious metamorphoses in size, shape and staining properties, without, in the usual sense, degenerating. Examples of such dyskeratoses are psorosperms, once considered microörganisms, and found in Darier's disease (Fig. VII):

molluscum bodies in molluscum contagiosum, and Unna's x-cells in pointed condylomas. These changes may well be due to some still undiscovered parasite.

The pathological alterations in the mesial layer of the skin or corium may be localized either in the papillary body or in any or all of the deeper levels. In a sense, too, any changes in this layer may be duplicated in the subcutaneous tissue, allowing for such differences as anatomical features would determine. There are many varieties of tissue and many types of organs in the corium, each or all of which may be abnormally altered. The chief substance is the connective or collagenous tissue. It is composed of a dense network of interwoven bundles of fibres, criscrossing at all angles, tending to be slightly wavy and distributed in a prevailingly horizontal fashion in the depths, and in a prevailingly vertical one in the papillary body. Normal collagen takes acid stains. It is mesodermal in origin and springs from mother cells called fibroblasts, which, in normal, matured connective tissue, are sparse. Many of the connective tissue fibres, however, can be traced to definite fusiform cells, known as fixed connective tissue cells. Parallelling the connective tissue is the elastic tissue, consisting of fibres following the course of the collagen bundles, and surrounding them with still finer intercommunicating fibrils. They are composed of a substance called elastin, which takes only special acid stains. The organs of the skin are nerves and nerve-endings, blood and lymph vessels, hair structures, sweat and sebaceous glands, with their respective ducts, muscles and nails. The most important fact to bear in mind is the wide distribution of the lymphatics, for all of the spaces within the connective tissue meshes are part of the lymphatic system.

The changes to which the connective tissue is subject are atrophy, necrosis, hypertrophy, various types of inflammation, degeneration, and involvement by neoplasms. Elastic tissue is never hypertrophied, commonly atrophied, distorted or entirely wanting in certain conditions such as the skin atrophies or after necroses or ulcerations. The first stage of disappearance of elastic tissue is fragmentation. One more fact to be recorded in this connection, is a peculiar type of degeneration in this substance which is indicated by a change in its staining affinity, which becomes basophile, instead of acidophile, a fact first observed by Unna, who designated the product of the metamorphosis as elacin. Elacin fibres are thicker, wavier and shorter than normal elastin, and occur in senile, weather-beaten skin, and in a few diseases.

In connection with the histopathology of the hair, nails, muscles, glands of the skin and their outlets, it need only be stated that they may

either participate in the general abnormal changes of the integument in which they lie, or themselves be the site of especial abnormal processes. Changes in the skin vessels are those common to all vessels in any part of the body. They share in nearly all the abnormal cutaneous changes, and of some diseases form the starting point. Unfortunately the cutaneous nerves have not yet received the attention in skin pathology that their probable importance warrants.

(*To Be Continued*).

REVIEW

OF

DERMATOLOGY AND SYPHILIS.

Under the direction of

FRED WISE, M.D., New York,

Assisted by

WILLIAM H. BAUGHMAN, M.D., New York.
CLARENCE A. BAER, M.D., Milwaukee.
PAUL E. BECHET, M.D., New York.
G. A. CARLUCCI, M.D., New York.
LOUIS CHARGIN, M.D., New York.
J. S. EISENSTAEDT, M.D., Chicago.
CHARLES GOOSMANN, M.D., Cincinnati.
ROBERT C. JAMIESON, M.D., Detroit.
M. F. LAUTMAN, M.D., New York.
M. L. RAVITCH, M.D., Louisville.
ISADORE ROSEN, M.D., New York.
PHILIP F. SHAFFNER, M.D., Chicago.
MAX SCHEER, M.D., New York.
FRANK E. SIMPSON, M.D., Chicago.
A. W. STILLIANS, M.D., Chicago.
JOHN H. STOKES, M.D., Chicago.
HARVEY P. TOWLE, M.D., Boston.

DERMATOLOGISCHE WOCHENSCHRIFT.

(Sept. 11, 1915, lxi, No. 37.)

Abstracted by MAX SCHEER, M.D.

THE PROPHYLAXIS OF PYROGALLOL POISONING. MAX BOCKHART, p. 859.

Ointments of pyrogallic acid, in strength from 5 to 10%, can be used on extensive areas of the body (e.g., in widespread psoriasis) without producing any toxic symptoms and not even a darkening of the urine, if at the same time 1 to 3 gms. daily, of dilute hydrochloric acid be administered internally.

Pyrogallol is most active in an alkaline medium; by combining with the oxygen of the blood, it causes an oxygen deficiency in blood and tissues. Dilute hydrochloric acid, taken internally, by diminishing the alkalinity of the blood, counteracts this undue oxidizing effect of pyrogallic acid.

CONCENTRATED NEOSALVARSAN AND SALVARSAN SODIUM INJECTIONS. J. SCHUMACHER, p. 860.

The author administers neosalvarsan dissolved in 8 cc. of tap water which has been boiled about an hour previously and allowed to cool. He uses a 10 cc. Record syringe. The injections are made intravenously. The results are good and there are no special ill-effects.

Salvarsan-natrium (which is also given intravenously) has, on account of its alkalescence, a deleterious effect on the blood and tissues. This is overcome by adding 2 cc. of a decinormal HCl solution for every 0.15 gm. of salvarsan-natrium to be injected. The drug is added after the decinormal HCl solution is mixed with the water.

(*Ibidem*, Sept. 18, 1915, lxi, No. 38.)

ULCER OF THE FACE (SELF-INDUCED) IN AN HYSTERICAL WOMAN. HANS MARX, p. 883.

The patient, an hysterical and physically underdeveloped woman, aged 28 years, was under observation for about one and a half years. She presented an irregularly triangular shaped, flat ulcer on the left cheek, of about the size of a five-mark piece; the edges were not undermined, there was a narrow inflammatory halo about the lesion, the floor showed from time to time a few islands of epithelium. The lesion was produced and kept up by scratching and was finally cured by the application of an occlusive dressing.

(*Ibidem*, Sept. 25, 1915, lxi, No. 39.)

A COMPARISON BETWEEN SALVARSAN AND NEOSALVARSAN IN RELATION TO THEIR EFFICACY IN EXPERIMENTAL SYPHILIS. MARIO COPELLI, p. 907.

As a result of experiments on rabbits, the author concludes that the antisyphilitic effect of salvarsan compared with neosalvarsan is as 5 to 4: i.e., when the doses employed are equivalent in their arsenic content. Both have a parasitotropic action, but neosalvarsan, at least in rabbits, has, in addition, also some organotropic action. Salvarsan seemed less rapid in its action than neosalvarsan.

A SIMPLE METHOD OF ADMINISTERING SALVARSAN. J. SCHUMACHER, p. 919.

For the chemical sterilization of tap water for neosalvarsan administration, the following conditions are essential:

1. No poison must be introduced.
2. The chemicals must be added in minimal amounts.
3. The sterilization must be certain.

4. There must be no chemical reaction with the salvarsan.

These conditions are fulfilled in the following procedure:

To 6 ccm. of ordinary tap water (in a syringe) are added first 0.001 gm. of iodic acid and then 0.005 gm. of sulphosalicylic acid. Then 0.01 gm. of potassium iodide is added, whereby the total amount of iodine is liberated which is amply sufficient for sterilization. The iodine is then bound by the addition of 0.0016 gm. of thiosulphate. In the water thus treated the salvarsan is dissolved.

These chemicals, in their appropriate amounts, are furnished in ampoules together with the neosalvarsan, in the same package.

(*Ibidem*, Oct. 2, 1915, lxi, No. 40.)

ARGULAN, A NEW ORGANIC MECURIAL. VICTOR MENTBERGER, p. 931.

Argulan is a dimethyl-phenyl-pyrazolon-sulphamino-mercury. It contains 46.8% of mercury; it is insoluble in water but can be suspended in lanoline. It is administered intragluteally in doses of 0.3 gm. at intervals of three to six days.

It is painful, causes infiltrates, is slow in its effects on specific lesions; it is not superior to other mercurials.

DERMATOLOGISCHE ZEITSCHRIFT.

(September, 1915. xxii, No. 9.)

Abstracted by PHILIP FRANK SHAFFNER, M.D.

RESORCIN POISONING PRODUCED THROUGH EXTERNAL APPLICATIONS OF THE DRUG. J. KYRLE, p. 506.

Kyrle reports a case of very severe and almost fatal resorcin poisoning produced by two applications of a ten per cent. resorcin wet dressing, in a boy two years of age. The drug was used in a case of herpes tonsurans maculosus in an attempt to exfoliate the epidermis, Wilkinson's ointment having been used previously, with good results as far as exfoliation was concerned but ineffectual in that the disease recurred.

The signs and symptoms were unconsciousness, pallor and subnormal temperature with cold sweats, cyanosis, superficial and rapid respiration, a very rapid and irregular heart action, dilated pupils, and clonic twitchings of the face and arm muscles. The temperature became high and was accompanied with chills. The urine was a dark violet-green color, becoming black-green on standing. The patient finally made an uneventful recovery.

Kyrle concludes from this case that an intact epithelium is no absolute protection against absorption of the drug. Moreover, absorption can occur even with an intact epidermis and cutis. He believes that the delicate structure of the child's skin (due to his age) was responsible for the absorption and consequent poisoning. Kyrle recommends therefore that only very weak solutions of resorcin be employed on children's skins.

SKIN MANIFESTATIONS, ESPECIALLY HERPES, IN CEREBROSPINAL MENINGITIS. G. SCHERBER, p. 511.

After reviewing the common types of skin abnormalities in this disease, Scherber reports a case of epidemic cerebrospinal meningitis that showed a

herpes facialis and mucosæ oris, and a herpes of the gluteo-crural area, innervated by the first and second lumbar roots. The latter lesions were disseminated and preceded by urticarial swelling. They assumed gangrænous characteristics and were very similar to what Scherber calls "multiple nervous skin gangræne." The author believes that the lesions occurring in the course of cerebrospinal fever are due to nerve involvement alone and comparable to the skin lesions observed in syringomyelia and other diseases of the central nervous system.

SCLERODERMA CIRCUMSCRIPTUM AND ITS RELATION TO LICHEN SCLEROSUS. Enzo Bizzozero, p. 517.

The author, from a study of several cases and from a very critical review of the literature, believes that there are two distinct entities, lichen sclerosus and sclerodermia (Unna's card-like variety) in this group. There are, however, various types of intermediate conditions which border on lichen sclerosus on the one hand and on this form of sclerodermia on the other:

I. Lichen sclerosus.
   1. Cases of C. A. Hoffmann, Ormsby and Bizzozero.
   2. Cases of Dreuw, Kretzmer and Riecke.
II. Lichenoid sclerodermia.
   1. Type of Fisher-Vignolo-Lutati.
   2. Type of Zumbusch-Csillag.
III. Sclerodermia (Unna's card-like variety).

A CASE OF SKIN GRAFTING WITH AN UNUSUAL RESULT. James Strandberg, p. 556.

The patient, when a young girl of twelve years, had a skin graft made on the back of the right hand following a loss of skin through some extensive suppurative process. The surgeon grafted abdominal skin on the hand by fixing the hand to the abdominal wall for a long period of time.

After a number of years the patient began to take on weight and the grafted skin assumed the same fat hypertrophy as did the abdominal wall. This hypertrophy produced a pseudo-tumor of considerable size on the back of the hand. The article contains a very excellent photograph of the hand.

CONCERNING FAT HYPERTROPHY ON THE BACK OF THE HAND. Ehrich Hoffmann, p. 558.

Hoffmann reviews Strandberg's case (see above) and mentions a similar circumstance that came under his observation. Upon a complete excision of the fatty mass and Thiersch's grafts, a cure was accomplished.

Hoffmann mentions the biological interest of these two cases in that, although it has been known that transplanted skin retains its local characteristics, as in skin containing hair follicles, yet it now seems that even the fat cells, in various regions, have and maintain certain characteristics even when the skin is transplanted.

To avoid such unpleasant complications, surgeons must separate the skin from the fat tissues as closely as possible. In the event of a tumor developing, one can excise the same and cover the defect with Thiersch's grafts.

The new growth of blood vessels which occurred in these two cases, manifested by a more or less deep blue color of the tumors, is of interest because it must be determined whether or not these fatty hypertrophies are the result of the normal hypertrophy of the panniculus adiposus or whether the proliferation of blood vessels is partly responsible.

DEUTSCHE MEDIZINISCHE WOCHENSCHRIFT.

(Sept. 16, 1915, xli, No. 38.)

Abstracted by Clarence Allen Baer, M.D.

LYMPHOGRANULOMATOSES (HODGKIN'S DISEASE) WITH PEMPHIGOID EX- AND ENANTHEMATA IN CONNECTION WITH GRANULOMATOUS SKIN NODULES. Ehrich Hoffmann, p. 1117.

The skin manifestations of Hodgkin's disease arrange themselves in two groups:

I. Circumscribed nodules or diffuse infiltrates (few cases).

II. (Larger group). Pruritis and pigmentation of pruriginous lichenoid and urticarial exanthemata; bullous or hæmorrhagic rashes; or erythrodermias. Usually considered toxic.

The bullous or pemphigoid eruptions of Hodgkin's disease have been reported in three cases by Yamasaki, Bloch and Königstein, respectively. The author reports a fourth case of pemphigoid Hodgkin's eruption, that showed in addition to the vesicular lesions, typical lymphogranulomatosis cutis. The history and findings in this case follow. The skin shows many bullæ, some as large as a hen's egg; in the right clavicular region the skin is of a bluish tint, and shows a nodular infiltrate and urticarial swellings. The blood shows 6,000 leucocytes—79% polymorphonuclears, 4% eosinophiles, 2% transitionals, 5% small and 10% large lymphocytes; the superficial lymph glands are enlarged. The Roentgen ray photograph shows enlargement of the mediastinal glands. Von Pirquet's reaction is negative. X-ray treatments produced absorption of the enlarged glands. After a four-week pause, the glands again enlarged. The bullæ were produced by mechanical irritation of the skin and also by irritation from Roentgen ray exposures.

MUENCHENER MEDIZINISCHE WOCHENSCHRIFT

(Apr. 6, 1915, lxii, No. 14.)

Abstracted by Arthur William Stillians, M.D.

RESULTS IN THE FIELD OF DERMATOLOGY OBTAINED BY MEANS OF THE ABDERHALDEN DIALYZING REACTION. G. Stuempke, p. 466.

In secondary syphilis, psoriasis, pemphigus, lichen planus, zoster, dermatitis herpetiformis, toxic dermatitis, universal eczema, seborrhœic, impetiginous, pruriginous and varicose eczema, the blood serum gave a positive Abderhalden reaction with kidney tissue. From this the author concludes that these dis-

cases are especially related in some way to the kidneys. Serum from syphilis in other stages than the secondary had no marked action on the kidney tissue, and one case of malignant syphilis gave a strong reaction with spleen. All syphilitic sera gave a stronger reaction with organs of a luetic fœtus than with normal organs. In many instances chancre tissue and secondary papules were digested by luetic serum, and serum from psoriasis gave a positive reaction with the scales of psoriasis.

(*Ibidem*, Apr. 13, 1915, lxii, No. 15.)

THE LASTING RESULTS OF THE COMBINED TREATMENT OF CARCINOMA OF THE UTERUS AND BREAST. G. Klein, p. 499.

The author uses radium or mesothorium, intravenous injections of enzytol or radium barium selenate and Roentgen rays in combination. Lately he has used radium or mesothorium in the uterus at the same time that he applied the Roentgen rays. He called this "mixed cross fire." He claims that the measurement of the dosage of Roentgen rays by the Kienboeck strips is a false one, for they measure only the soft rays. He uses the spark gap, milliamperage, amperage of the primary current, time and number of exposures to measure the dosage.

Of 25 operable carcinomas of the uterus, 10 are temporarily well, which means that no palpable sign of carcinoma remains. Of 59 inoperable uterine carcinomas, 13 are temporarily cured, and of 16 carcinomas of the breast, 5. The time is too short to speak of a cure. As contraindications to radiotherapy he designates very large carcinoma or sarcoma of the body of the uterus, where the rays cannot act on the whole tumor, and breast cases in which the axilla is full of carcinomatous glands, especially when they surround the large vessels and nerves. Here radiotherapy is insufficient and even dangerous. He often operates now, even when he cannot cut only in sound skin, relying on radiotherapy to clear up any tumor tissue that may remain.

He emphasizes his results in inoperable uterus and breast cases: apparent cure of many of the cases from two to two and three-quarter years. Many of the recurrent cases have been free from all signs of malignancy for various periods, up to nearly four years.

(*Ibidem*, Apr. 20, 1915, lxii, No. 16.)

THE LASTING RESULTS OF THE SURGICAL TREATMENT OF ELEPHANTIASIS-LIKE LYMPHŒDEMA. E. Kondoléon, p. 541.

The author removes longitudinal strips of fascia from the thigh to cure elephantiasis, thus relieving the lymphatic circulation. Of the cases reported, two were completely cured. Two other cases received lasting benefit, two others slight benefit, two failed to report though well at the time of discharge from the hospital. One case was well for a year, then the swelling slowly recurred, so that a second operation was necessary, two and a half years after the first. Good results have also been obtained by Léjars, Lénormant, Boecker and Royster.

ON THE TREATMENT OF SKIN AND VENEREAL DISEASES IN THE FIELD. Gennerich, p. 553.

A review of the various dermatoses coming under the care of the military surgeon and a discussion of the treatment most adapted to the necessities of

war times. For the prophylaxis of venereal disease he recommends the treatment for two weeks, every two months, of each prostitute and strict enforcement of the rule of reporting venereal disease. From his experience in the navy since 1890, he recommends as a prophylactic for gonorrhœa a 20% solution of argentum proteinicum in glycerin, to be dropped into the open fossa navicularis and held two minutes after coitus. Against syphilis, washing the genitals thoroughly for three minutes with a 1 to 500 solution of bichloride in water or 20% alcohol.

Because of the impossibility of holding the soldier long enough to give a complete course of salvarsan in the early stages of syphilis, he recommends treating with mercury alone in this stage, using the mixed treatment in later cases where there is less danger of severe recurrences. He closes with a warning on the necessity of examining the urine for albumin before every injection of mercury or salvarsan, and frequently during a course of inunctions.

A SIMPLE PREVENTIVE OF LOUSINESS AND ITS CONSEQUENCES. EYSELL, p. 564.

The author repeats his claim that precipitated sulphur, dusted carefully into all the seams of the underwear, is the best protection against body lice. He warns against sublimed sulphur because of the irritating crystals. Colloidal sulphur is no more active and costs twice as much. Sulphur salves are not good because the louse remains on the clothes and reaches over to the skin to feed. He advises dusting precipitated sulphur into all underwear before it is issued to soldiers. Those who sweat profusely need more sulphur in about two weeks. Others need it only about once a month.

THE TREATMENT OF SPOTTED FEVER. F. LEVY, p. 567.

The claim of Coglievina, that hexamethylentetramin is of great value in typhus has not been substantiated in the author's experience in about 60 cases. Five cases had severe diarrhœa, which was unusual, and four cases had severe hæmaturia. He saw no benefit from the drug. The best treatment is still lukewarm baths and careful watching and support of the heart.

RUSSKI JOORNAL KOJNIKH E VENERICHESKIKH BOLEZNEI.

(June, 1914, xxvii, No. 4.)

Abstracted by M. L. RAVITCH, M.D.

INFECTION WITH TUBERCULOSIS FROM CIRCUMCISION. KUDISH, p. 513.

While Ricord thought circumcision one of the best measures against manifold sexual diseases. Kudish questions whether this procedure is a good prophylactic measure against diseases of this class and adds that, since there appear many reports of circumcision being followed by tuberculosis and syphilis, this operative procedure should be entirely entrusted to surgeons. Many cases are cited where skin tuberculosis and syphilis were transmitted through circum-

cision, some of them reported by Löwenstein and Shtumisen. Kudish describes a case of syphilis transmitted in this manner. Up to this time the patient had shown no traces of syphilis and the family history was absolutely negative. The circumcision, including the sucking of the blood, was performed by an old man. The wound did not heal and glandular swelling soon developed in both groins and axillæ. The Wassermann test was negative, the von Pirquet was positive.

Pospelov lays particular stress on the contagiousness of lupus and believes the latter is easily transmitted not only from man to man, but from animal to man. He cites a case of a physician who became accidentally infected from lupus in an animal.

THE CAUSATION OF PYOGENIC ONYCHIA AND PARONYCHIA FROM AUTOINFECTION OF A PATIENT SUFFERING FROM SYCOSIS. Troitzki, p. 516.

Pyogenic onychia, according to Troitzki, is due to mixed infection, usually staphylococci and streptococci. Sabouraud described an impetiginous form, occurring most commonly in children and in young adults, and but seldom in grown persons; these pyogenic infections follow impetigo or pyogenic panaritium. The inoculation with pyogenic microbes on the fingers and toes may be accomplished in different ways: directly or indirectly, or even from focal infection. The author cites a case of autoinfection from the clinic of Prof. Zelenev, the patient getting the fingers infected through scratching his chin, which was affected with sycosis.

TREATMENT OF ERYSIPELAS. Bogrov, p. 523.

Bogrov comments on Boston's and Blackburn's treatment of erysipelas and states that out of 483 cases, 327 showed albuminuria and cylindroids. Death from erysipelas occurs very often from streptococcic septicæmia accompanied by endocarditis. The local treatment consists in the application of hot saline compresses and hot air douches for one-half to one hour, two or three times a day. Internally, the tincture of chloride of iron, diphtheria antitoxine, bacterial vaccines and antistreptococcic serum are advocated.

THE CAUSATION OF SARCOMA CUTIS IDIOPATHICUM MULTIPLEX HÆMORRHAGICUM (KAPOSI). Dagave, p. 531.

Troitzki cites Dagave's interesting case. The patient was 23 years old; was ill for one and one-half years, and complained of great pain in the sole of the right foot. Clinical examination revealed nodules on the dorsum of the toes and of the right foot; pigmented skin between toes and on the back of the foot; dark red spots on the surface of the foot, at times becoming bluish-red: the nodules of the skin were the size of a large pea. The left foot was also affected, but not to such an extent as the right. Both wrists were also covered with œdematous and cyanotic spots, which later became infiltrated and nodular. The latter were both discrete and aggregated, in places crowded together. There was an increase of skin reflexes and sensibility to touch in the affected foot, due to changes in the peripheral nerves. The Wassermann reaction was positive. A bioscopic examination of one of the nodules gave the following

picture: the epidermis was rather thin, the interpapillary processes flattened out, but still showing proliferation of the rete; œdema and capillary hæmorrhages throughout the affected area; the cells were mostly of the connective tissue type, both spindle and round; a very few mast-cells; marked vascular dilatation and deposition of blood pigment.

Three injections of neosalvarsan gave splendid results. In less than five months the patient was entirely well and able to resume his work as a laborer, which rather throws doubt on the correctness of the diagnosis.

A CASE OF TOTAL ALOPECIA. Kartashevski, p. 535.

The patient, a man aged 27 years, in perfect health, was absolutely devoid of hair on the head and cheeks. On the upper lip he had five or six hairs and about ten on his chin. The skin was perfectly normal. The only discomfort that he felt was due to the exposure of his head to the cold in winter, and headaches and dizziness from the direct rays of the sun in summer.

SHOULD SALVARSAN BE USED IN SYPHILIS IN THE PRESENCE OF AFFECTIONS OF THE EYE? Ostroumov, p. 548.

The ophthalmologists are often confronted with the above question. According to some authors, salvarsan is contraindicated in optic neuritis, while according to others it is beneficial. Barshavski gathered statistics on 681 cases in which salvarsan was used for different affections of the eye and he found that in 24% of all cases salvarsan stopped the atrophy of the optic nerve, and in 74%, while the atrophic process was not controlled, it was at least not aggravated. Thus no conclusion could be drawn as to its contraindication.

According to Golovin, optic neuritis was increased by the administration of salvarsan. The advocates of salvarsan attribute this development to syphilitic reinfection. They claim that this phenomenon is noticed after the use of mercury, but that it has not received as much attention as in those cases in which salvarsan was used. Ostroumov claims that neuritis has followed the administration of salvarsan even in non-syphilitic diseases, and gives warning that is should not be used when there is a hyperæmia of the retina.

ORTHOSTATIC ALBUMINURIA AND ITS RELATIONSHIP TO SKIN DISEASES, PARTICULARLY OF TUBERCULOUS AND SYPHILITIC ORIGIN. Arnold, p. 570.

Mescherski says that in Arnold's 44 cases of tuberculosis of the skin, the author found that five had orthostatic albuminuria; in eight cases of psoriasis there was one such case; and in seventeen cases of untreated syphilis, there were twelve. In general, orthostatic albuminuria has no connection with a dermatosis like psoriasis. It is seldom met with in cases of tuberculosis of the skin as compared with syphilis, according to Ludke and Sturm, but is often seen in pulmonary tuberculosis.

ANNALES DES MALADIES VÉNÉRIENNES.

(June, 1914, ix, No. 6.)

Abstracted by Paul E. Bechet, M.D.

INFLUENCE OF ANTISYPHILITIC TREATMENT, PARTICULARLY NEO-SALVARSAN, ON THE WASSERMANN REACTION. A. Levy-Bing, M. Dogny and F. Gerbay, p. 401.

From a series of 40 cases the authors arrive at the following conclusions: Neosalvarsan has a much more rapid effect on the Wassermann reaction than mercury. Negative reactions brought about by treatment are never permanent. Results depend upon the age of the syphilitic infection and the intensity of the treatment. In a number of cases it is impossible to affect the reaction, even with long continued intensive treatment. One cannot be guided as to when to institute or stop treatment by the reaction alone. The reaction is not a primordial sign in either the prognosis or treatment of syphilis.

AMERICAN JOURNAL OF THE MEDICAL SCIENCES.

(August, 1915, cl, No. 2.)

Abstracted by R. C. Jamieson, M.D.

LATENT SYPHILITIC INFECTION OF THE LUNGS. H. R. M. Landis and Paul A. Lewis, p. 195.

The authors think that this form of syphilis is more frequent than has been supposed, most of the cases reported showing involvement around the hilus or at the base of the lung. The cases they report, however, show that the apices were involved and exactly simulated a true tuberculosis. All cases were treated at first for tuberculosis and received no salvarsan until after a Wassermann test, following which treatment they improved rapidly and the tuberculosis disappeared. They state that all refractory cases of this type should be treated as luetic if there are other luetic symptoms present, but with many there are no accompanying symptoms. Wassermann tests should be done on all cases that are doubtful.

THE RÔLE OF SYPHILIS IN HYPERTENSIVE CARDIOVASCULAR DISEASE. H. F. Stoll, p. 178.

Stoll states that syphilis is an underlying factor inasmuch as 90% of the fifty cases studied gave a positive Wassermann test or luetin reaction. Most of the cases had a cardiovascular heredity and this would seem to be the form which many cases of hereditary syphilis take. He regards apoplexy and sudden cardiac death as almost always due to lues and thinks that the remaining members of a family in which one parent dies from this cause should have a Wassermann test or a luetin test applied, as a high positive percentage is found. Specific treatment gave good results and it was later found that kidney efficiency had been increased in some cases.

(*Ibidem*, September, 1915, cl, No. 4.)

A STUDY OF SPLENIC ENLARGEMENT IN EARLY SYPHILIS. UDO J. WILE AND J. A. ELLIOTT, p. 512.

Wile and Elliott examined one hundred cases of early syphilis and found a definite and palpable enlargement of the spleen in thirty-six, 78% of these showing a general deterioration in health, 76% an involvement of the nervous system. The enlargement may be present before the secondary eruptions appear and may be either soft or firm. It usually disappears promptly under treatment but may persist longer than other early manifestations.

JOURNAL OF THE AMERICAN MEDICAL ASSOCIATION.

(September 11, 1915, lxv, No. 11.)

Abstracted by WILLIAM H. BAUGHMAN, M.D.

ACANTHOSIS NIGRICANS AS AN INDICATION OF INTERNAL MALIGNANCY. A. J. MARKLEY, p. 925.

Two distinct forms of this disease are recognized: the adult, or malignant, accompanied by a malignant internal disorder in over 50% of the reported cases, short in duration and intensity, and with widespread skin lesions, sometimes marked by exacerbations, remissions or complete disappearance; and the juvenile or benign, showing little or no disturbance of general health, less marked development and spread of skin lesions, which shortly become stationary and persistent.

The case reported was that of a woman, 54 years old, operated on two years previous to the appearance of initial symptoms, for ulcer of the stomach; no symptoms of malignancy except enlargement of the subclavicular lymph glands and the development of cachexia following an exploratory laparotomy, were present. The condition began with intense itching over the abdomen, soon followed by the sudden appearance of numerous warts on the backs of the hands and forearms, and discoloration of the face and neck. Four months later the growths appeared on the tongue and palate, with rapid progress since then.

General condition good. The backs of the hands and forearms showed many hard papillary excrescences of all sizes up to that of a pea: the skin of the wrists was thickened and fissured, the affected parts being of a dark grayish color. The palms were greatly thickened, almost horny, and of a translucent, yellowish hue. The axillæ and genito-crural region were deeply pigmented; the former showed many soft filiform warts. The sides and back of the neck and the shoulders showed pigmentary changes, varying from gray to sooty black, and numerous papillary growths. The face showed pigmentary changes, a few warty growths on the forehead and a growth of coarse white hair. The ciliary borders were granular and had many large soft papillomas. The auditory canals and nasal orifices were surrounded by a rim of small filiform growths. The vermilion borders of the lips were wholly occupied by small and large papillary growths, the dorsal surface of the tongue was covered by long filiform projections, the hard palate was completely filled in by a dense condylomatous mass, the outer surfaces of the gums were involved and a condylomatous growth projected from each interdental space. The inner surfaces of the lips and cheeks were but slightly affected, and the fauces and pharynx were entirely unaffected. The scalp was dry and scaly, and the hair was being rapidly lost.

ILLUSTRATIONS OF THE HISTORY OF LEPROSY. D. W. MONTGOMERY, p. 927.

The various conceptions of leprosy held by different nations in ancient and modern times are narrated.

SYMPTOMS AND DIAGNOSIS OF LEPROSY, WITH REPORT OF CASES. H. MORROW AND A. W. LEE, p. 931.

Leprosy is a chronic, systemic infection produced by a semi-acid-fast bacillus, resembling somewhat the tubercle bacillus, implicating at some time any or all of the body units. Clinically, cutaneous lesions are: a macular eruption, trophic changes following nerve involvement, areas of pigment increase or decrease and hypertrophic processes located in the corium and superimposed structures. The macular lesions may be large or small; they are usually round or ovoid with sharply defined and sometimes raised margins; varying in color from bright red in early lesions to reddish brown; tending to clear in the centre, the integument becoming fawn colored or of a normal appearance, and to form gyrate figures as the process becomes chronic. The margins may show a purplish tinge or deep pigmentation in the outermost limits. On disappearance of the lesions there remains an area of decreased pigmentation, crape like irregularity of the skin, and scales. The lesions may be entirely free of changes in sensation, or hyperæsthetic, in the later stages anæsthetic. With an exacerbation of the eruption, the color usually becomes bright red. Pigmentary changes may occur independently of a macular eruption.

Unlike the macular and pigmentary lesions, direct implication of the nervous system produces deformities, most marked in the hands and feet because of the frequent involvement of the ulnar and peroneal nerves; and a rarefying osteitis resulting in the clinical condition of lepra mutilans, incapacitating the patient for work and rendering his personal appearance repugnant. Numerous large nodules may form, the eyes may be destroyed, the nasal bones absorbed, the nostrils closed, and spontaneous amputation of the fingers and toes occur. Bullæ are a rare manifestation, usually appearing on the hands and feet.

In the nodular type, large nodules usually appear on the face, smaller ones on the body. Hoarseness, an early manifestation, is due to the presence of nodules in the larynx and pharynx. Submucous lesions tend to ulcerate, but to heal during remissions. The nodules are generally located in the skin, but may occur subcutaneously, are frequently elastic to the touch, and, not unusually, large comedones occur on the trunk and extremities. Aside from the nodules, there is deep wrinkling of the forehead, broadening of the nose, thickening of the lips, and tumefaction of the skin at the outer part of the eyebrows, producing a "leonine expression." The hair of the face usually falls out, that of the scalp becomes dry and prematurely gray. Well marked nodules are usually grouped and of a reddish-brown color, becoming a brighter hue during exacerbations. Anæsthesia sets in early and may disappear in a few months or persist for years, with or without ulceration. Areas of cicatricial atrophy or of deep pigmentation remain at the sites of former non-ulcerated nodules.

Subjective manifestations include malaise, migratory neuralgic pains, anorexia, depression of mental and physical faculties, paræsthesia, occasional general hyperhidrosis, desquamation of the skin, and fever of a malarial character.

The eye is frequently involved in all types of leprosy and occasionally quite early. In the nerve type, excessive lacrimation followed by marked xerosis, atrophic shrinking of the mucous membrane, and distortions of the eyelids occur. Inability to close the eyelids from paralysis of the muscles is followed by drying of the cornea, exfoliation of the epithelium, deep infiltrates of the parenchyma and involvement of the interior of the globe. In the nodular type, nodules develop in the conjunctiva, cornea and iris. Iritis is common. The deeper corneal nodules tend to ulcerate, and frequently the entire uveal tract is involved, terminating in shrunken, painless globes requiring enucleation.

Material for investigation may be obtained by excising a nodule, curetting the affected area and examining the material microscopically, after being stained by the acid-fast method.

A report of thirteen cases is appended.

THE ÆTIOLOGY AND TREATMENT OF LEPROSY. E. D. Chipman, p. 934.

The causative agent is the Hansen bacillus. The disease is not hereditary. The contagiousness varies with different phases of the disease. Various insects, as the fly, bedbug and acarus of scabies, are possible intermediaries.

Prophylaxis consists of maintenance of good health and proper sanitary conditions, with segregation of lepra cases. Medical treatment is empirical; at present, chaulmoogra oil combined with camphorated oil and resorcin promises good results. Climate, food, hot baths and good hygienic conditions influence favorably all cases.

(*Ibidem*, Sept. 18, 1915, lxv, No. 12.)

CASES FROM THE SKIN CLINIC OF LELAND STANFORD, JR., UNIVERSITY SCHOOL OF MEDICINE. H. E. Anderson, p. 1018.

(*Ibidem*, Sept. 25, 1915, lxv, No. 13.)

TREATMENT OF SYPHILIS OF THE BRAIN. A PRELIMINARY REPORT OF THE USE OF MERCURIC CHLORIDE INTRADURALLY. G. O'N. Ireland and C. S. Wilson, p. 1108.

Twenty-three cases diagnosed clinically as general paralysis, most of them being in the so-called third stage, were given intradural injections of mercuric chloride, according to the method devised recently by Byrnes. The injections were combined in various cases with injections of neosalvarsan by the Swift-Ellis method, intravenous injections of neosalvarsan, and intramuscular injections of mercury. All but three cases showed clinical improvement at some time during treatment, 40% of these latter showed a tendency to return to their former clinical state. Reactions consisted of severe pain in the back, legs and testes; marked depression and constipation in some cases; the reaction was less marked with autogenous serum than with pooled serum. The serologic improvement was not so marked or constant as the clinical. The colloidal gold test was least affected by treatment. Clinical improvement usually appeared after about five treatments.

BRITISH JOURNAL OF DERMATOLOGY.

(Aug. 15, 1915, xxvii, No. 8.)

Abstracted by I. Rosen, M.D.

MYCETOMA PEDIS. H. C. Semon, p. 299.

Semon, in a short report, describes a case of mycetoma pedis, a disease mostly found in the tropics. There is a club shaped enlargement of the foot, with a filling up of the plantar arch. The skin over the dorsum is of dark, almost livid hue, and the exuberant growth, consisting of puffy, purplish granulations, is perforated at intervals by sinuses of varying depth, from which the typical granule-containing pus exudes.

The diagnosis is made by culture of the organism. There have been described fifteen distinct pathogenic varieties of mycetoma, which are divided into three groups, according to the color of the escaping granules; black, white or yellow, the commonest species being the melanoid, to which category the author's case belongs. Under the microscope, one sees a central mass of mycelium, obscured entirely by black pigment.

TWO CASES OF SWEAT GLAND TUMORS. W. H. Alderton and H. M. Turnbull, p. 304.

The authors describe two cases of tumors beginning in the sweat glands. One was an inflamed papilloma which rapidly healed after excision and treatment with X-rays. The other developed into a melanotic carcinoma, with rapid metastasis, terminating fatally.

NEW YORK MEDICAL JOURNAL.

(Sept. 4, 1915, cii, No 10.)

Abstracted by I. Rosen, M.D.

A HELPFUL SIGN IN DIAGNOSING LATENT SYPHILIS. Irving W. Voorhees, p. 491.

Voorhees states that, while operating for sub-mucous resection, if there should be difficulty in elevating the flap, and the blood should be darker than normal and more profuse, the cartilage and bone rough, suspect syphilitic involvement. The author has taken Wassermann tests in three of his cases where the above conditions existed, and found them all positive.

(*Ibidem*, Oct. 2, 1915, cii, No. 14.)

INFANTILE ECZEMA. H. W. Cheney, p. 704.

Cheney believes infantile eczema to be principally a nutritional disorder, and that in a great majority of cases the skin eruption is only the external evidence of this metabolic disturbance; treatment therefore should belong to the pediatrist, and not the dermatologist.

In speaking of the treatment, the author states that many cases clear up immediately upon the proper regulation of the diet of the infant. External applications are used only secondarily and any of the bland ointments, such as zinc oxide, starch with petrolatum, rubbed on to allay the irritation, are of service.

VIRGINIA MEDICAL JOURNAL.

(Aug. 5, 1915, xx, No. 9.)

Abstracted by I. Rosen, M.D.

ROENTGEN RAY THERAPY IN LARGE MEASURED DOSES. H. H. Hazen, p. 225.

INTERSTATE MEDICAL JOURNAL.

(June, 1915, xxii, No. 6.)

Abstracted by I. Rosen, M.D.

THE TREATMENT OF RECENTLY ACQUIRED SYPHILIS WITH MERCURY AND SALVARSAN. Douglass W. Montgomery, p. 532.

EDINBURGH MEDICAL JOURNAL.

(September, 1915, xv, No. 3.)

Abstracted by I. Rosen, M.D.

NOTES ON THREE CASES OF MALIGNANT PUSTULE. Alexander Miles, p. 201.

Miles reports three cases of malignant pustule, two of which were cured by free excision and touching up of the bases with pure carbolic acid, and then packing with iodoform gauze. The third case was cured by two injections of Slavos' serum, the first dose being forty cc., repeated in twenty-four hours by another injection of twenty cc.

BOSTON MEDICAL AND SURGICAL JOURNAL.

(July 8, 1915, clxxiii, No. 2.)

Abstracted by I. Rosen, M.D.

LEPROSY AND ITS RELATION TO MASSACHUSETTS. James A. Honeij, p. 48

The author emphasizes the importance of recognizing early cases of leprosy. Many rather advanced cases have been making the rounds of the various hospitals of Massachusetts before a correct diagnosis was made.

Certain manifestations are typical of the disease, and all physicians should be on the lookout for these symptoms: fever, with or without a macular erup-

tion, epistaxis, rhinitis or coryza, catarrh or other nasal symptoms, enlarged glands, areas of anæsthesia, itching, usually of the extremities, ill defined pains, small nodules on the face, are all described as early symptoms and lesions. Careful bacteriological examinations of nasal secretions should be made in every suspected case.

Leprosy being contagious from person to person, the patient therefore should be isolated. The children of lepers should be separated from their parents as soon as possible and should remain under observation. Examination of those having lived with lepers should be made from time to time. Lepers should not engage in trades or occupations.

(*Ibidem*, Aug. 5, 1915, clxxiii, No. 6.)

THE TREATMENT OF ECZEMA WITH SPECIAL REFERENCE TO THE USE OF VACCINES AND THE PART PLAYED BY BACTERIA IN ITS ÆTIOLOGY. LEON S. MEDALIA, p. 187.

The author's paper is based on fifty obstinate cases of eczema that did not respond to the ordinary therapeutic measures. The most prevalent organism found was the Staphylococcus aureus. The streptococcus and the Staphylococcus albus were found in a few of the cases.

The vaccines used were all autogenous and the dosage depended upon the severity of the case and the organism present. In a staphylococcus infection, the initial dose was one hundred million organisms, whereas in a streptococcus infection, he would begin with twenty-five million. The doses are increased gradually, and are given about every three or four days. The results obtained with this treatment were in a great measure successful.

BOOK REVIEWS.

THE PRINCIPLES OF BACTERIOLOGY. A PRACTICAL MANUAL FOR STUDENTS AND PHYSICIANS. A. C. ABBOTT, M.D. Ninth Edition. 650 pages, with 113 Illustrations, 28 of which are Colored. LEA AND FEBIGER, New York and Philadelphia, 1915.

This new edition retains the elementary character of its predecessors. The important new features are chapters on the ultramicroscopic or filterable viruses and on immunity and the Wassermann reaction. The few faults are mainly those of omission. The spirochæta pallida is disposed of in 14 lines (p. 178) which are devoted to Stern's method of staining. The bacillus of Ducréy, the trichophytons, the achorion Shoenleinii, the blastomycoses and sporotrichoses are not discussed. As a text book for students the book is excellent; as a text or reference book for those interested in dermatology, it will prove disappointing.

M.S.

SYPHILIS AS A MODERN PROBLEM. By Wm. Allen Pusey, M.D., Professor of Dermatology in the University of Illinois. *Chicago.* American Medical Association, 1915. Cloth, $1.00 Paper, 50 cents.

"This monograph is a part of the Commemoration Volume, issued by the American Medical Association at its meeting in San Francisco, June 22 to 26, 1915, as a tribute to the medical sciences, which made possible the building of the Panama Pacific Exposition."

It is no easy matter for a man who has for many consecutive years addressed the work of his pen to his brother-physicians, to write a complete and substantial scientific monograph, intended chiefly for the education of the layman. None but a versatile individual is likely to succeed in such a task. Fortunately, therefore, a wise choice was made in the selection of Dr. Pusey for this work.

In his little work of 130 pages, the author has succeeded in depicting the subject of syphilis in an entertaining and comprehensive manner: although written primarily for public consumption, it is safe to predict that there are few physicians, be they specialists or otherwise, who will not enrich their store of knowledge—or, at the very least, refresh some of the vague and hazy information stored away in the corners of their brains—by a perusal of the book.

The subject-matter is divided into twelve chapters. The first three deal with the historical aspect of syphilis; the next three, with the course of the malady; hereditary syphilis forms the subject of the seventh chapter; the eighth chapter is devoted to pathology, the ninth to prognosis, the tenth is entitled "Syphilis and Marriage," the eleventh deals with ætiology, the twelfth with prophylaxis.

From the layman's point of view, the outstanding feature of the work is the author's bright and cheerful outlook on the subject, with regard to the existing, as well as the latent victims of syphilis, as we understand the disease to-day. To the layman who is afflicted with both syphilis and syphilophobia, the little book is good medicine; to the youth who is "spoiling" for an infection, it is an excellent prophylactic; and to the host of patients who have safely passed the ordeal of a "cure," but whose minds, nevertheless, are possessed by faithlessness, fear and scepticism, the work is veritably a star of hope. In fact, the whole trend of the work is optimistic, not only in relation to actual sufferers from the malady, but also to those who are destined to become its victims in the future.

That Dr. Pusey is anything but an alarmist, many of his statements show. On p. 83 he says: "But except for its influence on the mouth, tobacco cannot be severely arraigned as affecting the prognosis of syphilis." Again, on p. 84: "As a practical fact, however, patients with damaged kidneys are usually able to pass through secondary syphilis without exaggeration of the syphilitic symptoms and with little or no effect on the course of the kidney disease."

The period of a week or ten days following the appearance of the chancre, during which the Wassermann reaction is negative, Dr. Pusey aptly calls "the golden opportunity in syphilis."

On the other hand, we see (p. 86) that the author does not permit his optimism to carry him beyond certain bounds; for here he says: "After syphilis has reached the tertiary stage, the prospect of the complete eradication of the spirochetes by specific treatment is practically gone. The patients may be freed from symptoms, but all vestiges of the infection cannot be destroyed."

Regarding his attitude toward the Wassermann reaction in its relation to contemplated marriage, Dr. Pusey believes that in late syphilis a positive Wassermann alone, "does not constitute a reasonable barrier to marriage." He subscribes to the old rule, "that a patient may marry five years after infection with syphilis, provided that during the first three years he has been thoroughly

treated and during the last two has shown no manifestations of the disease. And this regardless, as Keyes, Jr., has recently emphasized, of the Wassermann reaction at the end of five years."

The average intelligent young man (or young woman, for that matter), who reads this booklet understandingly, will have gained a considerable addition to his or her store of useful information.

(Orthographic errors: P. 24, *thory* should be theory. P. 34, *organ* should be organism. P. 78, *are* of great interest should be, is of great interest. P. 114, the word prostitute should be followed by comma. instead of semicolon).

F. W.

NOTICE

The readers of THE JOURNAL are requested to send items of personal interest about themselves or any dermatologists at home or abroad, to Dr. Howard Fox, 616 Madison Ave., New York City, for publication in THE JOURNAL. News items relating to college, hospitals or dispensary appointments, publication of books, election to office or other honors, marriages, family deaths, etc., are especially solicited.

NEWS ITEMS

DR. HENRY H. WHITEHOUSE has been appointed Professor of Dermatology at the New York Post-Graduate Medical School and Hospital, to take the place left vacant by the recent resignation of DR. SIGMUND POLLITZER.

DR. A. SCHUYLER CLARK has been appointed Professor of Dermatology at the New York Post-Graduate Medical School and Hospital, to take the place left vacant by the death of DR. WILLIAM BEDFORD BROWN.

DEATHS

Charles T. Dade, M.D., Dec. 26, 1915.
George T. Jackson, M.D., Jan. 3, 1916.
James C. White, M.D., Jan. 6, 1916.

THE JOURNAL OF CUTANEOUS DISEASES

Vol. XXXIV. FEBRUARY, 1916 No. 2

EDITORIAL

LEPROSY A NATIONAL PROBLEM.

At its last meeting in Atlantic City, the American Medical Association passed a resolution urging upon Congress the establishment of a national hospital for the care, treatment and study of leprosy. Within the past year or two several cases of leprosy have attracted wide attention on account of the scandalous behavior of an ignorant and alarmed public in the communities in which the cases occurred. The unfortunate victims of the disease have been driven from pillar to post and have been subjected to barbarous treatment that would have been a disgrace to a mediæval village in darkest Russia. A case of this kind driven from one town to another constitutes to a certain extent a real danger, which could best be obviated by prompt transference, under proper precaution, to a sanatorium.

The conditions under which leprosy may spread are not definitely known. That the disease is contagious is beyond any question and that both in the past as well as in recent times, entire countries have been swept by the disease is a matter of record. Leprosy has been endemic in the East, the cradle of the race, from the earliest times. It was scattered over Europe in the wake of the Roman army. Cases occurred sporadically in the countries under Roman domination, their number slowly increasing with the centuries till in the eleventh or twelfth centuries, probably as the result of the great movements of men at the time of the Crusades, there was a rapid increase in the number of cases, and in all the civilized countries of Europe the disease assumed the astounding proportions of a pandemic. Asylums for lepers became as common as hospitals to-day. At the end of the thirteenth century there were not less than two thousand leprosaria within the confines of France alone. During the succeeding centuries the incidence of the disease began to decline; the last indiginous leper in the British Isles

died a hundred years ago, and to-day the disease is known in England and France only by cases imported from leper countries.

In the Sandwich Islands the disease was unknown till about the middle of the last century. Introduced from the Orient, the number of cases increased slowly at first, then more rapidly, till within a single generation of the appearance of the first case a considerable percentage of the entire population of the Islands was affected by the disease. With intelligent inspection and strict isolation in the excellent hospitals under the direction of the Public Health Service of the Government, the epidemic gives signs of having run its course, but it will be many years, probably several generations, before the disease will have been stamped out.

At the present time the number of cases of leprosy within the United States is small; between five hundred and one thousand cases is a liberal estimate. While there is no strong evidence of a tendency to the development of an epidemic there is no doubt that the number of cases is slowly increasing. Through our great ports of entry cases are constantly passing undetected, for experts are agreed that it is not possible to recognize the disease in its earliest stages. In Louisiana and some other Gulf States, in the middle Northwest and on the Pacific Coast we have foci of leprosy in which new cases are occurring with more or less frequency.

In only three States in the Union is provision made for the care and isolation of lepers. The State of New York virtually ignores the disease, with the result that according to the best authorities there are probably one hundred and fifty lepers in the City of New York and its environs. In the City of New York leprosy is a reportable disease, and the Health Department exercises a certain amount of supervision over the cases, being prepared to isolate them if the sanitary conditions seem unfavorable in a given case. The free admixture of this element of contagion among our people constitutes a menace which at any time—if we read history aright—may become imminent. The care of these cases in State Hospitals is economically wasteful and their treatment from a medical and sanitary point of view necessarily inadequate. A State with three or four lepers among its inhabitants cannot be expected to provide a proper hospital for their care. These cases are often shifted across the border into another State. The matter is eminently one of national concern. The transfer of patients from one state to another can be controlled and regulated only by Congress. The present moment when the disease in our country is still comparatively rare, is a peculiarly favorable time for measures of national scope for the proper

control and care of lepers with a view to checking its possible spread into an epidemic of national magnitude.

At the last session of Congress, the House of Representatives passesd a bill, which met the approval of a joint committee of the American Dermatological Association and the Dermatological section of the American Medical Association, providing for the care of lepers by the Public Health Service of the United States. This bill (H. R. 20040) after passing the House did not come to a vote in the Senate. The bill will be brought up again during the present session of Congress. Members of the Dermatological Association and others interested in this important problem are urged to present the facts to their representatives in Congress and to make every effort to the effect that Congress takes action promptly.

S. Pollitzer.

ORIGINAL COMMUNICATIONS

THE ANAPHYLACTIC PHENOMENON IN ECZEMA AND THE RECENT PROGRESS IN OUR KNOWLEDGE OF THE ÆTIOLOGY AND TREATMENT OF THE DISEASE.*

(A Preliminary Report.)

By Charles J. White, M.D., Boston.

Assistant Professor of Dermatology in Harvard University.

(From the Skin Department of the Massachusetts General Hospital.)

No one who sees much of the condition called eczema can fail to appreciate the fact that the chronic type of the disease remains to-day one of the most perplexing problems which await solution. Innumerable treatises have been written upon the subject of its ætiology and its treatment for many generations, and yet how little even we moderns definitely know. Many writers have argued that the disease is purely

* Read before the 39th Annual Meeting of the American Dermatological Association, New York City, May 13-15, 1915.

of external origin; others have held equally tenaciously to the belief that the condition arises from an internal source; and a third group have declared with decided justice, I believe, that both internal and external factors are at work in the production of this baffling malady.

Have we made any progress recently toward the elucidation of this enigma? I believe we have.

Careful clinical observation has demonstrated clearly the various trades and callings which contribute materially by their methods and by their necessary processes to the coincidence of eczema. This knowledge is not wholly new to dermatologists but the modern social-economic movement is insistent that factories shall be more hygienic and that trades shall be made less dangerous and harmful, and this impelling force is spurring men on to more intimate knowledge of their patients and their daily lives, and, as a result, I think we dermatologists also have gained some recent knowledge regarding additional external sources of eczema.

Two years ago, at the meeting of the American Medical Association, one of our members, Dr. Towle, read a paper prepared by himself and Dr. F. B. Talbot, a pædiatrist, which I think has received but scant recognition among dermatologists at large, although the pædiatrists are alive to the importance of the subject. This paper definitely revealed the fact that a goodly percentage of eczematous infants were passing fæces containing an excess of fats or of starches. The readers were not at all insistent in their claims and perhaps their modesty hurt their cause, for dermatologists have apparently not laid sufficient importance upon this contribution, so far as I can judge, to the literature and have allowed the pædiatrists almost alone to pursue the theme further, much to the detriment of our prestige. This paper of Dr. Towle and Dr. Talbot made a deep impression upon me and since then it has become a rule in my practice to treat an eczematous infant in the following manner: The patient receives what seems the most suitable external application for the type of eczema present. At the end of a week the patient is seen again and if there has not been a decided amelioration of symptoms he is sent with his latest stool to Dr. Talbot, who almost invariably reports the finding of an excess of fat, less frequently of starch. Dr. Talbot then removes or diminishes the amount of the fat or of the sugar from the milk and from that time onward the eczema usually rapidly fades away, thus reducing to a few weeks' duration a disfiguring and tormenting condition, which, in my previous experience, had required for its eradication the first two winters of the child's life. Not only is this long period of treat-

ment largely obviated, but the shorter task is usually accomplished with much less care, for masks, straight jackets, boxing-gloves, fixation of the arms, *et cetera,* seem now no longer to be necessary.

Fæcal examinations from a certain number of these eczematous infants and older children do not seem to reveal any excess of fat or starch and in these rather exceptional cases the pædiatrists again have taught us to seek a possible eczematous source in egg anaphylaxis. This knowledge is obtained, as you know, from inoculation of the skin with the white of an egg. As a rule, egg anaphylaxis results in urticaria and in asthma, but I have seen a few examples of hitherto intractable eczema where the disease has slowly but permanently disappeared with the gradual artificial immunization of the patient to egg white.

From the above statements it would appear that the solution of the problem of the treatment of infantile eczema had been largely solved and to my mind this statement is warranted. But what of eczema in adults? Can we make the same claims? I do not feel competent to answer this question at present, and, so far as I can ascertain from a diligent search, there is no literature on the subject. Granting that we find an excess of fat or of starch in the fæces of an adult, the exclusion of all offending food substances from the diet of the average individual is a very difficult problem, for adult food is a complex food. Meat and fish often contain fat; eggs appear most unexpectedly in many dishes; vegetables or other carbohydrates are usually prepared with butter or milk—in fact we adults can scarcely obtain a food product which is not a compound of two or more of the several varieties of food substances.

Scientific methods of pure or simple food preparation are, however, possible when one can command the services of a "diet kitchen" and when this privilege is available, success can perhaps be obtained in adults as well as in infants, and the following cases demonstrate the value of this new method of attacking this old problem in adults. The number recorded is very small, of course too small to carry much weight, but as I have hinted above, it is very seldom that we can avail ourselves of the privileges of a "diet kitchen" in feeding our patients.

Report of Cases.

Case 1. Eruption of one year's duration. A typical varicose eczema of the fissured, moist variety, covering the entire lower leg. Stool was foul-smelling and alkaline, containing a great excess of neutral fat and of soaps, but no starch or vegetable fibres. The patient was placed upon a fat-free diet and in four days there was no excess of fat in the fæces and the eczema was greatly improved.

Case 2. A recurrent winter eczema with reddened infiltration, fissures and moisture of the face and neck in a man with arterio-sclerosis and mitral insufficiency. His fæces were dark, alkaline, and ill-smelling, and contained a large amount of free fats, fatty acids and soap, but no starch. A fat-free diet was instituted at once and one week later the fatty elements had disappeared from his stools and there was no indication of his previous eczema.

Case 3. The disease began on the left cheek three years previously and had gradually involved the skin of the whole face and body to such an extent that the limbs were contracted and the skin of the face would crack when the mouth was opened. The fæces were filled with masses of undigested starch but fats and soaps were absent. The patient was given a starch-free dietary and in six weeks left the hospital, free from her previous cutaneous afflictions.

Case 4. A child of three years, living upon an essentially adult diet. The disease had been present for eighteen months and at entrance to the hospital the face, neck, axillary regions and chest were moist and oozing. The stools showed a moderate amount of free fat and soap and much coarse vegetable matter. After a two weeks' suspension of all fat from the diet the face was almost free from involvement. The child was then given regular house diet and skin and disposition rapidly reverted to the conditions observed at entrance. Fat-free diet was again instituted and twenty-five days later the child was discharged, free from all outward manifestation of her disease save a slight scaliness behind the ears.

Case 5. The child had been allowed to eat everything. Six months earlier a red area developed on the face and was treated without success by several doctors. On entrance the whole face and neck were covered with moist crusts and the body showed generalized but isolated areas of infiltration, oozing and crusting. The stool was dark brown, ill-smelling and alkaline, and revealed a large amount of free fat and soap. A fat-free diet was administered and in sixteen days fat had disappeared from the stools and the skin was greatly improved. Unfortunately, the parents then took the child away.

Case 6. A child of four years showed on his face dry, cracking lesions and on his body a papular eruption. There were no fats in the fæces but large numbers of vegetable fibres and cells, algæ, cellulose and fruit and vegetable débris. The patient was put on a modified "house" diet and in eleven days there were no longer any signs of eczema. The child was then given a weighed carbohydrate diet and one week later the eruption was as bad as at entrance. The proper diet was restored and in two weeks the child left the hospital apparently well and was still free from eczema when it reported two weeks later, the proper diet having been adhered to.

Case 7. Male, æt. 71 years. (Case 43 in food tests). Leucocyte count 7,600. Hæmoglobin 85%. Stools dark, foul-smelling, formed and alkaline and contained large amounts of free fat and soap, but no starch. Putting this man on a fat-free diet reduced the fatty elements in his stools to nothing and caused a marked amelioration of his eczema. On several occasions the man was discharged practically free from cutaneous eruption but he would immediately break his diet rules and indulge in pastry and cream and in a comparatively few days return for the treatment of his recrudescent eczema. Redness, infiltration and moisture of face, neck and legs were the usual symptoms.

CASE 8. Female, æt. 30 years. (Case 53 in food tests). Eczema has been present as long as patient can remember. The severity of the disease has varied but the eruption has seldom been wholly absent and the face and hands have been the greatest sufferers. Lesions were papular and there was a more or less universal, papular, excoriated eczema, quite suggestive of scabies, except that the face was much involved. Leucocytes numbered 10,600, eosinophiles 0. The fats were removed from the diet so far as possible and two months later the patient wrote saying: "My skin remains perfectly well and it is the first time within my memory that it has ceased to trouble me for so long."

Let it be well understood that in these previous citations from our records as well as in all those that follow, external treatment has been used in all cases. It is not claimed that proper feeding alone will cure obstinate cases of eczema, although it might in time, but it is our object in this communication to emphasize the fact that suitable feeding plus appropriate external treatment has been able to cure rapidly many cases of infantile eczema and some examples of hitherto intractable adult disease.

The examination of fæces requires a degree of experience and skill which many of us do not possess and it is at all times a disagreeable process. The thought has therefore occurred to some men that there might be a simpler, quicker and more attractive method of arriving at the same valuable data relative to food poisoning. As mentioned above, pædiatrists have recently learned in certain cases of eczema, urticaria and asthma to detect the patient's susceptibility to egg by inoculating egg white into the skin, and the rhinologists have employed the same procedure in demonstrating the poisonous qualities of various pollens in their relation to so-called hay-fever and rose-cold. Somebody, I don't know who, applied this borrowed knowledge to dermatological problems and we at the Massachusetts General Hospital have been employing these tactics for a year or more. The principle involved seems to be that of the von Pirquet test for tuberculosis and the Schick test for diphtheria.

It was not a question in our minds that all patients with obstinate eczema had become sensitized to one type of food, for example egg albumin, but we regarded it as a possibility that all types of food might be incriminated in the foundation of the disease. With this end in view we have made these food tests on a reasonable number of eczematous individuals. The manual part of the work has been done by my successive house officers, Dr. Charles Dennie, Dr. Wade Wright and Dr. Lawrence Lunt, and I wish to thank these assistants for their conscientious help, without which this study would probably not have been possible.

The method has been as follows: the upper layers of the epidermis of the flexor surface of the forearm are broken in eight places in two parallel rows of four by the rotation of a dental burr. Neither blood nor serum should be drawn. On the first abrasion is placed a drop of fat-free milk; on the second a drop of egg albumen; on the third a small piece of salt-free butter; and on the fourth a few grains of lactose or a drop of oatmeal water. On the parallel controls nothing is used and the house officer has generally inoculated himself with the same substances each time a patient has been tested. In only one instance in all these opportunities was there a reaction on the operator, and that to fat-free milk. Simply breaking the surface of the epidermis in this way seems to produce no reaction except in a comparatively few instances, but after the food substances have been applied there is a slow and gradual change if the tests are to prove positive. Patients vary, but in the great majority of instances thirty minutes seem to denote the acme of the reaction, the rise and decline apparently being approximately equal. The maximum result observed has been a pink-red, elevated papule—never a wheal or a vesicle. All degrees of reaction up to this maximum have been noted and our method of interpretation has been to call a tense papule ++, a well developed papule + and a maculo-papule ±. Mere maculation — the appearance of erythema alone — has been disregarded in our findings.

A Study of the Anaphylactic Phenomen in Chronic Eczema.

Case 1. Male, æt. 4½ years. Disease present since birth. Treated for four years. Eruption consists of oozing redness of face and scalp, at times impetiginous. Von Pirquet negative. Food tests: negative.

Case 2. Female, æt. 24 years. Disease present since childhood and now consists of old lichenoid areas on flexor surface of wrists, on back of neck and on thighs. Tests: milk ±.

Case 3. Female, æt. 60 years. Recurrent attacks of eczema on fingers, face and bend of elbows usually following the use of some strong house cleaning substance. At times hands are red and œdematous; at others, skin is dry, red and scaling. Tests: negative.

Case 4. Male, æt. 8 weeks. Child breast fed. Has an occasional green stool. Scalp shows a large cradle cap and for five weeks there has been a redness and scaling of forehead and side of scalp. Tests: albumin ++, butter +.

Case 5. Male, æt. 7 months. White cell count, 20,000. Eosinophiles, 1%. Stools are yellow and sour and show many large, coarse, white curds. Infant breast-fed for two months and afterwards according to milk formulæ. Disease present for six months. The scalp, forehead and cheeks are moist, red and crusting. With the use of crude coal tar and suitable changes in the milk formulæ, disease was cured in twenty-five days. Tests: milk±, albumin +++.

Case 6. Male, æt. 52 years, carpenter. Disease off and on for fifteen years, always better in summer. Indigestion occasionally. The back of fingers and outer edge of hand showed a pink, superficially fissured, scaling, and in places, oozing skin. Tests: ± to all inoculations and controls.

Case 7. Female, æt. 8 years. Leucocytes, 6,000-11,000. Hæmoglobin, 75-90%. Eosinophiles, 2-3%. Stool shows some fat but not in excess. Disease present for two years. Eruption was finely papular for weeks and later became erythematous and impetiginous, affecting scalp, face, hands, arms, neck and upper thorax and accompanied by marked adenitis. Rebellious to many forms of treatment, including the use of X-rays and auto-serum. Aggravated by a non-nitrogenous diet, and somewhat benefited by a low fat régime. Tests: milk+, albumin +.

Case 8. Male, æt. 54 years, iron founder. White cells, 7,400. Hæmoglobin, 80%. Eosinophiles, 5%. A possible pituitary tumor complicated the case. Eruption for five years and always better in winter. Itching is universal and skin is dry. Face, however, is red, infiltrated, oozing and covered with crusts. Tests: milk +, albumin ++, butter ±.

Case 9. Female, æt. 43 years. Disease present with exacerbations and remissions for eighteen years, always manifest in winter. Fingers and forearms show indefinite, single and grouped, red and moist papules. Left hand and wrist are infiltrated, moist and crusting. Tests: milk +, albumin ±, butter ±, lactose ±, all controls ±.

Case 10. Female, æt. 16 months. Whole lower face a mass of oozing and crusting with similar areas on lower legs. Tests: milk ±, butter ±, lactose ±.

Case. 11. Female, æt. 20 years. Disease present three years off and on. An erythemato-squamous, mildly exudative condition. Palms red, dry and harsh; forearms red and infiltrated. Milk +, albumin +, butter +, lactose +, all controls +.

Case 12. Male, æt. 11 months. Child breast-fed. Disease evident for ten months. Forehead, cheeks, chin and wrists red and furfuraceous. Tests: milk ± albumin +.

Case 13. Female, æt. 40 years. Duration of outbreak, two months. Previous attack three years previously. Present eruption consists of redness, œdema and scaling of face, arms and legs, and subsequently an outbreak of grouped papules on the trunk. Tests: negative.

Case 14. Female, æt. 51 years. In 1904, varicose eczema; in 1906, a vesicular eczema of eyebrows; in 1913, a second attack on legs; and at present the skin of legs is dusky red in color and leathery in consistency. Tests: negative.

Case 15. Female, æt. 33 years. Patient is alcoholic and for the last ten days the arms and trunk have been excoriated. A papular urticaria and acne rosacea are also present. Tests: albumin and its control ±, butter +, control of lactose ±.

Case 16. Male, æt. 62 years. A man devoting himself to fishing in winter and sailing in summer has had eczema for seven years and now presents greatly thickened, fissured and exfoliating palms. Tests: milk ±, butter ±, oatmeal ±.

Case 17. Male, æt. 37 years, barber. Eczema for one year and all fingers of the right hand and several of the left are red, swollen, fissured and scaling. Tests: milk +, albumin +, butter +, and the controls of albumin and butter are both +.

Case 18. Male, æt. 3 years. The disease has been present, off and on, for two years and now the cheeks are pink and scaling and the trunk and back of thighs show grouped crusting papules. Tests: milk +, albumin ±.

Case 19. Female, æt. 6 years. Disease has been present ever since birth but child has not been treated. The hair is like tow and the skin of the face and bend of the elbows is infiltrated and excoriated. Tests: butter ±.

Case 20. Male, æt. 4 months. There are scattered macules on the trunk, and skin of the palms, flexor surface of the arms, lower abdomen, penis, scrotum and thighs is bright red and moist. Tests: milk ±.

Case 21. Male, æt. 63 years. Carriage painter. The patient has been under observation for perhaps fifteen or more years and has had repeated and obstinate attacks of œdema, redness, moisture, scaling and crusting of face, hands, and, at times, of body. He evinces a marked susceptibility to bismuth ointment and always does better with washes than with ointments. Tests: butter ±.

Case 22. Female, æt. 6 months. At age of one month the whole body was affected. Child entirely breast-fed. Now the skin behind the ears and in folds of neck is red and moist. Tests: milk ±, albumin ±, butter ±, control of albumin ±.

Case 23. Male, æt. 4 months. The baby is breast-fed and has bottled milk as well. For two months eruption has been present and consists of an extensive cradle cap and redness, scaling and, at times, moisture behind the ears and on the left cheek. Tests: milk +, albumin ±.

Case 24. Male, æt. 42 years. Worker in shoe factory for eighteen months. Two months ago eczema developed on lower legs and then appeared on hands and wrists. There are discrete patches of dark red, infiltrated and dry crusting skin. Tests: milk ±.

Case 25. Male, æt. 2 years. Since early life skin has been "broken out" Child nursed only ten days. Eruption comes and goes, better in summer. There is much itching and face, hands and arms show erythema, excoriations and bloody crusts. Tests: milk ±, butter ±.

Case 26. Female, æt. 23 years. Disease appeared four months ago and new lesions are constantly appearing. There are oval or round, pink-red macules which coalesce and form large polycyclic areas. Tests: negative.

Case 27. Female, æt. 3½ months. Breast-fed and constipated. The face, forehead and scalp are red and vesicular: the scalp greasy as well. Tests: milk +++, albumin ++, butter +++

Case 28. Female, æt. 27 years. Eruption has been present for years despite the use of "Rexal, Cuticura, Poslam, DDD and Cadum." Disease more aggravated in spring and autumn. All fingers, wrist and bend of elbow present infiltration and a reddened, oozing and crusting surface. Tests: butter +. lactose ±.

Case 29. Male. æt. 76 years. Fifteen months previously patient was stung by an insect and despite treatment, an eczema followed. The back of right hand showed a large, circular, red and moist area which was followed by an obstinate local redness and dryness and by an eczema of the groin. Tests: milk ±. albumin +, butter+, control of albumin and of butter ±.

Case 30. Male, æt. 46 years. Lawyer. As a boy could not drink Jersey milk. Free from eczema until after engagement to be married, now eighteen years ago. A long series of dinner parties, where patient indulged constantly and heartily in rich foods and wines, has been followed by many years of winter itching and consequent eczematisation of face and hands. Ointments do not agree but relief is gained by the use of washes and of zinc and glycerite of starch, but the greatest alleviation is gained by out of door exercise. Two children out of four have suffered severely in their early years from eczema. Tests: butter+, milk ±.

Case 31. Female, æt. 59 years. For the last eight months there has been redness and moisture, and slight scaliness behind the left ear and on the adjacent neck. Subsequently the affected skin became more deeply infiltrated and covered with branny scales. Tests: milk±, butter ±, lactose ±, all controls ±.

Case 32. Female æt. 42 years. Disease developed four months previously and now consists of bright red. oozing and, in places, scaling areas on left leg, right arm and back of left hand, while a maculo-papular eruption appears on the neck and face. Tests: negative.

Case 33. Male, æt. 14 years. Duration three years and disease always worse in cold weather The face and arms are thickened, lichenified, excoriated and crusted and there are excoriations over the rest of the body. Tests: negative.

Case 34. Female. æt. 14 years. Disease has lasted for one year and now consists of a leathery, yellow-red, excoriated condition of the face and hands. Tests: milk ±, albumin ±, butter ±.

Case 35. Male, æt. 66 years. Locomotive engineer. Five months previously the disease began as red papules on the wrists, followed by watery exudation. There have been several recurrences, one following the application of a plaster for a strained ligament. There is now a congested condition of ears, neck. forearms, hands, genitals and legs. Tests: milk +, albumin +, butter +, oatmeal water +, all controls +.

Case 36. Female, æt. 22 years. For the last four or five years there have been recurrent attacks of scattered, moist, oozing eczema. At present there are infiltrated areas on thighs. Tests: negative.

Case 37. Female æt. 29 years. During the last twelve years there have been recurrent and obstinate attacks of dryness, infiltration and scaliness on scalp, cheeks, hands, legs and thighs. At present the hands and forearms are red and leathery. Tests: milk +, butter +, lactose ++, control of albumin ±.

Case 38. Male, æt. 39 years. There have been recurrent attacks af eczema for twenty years and at present the cheeks and back of the neck are red and scaly; and the hands, front and back, and the forearms are red and crusting. Tests: albumin ±, butter ±, lactose +.

Case 39. Female æt. 14 years. Disease appeared at the age of three months and has persisted intermittently ever since. To-day the flexures of elbows and knees, the forehead and the neck are pink, infiltrated and dry. Tests: milk +, albumin ++, butter ±.

Case 40. Female æt. 23 years. During the winters of 1905-1908 the patient complained of rough cheeks and again this winter the same condition of erythema and rough scaling exists. Tests: milk ±, albumin +, butter +, controls of butter and lactose ±. For the first time in all the tests Dr. L. K. Lunt, the operator, showed a reaction to milk.

Case 41. Female æt. 11 years. On the left arm there are three pink-red eczematous patches, ¾ of an inch in diameter, and the patient states that she has shown the same condition for the last few winters. Tests: milk +, albumin ±, control of albumin ±.

Case 42. Female æt. 10 years. Leucocyte count, 10,000. Hæmoglobin, 75%. Eczema has existed for three years, principally on face and genitalia. The child is poorly nourished. While under observation in the skin ward on several occasions last autumn the disease manifested itself primarily on the scalp, in the eyebrows and on the neck in the form of redness and adherent crusting. There was discharge from the ear and nose, eventuating in an attack of erysipelas. This patient was benefited more by autogenous vaccines than by any other form of treatment. Tests: milk +, butter +, lactose +. The child would be discharged free from eruption but would return in few weeks as bad as ever.

Case 43. Male, æt. 71 years. Leucocyte count, 7,600. Hæmoglobin, 85%. Stools dark, foul-smelling, formed, alkaline and contain large amounts of free fat and of soap, but no starch. Putting this man on a fat-free diet reduced the fatty elements in his stools to nothing and caused a marked amelioration of his eczema. On several occasions the man was discharged practically free from cutaneous eruption but he would immediately break his diet rules and indulge in pastry and cream and in a comparatively few days return for the treatment of his recrudescent eczema. Redness, infiltration and moisture of face, neck and legs were the usual symptoms. Tests: butter +, controls of butter and of lactose +.

Case 44. Male, æt. 47 years. A large, oval, infiltrated area on lower left leg, associated with varices and of twenty months' duration. Tests: negative.

Case 45. Female, æt. 2 years. Leucocyte count, 10,000. Hæmoglobin, 75%. The child was breast-fed for four months and then given cow's milk and eggs. At the age of two months a lesion appeared on one heel and eczema developed

and has persisted ever since. The scalp is crusting and caked; the face and ears are red, oozing and bleeding; the eyelids are stiff; the back is red and stiff; the chest and abdomen are rough and papular and excoriated; the thighs and groins are red and infiltrated; the popliteal spaces are reddened. The fæces showed a moderate excess of fatty acids and soaps. The child was put on a fat-free diet and treated externally and in less than three weeks all areas, save the scalp, were healed. This region required six additional weeks to be cured. Tests: egg albumin, +.

Case 46. Male, æt. 3 years. Eczema for one year and there are now oozing lesions on scalp, abdomen and genitals with some papules on trunk. The fæces show an excess of fat. White count has varied from 10,000 to 37,000. Hæmoglobin, 75-80%. The eyes are prominent, the tonsils are enlarged and there is a general adenitis. Percussion and radiograph reveal an enlarged thymus gland. Two X-ray exposures of 30 milliampere minutes, 70,000 volts, with aluminum filter, produced a decided subsidence of the thymus and of the leucocytes. Tests: albumin +, fat +, lactose +.

Case 47. Male, æt. 67 years. An eczema followed through six months of the most varied treatment at home and in hospital, including a trip to Jamaica, vaccines, X-rays, all to no avail. A universal œdema, generalized infiltration and bronzing of the skin, accompanied by multiple furunculosis and complicated by cardio-renal involvement. Tests: negative.

Case 48. Female, æt. 45 years. Skin always chaps in winter and at present there are several nummular areas of pink-red, sharply bounded infiltration on neck, chest and thighs. Another entirely recalcitrant example with but little improvement at the end of six months. The patient is one who enjoys good food and lunches and dines out constantly. Tests: milk ±, butter and 40% cream each +, orange marmalade ±. Many other foods were inoculated in this case but gave negative tests.

Case 49. Female, æt. 16 years. Diesase began in Europe three years ago and has recurred at intervals. At present the eruption consists of pink-red to yellow, slightly infiltrated, delicately scaling, sharply bounded areas on upper lip, around neck and in bend of elbows. Tests: milk ±, butter +, 40% cream +. Many other tests were made but proved negative.

Case 50. Female, æt. 46 years. Patient very nervous and for ten years a sufferer from hay-fever and asthma. (In this connection note the positive reaction to egg albumin). Leucocytes, 12,000. Hæmoglobin, 80%. There have been for many years papules on hands and shins and now there is a universal erythema with œdema and infiltration and some moisture of lower back and legs. Tests: milk, albumin, butter, lactose and all their controls +.

Case 51. Female, æt. 51 years. Disease present during most of the last fourteen years and has affected a major part of the body first and last. The face and hands have always borne the brunt of the attacks and to-day, after the use of a strong solution of washing soda, the fingers are pink and moist and vesicular and the face macular. Tests: milk +.

Case 52. Female, æt. 26 years. Eight months ago the wrists were erythematous and pruritic. One month later the arms were involved up to the elbows. To-day the eyes are œdematous and the hands and arms are red, infiltrated, fissured and scaling. Tests: negative.

Case 53. Female, æt. 30 years. Eczema has been present as long as patient can remember. The severity of the disease has varied but the eruption has seldom been wholly absent and the face and hands have been the greatest sufferers. Lesions are papular and to-day there is a more or less universal papular, excoriated eczema, quite suggestive of scabies, except that the face is much involved. Leucocytes numbered 10,600, eosinophiles 0. Tests: milk±, albumin ±, butter +, lactose ±, control of milk ±. The fats were removed from the diet so far as possible and two months later the patient wrote saying: "My skin remains perfectly well and it is the first time within my memory that it has ceased to trouble me for so long."

Case 54. Female, æt. 23 years. Patient is nursing a baby and three weeks previously, eruption appeared. Now a red, moist and crusting condition of the palms, umbilicus, pubes and vulva. Tests: negative.

Case 55. Female, æt. 18 years. The girl works in a woolen mill and the atmosphere is decidedly dusty. For ten years, both in Sweden and in this country, the disease has been present and to-day there are curious-looking, yellow-red papules on "butterfly" area of cheeks and on arms. Tests: albumin ±, butter +, lactose +, control of lactose +.

Case 56. Male, child. Disease off and on for four years. Stool examination was negative. Tests: milk +. The patient was deprived of milk in all its food and in one month the eczema was apparently cured.

Summary.

1. There were twenty-four cases of moist, oozing, crusting eczema. Four patients gave entirely negative tests and in six the controls were positive. Fourteen patients reacted positively to fat-free milk; nine to egg albumin; thirteen to salt-free butter; and six to lactose or to oatmeal water.

2. There were twenty-four cases of red, infiltrated, dry and scaling eczema. Five patients gave entirely negative tests and in nine the controls were positive. Sixteen patients reacted positively to fat-free milk; twelve to egg albumin; sixteen to salt-free butter; and seven to lactose or to oatmeal water.

3. There were three cases of papular eczema. None gave entirely negative tests and in two the controls were positive. Two patients reacted positively to fat-free milk; three to egg albumin; two to salt-free butter; and two to lactose or to oatmeal water.

4. There were two cases of lichenoid eczema. One patient gave entirely negative tests and the other reacted positively to fat-free milk.

5. There were two patients where the only symptom was an infiltrated, leathery skin. One of these individuals gave entirely negative tests and the other reacted positively to fat-free milk, to egg albumin and to salt-free butter.

6. There was one patient who exhibited merely excoriations due to intense pruritus. This individual reacted positively to egg albumin and to salt-free butter and one of the controls was also positive.

Conclusions.

From the facts thus recorded and from other investigations not detailed we make the following deductions upon the question of food in its relation to chronic eczema at various ages of life.

A. Eczematous infants usually present in their stools an excess of fat or of starch. An excess of the former element generally means a moist eczema; of the latter, a dry type.

B. When eczema is present and neither fat nor starch appears in excessive amounts in the fæces the physician should look for susceptibility to egg albumin or to milk, or, in default of all these more common causes, to a diminished thyroid secretion.

C. Susceptibility to egg or to milk can be demonstrated by the new method of food inoculations — a procedure analogous to the von Pirquet test for tuberculosis and the Schick test for diphtheria.

D. This cutaneous method can be extended to the study of the action of other food elements in eczematous individuals.

E. Normal people, so far as we have ascertained, do not react to these tests.

F. In chronic eczema the great majority of its victims seem to exhibit anaphylactic reactions to one or more types of food substances.

G. This phenomenon, as evinced in the few instances investigated, seems to be present in other diseases which have been associated in the past with food disturbances, notably urticaria and probably acne vulgaris.

H. Approximately 20% of eczematous individuals do not appear sensitized to any of the common food types. These exceptions may denote that all cases of eczema are not due to food sensitization or that special individual articles of food, not tested by us, may be the causative factors. Such exceptions have been demonstrated by pædiatrists where, for instance, one child's asthma is produced by English walnuts.

I. In practically 30% of these eczematous patients one or more of the controls proved positive. This sign may be considered analogous to the symptom usually observed in urticaria, *i.e.*, dermographism.

J. In the few cases where both stool examination and cutaneous tests were made there was one contradictory finding. Fat was excessive in the stool and negative on the skin, while starch was present in the

fæces and negative cutaneously. Further combined examinations must be prosecuted in the future to strengthen this whole present theory of the relationship of food poisoning to chronic eczema.

K. One cannot apparently tell from the type of eczema present what food elements will give positive skin reactions.

ERYTHEMATOUS AND URTICARIAL ERUPTIONS RESULTING FROM SENSITIZATION TO CERTAIN FOODS.*

By William L. McBride, M. D., Kansas City,
and
Edwin Henry Schorer, M.D., Kansas City.

Varieties of fundamental foods, whether they be fats, carbohydrates or proteids, produce untoward symptoms. Of these the proteids seem to have a selective action for producing urticarial or erythematous manifestations. The peculiar reactions of certain individuals to some of the proteid foods are of considerable importance because, in the first place, they are common and essential food substances and in the second place, while the reactions are considered of little consequence, they still at times are obstinate and cause great inconvenience to the affected individual.

The cutaneous conditions, especially urticaria, were originally considered as a very mild grade of inflammation or by most writers, a vasomotor neurosis. The microscopic findings of Jadassohn, Török, Gilchrist and others were those of inflammation. Gilchrist[1] found, in sections of wheals, marked œdema of the connective tissue and fixed cells, emigration of polynuclear leucocytes, emigration of lymphocytes, pronounced fragmentation of the polynuclear leucocytes and fixed connective tissue cells, a few mast cells, swelling of the cells of the sweat glands and fibrin scattered throughout the corium. He gives as an explanation of this phenomenon that some toxine is circulating in the blood and in the production of a wheal there is liberation of this toxine which produces death of cells and is followed by an acute inflammatory change.

* Read before the 39th Annual Meeting of the American Dermatological Association, New York City, May 13-15, 1915.

[1] Gilchrist, *Jour. Cutan. Dis.*, 1908, p. 122.

The causes of disease are divided into two broad groups, predisposing and actual. The predisposing factors reduce or lower the vital and physical powers of the body and the actual causes are the ones that produce what we regard as the disease. Predisposing factors include age, sex, race, occupation, hygienic conditions of environment, heredity, food and connate conditions which include temperament, diathesis and, finally, idiosyncrasy.

Proper foods should not cause inconveneince to the consumer but for various reasons this is not always the case. Generally foods cause disease because they are not of proper quality and contain harmful substances; and foods of good quality may cause disease because they are not properly chosen, prepared and modified. Thus it is found that certain proteids of the simplest kind may produce mild or severe systemic and local symptoms. These manifestations were for a long time supposed to be due to idiosyncrasy, later experiments changed the causes of some of them from the predisposing to the actual and, in other words, have taken the cause of the disease away from the individual and laid it at the door of the proteid. On this basis we usually say they are due to alimentary toxæmia arising from visceral disturbances or a general toxæmia. Because, however, the primary attack is often followed by others on the ingestion of the smallest amount of the same article of food, the phenomenon of anaphylaxis has been resorted to in explanation of at least some of these cases.

Until one has analyzed the histories of a sufficient number of cases of these toxic erythemata, it is impossible to realize the constancy of symptoms produced by any one food and the variations of manifestations of the dfferent foods. While we have seen many cases, in only sixty are our histories complete and accurate enough to be of value. Our data are based on observations in patients varying in age from seven months to sixty years and are shown in Table I.

Many of the important findings noted in the above table cannot be enumerated here, but there are certain factors and facts that demand especial mention. It will be noted that these eruptive conditions apparently due to foods occur in children and adults, the more frequent occurrence in children being due to the fact that eggs and cereals are foods of early life. The lesions more often take the character of urticaria than of erythema, but it is to be noted that fish, tomatoes and cheese produced in our series only urticaria, while eggs usually were followed by urticarial lesions, and cereals and pork caused erythemata in a considerable percentage of the cases. The lesions usually appeared within less than four hours; tomatoes and cereals are likely to produce

TABLE 1.—SHOWING VARIOUS REACTIONS OBSERVED IN PATIENTS SENSITIZED TO VARIOUS FOOD SUBSTANCES.

Food Substance	Children	Adults	Urticaria	Erythema	When Appeared After Eating			Duration of Eruption				Probable Inheritance	Respiratory Symptoms
					—1 hr.	2-4 hrs.	4-12 hrs	3-6 hrs.	6-12 hrs.	1-7 days	12-24 hrs.		
	%	%	%	%	%	%	%	%	%	%	%	%	%
Eggs	80	20	75	25	40	40	20		60	20	20	45	60
Fish	10	90	100		10	10	80		20	50	30	Acquired	40
Cereals ..	60	40	40	60	65	20	15	20	40	25	15	40	40
Pork		100	60	40	40	60			100			40	40
Nuts		100		100			100		100			Acquired	—
Tomatoes	25	75	100		100				75		25	Acquired	—
Cheese ..	25	75	100			50	50	25	25	50		Acquired	—

their lesions in less than an hour, while fish, nuts and cheese are often not followed by lesions until after four to twelve hours. The eruption itself usually lasted one to twelve hours, but in a small percentage of cases persisted from one day to a week.

The peculiar reactions toward eggs, cereals and pork we have been able to show definitely, are inherited in a considerable percentage of the cases, having been able to trace the susceptibility back to mother, father or some member of the immediate family, they themselves having had the symptoms as long as they could remember.

Probably the most striking complication was the involvement of the respiratory tract; this varied from a slight cough to a severe dyspnœa. More than half of our cases of egg sensitization showed these symptoms, although they occurred in a considerable proportion in sensitization to fish, cereals and pork.

ANAPHYLAXIS IN GENERAL. That the sensibility of individuals to diseases, drugs and so on varies, has long been observed. What we to-day would call anaphylactic or hypersensibility phenomena were probably first recorded by Jenner, who observed that variolous matter, when the system is to reject it, excites inflammation on the part to which it is applied earlier than when it produces cowpox. Koch's observation that tuberculous guinea pigs are more susceptible to injections of tubercle bacilli than are normal pigs, and that tuberculous guinea pigs are markedly affected by tuberculin, while normal guinea pigs are quite non-susceptible to tuberculin, probably marks the first practicable application of anaphylaxis in diagnosis. Richet and Portier, in 1902, introduced the term anaphylaxis in the explanation of hypersensibility observation

in dogs to tox-albumins. Hypersensibility to serum which, in recent years, has been the most considered part of anaphylaxis, received but little attention before 1903, although diphtheria antitoxine had been used generally since 1894. The earlier of the observations on hypersensibility to serum were made by von Behring, von Pirquet and Schick, Theobald Smith, Arthus, Rosenau and Anderson, and Gay and Southard. Many other workers have since studied the problems of anaphylaxis, and most of the observations have been made on animals injected with blood serum. Other substances of an albuminous nature have, however, also been used to sensitize against parenteral introduction of heterologous or foreign proteins.

While it is easy to understand why hypersensibility to blood serum should have been determined when introduced parenterally, still it is hard to see why hypersensibility to egg albumin, milk and other foods were not tried when introduced intrastomachically. Indeed, the most severe consequences of serum injections in man, the cases of sudden death, are found to occur largely in those who have never had a former injection of horse serum and, therefore, if this sudden death in man is the same as anaphylaxis in animals, then sensitization must have occurred, and this can only have been as a result of intrastomachical introduction of the albuminous substances. Rosenau and Anderson succeeded in sensitizing guinea pigs to horse serum injections by feeding horse meat and horse serum. That the intrastomachical introduction of certain albuminous foods produces anaphylactic or hypersensibility phenomena was suggested a few years ago and now, apparently with little corroborative work, this view has been quite generally accepted.

It has been assumed as one of the objects of this presentation to add what knowledge we may have on the relation of food urticarias and erythemata to anaphylaxis or hypersensibility. For this purpose the anaphylactic phenomena, the most prevalent theories of anaphylaxis, and the food urticarias and erythemata, in the light of these theories, will be considered.

Anaphylactic Phenomena. Anaphylactic phenomena or manifestations of hypersensibility occur as toxic symptoms following some second or subsequent introduction of an albuminous substance into the living organism, which substances, on their first introduction, produced nothing abnormal. The anaphylaxis most studied and best understood is that which follows when an animal receives an injection of serum and it is noted that reinjection of this same serum produces toxic symptoms. While there are many variations, the following factors and observations hold generally for experimental anaphylaxis.

1. There is a sensitizing substance or antigen, of an albuminous nature, which may be from serum, animal or plant albumin, milk, egg albumin, pollen, bacteria and so on.

2. The injections may be made intravenously, intraperitoneally, subcutaneously and so on.

3. The amount used for sensitization is usually small, from .001 cc. to 5 or 10 cc.

4. Before hypersensibility is detected or manifested, it is generally necessary that a period of time (incubation period) must elapse between the first and second injection. The length of this period varies, but is generally from six to twelve days.

5. After hypersensibility has been once established, it may persist for years.

6. To produce anaphylactic shock an injection of the albuminous substance is made into the sensitized animal. The amount injected may be very small. The symptoms may come on almost immediately, but in some cases not until five or six hours, and vary in severity and character. In the severe reactions the animal becomes excited and moves about from place to place, scratches itself, rubs its nose with the forefeet, coughs, falls down, has respiratory distress, voids and defæcates, has convulsions, becomes paralyzed and dies in respiratory failure.

7. There is a difference of opinion as regards the lesions produced. Gay and Southard found definitely localized hæmorrhages in several regions, especially the stomach, and fatty changes in the voluntary muscle and nerve fibres. Auer and Lewis observed contracted bronchi and dilated alveoli of the lungs.

8. Within limits, sensitization is specific, being quantitatively or relatively, but not absolutely so. Very much smaller amounts of the homologous albuminous substances produce the reaction than of the heterologous albuminous substances.

9. Animals may be sensitized with serum that has been dried and dissolved and when dry, the horse serum may be heated to 170°F. for ten minutes.

10. Hypersensibility may be passively conferred to normal animals by injection of serum from sensitive animals, but passive hypersensitization is not well demonstrated until a number of hours after such injection.

11. Immediately following anaphylactic shock and repeated injections of antigen in smaller doses, there is a state of immunity to anaphylactic shock from further injection of the same antigen. This state is

called anti-anaphylaxis and is absolute, but only temporary and in this way distinguished from immunity.

12. It is possible, by repeated injections of proper sized doses, tc immunize a hypersensitive animal.

Toxic Erythemata Due to Food Sensitization and Anaphylactic Phenomenon. 1. Various albuminous substances apparently act as antigens, the principle ones being eggs, cereals, nuts, cheese, fish tomatoes, strawberries and so on. It is, however, observed that in some cases the food itself is not the antigen, but that the antigen is produced from the food by parasites (tape worm, ascaris, amœba and so on; Cases 1 and 8). It is probably fair to assume that some foods, in certain cases, do not act as antigen until they have undergone partial digestion in the intestines (Case 3) or partial decomposition in storage (Case 4).

2. The introduction of the antigen or food is usually by the mouth, and it is noted that the reaction may occur when the substances are introduced by mouth, but not always is it injected into the skin (Cases 1 and 2). In these cases it again is fair to note that the antigen may not be the food itself but one of the decomposition products.

3. It is very hard to determine the amount necessary to intra-stomachically sensitize the individual, as food sensitization is inherited, acquired early in life and occurs unknown to the individual. Apparently, in the cases of acquired sensitization, only small amounts are necessary.

4. Because we are dealing with such important and commonly used foods, it was impossible in any one of our series to determine the exact time elapsing between the sensitizing dose and the first development of sensitization.

5. Hypersensibility to food may and frequently does last throughout a lifetime (Case 5).

6. The amount of food that must be taken by the hypersensitive individual to produce urticaria or erythema varies. In some cases, even the application to the mucous membrane of the mouth is sufficient to produce the reaction (Case 6). The severity of the reaction varies in different individuals, in some cases even becoming grave.

7. The lesions of the skin, as has already been stated, are those of acute inflammation. In various parts of the body circumscribed œdemas occur, producing respiratory distress, vomiting, so-called mucous colitis, and so on.

8. Hypersensibility to foods is markedly specific; in some cases it seems to be absolutely so, the individual being hypersensitive not only to one food, but only to that food when certain conditions exist, as the

presence of parasites (Cases 1 and 8). In some cases there is only relative specificity, the individual being hypersensitive to several of the proteids (Case 9).

9. Hypersensibility to certain foods is transferred by inheritance, and probably may be transferred passively, as is hypersensibility to injection of serum.

10. Whether a state corresponding to anti-anaphylaxis exists in hypersensibility to foods, we are not able to prove. The results of our own experiments on this point have been most unsatisfactory. This may be partly due to the fact that we selected severe cases and produced increased instead of lessened reactions.

11. It is possible, in most cases, to increase the tolerance for, and immunize against the proteids by repeated increased feedings of the substance.

Theories of Anaphylaxis. While anaphylaxis appears to differ markedly from immunity, still it has been quite generally accepted that the phenomena are closely related. This relationship is well illustrated by the following facts: a single injection of foreign proteid leads to hypersensibility toward that proteid; frequent repetitions of injections lead to immunization toward the proteid, and blood serum from an immunized and sensitized animal, when injected into another animal, makes the second animal hypersensitive to the proteid.

To explain and correlate the phenomena of anaphylaxis and immunity, various theories have been formulated, but at the present time there are only two that receive much consideration, the so-called cellular or histogenic theory and the humeral or parenteral digestion theory.

1. Cellular Theory for the Explanation of Anaphylaxis. According to Ehrlich's theory of immunity, an injection of a foreign proteid leads to an overproduction of receptors for this proteid. Usually these excessive receptors are cast off, become free antibodies and immunize. At other times, however, the excessive receptors remain or become fixed to the cell, concentrate the free proteid on the cell and so sensitize it. Weil believes that all immune animals are potentially anaphylactic, that antibodies are anchored to the cells, but, because of the large numbers of free antibodies, the proteid cannot reach the cell. When serum from an immune animal or a sensitized animal is injected into another, some of the receptors are anchored by the cells and the second animal is sensitized, unless enough antibody is introduced to protect.

Fig. 1.



Schematic representation to show the cellular theory for the explanation of anaphylaxis.

1A to 5T show the representation for the production of immunity, and 4B and 5B, what happens when instead of immunity there is anaphylaxis. It will be noted that in immunity the excessive receptors are cast off while in anaphylaxis they remain sessile.

2. Humeral, Cleavage Products or Parenteral Digestion Theory. According to this theory the body cells, surrounded by foreign proteid, elaborate specific ferments to digest and destroy the proteid. Now, an animal is hypersensitive to injections of the proteid because a former injection of the proteid called forth a proteolytic substance which, at the next injection, causes the proteid to break up into intermediary toxic substances. This theory, too, assumes immune and anaphylactic antibodies to be the same; in immunity enough ferment to break the proteid completely to non-toxic substances, while in anaphylaxis only enough ferment is present to produce toxic substances.

Fig. 2.

Ferment + Proteid + Compliment = Nontoxic = Immunity.
Ferment + Proteid + Compliment = Toxic = Anaphylaxis.

Humeral, cleavage products, or parenteral digestion theory to explain anaphylaxis.

It will be noted that in immunity the ferment is present in sufficient quantity and of enough potency to break the proteid up into non-toxic substance, while in anaphylaxis the ferment is only potent enough and in quantities only sufficient to break the proteid to toxic substances.

This conception has been largely developed by Vaughn and is based on the fact that split proteids in the state of peptones and proteosis are highly toxic and, on injection, produce symptoms not unlike those observed in anaphylaxis.

Either of these theories may be used to explain what happens in active hypersensitization to injections of serum, but in the explanation of passive hypersensitization, difficulties are met with. Adherents of the cellular theory explain passively transferred anaphylaxis by assuming that free receptors are transferred with the serum of immune and sensitized animals, and that these receptors are fixed by the cells of the passively sensitized animal. Those accepting the humeral theory believe that in the blood of immune and sensitized animals there is transferred the proteid-splitting ferment.

Gradually the cellular theory lost favor, in spite of the facts that the humeral or parenteral digestion theory offers no adequate explanation of the latent period (sometimes called "incubation period") of passive sensitization, and that protection of passively sensitized animals can be produced by injections of large amounts of immune serum.

The latent period of passive sensitization varies and indeed has been eliminated in some experiments. Gurd, who is an advocate of the parenteral digestion theory, concludes on this point as follows: "Such experiments indicate, in a striking manner, that the so-called incubation period is not an essential characteristic of transferred anaphylaxis. At the same time it must be admitted that the phenomena of transferred anaphylactic shock are manifested with greater regularity and are more severe if an interval be allowed to elapse between the two (serum from sensitized animal and antigen) injections."

In regard to protection of sensitized animals by introducing large amounts of immune serum, it may be said that Weil has shown conclusively that this is possible in both actively and passively sensitized animals.

It apparently is possible to so modify experiments that almost any of the hypotheses may be proven. Gradually, however, the cellular theory of anaphylaxis is again coming into favor. Weil, from extensive studies, accepts it. He, in a recent publication, states that in sensitization the body cells anchor the antibodies and that the cells activate the anchored antibody by increasing the avidity of the antibody for the antigen and induce a physiological cellular response when the intracellular antibody is brought into contact with the antigen.

It is not incumbent on us to make definite choice of theories as far as our subject is concerned. In all explanations of anaphylaxis only parenteral introductions of proteids have been considered and normal intrastomachical introductions have been disregarded. The reason for this is at least partly due to the failure to find suitable individuals and to control experiments properly. It is, of course, easiest, as far as intra-

stomachical introductions of proteid are concerned, to assume that if urticarias and erythemata are due to anaphylaxis, these phenomena occur because the individual is not able to transform completely compounds that are metabolized with ease under normal circumstances. It is far easier to assume the production of abnormal specific ferments when injections of proteids are made, than when proteids are introduced in the normal way. Again, it is not necessary to assume that anaphylaxis enters at all into manifestations that occur when degradation products of proteids are ingested or injected. We are not prepared to say that the manifestations in some of the cases were due to anaphylaxis, or even idiosyncrasy, for they may have been due to simple poisoning. Other cases, however, certainly manifest themselves in a manner similar to anaphylaxis, actively or passively experimentally induced. In these cases we are inclined to accept the cellular theory to offer the best explanation. That manifestations occur because of some faulty anatomical or physiological condition that allows the unaltered proteid to pass through mucous membranes and so produce a condition analogous to serum injections, is not necessary, and in fact is disproved by Case 1.

We hardly feel warranted in withdrawing blood from a human sensitized to food and injecting it into another, so that we are not able to say whether there is an incubation period in man passively sensitized to intrastomachical introduction of the proteids in the common foods. Animals are quite unsuited for ingestion tests, and it probably will be some time before reliable observations are available in man.

Without doubt, as is shown by our cases, sensitization is not always to the food itself, but rather to a decomposition product of the proteid food. We assume this, because in some cases the period elapsing after eating such food is longer than in most cases, because injections of the food proteid in some cases do not produce manifestations, while ingestion of them does, and because, on the elimination of the intestinal parasites, lesions no longer are produced.

Diagnosis. Several factors enter into the specific diagnosis of these cases. That a specific diagnosis is necessary to give specific treatment is not debatable. At this time it is not incumbent to give the diagnostic points in the skin manifestations, but we must determine the actual cause of them in so-called "idiosyncrasy" to proteid foods.

Various methods have been followed for testing or determining the particular food or foods to which the reaction in a patient is due.

1. Feeding. In order to make tests by feeding it is first essential that all foods likely to cause the reaction be eliminated from the diet, and that gradually one after the other be added. Based on our observations

as shown in Table 1, we are able, in some cases at least, to leave in the diets certain foods that sometimes cause toxic symptoms, and in all cases we were able to continue the feeding of properly diluted skimmed milk, buttermilk, beef and beef broth, as these foods apparently never produce reactions. To make feeding tests it is necessary to prescribe the diet from day to day, usually to give the added food a two days' trial before another food is added, and in all cases to keep a record of the foods, amounts, times of feeding, condition of intestinal tract and symptoms.

Feeding tests have three important objections: Sometimes the diet must be too limited to satisfy the individual,—this is especially true in the feeding of children; it sometimes seems almost cruel to repeat the marked reactions; and when the reactions are due to more than one food, to foods and other agents, or to food only during disease, then feeding tests might give entirely erroneous information.

2. Parenteral Introduction of Foods. These tests are similar to the ones used in anaphylaxis experiments, and are made by cutaneous and subcutaneous injections. The cutaneous tests have been used more frequently and are preferred to subcutaneous injections. To make them practical, the method of von Pirquet is followed. The various foods to be tested for are placed on the skin and introduced into it by scarification or boring. These tests must be accurately controlled, and in no case should they be made during the active stage of urticaria, for at this time any scarification will produce considerable reaction. Even when there are no active lesions it is necessary to make control scarifications. These are made in the same manner as in the regular tests, but without food substances. The following is a sample test to show the method and results obtained:

Patient	Egg Albumin	Egg Yolk	Oatmeal
Billie	++	+	++
Mrs. N.	++	+	++
	Discomfort	Discomfort	Discomfort
Miss H.	Negative	Negative	Negative
E. H. S.	++	+	Negative

Reactions usually come on within a short time and remain for several hours.

This method also has several objections. It frequently is necessary to wait several days before it can be tried. Again, manifestations may not be due to the food as such, but to its decomposition products and therefore the parenteral introduction of the food may give no reaction, and still the manifestations are caused by the food when taken into the stomach. Case 1 illustrates this definitely.

3. Determination of the Presence or Absence of Animal Parasites.—In four of our patients animal parasites, such as tape worms, ascaris and amœba were found. In these cases it was necessary to eliminate either the particular food or else the parasite, to avoid further symptoms. The only explanation of the influence of the parasites that is advanced by us is that the parasite transforms the proteid, so that it produces reactions. From the frequency of the association of toxic erythemata with animal parasites, it seems necessary in all cases of doubtful origin, to make a careful examination of the mouth and stools.

4. Foods that, during health, produce no reaction, may do so during constipation, specific fevers and so on. The manifestations are usually only temporary. In most cases it is not difficult to make a diagnosis of urticaria or toxic erythema, but it is absolutely necessary to make a diagnosis of the specific causal factors to obtain results. Abderhalden[1] has examined the blood of sensitized guinea pigs on reinjection of the serum and found substance giving the biuret reaction. It is easy to see that on the basis of the humeral theory of anaphylaxis, this might be of clinical value. Bronfenbrenner and his associates have found a decrease in antitrypsin in serum in these cases.

Treatment. As has already been stated, the urticarial and erythematous manifestations of proteid ingestion are not all due to the same ætiological factors, which may be summarized as follows:

1. Sensitization or true anaphylaxis to: (a) foods as such; (b) foods as changed by parasites; (c) foods changed during disease.
2. Consumption of partly decomposed or spoiled proteids.
3. Simple idiosyncrasy.

Before we can decide on rational specific methods of treatment, it is absolutely necessary that the cause in each case be determined. Obviously we must both treat and prevent the condition.

Prophylactic Measures. These will vary according to the causes. For manifestations due to partly decomposed or spoiled foods, these measures have been practiced for a long time. Prevention of sensitization, however, has been but little considered so far. In order to avoid sensitization, two factors are of importance. In the first place, we must know what foods sensitize, and in the second place, these foods must be so given as not to cause this condition. Egg, oat-meal, buckwheat, nuts, fish, tomato, cheese, pork, as well as other foods produce manifestations and therefore they should never be given until they can be taken regularly. It must be remembered that in the feeding of infants it not infrequently happens that because of some particular reason, egg and oat-meal are given for a few days and then discontinued. Later on,

when these foods or some of the other foods to which sensitization occurs are given, it is found that the child develops urticaria or erythema and remains sensitized to these foods for the remainder of life. Because of this we have not given, for the past three years, to infants and children, any of these foods until they have reached an age when the foods could be given over a long enough period of time to establish tolerance or immunity. We have substituted skimmed milk for egg albumin and rice and barley for oats, and have been rewarded by entire absence to these manifestations in all of our children. In adults such measures obviously are of little avail.

Actual Therapy. It is not necessary to enumerate the many remedial agents used in the treatment of these conditions. The development and disappearances of symptoms in any one attack are usually so sudden that the real value of any one drug is very hard to determine. The real test of the value of a method of treatment lies in the ability to prevent future attacks. These methods will vary according to the ætiological factor in a given case.

a. Sensitization to Foods as Such. It is easy enough for an adult to abstain from the use of some of the foods, but it is almost impossible to avoid eating egg in some form, and individuals sensitive to eggs are the especially unfortunate ones. It is thus obvious that we must find actual remedial methods. During the last few years, attempts have been made to immunize patients with idiosyncrasies to common foods by the gradual administration of the food to which allergy exists. Generally, we may say that repeated injections of serum immunize actively and that one injection of serum sensitizes actively, and while large injections of serum from an immune animal immunize passively, a small injection of the same serum sensitizes passively. Sensitization and immunization apparently are part of the same phenomena, so that if some of the urticarias and erythemata are due to anaphylaxis, then sensitization to foods is a manifestation of the immunization or failure of immunization of the individual to the food. Almost since the recognition of the phenomenon of serum anaphylaxis, immunization of sensitized animals has been found possible and so, with the so-called allergy to common foods, active immunization to these foods has been undertaken.

Schloss[2] began immunization of an eight year old child, sensitive to eggs, oat-meal and almonds, by feeding first small amounts of ovomucoid. Later, feeding of egg produced no symptoms, and finally the patient was able to take egg and oat-meal without symptoms and was less sensitive to almonds. As has already been shown in our table, sensitization to food is not entirely specific, or at least that the same individual may be

sensitive to several of the foods. Reaction to a number of foods probably occurs more frequently in early life and in our series never occurred in adult life. To immunize actively, we used first small and then increasing doses of the particular food producing urticaria or erythema.

It was noted that in the cases where several foods produced symptoms, immunization to one immunized to the others also. Immunization of children is much easier than of adults on account of control; likewise it is easier to immunize against some foods than to others. This is partly because of the marked sensibility to some as to certain types of fish, especially shell fish. It would seem that if immunization to one proteid were possible by feeding a proteid to which the patient is less susceptible, that some of the adults should become immune. Such immunization probably occurs but these cases do not come under observation.

Barium chloride and hypertonic salt solution, supposedly because of contraction of the muscles of the vessel walls, are said to lessen anaphylactic shock, and accordingly injections of salt solution have been made in its treatment. We have tried the administration of these salts, without avail. In one case, at least, apparently the reaction was increased This is quite in accord with the view of Heilner[3] that salt produces symptoms of anaphylactic shock in serum treated animals.

Anti-anaphylaxis is the state existing in an animal that has survived anaphylactic shock. In regard to this, Heilner believes that serum in parenteral reinjections in the pre-anaphylactic period, that is, right after the sensitization injection, is utilized to better advantage than at the first injection. Anti-anaphylaxis is produced wholly by large injections, or partially by repeated small injections. In the hope that the anti-anaphylactic state might also exist in man, right after ingestion of large amounts of proteid substances which produced marked symptoms, we fed these proteid substances early after reaction had occcurred. Our experiment was almost disastrous for the patient developed such severe œdema of the glottis that intubation was necessary, and the patient refused further treatment in our hands. That this disproves that there is an anti-anaphylaxis to intrastomachically introduced proteids is not certain, for it must always be borne in mind that it is impossible to obtain in these tests, the quantitative nicety of experimental serum injection. We have had no opportunity to try the injection of antitrypsin as proposed by Bronfenbrenner.

b. Foods as Changed by Parasites. Drugs which belong to the class of parasiticides have been found to be of value in the treatment of

some cases of urticaria. The various text books have for some time referred to the presence of animal parasites as being an ætiological factor in urticaria. In a number of our cases we found parasites belonging to the amœba, ascaris and tænia. These alone did not cause the manifestations, for always ingestion of some proteid food was at least a part of the ætiological factor. That the food alone was not responsible for the urticaria was demonstrated (see Cases 1 and 8) by the fact that when the parasites were destroyed or removed by the usual methods (administration of ipecac, thymol, santonin), ingestion of the food no longer produced symptoms.

c. Foods as Changed During Disease. In these cases symptoms disappeared with the cure of the disease, so that apparently the absence of manifestations depends entirely on the treatment of the underlying disease.

2. Consumption of Partly Decomposed and Spoiled Foods. In these cases one often sees severe general symptoms. Treatment apparently depends on elimination, intestinal antiseptics and symptomatic measures.

3. Simple Idiosyncrasies. These cases are the most obstinate and confusing. Food apparently plays some part, but it is difficult to determine which food is at fault. Certainly some factors other than food cause the manifestations, as immunization is not possible and therefore treatment is only experimental. What part the connate conditions (idiosyncrasies, diatheses, temperament) and internal secretions may play, is not determined.

Case Reports.

Case 1. Male, age 42 years. The early history of this case was negative. Two years ago he moved to Manila and for a year and a half enjoyed good health. Then he suddenly developed urticaria. All internal and local treatment produced only temporary relief. He found that eggs were the source of his trouble and avoided eating them when possible. Any food substance containing the smallest quantity of egg produced, in the course of four to six hours, giant urticaria. He returned to the States and came under our observation. All tests proved positive excepting the local injections of egg white, and they were negative. The ova of the ascaris lumbricoides were found in the stools. The parasites were killed with large doses of thymol. Since then he has been able to partake of any quantity of egg without producing symptoms.

Case 2. Male, age 39 years. This patient states that he had urticaria ever since he can remember. His mother and also one sister have the same condition. He has never been able to take any quantity of egg without a reaction. He traveled for several years with a circus and was known as the "human writing pad." About three hours before it was time for his performance, he would take two teaspoonfuls of egg white and would then permit spectators to produce linear wheals with a blunt stick. These lesions would last from

six to eight hours. He was obliged to stop this, on account of an increase in the severity of symptoms. At present he is absolutely free from symptoms providing he does not eat egg. The reaction from the local injection of egg white is positive.

Case 3. Female, age 32. This patient has had attacks of urticaria, from five to eight times a year for the past six years. No especial variety of food seems to be an etiological factor but as soon as she becomes constipated, these attacks appear. For the past year she has been under our observation and with the regulation of her intestinal tract, she has had but one attack.

Case 4. Male, age 42 years. Until two years ago, the man does not remember of ever having more than two attacks of what he called "hives," and those when very young. When in the East two years ago, he ate soft shelled crabs, which he thought at the time were somewhat tainted. He developed an extensive rash within four hours which lasted for several days. Previous to this he had been able to eat all varieties of fish without producing reaction. Since then, on five different occasions, he has developed a toxic erythema from eating crab meat which he considered to be perfectly fresh.

Case 5. Male, age 70 years. This patient has had urticaria and toxic erythema six or eight times a year, for the past twenty years. He does not remember what produced these conditions and we have been unable to find any ætiological factor.

Case 6. Child, aged 14 months. Breast-fed to date, but since ten months old has had supplemental feedings. When ten days old, had frequency of stools, so was given egg albumin and barley water for three days. For two months has had asthmatic attacks and "hives". By feeding and skin tests, urticaria was found to be caused by egg, the idiosyncrasy being so marked that even placing the inner side of the egg shell to the lips caused them to swell. This child was immunized to egg albumin after thirteen months.

Case 7. Female, age 31 years. This patient developed a severe urticaria six months ago, after eating canned lobster. Since then she has been sensitized to egg albumin and each attack is more severe than the previous one. During her last attack there were marked respiratory symptoms, difficult breathing and an œdema of the glottis, so extensive that we were obliged to intubate.

Case 8. Male, age 60. This patient, after spending a year in Florida developed urticaria which lasted from 14 to 16 months. The attacks came on during the evening between seven and ten o'clock, lasted a few hours, and during the day the patient was free from symptoms. There was a loss of 50 pounds. Without apparent cause the urticaria disappeared. One year later he developed amœbic dysentery. The urticaria again appeared, lasting three months. One year later he developed an abscess of the liver. Injections of emetine were given and since then (two years) there have been no signs of the dysentery or urticaria.

Case 9. Boy, 22 months old, apparently in good health. The mother was 37 years old, had five pregnancies. In each pregnancy the mother had marked albuminuria; the first terminated in miscarriage, the second in abortion, the third the patient was born, the fourth was terminated at six and a half months and in the last, the mother died in the eighth month of pregnancy. The child was breast-fed entirely for three months, then cow's milk and later Mellin's food were added. At ten months an attempt was made to stop breast feedings and when solid food was given the child developed urticaria. Since then he

has respiratory distress, vomiting, wheals, most marked around the mouth and on the wrists, especially after eating eggs, but also after eating oat-meal and graham bread. The mother had similar idiosyncrasies. By feeding, all idiosyncrasies were overcome.

Conclusions.

1. Certain of the proteid foods, on ingestion by certain individuals, produce urticaria and erythemata and other symptoms.

2. Each of the foods produces fairly constant skin lesions.

(a) Urticaria occurs more frequently than erythemata; fish, tomatoes and cheese only producing urticaria, while cereals and pork produce erythemata in a considerable proportion of the cases.

(b) Tomatoes and cereals usually produce these lesions within an hour after ingestion.

(c) The eruptions usually persist less than twenty-four hours.

(d) The peculiar reactions on ingestion of eggs, cereals and pork are inherited in a considerable percentage of the cases.

(e) The skin manifestations in more than one-half of our cases of sensibility to egg ingestion were accompanied by cough and dyspnœa.

3. Most, but apparently not all, urticarias and erythemata following ingestion of these proteids are due to phenomena similar to those observed in anaphylaxis. The ætiological factors we have summarized as follows:

A. Sensitization or true anaphylaxis to (1) foods as such, (2) foods as changed by parasites, (3) foods as changed during disease.

B. Consumption of partially decomposed or spoiled foods.

C. Simple idiosyncrasy.

4. Diagnosis should be specific. To determine the particular food causing the manifestations, feeding and injection tests are of greatest importance. Parasites and other causes of disease must be looked for. Probably the Abderhalden tests and antitrypsin determinations may prove of value.

5. Treatment should be specific. After getting rid of parasites and disease, if there still is hypersensibility, then immunization by feeding is usually, but not always, possible.

References.

[1] Abderhalden. *Zeitschr. f. Physiol.*, 1912, lxxxii, p. 109.
[2] Schloss. *Am. Jour. Dis. Chil.*, 1912, iii, p. 341.
[3] Heilner. *Zeitschr. f. Brol.*, 1907, l, p. 26, and 1912, lviii, p. 332.

DISCUSSION.

Dr. Engman asked Dr. McBride how they arrived at the conclusion how certain food was causing these disturbances,—by the von Pirquet method, or how?

Dr. McBride replied, by elimination, not entirely by feeding.

Dr. Engman stated that this was of course a most interesting and important subject to all, and that it opened up a positive field for some definite therapy; yet in their work they had been greatly disappointed on the therapeutic side of the subject, in fact not reaching any conclusions at all from sensitization tests. Possibly their technique had not been just right, but even in the Children's Hospital in St. Louis, where one would expect the sensitization test to be valuable, they had been disappointed. Outside of egg albumin, he did not recall a case where the test was positive. In their work, with adults, especially with urticaria, they had been greatly disappointed. In investigating certain types of eczema, many tests had been made, and in many tests with private cases they had been disappointed in the study of urticaria. When they found a positive test and followed it up, they got no results. In two cases where there was a positive test to some milk product, they had no results by cutting out milk and foods of that class. In one case of chronic urticaria they found the transverse colon in the pelvis—a congenital condition. In the other case, for instance, there was an enlarged stomach and gastritis, but the therapeutic results did not answer to the sensitization tests. The study of egg albumin by Schloss was a classical work, showing that many kinds of ova-mucoid ran through certain classical foods; he found that it obtained nuts, eggs, and other food stuffs. Outside of the egg cases, their own results had been absolutely nil.

Dr. Towle said that he considered the question which Dr. Engman had raised as very important in connection with the two papers just presented. The whole subject of anaphylaxis was of great interest but was very complicated and ill-understood. He questioned whether the phenomenon was not indicative of a group rather than a specific reaction to some one food. We knew that eggs may provoke a tremendous reaction upon the slightest contact and in infinitesimal amounts. Yet he had never seen an infant who reacted to meat preparations in like manner and degree. He had also seen a reaction similar in kind, although much less in degree, in which sugar was seemingly the offending component of the food. We were all familiar with children who were intolerant of milk and who manifested that intolerance in the skin. Dr. Talbot and the speaker working together, once showed that, seemingly, there existed a certain relationship between the types of cutaneous symptoms and the types of digestive disturbances. Every one was familiar also, with the various degrees of cutaneous reactions which sometimes followed ingestion of drugs. Dr. Towle had recently seen a very marked case of drug susceptibility, in this instance, aspirin. There was a primary sensitization, a prolonged interval of incubation, a reactive dose of the substance aspirin, followed by the prompt appearance of cutaneous symptoms, consisting of tremendous œdema and the formation of vesicles and blebs and marked evidence of systemic effects. In another patient, clams produced a very pronounced condition of intolerance. The first meal had no result but the second was followed, within a few hours, by alarming systemic symptoms and enormous oedema of the skin. The condition of sensitization has persisted so that at the time of writing, after several years, the patient was unable to eat clams. Infants and very young children, to be sure, were not often furnished aspirin or clams. Nevertheless, the conclusion could not be avoided that while proteid substances were presumably the most frequent cause of anaphylaxis, not only may the reaction result from a variety of proteid-containing substances, but also from a number of utterly dissimilar chemicals. In all, however, the mechanism excited was always the same, with the result that however the symptoms may differ in degree, they were the product of a single mechanism, the vaso-motor system. Speaking broadly, then, the anaphylactic reaction was not specific.

To take up the cutaneous reactions in infants with disturbed digestive metabolic processes; it was not possible to prove that every infant having similar disturbance of metabolism had a cutaneous reaction. It even happened, in the experience of Dr. Talbot and himself that, like signs of digestive trouble were associated with divergent affections of the skin and *vice versa*, that similar cutaneous manifestations were associated with dissimilar digestive signs. Was not the conclusion obvious that not every case was anaphylactic and that even if anaphylactic the true diagnosis lay concealed in some deeper condition? Was it not enough, therefore, to merely cut out the food substance accused by the cutaneous vaccination test? Relief may follow, but not cure. If these cases of cutaneous excitability were studied, it would be found that the evidence pointed to the existence of some previously existing constitutional condition, which, presumably, had laid the foundation of the subsequent events. For example, German writers maintained that the systemic condition known as the exudative diathesis may be transmitted from the parents to the offspring. Constipation was the most constant accompaniment of the exudative cases reported by Dr. Talbot and himself. Fatigue notoriously rendered the subject susceptible to harmful influences. Indeed, Sontagh, arguing that scarlet fever was not a disease *sui generis*, but merely a cutaneous and systemic manifestion of absorbed streptococcus toxines from an angina, used fatigue as the great example of the lowering of resistance which rendered the toxic effects possible. Delayed digestive processes were also accused of a like impression upon the nervous system. It was to be remarked that, although all of these influences may occasion symptoms referable to the nervous system, it was not usually claimed that, of themselves, they produced the cutaneous disturbances which we associated with acute eczema. It would seem that still other contributing factors were needed to excite the swelling and the exudate. We find a hint as to the probable nature of this contributing factor in the predilection of these acute eruptions for the exposed parts, notably the face. The suggestion lies close at hand that the exciting cause was some form of trauma. The questions come naturally: Were we dealing with true anaphylaxis in the conditions described? May we not have to do with cases in which the food substance had merely laid the foundation upon which another factor may act to produce the eruption? Could we differentiate the events growing out of an intoxication from true anaphylactic phenomena? It was of interest to note that German pediatrists did not direct their treatment against a single food substance, but toward a whole food group, which they claimed so acted upon the organism of certain individuals as to render the reactive phenomena possible. In justification, they pointed to the results of extended serum experiments. Many believed that the most common contributing cause was a systemic state called acidosis, whose creation was especially favored by the ingestion of acid-containing food stuffs. They, therefore, treated not the immediately exciting, single cause but the group cause which underlay and had made the reaction possible. The logic of this therapeutic method appealed to the speaker, notwithstanding the reproach, often advanced in this country, that it was behind the times. To him, hypothesis of a specific, single cause did not seem broad enough to explain the exceptions.

Dr. Schamberg said that he had listened with pleasure and profit to the instructive papers of Dr. McBride and Dr. White; he felt that dermatologists were frequently humiliated by the lack of intimate knowledge of the causes of certain dermatoses which they encountered, notably eczemas, under which broad term were grouped many distinct and different conditions. Particularly were we at sea in regard to infantile eczema. At present he was engaged with others in carrying out systematic chemical analyses of maternal milk in connection with this condition and hoped to present, later, some definite findings. Some

years ago he had an opportunity to study large numbers of serum eruptions following the administration of diphtheria antitoxine. From the observation of these cases he felt that they could be classified into several groups. The great majority were urticarial, then followed macular erythemas, then purpuric eruptions and finally, and rarely, vesicular eruptions. They were accompanied by fever, joint pains and occasionally joint swellings. This was a complex with which dermatologists were familiar. Had the cause of this eruption not been known we would have recorded the condition as toxic erythema of unknown origin. We knew, however, that an alien sterile blood or serum will produce such a condition and that a definite period of latency after the introduction of the serum was necessary before the eruptive manifestation appeared. With a serum made by the Philadelphia Board of Health, they had observed a period of incubation of seven or eight days and the eruptions were chiefly urticarial: with an antitoxine made by the New York Board of Health, the period of incubation was about three days and the eruptions were chiefly scarlatinoid. Serum from certain horses would produce a large percentage of eruptions, whereas, that of other horses would produce relatively few. This whole subject was one of the greatest importance. In the interpretation of skin tests, it seemed difficult to estimate their real value because of border-line reactions. It was gratifying to learn that dermatologists were actively interested in the investigation of the influence of food stuffs in the production of various diseases of the skin. The continuance of this work will surely lead to an enlargement of our knowledge.

Dr. Heimann said that the questions raised by the two papers were of the greatest importance to the proper understanding of many of these vague cutaneous manifestations in the eczema and urticaria groups, and that too much stress could not be laid upon the importance of clearing up the subject. It was the province of bio-chemistry to determine whether they were caused by anaphylaxis in the true sense, or whether they were due to toxine in the old sense,—as in the pathological response to iodides or to other poisons.

He then asked for further elucidation on the following points: (1). Whether in the subjects sensitized to eggs the same phenomenon was caused by young chickens, as in egg albumin urticaria? (2). As to fish and pork: whether fresh or salted? (3). Tomatoes: whether the whole tomato or only the pulp? (4). The type of cheese used, whether cream cheese or "high" cheese ? (5). The question of the relationship of this sensitization to egg albumin in parasitic infections: what bearing the intestinal ova had to the ordinary eggs, or whether it might be due to the parasites themselves.

Finally, he directed attention to some work done by Eustis, of New Orleans, commented on editorially by the *Journal of the A. M. A.*. The substance was supposed to be the end product of proteid putrefaction and was supposed to be found in persons subject to urticaria. This test had been tried at Cornell also, and found to bear no relationship to patients with urticaria, nor to the presence or absence of indicanuria.

Dr. Hazen said we should be careful not to say that all of these cases were due to anaphylaxis. He had been much interested in the subject of chronic urticaria, and he told of fifty cases of urticaria, one third of which gave positive Wassermann reactions and recovered under salvarsan or mercury; hence it must not be assumed that all cases were due to anaphylaxis. In the second place, skin reactions were not always given in urticaria. One patient had a very severe urticaria, apparently due to oysters. An injection of oyster vaccine gave a definite attack, but no great reaction. In the third place, in intradermal injections, it was possible that some of the anaphylactic phenomena might not come from the proteid, but from bacteria. That should be ruled out.

Dr. C. J. White said that the brunt of the practical work had come upon

his three recent house officers. As to the controls, there were made on the skin two parallel lines of excoriations and into those which were called the controls, nothing was injected. Some of these controls became positive.

When Dr. Towle brought up this subject two years ago at a meeting of the American Medical Association, very little attention was paid to it. This theory held out hope for the future, and it seemed very desirable that more of us should make investigations of this nature and see what can be learned from this point of view. Such a study would be an appropriate subject for the general discussion next year.

Dr. McBride said that it was easy to eliminate many of these substances, but it was almost impossible for any one sentized to egg to keep from eating egg.

Replying to Dr. Engman, he said that it had been tried only in the egg cases according to the method of Schloss, using ovo-mucoid in very small doses.

Answering Dr. Heimann, Dr. McBride said that he was unable to make any statements about the chicken; the fish was fresh and the pork was fresh. He himself was sensitized to pork, and the smallest amount would produce a reaction in an hour. Whole tomatoes were used; Swiss cheese and cream cheese produced the same reaction. Just what took place in the presence of parasites, he could not say, but there was produced a foreign proteid and the parasite was the particular factor which changed it; the absorption produced the reaction. Later, he hoped to report the findings on seven cases then under study.

Dr. C. J. White asked, whether in giving the 1 : 1000 egg-white, it was given by the mouth or subcutaneously.

Dr. McBride answered that it was given by both methods.

IMMUNITY FROM SCABIES.

By Douglass W. Montgomery, M.D., San Francisco.

Scabies is so contagious between bedfellows that I do not remember of every hearing the question of complete immunity discussed. Everyone is supposed to be susceptible. This susceptibility is so marked that it is commonly employed as a means of diagnosis. If, for instance, two people occupy the same bed, and one of them has an itchy affection that the other does not acquire, the affection is justly supposed not to be scabies, as it must be very rare indeed for conveyance not to take place, and herein lies the interest in the following case.

A man, thirty-five years of age, called on Feb. 18, 1915, complaining of a very itchy eruption that had been plaguing him since the middle of the previous December, when it appeared on the shaft of the penis as an itchy "pimple." From there the eruption had quickly spread to its present locations. The rash was discrete, papular and excoriated, and was present on the anterior fold of the axillæ, on the forearms and over the elbow tips, over the lower part of the abdomen, and slightly on the penis and on the thighs, especially in the gluteal folds. There were

indications of an eruption having been present on the anterior surface of the wrists. The presence of the eruption in the above mentioned situations, together with the complaint of severe itchiness, especially at night, constituted enough data on which to make a diagnosis.

A search was made for runs, and a long calloused one, ending in a characteristic pustule, was found on the ball of the left thumb. A flat slice was shaved from this lesion and mounted in glycerine for microscopical examination, and a beautiful group of acarus eggs with fæcal droppings was discovered. Nothing like this can be found in any other disease; the run containing the female acarus and her eggs and droppings constitute an absolutely pathognomonic symptom. In any doubtful case the above procedure of demonstration is of the greatest value.

Now came the surprising part of the man's story. He said that he had first noticed the infection while working in a lumber camp, and blamed a comforter which he had borrowed, for conveying the infection, as it was shortly afterwards that he noticed the lesion on his penis. This primary manifestation of infection was noticed on Dec. 19, 1914. He returned home the following day, and at no time, he said, had his wife shown the slightest trouble, although they occupied the same bed.

As this would be, as above indicated, a highly interesting circumstance, I requested the patient to have his wife call at the office. She confirmed her husband's statements. She was a woman in her twenties, with a little acne over the chest, and complained of an annoying leucorrhœa, but was otherwise in good health. Her nipples were those of a woman who had never borne children, but neither in this situation, which is almost invariably affected in the female having scabies, nor anywhere else, was there the faintest indication of the presence of the acarus scabiei. She had not employed any means to shield herself from infection, and her husband had received only internal treatment, as the medical man, whom he had consulted before coming to me, had insisted the eruption was due to intestinal intoxication arising from habitual constipation.

The Aquisition of Scabies. As before indicated, scabies is almost always caught in bed, and usually from a bedfellow. Probably, however, it may be acquired by lying in a bed recently occupied by a person having scabies, especially if the sheets have not been changed. As the hands are frequently involved, it is also reasonable to suppose that wearing the gloves of an affected person may transmit the disease, and one case in my experience would seem to substantiate that mode of transmission. No danger of acquiring the disease is run in any ordinary

intercourse between persons, such as shaking hands or in examining patients. After exposure, symptoms appear in from two days to a month, usually in about ten days.

The Accord Between Immunity and the Natural History of the Disease. While complete immunity in scabies must be very rare, yet it would be perfectly in accord with what is known of the natural history of the disease. A regional immunity and susceptibility is always present, and constitutes one of the most valued characteristics of the affection as far as diagnosis is concerned. The itch mite and its eruption particularly favors the skin between the fingers, the flexor surfaces of the wrists, the skin over the elbow tips, the anterior fold of the axillæ, the lower part of the abdomen, the gluteal folds, in the female the nipples and in the male the penis, while the face, scalp, neck and the region between the scapulæ is almost never attacked. This regional selectivity is such a marked feature as to constitute, as above mentioned, a valuable point in diagnosis.

Furthermore, patients exhibit very varying degrees of irritability to the itch mite. Some will show almost no symptoms excepting a few burrows, and these may be very difficult to find. These ambiguous cases are not rare, in which the symptoms are reduced to nocturnal pruritus with traces of scratching in some of the previously mentioned points of election. It is therefore only a step between these and complete immunity.

Spontaneous recovery is spoken of as an extremely rare occurrence. I have never seen it. During fevers, however, the symptoms disappear, to reappear when the fever subsides.

The Important Place Occupied by Scabies in the Old Doctrine of the Dyscrasias and its Overthrow. Long after the discovery of the itch mite, scabies was supposed to be dependent upon a dyscrasia. The most powerful influences in breaking down these old speculative theories of medicine were the two remarkable men, Rokitansky (1804-1878), and his life-long friend, Skoda (1805-1881), who introduced the natural history method into disease. At Skoda's urgence his pupil, Hebra, took up diseases of the skin, and occupied himself, as did his master, in explaining symptoms by pathological findings. He turned his attention to the elucidation of scabies on a natural history basis, and clearly showed that all of the symptoms could be produced by the itch mite. His demonstrations in this humble disease constituted one of the severest and most deserved checks the purely speculative theorists received.

The interest in the present case, however, lies in the fact that some constitutional peculiarity lies at the bottom of the immunity enjoyed.

Rokitansky, the destroyer of the dyscrasic doctrines, himself never entirely abandoned them, and always tried to weave into them the facts he found in the dead house. He knew they represented something that is not found in the dead tissues, but is present in the living body: conditions which are coming to light in the modern investigations on immunity. In scabies we do not know in what this immunity consists, but it is worth something to know that it is an actuality. It is also a personal comfort to feel that the great founder of modern pathology, besides being an indefatigable searcher out and demonstrator of the substantial changes wrought by disease on the tissues, also endeavored to link these changes with the processes of life, which many of his followers in their enthusiasm for new facts, forgot to do.

The Importance of a Demonstration of the Burrow and its Contents. A word in conclusion in regard to the burrow and its contents, which constitute the pathognomonic symptoms of scabies. This is a much more important subject than it at first seems, as it constitutes a point for absolute diagnosis, in indefinite cases in which the symptoms are often reduced to nocturnal pruritus with traces of scratching in some points of election. In these, the fact of contagion between bedfellows, and the demonstration of the burrow with its contents is of the greatest importance. The burrow is a white roughened line, as if made by the scratch of a pin. The older ones may be blackened by the entrance of dirt. They are not straight; they are either sinuous or bent at an angle. At one end there is either a clear translucent or a yellowish dot that indicates the situation of the itch mite lying in the distal or blind extremity of the tunnel. If a needle is run into the tunnel, back of the itch mite, so as to shove her along and through the blind end in the direction in which she burrows, she may be extracted on the needle point. If the needle is introduced in the inverse direction, the mite cannot be extracted as the spines with which she is provided prevent her being dragged backwards. In fact these spines hold her normally a prisoner in her own drift by preventing her crawling backwards.

Although the itch mite, when held on the point of a needle, may be seen by the naked eye, as a minute white creature, very few people have such acute vision as to definitely make the diagnosis without the aid of a glass. An ordinary hand lens of about six diameters, that every physician should carry, is, however, sufficiently strong for the purpose.

Trying to find an acarus with a needle is a tedious business, and it is far better, on finding a burrow, or what looks like one, to make a horizontal slice or shaving of the skin reaching down into the quick, and to transfer it to a slide, add a drop of glycerine, place over it a cover glass and examine with a low power lens. This will include either a part or the whole of the tunnel, and if the eggs and fæces, with or without the itch mite herself, are found, the diagnosis is absolute.

Explanation of the Drawing. This drawing is from a slice made by shaving off the top layer of the skin, as before indicated, and includes quite a length of the cuniculus with the acarus at the blind extremity. The suckers at the anterior extremity of the insect seem to be retracted backwards; this may of course be part of a general retraction and contraction occurring at death. There is quite a good deal of dark matter, probably fæcal, in the abdomen, and there is an egg just being extruded from the posterior extremity of the mite. Curiously enough, this egg is not being extruded absolutely centrally and directly backwards, but slightly laterally, and in the same general direction that the others lie in the burrow. This direction of protrusion is probably why the eggs always lie, as figured by all observers, with their long axis across the burrow and not trailing along it. As also indicated in the drawing the eggs, and to a great extent also the fæces, lie grouped. In the illustrations generally given in books the burrow is shown filled with eggs. This assumption is incorrect.

As regards the size of these objects: in a microscopical sense all of them are quite large. As above mentioned the mite herself may be seen with the naked eye, and the first demonstrations by Ranucci, the Corsican student, in Alibert's clinic in Paris (1834) were so made. An egg is about one-tenth the size of the female parent; and each fæcal lump is about one-twentieth the size of an egg.

The eggs are large oval bodies, contained in a very thin membrane that is refractive, and in places may be seen to have a double contour. The contents are brown, homogeneous, and finely granular. The fæces, which lie scattered around and among the eggs, are small, compact, oval, very dark brown or almost black bodies of homogeneous structure.

A CASE OF EARLY MYCOSIS FUNGOIDES CLINICALLY INDISTINGUISHABLE FROM PARAPSORIASIS OF BROCQ.*

By Fred Wise, M.D., and Isadore Rosen, M.D., New York.

Attending Dermatologists, Vanderbilt Clinic, Medical Department of Columbia University.

Introduction.

Differential diagnosis as applied to diseases of the skin is admittedly a dry and tedious subject at its best. To the uninitiated, the finely drawn lines and minute details which characterize certain dermatological differentiations must seem to appear, in a large measure, a useless expenditure of time and energy. Indeed, such a view is often justified, for those who are sufficiently interested in the subject will often spend time which may well be used to better advantage, in discussing and debating clinical minutiæ, which, after all is said and done, have little or no practical or theoretical value, either from the physician's or the patient's point of view. Whether a patient presents an eruption labelled "psoriasiform seborrhœic eczema" or "eczematoid psoriasis" is a relatively negligible question from the practical side.

On the other hand, the practitioner frequently encounters eruptions of the skin, the exact interpretation of which is often of the utmost importance to the patient, to himself and sometimes to the community at large. A scarlet fever rash must be properly and unqualifiedly differentiated from the ordinary toxic erythema which it may closely simulate. A scaly and circinate syphiloderm must not be confounded with the harmless and self limited exanthem of pityriasis rosea. Eruptions due to the ingestion of drugs such as potassium bromide and arsenic require absolute diagnostic precision on the part of the consultant. In fact, any number of pertinent examples may be cited to illustrate the importance of exactness in the clinical interpretation of the different cutaneous eruptions seen in every day practice.

In a general way, then, it may be said that there are two broad aspects to the subject of dermatological differential diagnosis: one, the theoretical side, is of especial interest to the dermatologist, mainly from the academic and scientific standpoint; the other, the practical side, affects the patient himself insofar as it influences the prognosis, course, treatment, etc., of his malady and his general health.

* Read before the Clinical Society of the Department of Dermatology, Vanderbilt Clinic, Nov. 18, 1915.

The patient forming the subject of this report exhibited an eruption of the skin which not only serves to illustrate the points mentioned, but it also presents a striking example of the remarkable resemblance in clinical appearances, which may obtain in certain dermatoses otherwise entirely divergent in character, and totally dissimilar with respect to their ætiology, course, prognosis, treatment, etc.

Resemblance of Early Mycosis Fungoides to Other, Non-related Dermatoses.

The tendency which is frequently exhibited by early or premycosic granuloma fungoides to simulate various other and non-related dermatoses, has been dwelt upon and emphasized by numerous observers. Most commonly, these early manifestations of mycosis fungoides resemble ordinary eczema, or seborrhœic eczema, or psoriasis. Less frequently, they may simulate chronic urticaria or a persistent type of erythema multiforme, and other, more or less banal, dermatoses.

Now and then a case is encountered in which the question of differentiation rests solely between two diseases: namely, *early mycosis fungoides* and *parapsoriasis in patches.* Usually, careful study of the individual lesions and of the eruption as a whole, will reveal the nature of the disease without having recourse to the microscope; or the diagnosis will be established with the aid of the patient's history, the character of the subjective symptoms, the progressive or regressive changes observed in some of the efflorescences, etc., etc. Where microscopic examination of tissue is feasible, the question of differentiating the two maladies usually resolves itself into a simple matter.

Early Mycosis Fungoides and Érythrodermie pityriasique en Plaques Disséminées (Brocq).

In one of his papers on parapsoriasis in patches, Brocq stated: " I wish to emphasize the objective relations which exist between certain forms of mycosis fungoides at the commencement, and parapsoriasis in patches. I cannot repeat too often, that *in every case presenting an infiltration analogous in appearance to parapsoriasis in patches, and especially in every case in which there is the accompaniment of intense and persistent itching, a beginning mycosis fungoides must be suspected.* Under such circumstances it is advisable not to make a positive diagnosis until a histological examination has been made."

Speaking of differential diagnosis with reference to a case of érythrodermie pityriasique en plaques disséminées, reported by James C. White, that author remarked: "I am aware that the erythematous stage of mycosis fungoides has been observed to precede by more than twelve years the development of its other features, and that this condition is sometimes almost the exclusive man-

ifestation up to the fatal termination of the case. Yet in the cases [of mycosis fungoides] I have observed, the lesions of this stage are never of such uniform size and distribution, or remain so small as those of our patient. The hyperæmia is much more decided and the infiltration more marked. There is, however, never the regularity in the occurrence of the cutaneous manifestations as in this case [of parapsoriasis in patches]."

Charles J. White, in his paper dealing with the same subject, said: " . . . The second disease which presents somewhat similar features is mycosis fungoides in its initial stages, the so-called pre-mycosic dermatitis. Here again one feature practically always present in one disease is universally absent in the other; I mean pruritus, which forms so distressing and persistent a factor in mycosis fungoides, and which is so totally wanting in érythrodermic pityriasique."

According to Ormsby, "The close resemblance of the lesions in the early stages [of mycosis fungoides] to those of other diseases was emphasized in the case of a patient studied by the author, which was regarded for many years by well-qualified men as parapsoriasis. Later, infiltrated plaques and tumors developed and the patient succumbed. Similar cases are recorded by Jamieson, Hudelo and Gaston, Sherwell, and Unna."

In his monograph on Brocq's disease, Arndt devotes considerable space to a comparison between érythrodermic pityriasique en plaques disséminées and the pre-fungoid stages of mycosis fungoides. Arndt says, in part:

"There are instances of érythrodermie pityriasique en plaques disséminées in which the lesions develop relatively rapidly and show a slight amount of palpable infiltration of some of the patches, the eruption being accompanied by a mild degree of itching. In such cases, the question of differentiation from mycosis fungoides must be considered. *Changes undoubtedly take place in the early stages of mycosis fungoides which can scarcely be differentiated from some of those occurring in Brocq's disease.* Usually, even in these somewhat confusing types of mycosis fungoides, we find that the edges of the individual plaques are rather sharply defined, their contour is more prominent as a result of a more pronounced infiltration than is seen in Brocq's disease, the lesions show a tendency toward involution in their centres, and there may be ring-shaped, crescentic and festoon-like efflorescences, forming a part of the eruption. Such manifestations as these occur only in a very meagre degree in Brocq's disease, or they may be entirely absent. In most instances the clinical picture in early mycosis fungoides is a much more variegated one than in Brocq's disease. In the former malady there occur more or less circumscribed, yellowish and yellowish-red patches, often showing evidences of involution in their central portions and simulating an eczema seborrhœicum or resembling parapsoriasis in patches. Sooner or later, urticarial, lichenoid and psoriasiform changes supervene, accompanied by patches simulating the nummular type of eczema, with its moderate infiltration, weeping surface or crust formations. In érythrodermie pityriasique en plaques disséminées, on the other hand, the picture is that of a uniformly smooth or faintly desquamating eruption. While the course of mycosis fungoides is characterized by the comparatively rapid appearance and involution of the lesions, the peculiarity of Brocq's disease lies in the extreme chronicity and persistence of the patches, as has frequently been demonstrated in numerous cases of the latter dermatosis.

"One of the most prominent differential diagnostic points is the almost invariable presence of pruritus in mycosis fungoides. The itching is frequently unbearable, depriving the patient of sleep. In the later stage of mycosis

fungoides, when flat infiltrations and tumor formations make their appearance, the pruritus may partly or wholly vanish. Nevertheless, the symptom of pruritus is one of great significance. In érythrodermie pityriasique en plaques disséminées, puritus is either entirely lacking, or is present only in mild degree.

"In all cases presenting difficulties in clinical diagnosis, it is, of course, essential to make careful histological investigations. In judging the microscopic picture, we place less weight on the amount and the density of the infiltrate present in the upper portion of the cutis in both maladies, than we do upon its constituent parts. In some cases of érythrodermie pityriasique en plaques disséminées there is a quite dense and voluminous infiltrate in the corium, composed mostly of dark, mononucleated round cells, poor in protoplasm; also fixed connective tissue cells showing moderate proliferation, isolated leucocytes with scalloped nuclei, and very few mast cells. Plasma cells are very rare in the infiltrate. Mitoses are few.

"In mycosis fungoides, aside from the darkly stained, mononucleated round cells and leucocytes with scalloped nuclei, there are also numerous large, lightly stained proliferated connective tissue cells, frequently showing division of their nuclei; in some cases there are few or many large and small plasma cells with one or two nuclei. Eosinophile cells, not infrequently seen in the infiltrates of mycosis fungoides, have never been observed in érythrodermie pityriasique en plaques disséminées. Mast cells, which, after all, have but little significance in the differentiation of pathological processes, are nevertheless more numerous in mycosis fungoides, than they are in Brocq's disease. In mycosis fungoides, the number of mitoses in the infiltrate is a large one, due to the unusually rapid growth of the lesions. The œdema of the papillary layer is usually far more marked than it is in Brocq's disease, while the lymph spaces in mycosis fungoides are often enormously dilated. Involvement of the epidermis is far more extensive than obtains in érythrodermie pityriasique en plaques disséminées, the epidermis playing only a passive rôle in the latter affection. In mycosis fungoides there is often considerable evidence of proliferation of the rete cells, the pegs are elongated and sometimes broadened; there may be a great increase in the number of mitoses. Intra- and inter-epithelial œdema is a constant finding and frequently there is a formation of more or less circumscribed, empty vesicles, or vesicles containing nuclei. The latter represent the transition stages seen in mycosis fungoides with eczematoid lesions.

"In érythrodermie pityriasique en plaques disséminées, a marked proliferation of the epithelium is an exceptional occurrence. Intra- and inter-cellular œdema, together with isolated vacuole formations, may sometimes be encountered also in this disease.

"Finally, the question of therapy in relation to differential diagnosis must be considered. While the lesions of mycosis fungoides are susceptible to temporary or even permanent removal under the influence of X-rays, in all stages of the disease, the effect of radiotherapy on Brocq's disease is far less evident,—in fact, there is usually no effect whatever.

"When an eruption of mycosis fungoides simulating parapsoriasis in patches has reached the stage of infiltration and tumor formation, the differential diagnosis presents no difficulties."

In the case of early mycosis fungoides described below, the interesting feature of the eruption is not so much that it closely simulated the picture of parapsoriasis in patches (Brocq's disease, as Arndt likes to term it) but that in the course of a careful and painstaking clinical examination, it was literally impossible to decide with which of the

two dermatoses we were dealing. In fact, the correct diagnosis was not determined until microscopic examination of a section of one of the lesions revealed the true nature of the eruption. As has been said, the two diseases often present eruptions which may resemble one another very closely, but rarely to such an extent that a clinical differentiation may not be readily made after a little attention to details. The character and distribution of the eruption bore a slight resemblance to macular leprosy, a disease which was readily excluded on the grounds of clinical findings. There was no resemblance to other dermatoses.

The practical importance of exact diagnosis in a case of this kind at once becomes apparent when it is considered that mycosis fungoides almost invariably has a fatal outcome. In its early stages, however, it is well known that the progress of the disease may be very materially inhibited by radiotherapy; several instances are now on record in which the skin not only has been entirely freed of its eruption, but in which the disease itself has been apparently brought to a complete standstill. Brocq's disease, on the other hand, can be looked upon, from the practical point of view, as merely a cosmetic defect of the integument, of little pathologic significance. Usually the patients with érythrodermie pityriasique en plaques disséminées are entirely free of subjective symptoms, or at most there may be a little itching. The dermatosis is of interest mainly on account of its obscure ætiology, its extreme chronicity and its inexplicable resistance toward all forms of treatment, including radiotherapy.

Thus, in the case of the premycosic stages of mycosis fungoides, it is evident that the prompt institution of appropriate treatment may mean, not alone the avoidance of very serious future developments in the progress of the disease (tumor formation, ulceration, cachexia, etc.,) but possibly also a complete arrest of the malady in its incipient stages. Whereas, the question of therapy in Brocq's disease is relatively of no practical importance, the eruption constituting a negligible factor with relation to the patient's general welfare and state of health.

Case Report. Early Mycosis Fungoides. (Figs. 1 and 2.)

Sophie W., aged 30 years, married, a native of Southern Russia, has been living in Montreal since the past five years. Occupation, housewife.

Family History. Her family history is negative. She is the mother of two healthy children, aged one and four years. There were no miscarriages. The husband is said to be in good health.

Past History. She had measles when three years old and typhoid fever at the age of sixteen. Otherwise she had been well until the onset of the present illness.

History of Present Trouble. This began about sixteen months ago, manifesting itself by severe attacks of itching of the skin of the right upper arm, at its inner aspect. Here she noticed a smooth, oval patch of slightly reddened skin, about two inches by three inches in size, and free of scales or moisture. The pruritus was said to have been severe enough to deprive her of sleep. About two months later, another patch, similar to the first, appeared on the other arm, in the same location. She consulted several dermatologists in her city, and was advised to use various local applications, but with no effect upon the lesions or the degree of itching. A few weeks after the appearance of the patch on the left arm, new patches, similar in character, appeared in the axillæ, on the chest, back, abdomen, flanks, thighs, and a few scattered lesions on the lower extremities. All of these itched more or less. They varied considerably in size, shape, color, etc., some being circular, others oval, the surface reddish, pinkish, yellowish, etc., free of scales and level with the surrounding healthy skin.

The patient states she has lost 12 pounds in weight since the onset of the trouble.

Examination, October, 1915.

Physical Examination. The patient is a well-nourished white woman, who does not appear to be acutely ill. The scalp and hair are normal. The pupils are equal, regular and react normally to light and accommodation. There is moderate congestion of the conjunctivæ; no ptosis, strabismus or nystagmus are present. The thyroid gland shows a slight enlargement. Ears, larynx, nose, mastoids present no external evidence of disease. The teeth and gums are in good condition, the tongue is moist, moderately coated and is projected mesially without tremor. Tonsils and pharynx are normal. The chest is well-developed, expansion is good, respiration is regular and equal. The heart is normal in size and position; the sounds are normal. Slight accentuation of the pulmonic second sound is present. The pulses are equal, regular, with good force and tension; no thickening of the walls. The lungs, anteriorly and posteriorly, are resonant throughout. The abdomen is soft and relaxed. The liver dullness extends from the fifth intercostal space to four centimetres below the costal margin, where its smooth edge can be felt. Both kidneys are readily palpable. The spleen cannot be felt. The genitals and extremities are normal. No abnormalities of the reflexes are present.

There is a moderate adenitis of the cervical, axillary and inguinal glands; the right epitrochlear gland is also palpable.

The Wassermann and von Pirquet tests are negative. The urine is normal. The blood count shows no abnormalities.

Description of the Eruption. The patient presents a variegated macular eruption involving chiefly the back and chest, the thighs, buttocks and the abdomen. Scattered over these regions of the body are a large number of macular patches, varying in size from the diameter of a split pea to areas several inches in width. They are mostly oval and circular in outline, some of them, however, being irregularly scalloped; the latter appear to be the result of the fusion of several oval and discoid patches. The color of these areas is chiefly a yellowish and reddish-brown; some of the macules are so faintly stained as to be scarcely visible, others show a distinct and well marked buff color, or *café au lait* tint, while still others present gradations in the depth of color, varying between these two extremes. With the exception of a single silver-dollar sized patch, situated near the left shoulder blade, none of these plaques presents the slighest degree of resistence to the palpating finger. The single lesion referred to, is, however, slightly raised above its surrounding normal integument, and a faint amount of infiltration can be elicited by delicate palpation.

The surfaces of these patches are uniformly smooth and appear very much like the unaffected integument in texture; but here and there are a few spots showing a fine branny desquamation, and, on close inspection, several of the medium sized macules depict a finely wrinkled appearance of the surface. None of the spots shows signs of superficial atrophy.

Some of the larger patches, notably those situated on the breasts, differ somewhat from the lesions already described, in that, instead of being uniformly tinted, they consist of pigmented areas of skin, surrounded by narrow zones of healthy and normal appearing integument, resembling little islands. In some regions, the partial or complete coalescence of the macules and patches, with their varying depths of pigmentation, have resulted in a mottled and muddy looking surface, well shown over the groins. Underneath the breasts, where they come in contact with the chest wall, the skin presents crescentic areas, reddish-brown in color, the surface somewhat moist and eczematous, like an intertrigo.

Two deeply-pigmented, pea-sized soft moles are present on the lower part of the back.

Histopathology. (Figs. 3 and 4.)

The histological structure of a section of diseased skin from our patient conformed in every essential detail with the microscopic changes so often described in other cases of early mycosis fungoides. It will suffice, therefore, to submit the following brief report of our findings.

A small piece of skin was excised from a silver-dollar sized, rather sharply defined, light red, faintly infiltrated patch, free of scales, situated between the shoulder blades.

The most prominent pathological alteration consisted of a cellular infiltration, having its seat in the papillæ and the subpapillary portion of the corium. This infiltration was uniform in appearance, presenting a well defined boundary at its lower (deeper) border. A predilection for the blood vessels was not especially marked. The epidermis showed evidences of pressure exerted from below, resulting in a moderate degree of atrophy. Moderate œdema was present. The deeper structures were apparently unaltered, excepting a varying degree of dilation of some of the blood vessels in the corium. The sebaceous and coil glands were unchanged.

Epithelium. The stratum corneum was reticulated and slightly hyperkeratotic. In some areas the cells were compact and laminated. There was no parakeratosis and no infiltration with leucocytes. The stratum lucidum was faintly indicated, here and there. The granular layer was unaltered, varied in thickness between one and two layers, the granules and nuclei of the cells appearing normal. The stratum spinosum presented a mild intracellular œdema. Intercellular œdema was more marked. In the upper layers the intracellular spaces were quite prominent, the nuclei of some of the cells being laterally situated within the cell bodies. Occasional mitotic figures were encountered here. Some areas presented a moderate grade of acanthosis, varying considerably in degree. The basal cell layer, as a whole, was unaltered, but in some areas the palisade cells were disorganized, more especially at the apices of the papillæ, and where the epidermis showed evidences of pressure from below. Cellular infiltration of the epidermis was nowhere present.

Intra-epidermal cavities (to which Unna, Arndt and others have called attention) were scattered in various portions of the epidermis. Two types of these cavities could be differentiated. In one, situated chiefly in the upper portion of the prickle cell layer, the walls depicted a moderate grade of œdema. The prickle cells which bounded these spaces were separated by the œdema; the epithelial cells within the cavity were broken down, as was the protoplasm, evidenced by the presence of many granules. The nuclei of these prickle cells were stained more deeply than those in the vicinity of the cavity. The other type of intra-epidermal cavity was seen chiefly in the mid-portion of the prickle cell layer, the neighboring epithelial cells being apparently unchanged. The contents of the cavities here consisted mainly of clusters of polymorphic cells, similar to those making up the infiltrations in the papillæ, to be referred to later, and bearing the same relation to their surroundings.

Corium. The cells forming the infiltration were polymorphous, many different shapes being depicted. They contained nuclei, some of which were round, others fusiform, others rod-shaped, some being faintly, others deeply stained. Among them were scattered numerous large multinucleated connective tissue cells, possessing prolongations of their cell bodies (dendrites), which connected them to the surrounding connective tissue reticulum. Their nuclei were large, well defined, showing a sparse amount of fine, granular chromatin. The connective tissue reticulum was in no place wanting. It formed a distinct mesh-work, harboring the infiltrating cellular elements. Very few mitotic figures were encountered here, and there was practically an absence of cellular disintegration. Some types of infiltrating (tumor) cells, however, presented double and overlapping nuclei, evidences of mitotic changes. Plasma cells were only occasionally seen in the infiltrate.

The papillary blood vessels were moderately—occasionally markedly—dilated, containing hæmolized red blood cells and a few leucocytes.

The deeper portion of the corium and the underlying tissues were normal in appearance.

The elastic tissue throughout the papillary and sub-papillary strata appeared normal; in the pars reticularis of the corium, however, there was evidence of considerable fragmentation and degeneration of elastin.

The clinical resemblance which this eruption bears to that of parapsoriasis in patches is strikingly illustrated by a case of érythrodermie pityriasique en plaques disséminées (Figs. 5 and 6) which had recently been under our observation and whose history is herewith appended.

Case Report. Parapsoriasis in Patches.*

Referred by Dr. Louis Weinstock; *érythrodermie pityriasique en plaques disséminées; xanthoerythrodermia perstans*). Mrs. C. R., aged twenty-seven years, a widow, stout, healthy woman, whose family and past history presented nothing of interest; personal history, negative. About four years ago, indefinite, slightly scaly, reddish yellow spots appeared on the upper and lower extremities; shortly after, similar spots were noticed on the chest, back and buttocks. They appeared insidiously and without subjective sensations. None of the patches entirely vanished during the past years, but some became lighter and darker at times. Scaling had always been very moderate in amount, especially so on the trunk.

* This case is one of five examples of parapsoriasis reported in the *N. Y. Medical Journal*, Nov., 20, 1915, cii, No. 21, by Wise.

Plate IV.—To Illustrate Article on Mycosis Fungoides and Parapsoriasis, by Fred Wise, M.D., and I. Rosen, M.D.

Fig. 1.
Early mycosis fungoides.

Plate V.—To Illustrate Article on Mycosis Fungoides and Parapsoriasis, by Fred Wise, M.D., and I. Rosen, M.D.

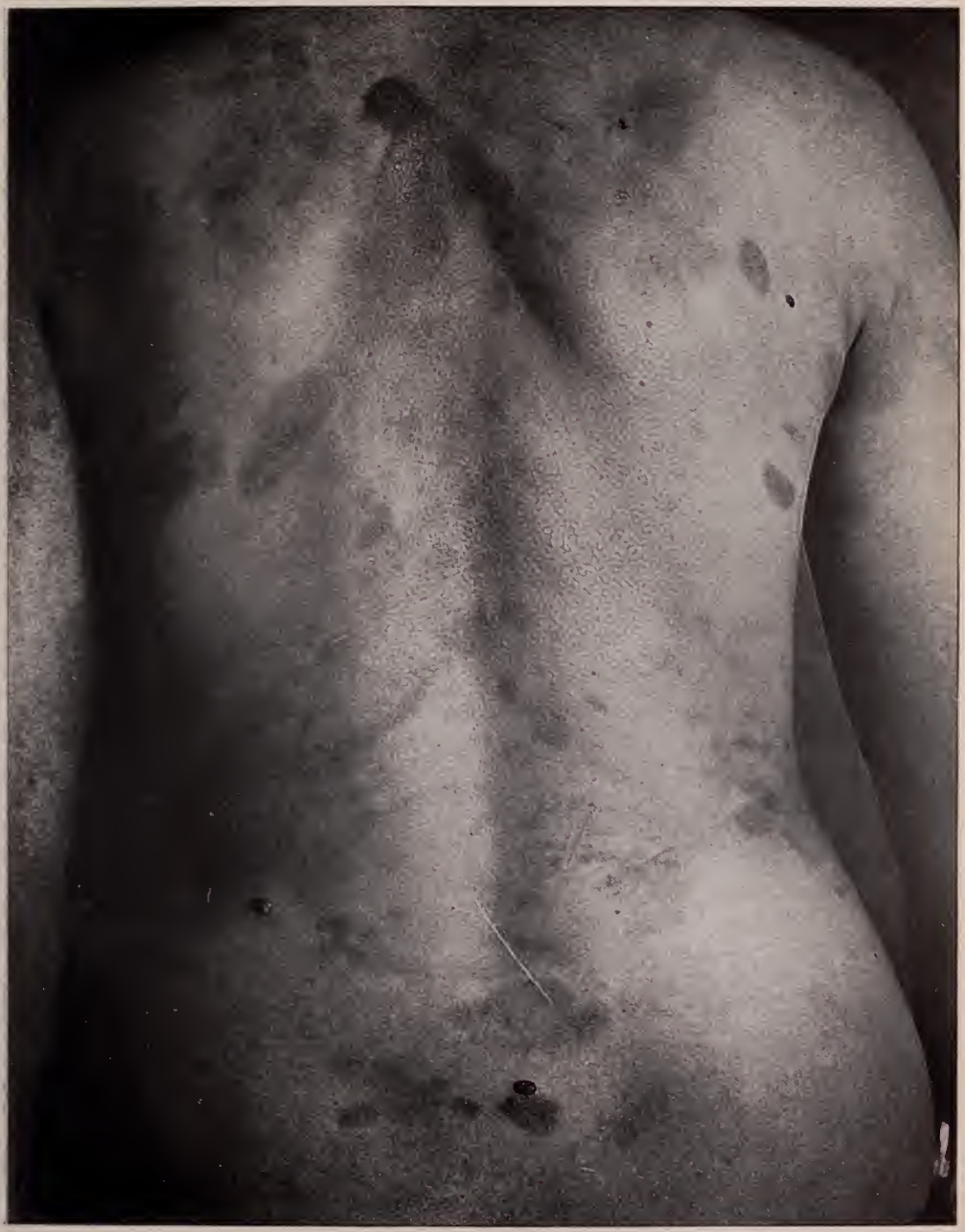

Fig. 2.
Early mycosis fungoides.

Plate VI.—To Illustrate Article on Mycosis Fungoides and Parapsoriasis, by Fred Wise, M.D., and I. Rosen, M.D.

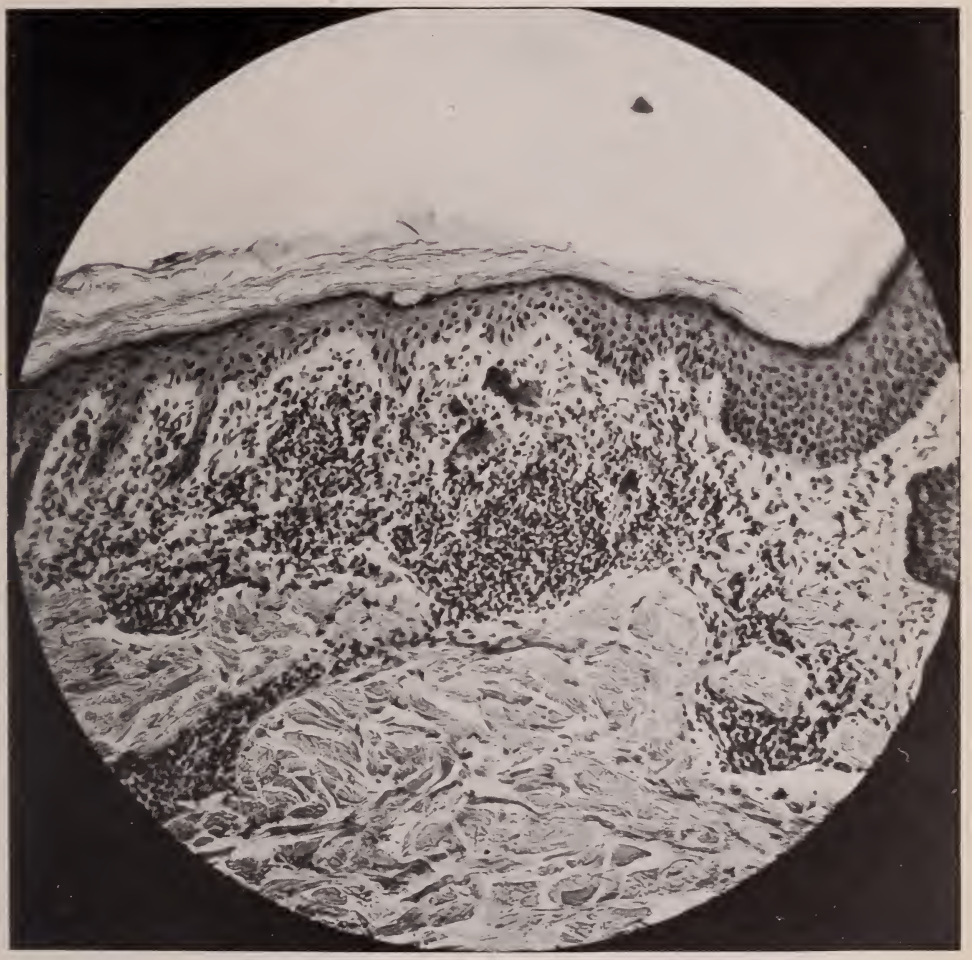

Fig. 3.

Early mycosis fungoides. Zeiss obj. 8 mm., co. oc. 4. Showing thinned epidermis over diffuse round-celled infiltration. Slight hyperkeratosis. Also multinucleated cells (giant cells).

PLATE VII.—To Illustrate Article on Mycosis Fungoides and Parapsoriasis, by FRED WISE, M.D., and I. ROSEN, M.D

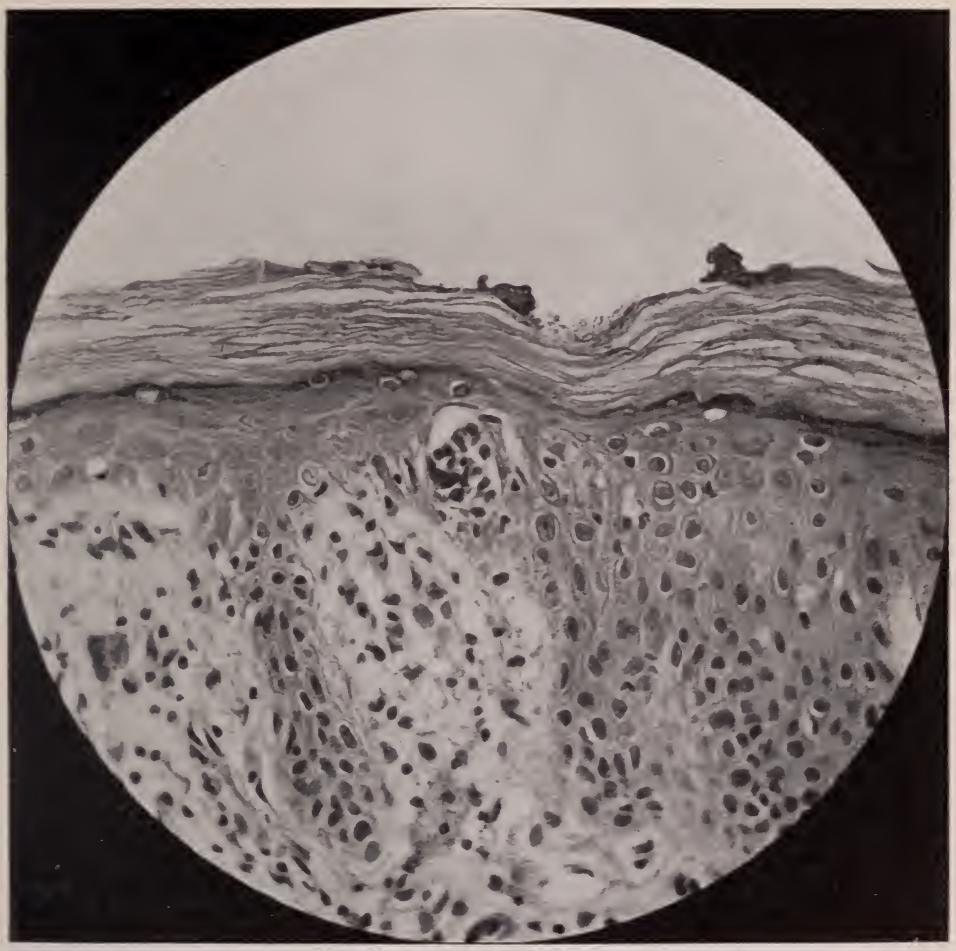

FIG. 4.

Early mycosis fungoides. Zeiss obj. 4 mm., co. oc. 4. Showing inclusion cells in the epidermis; also hyperkeratosis, loss of nuclei, and disorganization of basal cell layer. Round cells, plasma cells and giant cells may be seen.

Plate VIII.—To Illustrate Article on Mycosis Fungoides and Parapsoriasis, by Fred Wise, M.D., and I. Rosen, M.D.

Fig. 5.

Parapsoriasis in plaques.

Plate IX.—To Illustrate Article on Mycosis Fungoides and Parapsoriasis, by Fred Wise, M.D., and I. Rosen, M.D.

Fig. 6.

Parapsoriasis in plaques.

The Journal of Cutaneous Diseases, February, 1916.

Plate X.—To Illustrate Article on Mycosis Fungoides and Parapsoriasis, by Fred Wise, M.D., and I. Rosen, M.D.

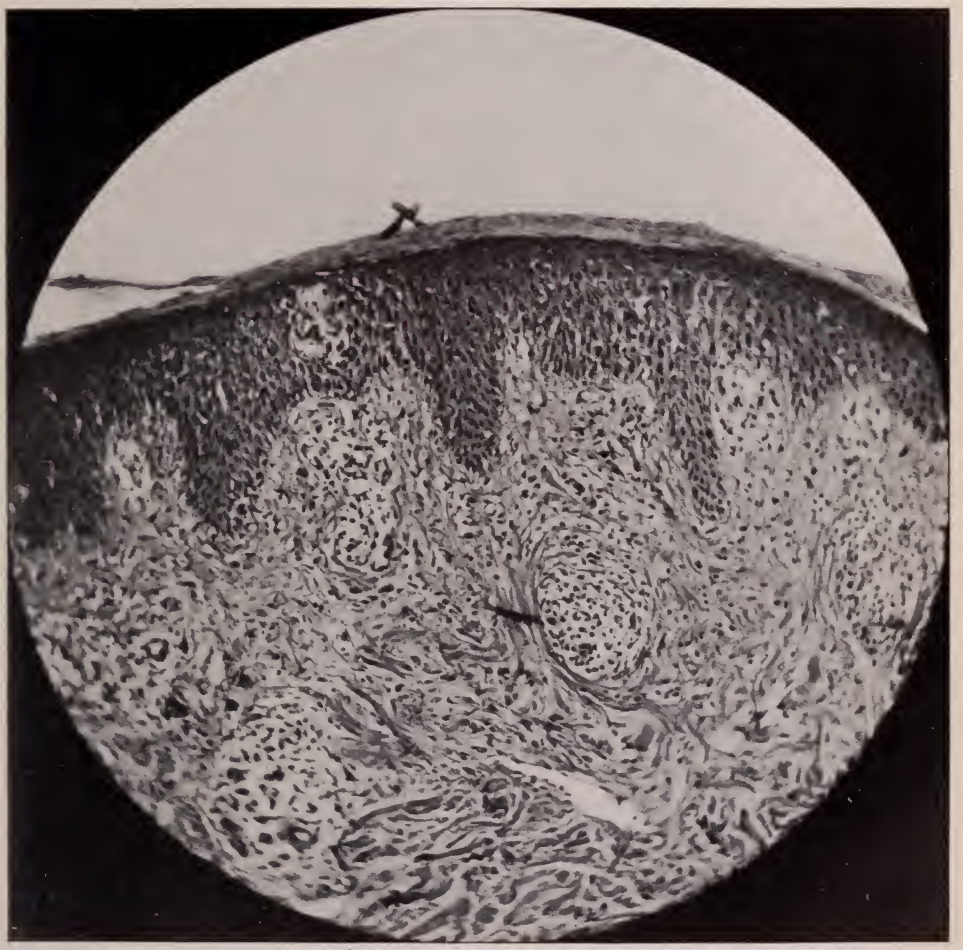

Fig. 7.

Parapsoriasis in plaques. Zeiss obj. 8·mm., co. oc. 4. Showing parakeratosis, œdema of epidermis and derma and moderate perivascular infiltration.

With the exception of the face and neck, and the hands and feet, the skin of the entire body presented a multitude of scattered macular patches, most numerous and most prominent on the trunk, buttocks and thighs, and, approaching the ankles and wrists, gradually becoming paler and paler, finally fading entirely. These macular patches varied in size from that of a silver quarter to areas from three to six inches in diameter. The majority were of about the size of a man's palm. Most of them were circular in outline, especially those on the buttocks and the lower half of the thighs; others were elongated and oval in shape. On the backs of the thighs, just beneath the transverse gluteal fold, these oval patches were seen to follow a certain arrangement in lines, conforming with the folds of the skin. On the anterior and upper portion of the thighs they had a tendency to arrange themselves parallel to the oblique line of the groin. The consistence of these macules was that of the normal skin, *i.e.*, nothing could be made out by the palpating finger. Not the slightest difference between a macule and the neighboring normal skin was perceptible. The patches were flush with their surroundings. In color, these lesions presented a distinct yellow tint, giving the integument a somewhat muddy looking, mottled appearance. The yellow tint was nowhere uniform, but presented gradations, so that some areas were salmon colored, others fawn colored, others buff colored, etc. On the chest and back, these various shades could not be distinguished clearly, for in many areas the patches presented a mixture of colors. On the buttocks, thighs and legs, some of the lesions were reddish brown and purplish in color. Over the shins there were a few ill defined, yellowish, slightly scaly areas, resembling patches of fading seborrhœic eczema. The boundaries of these macules were not sharply defined, but fused imperceptibly with the surrounding normal integument. None of the patches (excepting those on the lower legs) was actually scaly in any sense of the word, but many of them, notably those on the anterior and upper portions of the thighs, gave the impression, to the eye, of being covered with fine scales. Scratching these lesions with the finger nail, however, failed to remove anything more than a meagre scurf. Over the hips, some of the macular patches were distinctly wrinkled into longitudinal folds; this appearance was due to the underlying striæ atrophicæ. On the chest and back the macules had a greasy appearance, due to the coexistence of seborrhœa oleosa. Dermographism was present to a marked degree.

Treatment with sulphur, tar, resorcin, salicylic acid, pyrogallic acid, etc., proved fruitless. A temporary disappearance of some of the lesions was demonstrated after a series of exposures to the Kromayer light. The lesions relapsed as soon as the light treatment was discontinued. The patient was careless and indifferent, so that the value of ultraviolet rays was not ascertained.

Histopathology. (Fig. 7.)

(Section removed from a patch on the thigh): The horny layer was thinned and for the most part composed of two strata, one closely adherent to the underlying epithelium, somewhat homogeneous in appearance; the other, separated from the former by narrow clefts, was lamellated and, in some spots, presented numerous cells containing well stained, elongated, flattened nuclei (parakeratosis). The stratum lucidum was represented by a fine line, in some places absent, in others rather prominent. The stratum granulosum consisted for the most part of from one to four layers of regularly disposed, well preserved cells with distinct granular nuclei. Most of the cells showed evidence of advanced keratohyaline degeneration. The cells of the granular layer seemed to be equally in evidence in areas showing retained nuclei in the horny layer, as in regions where the latter were wanting.

The stratum spinosum was moderately increased in thickness and showed only a moderate amount of intracellular and intercellular œdema. The nuclei were well stained in some areas, poorly defined in others. Throughout the prickle cell layer were scattered spots with cellular infiltrations and collections of pigment granules. Many plasma cells were among the infiltrating round cells. Œdema was a pronounced feature in this stratum.

The basal cell layer was in some regions almost completely obliterated, the palisade cells having lost their uniform arrangement, so that the line of demarcation between epidermis and derma was lost. This condition was most pronounced in areas subject to cellular lymphocytic infiltration around the papillary blood vessels. In other places, the basal cell layer was unaffected, the palisade cells and their nuclei retaining their normal contours.

The pars papillaris of the corium showed a marked degree of œdema, with granular degeneration of the collagen. Lymphocytic cellular infiltrations were scattered throughout this portion of the derma, all of them apparently surrounding dilated capillaries and small blood vessels. These cells were composed of a small, round, well stained nucleus with very little protoplasm. Plasma cells were numerous and polynuclear leucocytes very sparse. The blood vessels were dilated and some had distinctly thickened walls. Most of them were also surrounded by "cuffs" of cellular infiltrations. Infiltrations independent of blood vessels were not seen. The papillæ were narrow, œdematous, and nearly all of them presented the picture of harboring a dilated blood vessel, surrounded by lymphocytes.

The pars reticularis corii presented a swollen and œdematous collagenous tissue. The vascular walls were thickened. The arrectores muscles were swollen and œdematous. The glands were normal.

Clinical Differentiation.

In contrasting two dermatoses such as those described, it need hardly be said that the clinical features which the two eruptions depict to the eye of the observer, are compared only in a given moment, simultaneously, during the course of each eruption. In the more advanced stage of mycosis fungoides—that of infiltration and tumor formation—not the slightest resemblance between the two eruptions exists. If we will therefore imagine that the two patients are before us, stripped for examination and presenting the cutaneous changes above described, we will at once appreciate that certain clinical manifestations of like character, are common to both dermatoses. Both patients exhibit a large number of patches on the skin; some of these are circular, some ovoid, some irregular in shape; their surfaces are smooth, flat, variously colored, some showing a very faint branny deposit, others being slightly wrinkled in appearance, while still others are so delicate as to be scarcely distinguishable from the surrounding healthy integument. The predominating colors in each eruption are light brown, yellow and yellowish-red. In the mycosis fungoides patient the patches are rather better defined and sharply marginated than are those of the parapsoriasis eruption, although the latter is not altogether devoid of

sharply defined lesions. The gradations of tint, also, are rather more evident in the plaques of mycosis fungoides, but even this feature is not very marked in contrast to the variety of colors seen in our parapsoriasis eruption. There is no question, however, that the color scheme in the mycosis fungoides picture is a more variegated one then in the case of parapsoriasis in patches.

The areas of distribution of the lesions, their lack of systematic arrangement, the variability in the size of the plaques, and the coalescence of large and small patches, giving rise to irregularly scalloped areas of discolored skin, are depicted in both eruptions to a like degree. In both cases the palpating finger fails to sense any degree of infiltration or thickening of the affected areas of skin. Scratch marks and other visible evidences of pruritus are lacking in both patients. In one case, the duration of the eruption is approximately two years, in the other, about four years.

Let us now consider the two dermatoses from the opposite point of view and discuss the points of dissimilarity or divergence which can be elicited by contrasting them. Here we cannot limit ourselves to a momentary inspection of the two eruptions as they appear on a certain day, but must take into account the preceding and subsequent behavior of the two dermatoses. While the lesions in the parapsoriasis exanthem have remained practically unchanged during a long period of time—say a year,—those of mycosis fungoides are said to be undergoing more or less appreciable clinical changes, from month to month. New patches are said to appear now and then, in hitherto unaffected skin; older lesions seem to be fading; while some lesions are about to disappear, others are assuming a dark-brown tint, giving rise to a more or less variegated picture—one of the important features of the early stages of the malady. Obviously, the history is of some importance in the determination of the diagnosis of the eruption, although in the present instance, the patient's account of the changes which she observed was too vague to be of the slightest value to us in differentiating her trouble from other dermatoses (a limited English vocabulary must be here considered). While the parapsoriasis patient complained of only very mild itching, severe pruritus was the chief complaint in the mycosis fungoides case. Strange to say, however, in frequent subsequent observations of this woman, we failed to see her in the act of scratching or rubbing the skin for the relief of itching. Of course, the pruritus is most pronounced at night, under cover of the warm bed-clothes.

Nearly all writers on the subject emphasize the occurrence of intense pruritus as a very important and constant diagnostic sign in the premy-

cocic stages of mycosis fungoides. Indeed, so much stress has been laid on this symptom that many clinicians consider it to be the chief differential diagnostic point between early mycosis fungoides and eruptions which are prone to be confused with it. This viewpoint, in our opinion, is not entirely correct. Instances are encountered of mycosis fungoides in its early stages, who do not complain of itching and who present no clinical evidences of scratching or rubbing of the skin. On the other hand, we have seen eruptions of parapsoriasis in patches which occasioned considerable pruritus. Riecke has drawn special attention to this point in a case of macular mycosis fungoides which he reported at length, in whom there was *a total absence of subjective symptoms* referable to the skin, throughout the entire course of the malady. It is fair to say, therefore, that *the presence or absence of pruritus is not really a dependable symptom in the differentiation of the two dermatoses.* "Itching is usually a pronounced feature but may be absent," says Ormsby in his recent text book, with reference to the subjective symptoms in mycosis fungoides. A very extensive example of the *lichenoid* type of parapsoriasis is under our observation at the present time, at the Vanderbilt Clinic. This patient, a man, about fifty years old, complains constantly of very considerable attacks of pruritus, so much so that several competent dermatologists looked upon the eruption as one of lichen planus, which, in truth, it greatly resembles. A microscopic examination of a papule from this patient, however, revealed the typical minute structure of parapsoriasis. Evidently, therefore, mycosis fungoides may occur without pruritus, just as parapsoriasis may be associated with marked pruritus.

Probably the most striking difference between the two cases lies in their response to the therapeutic measures directed against them. While the eruption of parapsoriasis remained practically unchanged despite prolonged treatment of various kinds, and, at the present writing, appears the same as it did a year ago, the patient with mycosis fungoides is now (October, 1915) free of her eruption and free of pruritus, as a result of a few doses of X-ray, administered by Dr. Remer and his assistants at the Vanderbilt Clinic. The beneficial effects of radiotherapy were manifested almost at once and the patient is now apparently rid of the malady for which she sought relief.

Conclusions.

1. An eruption of early mycosis fungoides may so closely simulate one of parapsoriasis in patches that a clinical differentiation, at a given moment, may be impossible.

2. The presence or absence of itching is not to be regarded as an important sign in the differentiation of the two dermatoses. The symptom of pruritus may be lacking in mycosis fungoides and may be present in parapsoriasis, although the reverse usually is true.

3. It may be very difficult to differentiate the two dermatoses without microscopic study of the lesions. In both cases, the histological structure is peculiar to each malady.

4. While the lesions of mycosis fungoides melt away under the influence of X-rays, those of parapsoriasis in patches are uninfluenced by radiotherapy and other remedial agents.

We desire to thank Professor John A. Fordyce for placing the facilities of the Department of Dermatology at our disposal.

For the photographs and microphotographs accompanying this paper, we are indebted to Dr. G. M. MacKee.

REFERENCES.

ARNDT. Ueber Brocq'sche Krankheit (Érythrodermie pityriasique en plaques disséminées) nebst einigen Bemerkungen zur Frage der Parapsoriasis. *Arch. f. Dermat. u. Syph.*, 1900, c, p. 7.

BROCQ. Parapsoriasis; Including the Érythrodermie pityriasique en plaques disséminées. *Jour. Cutan. Dis.*, July, 1903, xxi, No. 7, p. 315.

ORMSBY. Diseases of the Skin. 1915. Lea and Febiger, Phila.

RIECKE. Zwei Fälle von Mycosis Fungoides. *Arch. f. Dermat. u. Syph.*, 1903, lxvii, p. 193.

WHITE, J. C. Case of Brocq's Érythrodermie pityriasique en plaques disséminées. *Jour. Cutan. Dis.*, Dec., 1900, xviii, No. 12, p. 536.

WHITE, C. J. Érythrodermie pityriasique en plaques disséminées. *Jour. Cutan. Dis.*, April, 1903, xxi, No. 4, p. 153.

SPECIAL ARTICLE.

HISTOPATHOLOGY.

(*Continued from January number, page 37*)

By Walter J. Heimann, M.D., New York.

(From the Department of Dermatology and Pathology, Cornell Medical School.)

CHAPTER II.

Infiltrations.

Infiltrations develop in the papillary body, corium, and at times subcutaneous tissue, or in all three together. They are arranged in more or less dense cell deposits, either about vessels or independent of them. They are inflammatory, neoplastic, or embryonic in origin, but only the first type will be discussed in this chapter. Numerous kinds of cells in various combination compose infiltrations, depending upon whether the inflammation be acute or chronic, and whether the latter is of granulomatous character or not. Inflammations are caused by irritants applied to the skin, chemicals, or toxines ingested, or engendered within the body, and by microörganisms of different classes, species and varieties, or by their toxines. The cells of which infiltrations are formed are of either generic or specific types. The former are such cells as are found in different proportions in all types of inflammation, either in the skin or in any other tissue. The latter are cells peculiar to given diseases in connection with which they will be described. They are lepra, xanthoma and Mickulicz or rhinoscleroma cells. The generic cells are derived either from the blood, the endothelial lining of vessels, or connective tissue.

Cells derived from the blood are leucocytes and these are polymorphonuclear or mononuclear. Most of the so-called round cells belong to the latter group. Some round cells may spring from vascular endothelium, or from lymphatic deposits in the skin, and it is conceivable that some originate from connective tissue ancestors. Epithelioid cells may have a similar genesis. Connective tissue yields fibroblasts and possibly the two other types mentioned. Giant cells, which are derived either from the endothelium of swollen capillaries, or epithelioid, or connective tissue cells, must be included at this point. The following table includes the cells which are commonly found in ordinary inflammations:

1. Polymorphonuclear leucocytes known as pus cells.
2. Round cells.
   (a) Cells resembling lymphocytes and derived either from the blood, in which case they actually are lymphocytes, or from vascular endothelial cells, or from connective tissue cell ancestors.
   (b) Plasma cells.
   (c) Mast cells.
3. Epithelioid cells.
4. Connective tissue cells.
   (a) Fibroblasts.
   (b) Old or fixed connective tissue cells.
5. Giant cells.

Polymorphonuclear (Fig. I) leucocytes are present in infiltrations provoked by pyogenic organisms, unknown organisms, and by certain toxines and chemicals. Thus, we find them in great numbers in acne, sycosis, furuncle, carbuncle, glanders, malignant œdema, trichophytosis, the acute exanthemata, particularly in variola, varicella, varioloid, vaccinia, vaccination pustules, the pustular and granulomatous forms of iodine and bromine poisoning, the non-specific ulcerations, the pyodermias and impetigos, and in all dermatoses secondarily invaded by pyogenic organisms. The nuclei of these cells are twisted or curved, and appear in several clumps, united by thin bands of nuclear substance, and look exactly as they do in blood smears. They take basic dyes, such as hæmatoxylin, methylene blue and cresyl violet, intensely. The cytoplasm appears homogeneous, or very finely granular, and is also dyed by basic substances, but less intensely than the nuclei. The cells are round and about double the size of an erythrocyte. Another variety of this group are eosinophile cells. They are found in infiltrations in itching dermatoses and frequently in pemphigus, dermatitis herpetiformis, some leukæmic and pseudoleukæmic skin changes, and in granuloma fungoides, chiefly in the premycotic period. Their significance is not understood. They resemble pus cells, excepting with regard to the staining affinity of the cytoplasm, which, as the name suggests, takes eosine most intensely, the cell body appearing bright red and either homogeneous or granular, and the nucleus dark blue, violet or green, according to the basic dye employed.

Round cells are the commonest constituents of chronic infiltrations. Virchow, according to Lubarsch,[1] thinks that they spring from fixed connective tissue cells, while Cohnheim looks upon them as wandering leucocytes. Ribbert[6] thinks they are fixed lymphocytes in the lymphatic spaces, which multiply locally. Lubarsch distinguishes two varieties,

the small and large. The former, (Figs. II, IX, XI) which are as large as red blood cells, he states are obviously lymphocytes. They have a large, intensely staining nucleus which is deeply colored by basic dyes, while the cytoplasm, staining less intensely with these substances, is narrow and forms a fine zone about the nucleus. The larger type are epithelioid forms, which, according to Maximow,[2] together with plasma and mast cells, are closely allied to round cells. Unna[3] holds that round cells originate from connective tissue ancestors. Favera,[4] in a study on lichen planus, concluded that in this disease at least, Maximow's views are correct, but he quotes Ribbert, Rabl and Gilbert, who state that they develop from foci of lymph cells about vessels. Thus, there are equally authoritative views in favor of the blood vascular endothelial and lymph vascular endothelial, leucocytic and connective tissue cell origin of round cells.

There is scarcely an infiltration from which round cells are absent. Their number varies from very few to the opposite extreme. They tend to group themselves about blood vessels, lymph spaces, or apparently independently of either. They are most characteristic of the infiltrations seen in tuberculosis, lepra, rhinoscleroma, syphilis, the various fungus diseases of the skin, and in pure dermatoses, such as lichen planus, the lichenifications, psoriasis, seborrhœa and many others. They usually signify a chronic inflammatory process, but not invariably.

Plasma cells (Figs. III, XI) are derived, according to Unna[3] and Ivan Bloch,[5] from fixed connective tissue cells which have become hypertrophied, and hence rounded. Lubrasch[1] considers them round cells and states that they are derived from leucocytes. Ribbert[6] considers them large lymphocytes. Unna distinguishes a small and large variety. They are found in the spaces among the collagenous fibres, but are not related to them as are the mature connective tissue cells. Jadassohn, Neisser and Marschalko, says Bloch, found plasma cells wandering from the blood stream into granulomatous areas, a fact which Unna and Ehrlich were unable to confirm. Plasma cells are present in variable numbers in all chronic granulomata, and in many non-granulomatous diseases. The most common of the former are syphilis, rhinoscleroma and lepra. Although these cells possess definite characteristics when stained by ordinary methods, the Unna-Pappenheim pyronin-methylene blue stain shows these features most clearly. The nucleus is circular, and its chromatin is arranged radially so as to suggest a wheel with four or five spokes, broadest at the rim and tapering toward the centre, which they do not however reach. These spokes are more deeply stained by the basic dyes than in the rest of the nucleus. The nucleus

Plate XI.—To Illustrate Article on Histopathology, by Walter J. Heimann, M.D.

Fig. 1.
Polymorphonuclear leucocytes. Semi-diagrammatic. Zeiss obj. 3 mm., oc. 8.

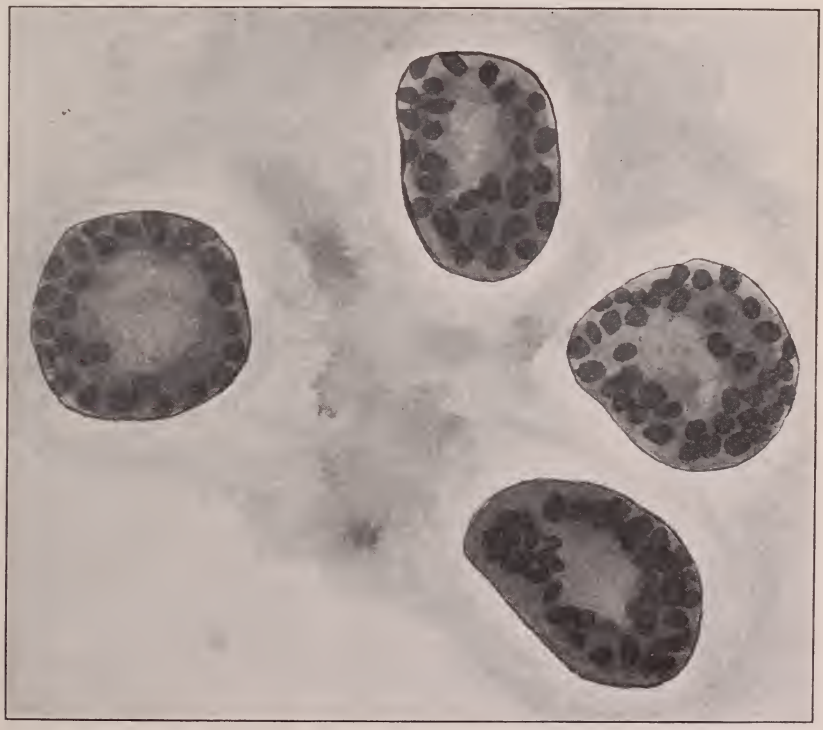

Fig. 2.
Small round cells of lymphocyte type. Semi-diagrammatic. Zeiss obj. 4 mm., oc. 8.

PLATE XII.—To Illustrate Article on Histopathology, by WALTER J. HEIMANN, M.D.



FIG. 3.

FIG. 3.—Plasma cells. Diagrammatic. Zeiss obj. 3 mm., oc. 8.



FIG. 4.

FIG. 4.—Mast cell. Diagrammatic. Zeiss obj. 3 mm., oc. 8.

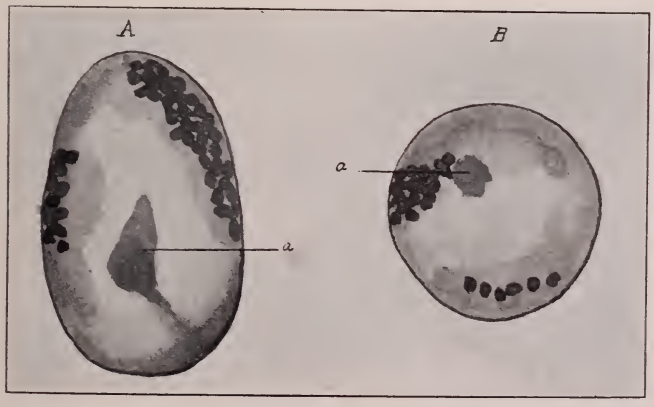

FIG. 5.

FIG. 5.—Epithelioid cells. Semi-diagrammatic. Zeiss obj. 3 mm., oc. 8.

Plate XIII.—To Illustrate Article on Histopathology, by Walter J. Heimann, M.D.

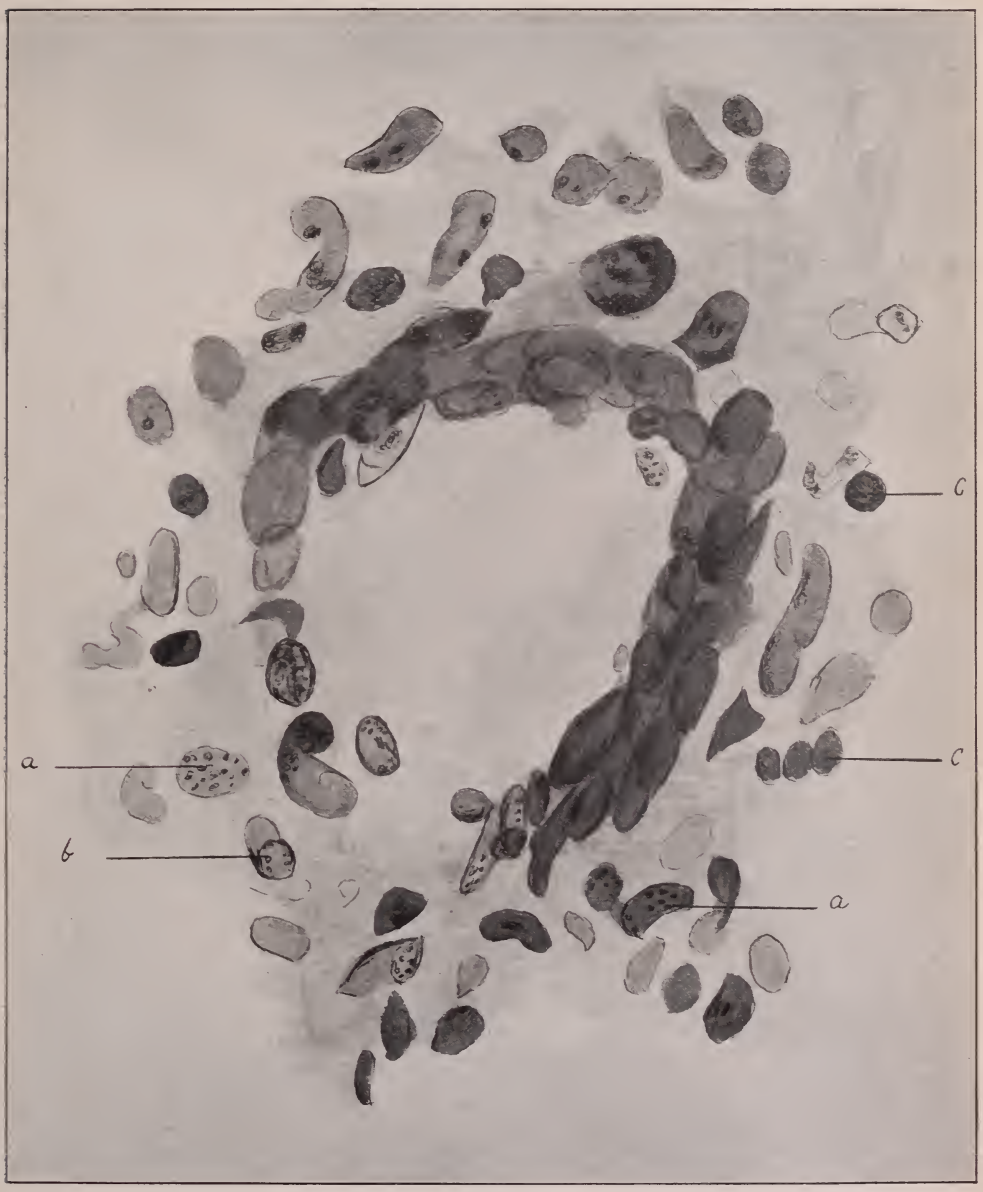

Fig. 6.

Giant cell. Drawn as actually seen. Zeiss obj. 4 mm., oc. 8.

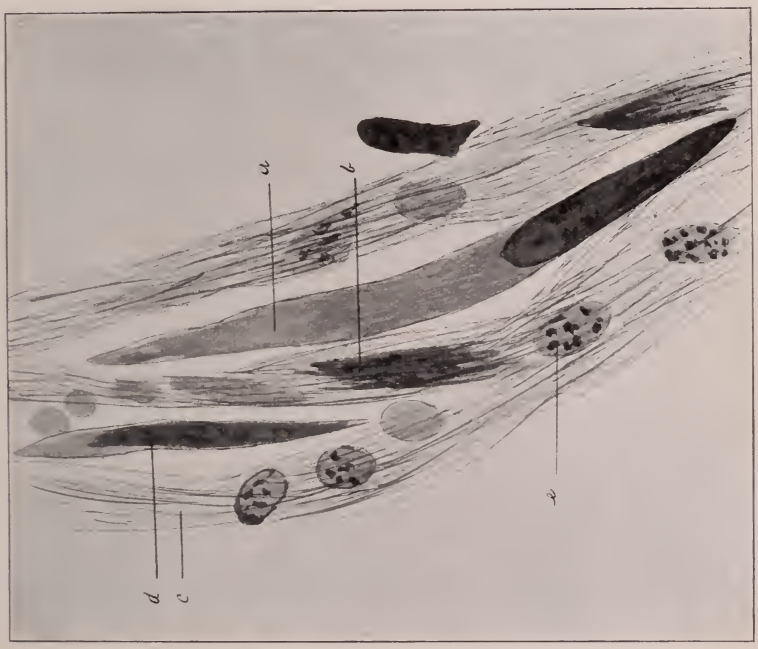

FIG. 8.
Connective tissue cells of fixed or mature type. Semi-diagrammatic. Zeiss obj. 3 mm., oc. 8.

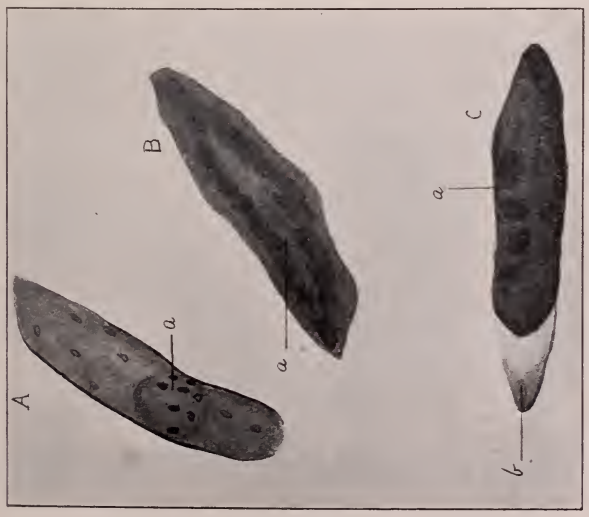

FIG. 7.
Young connective tissue cells—fibroblasts—semi-diagrammatic. Zeiss obj. 3 mm., oc. 4.

Plate XV.—To Illustrate Article on Histopathology, by Walter J. Heimann, M.D.

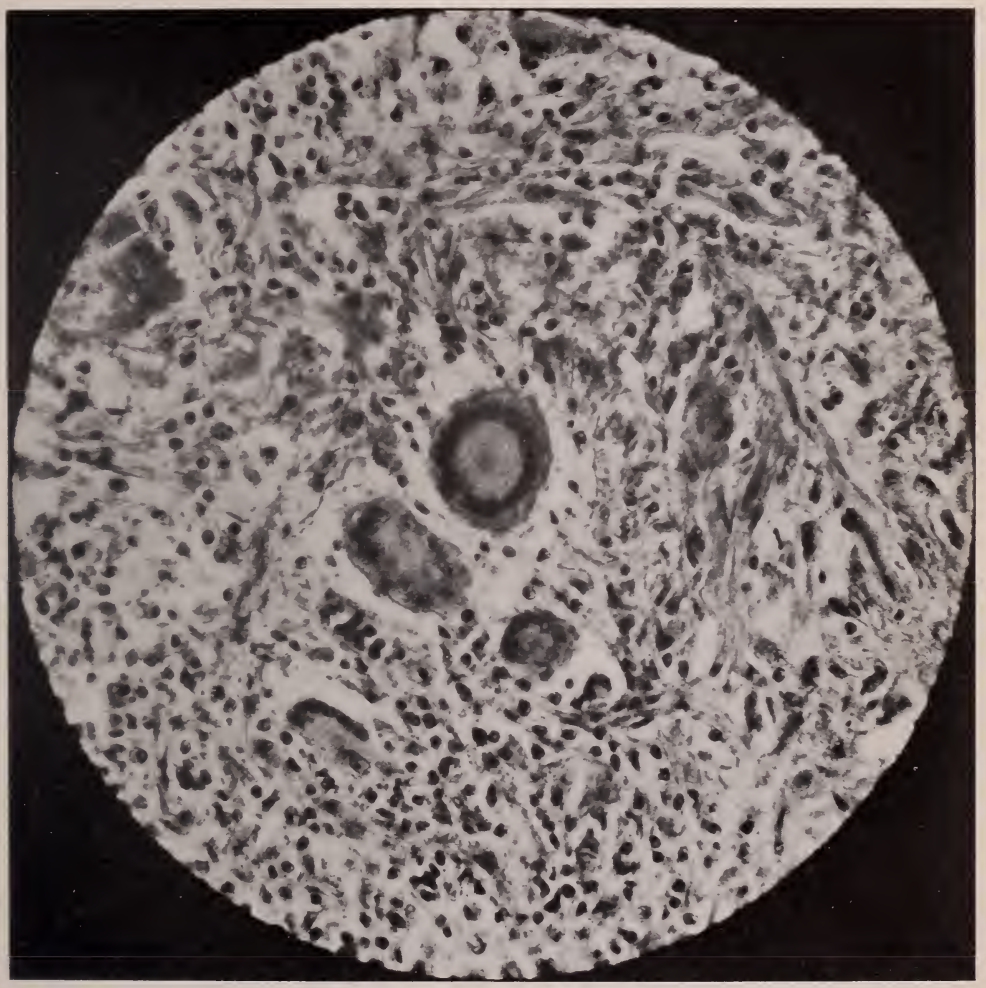

Fig. 9.

Microphotograph from the collection of Drs. Fordyce and MacKee. Zeiss obj. 8 mm., co., oc. 4. Giant cells in syphilis

Plate XVI.—To Illustrate Article on Histopathology, by Walter J. Heimann, M.D.

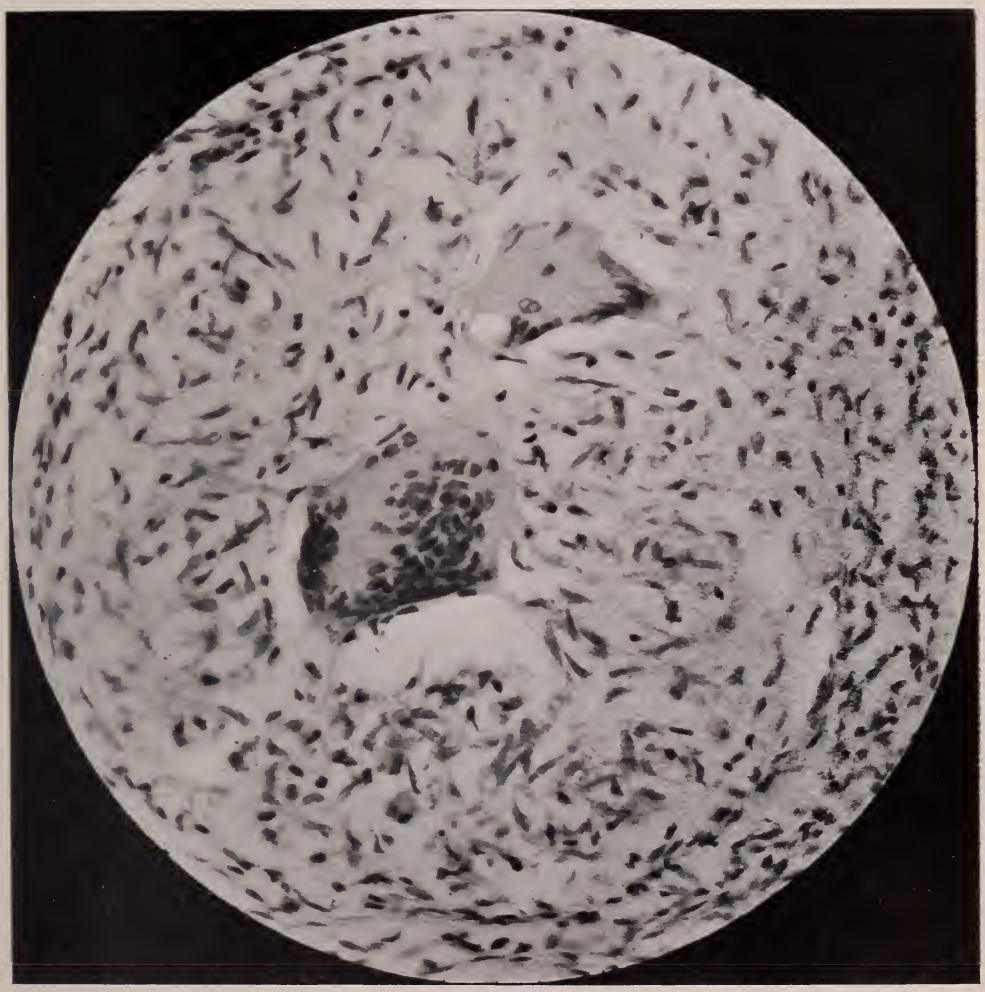

Fig. 10.

Microphotograph from the collection of Drs. Fordyce and MacKee. Zeiss obj., 4 mm., co., oc. 4. Giant cells in tuberculosis.

Plate XVII.—To Illustrate Article on Histopathology, by Walter J. Heimann, M.D.

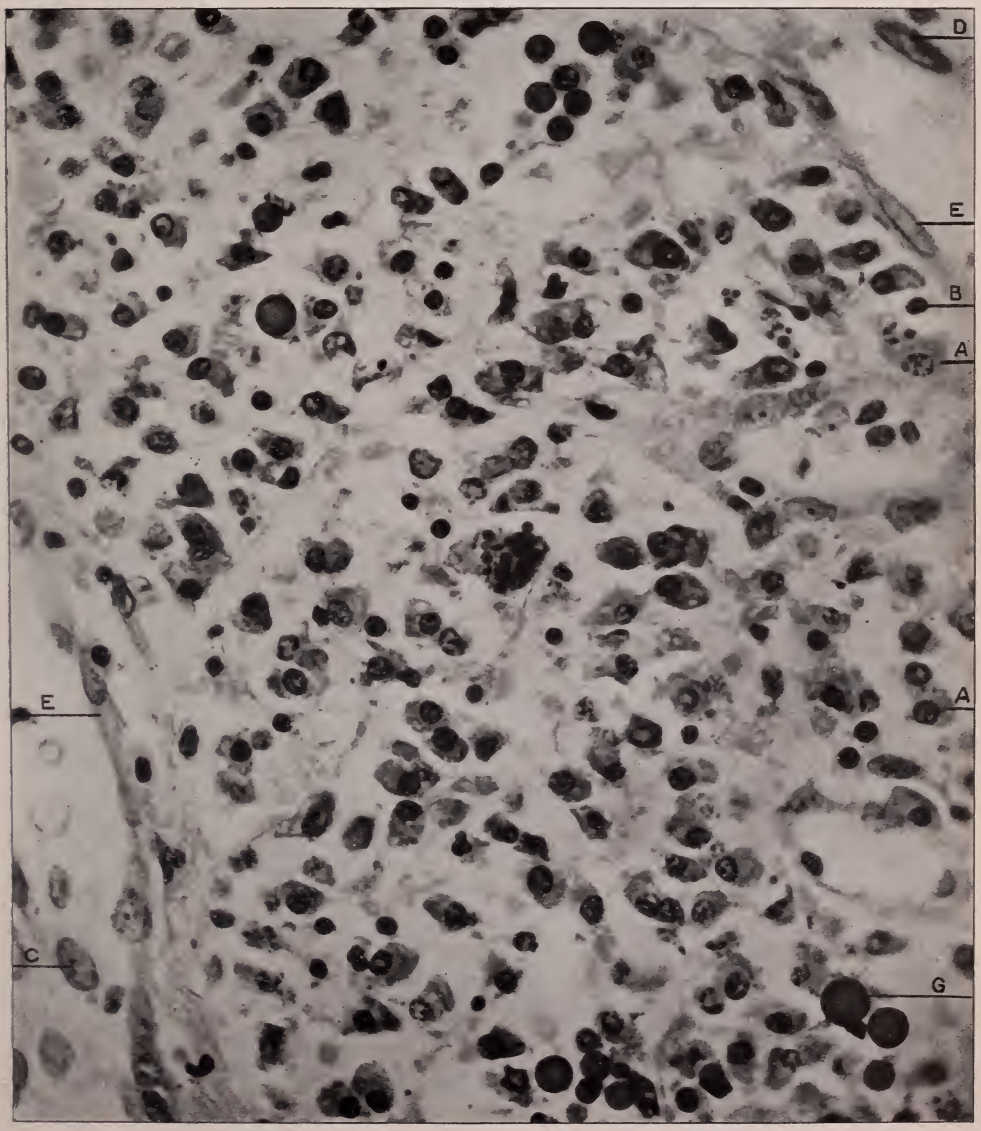

Fig. 11.

Microphotograph from the collection of Drs. Fordyce and MacKee. Zeiss obj. 3 mm., co., oc. 4. A. Plasma cells. B. Small round cells. C. Epithelioid cells. D. Fibroblasts. E. Fixed cells. G. Hyaline bodies.

lies excentrically in the cytoplasm which is granular and appears red when stained by pyronin. The cytoplasm tends to mass itself at the cell periphery, and thins out to nothingness about the nucleus. Thus, the nucleus appears to be separated from the cytoplasm by a clear zone called by the Germans, *"der helle Hof."* The small plasma cells are round and about the size of erythrocytes. The larger ones are from two to three times this size, and either round or roughly polygonal.

Mast cells (Fig. IV) are commonly found in the angioneurotic skin diseases, chiefly the urticarias, both acute and chronic, and they are pathognomonic of urticaria pigmentosa, in which they seem to form almost the entire infiltration. They are also present, however, in other inflammatory lesions and they occasionally occur in epitheliomata. Their morphology may be studied most easily when they are stained with Unna's polychrome methylene blue. They are metachromatic and basophilic, and by Maximow[2] they are included among the round cells. They are twice or three times the size of round cells, irregular or stellate in outline, the nucleus being small and flat and the cytoplasm extensive. The nucleus takes a deep blue stain, while the cytoplasm is partly claret colored and partly dark blue. The former represents the greater part of the cytoplasm, a smooth red surface in which are seen numerous coarse blue granules.

Epithelioid cells (Fig. V, VI, VIII, XI) are included by Lubarsch among the round variety, of which they represent the large type. They are circular or ovoid in shape, about twice the size of small round cells, and consist of a small light nucleus, and an ample, vacuolated, granular cytoplasm, which takes a somewhat deeper stain than does the nucleus. The prevailing impression is one of lightness of color. They correspond to Metchnikoff's phagocytes. Marchand calls them leucocytoid wandering cells, Maximow designates them as polyblasts, and Ranvier as klasmatocytes. They are derived either from leucocytes or fibroblasts and their phagocytic properties are attested to by their occasional content of small leucocytes. Maximow[2] states that they are migrated and altered lymphocytes, which, after wandering, may become fixed. These cells are found in granulomata and many chronic inflammations, mostly of infectious origin. Their presence is explained by their phagocytic attributes. They are peculiarly abundant in tuberculosis and in the tuberculides, in the histological picture of which they frequently present a definite arrangement.

Giant cells, (Figs. VI, IX, X) found in skin infiltrations, excepting those of the giant celled sarcoma, are of two not clearly distinguishable types, that of Langhans, and the foreign body variety. They are alleged

to have a phagocytic function, and their mode of development is accounted for in several ways. They arise, according to Lubarsch[1] from fibroblasts, vessel endothelium, or through a confluence of leucocytoid cells. Those springing from fibroblasts are due to amitotic division of the former. Borst thinks that they come from endothelial or epithelial cells. They may also be formed by the swelling of the endothelium of capillaries, and according to the plane at which these are cut, the giant cells will seem round, oval or irregular. They are found in granulation tissue, tuberculosis, syphilis, lepra, indurated acne, acne keloid and many other diseases. The foreign body variety usually occur near sutures, fibres of dressings included in healing tissue, near paraffin injections, or any other foreign body or substances included in the skin. Within the confines of these cells are found fragments of foreign matter, and in the Langhans cells, foreign substances, bacteria, elastic fibres and leucocytes are often seen. The foreign body cells are more irregular than the Langhans variety. The latter are rounder, with smooth or jagged borders, consist of a great quantity of protoplasm, finely granular, and moderately dyed with basic pigments. At the periphery, either in annular or crescentic arrangement, are the nuclei, from ten to two hundred in number, and darkly colored. The distinction between these two types of giant cells, both as to their significance and origin, as well as appearance, is more or less artificial.

Fibroblasts (Figs. VII, X, XI) are young connective tissue cells. They are mesoblastic in their source, and probably the parents of old or fixed connective tissue cells. They are round or oval, possess a small, deeply staining nucleus and a finely granular or homogeneous cytoplasm. The existence of round fibroblasts is not proved conclusively. Those which appear round are probably oval ones cut transverely. The fibroblasts are able to migrate, but sooner or later they become fixed, and in the latter state either are the source of fibrous connective tissue, or in some way control the development of the latter, a point of view championed by Ribbert.[6] The young cells may divide by mitosis, but more commonly do so by the direct method. They are found in enormous numbers in granulation tissue and young scars, the granulomata, and to some extent in all other types of dermatoses. The old or fixed (Figs.VIII, IX, XI) connective tissue cells are present in these diseases, particularly when organization takes place, and of course they are present in normal connective tissue. They are never numerous as compared with fibroblasts, and are elongated, narrow cells, their length being from ten to twelve times their breadth and their small diameter about that of a round cell. They are fusiform, slightly wavy, and contain a small,

deeply basophilic nucleus, rich in chromatin. The nucleus is elongated, and its long axis corresponds to that of the cell. The cell body is less avid for basic dyes.

The proportions of the various cells enumerated and their arrangement vary in the various dermatoses. A further feature of infiltrations is the changes in number and morphology of the blood and lymph vessels, as well as of the connective tissue and elastic fibres, and the presence or absence of serous, sero-sanguineous or fibrinous exudates. Special and general forms of cell and matrix degenerations, too, are found, such as colloid and cystic changes, fatty degeneration and the presence of cholesterin crystals. All of these features will be duly noted in the subsequent chapters.

Explanation of Figures.

Fig. 1. Polymorphonuclear leucocytes, the so-called pus cells. Semi-diagrammatic drawing as seen with the Zeiss apochromatic system, ocular 8, objective 3 mm. Note shape of nuclei and their granulation. Eosinophiles look like these cells, but their bodies are red when stained with eosin, coarsely or finely granular, and at times homogeneous.

Fig. 2. Small round cells of the lymphocyte type (tuberculosis verrucosa cutis). Semi-diagrammatic drawing as seen with the Zeiss apochromatic system, ocular 8, objective 3 mm. Nuclei are intensely dark, granular and fill out the entire cell area, the cytoplasm being invisible in these specimens. The cells are drawn with surrounding swollen collagen in order to show their relation to the latter in infiltrations.

Fig. 3. Plasma cells (chancre stained with Unna-Pappenheim stain). Diagrammatic drawing as seen with the Zeiss apochromatic system, ocular 8, objective 3 mm. Note the polygonal outline of the large, and the circular outline of the small plasma cell. The nuclei are eccentric and the chromatin is arranged typically. The round patches of chromatin are spoke-shaped masses cut transversely at various levels, the clear zone about the nuclei is crescentic, and outside of this is the rest of the cytoplasm, most intensely stained at the edge. It must be remembered that not all of these features are invariably present together, although usually they are.

Fig. 4. Mast cell (urticaria pigmentosa). Diagrammatic drawing as seen with the Zeiss apochromatic system, ocular 8, objective 3 mm. Note the general flattening and irregular contour of the cells, the small, flat, dark and slightly granular nucleus, and extensive cytoplasm rich in darkly tinted granules. With the polychrome-methelyne-blue stain of Unna the nucleus is dark blue, the cytoplasm light claret, and the granules vivid blue in shade.

Fig. 5. Epithelioid cells (tuberculosis verrucosa cutis, eosin-hæmetoxylin stain). Semi-diagrammatic drawing as seen with the Zeiss apochromatic system, ocular 8, objective 3 mm. Cell A is cut parallel to its long axis. Cell B is cut parallel to its transverse axis. Note the lightness of tint of the cells, the sparse granulation and the small light nuclei (a).

Fig. 6. Giant cell (tuberculosis verrucosa cutis). Drawn as actually seen with the Zeiss apochromatic system, ocular 8, objective 3 mm. Note the size of the cell in relation to the surrounding cells of other types. The giant cell contains between 40 and 50 nuclei which in shape and size resemble epithelioid

cells, and many of the latter actually seem to be derived from this source. The centre of the giant cell is homogeneous. *a.* Epithelioid cells. *b.* Epithelioid cell curved on itself and cut transversely. *c.* Small round cells.

Fig. 7. Fibroblasts (chancre). Semi-diagrammatic drawing as seen with the Zeiss apochromatic system, ocular 8, objective 3 mm. *a.* Nucleus in all the cells. Cell A is very young, suggests the appearance of an epithelioid cell and has a small, faint, round nucleus. Cell B is somewhat older and the nucleus fills the whole body. This cell is more intensely stained than A. Cell C is still maturer, resembles the fixed connective tissue cell in type, and its nucleus is distinct from the cytoplasm. The cytoplasm is beginning to be differentiated in the manner of the fixed cells, as its staining properties show.

Fig. 8. Fibrous connective tissue cells of the fixed or mature type, in relation to collagen fibres and epithelioid cells (tuberculosis verrucosa cutis). Semi-diagrammatic drawing as seen with the Zeiss apochromatic system, ocular 8, objective 3 mm. *a.* Fixed cell. *b.* Fixed cell covered with fibres, the nucleus alone showing clearly among the latter. *c.* Fibres. *d.* Edge of a fixed cell. *e.* Epithelioid cell.

Fig. 9. Microphotograph (syphilis) from the collection of Drs. Fordyce and MacKee. Zeiss 8 mm., co. oc. 4. Giant cells in an infiltration of small round cells and plasma cells. A few epithelioid cells and fixed cells are also present.

Fig. 10. Microphotograph (tuberculosis) from the collection of Drs. Fordyce and MacKee. Zeiss 4 mm., co. oc. 4. Showing giant cells in an infiltration consisting prevailingly of fibroblasts and a few fixed cells, small round cells and epithelioid cells.

Fig. 11. Microphotograph (actinomycosis) from the collection of Drs. Fordyce and MacKee. This is the characteristic picture of a plasmoma. Myriads of plasma cells are present, among a few small round, and epithelioid cells, fibroblasts and fixed cells. There are many hyaline bodies of the Russel type. *a.* Plasma cells. *b.* Small round cells. *c.* Epithelioid cells. *d.* Fibroblasts. *e.* Fixed cells. *g.* Hyalin bodies.

(*To be Continued.*)

References.

[1] Lubarsch. Aschoff's Path. Anatomie, 3d Ed., 1913, p. 550.
[2] Maximow. Ziegler's Supplement, 1902, 5.
[3] Unna. Histopathologie.
[4] Favera. Beitrag. zur Histologie der Papel des Lichen Planus. *Monatsch. für prakt. Dermat.*, Apri., 1909, p. 305.
[5] Bloch. Unna's Lehren, p. 58.
[6] Ribbert. Allg. Pathologie.

SOCIETY TRANSACTIONS.

NEW YORK DERMATOLOGICAL SOCIETY.

Regular Meeting, Oct. 26, 1915.

HOWARD FOX, M.D., *President.*

RHINOSCLEROMA. Presented by DR. G. H. FOX.

The patient was an adult male, twenty-seven years of age. About eleven years ago, a lesion with a scab appeared on his nose, leaving a depressed scar, for which paraffin was injected. In a few weeks the nose looked and felt well. Three years ago another lesion appeared on the right ala, after he had been working in a great heat, by a forge. From this lesion he extracted a hair, with a pair of tweezers, and and the nose became well again. Two years ago the mucous membrane became affected and a sore formed in the right nostril, obstructing the passage. The right nostril became indurated, and this induration spread gradually up the nasal ridge. Eight months ago the patient noticed tenderness on pressure. The greater portion of the nose, the septum, tip and ridge were involved. He had been treated with electrolytic needles, with no benefit.

Dr. Fox showed the case as one of incipient rhinoscleroma and asked if any of the gentlemen thought that the paraffin injected had anything to do with the condition presented.

DISCUSSION.

DR. FORDYCE said that he would hesitate to make the diagnosis of rhinoscleroma without demonstrating the organisms in the lesions. He was inclined to think, from the history of the case, that it was a reaction of the skin to the paraffin injection. These reactions came on months, and sometimes years, after paraffin had been injected under the skin. The connective tissue proliferation which occurred was excited by the foreign body.

DR. WHITEHOUSE could not reconcile the diagnosis of rhinoscleroma with any case that he had seen, and it should not be definitely decided upon without demonstration of the organism. He had never seen a case in which the lip and nares were not simultaneously involved and they usually had a different hardness than that presented by this case. The hardness in this instance was not the hardness of rhinoscleroma, but was an infiltration rather than a real hardness. The color was not the same. Paraffin was diffused over the bone area and a small amount was injected under the scar, which might have accounted for some of the clinical appearances. Whether lupus vulgaris could be entirely eliminated from the possibilities in the case was a suggestion to be considered, but from the clinical standpoint he could not think it was a case of rhinoscleroma.

DR. MACKEE said he had been impressed by the fact that the lesion was apparently composed of semi-transparent nodules, suggesting the apple-jelly

nodules of lupus vulgaris, or the mother of pearl nodules of basal cell epithelioma. In the few cases of rhinoscleroma which he had seen, the tissue was opaque. He then called attention to the teleangiectasis in the case presented, which was seen in certain types of basal cell epithelioma,—as, for instance, the "button" epithelioma,—and in lupus, but he had not seen it in rhinoscleroma. The hardness suggested rhinoscleroma, but the location was against such a diagnosis. Dr. MacKee said he hoped Dr. Fox would be able to report the histological findings at the next meeting.

Dr. Clark could not recall whether he had shown a similar patient before the Society as well as before the Academy of Medicine, but he had presented a patient before the Academy two years ago with a lesion on the right side of the ala of the nose, extending up toward the median line, about the size of half a hickory nut, and elevated. It was very firm and had teleangiectasis associated with it,—little vessels running off into the surrounding tissue. It presented a translucent appearance similar to this case. A section which was removed resembled cartilage, though it was not so hard. It shaded off into the surrounding tissues, and was fairly marginated—about as marginated as the lesions of the case presented seemed to be at its edges. Cultures were made from the biopsy and a variety of diphtheroid bacillus was grown in pure culture. The pathologist at the Skin and Cancer Hospital urged that a vaccine be made and administered. This was done, and after the sixth injection, when he had received four hundred millions, it practically disappeared. The man had remained well ever since.

When the case was presented before the Academy, a diagnosis of possible rhinoscleroma was made. The lesion resembled this one in appearance. Dr. Clark suggested that a similar investigation be made in the case of this patient. The duration of the condition in his own case covered a number of months—he could not at the moment recall the exact time,—but the lesion disappeared entirely after the injections.

Dr. Williams agreed with Dr. MacKee that the translucency and brownish color of the lesion suggested lupus vulgaris, and said that there was a possibility that the eruption was an unusual form of tuberculosis.

Dr. Howard Fox thought it was difficult to reconcile the blueness and teleangiectases with the diagnosis of rhinoscleroma. It seemed most probable that the condition was an inflammatory reaction to paraffin. He had never, however, seen such a hard mass following paraffin injection.

Dr. George H. Fox said that a positive diagnosis could not be made without a biopsy. At first he was inclined to believe, as Dr. Fordyce had suggested, that an inflammatory condition had resulted from the paraffin, but after examining the case very carefully and taking the history into consideration,—finding that the lesion on the mucous membrane had been gradually progressive and that for several years the patient had been perfectly well after a small amount of paraffin injection, he finally concluded—much as he desired to think it an inflammation from the paraffin—that the case was one of incipient rhinoscleroma. Most of the cases that he had seen involved the lip, but they were of long standing. The few cases of paraffin injury that he had seen had not presented this almost stony induration. Examined in the day time, he did not think the idea of lupus would suggest itself. In no other disease had he found such induration, certainly neither in lupus nor in cases of paraffin dermatitis.

The diagnosis was based upon the development of the condition upon the nasal mucosa and its slow, gradual and painless extension upon the surface of the nose, and especially upon the unusual hardness of the cutaneous tissue, with redness and formation of teleangiectases. Although the patient was leaving town for Buffalo, Dr. Fox hoped to have a biopsy made, and to report upon the case at another meeting.

FOR DIAGNOSIS (SYPHILIS OR TUBERCULOSIS?). Presented by Dr. Trimble.

The patient, a girl of eight years, from the University and Bellevue Clinic, had a peculiar crusted lesion on the cheek, with some infiltration. The glands at the angle of the jaws were swollen and tender. The lesion had existed for three months, and had come on after a slight scratch which rubbed off the epidermis. The lesion, with the glandular enlargement, resembled an initial lesion of lues, and this was the tentative diagnosis until the case was further investigated. Three careful examinations for spirochætæ were all negative. Also some scales had been removed for examination, but nothing was found. Culture experiments were being made.

Discussion.

Dr. Wise said that he had seen the case at a previous meeting, and could only repeat what he had then stated, that the lesion seemed to him to be a verrucous type of tuberculosis.

Dr. MacKee agreed with the diagnosis of tuberculosis verrucosa cutis.

Dr. Trimble said that the diagnosis of tuberculosis verrucosa cutis had been very seriously considered, but it could not be proved without making a biopsy, and he had not desired to do this until some palliative treatment had been tried. Although the lesion bore some resemblance to tuberculosis, the duration was very short (3 months) for a lesion of that size. The case would be reported at a subsequent meeting.

FOR DIAGNOSIS (ULERYTHEMA OPHRYOGENES?) Presented by Dr. Clark.

About three years ago the patient, a young man, noticed a reddened condition of the skin of the eyebrows, and that the eyebrows were thinning a little. The condition always grew redder when the patient became flushed and the whole skin flushed up under any excitement or any exertion. He had had many forms of treatment for the condition,—salicylic ointments, mild and strong, and white precipitate ointments, mild and strong; red oxide of mercury and other anti-parasitic and antikeratotic applications,— without any real effect on the condition, which had persisted practically in the same state for the last two years.

The patient was presented for diagnosis: the reddened condition of the eyebrows could be distinctly noted. The man stated that he had had some scaling after some of the stronger ointments had been used, and a dermatitis had apparently been produced. There had not been much scaling, however, except where the eyebrows had fallen out, leaving a slight pit-like depression at the site of the hair. At the time of presentation, the partial alopecia was confined to the outer ends of the eyebrows. The speaker stated that he had another private case presenting a condition very similar to this one, with the lesion very extensive in the region of the eyebrows. The scalp and remainder of the body surface was free in both cases.

Discussion.

Dr. Whitehouse said he was sure the condition was one of those cases of ulerythema ophryogenes described by Taenzer. There had been several of these at the Skin and Cancer Hospital at the time Unna wrote on its pathology, and the clinical type was precisely the same as in the case presented: none of them extended beyond the eyebrows, and they took in one-half or the outer third of

the eyebrows first, and then worked across with keratosis, depilation and atrophy. In Unna's histopathology he gives Taenzer's description and his pathological investigation of the condition. This affection was first described by Taenzer as occurring mainly in blond individuals, but the boy presented by Dr. Clark was not blond. "It affects always and preferentially the eyebrows, extends to adjacent parts of the forehead and cheeks to the neck, and later appears on the extensor surfaces of the upper arms." (All the cases which the speaker had seen appeared to be limited to the eyebrows). In certain cases it extended over the forehead, to the hairy scalp. In the milder forms it was merely a persistent erythema with the elevation of small horny globules at the mouths of the hairy follicles. The hairs were usually broken off close above the surface. After years of persistence, the affection led to a follicular and inter-follicular atrophy, and small scar-like depressions stood out clearly from the hyperæmic surroundings; the outer part of the eyebrows completely disappeared. Individual hair circlets were enclosed by a scar-like, hairless, smooth zone, while the centres of the hair circlets still contained abnormally dry hairs on a hyperæmic base. Many cases remained throughout life at the stage of erythema and horny globules. Except for the atrophy, the affection resembled keratosis suprafollicularis.

Dr. Clark said he would be glad if some one would make a new suggestion along therapeutic lines, as these patients of his were private cases, and every thing he knew of had been tried.

SECOND X-RAY DEPILATION IN A CASE OF TINEA TONSURANS. Presented by Dr. MacKee.

The patient was a little girl from Dr. Fordyce's Clinic, who applied there for treatment of disseminated ringworm of the scalp. On October 22, 1914, the entire scalp was depilated by means of the X-ray, in accordance with the Kienböck-Adamson method. In about three weeks, the hair fell out. The return of the hair was unusually prompt, beginning in about a month, with a vigorous and rapid growth. Spores were still demonstrated on the hairs, so a second Kienböck-Adamson treatment was administered, five months after the first treatment. The hair again fell out, and began to regrow in about two months.

When presented to the Society there was a vigorous growth of hair. The scalp was scaly, but repeated examinations had failed to reveal evidence of ringworm. Dr. MacKee said that a mild pityriasis of the scalp was common after X-ray treatment, and usually disappeared in about a year. The patient was presented for the purpose of demonstrating the safety and advisability of a second treatment in case of failure following the first application. It was, however, always necessary to allow the hair to regrow vigorously before applying the X-ray for a second time, otherwise more or less permanent alopecia might result. The speaker said that recurrences following a single properly administered treatment were uncommon but occasionally did occur.

BASAL-CELLED EPITHELIOMA OF ABDOMEN. Presented by Dr. Trimble.

The patient was a female; fifty-six years of age; born in Scotland. She had been in this country thirty-two years and was the mother of eight children. The lesion began thirty years ago, immediately below the umbilicus, gradually spreading until it became about the size of the palm, as presented. There was very little thickening. There was a distinct line of demarcation, slightly scaly—scales adherent— color, slightly red. The lesion was always dry excepting that at times there was a slight hæmorrhage, due to irritation. The patient claimed

that the lesion was sometimes tender. From a suspicious looking spot in the border, a piece of tissue had been taken, which upon examination proved to be basal-celled epithelioma.

Discussion.

Dr. Potter said that the lesion appeared as a chronic eczematoid dermatitis, which one should always suspect as being malignant. In this instance, he could not make out any distinct border to the lesion, characteristic of Paget's disease. It appeared to be a chronic eczematous condition, with a suggestion of Paget's disease. He said he had seen such a case the previous week. It was examined very closely, and a biopsy was made, demonstrating Paget's disease. He could not make the diagnosis clinically, but relied upon the biopsy.

Dr. Whitehouse agreed with the diagnosis and thought it was a basal-celled epithelioma, spreading over the skin, presenting the early characteristics of Paget's disease without metastasis.

Dr. Fordyce also agreed with the diagnosis, and said that it was a rather unusual type of skin epithelioma which was often met with in multiple patches. It was seen over seborrhœic areas, most frequently over the trunk and sometimes on the lower portion of the back and buttocks. In the early stages, the lesions were very superficial, slightly scaly, and had a definite border. The histological examination in the early stages of development sometimes showed the picture of Paget's disease, but later, as the lesions developed, the picture was more that of basal-celled epithelioma. This type of epithelioma was sometimes mistaken for late syphilitic lesions.

Dr. Williams said that he had seen a similar case at the Skin and Cancer Hospital. The patch was about as large as the palm of the hand and was exceedingly superficial. It had an almost invisible border and was of several years' duration.

Dr. Trimble said that the border was not very definite, being almost like a thread in one or two places. Two biopsies were made, but it could not be said definitely that it was Paget's disease, though the clinical resemblance was very close.

KERATODERMIA BLENORRHAGICA? Presented by Dr. Fordyce.

The patient was a woman, thirty-eight years of age, who was first seen at the clinic that day. She had a gonorrhœal vaginitis and gonorrhœal rheumatism. The interesting condition was a keratitis which involved the elbows and palms and in some of its features suggested psoriasis. It had developed since her gonorrhœal infection. Previous to that time she had had no skin eruption whatever. The duration was about four months. The lesions on the palms suggested a scaling syphilide, and for that reason a specimen of the blood had been taken for the Wassermann reaction.*

Discussion.

Dr. Trimble said that he had never seen a case of the disease, unless this case presented by Dr. Fordyce proved to be one. He could not agree with the diagnosis if he followed the conception of the disease gleaned from the literature. He had read Simpson's paper and had seen colored photographs in the various atlases, none of which were like the case under discussion. He did not know

* After the patient was presented before the Society, the Wassermann reaction was reported positive. In all probability, therefore, the lesions were syphilitic.

of any case in which the type of eruption exhibited by this patient had been described in connection with gonorrhœa. His idea, gathered from the literature, was that the lesions were all small (not larger than a split pea), more keratotic than in the case presented, and distinctly raised above the skin.

Dr. Wise remarked that Dr. Ormsby, in his recent text-book, makes the statement that lesions of this kind were very apt to resemble psoriasis.

Dr. Clark said that the lesion very strongly suggested a syphilitic nature, and he would like to see that ruled out before the diagnosis was accepted.

Dr. Howard Fox said that, like Dr. Trimble, his idea of gonorrhœal keratodermia was that the lesions were more distinctly keratotic. He recalled a recent abstract in The Journal, of two cases of this disease, in which the eruption recurred with successive attacks of gonorrhœa. This seemed to be strong clinical evidence of a relationship between the two conditions.

Dr. Fordyce said that of course the connection between the patient's eruption and the existing gonorrhœal vaginitis was not demonstrated. The case was presented with a tentative diagnosis only. We had to eliminate syphilis and take her word that she never had any eruption until she had the gonorrhœa. She might have had it, as patients were usually very poor observers. Dr. Fordyce said that he thought none of the members had seen a sufficient number of cases to say that a certain definite clinical picture was associated with this keratodermia that follows gonorrhœa. He himself had seen one case in Gaucher's clinic, in which there was a more diffuse keratodermia involving the palms and dorsal surfaces as well, with localization on the extremities.

URTICARIA PIGMENTOSA. Presented by Dr. MacKee for Dr. Fordyce.

The patient was an unmarried female, twenty-two years of age, born in Austria. She had had a skin eruption since birth. The face, trunk and extremities were affected. The eruption consisted of yellowish-red lentil- and pea-sized papules and macules. The papules were most numerous on the flexor surfaces of the forearms. There were many pigmented macules scattered over the affected parts. Pruritus was not complained of. Occasionally there were outbreaks of urticarial wheals.

SCLERODERMA. Presented by Dr. MacKee for Dr. Fordyce.

The patient was a male, forty-five years of age, born in Russia. The duration of the condition was about six months. The skin of the neck, but especially the thorax, was hard and adherent to the underlying tissue. The rigidity was so great as to markedly interfere with the flexor muscles of the neck and prevented thoracic respiration.

Discussion.

Dr. Fordyce said that in his opinion warm bathing and massage were the only things that had done such cases any good.

FOR DIAGNOSIS (PARAPSORIASIS LICHENOIDES CHRONICA.) Presented by Dr. MacKee for Dr. Fordyce.

The patient was a male, fifty-eight years of age. Three years ago he had suffered from gout and rheumatism and had taken the salicylates and iodides. The eruption developed about two years ago and had remained ever since. The mucous membranes, the face, the soles and the scalp were unaffected; otherwise the eruption involved nearly the entire cutaneous surface. While there were

no scratch marks, the patient complained of intense itching, and frequently he could be detected scratching and rubbing the skin.

The lesions were slightly elevated papules of a dull red color, smooth, and closely crowded, with here and there a tendency to grouping and configuration. They were flat-topped, but not angular or polygonal, and with very few exceptions they were not umbilicated. Most of them were pinhead in size, although a few were the size of a split pea. There was no pigmentation nor scaling. There were a few lesions on the palms. In a few locations a linear arrangement of the lesions was detected. The eruption markedly suggested the acute type of lichen planus, but the papules were not polygonal in outline, there was no pigmentation, the mucosa was free and the duration was over two years. The speaker thought that the diagnosis rested between an unusual case of lichen planus or the type of parapsoriasis described by Juliusberg.*

Discussion.

Dr. Clark said he thought he saw lesions on the man's back and one or two on the legs near the knee, which were rather flat and umbilicated papules, and while they were not polygonal, they certainly suggested lichen planus lesions. It was difficult to determine the color of the lesions by artificial light and that was an important feature in determining the diagnosis. He was inclined to think it was lichen planus.

Dr. Fordyce agreed with Dr. Wise's diagnosis of parapsoriasis lichenoides. He said that the absence of scaling, pigmentation and plaque formation, with the absence of lesions on the mucous membranes, would speak against lichen planus. In such a widely disseminated eruption as the case presented, with the history of long duration, it would be very unusual not to find some lesions which presented the features of lichen planus. In this case none was present.

Dr. Whitehouse said he could not conceive of lichen planus lasting for so long a time without pigmentation and without itching. The word lichenoid was used because it was the lichenoid type of parapsoriasis, and that was why the lesions were similar to lichen planus. We saw many polygonal lesions in other diseases that were not lichen planus, and sometimes we erroneously based our diagnosis wholly on that fact.

Dr. George H. Fox said that there were many cases of undoubted lichen planus in which the lesions were not polygonal. In many cases of chronic eczema, there were shining papules which resembled lichen planus and frequently caused a mistake in diagnosis. He had seen one or two cases of chronic lichen planus lasting for years, and inasmuch as some of the lesions in this case bore a strong resemblance to lichen planus papules, although not typical, he would call it a case of lichen planus. As near as he could judge it by artificial light, the eruption seemed to have the typical purplish color which was a most important diagnostic feature in this disease.

Dr. Potter said that at first glance the case was apparently a lichen planus, but after a closer study of the lesions and their individual characteristics, he agreed with Drs. Fordyce and Whitehouse in the diagnosis of parapsoriasis lichenoides.

Dr. Trimble said that the case was an extremely interesting one. On first examination he would be inclined to think it was lichen planus, although the

* A piece of tissue had been removed for histopathological investigation but it was not obtained in time to allow of a report at the time of presentation. The histological picture conformed to that found in parapsoriasis lichenoides chronica. Lichen planus could be excluded.

majority of the lesions were not typical. However, there were a few that seemed to bear a close enough resemblance to lichen planus lesions to call it lichen planus in a stage of retrogression. He had never seen a case so long in duration as this one, but had seen several that lasted a year. Perhaps if the man had not been properly treated before he appeared at Dr. Fordyce's clinic and the disease was allowed to progress, it might go on to a certain stage, then remain stationary for a long period, thus presenting a clinical picture like this one. If it became necessary to make a diagnosis at this sitting, he would think it was lichen planus.

Dr. Wise said that the patient had taken large quantities of Fowler's solution for a long period of time, without any improvement in the eruption. A biopsy was obtained and the findings were to be reported at the next meeting of the Society. His clinical diagnosis had been parapsoriasis lichenoides chronica.

FOR DIAGNOSIS. Presented by Dr. Clark.

The patient, a male adult, brought his brother with him, who presented a similar condition to this one. The patient was forty-nine years of age, born in Switzerland, and stated that at about the age of fourteen years, when he commenced to do hard work, he began to have bleeding from the nose and had had more or less nose-bleed ever since. It was worse in winter, when he apparently got a cold in the head easily. At times the bleeding was so profuse that the patient was practically almost exsanguinated. He stated that his father and three uncles had had the same condition. There were four boys in his immediate family, and he brought his brother with him to show that two out of four had a similar condition. Two sisters also seemed to have the same type of bleeding from the nose.

These patients presented multiple teleangiectases of the face and neck and the mucous membranes. There were definite small punctate, angiomatous lesions, and the bleeding was apparently due to a rupture of one of the small angiomata. The patient was presented without naming the condition. It might be called a case of multiple punctate bleeding angiomata, as Dr. Whitehouse had suggested in the morning, or a multiple bleeding teleangiectases of the skin and mucous membranes. There were lesions on the tongue and mucous membranes of the mouth, but no bleeding. He had had various sorts of treatment for the condition. Horse serum had been given to him at various times. He would bleed, off and on, for a week or ten days at a time,—sometimes a little bit, and at other times quite profusely,—so that he had to be taken to the hospital and have his nose packed. He had been transfused two or three times, and the blood clotting time was perfectly normal. Dr. Clark said that he supposed that was the reason the patient had received no benefit from the serum treatment.

Apparently this was a case of congenital dilatation of the vessels of the skin, of rather an unusual character, and the rupture of these vessels produced the hæmorrhages. In the lesions on the skin, the speaker had taken a fine point galvano-cautery and cauterized them and they could be easily obliterated, leaving a little punctate scar. He had attempted to do the same with the little angiomatous lesions of the mucous membrane of the nose. In a good many which he had attempted to cauterize, the bleeding had been profuse and it had to be followed by a very tight packing of the nares, both anteriorly and posteriorly. All sorts of styptics had been tried and he now presented the patient for a definite nomenclature and particularly for suggestions along therapeutic lines. The patient had no lesions on his body nor on his extremities. The lesions stopped at the neck, and so far as could be determined, were confined apparently to the head region.

DISCUSSION.

DR. WHITEHOUSE said that these cases were very interesting but that he could not shed any light upon the therapeutic possibility in such cases. He thought the nature of the condition might possibly be solved by the physiologist.

DR. WISE said that cases of this type were described by F. Parks Weber, of London. Some of them were said to be related to hereditary syphilis.

DR. WILLIAMS said that, in view of the fact that the bleeding in this case was limited to the nose, the fact that the coagulation time was normal, and that the man did not bleed easily from the cut surfaces, he was inclined to think that the symptoms were due to some pathological condition of the vessel walls in that region and not to a chemical fault of the blood, in which case one would expect lesions scattered over various parts of the skin, and not limited to a single area.

DR. CLARK said that he agreed with Dr. Williams' suggestions, because the little punctate angiomata kept on appearing. New ones cropped out and appeared, presenting themselves through the mucous membranes and the skin.

NÆVUS VERRUCOSUS LINEARIS. Presented by DR. WISE.

The patient was a male adult from Dr. Fordyce's Clinic and was twenty-one years of age. He presented a number of verrucous linear nævi, symmetrically arranged on the back, chest, abdomen, upper and lower extremities. He had had six massive X-ray treatments on various regions of the body, but sufficient time had not yet elapsed to show much improvement. The discoloration on the elbows was due to the X-ray, and was rapidly fading.

MACULO-ANÆSTHETIC LEPRA. Presented by DR. TRIMBLE.

The patient, an adult, was twenty-four years of age and had been born in Greece. He presented leprosy of the maculo-anæsthetic type, and the only special feature of the case was the fact that the lesion on the forehead was unilateral, stopping very abruptly at the middle line of the forehead. There were some lesions on the trunk and extremities, and there was some anæsthesia in the various regions of the body.

NEW YORK ACADEMY OF MEDICINE,

SECTION ON DERMATOLOGY.

Regular Meetings, Oct. 5, and Nov. 8, 1915.

CHARLES M. WILLIAMS, M.D., *Chairman.*

ARSENICAL PIGMENTATION AND KERATOSIS. Presented by DR. HOWARD FOX.

The patient, J. J., was a man, 22 years of age, born in France, and employed in a lace factory. He was said to have suffered from scarlet fever, followed by nephritis, as a child. Eighteen months ago a general eruption appeared upon the face, trunk and extremities, the greater part of which cleared up at the end of about six weeks. He then consulted a physician who prescribed Fowler's solution in doses of five drops, three times a day. The patient, however, on his own initiative, took ten drops three times a day and continued this without interruption for a year. After he had taken arsenic for three or four months, the keratoses of the hands began to develop. He did not remember when the pigmentation first appeared. In spite of arsenic and other treatment he continued to suffer at intervals from attacks similar to the first one. These consisted of crops of erythematous spots upon some of which vesicles developed (according to the patient's statement and that of Dr. Morrisey, of Hartford, who had recently observed the eruption). The lesions were very itchy and never entirely disappeared; a diagnosis of probable dermatitis herpetiformis was made. At the time of presentation, the patient showed a few pea sized, erythematous spots and punctate excoriations, particularly on the face and interscapular region. He was presented to show the effects of prolonged ingestion of arsenic, namely, pigmentation and keratoses. The pigmentation, which was reticulated in character, was most marked upon the abdomen and about the axillæ, extending slightly upon the arms. The entire palmar surfaces of both hands and fingers showed a diffuse, horny thickening, upon which were scattered acuminate, horny elevations, the size of pin heads.

CASE FOR DIAGNOSIS. Presented by DR. BECHET.

L. C., aged 30 years, first noticed the appearance of the tumors on the face, three years ago. Within a comparatively short time the skin of the trunk and arms became involved. The tumors at first slowly increased in size and number, but in the past year the increase had been very rapid. He presented for examination a large number of tumors, most numerous on the face, particularly the chin, and on the arms. They varied much in size, the largest being filbert-sized. They were firm and hard on palpation, were freely movable and painless. A number of them were of a saffron-yellow color, particularly the more recent lesions. As they underwent involution, they left a deeply colored teleangiectatic area, with a tendency to increased pigmentation. Dr. Heimann kindly examined sections of one of the tumors and will report upon it.

DISCUSSION.

DR. OULMANN said that he had seen the patient four years ago, and that he had then had xanthoma planum of the eyelids and lesions on the face and body similar to those found on presentation. Some of the lesions upon involuting left depressed scars or atrophies. He considered the case one of xanthoma multiplex elevatum et planum, under which title he had presented it before the Manhattan Dermatological Society. A microscopic examination of the lesions about the eyelids showed the structure of xanthoma planum, while those on the body were not xanthomata, microscopically.

DR. HEIMANN said that he had examined a specimen sent him by Dr. Bechet, and had found it to be fibroma.

DR. POLLITZER said that he found the case difficult to understand, but that he conceived it to be primarily teleangiectatic rather than hæmorrhagic, and that deposits of fibroblasts developed about the dilated vessels. He suggested that a study of early rather than mature lesions, would explain the condition.

CASE FOR DIAGNOSIS. Presented by DR. TRIMBLE.

The patient, a young girl of 8 years, had a peculiar crusted lesion on the cheek, with some infiltration. The glands at the angle of the jaw were swollen and tender. The lesion had existed for three months, coming on after a slight scratch which rubbed off the epidermis. The lesion, with the glandular enlargement, resembled an initial lesion of lues, and was tentatively so regarded. Three careful examinations for spirochætæ were negative, as was also the Wassermann reaction. Some scales were removed for examination, but nothing was found. Cultures were being made.

DISCUSSION.

DR. MACKEE said that the case appeared to him to be either favus or tuberculosis verrucosa cutis.

DR. FOX agreed with Dr. MacKee.

DR. OULMANN said that the case was probably one of favus, for he had seen enlarged glands in favus but never in tuberculosis verrucosa cutis.

CASE FOR DIAGNOSIS. Presented by DR. TRIMBLE.

The patient was a man, 36 years of age. He showed on the inside of the lower lip an area of slightly granular appearance with fairly well defined borders. For the past six months, following an attack of "hoarseness," he had had recurrences of swellings of the lips, cheeks, gums and palate, lasting for a day or less and followed by the appearance presented. The Wassermann examination was negative, as was the luetic history.

DISCUSSION.

DR. SATENSTEIN said that he had seen the patient a year ago with a condition similar to, but worse than the one presented. His tongue, mouth and lips were swollen, and the lips were scaling. The saliva was acid and a gastrointestinal derangement was diagnosticated. After dental care and alkaline mouth washes, the disease subsided.

In addition to the above cases, the following also were presented:

Dr. Trimble presented two cases of dermatitis herpetiformis, one of Recklinghausen's disease, one of sarcoma hæmorrhagicum and one of lupus vulgaris with epithelioma.

Dr. Parounagian presented a case of syphilis palmaris et plantaris and one of alopecia universalis.

Dr. Howard Fox presented a case of Darier's disease and Dr. Williams one of bromoderma tuberosum.

Drs. MacKee and Wise presented a casė of dystrophy of the nails, one of hydroa æstivale, one of dermatitis exfoliativa, one of dermatitis bullosa and a case of parapsoriasis en plaques.

Drs. Goldenberg and Chargin presented a case of granuloma annulare.

DERMATITIS HERPETIFORMIS IN LYMPHATIC LEUKÆMIA. Presented by Dr. Parounagian.

The patient, Mrs. F. T., aged 52 years, married, was born in Hungary. Her skin affection began about fifteen months ago and the glandular enlargements throughout the body about ten months ago. The skin lesions were multiform and consisted of papules, vesicles, urticarial wheals, etc., and were extremely itchy. At the time of the presentation, the extremities were the most involved; as she was under treatment, her skin condition became markedly improved. She presented a typical picture of Duhring's disease, and while some of the lesions were receding, newer ones were appearing.

The enormous glandular swellings were thought to be due to Hodgkin's disease, though the blood picture was that of a true lymphatic leukæmia.

Discussion.

Dr. Heimann said that he had seen the case three months before, in a ward at the German Hospital. The patient's arms and legs had been studded with papules, vesicles and wheals, and transition forms from wheals to papules. The papules felt hard and resembled spherical, shotty infiltrations in the skin, suggesting a condition he had seen in leukæmia. The white cell count was 60,000, 80% of which were leucocytes; the structure of an extirpated gland, and of an excised papule, confirmed these findings. He said that the papule was made up of a dense infiltration of lymphocytes in the corium and papillary body and resembled only leukæmia, lymphosarcoma, round-celled sarcoma, or mycosis fungoides, but that together with the blood picture and general examination, he considered it a leukæmic infiltration. He said that the patient had had general glandular enlargements and a markedly enlarged spleen.

Dr. Lapowski said that he considered the case one which clinically was dermatitis herpetiformis, and that if it were due to leukæmia, it ought to be regarded as a leukæmia cutis of the dermatitis herpetiformis type. He asked whether Dr. Heimann thought it possible to have recognized the lesions as due to leukæmia without the general findings in the patient, and without the blood count.

Dr. Heimann said that he thought it possible to recognize these cases clinically.

Dr. Parounagian in closing the discussion stated that he regarded the skin condition as a typical case of Duhring's disease and believed the existence of the lymphatic leukæmia a mere coincidence. However, as the case had been in the German Hospital and Dr. Heimann had studied the lesions microscopically, he was glad to learn that leukæmia could produce skin lesions simulating dermatitis herpetiformis.

CASE FOR DIAGNOSIS. BROMODERMA? Presented by Dr. Clark.

Miss F., aged 50 years, in August, 1911, noticed that "something like a blister" formed upon the right calf. It opened and discharged repeatedly. After a month it healed. In June, 1912, it broke out again, opening and discharging and finally flaking off "like the skin of a burn." It never definitely healed after this, presenting a dusky lesion with a red areola, shot with small vesicles. Later the whole lesion seemed pitted with minute abscesses. It gradually spread until it had reached five inches in one diameter and four in the other. It advanced by the development of vesicles and pustules at the periphery, and also relapsed in the ground already covered. It became boggy all over and exuded pus from a large number of small orifices; then it became crusted and after the prolonged application of a bland ointment, it settled down into a brownish patch, exquisitely painful, slightly elevated, and steadily encroaching peripherally. The Wassermann and luetin reactions were negative. Twelve injections of mercury were ineffective. Mouth medication along the same lines had been fruitless. On November 2nd, 1915, a pathological examination was made and reported. The patient has been using "bromo-seltzer" in varying amounts, for years, to relieve headache.

Discussion.

Dr. Clark said that microscopically the disease was a granuloma containing gram-positive diplococci, and that cultures were being made from sections of the ulcer.

Dr. Aitkin said that he thought the case was one of bromoderma tuberosum because the patient had been taking "bromo-seltzer" for ten years and that the dark red color, the location, the duration, the fungoid periphery and the scarred central points of old ulcerations, favored this diagnosis.

Dr. Trimble said that he thought the case was one of bromoderma, although he did not consider it a typical one. The edge resembled bromoderma, but the solitary lesion, peripheral extension, and absence of crusting were against this diagnosis. The lesions of bromoderma were usually multiple, warty, and did not extend serpiginously.

Dr. MacKee agreed with Dr. Aitken, and would call the case one of serpiginous bromoderma. He had seen two or three instances of this particular type. One was on the forehead and the other two were on the leg. They were all unilateral, somewhat painful, active at the margin, and healed in the centre. The speaker said that he had had two cases of bromide acne due to the ingestion of "bromo-seltzer."

Dr. Aitken said that a teaspoonful of "bromo-seltzer" contained seven and a half grains of bromides, according to an analysis made in the laboratory of the American Medical Association.

Dr. Clark said that he thought the case one of bromoderma.

BALD RINGWORM. Presented by Drs. MacKee and Wise.

The patient, a girl of twelve years, was from Dr. Fordyce's Clinic. Three other children in the same family had ringworm of the scalp. The patient's hair began to fall out in patches one year ago, leaving silver-dollar-sized, bald areas. When presented before the Section, there were several bald areas which showed no sign of inflammation, no redness nor scaliness. Some of the areas presented black dots which either represented broken hairs or new hairs grow-

ing in. Around the margins of some of the lesions there were a few short hairs. Examination of these hairs revealed small spores and mycelia. The case bore a striking resemblance to alopecia areata.

Discussion.

Dr. Lapowski said that the case looked like alopecia areata, and that the French had described cases of infectious pélade, of which this one might be an example.

CASE FOR DIAGNOSIS. Presented by Dr. Williams.

Mrs. B. B., about 70 years old. There was no previous skin disease and no skin disease in the family. The patient first noticed, about twelve to fourteen years ago, roughness, scaliness and itching around the insteps, ankles and popliteal spaces. There was no exudation and no pain. The condition was then diagnosed as eczema by a competent dermatologist. The disease spread gradually over the greater part of both feet and legs, and to a less extent the lower part of the thighs. The itching had always been severe, and had led to much scratching. There had been little or no exudation until the past two months, but recently it had been considerable. The patient showed dry, rough, grouped papules just above the knees, each about one-fourth of an inch in diameter. Similar but larger papules occurred on the legs, running together to form hypertrophic patches. Under the right knee there was a patch about two by three inches, showing much thickening and white cross-hatching. On the legs, outside the thickened areas, were many small papulo-vesicles.

Discussion.

Dr. Williams said that he thought the case one of lichen planus.

Dr. Trimble said that he considered the case to be vegetating dermatitis or infiltrated eczema, but that the violaceous color supported the diagnosis of lichen planus.

Dr. MacKee agreed with this diagnosis.

Dr. Heimann said that the case could not be dismissed so summarily, but that several possibilities were to be considered. He said that in the first place its origin in the popliteal space suggested lichen chronicus simplex, which extended downward, involving the legs, and that there was one patch on the left thigh strongly supporting this view; in the second place that it might be a chronic eczema; and in the third a lichen planus, a possibility suggested by some of the papules, but which, on general clinical grounds, could be excluded. He said that if it was lichen simplex it was secondarily eczematized through scratching, a condition often encountered, and through the presence of varicose veins; if it was eczema, it was a lichenified type. He suggested wet dressings to start the treatment to allay the iritation, followed by other irritative or sedative treatment, as indicated.

Dr. Lapowski said that the case appeared to be one of parasitic eczema, not in the sense that a definite parasite was present, but according to the old usage of the term, and not a lichen simplex. He said that the spot in the popliteal space was the site of origin. He disagreed with the treatment outlined by the previous speaker, in so far as to suggest reinforced Lassar's paste (66% of inert powder, instead of 50%) rather than wet dressings, which he thought would be harmful.

Dr. Clark said that the shiny, polygonal, umbilicated papules just above the knee were diagnostic of lichen planus.

Dr. Trimble said that he thought the case more likely to be one of chronic eczema with an acute exacerbation. He said that the weeping was against the diagnosis of either lichen chronicus or lichen planus.

Dr. Williams said that there were evidently two processes going on in this case, and that the oozing could be explained by the dermatitis superimposed before the chronic process, which he regarded as lichen planus. He said that a histological examination would probably clear up the diagnosis.

The following cases also were exhibited.

Dr. Pollitzer presented a case of ulcerating and cicatrized gummata of the face, resembling tuberculosis.

Dr. Heimann presented a case of vitiligo.

Dr. Bechet presented an unusual type of alopecia and a case of multiple chancres.

Drs. Howard Fox and Ochs presented a case of erythema multiforme (?), and one of von Recklinghausen's disease.

Dr. Trimble presented a case of multiple sebaceous cysts.

Dr. Orleman-Robinson presented a case of lichen planus in a Mulatto.

Dr. Lapowski presented a case of generalized scleroderma.

MANHATTAN DERMATOLOGICAL SOCIETY.

Regular Meeting, Oct. 8, 1915.

George M. MacKee, M.D., *Chairman.*

PRURIGO NODULARIS. Presented by Dr. George Henry Fox.

The patient, a female adult of about forty-five years, a deaf mute, had had an eruption of extremely itchy nodules for ten years. It was very hard to get a definite history of the case. In many cases which had been reported as urticaria perstans, etc., and characterized by the formation of nodules, the itching or rather the scratching evoked by it, seemed to have been the cause of the nodules, but in prurigo nodularis the nodules developed upon a healthy portion of the skin and caused the intense itching. They usually persisted indefinitely but in this patient lesions upon the cheek had apparently disappeared and there was simply a little pigmentation left. They occurred singly or grouped, forming small, rough patches, somewhat like hypertrophic lichen planus. The patient appeared to be in good health and the lesions were confined to the arms and face.

This case was quite similar to one shown by Dr. Zeisler, a few years ago, at a meeting of the American Dermatological Association. There had been no blood examination made and Dr. Fox said he would make a further report later.

Discussion.

Dr. Wise agreed with the diagnosis of prurigo nodularis, and said that Dr. Williams showed a case at the Academy last year, analogous to this one, only that there were a great many more lesions and the diagnosis was accepted as prurigo nodularis.

Dr. Oulmann said that White showed a case of this kind at the International Congress held in this city. These cases were described as granulosis cutis, and resembled prurigo nodularis; as a result of the intense itching and scratching, verrucous tumors developed in the skin.

Dr. Satenstein suggested leukæmia cutis because of the intense itching and the color of the nodules. A similar condition, in a patient in the German Hospital, proved upon further examination to be true leukæmia.

ALOPECIA UNIVERSALIS. Presented by Dr. Parounagian.

The patient, a little boy, from the Dermatological Department of the Post Graduate Hospital, was eleven years old, born in the United States. His affection had begun five years previously, in the form of ordinary alopecia areata, hairs falling out in patches and returning. Finally all the hairs had disappeared. The patient had a box-shaped head and sunken nose and was mentally deficient, suggesting hereditary lues. The Wassermann test had been doubtful.

FOR DIAGNOSIS. TRICHO-EPITHELIOMA? LUPUS ERYTHEMATOSUS? Presented by Dr. Gottheil.

The patient was a male adult, aged thirty years. Two years previously a bald spot appeared on the left side of his head, and the skin of the affected area had become red; it gradually extended until it had reached its then present size. On the right side of his scalp, from the hair line in front to behind the ear and up almost to the vertex was a deep red, oozing and moist, entirely hairless area; the skin covering it was swollen and œdematous, but smooth. At the margins of the patch, which measured some five by six inches, the long scalp hair began abruptly; and the skin around it was covered with seborrhœal scales. There was no atrophy or scar tissue. The patient had had X-ray treatment; but it had been used after the disease had appeared and the patch had reached a considerable size. A microscopic examination at the City Hospital laboratory showed a proliferation of the epithelium beginning in the hair sheaths, a tricho-epithelioma; but the clinical picture did not at all correspond with a diagnosis of that kind. Radiodermatitis, which had been the speaker's first diagnosis, could be excluded from the history. There remained lupus erythematosus of some very acute and unusual type, and possibly a chronic seborrhœal eczema. Further microscopic study alone could resolve the diagnosis.*

Discussion.

Dr. Wise believed that one had to bear in mind the possibility of an isolated lesion of mycosis fungoides in this case.

Dr. Oulmann said he was against calling this a case of mycosis fungoides; the isolated patch on the scalp was neither pruritic nor scaly when he first examined the patient, and beside the loss of hair in this region there was a bluish-red and œdematous infiltration of the patch. He sent the patient to the City Hospital for further observation, where a microscopical diagnosis of epithelioma was made. The speaker did not look upon the lesion as one of tricho-epithelioma.

* Further histological study resulted in a diagnosis of mycosis fungoides.

LUPUS VULGARIS. Presented by Dr. Gottheil.

The patient, a negro boy, had been presented before the Society twice previously, during the past two or three years, under the designation of lupus hypertrophicus. The hypertrophic element had receded; the large tuberous masses which occupied the alæ nasi and the lips had retrogressed; the nose and lips were flattened out in a more or less cicatricial condition. But the disease had advanced steadily at its margins, and occupied almost the entire area of the face, including the lower eyelids, the malar prominences and the chin. Treatment of the most varied kinds had failed to influence the condition favorably. He had had at least forty tuberculin injections in increasing doses; every once in a while he would get a severe febrile reaction which would confine him to bed and necessitate a temporary discontinuance of treatment. Local destructive measures of the individual nodules had been persistently employed, without much result. At the time of presentation the advancing margins on the right side of his face were being treated with the Finsen-Reyn lamp; there was apparently some improvement as compared with the left side, but it was not marked. The daily applications of the lamp had to be discontinued from time to time, on account of the supervention of inflammatory reactions. In spite of two years of persistent hospital treatment there had been a steady progression of the disease.

PURPURA OF SEVERAL YEARS' DURATION. Presented by Dr. Parounagian.

The patient was a male adult, aged fifty-one years, born in the United States, watchman by occupation. His skin affection appeared around both ankles about four years ago, in the form of a reddish discoloration, which gradually increased and since about two years had extended to the umbilicus and the upper extremities, up to the shoulders and part of the scapular regions.

The lesions consisted of large patches of discolorations, purplish-red with a brownish tinge, with a few islands of healthy skin interspersed. He had no subjective symptoms, excepting an occasional rheumatic pain in his elbows and knees. The lower extremities were slightly scaly. He did not use alcohol at all but smoked excessively. The Wassermann test had been negative and he would not permit a biopsy.

Discussion.

Dr. Oulmann thought there was not so much purpura present as a new formation of capillaries and it seemed to him to belong to the angioma group.

Dr. MacKee said that the case was one of generalized teleangiectasia with capillary thrombosis, rather than purpura. It was pretty well established, the speaker said, that both tuberculosis and syphilis, especially the latter, could produce a generalized teleangiectasia. Stokes, working in Wile's clinic, besides reviewing the literature on the subject, had reported a case of generalized teleangiectasia in a hereditary syphilitic. Histologically he found a panarteritis with an infiltration of plasma cells and lymphocytes. He concluded, therefore, that the affection was a syphilitic capillary arteriosclerosis.

Dr. Parounagian stated that when he first saw the case, he considered the possibility of mycosis fungoides from the general appearance of the lesions, though the absence of itching ruled it out. The symmetry and the color of the lesions induced him to make the diagnosis of purpura. Crocker cited a case of several years' duration in his text book.

MONILETHRIX. Presented by Dr. Rosen.

The patient, Helen B., twelve years old, was born in this city. The family history was negative. The condition dated since infancy. She never had much hair as a child and what hair was present was short and coarse.

On inspection, one was immediately attracted by the peculiar moth-eaten appearance of the scalp and its color, which was mouse gray. There were three types of hairs, first, the short lanugo, second, the short coarse, and third, the long coarse. The hair was without lustre. Placed under the low power of the microscope, one saw the beading which was typical of this disease in the short hairs. Keratosis pilaris was a concomitant feature of all cases of monilethrix.

Discussion.

Dr. Oulmann said that he had obtained very good result with X-ray treatment in this condition. It was very interesting to him to see the large number of sweat glands in the upper region of the cutis, next to the hair, in the specimen of the scalp presented by Dr. Rosen, as he did not remember having seen such a picture before.

Dr. Rosen said that the scalp changes that this case presented obtained in all cases of monilethrix; that is, a keratosis pilaris and a marked diminution of the fatty layer, giving the scalp a tight feeling.

ERYTHRODERMIA CONGENITALE ICHTHYOSIFORME. Presented by Dr. Rosen.

The patient, Ethel M., was fourteen years of age, born in New York City. Both parents were dead. The father died of an accident and the mother died of some unknown disease.

The condition dated since infancy and at that time her skin was red and much coarser than that of the ordinary baby, and as she grew older there was a great deal of scaling. As the years passed the skin became very much coarser and the ichthyosis more pronounced and when she presented herself at the Vanderbilt Clinic the following was found:

The scalp showed an abundant growth of hair and no abnormal condition. The face presented a mottled condition, erythrodermia, interspersed here and there with normal skin. The skin was slightly thicker than normal. On the neck there was a marked erythrodermia and beginning ichthyosis. The normal skin markings were very much exaggerated. The chest, abdomen, back and upper extremities showed a very marked ichthyosis and on removal of some of the hyperkeratotic epidermis, one saw a base of erythrodermia. On the lower extremities the ichthyosis was most marked, so much so that the surface of the skin looked like the surface markings of a cauliflower.

The patient was receiving X-ray treatment, the result at first being very gratifying, but just as soon as the treatment was discontinued, the ichthyosis returned to its original condition.

Discussion.

Dr. Wise said it was interesting to note that this girl was under treatment at the Skin and Cancer Hospital eleven years ago, when the patient showed this condition only in the arm pits; it was then believed to be a case of acanthosis nigricans.

Dr. Bechet said he saw the case five years previously at the Skin and Cancer Hospital. The lesions apparently had greatly increased.

Dr. Howard Fox agreed with the diagnosis of congenital ichthyosiform erythrodermia and mentioned that the patient had been presented a number of times before other societies, being shown first eight or nine years before. The diagnosis of acanthosis nigricans, which had been previously made, could be absolutely excluded from the fact that more or less of the lesions could be removed by soap and water. The case had been thoroughly discussed in The Journal at the time, by Dr. Pollitzer, who described the disease.

Dr. MacKee said that the histological changes, while simulating ichthyosis, nevertheless differed quite considerably from that affection. There was a marked and pure hyperkeratosis. The epidermis was thrown into folds. There was very little alteration in the histology of the epidermis. The papillæ were markedly elongated. There was some dilation of the superficial vessels, but practically no evidence of inflammation. The sebaceous glands were well developed, numerous and normal in appearance. The sweat glands were numerous but showed both fatty and hyaline degeneration. Clinically, the disease affected locations always exempt in ichthyosis.

LEUCODERMA SYPHILITICUM. Presented by Dr. Gottheil.

The patient, a female, aged sixteen years, had an initial lesion on the vulva two months previously; there was a papular syphiloderma of the trunk and limbs at the time of presentation, and an extensive and well marked leucoderma of the neck and upper chest and back. The patient was quite positive that the white spots appeared at the same time as the red papules on the lower trunk and limbs; and she was equally certain that there was no eruption on the neck and upper trunk before they had appeared. This latter statement was corroborated by the fact that there was not a single ordinary papule, or the remains of one, on the regions occupied by the leucodermic areas, and these latter were larger, more numerous and more confluent than roseolous eruptions were.

Discussion.

Dr. Parounagian said he did not agree with the opinion that this condition preceded the roseola, as all the cases of this nature which he had observed were preceded by a macular eruption.

Dr. Gottheil said that once at least, in his experience, he had seen a leucoderma developing in a patient suffering from secondary syphilis. The patient, as was usually the case, was a woman; she had other signs of secondary syphilis, though he did not remember just what they were. The leucoderma developed while she was under observation in the City Hospital.*

GENERAL MACULAR AND STRIATED ATROPHY WITH TELEANGIECTASES OF THE SKIN, ASSOCIATED WITH INFANTILISM AND IMPERFECT DEVELOPMENT OF THE BONES. Presented by Dr. Gottheil.

This patient was a female, sixteen years of age, who entered the City Hospital on account of the masses of acuminate condylomata present on the left side

* Addendum, two weeks later: The leucodermic spots had undoubtedly increased in size since the patient was shown to the Society; they were just as marked as ever, though her other symptoms had retrogressed under treatment.

of her lower lip. Mentally she was approximately normal; but her physical development, her size, weight and figure were those of a child of ten years or less. There was absolutely no mammary development and her hips and shoulders were those of a young child. Though her face was small, her lower jaw was so much smaller than her upper one that it imparted a peculiar appearance to her face, especially in profile. Her feet presented peculiar congenital deformities; in one, the great and second toes were fused together and in the other the third digit was apparently missing. The X-ray plate showed that in the one foot the digits were perfect and distinct, the soft parts only being united; and in the other the third phalanx was rudimentary.

The skin condition, however, was the point that interested the speaker. Its entire surface was covered with atrophic lesions, in some places macular and in others linear and striated, more especially on the limbs. No part of her body was free from these atrophies; they were present even on the face. On her neck they were especially abundant and prominent; it looked as if she had had a severe small pox in early life. She was positive, however, that she had always had these marks; and she had been told that she was born with them, and that they had not been occasioned by any disease. The linear atrophies, some of which on the arms were two inches in length by a quarter of an inch in breadth, were sufficient to confirm her statement. Scattered all over her body, but especially marked on her palms and soles and the inner side of her wrists, were superficial teleangiectases, appearing as congeries of small red vessels. Her hair development, though sparse, was not abnormal. Her Wassermann reaction was negative. The exhibitor thought that this was the most extensive case of macular and striated atrophy of the skin that he had ever encountered.

Discussion.

Dr. Oulmann said that this case had not only annular atrophies, but also longitudinal striæ along the arms. He therefore did not regard it as a case of atrophia cutis maculosa, but as one of anetodermia, as Oppenheim described the condition.

DERMATITIS HERPETIFORMIS. Presented by Dr. Brechet.

This patient, an adult female, from the service of Dr. Trimble at the Skin and Cancer Hospital, had had dermatitis herpetiformis for two years. The eruption had always been very extensive and the pruritus excessive. Two intravenous injections of thirty cc. of autogenous serum, a week apart, were administered. The last injection was given on the day of presentation. The patient stated that the pruritus had disappeared. There seemed some slight objective evidence of improvement. The case was presented in order to bring out some discussion on the use of autogenous serum in bullous diseases, particularly dermatitis herpetiformis.

Discussion.

Dr. George Henry Fox said that in the treatment by autogenous serum the pendulum of professional approval appeared to have swung as it did years ago in the case of tuberculin, which was at first overpraised, then utterly condemned and finally estimated at its proper value. From what he had seen in his own practice and in that of others and from what he had read, he felt certain that brilliant results had been produced in some cases of dermatitis herpetiformis. In some cases of obstinate psoriasis he had seen good, even if not permanent results, which were evidently due directly to the autoserum treatment and

which could not have been obtained by any other treatment with which he was familiar. He did not claim that it was a wonderful remedy or that it would cure all cases, but it was certainly a remedy of value and would help in curing some very obstinate cases. The point to be determined was just what class of cases was likely to be benefited and why. Dr. Fox said he wished he could settle that.

Dr. Oulmann said that in his experience autogenous serum had a very good result on the symptoms, but not on the disease itself.

Dr. Satenstein said he had treated with autogenous serum the case of erythema multiforme perstans presented by Dr. Robinson at the American Dermatological Association in May, in a boy, twelve years of age. The lesions at that time had been present nine months. Nine injections were given; after the first the subjective symptoms ceased. The eruption on the face disappeared after the second injection and after each subsequent injection there was a diminution in the lesions of the body and extremities. After nine injections all the lesions disappeared and he received his last injection on August 24th. He showed up again on October 5th, with a few spots on his leg. On October 16th, the lesion had entirely disappeared.

Dr. Gottheil said he had had no opportunity of employing the autoserum in dermatitis herpetiformis; his experience of it in bullous affections had been limited to pemphigus, of which he had treated five cases in this manner. In two instances it improved the patient's condition temporarily only; in the others it had no effect and all the patients died. All the cases, however, were desperate ones, even when the treatment was first used.

Dr. Mount said he had employed the method in one case of the vesicular and bullous type of erythema multiforme. There was neither amelioration of the itching nor disappearance of a single lesion.

Dr. Howard Fox said that at the last meeting of the American Dermatological Association there seemed to be a unanimity of opinion that injections of autogenous serum were of benefit in dermatitis herpetiformis. In his cases the best results had been obtained by heterogeneous serum and blood, especially in one very extensive and severe case of the bullous type. This patient, who was an old woman of eighty years, was treated with two injections of autogenous serum without much benefit. She was then given injections of heterogeneous serum and blood obtained from two other healthy individuals. After the ninth injection she recovered entirely and had remained well to date. Most of the serum and all of the blood injections were given intramuscularly. The injections of blood were somewhat painful at times.

Dr. MacKee said that at Dr. Fordyce's Clinic, where considerable work had been done with autoserum, the results had not been particularly encouraging. There had been apparent improvement in a number of chronic vesicular and bullous eruptions, but the speaker was not convinced but that the improvement had been spontaneous.

Dr. Bechet said this woman complained of an almost constant itching. She stated to him that day that the pruritus had practically disappeared.

MORPHŒA. Presented by Dr. Weiss.

The morphœa lesions of this patient, a female, twenty years of age, had extended since her presentation before the Society in May. The band-like, hard, elevated violaceous skin infiltration extended from the root of the nose diagonally over the right side of the forehead and had reached the middle of the scalp.

The speaker had administered small doses of thyroid extract, once a day, and while the morphœa did not disappear, it did not progress. He lost track

of the patient, as she had not attended the clinic for four months. He thought that if the thyroid treatment had been kept up, the morphœa would not have extended. As the patient showed several symptoms of thyroid insufficiency, heavy eyelids, dry skin, increase of weight, slow pulse, dizziness, etc., and had never as yet menstruated, Dr. Weiss would continue the thyroid treatment systematically, with an expectation of a favorable result.

LUPUS ERYTHEMATOSUS. Presented by Drs. MacKee and Wise.

The patient, J. W., from Dr. Fordyce's clinic, was twenty-eight years of age, single. Her trouble began two years ago. She had lesions of lupus erythematosus of the diffuse, disseminated type on the face and arms, and showed a marked improvement from X-ray treatment, administered in massive doses. When she first came under observation her skin was inflamed and œdematous, but the lesions had become flattened, paler, smoother and free of scales. The patient also suffered with arthritis deformans.

SCLERODERMA WITH UNUSUAL PIGMENTATION. Presented by Drs. MacKee and Wise.

The patient, M. S., from Dr. Fordyce's Clinic, was twenty-five years of age and married. She had an eruption of almost the entire skin which began two years ago. It began with the formation of indurated patches, resulting in a hide-bound skin. Some patches on the neck showed involution. The patient stated that her skin on the neck was hard and infiltrated at first and that the infiltration had been receding since the last two years, leaving the pigmentation. On the right foot she had a distinct band of scleroderma. There was a mild amount of terminal atrophy in certain areas on the neck and chest, where the condition was most marked.

MYCOSIS FUNGOIDES. Presented by Drs. Rosen.

This patient came under the observation of Dr. Wise and the speaker about the beginning of September, 1915, with the following history:

Sophie W., married, thirty years of age, was born in the southern part of Russia and located in Montreal about five years ago. Up to sixteen months previously she had been perfectly well, when this condition began, with intense itching on the inner surface of the left arm. On investigation she noticed a patch about two by three inches in size. The itching was so intense that it kept her awake at night. About two months later similar lesions made their appearance over the chest, back, abdomen, flanks and extremities.

The lesions varied in size from a split pea to large plaques, about three by four inches in size: the color also varied: some were brownish-red and others light brown, some showed a very fine scaling and there was very little infiltration, if any, present. One plaque in the inter-scapular region showed a moderate infiltration. A portion of this patch was removed for pathological study, and a further report of the case was in preparation.

PARAPSORIASIS IN PATCHES. Presented by Dr. Weiss.

The patient, a female adult, had been sent to the speaker that morning for diagnosis. The duration of the disease had been three years. There had been very little itching. It started over the whole body at once as well defined, large plaques of a pale red color, accompanied by slight scaling. It had never disappeared since its inception, three years previously.

PALMAR AND PLANTAR SYPHILODERM. Presented by Dr. Parounagian.

The patient was a female, twenty-one years of age, married. Infection took place about one year ago. She presented extensive papulo-squamous lesions on both palmar and plantar regions with a few scattered lesions on the body. Her throat was sore, there was marked adenopathy and a strongly positive Wassermann reaction.

TINEA TONSURANS SHOWING PECULIAR EFFECT OF X-RAY TREATMENT. Presented by Drs. MacKee and Wise.

In presenting this case Dr. Mackee said that he desired to call attention to some peculiar results of the disease and its treatment, observed at Dr. Fordyce's Clinic.

It was quite often noticed, for instance, a few hours after complete depilation exposure by the Adamson-Kienböck method, that the children were indisposed, slightly feverish and complained of nausea. These symptoms soon disappeared.

Sometimes, about a week or ten days after the treatment, the areas of disease would become markedly inflamed and painful, but then would disappear in a few days and it did not interfere with the growth of hair.

It had been noticed, on several occasions, where areas had been twice depilated, on account of a recurrence, that the hair returned sooner and grew more vigorously in areas that had been twice depilated than in areas only receiving one treatment. The treatments, of course, were never repeated until after the hair had regrown—from three to six months.

The patient exhibited had had a disseminated ringworm of the scalp. Complete depilation of the entire scalp was affected by the X-ray, in accordance with the Adamson-Kienböck method. When presented, two months after the treatment, the hair was regrowing all over the scalp, but the growth was far more vigorous in areas that had not been attacked by the affection. The speaker said that sometimes the reverse was true—namely, that the regrowth of hair was more rapid in the areas previously occupied by the disease.

The patient was presented as a complete cure. Repeated examination of scales and hair had failed to reveal any evidence of the former disease.

PITYRIASIS ROSEA. Presented by Dr. Oulmann.

The patient, a male adult, showed the lesions of pityriasis rosea over the entire body. The face also was covered by lesions, consisting of rings with the "cigarette paper wrinkling" skin in the centre.

Discussion.

Dr. George Henry Fox said this was one of the most remarkable cases of pityriasis rosea that he had even seen. It was claimed by some that the eruption never appeared above the angle of the jaw. He recalled a well marked circle on the cheek in one case, but he had never seen the face covered by the lesions, as in this patient.

Dr. Parounagian stated that he also had presented a case of pityriasis rosea presented by Dr. Oulmann.

REVIEW

OF

DERMATOLOGY AND SYPHILIS.

Under the direction of

FRED WISE, M.D., New York,

Assisted by

WILLIAM H. BAUGHMAN, M.D., New York.
CLARENCE A. BAER, M.D., Milwaukee.
PAUL E. BECHET, M.D., New York.
G. A. CARLUCCI, M.D., New York.
LOUIS CHARGIN, M.D., New York.
J. S. EISENSTAEDT, M.D., Chicago.
CHARLES GOOSMANN, M.D., Cincinnati.
ROBERT C. JAMIESON, M.D., Detroit.
M. F. LAUTMAN, M.D., Hot Springs.
M. L. RAVITCH, M.D., Louisville.
ISADORE ROSEN, M.D., New York.
PHILIP F. SHAFFNER, M.D., Chicago.
MAX SCHEER, M.D., New York.
FRANK E. SIMPSON, M.D., Chicago.
A. W. STILLIANS, M.D., Chicago.
JOHN H. STOKES, M.D., Chicago.
HARVEY P. TOWLE, M.D., Boston.

DERMATOLOGISCHE WOCHENSCHRIFT.

(Oct. 9, 1915, lxi, No. 41.)

Abstracted by MAX SCHEER, M.D.

THE INFLAMMATORY AND URTICARIAL SKIN REACTION. A CLINICAL STUDY. F. SAMBERGER, p. 947, *Part ii.*

The inflammatory efflorescences are 1, macule; 2, papule; 3, vesicle; 4, pustule. The lymphatic efflorescences (caused by hypersecretion of lymph) are:

1. Acute œdema of the skin,
2. Urtica (wheal),
3. Urtica bullosa,
4. Bulla pemphigosa.

A hypersecretion of lymph into the pars reticularis cutis causes an urtica; when the secretion separates the rete cells of the epidermis, or the latter from the corium, an urticarial vesicle results; if the exudation affects the pars papillaris and the epidermis, there results a vesicle on a normal skin, without evidence of inflammatory or urticarial reaction; this lesion the author designates as the pemphigus vesicle.

Corresponding to these pathological changes are the following clinical forms: 1, Acute œdema of Quincke; 2, Urticaria; 3, Pemphigus.

The pathological distinction between urticaria and pemphigus is not in the nature of the reaction (both are lymphatic reactions) but in its location,—urticaria in the corium, pemphigus in the epidermis.

If this deduction is correct, there must exist a clinical relationship between these two, as well as a pathological one. It is well known that a pemphigus may begin as an urticaria or may simulate it for a long time. During the course of pemphigus urticarial eruptions occur. It may be impossible to differentiate urticaria pigmentosa from pemphigus unless the whole course of the disease is

taken into consideration. In the course of urticaria or of pemphigus the one eruption may substitute the other. Both eruptions arise suddenly and may assume various sizes and shapes.

When individual wheals last a short time, even when by occurrence of new wheals the process is considerably prolonged, the designation acute urticaria alone is permissible. The term chronic urticaria must only be applied to individual wheals lasting a long time, weeks or months. The duration of action of the ætiologic factor, the temporary or more prolonged hypersecretion of lymph, make the urticarial lesion acute or chronic.

The same classification of lesions into acute and chronic applies to pemphigus, except here the vesicles do not disappear when the ætiologic factors have ceased to act; the location of the process in the epidermis, for mechanical reasons, prevents its rapid absorption. From the appearance of the eruption no conclusions can be drawn concerning the acute and chronic nature of the process. Through soaking of the epithelial cells with lymph, a vesicle forms; the moistened epithelial cells separate by the slighest mechanical pressure, exposing a raw, denuded surface. The lesions may last a short while—pemphigus acuta; or they may recur over a longer time—pemphigus acuta recidivans. Only when Nikolsky's sign is present, when slight pressure on the skin causes a vesicle, in other words when there is a continuous hypersecretion of lymph into the skin, can we speak of pemphigus chronicus or perstans.

In spite of their anatomico-pathological similarities, the two diseases differ in prognosis; urticaria is benign, pemphigus grave. The secreted lymph is never lost in urticaria; it is always lost in pemphigus. The epithelium, softened by persistent lymphatic œdema, is exposed to irritation and injury, the skin becomes secondarily inflamed and no longer protects the organism as it should. In this way, pemphigus vegetans and pemphigus foliaceous arise.

Just as there are individual predispositions to inflammatory and to urticarial reactions, so they also exist for pemphigus reactions.

(*To be continued.*)

(*Ibidem*, Oct. 16, 1915, lxi, No. 42.)

CONTRIBUTIONS TO THE TREATMENT OF URTICARIA. (COMPRESSED TABLETS OF CALCIUM CHLORIDE). O. Seifert, p. 971.

The sedative effects of calcium salts in hay fever and in conditions of nervous irritability, e.g., tics, induced the author to try them in urticaria, especially in cases where the ætiological factors were obscure and where there were no gastrointestinal disturbances.

Compressed tablets of calcium chloride 0.1 each (made by E. Merck, Darmstadt) were administered hourly, until ten a day were taken. Four patients with urticaria and one with acute œdema of Quincke, in all of whom the ætiological factors were unknown, were thus treated. The results were prompt and gratifying. The tablets should be continued for about one week after the dis appearance of the eruption.

THE INFLAMMATORY AND ULTICARIAL SKIN REACTION. A CLINICAL STUDY. F. Samberger, p. 976. *Part ii* (*Continued*).

There are cases in which there is a coexistence, in varying degrees, of the inflammatory and the lymphatic reactions. The clinical picture does not always depend on the nature of the irritant, but may be influenced by the reactibility of the affected organism. A combination of the two reactions (inflammatory and lymphatic) is exemplified in erythema exudativum multiforme. From the ætiolo

gical standpoint, erythema exudativum multiforme may be divided into, 1, exudative infectious erythema and 2, exudative non-infectious erythema.

The exudative infectious erythemas can be subdivided into two well characterized clinical groups: (a) erythema exudativum (multiforme) of Hebra and (b) erythema exudativum nodosum.

Examples of non-infectious erythemas are erythema exudativum toxicum from various toxines, drugs or other substances. The author has seen a case of erythema exudativum multiforme solare.

Just as the urtica (wheal) is an efflorescence of the disease urticaria, so is erythema exudativum multiforme the skin manifestation of some underlying condition.

(*To be concluded.*)

(*Ibidem*, Oct. 23, 1915, lxi, No. 43).

CONCERNING CONTRA-LATERAL ALOPECIA AFTER GUNSHOT INJURIES OF THE HEAD. E. Klausner, p. 995.

The author observed four cases and has knowledge of four others, in which the alopecia could be definitely attributed to the X-ray. The alopecia in all of these patients began six weeks after the X-ray exposure; it was always on the side of the head exactly opposite the injury and in the line of the ray; the patches were never sharply defined; after a time there was always *restitutio ad integrum.*

The author attributes the three cases of alopecia reported by Knack in No. 34 of this Journal to the X-ray. In all of them the hair loss began from three to four weeks after the X-ray exposure.

THE INFLAMMATORY AND URTICARICAL SKIN REACTION. A CLINICAL STUDY. F. Samberger, p. 999. *Part ii* (*Conclusion.*)

The term erythema is a clinical conception. Pathologically it is due to 1, hyperæmia, dependent on stimulation of vaso-dilators (erythema congestivum), or to 2, the inflammatory reaction. Here the dilatation and filling of blood-vessels predominate over the exudation and infiltration (erythema inflammativum; or to 3, the combination of inflammatory and lymphatic reactions, erythema exudativum).

Erythema inflammativum are (a) infectious, e.g., due to typhoid fever, scarlet fever, etc.; or (b) non-infectious, due to injuries, burns, etc.

In this work the author has attempted to classify a large group of skin diseases, the so-called angineuroses of the skin, upon a pathological-anatomical basis. In this way he hopes to have approached the ideal of Hebra,—a more uniform conception of skin diseases, based on their pathology.

(*Ibidem*, Oct. 30, 1915, lxi, No. 44).

THE TRICHOPHYTIN REACTION IN THE BLOOD. G. Miescher, p. 1011

The deep forms of trichophytosis (kerion Celsi, sycosis trichophytica, folliculitis agminata) show at the height of the disease, a more or less well pronounced leucocytosis. The superficial forms do not influence the blood picture.

Characteristic of the specific trichophytin reaction is a polymorphonuclear leucocytosis, usually associated with an absolute diminution of lymphocytes. This reaction occurs after intradermal as well as after subcutaneous inoculation of trychoyphytin and is more pronounced when trichophytin from the deeper forms of ringworms is used.

Injections of trichophytin into normal individuals causes an absolute increase in the number of lymphocytes. The degree of the leucocytosis bears no relation to the local or the general reaction phenomena.

(*Ibidem*, Nov. 6, 1915, lxi, No. 45).

CONCERNING THE TECHNIQUE OF ADMINISTERING NEOSALVARSAN. CARL STERN, p. 1040.

The author believes that the method of administering neosalvarsan described by Schumacher (No. 39 of this JOURNAL) is neither rapid nor safe. Simple dilution of the neosalvarsan in water (which has previously been boiled) at body temperature, is convenient and certain. The drug is dissolved in 5 cc. of water and injected intravenously with a Record syringe. The author considers neosalvarsan to be just as efficacious as salvarsan.

PRESSE MÉDICALE.

(April 11, 1914, No. 29).

Abstracted by PAUL E. BECHET, M.D.

TUBERCULOSIS AND CANCER OF THE BACK OF THE HAND. LAPEYRE, p. 276.

Report of a case.

(*Ibidem*, Apr. 15, 1914, No. 30).

THE DIAGNOSIS OF THE ALOPECIAS IN CHILDREN. BURNIER, p. 286.

(*Ibidem*, June, 3, 1914, No. 44.)

WHEN, WHY AND HOW TO ADMINISTER COLLOIDAL SULPHUR. MARTINET, p. 422.

(*Ibidem*, July 18, 1914, No. 57).

A MODIFICATION OF THE TECHNIQUE IN THE INJECTION OF NEOSALVARSAN BY THE RAVAUT METHOD. LE DAMANY, p. 545.

(*Ibidem*, Jan. 21, 1915, No. 3.)

TREATMENT OF CHILBLAINS. COURCOUX, p. 19.

Courcoux has treated a large number of wounded for frostbites of the first and second degree. He uses a lotion composed of equal parts of glycerine and alcohol, with five per cent. formol; this is applied morning and night and allowed to dry on. It seems to harden the epidermis and prevent excoriations. The affected parts are elevated, and the patient instructed to exercise them gently.

CHILBLAINS AND GANGRÆNE FROM CONGELATION. IMBERT, p. 19.

Imbert believes that gangræne following congelation is due to the sudden application of heat to the frozen parts, and that the old treatment or friction with ice, snow, etc., as advanced by Larrey, Napoleon's famous surgeon, is still the correct one.

(*Ibidem*, Jan. 28, 1915, No. 4.)

TREATMENT OF GANGRÆNE WITH ARSENOBENZOL. LACAPÈRE AND LENORMENT, p. 25.

Lacapère and Lenorment found that arsenobenzol, intravenously administered, had a favorable influence on gangræne, and particularly so, in those caused by a fuso-spirillar association, such as exists in Vincent's angina.

(*Ibidem*, May, 13, 1915, No. 21.)

LEUCOPLAKIA OF THE INTERNAL SURFACE OF THE CHEEKS. LANDOUZY, p. 161.

Landouzy believes that syphilis is practically the only cause of leucoplakia, and that the presence of these lesions is almost pathognomonic of an antedating syphilis.

(*Ibidem*, May 20, 1915, No. 22.)

MYXŒDEMA AND LEPROSY. JÉRUSALEMY, p. 174.

Jérusalemy reports a case of myxœdema in a Chinaman, 16 years old. There were no leprous symptoms. A nasal examination showed an infiltration over the middle turbinate. Examination of the nasal mucous showed the presence of Hansen's bacillus. Thyroid therapy aggravated the symptoms; marked improvement followed the administration of chaulmoogra oil.

ANNALES DES MALADIES VÉNÉRIENNES.

(July, 1914, ix, No. 7.)

Abstracted by PAUL E. BECHET, M.D.

A NEW CAUSE OF DEATH FROM "606." DREYFUS, p. 481.

Dreyfus believes that deaths from salvarsan are frequently due to hepatic insufficiency. Salvarsan is not rapidly eliminated; it has been found in the liver as long as 100 days after three injections, given at intervals of four days. Urobilinuria, more or less intense, frequently follows injections of salvarsan. The author quotes a number of cases of icterus following its injection. He reports a fatal case occurring in a man, aged 38, of alcoholic habits and quite obese. There were evidences of liver enlargement, but he was otherwise healthy. Traces of urobilin were found in the urine; glucose, albumin and other pathological constituents were absent. Injection of dose No. 1, neosalvarsan, was followed by the presence of a large amount of urobilin in the urine and also traces of albumin. Convulsions, coma and death followed the second injection of 0.75 neosalvarsan. No autopsy was made.

NOTE ON THE USE OF ADRENALIN FOLLOWING INJECTIONS OF SALVARSAN. SCHWARZMAN, p. 503.

Schwarzman noticed that in a great majority of cases, a hypotension followed the injection of neosalvarsan. He believes that the blood pressure should be

taken before injecting the arsenical preparations, and should it prove insufficient, adrenalin is indicated.

EPITROCHLEAR ADENOPATHY IN SYPHILIS. LEVY-FRANCKEL, p. 508.

Levy-Franckel found that epitrochlear adenopathy was exceptional, outside of syphilis. In early secondary syphilis, the adenopathy is not as noticeable as in the late secondaries.

GAZETTE DES HÔPITAUX.

(July 14, 1914.)

Abstracted by PAUL E. BECHET, M.D.

SYPHILIS AND THE SUPRARENAL GLANDS. SEZARY, p. 1317.

(*Ibidem*, April 30, 1914.)

AUGMENTING THE EFFICACY AND TOLERANCE OF MERCURY IN SYPHILIS. BOUVEYRON, p. 824.

Bouveyron found that colloidal sulphur internally administered, quickly relieved symptoms of mercurialization and materially aided the tolerance for the drug. A tablespoonful of a liquor containing 20 centigrammes of colloidal sulphur was given twice daily with the principal meals.

(*Ibidem*, April 28, 1914.)

REPORT OF A CASE OF INVASION OF THE SCALP BY THE PEDICULUS PUBIS. BRAULT AND MONTPELLIER, p. 805.

(*Ibidem*, June 18, 1914.)

WHAT CLINICAL FORM OF SYPHILIS MOST FREQUENTLY ENDS IN GENERAL PARALYSIS? COLLIN, p. 1125.

Collin believes that syphilis may attack the nervous system primarily, with absence of other manifestations, and subsequently cause a generalized paralysis. This would explain the absence of secondary lesions in the clinical history of the majority of specific paralytics.

BRITISH JOURNAL OF DERMATOLOGY.

(Sept. 15, 1915, xxvii, No. 9.)

Abstracted by I ROSEN, M.D.

A CASE OF FOLLICULITIS DECALVANS ET LICHEN SPINULOSUS, WITH REPORT ON MICROSCOPICAL FINDINGS. WALLACE BEATTY AND JOHN SPEARE, p. 331.

(*Ibidem*, Oct. 15, 1915, xxvii, No. 10.)

A CASE OF ACUTE LUPUS ERYTHEMATOSUS. H. W. BARBER. p. 365.

The author reports a case in a female, 43 years of age, who had an extensive, scaly, erythematous eruption on the face, neck and ears, with intense œdema of the skin, the eyelids swollen and conjunctivæ injected, the scalp red and scaly. The hands were similarly affected with a scaly, erythematous eruption.

The patient had chills and fever, and was delirious at times. The temperature varied from 103° F. to 104½° F. for about twelve days, when it dropped by lysis, to about normal. As the temperature dropped, the patient's condition improved with amazing rapidity, and in a few days, her appearance had completely changed.

On admission, examination of the fæces showed a pure growth of Streptococcus longus. The author believes the patient's eruption was due to the continuous absorption of toxines, from an abnormal strain of streptococci in her intestine. The onset of pyæmia, chills and malaise, no doubt indicated the passage of these streptococci, or their toxines, into the general circulation.

FACIAL MORPHŒA. W. J. O'DONOVAN, p. 377.

The author's case completes a series to support Dr. Sequeira's hypothesis of a ganglionic neurotrophic origin of morphœa. In two cases previously reported by Dr. Sequeira, the territory of both the first and second divisions of the fifth cranial nerves was involved, and in the third case, while apparently missing the second division, it affected both the first and the third. This gives strength to the hypothesis that the underlying cause is not in the peripheral nerve, but in the Gasserian ganglion, where all these branches can be affected by some localising lesion, similar to that found in herpes zoster, or acute poliomyelitis.

(*Ibidem*, November, 1915, xxvii, No. 11.)

THE RELATIONS OF THE STAPHYLOCOCCUS ALBUS AND THE ACNE BACILLUS TO THE EPIDERMIS AND THE EXCRETIONS OF THE SKIN; WITH SPECIAL REFERENCE TO THE LESIONS OF ACNE VULGARIS. T. H. C. BENIANS. p. 393.

The author in his investigation seeks to make clear some of the many gaps in our knowledge of the precise ætiology of certain skin affections, and further, to provide indications for rational forms of treatment.

The summary of the conclusions drawn from his experimental work is as follows:

1. Keratinous tissues when exposed to the action of a growing culture of certain strains of Staphylococcus albus in broth, may become eroded and partially disintegrated. This disintegration is not due solely to the alkalinity of the medium.

2. The destructive action of keratin is not evident where olive oil is present in the medium; the medium then becomes acid in reaction, instead of alkaline.

3. The acne bacillus in pure culture does not effect this destruction of keratin, despite the fact that it produces a marked degree of alkalinity in the medium.

4. The acne bacillus splits up certain fats, with the liberation of fatty acids; which fatty acids in some cases melt at a considerably higher temperature than the original fat, or than the pure fatty acid of the same nature.

5. The acne bacillus when growing in contact with fat, produces in most cases, a definite brown coloration in the fat.

6. The Staphylococcus albus may exert an action on fat, similar to that resulting from the acne bacillus: in addition it forms soapy matter, and in some instances masses of gelatinous looking material.

7. The acne bacillus alone, and especially when growing in conjunction with staphylococcus in broth, produces a foul smelling substance, similar to that met with in some cases of bromidrosis. The production of this foulness is inhibited by the presence of fat and by the presence of glycerine in the medium. The foul products can be completely extracted by shaking up with ether. The ether extract, on evaporation, leaves a foul, slightly brown, oily material which slowly volatilises.

(To be continued.)

A SECOND CASE OF NORWEGIAN SCABIES. WALLACE BEATTY, p. 404.

The author reports a case of Norwegian scabies in a boy, 14 years of age. There were scales scattered over the entire body, but the hands and region of the nails were especially affected. There was a dense accumulation of scales or crusts under the fore part of most of the nails, separating them partly from their bed. Over the nail wall of some of the fingers was an accumulation of scales, forming a semi-circular ridge around the nail. The scales or crusts, treated with caustic potash solution, showed, under the microscope, acari in all stages, and of both sexes; also their eggs and empty shells.

A CASE OF EXOPTHALMIC GOITRE FOLLOWED BY ALOPECIA AREATA. C. E. JENKINS, p. 407.

HERPES ZOSTER WITH PARALYSIS OF ARM. F. PARKES WEBER, p. 408.

The author reports a case in a man, 64 years of age, who, while taking his regular afternoon nap, suffered a paralysis of his left upper extremity. One week later an eruption of typical herpes zoster made its appearance. The eruption involved the left side of the head and neck, the left clavicular region and shoulder, and the upper and front portion of the left side of the chest.

JOURNAL OF THE AMERICAN MEDICAL ASSOCIATION.

(Oct. 30, 1915, lxv, No. 18.)

Abstracted by WILLIAM H. BAUGHMAN, M.D.

INTRATHECAL INTRACRANIAL INJECTION OF AUTONEOSALVARSANIZED SERUM FOR SYPHILITIC HEADACHE. ALFRED GORDON, p. 1545.

Gordon reports a case which had, among other symptoms, intense pain in the entire cervical and upper dorsal regions but especially in the occipital region and over the vertex on the left side. The Wassermann test was strongly positive

in both the serum and the spinal fluid. Five intravenous injections of salvarsan produced no permanent effect on the headache. Seven intraspinal injections of autoneosalvarsanized serum, while followed by a disappearance of all the symptoms referable to the spinal cord, and an improvement in the pain in the neck, the severity of the headache remained unaltered. A decompression operation was performed over the left parietal region revealing a thickening of the skull and the presence of a number of small light gray patches on the membranes. The dura was not opened. The patient felt some temporary relief from the headache, which however returned with the usual severity in twenty-four hours.

Two weeks later, the patient was etherized, 30 cc. were withdrawn by lumbar puncture, the skull wound was reopened, and 30 cc. of autoneosalvarsenized serum were injected under the dura in close proximity to the gray patches. The following day the patient felt better and there was an improvement in the associated insomnia and headache. The patient was discharged from the hospital two weeks later totally free from pain. Four months later, no recurrence of pain had occurred, the patient's general condition was normal, but the condition of the eyes remained unaltered.

The author considers that the result obtained in this case by intracranial injection, and the apparent experimental demonstration of the movement of the cerebrospinal fluid from the cranium spinalward, but not upward from the spinal canal into the cranium,—at least the stain does not pass into the cranium,—point strongly to the intracranial route as being the only one to be adopted in cases with conspicuous and persistent cerebral manifestations.

(*Ibidem*, Nov. 6, 1915, lxv, No. 19.)

FACTITIOUS DERMATOSES. Oliver S. Ormsby, p. 1622.

Ormsby reports a number of interesting cases of this condition produced by various methods, the underlying cause of which should be sought for in some derangement of the nervous system.

(*Ibidem*, Nov. 13, 1915, lxv, No. 20.)

THE PREVENTION AND TREATMENT OF RINGWORM AND FAVUS OF THE SCALP. J. E. Lane, p. 1717.

Methods of prevention suggested are:

1. Reporting of all cases to the health authorities and supervision by them.
2. Examination of all school children associated with cases.
3. Examination of other children in the same family.
4. Disinfection of houses after disease is cured or when vacated.

The modern and only satisfactory rapid method of treatment is epilation by the use of the Roentgen ray. The use of vaccine has been recently reintroduced. The treatment advocated by the author consists of:

1. Cutting the hair short.
2. Removal of crusts.
3. Depilation by the Roentgen ray when possible, otherwise by thumb-forceps.
4. The local use of antiseptic applications.
5. The frequent washing of the scalp.
6. The use of individual toilet articles, etc.

RAYNAUD'S DISEASE. REPORT OF A CASE OF SYMMETRICAL GANGRÆNE OF UNUSUAL SEVERITY. A. L. HOYNE, p. 1725.

The case reported belongs to the third variety of the disease as classified by Raynaud, and occurred in a boy 5 years old whose previous and family histories revealed nothing of importance. Patient was admitted to the hospital with a typical rash of scarlet fever, and rise of temperature. Eight days later, the eruption of measles appeared. Fifteen days after admittance the extremities were noted to be cold. Two days later, double otitis media developed. Temperature was normal since eight days following the measles onset. Patient was out of bed on the twentieth day after entrance. Six days later, a swelling appeared in the right parotid region, but with no fever. Thirty-three days after entrance, a profuse eruption of varicella and fever appeared, accompanied by whooping cough, the temperature returning to normal after five days. Seven days after onset of whooping cough, large bluish-black patches appeared on dorsum of both feet near base of toes, smaller patches on back of right wrist, and a small area of discoloration on right cheek. The areas enlarged, the entire right extremity becoming involved from about one-half the distance from the knee down. The left lower extremity from the ankle down, excepting the big and second toes, and part of the calf were also affected. An area, identical in appearance but smaller, appeared on the left cheek. All areas were rather sharply defined and extremely painful. Proximally about the cyanotic areas on the extremities, the skin had a swollen, tense, waxy appearance; looking œdematous, but was rather hard and did not pit on pressure, and was very painful. All the affected parts were icy cold from the first. On the second day, the upper half of each ear became black and cold, the lower extremities began to look gangrænous, but without extension of the process. The left two ulnar and the right three ulnar fingers were black and cold. The temperature rose to 101° F., the urine showed a faint trace of albumin and some hyaline casts. From the third day to the fourteenth day, there was practically no extension of the process, the lesions became deeper in color, dry and leathery, lines of demarcation appeared on the third day, a broncho-pneumonia developed with increased fever and anaemia. On the sixth day, suppuration was evident at the lines of demarcation. The patient had involuntary movements. On the eighth day, the gangrænous areas began to separate, the temperature fell to normal, but increased slightly later. His general condition remained fair, though the pulse and respiration were rapid and his strength was decreasing. On the fourteenth day, he died as a result of the pneumonia, though he was toxic and had involuntary movements, but apparently suffered little pain. The involved areas had continued to dry, except at the demarcation lines, to shrivel up, and to separate. The blood examination showed a decrease of red cells and hæmoglobin, and an increase of white cells with an alteration in the relative numbers of the different cells. The Wassermann reaction was negative.

The histological findings are briefly stated, though nothing definite was found to indicate the ætiology of the disease. A green streptococcus and a hæmolytic streptococcus were found, which, on being injected into rabbits, produced a malignant endocarditis.

AN UNUSUAL CASE OF SALVARSAN POISONING. K. C. EBERLY, p. 1729.

A patient with early tabes received, accidentally, an intraveonus injection of salvarsan, made up so that 0.6 gm. of salvarsan was contained in 10 cc. of freshly distilled water, only a part of it dissolving, the solution being unneutralized. Five cubic centimetres were injected; a choking sensation and constriction of the pharyngeal muscles were almost immediately complained of. He became

extremely pale; pulse was small, weak and rapid; respiration dyspnœic. Within an hour, he was markedly prostrated, coughed and vomited, and complained of general weakness and pain in the region of the left kidney. A phlebitis started in the cephalic vein at the site of injection and extended to the shoulder. His pulse became rapid and he had some fever and anuria. A catheterized specimen showed a trace of albumin but no casts. After six weeks, under treatment, the phlebitis subsided, the urine became free from albumin, and apparently he suffered no permanent lesion from this mistake. Alkaline therapy relieved the anuria and toxic symptoms almost immediately.

NEW YORK MEDICAL JOURNAL.

(Nov. 20, 1915, cii, No. 21.)

Abstracted by I Rosen, M.D.

PARAPSORIASIS. THE DISEASE FROM THE CLINICAL AND DIAGNOSTIC STANDPOINT; A BRIEF REPORT OF FIVE CASES. Fred Wise, p. 1032.

Wise reports, in detail, both clinically and histopathologically, five cases of parapsoriasis, four of them being of the érythrodermie pityriasique en plaques disséminées type, and the other, parapsoriasis lichenoides, or the parakeratosis variegata of Unna, Santi and Pollibzer.

In discussing the differential diagnosis, the author emphasizes the important diseases that one must exclude. These are maculo-papular syphilis, lichen planus, leprosy, urticaria pigmentosa, psoriasis, seborrhœic eczema, pityriasis rosea, mycosis fungoides, leukæmia cutis, tinea versicolor and atrophia maculosa cutis.

With the aid of the microscope, the differentiation of the various types of parapsoriasis from the above named maladies, becomes a comparatively simple matter. All or nearly all the diseases which simulate parapsoriasis clinically, possess a histopathological picture so greatly at variance with the characteristic changes observed in parapsoriasis, that a microscopic differentiation usually entails no difficulty.

The article is illustrated by clinical photographs.

THE ARTFUL ACARUS; SCABIES EXPOSED. William P. Cunningham, p. 1042.

(*Ibidem*, Dec. 4, 1915, cii, No. 23.)

SYPHILIS OF THE CARDIOVASCULAR AND RENAL SYSTEMS. Joseph H. Barach, p. 1139.

The foremost and important point which the writer makes is, that in syphilis the vascular tissues are first, last and always affected. Just as the minute capillaries are involved, so are the larger blood vessels, the aorta and the heart.

The cardiac disturbances in syphilis may assume any form; from the occasional extra systole on exertion, to the serious cases of heart block.

Having made the decision that syphilis is the underlying cause of the cardiac disturbance, the treatment should consist of a beginning course of iodides, small

or gradually increasing doses of salvarsan, and with these, the judicious use of mercury. Under this régime, the author has had very good results in the majority of his cases.

In speaking of the treatment of syphilitic nephritis, he states that, aside from the mercurials and iodides, the patient should be placed on a purely vegetable diet. Salvarsan should be used with extreme caution.

UNITED STATES DEPARTMENT OF AGRICULTURE. FARMERS' BULLETIN NO. 439.

Abstracted by I Rosen, M.D.

ANTHRAX; WITH SPECIAL REFERENCE TO ITS SUPPRESSION. Henry J. Washburn.

The author of this excellent monograph goes into the nature and history of the disease, its various forms, the morphology of the anthrax bacillus and the methods of combating infectious diseases.

Preventive inoculation will undoubtedly play a very important part in eradicating anthrax. The infected areas of soil should be thoroughly drained and kept under cultivation for some time, before attempts are made to pasture stock upon them. Sunlight greatly hinders the development of the anthrax bacillus and the repeated stirring up of the soil favors the action of the sun's rays.

The complete destruction of all anthrax infected carcasses is also very important. This is best accomplished by burning or deep burial, and the carcass covered with quicklime. No animal dying from anthrax should ever be skinned or cut open, as the blood from such sources is one of the most dangerous means of spreading the infection.

NEW YORK STATE JOURNAL OF MEDICINE.

(November, 1915, xv, No. 11.)

Abstracted by I Rosen, M.D.

THE PATHOLOGY OF SYPHILIS. John A. Fordyce, p. 417.

See The Journal for December, 1915.

(*Ibidem*, November, 1915.)

TREATMENT OF SYPHILIS IN THE PRIMARY STAGE. E. L. Keyes, Jr., p. 425.

Keyes emphasizes the following facts: The foundation of abortive treatment is the diagnosis of syphilis before the Wassermann reaction becomes positive. It also consists of repeated intravenous injections of old salvarsan, followed by injections of mercury.

The success of abortive treatment must be verified by repeated blood examinations, finishing with provoked Wassermann test and spinal fluid tests. The

failure of abortive treatment may be shown by a succession of symptoms, exactly simulating reinfection with syphilis.

THE METHODS OF TEACHING SYPHILIS. William T. Corlett, p. 427.

Syphilis being one of the most important branches of medicine, what are the best means of imparting instruction in the subject to the student body? First. Providing greater hospital facilities for its study and treatment. Second. So far as practicable, the disease should be taught under one department, that of Dermatology, since no one can be considered a syphilologist without a thorough knowledge of dermatology. Third. The equipment for treating syphilis should include a well-equipped laboratory, an operating room, with the accessories required in serum therapy, a male and female ward for the admission of aggravated cases, and a clinic with competent men as heads of each department, where ambulatory treatment can be carried on in a systematic and thorough way.

INTERSTATE MEDICAL JOURNAL.

(1915, xxii, No. 7.)

Abstracted by I Rosen, M.D.

SKIN CANCER AND ITS TREATMENT. Isadore Dyer.

Dyer emphasizes the fact that any scaling patch on the skin covering a wart, mole or small growth, is suggestive of cancer. Seborrhœic patches, particularly if on the face and neck, will become destructive lesions, if not checked.

Where a skin cancer is so situated that free excision without undue mutilation can be practiced, this should be the procedure of choice, and the excision should be extensive enough to preclude any likelihood of any remnant of the growth being left.

The treatment of epithelial cancer is essentially destructive and may be effected by the use of acids, caustics, pastes, plasters, the thermo-cautery, the galvanic cautery, the high frequency current, the X-ray and radium. Carbolic and nitric acids should never be used, as they only irritate the surface and actually stimulate the growths.

BOSTON MEDICAL AND SURGICAL JOURNAL.

(Oct. 21, 1915, clxxiii, No. 17.)

Abstracted by I Rosen, M.D.

THE SYPHILIS WE SEE BUT DO NOT RECOGNIZE, AND THE IMPORTANCE OF FAMILIAL STUDIES. Henry F. Stoll, p. 606.

Stoll describes in detail thirteen cases, (most of them medical, with non-luetic histories) examples of which come under the observation of the family physician. He states that late symptoms of syphilis are often vague, but their indefiniteness should put one on his guard. Chronic rheumatism and chronic

headache mean chronic syphilis in many instances. The physician who does not avail himself of all the newer tests before making his diagnosis, assumes a grave responsibility. By carefully studying other members of the family, some evidence of syphilis may be detected, when nothing can be discovered in the patient himself. Of supreme importance is the realization that syphilis is a familial disease.

BULLETIN OF THE JOHNS HOPKINS HOSPITAL.

(April, 1915, xxvi, No. 20.)

Abstracted by R. C. Jamieson, M.D.

REPORT OF A CASE OF ACNITIS WITH A STUDY OF THE POINT OF ORIGIN OF THE PATHOLOGICAL PROCESS. L. W. Ketron, p. 111.

The author gives the views of other investigators regarding this disease and follows with a complete history of the case under observation. He has found, by a careful study of the pathology of this condition, that the primary lesion develops in the small vessels of the cutis, beginning as a collection of epithelioid cells, probably from the vessel wall endothelium, and connective tissue. This infiltration extends peripherally, the picture varying as different organs are involved, such as hair follicles, sweat and sebaceous glands, or according to the location on the face.

The cause is still unknown. Cultures from the lesions gave negative results. X-ray cleared up the lesions, leaving scars.

(*Ibidem*, September, 1915, xxvi, No. 25.)

LESIONS PRODUCED BY ARSENICALS AND THEIR BEARING ON THE PROBLEM OF SPECIFIC ARSENIC THERAPY. Wade H. Brown, p. 309.

This article gives the general results of the use of arsenic preparations and the lesions produced in the various tissues by their use. Cardiac and vascular changes may be produced by arsenic; also petechial hæmorrhages in the lungs, degenerative lesions with necrosis in the liver as well as kidney and adrenal lesions. The article is written from an experimental point of view.

JOURNAL OF TROPICAL MEDICINE AND HYGIENE.

(Mar. 15, 1915, xviii, No. 6.)

Abstracted by R. C. Jamieson, M.D.

NOTES ON THE INTERNAL TREATMENT OF YAWS. Aldo Castellani, p. 61.

Salvarsan is a specific in yaws but the author has devised a mixture for the treatment of this condition as follows: tartar emetic, 1 grain; sodii salicylat., 10 gr.; potassium iodid., 1 dr.; sod. bicarb., 15 gr.; water, 1 oz., diluted in water 4 oz., three times a day, to those over fourteen years of age.

Cases were treated for ten to fifteen days, rested for five to ten days and then had another course for ten days. Good results were obtained in recent cases, the old cases being more resistant.

(*Ibidem*, June 1, 1915, xviii, No. 11.)

ANIMAL INOCULATION OF TRICHOPHYTON DISCOIDES SABOURAUD, 1909. A. J. CHALMERS AND NORMAN MACDONALD.

These experiments were made on a bull and a donkey, to determine which species was more susceptible and from which the infection could occur. Both animals were inoculated under identical conditions and in eleven days the donkey showed signs of infection, the bull remaining unaffected. The organism was recovered from the donkey in pure culture. They recommend tobacco soap as a remedy.

DIFFERENTIAL DIAGNOSIS OF VERRUGA PERUVIANA. R. P. STRONG. E. E. TYZZER, A. W. SELLARDS.

The authors differentiated verruga Peruviana from yaws as follows: the yaws primary lesion is a papule, later moist and covered with a yellowish crust. The verruga lesion is smooth. tense and translucent and resembles a cherry.

Ætiologically and pathologically the two are distinct. Yaws is due to the spirochæta pertenuis, verruga has never produced any discoverable organism nor is it cured by salvarsan as yaws is. Frambœsia lesions affect the epithelium rather than the cutis while verruga produces endothelial proliferation about newly formed blood vessels. The Wassermann test in verruga Peruviana was negative with but one exception.

The disease was also differentiated from Oroya fever and paratyphoid.

(*Ibidem*, July 1, 1915, xviii, No. 13.)

TRICHOPHYTON VIOLACEUM VARIETAS KHARTOUMENSE. A. J. CHALMERS AND NORMAN MACDONALD. p. 145.

The authors give a complete historical sketch of this variety of trichophyton which was first described by Sabouraud in 1892. It has been spread to various parts of the world by emigrants, though seeming to originate in Italy. They give a most detailed description of the fungus and its cultural characteristics and consider their variety to be a new one. They have found only one case in the Anglo-Egyptian Sudan.

ARCHIVES OF INTERNAL MEDICINE.

(Mar. 1, 1915, xxi, No. 3.)

Abstracted by R. C. JAMIESON, M.D.

NOTES ON THE CULTIVATION OF TREPONEMA PALLIDUM. H. ZINSSER. J. G. HOPKINS AND RUTH GILBERT, p. 213.

Growths of varying ages were used and filtered through a Berkefeld filter. The results of filtration were negative with one exception and led them to

believe that there are no ultramicroscopic forms of the organism. They discuss at length the various methods used and conclude from their experiments that "treponema pallidum can be cultivated in fluid media without the addition of agar, together with tissues sterilized by heat." They found especially active and motile cultures when lung and suprarenal tissues were employed.

(*Ibidem*, June, 1915, xv, No. 6.)

ANTIBODY FORMATION AGAINST TREPONEMA PALLIDUM AGGLUTINATION. H. ZINNSSER AND J. G. HOPKINS, p. 576.

Zinsser and Hopkins injected rabbits intravenously with killed cultures of treponema pallidum and in their experiments used rabbit serum, in dilutions of 1:2 to 1:4000. Each tube contained .5 cc. of these dilutions and .25 cc. of prepared suspension of a growth of the treponema pallidum. Macroscopic and microscopic tests were made, giving positive results in dilutions up to 1:500 in the test tube reaction.

Other experiments are in progress to determine the specificity of this agglutination reaction. Plates are shown to illustrate the microscopic and macroscopic appearance of these tests.

(*Ibidem*, October, 1915, xvi, No. 4.)

SYPHILIS AND RAYNAUD'S DISEASE. H. LISSER, p. 509.

Lisser, in discussing the coincidence of syphilis and Raynaud's disease, does not lay much stress upon syphilis as a causative factor, even though probably 10% of all cases are in syphilitics. This coincidence of the two diseases is negatived by the prevalence of lues. The gangræne may be due to luetic lesions although the spirochæte must be found to prove this, while it is possible that the luetic toxines may be responsible, as in many other conditions in which the symptoms and pathological picture are not typical but yet are due to the syphilitic toxine. He holds that it is not yet proved that syphilis causes Raynaud's disease.

ARCHIVES OF THE ROENTGEN RAY.

(January, 1915, xix, No. 8.)

Abstracted by CHAS. GOOSMANN, M.D.

SOME EXPERIMENTS WITH X-RAY FILTERS. J. H. SEQUEIRA, p. 277.

Lint impregnated with sodium tungstate was used to filter X-ray treatments at the London Hospital during the period 1902-1909. Since then thin sheets of aluminum are being used: the thickness varying from 0.25 to 5.0 millimeters. A sheet of aluminum of 0.25 mm. thickness permits the passage of about four-fifths of the total radiation. With 1.0, 2.0, 3.0 and 4.0 mm. aluminum, the amounts passing through are three-fifths, one-half, one-third plus and one-third the total amount. (The penetration of the tube is not stated.) Sequeira's clinical experience confirms the observation that the skin will tolerate a much larger dose (measured on the skin) of filtered rays than of unfiltered.

(*Ibidem*, February. 1915, xix. No. 9.)

HARD AND SOFT X-RAYS. SIDNEY RUSS, p. 323.

A fact of great interest has emerged from the therapeutic use of hard X-rays; namely, the entirely different effects which hard and soft rays have on the skin. A much greater quantity of hard rays (filtered through 4 mm. aluminum) can be applied to the skin than would be tolerated if the rays were soft (unfiltered). Recent research bids us think of X-rays as ether vibrations of various wave-lengths, the wave-length of soft rays being just about twice that of hard rays. The marked difference in their effects need not appear so surprising when we consider the visible spectrum. Here the ultra-red or heat rays are about twice the size of the ultra-violet or actinic rays, but what a difference that makes in their action!

(*Ibidem*, May. 1915, xix, No. 12.)

TREATMENT OF ONYCHIA BY IONIC MEDICATION. D. DE VOS HUGO, p. 437.

Three cases of purulent onychia were treated. Two were acute, while the third had persisted for eighteen months. In each case the treatment consisted in soaking the part, for a couple of hours, by means of a pad moistened with 5% solution of zinc sulphate. A thread of lint soaked in a 2% solution of the zinc salt was gently insinuated within the nail fold, and an electric current applied in the usual way. The results were very good.

ARCHIVES OF RADIOLOGY AND ELECTROTHERAPY.*

(June, 1915, xx, No. 1.)

Abstracted by CHAS. GOOSMANN, M.D.

THE INHIBITIVE EFFECT OF X-RAYS UPON MALIGNANT GROWTHS. CHRISTOPHER KEMPSTER, p. 2.

Kempster has found that clinically similar cases of epithelioma may respond very differently to X-ray treatment. He has made microscopic examinations to determine the series of changes that occur under treatment, the sections having been obtained before and after the application of X-rays to an epithelioma of the leg.

The general assumption is that the more nearly a cell approaches the embryonic type, the more profoundly is it affected by the rays. Malignant proliferations are, therefore, more susceptible to the treatment than normal tissues; and the tumor cells that are killed are absorbed by an invasion of small round cells which eventually develop into keratotic tissue.

An epithelioma cell-nest or pearl is described and illustrated, Kempster describing the outer cells as the older, and the inner cells as the younger and more rapidly proliferating (contrary to the belief of most pathologists). After X-ray treatment, he finds the epithelial pearls appear looser in structure, and do not contain so many cell layers, and the outer cells do not stain so deeply as the inner ones. The conclusion is drawn that any change which may be taking place is in the older (outer) cells and not in the younger. There is no particular evidence of cell destruction, but there is evidence of the disappearance

* New name adopted for the "Archives of the Roentgen Ray."

of malignant cells, the down-growths being interrupted in places, and isolated islets of cells are found here and there, cut off by round cell infiltration and connective tissue.

In conclusion, Kempster states that in order to cause the disappearance of a new growth, it is unnecessary to destroy a single cell, but simply to inhibit their proliferative power.

(*Ibidem*, July, 1915, xx, No. 2.)

THE SABOURAUD PASTILLE AND X-RAY FILTERS. AGNES F. SAVILL, p. 55.

Some tables are presented, showing the amount of X-ray absorbed in passing through various thickness of aluminum and sodium tungstate lint. The tables show that 0.4 mm. aluminum retards about one-fourth, while 3 mm. aluminum retards three-fifths to one-half the total radiation applied. Bordier, employing chemical methods of measurement, obtained different results—0.5 mm. aluminum stopped 45%, and 3 mm. stopped 86% of the rays. The author believes that the penetration, as registered by the pastille, differed but little with hard and soft tubes, unless the degree of softness was very low indeed—2 or 3 Benoist.

(*Ibidem*, September, 1915, xx, No. 4.)

RADIOTHERAPY: ITS SCIENTIFIC BASIS AND ITS TEACHING. J. JOLY, p. 109.

For many years medicine has been invoking the aid of the mysterious X- and gamma-rays, without knowing what these agents were. Since it has been shown that they are physically identical with light, medicine is made heir to the discoveries of photoelectric science, of which Joly gives a brief review. Although we are to-day far from a knowledge giving complete control of radiative effects, he thinks that these will ultimately be found to be more definable and managable than medicinal treatment.

Failing the guidance which investigation will assuredly one day give us, it is interesting to discuss the cell as a photo-sensitive molecular system, comparable with another photo-sensitive molecular system with which we are familiar in the photographic film. Such a film can exist in different degrees of sensitiveness to light, just as different types of cells vary in their reaction to X-rays.

(*To be concluded.*)

(*Ibidem*, October, 1915, xx, No. 5.)

RADIOTHERAPY: ITS SCIENTIFIC BASIS AND ITS TEACHING. J. JOLY, p. 162. (Continued.)

Joly discusses in detail the parallel reactions of living cells and the photosensitive film. For instance, the substances present in tobacco smoke,—of which nicotine is the most important.—produce a vigorous latent image on a photographic plate; and it has been observed, by direct observation on animal cells, that nicotine produces pathologic mitoses and derangements of cell division closely similar to those which are observed in cancer growth.

Tannin also is a photographic sensitizer, and is the parent substance of a group of chemicals used in developing photographic plates. Joly suggests that

a general instability or irritability is promoted throughout the body cells by this substance tannin, or its derivations. After long and excessive absorption of the injurious substance, a state is reached in which local causes are competent to precipitate pathologic mitosis and cell proliferation. These local causes may be mechanical, or due to the application of a chemical sensitizer, such as nicotine. It is suggested that the increased consumption of tannin containing beverages may explain the growing incidence of cancer.

TWO CASES OF ELECTRICAL BURN SUCCESSFULLY TREATED BY IONIZATION. ALASTAIR MACGREGOR, p. 167.

Burns from electric cables are notoriously sluggish in healing under the usual régime of ointments and lotions. In the two reported cases, healing was accelerated by ionization (cataphoresis) treatment. One cannot draw definite conclusions from the result in two cases, but MacGregor's experience has been almost invariably favorable in other ulcers, callous and septic. Zinc sulphate solution is used on the electrode, and if that fails, a solution of iodine in potassium iodide is tried. The salicylic ion is also used sometimes. Treatments last about 20 minutes, and are repeated once or twice a week.

BOOK REVIEWS

SOLIDIFIED CARBON-DIOXIDE IN THE SUCCESSFUL TREATMENT OF CUTANEOUS NEOPLASMS AND OTHER SKIN DISEASES, WITH SPECIAL REFERENCE TO ANGIOMA, EPITHELIOMA AND LUPUS ERYTHEMATOSUS. FULLY ILLUSTRATED. BY RALPH BERNSTEIN, M.D., Philadelphia, Pa. Clinical Instructor in Skin Diseases, Hahnemann Medical College, Philadelphia, Pa., Consulting Dermatologist to the Women's Southern Homœopathic Hospital, Philadelphia, Pa., Consulting Dermatologist to J. Lewis Crozer Hospital and Home for Incurables, Chester, Pa., Consulting Dermatologist to the House of Detention for Juveniles, Philadelphia, Pa., Dermatologist to West Philadelphia General Homœopathic Hospital and Dispensary; Dermatologist to Hahnemann Hospital Dispensary, Philadelphia, etc. Pp. 95. FRANK S. BETZ CO., Hammond, Indiana.

In this book are described the methods of producing CO_2 snow, its action and its therapeutic efficiency in skin diseases. In 63 cases of cutaneous neoplasms of all kinds, the author obtained 98½% of cures. Epithelioma which had resisted all other methods of treatment, were cured without leaving scars. Among the numerous dermatoses "cured" or "apparently cured" with the CO_2 snow, were acne pustulosa, acne indurata, carbuncle, eczema, pernio, folliculitis decalvans, leprosy, Paget's disease, tuberculosis verrucosa cutis, leg ulcers and xeroderma pigmentosum.

The following statement occurs on page 47:

"There is one important fact which is not at all thoroughly impressed upon either the laity, upon the student, or even upon the physician himself, and that is the early suspicious growths; for it is absolutely certain, with our present

knowledge, that such growths can be effectively removed with solidified carbon dioxide. If such a course were pursued, the future generation would be without cancer, because, I reiterate, that I believe the parasite theory of cancer will be duly affirmed. Our knowledge, certainly, during the past has not tended that way, but certain it is that indirect evidence does exist that we can possibly have a parasitic hypothesis."

The paragraph speaks for itself.

The author's claims for carbon-dioxide snow exceed by far those previously made by its most sanguine enthusiasts. Carbon-dioxide snow has a definite place in dermatological therapeutics, and its usefulness should not be jeopardized by exaggeration.

M. S.

OUTLINE OF COMMON SKIN DISEASES, INCLUDING ERUPTIVE FEVERS. By T. Casper Gilchrist, M.D. Pp. 40. The Students' Book Store, Baltimore, 1915.

These notes have been in use at the Johns Hopkins Dispensary, Department of Pediatrics, for fifteen years. They are intended as a guide for students and practitioners. They include a classification, method of examination and an arrangement of skin diseases regionally and also according to their primary lesions.

The author discusses differential diagnostic points in the common ulcers, the common eruptive fevers, the regional forms of eczema and other diseases; there is also a list of the usual diseases of childhood, a list of diseases which tend to form rings or annual lesions, a few general rules about some of the commonest skin diseases, and, finally, a diet plan for children in use in the Pediatric Department of the Johns Hopkins Hospital, by Dr. John Howland.

M. S.

ANNOUNCEMENTS.

Scientific Contributions.

In spite of numerous notices to the contrary, the opinion still prevails that The Journal is a sort of "closed corporation"; that it does not welcome contributions from physicians who are not members of the American Dermatological Association.

The Journal is owned by and published under the auspices of the Association, which means that this body accepts the financial burden and, also, it is responsible, through its Publication Committee and the Editorial Staff, for the general welfare of The Journal—for its scientific, ethical and literary standing. In other words, the Association purchased The Journal in order to guarantee its future. In the management of The Journal the Association is exceedingly liberal and its members, who individually deserve credit for their unselfish financial support, have but one purpose, namely, to elevate the standing of The Journal and to increase its value to its readers.

The editorial management is entirely in the hands of the Editor, who must assume all responsibility for accepting or rejecting articles from any source. Some of the most important material that has appeared in The Journal has been from the pen of individuals who are not members of the Association. Many of the members of the Abstract Department are not members of the Association. It should be remembered, too, that both the present Editor and Associate Editor were not members of the Association during the past few years of their incumbency. And it is quite possible that an Assistant Editor will soon be appointed who is not a member of the Association. Nothing could be more liberal or broad-minded than is the management of The Journal of the Association.

We will welcome scientific communications of interest to the dermatologist from any ethical physician. The articles will be considered and judged solely upon their merits by the Editor. Whether or not the author is a member of the Association will have no influence upon the acceptance or rejection of the communication.

American Journal of Orthopedic Surgery.

The American Orthopedic Association announces the appointment of Dr. Mark H. Rogers, Boston, as Editor of *The American Journal of Orthopedic Surgery*, the only periodical in the English language devoted to Orthopedics. This *Journal*, which has now completed 13 volumes as a quarterly publication, will henceforth be issued monthly, the first number in the new form being that of January, 1916.

The office of publication has been transferred from Philadelphia to Ernest Gregory, 126 Massachusetts Ave., Boston. The subscription price is $4.00 per year.

Personal.

Dr. Hermann G. Klotz has resigned his position of Visiting Dermatologist to the German Hospital, where he has served for the past thirty-six years. In recognition of his service he has been appointed Honorary Dermatologist to the hospital. Dr. Klotz has also retired from private practice.

THE JOURNAL OF
CUTANEOUS DISEASES

VOL. XXXIV MARCH, 1916 No. 3

ORIGINAL COMMUNICATIONS

THE SUGAR CONTENT OF THE BLOOD IN VARIOUS DISEASES OF THE SKIN.*

BY HANS J. SCHWARTZ, M.D., WALTER JAMES HEIMANN, M.D., AND HARRY C. MAHNKEN, M.D., NEW YORK.

(From the Departments of Clinical Pathology and Dermatology, Cornell University Medical School, New York.)

IN RECENT years, much interest has been manifested in the relation of blood sugar to various diseases, particularly diabetes, nephritis, disorders of the glands of internal secretion and nutritional disorders of infancy. The study of the concentration of blood sugar has added many important facts to our knowledge of these conditions. Scott[1] emphasizes its importance by pointing out that a study of the sugar content of the blood offers a more satisfactory indication of the condition of mobile sugar than does the examination of the urine. By examination of the blood, either an increase or a decrease of the amount of sugar may be demonstrated, while the urine is capable of showing only an increase. Furthermore, profound changes may occur in the sugar content of the blood in response to conditions which do not produce glycosuria.

The blood sugar in the normal adult varies from 0.07 to 0.11 per cent., and practically the same figures are found in infants. There is a marked tendency for the blood sugar to maintain a constant level, but striking changes may follow the ingestion of carbohydrate foods. A definite increase appears shortly after a meal, reaches its maximum in from one and one-half to two and one-half hours, after which the

* Read before the 39th Annual Meeting of the American Dermatological Association, New York City, May 13-15, 1915.

blood sugar decreases. The increase may be caused both by starch and sugar, but that caused by starch is slower and less marked. Owing to these facts, blood used for sugar examination should be withdrawn about three and one-half hours after meals.

Relation of Blood Sugar to Carbohydrate Metabolism.

The sugars and starches of the food, after conversion by the intestinal enzymes into glucose, pass by way of the portal circulation to the liver, in which the major part is stored as glycogen and delivered to the blood as glucose is needed by the tissues. It is then utilized to produce heat and energy, mainly by the muscles, which also contain a moderate reserve of glycogen. The most important factor in the maintenance of a constant sugar content in the blood is the reconversion of the stored-up glycogen of the liver into glucose, and the amount of sugar in the blood depends on the rapidity of mobilization of glycogen in the liver. Hyperglycæmia, therefore, probably means a disturbance in the balance between mobilization and consumption of sugar, provided the temperature and diet are normal.

The importance of the ductless glands in the regulation of carbohydrate metabolism has been much emphasized. It is generally assumed that the pancreas furnishes an internal secretion, a hormone, necessary to this metabolism. Any interference with this secretion results in decreased tolerance for sugar.

Increased activity of the thyroid is said to result in decreased activity of the pancreas. This causes a corresponding increase in glycogen mobilization and decreased tolerance for sugar; hence the decreased tolerance for sugar seen in hyper-thyroidism. Cushing believes that the posterior lobe of the pituitary gland has an important influence on carbohydrate metabolism, deficiency of secretion being associated with increased tolerance for carbohydrates, and excess of secretion with diminished tolerance. Experimentally, it has been shown that adrenalin has a marked influence upon carbohydrate metabolism. Injections of this substance into animals are almost invariably followed by glycosuria. Clinically, however, no organic disease of the adrenals is known which causes glycosuria or diabetes.

Conditions Causing Variations in Blood Sugar Concentration.

Besides alimentary hyperglycæmia, increase in the blood sugar is found associated with great nervous and mental disturbances, preg-

nancy, diabetes, disorders of the glands of internal secretion, pancreatic and certain hepatic diseases, cerebral tumor, injury, and hæmorrhage, certain cases of nephritis, cancer and some fevers. Hyperglycæmia is less common and is found in exhaustion, starvation and phloridzin diabetes.

Alimentary Hyperglycæmia in Health and Disease.

Jacobson,[2] using Bang's method, has shown that in normal cases a rise in blood sugar occurs within five minutes after the ingestion of 100 gms. of glucose, the maximum being reached in half an hour and the preformed level being resumed in approximately two hours. Hopkins,[3] using the same method, found that the height of the curve was reached in from half an hour to two hours, after which it quickly subsided. He noted that, in diabetes, alimentary glycosuria is very pronounced, the height of the level appearing at any time from one-half to three hours after the glucose feeding, the duration being greatly prolonged. In pancreatic, nephritic and in pituitary cases, he found high figures, following glucose feedings, the duration lying between that of normal and diabetic patients. In many of these last cases, normal, preformed sugar values were associated with markedly abnormal figures in alimentary hyperglycæmia, thus demonstrating the necessity of glucose tolerance tests when a disturbance of carbohydrate metabolism is suspected.

In diabetes, skin complications are very common, such as eczema, furunculosis, carbuncle, gangræne, pruritis, bronzing of the skin,—as in the so-called *diabète bronzé*,—zoster, and perforating ulcer of the foot. The last two are an expression of diabetic neuritis.

The above facts and the fact that hyperglycæmia can exist without glycosuria, suggested the possibility that a disturbance of carbohydrate metabolism, demonstrable by means of blood sugar estimation with or without a glucose tolerance test, might at least play a part in the ætiology and obstinacy of some dermatoses. In particular, it was thought that this might be the case in the inflammations and infections. To determine this point, the present study was undertaken.

Literature.

An extensive literature on the subject of hyperglycæmia exists, which was thoroughly studied in connection with the present work. Although it covers questions of method, diseases of infancy, and chronic metabolic

diseases of adult life, so far as could be determined, nothing has been written concerning hyperglycæmia in diseases of the skin. But few of the articles have any bearing on this field, excepting where the latter becomes one with the problems of general medicine.

Method.

Most investigators of recent years have used the micro-method of Bang. The minute quantities of blood used, and hence the resultant small quantity of sugar actually determined, would seem to allow of a large error in the readings. Thus, we have adopted the method recently devised by Benedict and Lewis[4] which is well suited to clinical use, combining as it does accuracy, simplicity and the need for relatively small quantities of blood.

Results.

The patients to be studied were chosen at random, for, with the qualifications already mentioned, no preconceived notions of probable results were entertained. All of the ordinary dermatoses, as a glance at the accompanying charts will show, were included in the study, as well as some of the rarer diseases, such as scleroderma, morphœa, xanthoma and a case of pseudo-xanthoma elasticum. The cases were found to arrange themselves in two groups. In the first group,—or those in which the presence of hyperglycæmia was frequent,— are included acne, seborrhœa, and sycosis (Table ii). In the second group,—in which hyperglycæmia was seldom found,—are all the remaining dermatoses (Table i). Sixty cases of acne, seborrhœa and sycosis were studied, of which 26 showed excessive blood sugar and only 24 a normal amount, the remaining 10 being on the border line. A seriatim analysis of these conditions will further the interests of clearness.

There were 30 cases of acne, 23 of which were of the simple type and 7 of the indurated. Of the former, 7 showed increased blood sugar; of the indurated, not one was normal, 4 showing a marked hyperglycæmia and 3 being on the border line. Kahler[5] noted a distinct and definite hyperglycæmia occurring before or with the onset of menses and disappearing with the latter's cessation. This is of interest in connection with the well-known acne eruptions associated with menstruation. Kahler ascribed menstrual hyperglycæmia to disturbed liver function, basing his argument on Chvostek's[6] demonstration of hepatic congestion during the periods.

Twenty-four cases of seborrhœa were studied, of which 10 were normal, 4 on the border line, and 10 associated with hyperglycæmia. It is to be emphasized that of the last ten, the majority were examples of oily seborrhœic alopecia, resistant to all usual therapy, a type frequently accompanied by indurated acne.

Of 5 patients afflicted with staphylogenic sycosis, only one was normal. The other four had markedly increased blood sugar values. One of these cases was particularly obstinate, the disease having been present for two years. A glucose feeding was administered to him with the results shown in Table III, denoting a diminished sugar tolerance.

In passing, it may be remarked that only one patient with rosacea was studied, in whom, however, a marked hyperglycæmia was present. Of the patients with seborrhœa and pilo-sebaceous diseases, slightly over 43 per cent. had hyperglycæmia. In contrast with the results in other dermatoses, this is striking. Eighty-nine cases (Table I) were examined, and but 15 showed a high blood sugar, 74 being within normal limits. Of the 15 abnormal ones, 3 were diabetic, and one, a syphilitic, also had acne. Thus only 11 cases in this group remain to be considered. One of these occurred in a case of eczema. Sixteen other eczema patients were normal as to blood sugar. The other instances were as follows: 1 in 5 dysidroses, 1 in 3 multiform erythemas, 2 in 23 syphilitics, 3 in 16 psoriatics, 1 each in 2 sclerodermas, 3 pruritics and 4 urticarias. It is apparent that in this group positive findings are few, sporadic and peculiar to no one particular disease. On the other hand, a definite correlation exists between pilo-sebaceous infections and hyperglycæmia. Without drawing extensive conclusions from these facts, there does appear to be a selective force at work causing this association between diseases of the pilo-sebaceous follicles and an excess of blood sugar. Both simple and indurated acne and sycosis are obviously infections, and seborrhœa is also widely assumed to be due to a micro-organism. Now in diabetes we are familiar with the ease with which cutaneous infections arise, and this is, in part at least, due to the increased fertility of the soil for bacterial growth. The thought suggests itself that a similar state exists in hyperglycæmia, thus accounting for its frequent presence in pilo-sebaceous infections.

TABLE I.

Diagnosis	Number of Cases	Readings Normal	Readings Border	Readings High
Alopecia areata	2	1—0.077%	1—0.11%	
Macular atrophy	1	1—0.100%		
Hyperidrosis and pompholyx	5	3—0.100%	1—0.11%	1—0.133%
Eczema, various types	17	13—0.070-0.1%	3—0.11%	1—0.130% (2 tests)
Erythema multiforme	3	1—0.090% 1—0.100%		1—0.115%
Erythrodermia, scarlatiniform acute type	1		1—0.11%	
Syphilis—all varieties	25	20—0.055-0.1%	2—0.11%	2—0.125% 1—0.150%
Erythematous lupus	2	1—0.070% 1—0.090%		
Nævus, pigmented	1	1—0.010%		
Pruritus	4	1—0.080%	1—0.11%	1—0.125% 1—0.250% (young woman with diabetes but no glycosuria at time of blood test).
Psoriasis	17	12—0.060-0.1%	1—0.11%	1—0.250% (Diabetes) 3—0.125%
Fibroma molluscum	1	1—0.070%		
Scleroderma	2	1—0.085%		1—0.143%
(morphœa)	2	1—(100 gms. sugar fed: Five tests 0.059-0.088 per cent. See Table III). 1—0.090%		
Xanthoma	2	1—0.1% (Dr. Kingsbury's case). Diabetic.		1—0.133% (Dr. Trimble's case. Baby 14 months old, with transient glycosuria).
Urticaria	4	2—0.100%	1—0.11%	1—0.140%
Total	89	63	11	15

TABLE II.

Diagnosis	Number of Cases	Readings Normal	Border	High
Acne	23	13—0.060-0.1%	3—0.11%	7-1—0.117% 1—0.118% 4—0.125% 1—0.130%
Acne indurata	7		3—0.11%	4-1—0.125% 2—0.133% 1—0.153%
Total acne	30	13	6	11
Rosacea	1			1—0.133%
Seborrhœa of scalp with and without alopecia; also of body.	24	10—0.055-0.1%	4—0.11%	10-7—0.125% 1—0.142% 1—0.143% 1—0.200%
Sycosis, staphylogenic	5	1—0.1%		4-1—0.125% 1—0.143% 1—0.120% 1 test 0.125% 2 " obstinate case, 2 yrs. old. 100 gms. sugar fed, 5 tests. See Table III.
Total	60	24	10	25

With the exception of the three cases mentioned in the tables, no sugar was found in the urine of any of the patients examined. In the cases showing hyperglycæmia, albumin was tested for in the urine, but the examinations were all negative.

TABLE III.

These cases illustrate the method of determining sugar tolerance. After estimating the preformed level of sugar in the blood, 100 gms. of glucose are given, dissolved in water. At the end of a half hour, one, two and five hours, blood readings are made. As a rule the maximum point is reached in half an hour.

	Morphœa		Sycosis		Hyperidrosis	
	Blood	Urine	Blood	Urine	Blood	Urine
Preformed level.....	0.088%	0	0.11%	0	0.11%	0
After ½ hour.....	0.069%	0	0.154%	0	0.16%	0
" 1 "	0.07%	0	0.143%	±	0.125%	0
" 2 hours.....	0.083%	0	0.143%	±	0.11%	0
" 5 "	0.077%	0	0.125%	0	0.11%	0

REFERENCES.

[1] SCOTT, E. L. *Amer. Jour. Physiol.*, 1914, xxxiv, p. 306.
[2] JACOBSON. *Biochem. Ztschr.*, lvi, Nos. 5-6, p. 471.
[3] HOPKINS. *Amer. Jour. Med. Sci.*, February, 1915, p. 254.
[4] BENEDICT AND LEWIS. *Jour. Biol. Chem.*, January, 1915, No. 1.
[5] KAHLER. *Wien. Klin. Wchnsch.*, 1914, xxvii, p. 417.
[6] CHVOSTEK. *Wien. Klin. Wchnsch.*, 1909, ix.

COMPLEMENT FIXATION IN ACNE VULGARIS.*

By Albert Strickler, M.D.,

Instructor in Dermatology, Philadelphia Polyclinic and College for Graduates in Medicine,

John A. Kolmer, M.D.,

Professor of Pathology and Bacteriology, Philadelphia Polyclinic and College for Graduates in Medicine

AND

Jay F. Schamberg, M.D.,

Professor of Dermatology, Philadelphia Polyclinic and College for Graduates in Medicine.

Despite numerous bacteriological investigations and contributions to literature on the subject of the ætiology of acne vulgaris, our knowledge of the subject remains incomplete.

While the increased activity and growth of the pilosebaceous system incident to accession to puberty, is unquestionably a predisposing cause, and gastrointestinal disorders and general impoverishment of vitality contribute to the development of acne, most dermatologists regard the disease as dominantly and primarily an affection of microbic nature.

Unna, in 1893, described a micro-bacillus as the causative agent of acne; in 1908 he relegated this organism to a place of secondary importance in favor of a special coccus; investigators have since been divided in their opinion regarding the ætiological importance of this bacillus and various cocci and diplococci.

The micro-bacillus of Unna is probably identical with that described by Sabouraud in 1897 and regarded by him as the cause of oily seborrhœa which, in operation with a special coccus, is regarded as producing the various cutaneous lesions grouped under the general term of acne vulgaris. The bacillus of acne described by Gilchrist, while presenting certain differences in its morphological and biological characteristics, is probably to be placed in the same category as the bacillus of Unna and Sabouraud.

* From the Laboratories and Dermatological Department of the Philadelphia Polyclinic and College for Graduates in Medicine.

Many investigators, as Engman, Gilchrist, Flemming, Western, Molesworth and others regard the acne bacillus as the cause of both the comedones and the associated pustules; others, as Sabouraud and Whitfield, accept the bacillus as the cause of the comedones but maintain that a secondary infection is necessary for the production of suppuration. As shown by Schamberg, a bacillus resembling morphologically the micro-bacillus of Unna may be found in the sebaceous material from the nasal follicles of normal individuals and while it is generally accepted by dermatologists that this bacillus may remain harmless under normal conditions, it is probable that in susceptible individuals it may exert a pathogenic influence.

A similar diversity of opinion exists relative to the rôle of cocci found in acne lesions. Unna and Schwentes-Trächsler regard a special coccus as the cause of both comedones and pustules and similar claims are made for the diplococcus described by Varney and Clark.

We have attempted a study of the relationship to the disease of the bacillus of acne and of the cocci recovered from acne lesions, by means of complement fixation tests, employing antigens of these various microorganisms and the sera of infected individuals. Haase[1] has applied this technique in the study of ten cases of acne, using an antigen of B. acne; with this organism there were six positive reactions; an antigen of the milk-white coccus of Trächsler yielded three positive reactions and the diplococcus of Varney and Clark gave one positive reaction.

We have employed a polyvalent antigen of cocci recovered from acne pustules which we regard as belonging to the species of Staphylococcus albus; also a monovalent antigen of the B. acne of Unna, Sabouraud, Gilchrist, etc.

In view of the frequency of intestinal disorders among persons suffering from acne, we have also employed a polyvalent antigen of different strains of B. coli communis and communior, isolated from the fæces of these patients, on the basis that a toxine formed by these bacilli in the intestinal tract may be operative in the pathogenesis of the disease and if so, produce antibody formation that may be detected by complement fixation tests.

As controls, a polyvalent antigen of staphylococci from furuncles was also employed; likewise a polyvalent antigen of colon bacilli from the intestinal tracts of normal persons. In addition to a study of acne cases, all antigens were tested out with the sera of patients with acne

[1] HAASE, M. An Attempt to Determine the Bacterial Ætiology of Acne With the Complement Fixation Reaction. *Jour. Cutan. Dis.*, 1913. xxxi, p. 1015.

rosacea, seborrhœic dermatitis and other non-acneiform skin diseases as well as with the sera of syphilitics and persons suffering with various non-cutaneous affections.

Materials and Method of Study.

Hæmolytic System. The anti-sheep hæmolytic system was used throughout. Complement was furnished by the pooled sera of two or more guinea pigs and used in a constant dose of one cc. of a 1:20 dilution (0.05 cc. undiluted serum). Washed sheep cells were prepared in a 2½% suspension and the hæmolysin titrated each time with each complement serum and corpuscle suspension and used in the antigen titrations and complement fixation tests, in amounts equal to two hæmolytic units.

In the antigen titrations, increasing amounts of antigen were incubated for an hour at 37° C. with 1 cc. of the complement serum (1:20), when 1 cc. of corpuscle suspension (2½%) and two units of hæmolysin were added. After mixing, the tubes were re-incubated for an hour when the results were read; the smallest dose of antigen that showed just beginning inhibition of hæmolysis was taken as the anti-complementary dose. In the complement fixation tests, one-third to one-fourth this amount was used as the dose of antigen.

In the complement fixation tests serum, antigen and complement were incubated for an hour, when corpuscles and two units of hæmolysins were added; after reïncubating for an hour or an hour and a half, according to the hæmolysis of the controls, the results were read. As usual in complement fixation tests, serum antigen, hæmolytic, etc., controls were always employed.

Antigens. Five different bacterial antigens were employed. All of these were polyvalent except that of B. acne.

No. 1. Staphylococcus control antigen; prepared of eight strains of Staphylococcus aureus from abscesses.

No. 2. Staphylococcus acne antigen; prepared of six strains of Staphylococcus albus from pustules of acne vulgaris. No. 3. B. coli control antigen; prepared of six strains of B. coli isolated from the fæces of healthy persons (mostly children).

No. 4. B. coli acne antigen; prepared of six strains of B. coli isolated from the fæces of persons with acne vulgaris.

No. 5. B. acne antigen; prepared of one strain of B. acne (Unna-Sabouraud-Gilchrist type).

In the preparation of each antigen, cultures were grown on suitable solid media until good growths were secured; these were washed off with sterile normal salt solution with care not to break away portions of the medium. Each emulsion was shaken mechanically with glass beads for two hours; filtered through sterile filter paper; diluted with normal salt solution as necessary and heated at 60° C. for an hour. To each emulsion was added 0.5% phenol as a preservative.

Each antigen was titrated for its anticomplementary unit before complement fixation reactions were conducted. Preserved in a refrigator, they maintained their titres fairly constant but gradually lost in antigenic sensitiveness. The following table gives the results of one series of antigen titrations:

TABLE 1. ANTICOMPLEMENTARY TITRATIONS OF VARIOUS BACTERIAL ANTIGENS.

Tube No.	Dose cc.	Antigens: Staph. Control	Staph. (Acne)	B. Coli (Control)	B. Coli (Acne)	B. Acne
1	0.4	H	H	H	H	H
2	0.6	H	H	H	H	H
3	0.8	H	H	H	H	H
4	1.0	S I H	S I H	H	H	H
5	1.2	M I H	M I H	H	H	H
6	1.5	I H	I H	S I H	S I H	S I H
Dose used		0.3	0.3	0.5	0.5	0.5

H. Complete hæmolysis.
M I H. Marked (50 per cent.) inhibition of hæmolysis.
S I H. Slight (25 per cent.) inhibition of hæmolysis.
I H. Complete (100 per cent.) inhibition of hæmolysis.

In addition to these bacterial antigens an alcoholic extract of heart, reënforced with cholesterin, was used in testing each serum for the Wassermann reaction. This extract was perfectly antigenic in dose of 0.05 cc. of a 1:20 dilution and was used in dose of 0.2 cc. of this dilution, being free of anticomplementary action in amounts under 3.9 cc In our experience these cholesterinized extracts when properly titrated and used, constitute the most delicate antigen in the syphilis reaction with which we are familiar.

SERA. The sera of 128 persons have been used in this study; of these, 57 were from persons suffering with acne vulgaris, 9 from persons with acne rosacea. 10 from persons with seborrhœic dermatitis, 26 from persons with various non-acneiform skin diseases, 26 from persons with syphilis and other diseases but free of cutaneous affections.

In the tables the type of predominating lesion of each case is given, although all are listed under the general heading of acne vulgaris.

Most interest centred about the group of patients with acne vulgaris and acne rosacea. The group of patients with seborrhœic dermatitis was likewise of interest in this study, owing to the views of Sabouraud, who regards the bacillus of acne as the cause of oily seborrhœa, which, with secondary infection with cocci, produces the lesions of acne.

The sera of persons with various non-acneiform skin diseases were included as controls, as were likewise the last mentioned group of sera from syphilitics in the tertiary stages and from persons with other non-cutaneous diseases. The syphilitic sera were included with the main purpose of determining whether the syphilis "reagin" would absorb complement with the bacterial antigen.

All sera were inactivated by heating at 56° C. for half an hour and used in constant doses of 0.2 cc.

Results.

1. In Acne Vulgaris, Table 2 shows the results obtained in complement fixation tests with the sera of 57 cases of acne vulgaris.

Table 2. Complement Fixation in Acne Vulgaris.

No.	Character of Lesions.	Degree of Infection.	React. Wass.	Antigens 1 Staph. (Control)	2 Staph. (Acne)	3 B. Coli (Control)	4 B. Coli (Acne)	5 B. Acne
1	Papulo-pustular	Moderate	—	0	+	0	+	++++
2	Pustular	Very severe	—	0	+	0	+	++++
3	Papulo-pustular	Severe	—	0	+	0	++++	++++
4	" "	"	—	0	—	0	D H.	++++
5	Papular	"	—	0	+	0	++	+++
6	Comedones	Moderate	—	0	—	0	—	+++
7	Papular	Severe	—	0	—	0	—	—
8	Comedones ...	"	—	0	+	0	—	++++
9	Papulo-pustular	Moderate	—	0	—	0	+	++
10	Papular	Mild	++	0	—	0	—	+
11	"	Moderate	—	0	—	0	—	++
12	Pustular	"	—	0	+	0	+	+++
13	Papular	Mild	—	0	—	0	—	—
14	Papulo-pustular	Moderate	—	0	++	0	—	++
15	" "	Severe	—	0	++++	0	±	++++
16	" "	Moderate	—	0	++	0	—	++
17	" "	Severe	—	0	++++	0	++	++++
18	Papular	Moderate	—	0	++++	0	—	++++
19	"	"	—	0	++++	0	—	++++
20	Papulo-pustular	Mild	—	0	—	0	—	±
21	" "	Moderate	—	0	—	0	±	+
22	" "	"	—	0	+	0	+	++
23	" "	Mild	—	0	—	0	—	+
24	Papular	"	—	0	—	0	+	++
25	"	Severe	—	0	+	0	++++	++++
26	"	Moderate	—	0	—	0	±	+

TABLE 2. COMPLEMENT FIXATION IN ACNE VULGARIS.

No.	Character of Lesions.	Degree of Infection.	React. Wass.	Antigens 1 Staph. (Control)	2 Staph. (Acne)	3 B. Coli (Control)	4 B. Coli (Acne)	5 B. Acne
27	Papulo-pustular	Moderate	—	0	+	0	++	++
28	" "	Severe	—	0	++	0	++	+++
29	Papular	Mild	++	0	—	0	—	++
30	"	"	—	0	+	0	+	+++
31	"	"	—	0	—	0	—	++++
32	Pustular	Severe	—	0	+	0	++	++++
33	Papulo-pustular	Mild	—	—	—	—	+++	++++
34	" "	Moderate	—	+	+	—	++++	++++
35	Papular	Mild acne and syphilis	++++	++++	++++	++++	++++	++++
36	Papulo-pustular	Severe	—	+	+	—	+	±
37	Papular	Mild	—	+	+	—	+	— +
38	Papulo-pustular	Moderate	—	—	—	—	+	—
39	" "	"	—	±	±	—	±	±
40	" "	"	—	—	—	+	++++	+
41	" "	"	—	++++	+++	[illegible]	++++	++++
42	Papular	Mild	—	+++	++	—	+	—
43	Papulo-pustular	Severe	—	—	—	—	—	—
44	Pustular	Moderate	—	—	—	+	++++	++++
45	Papulo-pustular	Moderate	—	++	+	+	++++	++++
46	Indurated	Moderate	—	+++	+++	—	—	++++
47	Papular	Severe	+	++++	++	+	+	++++
48	"	Mild	—	+	+	—	—	—
49	Papulo-pustular	Moderate	—	++	++	±	++++	++++
50	Papulo-pustular	Severe	—	++++	++	±	±	++++
51	Indurated	"	—	—	—	—	±	±
52	Papulo-pustular	Mild	—	—	—	—	—	±
53	" "	"	—	—	—	—	—	—
54	Papular	"	—	—	—	—	+	—
55	Papulo-pustular	Moderate	—	++++	++++	—	+	+
56	" "	"	—	+++	+++	—	++	+
57	" "	"	—	++	++	—	—	±

As shown in the table, well marked positive reactions were observed with 48, or 84.2% of the sera with the antigen of B. acne. As a general rule the severer the infection the higher were the percentages and degree of complement fixation reactions.

With the antigen of staphylococci positive reactions were observed with about 64% of sera and the control antigen of various strains of Staphylococcus aureus from furuncles yielded similar results to those observed with the antigen of cocci from acne lesions. These results would indicate that the cocci found in acne lesions are not of a special variety but belong to the general group of staphylococci which develop feeble pyogenic powers in a favorable soil.

Considerable interest is attached to the results observed with the antigens of colon bacilli. With the polyvalent antigen of colon bacilli from the intestinal tracts of persons suffering with acne, positive reactions

were observed with 63.1% of sera; the control antigen of colon bacilli yielded 32% positive reactions. Even more significant is the observation that while the serum of an acne patient may fix complement with both colon antigens, the degree of fixation was usually greater with the antigen composed of colon bacilli from acne patients. This will be observed in TABLE 2, where the plus signs indicate the relative degrees of complement fixation.

In a series of separate experiments the sera of several persons with acne were used in descending doses with constant doses of both colon antigens. In these tests it was apparent that the colon antigen of bacilli from acne patients was more sensitive and served to absorb complement in smaller doses than the antigen of colon bacilli from normal persons.

These results we would interpret as indicating an activity on the part of the colon bacilli in the pathogenesis of some cases of acne vulgaris. Whether or no special strains of colon bacilli are concerned and to what extent they are operative in the production of acne we are unable to express an opinion. We are content at the present time to record the results of the complement fixation tests.

As will be shown later, these reactions with the colon bacilli antigens were not confined to acne vulgaris but were likewise observed with sera from persons with acne rosacea, seborrhœic dermatitis and in a few non-acneiform skin diseases, while the sera of normal persons and those with non-cutaneous diseases reacted uniformly in a negative manner.

II. IN ACNE ROSACEA, the results observed with the complement fixation tests with the sera of nine cases of acne rosacea are shown in TABLE 3.

TABLE 3. COMPLEMENT FIXATION IN ACNE ROSACEA.

No.	Character of Lesions	Degree of Infection	Wass. React.	Antigens 1 Staph. (Control)	2 Staph. (Acne)	3 B. Coli (Control)	4 B. Coli (Acne)	5 B. Acne
1	Pustular	Moderate	—	0	—	0	+	+++
2	"	"	—	0	—	0	—	—
3	Papular	"	—	0	—	0	—	+
4	Redness; no lesion	"	—	—	—	—	—	—
5	—	"	—	—	—	++	++	+
6	Papular	"	—	—	—	—	—	—
7	"	Mild	—	++	++	+	+++	++++
8	Pustular	Moderate	—	++++	++++	++	++++	++++
9	"	"	—	±	±	—	+	+

Of these 9 cases the sera of 6, or 66.6% reacted positively with the antigen of B. acne, thus indicating the activity of this bacillus in acne rosacea. Positive reactions were likewise observed with about 40% of sera with the staphylococcus antigens and in about 52% with the colon antigens. With the latter the results observed with both colon bacillus antigens were about the same.

The fact that two-thirds of the cases of acne rosacea gave a positive complement fixation with the acne bacillus would seem to indicate that this organism is a factor in the causation of this affection. It will be recalled that some dermatologists hold this dermatosis to be a condition distinct and apart from acne vulgaris and they emphasize this opinion by applying to acne rosacea the terms rosacea erythematosa, rosacea papulosa and rosacea pustulosa.

III. In Seborrhœic Dermatitis, the results observed in 10 cases are shown in Table 4.

Table 4. Complement Fixation in Seborrhoeic Dermatitis.

No.	Distribution	Degree	Wass. React.	Antigens 1 Staph. (Control)	2 Staph. (Acne)	3 B. Coli (Control)	4 B. Coli (Acne)	5 B. Acne
1	Scalp	Mild	—	0	—	0	—	—
2	Scalp	Severe	—	—	—	—	—	—
3	Body and scalp	Severe	—	—	—	—	—	—
4	Scalp	Severe	—	—	—	—	—	—
5	Scalp	Moderate	—	—	—	—	—	—
6	Body	Moderate	—	—	—	—	++	++
7	Body	Moderate	—	+	+	++	++++	++
8	Face	Severe	—	+	+	—	—	—
9	Face and scalp	Moderate	—	—	—	—	++++	—
10	Scalp	Mild	++	—	+	—	++	++

As previously stated, these sera were of particular interest on account of Sabouraud's claim that the acne bacillus produces an oily seborrhœa which, acting in conjunction with cocci, produces the lesions of acne.

Of these 10 cases the sera of 3, or 30%, yielded positive reactions with the antigen of B. acne and about 25% reacted positively with the staphylococcus antigens. With the antigen of colon bacilli from acne patients, complement fixation occurred with 40% of sera and in 11% with the antigen of colon bacilli from normal persons.

Several of our cases represented mild types of the disease which may account for the negative reactions with the antigen of B. acne, due to low content of antibodies in the blood serum.

IV. Non-Acneiform Skin Diseases. As shown in Table 5, the sera of 26 persons suffering with different forms of eczema, furunculosis, lupus, etc., were included in this study to determine the specificity of our antigens in acne.

Table 5. Complement Fixation in Various Non-Acneiform Skin Diseases.

No.	Diagnosis	Wass. React.	Antigens 1 Staph. (Control)	2 Staph. (Acne)	3 B. Coli (Control)	4 B. Coli (Acne)	5 B. Acne
1	Squamous eczema....	—	0	—	0	—	—
2	" "	—	0	—	0	—	—
3	" "	—	0	—	0	—	—
4	" "	—	—	—	—	—	—
5	" "	—	±	±	±	+	+
6	" "	—	+	—	—	—	—
7	" "	—	—	—	—	—	—
8	Vesicular eczema.....	+++	—	—	+	+	±
9	" "	—	+	—	—	—	—
10	" "	—	—	—	—	—	—
11	" "	—	+++	+++	—	—	++
12	" "	—	+++	++	±	++	—
13	Sycosis vulgaris.....	—	0	++++	0	++++	++
14	Tineatonsurans	—	—	—	—	—	—
15	Furunculosis	—	—	—	—	—	—
16	"	—	—	—	—	—	—
17	"	—	+	+	—	—	—
18	"	—	++	++	—	—	—
19	Lupus erythemat.	—	0	+++	0	—	+++
20	Impetigo contagiosa..	—	—	—	—	—	—
21	Alopecia areata.....	—	—	—	—	—	—
22	Variola	—	±	±	—	—	—
23	"	—	±	±	—	—	—
24	Psoriasis	—	—	—	—	—	—
25	Pruritus	—	—	—	—	—	—
26	"	—	—	—	—	—	—

In squamous eczema the results of the complement fixation tests were generally negative; in vesicular eczema a number of positive reactions occurred, especially with the antigens of cocci and the acne bacillus. A few of the cases of furunculosis reacted positively with the cocci antigens and scattered positive reactions with the various antigens occurred in a few of the other diseases, as lupus erythematosus and sycosis vulgaris.

These reactions, along with those observed in acne rosacea and seborrhœic dermatitis, may be interpreted as indicating that the staphylococci and B. acne of the skin exert a pathogenic influence in various skin diseases other than acne vulgaris, although most intimately concerned in the latter.

V. In Syphilis and Non-Eruptive Diseases. As shown in Table 6, the sera of normal persons and persons suffering with non-cutaneous diseases did not absorb complement with any of the antigens.

Table 6. Complement Fixation Tests with the Bacterial Antigens and the Sera of Persons with Syphilis and Non-Syphilitic Diseases (No Cutaneous Eruptions).

			Antigens				
			1	2	3	4	5
No.	Diagnosis	Wass. React.	Staph. (Control)	Staph. (Acne)	B. Coli (Control)	B. Coli (Acne)	B. Acne
1	Syphilis	++++	0	—	0	—	—
2	"	++++	0	—	0	—	—
3	"	++++	0	—	0	—	—
4	"	++++	0	—	0	—	—
5	"	++++	0	—	0	—	—
6	"	++++	0	—	0	—	—
7	"	++++	0	—	0	—	—
8	"	++++	0	—	0	—	—
9	"	++++	0	—	0	—	—
10	"	++++	0	—	0	—	—
11	"	++++	—	—	—	—	—
12	"	++++	—	—	—	—	—
13	"	+++	—	—	—	—	—
14	"	++++	—	—	—	—	—
15	Acute arthritis	—	0	—	0	—	—
16	Cardio-renal	—	0	—	0	—	—
17	Carcinoma	—	0	—	0	—	—
18	Typhoid fever	—	0	—	0	—	—
19	Typhoid fever	—	0	—	0	—	—
20	Pneumonia	—	0	—	0	—	—
21	Diabetes mel.	—	0	—	0	—	—
22	" "	—	0	—	0	—	—
23	Normal	—	—	—	—	—	—
24	"	—	—	—	—	—	—
25	Carcinoma	—	—	—	—	—	—
26	Paralysis	—	—	—	—	—	—

We were particularly interested in the syphilitic sera, all of which yielded strongly Wassermann reactions. As noted in the table, none of these sera served to absorb complement with the bacterial antigens. One bacterial antigen of B. acne, grown in a fluid medium containing oleic

acid, showed a tendency to absorb complement with syphilitic sera, whereas an antigen of washed bacilli lacked this property.

These results further indicate that in the absence of cutaneous lesions, antibodies for the B. acne and staphylococci are absent; in involvement of the skin these microörganisms are apparently active, producing antibodies that were not found specific in any one disease, although occurring in best degree in acne vulgaris.

TABLE 7. SUMMARY OF RESULTS OF COMPLEMENT FIXATION TESTS IN ACNE VULGARIS, ETC.

Disease	Antigen	Total	Results. Number Positive	Number Negative	Per Cent. Positive
Acne vulgaris	Staph. (control)	25	16	9	64.0
	Staph. (acne)	57	36	21	63.1
	B. coli (control)	25	8	17	32.0
	B. coli (acne)	57	36	21	63.1
	B. acne	57	48	9	84.2
Acne rosacea	Staph. (control)	6	3	3	50.0
	Staph. (acne)	9	3	6	33.3
	B. coli (control)	6	3	3	50.0
	B. coli (acne)	9	5	4	55.5
	B. acne	9	6	3	66.6
Seborrhœic dermatitis	Staph. (control)	9	2	7	22.2
	Staph. (acne)	10	3	7	30.0
	B. coli (control)	9	1	8	11.1
	B. coli (acne)	10	4	6	40.0
	B. acne	10	3	7	30.0
Non-acneiform skin diseases	Staph. (control)	21	9	12	42.8
	Staph. (acne)	26	9	17	34.2
	B. coli (control)	21	3	18	14.3
	B. coli (acne)	26	4	22	15.3
	B. acne	26	5	21	19.3
Syphilis and non-eruptive diseases	Staph. (control)	8	0	8	00.0
	Staph. (acne)	26	0	26	00.0
	B. coli (control)	8	0	8	00.0
	B. coli (acne)	26	0	26	00.0
	B. acne	26	0	26	00.0

SUMMARY.

1. As based upon complement fixation tests with a monovalent antigen of B. acne (Unna-Sabouraud type), this bacillus, while apparently exciting most marked pathogenic effects in that group of lesions commonly spoken of as acne vulgaris, is also active in acne rosacea, sebor-

rhœic dermatitis and occasionally in such diseases as vesicular eczema, sycosis vulgaris, etc. This would seem to indicate that the bacillus is not specific for acne but may be a normal inhabitant of sebaceous follicles, capable of assuming pathogenic powers under favorable conditions in other skin diseases.

2. While we have used in the complement fixation tests a polyvalent antigen of cocci recovered from the pustules of acne, without attempting to identify any of those with the special coccus of Unna or the diplococci of Varney and Clark, the reactions indicate the activity of the cocci in an antigen in acne vulgaris and other pustular diseases of the skin and that an antigen of these cocci did not possess any degree of specificity over the control antigen of staphylococci from furuncles. This would indicate that the cocci recovered from the acne lesions were not specific for acne but belong to the family of Staphylococcus albus and aureus. Additional work is being conducted to further test the correctness of this opinion, by using monovalent antigens of different strains of cocci, from acne lesions.

3. The complement fixation reactions also tended to show the activity of colon bacilli in certain skin diseases, particularly acne vulgaris, acne rosacea and seborrhœic dermatitis. Dermatologists have suspected for many years that the disturbances of the intestinal tract have been a factor in the production of acne. It is interesting to note that this opinion, based upon purely clinical grounds, appears to be corroborated by the serological findings; almost two-thirds of the cases of acne give a positive complement fixation test with the bacillus coli obtained from the fæces of acne patients. In contrast with this, but 15% of non-acneiform skin affections give positive reactions with this bacillus and the non-eruptive controls which we have examined gave entirely negative results with this organism.

With a polyvalent antigen of strains of colon bacilli recovered from the fæces of persons suffering with acne vulgaris, the percentage of positive reactions and the degree of complement absorption were found to be higher than with the control antigens of colon bacilli from the fæces of normal persons, with the sera of persons suffering with acne vulgaris and seborrhœic dermatitis. In acne rosacea as also in the eczemas, there were evidences of the activity of colon bacilli as based upon positive complement fixation reactions, due, apparently, to the presence of antibodies in the serum, although the reactions with both antigens of colon bacilli were similar.

In what manner the colon bacilli are active in the pathogenesis of these various diseases of the skin we are not prepared to express an

opinion at this time, but the occurrence of complement absorption in these tests with antigens of B. coli indicate that these bacilli may exert a direct influence in the pathogenesis of some skin diseases.

At the present time, further work is under way to determine if definite strains of colon bacilli are to be identified with certain diseases of the skin and also a study of other intestinal bacteria in this relation.

4. We have prepared autogenous vaccines in accordance with the serological findings in individual cases; that is, if the serum of an individual with acne absorbed complement with the B. acne and B. coli antigens, the vaccine was prepared of these bacteria using an autogenous vaccine of B. coli and a stock vaccine of B. acne; if complement absorption occurred with all three antigens of staphylococci, B. coli and B. acne, the vaccine was prepared accordingly. Cases are being treated at present with vaccines by this method and the effects studied.

THE VALUE OF VARIOUS DIAGNOSTIC METHODS FOR THE CEREBROSPINAL FLUID.

By H. Nakano, M.D., Tokyo.
Instructor in Dermatology, Tokyo University.

(From the Dermatological and Urological Institute, Tokyo University.
Director, Prof. Dr. K. Dohi.)

For the detection of a syphilitic infection of the nervous system by means of an examination of the spinal fluid, the Wassermann reaction, the Nonne-Apelt globulin reaction, the lymphocytosis in the fluid, the Weil-Kafka hæmolysin reaction and Lange's goldsol reaction (*Berl. klin. Wchnschr.*, 1912, No. 19) are very valuable. But the views generally entertained respecting their scientific and practical value are widely divergent. We have attempted to determine this problem by means of the following experiments.

A. Concerning the Site of Production of the Antibody of the Wassermann Reaction in the Spinal Fluid.

Seven years ago we undertook, in the Dermatological Institute of Tokyo University, the investigation of the antibody of the Wassermann reaction in the spinal fluid, and obtained the following results.

Table I.

Classes of Disease	Number of Cases	Number	W. R. of Spinal Fluid Positive	W. R. of Spinal Fluid Negative	W. R. of Serum Positive	W. R. of Serum Negative
No syphilis	16	16	0	16	0	16
Syphilis I	3	3	0	3	1	2
Syphilis II	4	4	0	4	3	1
Syphilis III	7	7	0	7	7	0
Syphilis ?	5	5	0	5	2	3
		1	1	0	1	0
Metasyph.	11	4	0	4	0	4
		3	3	0	0	3
		3	0	3	3	0
Syph. cereb.	1	1	1	0	1	0
Tab. dorsal.	2	2	2	0	0	2
		1	1	0	1	0
Progressive	4	1	0	1	0	1
Paralysis		1	1	0	0	1
		1	0	1	1	0
Hemiplegia	1	1	1	0	0	1
Epilepsy	1	1	1	0	0	1

As shown in the above table, a positive Wassermann reaction in the spinal fluid is not always associated with a positive serum Wassermann reaction. Out of 11 cases of metasyphilis, one showed a positive Wassermann reaction in both fluid and serum; 4 cases were negative in both fluid and serum; 3 cases were positive in fluid and negative in the serum; 3 cases were negative in the fluid and positive in the serum, and none of 4 cases of paralytics was alike. Two cases of tabes dorsalis, one case of hemiplegia and one case of epilepsy showed positive reactions in the fluid and negative reactions in the serum.

What is the reason for these conflicting results in the reactions in the fluid and the serum? Some authors state that there is no production of local antibody in the subarachnoid cavity and the spinal cavity. Others maintain that there is no production of local antibody, but that the accelerated permeability of the blood vessels causes the same to penetrate from the blood to the fluid. The spinal cavity being connected with the lymphatic vessels of the peripheral nerves, it is very probable that the antibody of the Wassermann reaction enters the fluid from the blood. We already know that meningococci and the typhoid bacilli grow in fluid, and Bruynoghe, Cohen and Schurmann found that the complement fixation was applicable for diagnostic purposes by means of lumbar puncture in cases of epidemic meningitis. Therefore, although we are not yet able to determine the local production of antibody in the cerebrospinal cavity, this possibility may by no means be definitely precluded.

But the antibody of the Wassermann reaction is not identical with the local antibody produced in epidemic meningitis. Some years ago we made some experiments concerning the nature of the Wassermann reaction at the laboratory of Professor O. Bail in Prague, from which I concluded that "the antigen for complement fixation is contained in the organic cells, which, through the syphilitic infection, undergo a certain alteration and liberate pathological products. The latter subsequently enter the blood circulation and bring about the formation of an antibody. Thus, the antibody here represents an auto-antibody." It is therefore undeniable that the antibody of the Wassermann reaction enters into the fluid from the blood circulation.

The following is a very remarkable case. A patient, a farmer, 54 years of age, suffered from an ulcer of inveterate gumma on his right leg, in October, 1910, which subsequently repeatedly appeared in spite of medical treatment. At first the Wassermann reaction in serum was positive for a fairly long time, but the fluid reaction was negative. In January, 1911, the Wassermann serum reaction had likewise become positive. After 3 years, I had an opportunity of again treating the patient. The ulcer of his leg had quite healed, but the patient was now suffering from tabes dorsalis. The Wassermann serum reaction was negative, but the fluid reaction was positive.

I believe that in this case the Wassermann serum antibody was destroyed through the syphilis treatment, but that the fluid antibody had remained.

B. The Study of the Nonne-Apelt, Wassermann, Weil-Kafka and Lange Fluid Reactions, Compared with the Wassermann Serum Reaction.

We centrifugated about 10 cc. of spinal fluid which we had obtained through lumbar puncture (of course without admixture of blood) and with the sediments of the same we examined the Nonne-Apelt reaction. The difference between the positive and negative reactions is not easy to establish with this weak reaction, because the leucocytes appear in the same degree as in normal persons; but the result may be stated as positive, as the number of leucocytes was more than an average of two in a field. The Weil-Kafka reaction was taken in the original method, and in the Lange reaction it was quite analogous to the latter, but in the production of colloidal gold, we found that a 0.33% solution of formalin was better than a 1% solution (see *Berl. Klin. Wchnschr.*, 1912, No. 19, with regard to detailed information). The degree of the Lange reaction may be classified as follows: Strong reaction, if the color varies from an intense blue to a colorless and transparent hue produced by the marked flocculence; weak reaction, if it varies from a light blue to a strong blue. We here omit to mention the ascending and descending fluctuations, as the statements of the same are very troublesome. We examined 144 cases of nervous diseases and obtained the following results.

TABLE II.

Class of Disease	Number of Cases	Study of Fluid: Lymphocytos. Positive	Lymphocytos. Negative	Nonne-Apelt Reaction Strong	Nonne-Apelt Reaction Weak	Nonne-Apelt Reaction Negative	W. R. Positive	W. R. Negative	Weil-Kafka Reaction Comp. Loos.	Weil-Kafka Reaction Weak	Weil-Kafka Reaction Negative	Lange Reaction Strong	Lange Reaction Weak	Lange Reaction Negative	Study of Serum: Wassermann Reaction Positive	Wassermann Reaction Negative	
Dem. paral.	45	20	25	29	16	0	21	24	21	3	21	30	15	0	23	22	Here are 13 cases of the positive Wassermann reactions in fluid and negative reaction in serum.
Tabes dors.	3	2	1	2	1	0	2	1	2	0	1	3	0	0	0	3	2 cases of positive Wassermann reaction in fluid and negative reaction in serum.
Hemiplegia	1	1	0	1	0	0	1	0	1	0	0	1	0	0	0	1	Positive Wassermann reaction in fluid and negative reaction in serum.
Epilepsy	1	1	0	1	0	0	1	0	1	0	0	1	0	0	0	1	Positive Wassermann reaction and negative reaction in serum.
Metalues?	7	6	1	6	1	0	3	4	2	3	2	7	0	0	2	5	2 cases of positive Wassermann reaction in fluid and negative reaction in serum.
Brain lues	6	6	0	5	1	0	4	2	5	0	1	6	0	0	2	4	Complement reaction (also Weil-Kafka) appears in one case, very little.
Myelit. syphil.	4	4	0	4	0	0	1	3	2	1	1	4	0	0	2	2	3 cases of positive Wassermann reaction in fluid and negative reaction in serum.

TABLE II (*Continued*).

Class of Disease	Number of Cases	Study of Fluid: Lymphocytos.		Nonne-Apelt Reaction			W. R.		Weil-Kafka Reaction			Lange Reaction			Study of Serum: Wassermann Reaction		
		Positive	Negative	Strong	Weak	Negative	Positive	Negative	Comp.	Loos	Weak	Negative	Strong	Weak	Negative	Positive	Negative	
Mening. acuta	1	1	0	0	1	0	0	1	1	0	0	1	0	0	0	1	Mononuclear leucocytes show 25, an average in a range, and the complement reactions were very strong.
Tumor of eye or brain	3	2	1	1	1	1	0	3	0	0	3	2	0	1	0	3	
Lues?	5	1	4	1	1	3	0	5	0	0	5	1	1	3	3	2	
Lues I	5	0	5	0	1	4	0	5	0	0	5	0	5	0	1	4	
Lues II	11	4	7	4	2	5	0	11	0	0	11	5	1	5	9	2	
Lues III	10	7	3	3	1	6	0	10	0	1	9	4	0	6	8	2	
Lues hered.	1	0	1	0	1	0	0	1	1	0	0	0	1	0	0	1	
Lepra	16	4	14	8	2	6	0	16	0	0	16	8	1	7	0	16	
No lues and no nervous disease	25	2	23	1	9	15	0	25	0	0	25	1	7	17	0	25	

We treated some cases of tabes dorsalis and cerebral lues with salvarsan, mercury and iodine and after the treatment we found that the Lange, Wassermann and Weil-Kafka reactions in the spinal fluid were weaker. However, the weakening of the reactions does not follow promptly, but only after many weeks. The Wassermann reaction in serum disappeared very rapidly after treatment, but the reaction in the fluid less rapidly. We believe that the material which produces the Wassermann reaction enters into the fluid from the blood, from where it proceeds to the spinal cavity, and that it is thus not easily expelled by the antisyphilitic treatment. The following table shows the percentage of these findings obtained:

TABLE III.

Class of Disease	Number of Cases	Lymphocytes.		Study of Fluid: Nonne-Apelt Reaction			Study of Fluid: Wassermann Reaction		Study of Fluid: Weil-Kafka Reaction			Study of Serum: Lange Reaction			Study of Serum: Wassermann Reaction	
		Positive	Negative	Strong	Weak	Negative	Positive	Negative	Comp. Loos.	Weak	Negative	Strong	Weak	Negative	Positive	Negative
Cerebral and spinal disease	71	43 60.5%	28	55 69%	16	1	33 46.5%	38	35 49%	7	29	56 78.6%	15	1	29 40.8%	42
Lues (no nervous disease)	32	12 37.5%	20	8 25%	6	18	0 0%	32	1 3%	1	30	10 31%	8	14	21 65.6%	11
Lepra	16	2 25%	14	8 50%	2	6	0 0%	16	0 0%	0	16	8 50%	1	7	0 0%	16
No lues and no nervous disease	25	2 8%	23	1 4%	9	15	0 0%	25	0 0%	0	25	1 4%	7	17	0 0%	25

From the above table we see that the Nonne-Apelt reaction is obtained more clearly in the cerebral and spinal diseases than in any other disease of the nervous system. The Weil-Kafka reaction appears but rarely, namely, in but one-half of the cerebral and spinal diseases, while the Lange reaction appears in all diseases of the nervous system. As can be seen in the above table, the positive Wassermann reaction in the fluid appears in cerebral and spinal lues with the same frequency as it occurs in the serum in ordinary lues.

The Lange reaction in lues and leprosy is very remarkable. This reaction appeared in none of 5 cases of primary lues, 45% in 11 cases of secondary lues, 40% in 10 cases of tertiary lues, and 50% in 16 cases of leprosy; but in 25 cases showing neither syphilis nor any other nervous disease there was only 4% positive Lange reaction. Lange says: "Wenn man nun die verschiedenen Erkrankungsformen, die eine positive Goldausflockung geben können, nach ihrem Ausflockung-maximum gruppiert, so lässt sich bis jetzt anscheinend so viel sagen, dass die Lues auf der einen Seite sich in gewisser Beziehung von allen übrigen Erkrankungsformen absondert, die untereinander mit der bisherigen Technik nicht sicher zu unterscheiden sind."

Our experiments agree on the whole with the results of Lange. We think that there is a great difference between the nature of the Wassermann and Lange reactions. The Lange reaction is related to the globulin and nucleoprotein of serums, but the antibody of the Wassermann reaction consists not only of albumin, but also of other components, which we cannot yet clearly describe. The Lange reaction appears with a higher percentage than in leprosy in all cerebral and spinal diseases, as well as in primary and secondary lues. The general symptoms (fever, gastrointestinal disturbances) frequently occur during the latent period of secondary lues, and during the period of malignancy, slight swelling of the liver occurs; it is, therefore, not remarkable that globulin and nucleoprotein appear in the spinal cavity during secondary lues.

Conclusions.

1. The Wassermann reaction in the spinal fluid in late syphilis, as well as in cerebrospinal lues, tabes dorsalis and dementia paralytica rapidly disappears, but the serum reaction remains for a long period.

2. The substance causing the complement fixation in the spinal fluid probably enters the fluid from the blood, but we are not yet able to determine whether the antibody of this reaction is produced in the fluid itself.

3. The Nonne-Apelt reaction frequently appears in the cerebral and spinal diseases.

4. The Weil-Kafka reaction appears in acute and chronic inflammations in cerebrospinal and meningeal diseases (lues, general paralysis, tabes dorsalis and acute meningitis).

5. The Lange reaction appears in almost all cerebral and spinal diseases. The nature of the Lange reaction is closely connected with the presence of globulin and nucleoprotein in the fluid. It is very difficult to determine the difference between lues and other diseases. But in cases which have been proclaimed to be luetic by other diagnostic methods, the Lange reaction may be used to determine the early involvement of the nervous system of a syphilitic patient, since it is more sensitive than other reactions.

6. Nonne-Apelt, Wassermann, Weil-Kafka and Lange reactions disappear by degrees under treatment with salvarsan, mercury and iodine.

Bibliography.

1. Nakano, H. A Study of the Wassermann Reaction. *Dermat. u. Urol. in Japan.* 1910 and 1911, x and xi.
2. Nakano, H. Über die Immunisierungsversuche mit der Spirochätenreinkultur. *Arch. f. Dermat. u. Syph.*, 1913, cxvi, No. 1.
3. Nakano, H. Experimentelle und klinische Studien über Kutireaktion und Anaphylaxie bei Syphilis. *Ibidem*, 1913, cxvi, No. 2.
4. Nakano, H. Untersuchungen über das Wesen der Wassermann Reaktion. *Ztchr. f. Hyg. u. Infektionskr.*, 1913, lxxvi, No. 1.
5. Nonne-Apelt. *Arch. f. Psych.*, xliii, No. 3.
6. Nonne-Apelt. *Neurolog. Centralbl.*, 1908, No. 4.
7. Weil-Kafka. *Wien. klin. Wchnschr.*, 1911.
8. Liefmann u. Cohn. Das Verhalten des Komplementes zu den ambozeptorbeladenen Blutzellen. *Ibidem*, 1911, xi.
9. Halpern. Experimentelle Studien über die Antikörperbildung gegen Gewebe des eigenen Organismus. *Ibidem*, 1911, xi.
10. Bruynoghe. *Centralbl. f. Bakt.*, 1911, lx.
11. Cohen. *Bull. Soc. r. d. sc. med. et anat. de Bruxelles*, 1908, No. 8.
12. Schürmann. *Münch. med. Wchnschr.*, 1908, No. 43.
13. Wile, U. J., and Stokes, J. H. *Jour. Cutan. Dis.*, September, 1914.

DERMATITIS REPENS; REPORT OF TWO RARE CASES.*

By H. J. F. Wallhauser, M.D., Newark.

In *dermatitis repens,* Crocker established a definite form of pustular eruption in which an injury precedes its development. The condition, though rare in dermatological practice, is apparently of quite common occurrence in surgical experience; at least such was my personal observation while connected with a surgical outdoor clinic some years ago, in which it was my privilege to observe some twenty cases. In all these cases, there was a uniformity in clinical manifestations, always running the typical course of spreading pustular lesions undermining the epidermis, which on removal exposed a red, raw, oozing surface with a depressed border, covered with a creamy white exudate.

Microscopical examination of the exudate varied only slightly, generally showing the presence of the Staphylococcus albus; in a few cases the Staphylococcus aureus was present, and occasionally a streptococcus, but as a rule the Staphylococcus albus predominated, and in some cases a pure culture on glycerine agar was developed.

In this group of cases, the distinctive features were those of a spreading dermatitis, undermining several layers of the epidermis in a pustular, spreading eruption, progressing rapidly to involve large areas of the skin, in some cases beginning on the finger and involving the whole hand, wrist and part of the forearm, in a week or two, clearly defining a specific type of eruption.

We next find a confliction in placing under this head a dry form of the disease, also a similar spreading eruption, under the title of acrodermatitis perstans, being considered as in some way related. Having had an experience with both of these types, I was prompted to give this brief résumé.

The description of the dry form by Crocker was based upon an observation of three cases in which the main clinical feature of extension under the epidermis occurred, but varied, in that the centre of the lesion was dry throughout and peripheral extension was slower, one case lasting two years. A history of syphilis was present in two cases and

* Read before the 39th Annual Meeting of the American Dermatological Association, New York City, May 13-15, 1915.

could not be excluded in the third. Syphilis as the underlying cause, however, in these cases was excluded on the ground that they failed to respond to specific treatment.

In the case here reported syphilis was strongly manifested. The patient was a male, aged 62 years, who was being treated for a gummatous ulceration of the lower extremity, when the soles of the feet became involved in a spreading dermatitis, the lesions assuming identically the clinical appearance of dermatitis repens, except that the centres dried and exfoliated, or remained scaly as they advanced peripherally; extension, however, was much slower than in dermatitis repens, advancing about one-fourth of an inch in a period of four or five weeks; the whole process giving the impression of a less acute grade of inflammation.

As in Crocker's experience, the remedies employed in dermatitis repens, together with oral medication for syphilis, did not have the slightest effect in arresting the condition, which progressed and involved the entire soles of both feet, extending to, but not involving, the dorsal surface, remaining confined to the thicker epidermis of the plantar surface. Continuing thus for more than a year, it finally yielded, along with the ulcerations of the leg, to intramuscular injections of gray oil. From clinical observation, the resemblance to dermatitis repens was remarkable, but we are hardly justified in so classing it, when we take into consideration its slow progress, resisting all forms of local antiseptic measures, and finally yielding to intensive mercurial treatment.

Hallopeau, under the title of acrodermatitis continués (acrodermatitis perstans), described a similar spreading eruption in which the initial lesions were located chiefly on the hands, secondary eruptions occurring on any part of the body by the development of fresh foci. Hallopeau recognized three varieties,—a vesicular, bullous and pustular—also variant forms of secondary manifestations.

Regarding the primary lesions as compared to dermatitis repens, no distinguishing features are recognized; the difference between the two conditions consisting in the development of secondary manifestations, in acrodermatitis perstans, by fresh foci at points distant from the original lesion, being thus continued for indefinite periods of months or years. The secondary manifestations likewise vary, a desquamating, erythematous eruption and fatal impetigo herpetiformis having been observed.

In the following case the lesions were always the same, and while extension from the original site occurred, involvement of new locations followed an injury, the latter being of such a trivial nature as to be readily overlooked.

Case Report.

The patient was a male, aged 53 years, presenting a skin affection of nine years' duration. At the onset, it consisted of several blisters on the dorsal aspect of both hands, which disappeared in several weeks under local treatment. His family physician diagnosed the condition as "ivy poisoning." About a month later he had a recurrence which ran about the same course; following this, as one outbreak subsided, another developed, and during the succeeding years he was never entirely free of eruption. For several years it was limited to the hands, gradually the neck, face and edge of the scalp becoming involved. After several attacks the patient noticed that an injury, such as a pin prick or scratch, preceded the outbreak, or if a flying particle of stone struck him, which frequently occurred in his occupation as a stone cutter, a blister would develop at the site of injury, which, rapidly becoming pustular, would spread peripherally from one to several inches in either direction. The tendency to recurrence in the scar tissue became more marked as time went on, so that if even a most insignificant flying particle of stone struck the location of a scar, it would be followed by an outbreak, involving the whole area of scar tissue in that particular location, before it was arrested.

When he came under observation, he presented a dermatitis involving the dorsal surface of the right hand; the centre was denuded of epithelium and oozing a thin, serous fluid; at the periphery the epidermis was undermined, and on removal presented the characteristic depressed border, covered with a creamy white detritus as seen in dermatitis repens. On the left hand, in the same location, also involving the neck, face and border of the scalp, pearly white scars marked the sites of previous involvement. In the location of the scalp, the hair follicles were destroyed, presenting a band-like patch of baldness, extending from the nape of the neck across the temporal and frontal regions.

Microscopical examination of the pus showed the presence of the Staphylococcus albus.

Treatment consisted of first removing all loosened epidermis, especially at the border; the parts were next washed with a solution of bichloride of mercury, 1 to 1000, followed by a dusting powder of aristol and zinc oxide; this was continued twice daily. All exposed parts, including the neck, face and hands being washed morning and evening with a 1% solution of betanaphthol in diluted alcohol.

Nothing unusual was noticed in the further progress of the case; at the end of a month the inflammation had entirely subsided. The patient was seen six months following the treatment, at which time he was entirely free of eruption, and, although during this time he had had slight skin injuries, they healed without becoming pustular.

From an observation of the progress of this case, it would seem hardly reasonable to separate it from dermatitis repens, as it was really continued over the long period of its duration by repeated injuries. However, an added predisposition must be granted on account of the trivial nature of these injuries, which was most pronounced in the scar tissue; in a new location, a vesicle or bulla frequently subsided without suppuration, which led to the possibility of the presence of a predisposition, as

seen in epidermolysis bullosa hereditaria. The patient was certain, however, that this peculiarity to the formation of blisters from slight injuries developed shortly after the initial attack of dermatitis, which can, therefore, be considered only in the light of an acquired tendency.

As to a distinction between dermatitis repens and acrodermatitis perstans, this case could be included in the latter; but if we consider the outcome, resulting in its cessation, following the application of an antiseptic plan of treatment, it should be considered as a case of dermatitis repens recurrens.

In concluding the subject, from a clinical viewpoint, we can easily accept Crocker's original description of dermatitis repens as an acute inflammatory process of definite cause, due to bacterial invasion of the lower layers of the epidermis.

The subsequent addition of a dry form of the disease, however, lacks confirmation. In all reported cases of this character the evidence is strongly in favor of syphilis as the underlying cause.

A chronic or recurring form should be considered in order to properly classify cases of the type reported above.

Discussion.

Dr. Ormsby said that he had observed several cases of this disorder, one of which was of the type described by Hallopeau, that involved not only the hands but spread to the body. In this case the patient eventually succumbed to a general exfoliative dermatitis.

During the early progress of the disorder, the lesions consisted of vesicles, which slowly spread over the hands. In about two years, and several months preceding its generalization, the lesions became scaly. All methods of treatment were resisted by the disorder, reminding one in this respect of parapsoriasis.

Dr. Stelwagon said that as yet dermatitis repens could not be considered a positive entity. A number of cases so classed had dissimilar symptoms. Some of the cases were probably not staphylococcic, and some will doubtless be found to be epidermophytic.

Dr. Wallhauser said that he had tried many different methods in these cases. The best results were obtained by keeping the edges well trimmed and the surface covered with a drying powder.

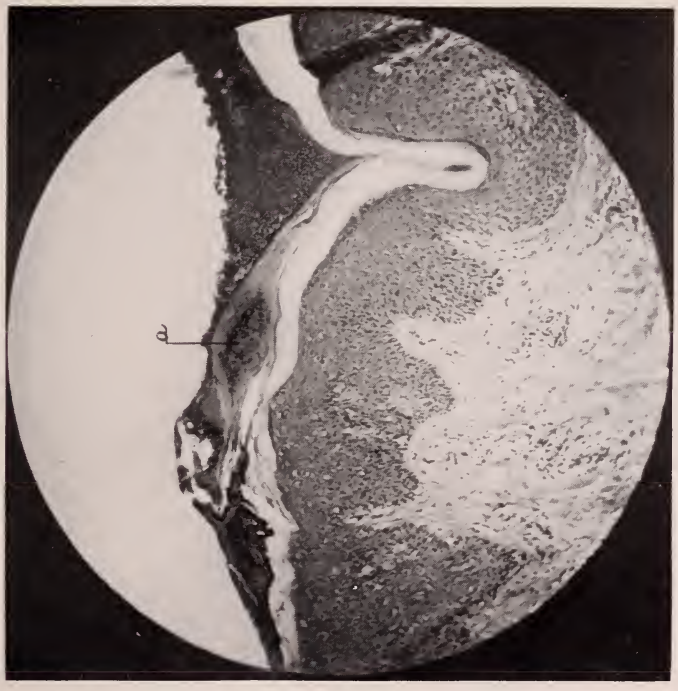

FIG. 15.
Psoriasis. Microphotograph from collection of Drs. Fordyce and MacKee, showing corneal abscess.

FIG. 14.
Psoriasis. Microphotograph from collection of Drs. Fordyce and MacKee. Early lesion.

FIG. 17.
Parapsoriasis. Microphotograph from collection of Drs. Fordyce and MacKee.

FIG. 16.
Parapsoriasis. Microphotograph from collection of Drs. Fordyce and MacKee.

FIG. 19.
Parapsoriasis. Microphotograph from collection of Drs. Fordyce and MacKee.

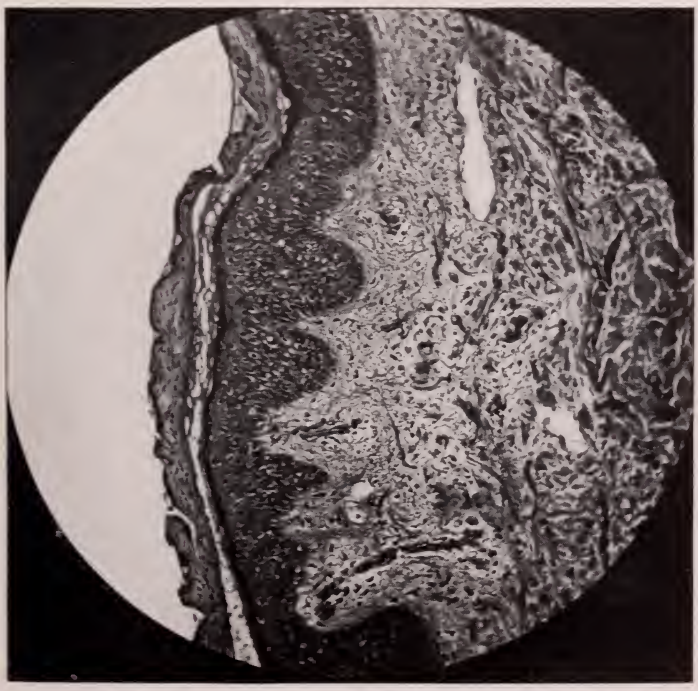

FIG. 18.
Parapsoriasis. Microphotograph from collection of Drs. Fordyce and MacKee.

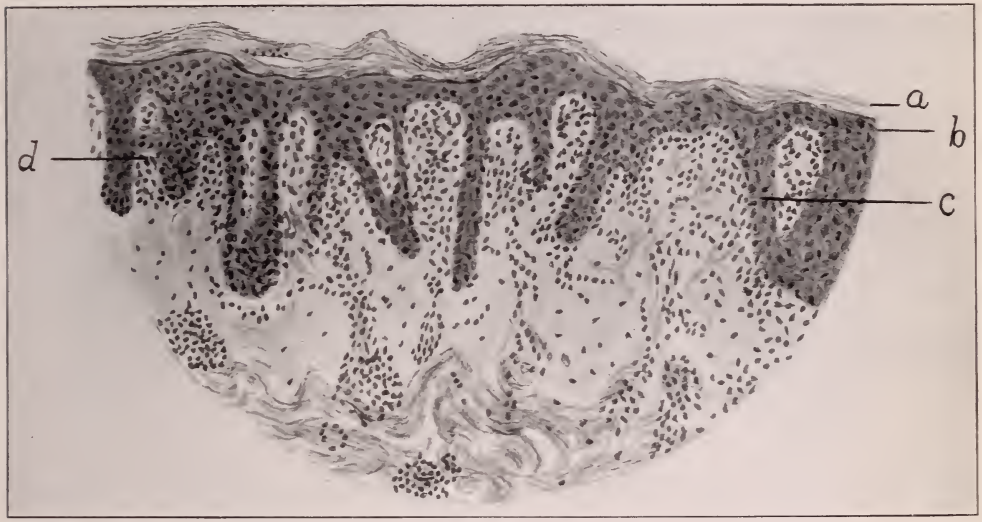

FIG. 20.
Parapsoriasis.

FIG. 21
Seborrhœa.

Plate XXIV.—To Illustrate Article on Histopathology, by Walter J. Heimann, M.D.

Fig. 22.
Seborrhœa.

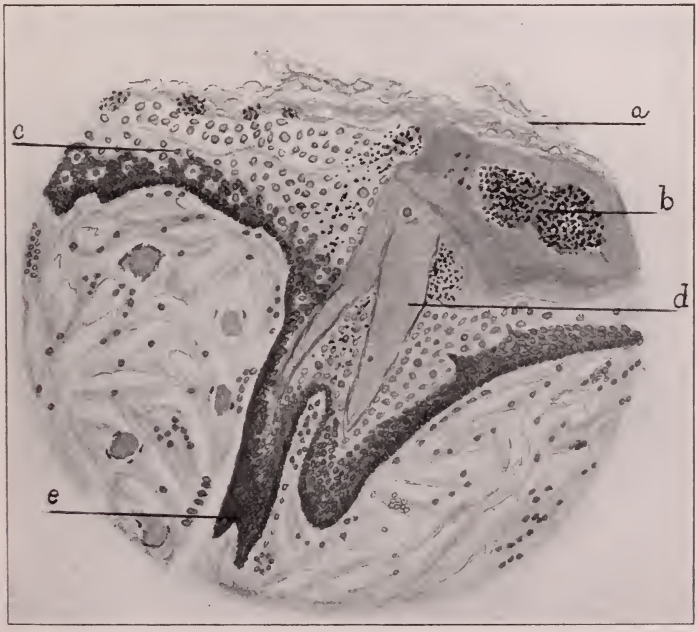

Fig. 23.
Seborrhœa.

FIG. 25.
Pityriasis rosea. Microphotograph from collection of Drs. Fordyce and MacKee.

FIG. 24.
Pityriasis rosea.

PLATE XVIII.—To Illustrate Article on Dermatitis Repens, by H. J. F. WALLHAUSER, M.D.

FIG. 1.
Showing scars of previous lesions.

FIG. 2.
Showing an active, spreading dermatitis.

THE MODERN TREATMENT OF BURNS.

By George de Tarnowsky, M.D., Chicago.

Surgeon to Cook County and Ravenswood Hospitals.

It is not my purpose to take up the elementary and well-known facts concerning burns of chemic, thermic or electric origin. I have elsewhere[1] taken up the behavior and treatment of electric burns. As indicated by the title, I shall devote my time to a consideration of the practical treatment of these injuries, basing my remarks on the experience acquired through the handling of several hundred electric burns, supplemented by experimental work done at Cook County Hospital.

I have nothing radically new to offer and no new theories to propound. Whatever has seemed to give the best results has been adopted, and all unnecessary measures have one by one been discarded, with a view to simplification of technique. The evolution in the treatment of burns parallels that of general surgical technique.

Our increasing knowledge of pathology and especially of tissue repair, has gradually led surgeons to rely more and more on nature and less on extraneous substances which tradition had handed down to us as more or less essential to success in the care of wounds. There is no longer any controversy over asepsis versus antisepsis; the latter has been weighed, found wanting and justly rejected. The only chemicals that can still be logically used are those which, while possessing a moderate bactericidal power, are mainly beneficial through their ability to induce local hyperæmia with its accompanying leucocytosis. Collodial silver and ether come under this class. Theoretically, every burn might be considered as a sterilized wound; practically, it must be treated as a potentially infected one because of the contact with hands, cloths, handkerchiefs, etc., which it has been subjected to before the physician can take charge of the case. The problem is therefore primarily a two-fold one; we desire to remove infective material, while we must at the same time avoid the destruction, mechanically or through powerful antiseptics, of cells which are still living. All violent scrubbing with green soap and brush; all powerful antiseptics such as bichloride or cyanide of mercury, phenol or picric acid solutions, should be given up. Their use is illogical and based on ignorant tradition.

Let us begin with a burn of the first degree: One or possibly two layers of the epidermis are involved. The papillary layer of the corium is intact; the tactile bulbs are not affected or are only slightly hyperæmic, hence the pain is not severe. Unless the burnt area is very extensive there is no danger of toxæmia through absorption of secretions from the sweat and sebaceous glands. The deeper layers of the epidermis—under stimulus of the hyperæmia present—will rapidly replace the burnt superficial cells with a resulting *restitutio ad integrum.*

Is it logical to scrub off the deeper layers of epidermis with soap and brush or soap and gauze?; is it intelligent to destroy these same epidermal cells through the use of strong antiseptics? We have long since discarded both of these methods as obsolete. Our technique for a burn of the first degree is the following: As a prophylactic measure, employees of the Northwestern Elevated Railway Company have been repeatedly warned not to apply anything but vaseline to a burn, covering the burnt area with gauze and sending the patient to our office. With small gauze sponges, soaked in ordinary commercial ether,[2] the area beyond the burn is gently but thoroughly cleansed of all grease and dirt. A fresh, ether-soaked sponge is then gently sopped—not rubbed—over the burnt area, which is covered with a coating of equal parts of zinc oxide and cold cream ointments, to which white precipitate of mercury is added, in the proportion of one half drachm to the ounce. (White precipitate is an insoluble compound, having no bactericidal power, but largely used in dermatology as a stimulating powder or ointment in lupus erythematosus, impetigo and psoriasis. It also seems to have a decided anti-pruritic value). Over this a sterile gauze compress and bandage are placed. In the absence of severe pain or a rise in temperature, this dressing is not removed until *restitutio ad integrum* has occurred. There can be no valid reasons, other than the pain and fever already referred to, for changing the dressings of a first degree burn. Lejars[3] is most emphatic on this point. He says, in substance, "Leave the dressings untouched as long as possible, 8, 10 to 12 days, if there is no rise in temperature. This is applicable to burns of any degree."

Severe pain denotes that blebs under high tension are present or that the dressing and bandages are interfering with venous and lymphatic circulation. Painless blebs should be left alone; if the pain of tension manifests itself, they should be emptied. The dressing for a burn of the face should consist of a gauze mask with holes corresponding to the eyes, nostrils and mouth; the ointment keeps the central part of the gauze in place while a chin and forehead bandage prevents the edges

from falling away. For fastidious patients, who sometimes object to the odor of old dressings, I advise a stearate of zinc dusting powder or a spray of perfume applied directly on the dressings.

Clinical experience has amply proven that, under careful hospital supervision, burns will heal more rapidly if exposed to the air. For burns involving either the upper or lower extremities, screen cages in which the burnt extremity is placed, are now being used at the Cook County Hospital. Where the burn involves the entire circumference of the limb, the latter is slung up by means of gauze bands so that the burnt area does not come in contact with either the sides or bottom of the cage. Stearate of zinc or bismuth is dusted over the burnt area and nature does the rest. In private practice this method is seldom feasible, hence the protective ointment and dressings.

With burns of the second degree, the problem is enlarged by the presence of two new factors. The first is pain, which is at times intense. Whenever the burnt area presents an irregular surface, composed of minute elevations which bleed readily, we know that the entire epidermis has been destroyed, leaving exposed the papillary layer of the corium. Each elevation consists of bundles of fibro-elastic tissue supporting vascular loops, together with terminal nerve-end bulbs (tactile corpuscles of Meissner). Exposure of these end-bulbs to the atmosphere is the chief cause of the severe pain of second degree burns. The second factor is the process of repair. Can we allow connective tissue cells to replace the epidermis or must we replace burnt epidermal cells by grafts of the same type of cells? The location of the burn, its extent, and cosmetic considerations must decide the question. If the burn is on the trunk or involves portions of one or more extremities, fairly remote from joint surfaces, connective tissue healing, though less rapid than grafting, is still permissible. All second or third degree burns of the face, neck, hands, feet, or situated in the immediate neighborhood of joints, must be grafted. The relief of pain must be obtained by means of some application which will protect the terminal end-bulbs from contact with the atmosphere until either connective tissue repair has taken place or epidermal cells have been grafted on.

The most potent protectives are amniotic grafts, pure vaseline or the white precipitate compound ointment used in the treatment of first degree burns. If scar tissue is selected as the means of repair, the burnt area should not be covered by dressing—or at least the gauze should not come in contact with skin. Here again the open treatment is best. For the protection of the tactile end-bulbs and checking of pain, the choice lies between amniotic membrane and the white precipitate com-

pound ointment. When first advocated, it was believed that the embryonal epithelial cells of the amnion were capable of forming permanent grafts; *i.e.*, it was thought that these embryonal cells would eventually mature and assume the functions of normal epithelial cells. This belief is now untenable. That amnion will live when grafted on a burnt area is undoubtedly true; that the cells die, to be ultimately replaced by connective tissue is unfortunately equally true. We gave amniotic grafts a thorough test on my service at the Cook County Hospital; the longest time a graft lived was seven weeks. This was a case of phosphorus burn involving the entire right gluteal region and outer surface of the thigh. We ultimately had to resort to Thiersch grafts in order to assure free motion of the hip joint.

Certain precautions should be observed when using amnion:

1. A negative Wassermann test must be obtained from the mother in all doubtful cases. This was a routine measure observed in all of our County Hospital experiments. This might be dispensed with, where the donor is well known to the physician, yet the possibility of luetic transmission must be thought of.

2. The entire amniotic sac should be cut away from the placenta, placed in sterile physiological salt solution and kept in the refrigerator until used. This should be done immediately after expulsion of the secundines. If the amnion has to be preserved for several days, Carrell[4] recommends petrolatum and Ringer's solution,* in which the membrane is immersed and kept at a temperature of 36° to 40° F.

3. It is not necessary to separate amnion from chorion. The amniotic sac is a smooth glistening membrane composed of two layers which are loosely connected and which can be freely moved by rolling between the thumb and index fingers. The outer layer, of chorionic origin is made up of a single layer of cuboidal epithelium. This is the side which should be laid against the denuded burnt area, as it is simply an extension of embryonic skin.[5] The smooth, glistening surface of the joint membrane is applied directly on the burnt area, the rough, inner layer remaining outside.

4. The membrane must be cut into its proper size or sizes while immersed in warm saline solution, as it is impossible to handle if not thoroughly moist.

5. It may be cut into strips of varying length and widths, but it is simpler to cover the entire burnt area with one single piece. Strips of gutta-percha tissue are laid over the margins—if the open treatment is to be followed—or at right angles over the entire area, if gauze dress-

* NaCl. 0.7% KCl. 0.03% CaCl. 0.025%.

ings are to be applied. Carrell fixes the grafts to the granulating surface by means of a warm mixture consisting of:

> Eighteen gms. paraffin, melting at 52° C., 6 gms. paraffine, melting at 20° C., 2 gms. beeswax and 1 gm. of castor oil. This is applied, while warm, with a camel hair brush.

We rejected this method because it must, of necessity, lock up secretions; it also unnecessarily complicates technique. These gauze dressings should be changed as seldom as possible, and unless lack of drainage and consequent pain demand it, the layer of gauze next to the burnt area should not be removed, but merely covered by fresh pieces of gauze. We would strongly advise those physicians who still change dressings daily or even twice daily, to take one of the gauze dressings which they have just pulled from a burnt area, wash it in physiological salt solution and examine the solids under the microscope. Perhaps the sight of countless new connective tissue cells which have thus been torn off and destroyed, may prompt a change of treatment.

The open method obviates this constant loss of new cells; drainage is excellent and healing proceeds rapidly. Where, for reasons previously enumerated, scar tissue repair is not desirable, skin grafting should be resorted to, as soon as primary shock is overcome. Small defects involving fingers, hand or forearm can easily be covered by skin flaps taken from the abdomen or flanks by the classical two-step or Italian method, allowing an interval of ten days to elapse before final separation of the base of the flap. Capillary continuity is more rapidly reformed if the subcutaneous adipose tissue is not removed from the flap; hot moist dressings for 48 hours maintain hyperæmia and are therefore beneficial.

The one-step method of transplanting pieces of skin to the burnt area may be successful if the vascularity of the part is great or intense hyperæmia can be maintained; it is never as reliable as the two-step method and should be resorted to only when the burnt area can not be brought into close proximity to the abdomen, flanks or an upper extremity. Heterogeneous flaps of skin occasionally take. Four years ago I successfully transplanted a piece of skin, covering an interscapular lipoma in a young woman, on to a third degree burn involving the cheek—including the outer table of the malar bone—of a switchman who had first suffered a Pott's fracture and then fallen downwards on to the "third rail," where he lay for several minutes. The ultimate usefulness of heterogeneous grafts, of whatever variety, will always remain an uncertain quantity. Many of these grafts will break down and disappear, months after they have apparently taken.

Homogeneous grafts, on the other hand, when sufficient blood supply

has been provided for them, permanently live. Only in those cases where the grafting had been done late, *i.e.*, after granulations have become vigorous, do the homogeneous Thiersch or Reverdin grafts die, after apparently taking. The explanation of this necrosis lies probably in the fact that, as the abundant granulations contract under the grafts, the circulation of the latter is gradually shut off. This should prompt us to apply our grafts as soon as primary shock has abated.

It is an error to think that grafts cannot live if there is any pus present. I have repeatedly proven the contrary to be true. Grafts die, either from primary inadequate blood supply or because capillarity has been interfered with by compressive dressings. The ideal after-treatment consists in lightly applying thin strips of gutta-percha tissue over the grafts, in order to prevent their slipping, and then protecting the burnt area by means of a wire netting cage. If dressings must be applied, the gauze should first be covered with vaseline and then gently laid on the grafts (which have previously been protected by gutta-percha strips); the outer bandage should also be very loosely applied. These dressings are changed as seldom as possible. My associate, Dr. Dale, is at present carrying out some experiments with a view of devising some form of dressing which will allow free drainage of secretions, while acting as a non-adherent protective. The following mixture is, at present, giving satisfactory results: White precipitate of mercury, 1 drachm, white wax, ½ ounce, zinc oxide ointment, 1½ ounces. This is first liquefied and sterilized by boiling; then strips of gauze of varying width and length are dipped in the boiling liquid, held up by forceps in order to allow the excess to drain off and placed in sterile Mason jars, which are at once sealed up for future use. Ambulatory patients find these dressings very comfortable.

Third degree burns often lead to the formation of deep contractures which may totally or partially incapacitate an extremity. Their management will tax the ingenuity and resources of the surgeon to the utmost, involving, as they perforce must do, a consideration of nerve transplantation and of tendon lengthening, shortening or transplantation. These details do not properly belong in our paper and are therefore purposely omitted.

Summary.

1. Leave burns of the first degree to nature as far as possible.
2. In burns of the second degree, decide early whether to resort to skin grafting; if deemed necessary, apply the grafts as soon as shock has abated, even in the presence of pus.

3. The open-air treatment of burns of all degrees gives the best results.

4. If the open-air treatment is impossible to carry out, apply a bland, non-adherent dressing and leave the dressing on as long as possible.

5. In all second and third degree burns, pain must be overcome by protecting the exposed tactile bulbs. Amniotic membrane or a bland, non-irritating ointment will give the best results.

References.

[1] Tarnowsky, G. de. Commercial Electricity and Its Dangers. *Ill. Med. Jour.*, November, 1906.

[2] Tarnowsky G. de. Sulphuric Ether Lavage in Infections. *Jour. A.M.A.*, Jan. 24, 1914, p. 281.

[3] Lejars. Urgent Surgery. ii, p. 506.

[4] Carrell. Preservation of Tissues and Its Application in Surgery. *Jour. A.M.A.*, 1912, lix, p. 523.

[5] Stern, M. The Grafting of Preserved Amniotic Membrane to Burnt and Ulcerating Surfaces. *Jour. A.M.A.*, 1913, lx, p. 973.

CLINICAL REPORTS

RHINOSCLEROMA: PROGRESS NOTES ON A CASE PREVIOUSLY REPORTED.

By Harry E. Alderson, M.D., San Francisco.

(From the Dermatological Clinic, Stanford University Medical School, San Francisco.)

In the April, 1914, issue of The Journal (p. 308) there appeared a detailed report of the first case of rhinoscleroma,* recorded on the Pacific Coast. (A Case of Rhinoscleroma: Treatment With Autogenous Vaccine).

The patient had typical lesions involving and closing the entire left nasal cavity and showing also a small growth above the left ala nasi. The clinical diagnosis was amply confirmed by the histopathological and bacteriological findings. An autogenous vaccine was made and five injections of the same were given. The growth, however, slowly but surely increased in extent, although the secretion became somewhat diminished. The accompanying photograph (Fig. 1) shows the process as it appeared at that time. The patient went to the mountains and did not return to us for thirteen months. It was then observed that the disease had extended across the septum and the floor of the right nostril and the thickening of the hard palate had increased markedly.

Cultures made by Dr. E. C. Dickson again showed the rhinoscleroma bacillus to be present.

One injection of a freshly made autogenous vaccine (125,000,000 dosage) was followed by no results of note, excepting a painful local reaction. The patient refused to have further vaccine therapy. He was seen by Prof. Dr. G. Arndt (of Berlin), who was then in San Francisco, and radiotherapy was advised.

Roentgen therapy (Coolidge tube, with five-inch spark gap, the target ten inches from the lesions and an aluminum filter, 1 mm. thick, interposed) was then carried on by Dr. W. W. Boardman, as follows:

* Stanford University Medical School, serial number 1228-14.

June 1, 1914	30	milliampere	minutes
" 11	"	"	"
" 15	"	"	"
" 16	"	"	"
" 17	"	"	"
" 18	"	"	"
" 19	"	"	"
Total:	210	"	"

The external lesions soon began to shrink and the secretion became noticeably less.

The lesions on the palate were treated with the same technique as follows:

July 23, 1914	20	milliampere	minutes
" 24	12	"	"
" 31	12	"	"
Total:	44	"	"

On August 18th, 1914, it was noted that all of the lesions (cutaneous and mucous membrane) had shrunk considerably and had a much cleaner appearance than before. Roentgen therapy, as before, was administered to the amount of 52 milliampere minutes.

In September, 1914, he was given, in three treatments, 52 milliampere minutes of X-ray.

He left for the mountains and did not return until June, 1915, when the following history notes were made and the photograph (Fig. 2), published herewith, was taken.

June 25th, 1915. "The lesions on the outer surface of the nose and upper lip and tear duct have completely disappeared, leaving somewhat depressed and puckered cicatrices. On the hard palate there remains thickening, with one superficial, dime-sized ulceration. There is a purulent discharge from both ears, suggesting involvement of the nasopharynx."

Cultures of this pus (made by Dr. E. C. Dickson) again showed the presence of the rhinoscleroma bacillus.

An examination in the ear, nose and throat clinic, by Dr. H. B. Graham, disclosed the following: "Double chronic suppurative otitis media. Healed ulceration of the soft palate. The palate is much thickened, producing a stenosis of the nose posteriorly. There is much pus in the nose on both sides."

During the patient's long absence he had applied no treatment to his lesions, but had led an active out-door life on a mountain ranch.

It was decided to try *deep* Roentgen therapy with the Coolidge tube as before, the circuit having a resistance equal, this time, to a six-inch spark gap.

Accordingly, in June, 1915, the patient was given 120 milliampere minutes. Shortly thereafter, he returned to the mountains where probably he will remain for six or seven months.

COMMENT: It is very evident from the *complete eradication* of the process on the nose, lip and external tear duct by Roentgen therapy, that wherever it is possible to apply this agent accurately, rhinoscleroma can be cured thereby.

FIG. 1.
Showing the lesion before treatment.

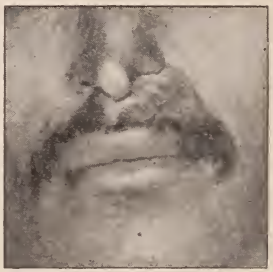

FIG. 2.
Showing complete eradication of the visible lesion by Roentgen therapy (Coolidge tube).

A CASE OF POSTVACCINAL PSORIASIS.

By John E. Lane, M.D., New Haven.

The appearance of new patches of psoriasis at the seat of vaccination or of other mechanical injury is not very uncommon in patients who are in full eruption, or who have had the disease previously. On the other hand, psoriasis which originates immediately after vaccination, and is located at the point of vaccination, in a subject previously immune, is quite rare. The first mention of this occurrence that I have been able to find was made by Gaskoin, in 1873; while Klamann, in 1879, was the first to report a case in detail. Several other observers have published one or two cases each, and Blanc, in 1907, collected nineteen cases, including his own and those previously published. Some cases have also been reported since then.

Fig. 1.
Showing psoriatic lesions in the neighborhood of the vaccination scar.

At first the question of the possibility of the inoculation of psoriasis was considered. Though it is possible that vaccination may determine the time of the outbreak of psoriasis in a predisposed individual, there is now believed to be no causal relation between them.

The following typical case was recently seen in the Dermatological Clinic of the Yale Medical School.

Julia K., six years old, was born in this country, of Polish parents. Her general health was always good. She is one of eight children. A sister of twelve years had a mild attack of psoriasis a year and a half ago. This yielded readily to treatment. The patient was vaccinated during the latter part of September, 1914, and the course of the vaccination was normal. A few days after the scab had fallen off, a spot of psoriasis appeared at one side of the scar, and advanced until the scar was completely surrounded. Two or three weeks later other lesions appeared in the immediate vicinity, and after some delay, spots appeared one by one on other parts of the body.

SPECIAL ARTICLE

HISTOPATHOLOGY.

(*Continued from February number, page 114.*)

By Walter J. Heimann, M.D., New York.

(From the Departments of Dermatology and Pathology, Cornell Medical School.)

Chapter III.

Scaling Inflammations of the Psoriasiform Type.

Although the sequence would be more logical if the congestions and exudative inflammations were first described, the histological changes of the scaling inflammations are so much simpler to grasp that it seems wiser to begin the special study of skin pathology with this group. Two types are included under this heading—the psoriasiform and the erythrodermial. The former comprises psoriasis, parapsoriasis, seborrhœa and pityriasis rosea; the latter, the exfoliating erythrodermias, Ritter's dermatitis exfoliativa neonatorum and Leiner's erythrodermia desquamativa neonatorum. The exfoliative stages of vesicular and bullous diseases do not belong in this group.

The diseases enumerated possess many common as well as individual features. In the epidermis, hyperkeratosis and parakeratosis are present, as well as more or less acanthosis. In some of the conditions, microscopic epidermal abscesses exist. In the papillary body, as well as deeper in the corium, there are blood and lymph vessel dilatation, accompanied by other vascular changes, and infiltrations varying in type and degree. The connective tissue suffers some alteration, while in seborrhæa, the coils and hair, and in some of the erythrodermias other skin adnexa as well, are disturbed. The combinations in which these features are associated constitute the special microscopic pictures of the various diseases, but they are, at best, none too distinctive.

Psoriasis.

There is a diversity of views on the histology of psoriasis. Hebra, Duhring, Cornil and Ranvier[1] regard the disease as vascular in origin, Unna,[2] Auspitz, and Robinson,[3] as epidermal. The majority of authors favor Hebra's views, locating the beginning of the process in the papillæ, and regarding the epidermal changes as consecutive, explaining the sequence, however, in a variety of ways. Kromayer[4] believes that the first changes are a congestion in the papillary vessels about which an infiltration forms. He further believes that this vascular disturbance, accompanied as it is by papillary œdema, favors epidermal proliferation. The epidermal findings are hyperkeratosis, parakeratosis, acanthosis and the presence of wandering cells and microscopic abscesses.

Unna[2] emphasizes the hyperkeratosis and parakeratosis and finds that the scales resist hydrochloric acid and pepsin digestion. Ehrmann and Fick[5] lay more stress on the parakeratosis, as do Kopytowski,[6] Munro,[7] and Sabouraud,[8] who regard it as a reaction to the wandering cells in the epiderm. Ehrmann and Fick[5] find the stratum granulosum variable in thickness and broken in continuity, a view confirmed by Grosz.[9] Suchard, quoted by Unna, states that the stratum granulosum decreases as the scale develops. Neumann finds it increased; Sellei, according to Grosz,[9] finds the stratum lucidum increased, while Ciliano and Wile[10] maintain that it is absent. All of these authors agree on the presence of acanthosis, some holding that it is the result of the increased size of the papillary body, others, that the increased size of the papillæ is due to the downward proliferation of the rete pegs. Auspitz particularly favors this idea. Ehrmann and Fick[5] find lengthening without broadening of the rete pegs.

Kromayer[4] points out the presence of wandering cells or leucocytes in the epidermis, arising from the congested papillæ, as do Jarisch,[11] Kopytowski,[6] Munro[7] and Sabouraud.[8] Opinions are unanimous as to the vascular source of these cells. They tend to collect and form microscopic abscesses, and they are associated with the enumerated epidermal changes. Mantegassa[12] particularly points this out, and Kromayer, Munro and others agree with him. Jarisch[11] thinks that the number of leukocytes bears a distinct ratio to the intensity of the process.

All authors, too, agree on the changes in the papillary body, namely, proliferation of collagen, dilatation of vessels, œdema and infiltration. Ehrmann[5] and Audry[13] find the papillæ long and thick, and the former states that they tend to acquire clubbed ends in old lesions which lead to the verrucous type of psoriasis. Ehrmann also finds dilatation of the subpapillary vessels, with an infiltration about them. The elastica and skin adnexa are not altered, and occasionally deep pigmentation follows the lesions.

Haslund[14] describes the histology of psoriasis excellently. The stratum corneum, he says, is twenty to thirty layers thick at the centre of the lesions, convex, and tends to become thin at the margin. Air spaces are present and at times whorls are formed. Parakeratosis is most marked in new lesions, and the stratum lucidum is interrupted. The stratum granulosum is normal. An acanthosis exists, due to disturbed balance between the papillary body and rete. It is uneven, and at times the rete overlying the tips of the papillæ is thin. The elevation of the lesions is due to the thickness of the scale rather than to the acanthosis, although, in old lesions the latter, too, plays a rôle, and reaches its maximum at the centre of the lesion. Intercellular œdema is found, often blurring the outline between the epidermis and the papillæ, particularly at the summits of the latter. Migrating cells are to be observed in the epidermis forming Munro's micro-abscesses, particularly over the tips of the papillæ.

The abscesses tend to rise as the epidermis proliferates and are sloughed off in the scales. In the papillary body an increase in size is found in accomodation to the enlarged rete pegs. Œdema and infiltration are present. The vessels are dilated, engorged, surrounded by a deposit of leucocytes and fibroblasts, and some of the leucocytes seem to be migrating, their objective being toward the epidermis. The elastica, skin adnexa and nerves suffer no change.

In describing the histologic changes of psoriasis it is best first to consider fresh and then older lesions. Whether the latter are guttate, nummular, circinate, gyrate or verrucous, the differences from fresh lesions that they display are of degree and not of kind. The fresh lesions are punctate, involving an area of skin corresponding in diameter to from four to twenty papillæ, and the three most striking features are the presence of a scale, acanthosis and changes in the papillæ. The scale is convex and thickest at the centre, at which point, too, acanthosis is most marked. (Figs. 1, 12 and 14.) The Scale is made mainly of hyperkeratotic cells, from twenty to thirty layers deep, and shading off to normal depth at the periphery. The layers of cells in the scale resemble, in arrangement, loose pie crust, and are wavy or whorl-like. At bottom of the scale parakeratosis (Fig. 1), in small and irregular areas, is to be seen. Below the scale is found a normal granular layer and below this the rete is found increased. The increase is due to a

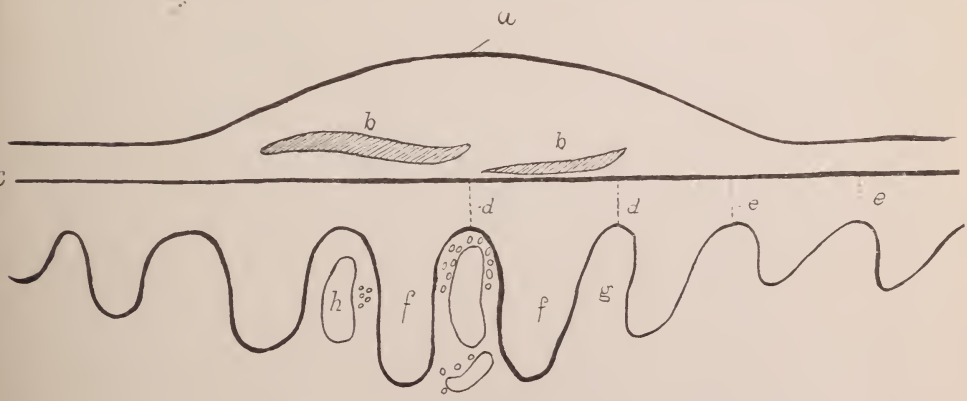

FIG. 1.
Fresh psoriasis papule (diagram).

a. Convex scale.
b. Parakeratotic areas.
c. Normal granular layer.
d. Malpighian layer above papillæ in the neighborhood of enlarged pegs of same depth as in normal region *e*.
f. Lengthened but not broadened rete pegs.
g. Papillæ, lengthened and broadened.
h. Dilated vessels with perivascular infiltration.

lengthening of the pegs, and not to a broadening of the suprapapillary area. In the centre of the lesion the pegs are uniformly long, and for the most part not markedly thickened. They often coalesce, however, and thus seem abnormal in breadth. A very slight intracellular œdema and a few migrated leucocytes are found. I have been unable to ascertain the presence of Munro's abscesses in the early stages of psoriasis. In some specimens, patches of intercellular œdema, suggesting *altération cavitaire,* may be found.

The papillary body is lengthened and broadened in compensation for the changes in the dimensions of the rete peg. The vessels in the papillæ and those of the subpapillary layer are dilated. The endothelium is slightly swollen and about it is seen an infiltration of round cells looking like lymphocytes, and many fibroblasts. Here and there leucocytes are to be observed in the act of migrating from the papillæ to the epidermis. The vascular changes and infiltration in the papillary body are the more intense. The collagen bundles are œdematous and some are stained faintly. The lymphatics are slightly dilated. The elastic tissue and skin adnexa remain undisturbed.

Older lesions (Figs. 1, 2 and 13) show the same features to a more marked degree. Obviously, because of the larger size of the affected skin, more papillæ are included. The scale covers it entirely, is no longer convex, and consists of hyperkeratotic and parakeratotic cells, among which are migrated leucocytes and an occasional microabscess, flattened out (Fig. 3) in the course of the scale's development. An arrangement sometimes seen not only in psoriasis but in other skin lesions is an alternation of layers of hyperkeratotic and parakeratotic cells (Figs. 2 and 13), so that from above downward, one sees first unnucleated then nucleated islands of cells, then another unnucleated and a second nucleated layer, etc. The stratum granulosum is slightly thickened in places, but prevailingly normal. The pegs are longer and broader than in the earlier lesions, but the suprapapillary portion of the rete is not thickened. Wandering cells are found and they occasionally gather in clusters, suggesting the so-called abscess. A fair degree of œdema is present. The columnar stratum is normal. The papillary body is longer than in the earlier lesions, and, as pointed out by Ehrmann, in some the summit becomes clubbed. (Fig. 3.) The vascular changes and infiltration are more marked, but of the same type as in the earlier lesions.

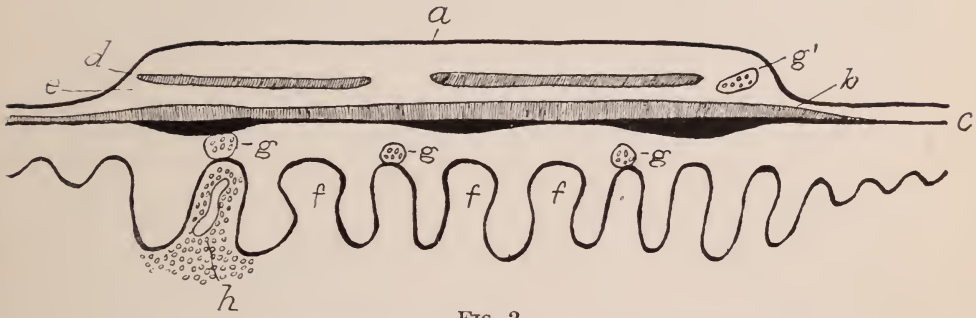

FIG. 2.

Further advanced psoriasis lesion (diagram).

a. Scale, no longer convex.
b. Parakeratotic layer.
c. Stratum granulosum, irregularly thickened.
d, e. Showing alternate layers of hyperkeratosis and parakeratosis.
f. Clubbing of the papillæ.
g. Munro's abscesses (note presence above papillæ).
g.' Munro's abscess in scale, somewhat flattened.
h. Dilated papillary vessel with infiltration coalescing with subpapillary infiltration.

FIG. 3.

Inveterate lesion (diagram).

a. Scale.
b. Acanthotic pegs.
c. Shaded areas show dense infiltration in the papillæ, below the papillæ, and, in places, deeper down in the corium. The vessels are dilated. (The details of the structure of the scale are as in Fig. 2.)

In still later lesions, in the chronic plaques, geographical and infiltrated forms, only the intensity of the process distinguishes it from that seen in the newer ones. In the gyrate and figured types, which involute centrally while they progress peripherally, the characteristic alterations are found in the advancing margins (Fig. 4).

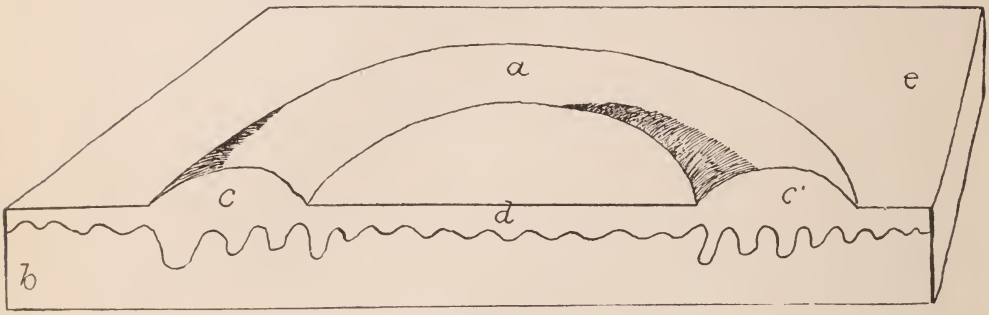

FIG. 4.

Scheme of gyrate or circinate lesions with peripheral extension and central involution (diagram).

a. Lesion rising from surface *e*.
b. Transverse section of skin.
c, *c'*. Transverse sections of lesion, each plane resembling a papule.
d. Involuting centre.

A word as to negative features. No true vesicles are found, which distinguishes psoriasis from eczema in the exfoliating stage, nor plasma cells which are occasionally present in lichen, nor Unna's peculiar chorioplaques, found in premycotic eruptions.

The positive characteristics of psoriasis are:

(1) Hyperkeratosis and parakeratosis.

(2) The presence of migrated leucocytes in the scale and rete.

(3) Microscopic gatherings of these leucocytes, forming abscesses.

(4) Acanthosis confined to the rete pegs, increasing them in length rather than in breadth, and none or very little in the suprapapillary portion of the Malphighian layer.

(5) An enlargement of the papillary body corresponding to that of the pegs.

(6) Dilatation and swelling of the endothelium in the papillary and subpapillary vessels.

(7) Perivascular infiltration of leucocytes and fibroblasts.

(8) Œdema of the collagen in these regions.

Parapsoriasis.

Parapsoriasis, according to Darier[15] and Brocq[16] includes three clinical varieties and manifestations.

(1). Parapsoriasis en gouttes. Exanthème psoriasiforme et lichenöide, Jadassohn.

(2) Parapsoriasis lichenöide, corresponding to parakeratosis variegata of Unna, Pollitzer and Santi; lichen psoriasis of Pinkus: pityriasis lichenoides chronica of Neumann, Rille and Juliusberg; dermatitis psoriasiformis nodularis of Juliusberg.

(3) Parapsoriasis en plaques; érythrodermie pityriasque en plaques disséminées of Brocq, and Crocker's xanthoerythrodermia perstans.

Despite the wide variations in gross appearance of the lesions, the microscopic picture of all is singularly uniform, and despite the distinctiveness and chronicity of the disease, the histological changes are astonishingly slight. Changes occur in the epidermis and papillary body.

Unna,[2] and Unna, Pollitzer and Santi[17] find the stratum corneum thickened, and an increase in the rete caused by œdema. Brocq[16] confirms the œdema and states that it also involves the stratum granulosum. No parakeratosis is present and the germinative layer is absent. Callomon[18] says the œdema is also intracellular, that epidermal abscesses are present, and *alteration cavitaire* is found. Arndt's[19] findings correspond with those of the preceding authors to a large extent, particularly as regards œdema and vesicles. No acanthosis, but rather an atrophy of the rete is present. A few wandering cells are found in the epidermis, the horny layer is normal, or but slightly thickened, and there is no parakeratosis. The basal layer, as Brocq stated, is often wanting, and this is due to obliteration from below by the infiltration in the papillæ, which overflows into the epiderm.

The papillary body is found œdematous by Unna[2]; the vessels are dilated and a perithelial infiltration exists. Brocq[16] confirms this, and points out that the papilliæ are flattened, because of the œdema. Callomon[18] reports similar findings, and mentions the presence of round cells, fibroblasts, a few mast cells, but no plasma cells in the infiltration, which is sharply limited below, but is without relation to the subpapillary vessels. The lymphatics are dilated. Arndt's[19] views are substantially the same, but he adds that in the infiltration an occasional polymorphonuclear leukocyte may be discovered, and that the infiltration is not sharp below. Callomon[18] states that the œdema separates the elastic fibres, while Heller[20] finds the elastic tissue and collagen normal.

The basis of the subsequent description is material from a case presented by Dr. Pollitzer at the midwinter session of the American Dermatological Association, and microphotographs from the collection of Drs. Fordyce and MacKee. All of the points enumerated by Arndt can be demonstrated. (Fig. 5.) To judge by Brocq's quotation from Civatte's thesis, all forms of parapsoriasis correspond, in their structure, to that of the variety in plaques with the one exception that Civatte emphasizes parakeratosis (Figs. 16, 18 and 19) more than do other writers. The salient histological features of the disease are found in the epidermis and papillary body, and the relation between the epidermis and papillary body. The stratum corneum is so slightly thickened as scarcely to be considered hyperkeratotic, although its layers are more loosely

united than normal. There are no changes in the stratum granulosum. The rete not included in the pegs is not thick; rather somewhat thinner than normal, and the seat of a slight, though distinct, intercellular œdema. The rete pegs are either irregularly elongated, but not broadened (Figs. 16 and 20) or, in places (Fig. 5), absent. Here, too, intercellular œdema is present; a few cells show Leloir's changes (Figs. 16 and 18) and an occasional leucocyte is found. The columnar layer (Fig. 17) is invisible at certain points.

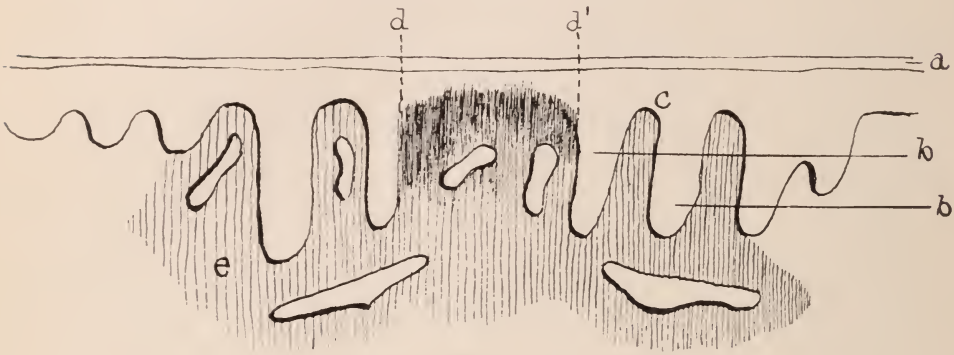

Fig. 5.
Parapsoriasis (diagram).

a. Thin hyperkeratotic scale.
b. Elongated pegs.
c. Suprapapillary rete somewhat thinned in diseased area as compared with unaffected region.
d. d'. Area showing flattened papillæ, absent pegs and infiltration overflowing into epidermis and eliminating basal layer.
e. Shaded area shows infiltration and dilated vessels. At point at which infiltration eliminates basal layer it is more dense.

The papillary body is œdematous; its vessels are dilated and surrounded by an infiltration consisting of round cells and numerous fibroblasts, with an occasional mast cell and no plasma cells. Some of the papillæ are flattened, causing the absence of rete pegs as mentioned above. The subpapillary vessels are also slightly dilated, and an infiltration is seen in this region sometimes coalescing with that in the papillæ. The collagen fibres are swollen so that at times they seem homogeneous (Fig. 20), the lymphatics slightly dilated and the elastic tissue normal.

It has been mentioned that the columnar stratum is invisible at certain points. These points correspond to the areas in which the

papillæ are flattened and the pegs absent. Here, too, the infiltration is usually densest, appearing to overflow into the rete (Fig. 5), the basal layer of which is thus obliterated.

The diagnostic features of parapsoriasis thus are:

(1) Slight, if any, hyperkeratosis, and often parakeratosis.

(2) Intercellular œdema in the rete, but no marked thickening of this layer; in fact, thinning in places.

(3) Irregular elongation without broadening of some rete pegs; disappearance of others.

(4) Interrupted obliteration of the basal layer.

(5) Œdema of the papillary layer with dilatation of vessels.

(6) Flattening of the papillæ where pegs are absent.

(7) Infiltration consisting of round cells (lymphocyte type) and fibroblasts. (Absence of plasma cells.)

(8) Coalescence of infiltration in the papillary body with that in the subpapillary region.

Seborrhœa.

In describing the histology of seborrhœa, it is necessary first to define and limit the scope of the discussion. Unna has included so extensive a series of conditions under this caption, and has so widely dilated upon their individual microscopic aspects, that were we to adopt his views, this chapter would be too long for publication. The opinion is ventured that seborrhœa is no such complex matter, either clinically or microscopically, as the school of Hamburg would indicate. Unna[21] enumerates seborrhœa simplex, circumcisa, petaloides, nummularis, rosacea seborrhœica, seborrhœa capitis, which he again divides into alopecia pityrodes, eczema seborrhœicum, crustosum and madidans, and finally, a malignant exfoliative type is mentioned. Acne, rosacea, dermatose médio-thoracique, seborrhœa oleosa and sicca, Brocq's seborrhœides and parakeratosis psoriasiforme, have all been included in, or allied with, the seborrhœas. Without entering deeply into the discussion of this matter, under seborrhœa will be described those forms of the scalp and body-affections which resemble psoriasis and pityriasis rosea. It may be permitted to state the following: Unna's seborrhœa simplex, circumcisa, petaloides and nummularis, as well as the dermatose figurée médio-thoracique are to seborrhœa what the different clinical varieties of psoriasis, such as the guttate, circinate, etc., are to psoriasis. Acne and rosacea are found only in seborrhœal individuals, but are not forms of seborrhœa in the sense to be applied in this chapter.

Within the limitations set forth, seborrhœa has a fairly definite microscopic structure resembling that of psoriasis, but possessing some individual characteristics which distinguish it from the latter. Granting the existence of seborrhœal eczema as a disease entity, its microscopic study belongs with that of the other eczemas. Thus, the ensuing description will be confined to seborrhœa of the scalp and the simple or figur-

ated seborrhœal lesions of the body. We glean from the literature that the minute anatomy of seborrhœa embraces the following changes: hyperkeratosis, parakeratosis and acanthosis, the hyperkeratosis including the pilosebaceous follicles usually to the opening of the sebaceous gland, and often actually involving the latter. Associated phenomena are atrophy of the hair follicle and hair shaft, hypertrophy of the sebaceous and sweat glands, and an increase of fat. The first group of phenomena are common to psoriasis as well as seborrhœa; the second group are peculiar to seborrhœa.

A recapitulation of Unna's views will serve as a starting point. In seborrhœa simplex is found simple acanthosis; in seborrhœa circumcisa, acanthosis at the margin and parakeratosis at the centre of the lesions, with slight œdema and vascular dilatation; in the petaloid form, follicular hyperkeratosis, parakeratosis and acanthosis with a perifollicular infiltration; in the nummular form, extensive parakeratosis, acanthosis, vesiculation, spongiosis and a dense infiltration in the papillary body; in pityriasis capitis, a dilatation of the follicles with marked follicular hyperkeratosis, as well as hyper- and parakeratosis outside of the follicular area. The transformation in the hairs is marked. A collar of hyperkeratotic cells surrounds the shaft causing a diminution in the number of papillary hairs, and an increase in the bed-hairs. In other words, the tendency of hairs to leave their papillæ and grow from the side of the follicles is an augmentation of the normal mode of hair growth. The attachments to the beds are loose. This gives four distinct pictures; namely, hair separated from their papillæ; hairs loosely attached to their lateral beds; hyperkeratotic follicle walls; and, finally, empty follicles. In some, Unna finds various changes in the epidermis common to all exfoliative processes, particularly, however, acanthosis, and a like involvement of the hair follicle epithelium, predisposing to certain alterations in the hair. A third and extremely significant feature is the presence of fat in the skin, in the intercellular spaces of the rete and basal layer, coil glands, vascular endo- and perithelium, and even in the smooth muscles and nerves. Civatte, in a personal communication to Brocq,[16] substantially confirms Unna. Ehrmann and Fick[5] find the infiltration poor in plasma, and rich in mast cells, with dilated vessels and some collagen degeneration, mentioned by no one else, however, while epidermis and follicle changes are found as described by Unna. These two authors find the hair papillæ small. Jackson and McMurtry[22] find a simple hyperkeratosis in pityriasis simplex. Audry[13] particularly emphasizes the epidermal changes already described and the involvement of the sebaceous and coil glands. He applies Sabouraud's fanciful designation to the follicular plug of "cocoon," but does not admit its pathogenic function. Sabouraud, in using this term, considers it the breeding place of the acne bacillus, held by him and Unna as the cause of seborrhœa. Giovaninni[23] points to the presence of keratinization in the sebaceous glands. Cedercreutz[24] finds fat increased in the basal layer of the epidermis, intercellular spaces of the rete, and in the blood lymph vessels, by staining with scarlet red. This corroborates Pollitzer's work, done in 1890 with osmic acid. Ledermann, Barlow and Dreysel had regarded Pollitzer's findings as due to pigment, but the scarlet red method excludes this view. Kreibich[25] has confirmed Cedercreutz's work by using Sudan III.

Audry's statement as to the hyperplasia of the sebaceous glands may be true, but it is hard to prove. Seborrhœa occurs in regions in which the sebaceous glands are usually large, namely, on the face, scalp, chest and between the scapulæ. Whether this is cause or effect cannot be established, because seborrhœa in some form is practically always present in the adult. That seborrhœa is usually associated with a disturbance of the hairs is equally true, but for the same reason its causative rôle in baldness is difficult to assert. It is certain that many people with severe seborrhœa never grow bald, and equally true that many with mild seborrhœa do. Whether Unna's findings regarding the decrease in papillary and increase in bed hairs are correct, cannot be definitely established either, for the process he points out is characteristic also of the physiological changes found in the development and moulting of hair, and comparisons are impossible between the abnormal and normal, because practically no scalp is free from seborrhœa. The atrophy of

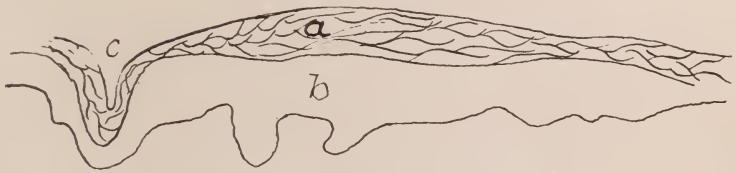

Fig. 6.

Seborrhœa showing relation of follicular plug to scale (diagram).
a. Scale. *b*. Rete. *c*. Plug.

the scalp following so-called seborrhœal baldness is definite, but may be due not to the disease process so much as the absence of hairs and closure of the follicles which would cause the skin to contract.

The changes in seborrhœa are found both in the epidermis and cutis, and those of the glabrous surface differ somewhat from those on the hairy. A variable degree of hyperkeratosis (Fig. 21) is present, very little parakeratosis and a proliferation of the rete pegs, most irregular both as to the number involved, and the degree of the changes. (Figs. 6 and 7.) Thus, the junction of the epidermis and papillary body is represented by an irregularly sinuous line. In places the rete pegs are normal, in others lengthened, in still others broadened as well as lengthened, and finally, in some areas the length is two to three times the normal, so that the pegs project downward like fangs. The acanthosis is due not only to a proliferation of rete cells, but to an intercellular and intracellular œdema, so that small vesicles are formed. *Altération*

cavitaire (Figs. 22 and 23) is common and spongiosis not rare. The abnormal prickle layer is bounded below by a normal columnar stratum and above by a normal stratum granulosum. The latter is surmounted by a scale consisting of hyperkeratotic cells and very few parakeratotic ones. Within the scale lie exfoliated abscesses or vesicles (Fig. 23) and some pus cells, the latter being also present in the rete. The scale varies greatly in thickness in different specimens and for that matter even in the same section. Fat (Fig. 8) is found in osmic acid preparations, in the basal layer among the rete cells and within the scale.

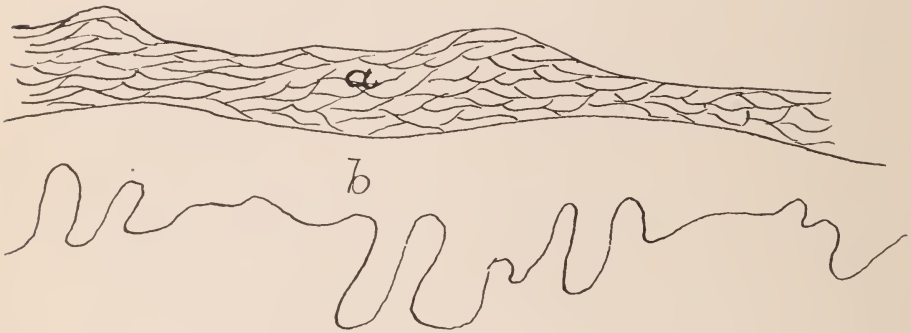

Fig. 7.
Seborrhœa (diagram).

a. Scale.
b. Rete.

The hair follicles are also involved by direct extension from the surface epithelium, and the changes in them can be best studied by specimens from the scalp. A hyperkeratosis (Fig. 23) in the mouth of the follicle causes a plug to form there, which is continuous (Fig. 9) with the scale about the follicles. This entire structure resembles an old-fashioned nosegay set in a vase, the plug being the stalk and the hyperkeratotic cells radiating thence, the bending stems, while the follicle is the vase. Here and there the plug is lifted out of the follicle *in toto,* and is found adherent to the inferior surface of the scale. The hair shafts are compressed by the hyperkeratotic zone and form the axis of the plugs. Some follicles are dilated, others atrophied, and others normal. The hairs are either on papillæ or beds and the follicle walls contain fat. No great alterations are present in the sebaceous glands.

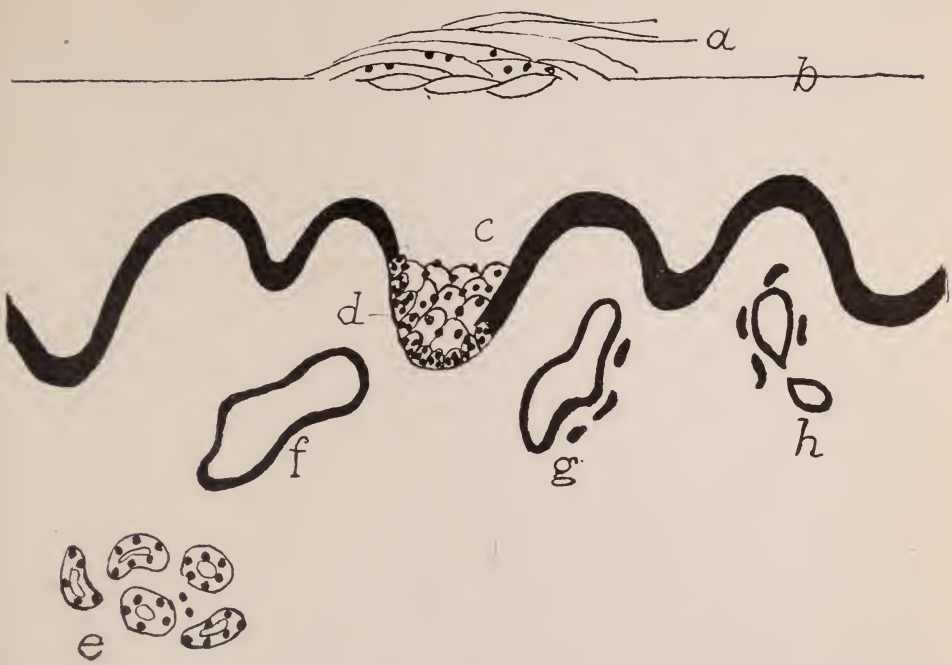

Fig. 8.

Seborrhœa (diagram), Composite of fat distribution based upon the findings of Pollitzer, Cedercreutz and Kreibich.

a. Hyper- and parakeratotic layer with fat drops.
b. Statum granulosum; *c*, rete cells; *d*, basal cells with fat. The broad black band indicates the rich fat content of the columnar stratum.
e. Coil glands with fat.
f, g, h. Vessels with endothelial and perithelial fat.

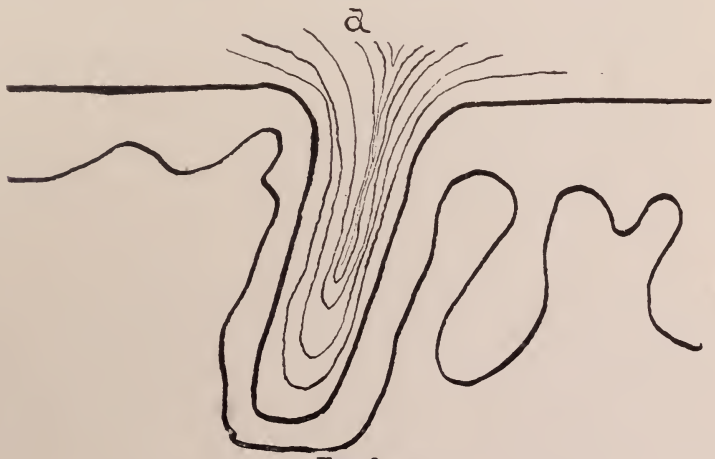

Fig. 9.

Seborrhœa, follicular hyperkeratosis (diagram).

a. Diagram of plug.

Changes are present both in the papillary body and corium, and they consist of an infiltration (Fig. 22) vascular dilatation, and alterations in the coil glands. The papillary body (Figs. 16 and 22) is somewhat œdematous; its vessels are greatly dilated, engorged, and surrounded by an infiltration of varying degrees of intensity. The subpapillary vessels present a similar aspect. The infiltrations in the two areas coalesce (Fig. 22), and consist mainly of lymphocytes and fibroblasts, but an occasional plasma cell and a great many epithelioid cells are found, particularly near the vessels. The collagen is swollen but otherwise unaltered, and the elastic tissue and muscles are normal. Especial mention must be made of the coil glands which are numerous, very possibly increased in number, but certainly hyperplastic and hypertrophied. The coils are more numerous, their epithelium proliferated so that it is from two to four layers deep, and many contain fat droplets.

These features are found in various combinations and various degrees, from mild to very extensive hyperkeratosis, vascular dilatation and infiltration. It must be mentioned that perifollicular abscesses may form (Fig. 23). These are due to secondary infection by pyogenic organisms such as the cocci of Malassez, and perhaps Unna's or Sabouraud's bacilli, to say nothing of the various types of staphylococci common to the skin.

The characteristic microscopic features of the disease are:

(1) The hyperkeratosis and irregular acanthosis, the former involving the hair follicles.

(2) Minute vesicles.

(3) Increased fat in the scale, rete, columnar layer, vessels, hair follicles and coils.

(4) Atrophy of the hairs, and atrophy or hypertrophy of hair follicles.

(5) Hyperplasia and hypertrophy of coil glands.

(6) Vascular dilatation and perivascular infiltration of lymphocytes, fibroblasts, mast, epithelioid, and occasional plasma cells.

Pityriasis Rosea.

In view of the comparatively slight clinical symptoms of this disease, its microscopic signs are truly astonishing in their intensity. The literature on the subject is sparse, but the descriptions are fairly uniform. The centre of interest has been the question of the ætiology of pityriasis rosea, and although the presumption of its parasitic causation is strong, it has never been definitely established.

Unna[2] finds a parenchymatous swelling of the epidermis, epithelioid proliferation, mitoses in the basal layer and a most irregular acanthosis. A moderate vascular congestion and leukocytic infiltration are found in the papillary body. In more advanced lesions these features are more intensely developed; in fact, a most marked hyperplasia of fibroblasts and multinuclear spindle cells are found. Hollman, according to Jarisch, finds vesicles in the epidermis as does Darier[15] also. Thibierge,[26] in addition to findings corresponding to Unna's, notes an absence of the stratum granulosum in advanced lesions, and Ehrmann and Fick[5] practically substantiate all of the facts mentioned, adding the invasion of the horny layer by leucocytes and the serous saturation of the epidermis.

From the foregoing and the appended description of a section, it is clear that pityriasis rosea is an exudative inflammation of the skin. That it should occasionally resemble erythema multiforme, even of the bullous type, as reported by Udo Wile and others, is not astonishing, in view of the picture the microscope discloses. The epidermis (Figs. 24 and 25) is hyperkeratotic; no more so, however, than is the case in fading multiform erythema, but a marked and irregular acanthosis is present. The pegs are irregularly enlarged both in length and breadth, and occasional mitoses are found in the lower strata of the rete. A marked œdema of the intercellular type, some intracellular œdema and vesicle formation (Fig. 24) are present, as well as an invasion of the epidermis by a few leucocytes. The papillary body is swollen, the collagenous fibres are œdematous, the vessels dilated and surrounded by a cell deposit made up of lymphocytes and fibroblasts. Similar changes exist in the subpapillary area. The scaling elements of the lesion suggest a mild psoriasis; the exudative elements, erythema multiforme.

Although the picture is not pathognomonic, it is suggestive and its important features are:

(1) Hyperkeratosis, irregular acanthosis, intercellular œdema and vesicle formation.

(2) Dilatation and congestion of vessels.

(3) Lymphocytic and fibroblastic infiltration in the neighborhood of the vessels.

Explanation of Plates.

Plate XIX.—Figs. 12 and 13.

Fig. 12. Fresh psoriasis lesion. Drawing, Zeiss Oc. 4. Obj. DD. *a.* Hyperkeratosis. *b.* Leucocytes in scale. *c.* Parakeratotic area. *d.* Leucocytes in rete. *e.* Irregular thickened granular layer. *f.* Acanthosis of peg. *g.* Leucocytes in papilla. *h.* Dilated vessel with swollen endothelium. Note general character of the infiltration in the papillary body and below, and the swelling of the collagen, shown by the loss of its distinct fibrillation in the upper levels.

Fig. 13. Old psoriasis lesion. Drawing. Zeiss Oc. 4. Obj. DD. *a*. Parakeratotic area. *b*. Hyperkeratotic area. *c*. Munro's abscess. *d*. Stratum granulosum, of varying thickness. *e*. Whorle. *f*. Deposit of leucocytes in rete, (Munro's abscess). *g*. Acanthotic peg. *h*. Clubbed papilla. Note the œdema and swelling of the papillary body, and the almost verrucous proliferation of the rete, so that the papillæ are transected in many places.

Plate XX.—Figs. 14 and 15.

Fig. 14. Psoriasis. Zeiss obj. 16 mm., co. oc. 4. Microphotograph from the collection of Drs. Fordyce and MacKee. Early lesion showing thick, lenticular scale.

Fig. 15. Psoriasis. Zeiss obj. 8 mm., co. oc. 4. Microphotograph from collection of Drs. Fordyce and MacKee. *a*. Munro's abscess lying in parakeratotic scale. Note the marked acanthosis of the pegs, and the œdema of the papillary body. The vacuolization of the rete cells is more marked than is commonly observed in psoriasis, and is probably caused by treatment.

Plate XXI.—Figs. 16 and 17.

Fig. 16. Parapsoriasis. Zeiss obj. 8 mm., co. oc. 4. Microphotograph from collection of Drs. Fordyce and MacKee. *a*. Elongated peg. *b*. Confluent pegs. Note the parakeratosis, alteration cavitaire, intercellular œdema in the rete, and vascular dilatation. The infiltration in very slight.

Fig. 17. Parapsoriasis. Zeiss obj. 8 mm., co. oc. 4. Microphotograph from collection of Drs. Fordyce and MacKee. *a*. Obliteration of the basal layer by infiltration from below. Note obliteration of pegs, thin hyperkeratotic scale, and infiltration and congestion more marked than in Fig. 4.

Plate XXII.—Figs. 18 and 19.

Fig. 18. Parapsoriasis. Zeiss obj. 8 mm., co. oc. 4. Microphotograph from collection of Drs. Fordyce and MacKee. Note the normal contour of the pegs, the thin granular layer, alteration cavitaire, marked parakeratosis, and very slight congestion.

Fig. 19. Parapsoriasis. Zeiss obj. 8 mm., co. oc. 4. Microphotograph from the collection of Drs. Fordyce and MacKee. Note the œdema of the papillary body, the more marked infiltration than in the other pictures, and the depth of the infiltration.

Plate XXIII.—Figs. 20 and 21.

Fig. 20. Parapsoriasis. Drawing. Zeiss oc. 8. obj. DD. *a*. Hyperkeratotic scale. *b*. Thinned suprapapillary rete. *c*. Pegs, long and narrow. *d*. Papilla containing infiltration. Note the interrupted granular layer, and the presence of leucocytes in the epiderm and corium. These are indicated by the darker cells. The collagen fibres in the papillary body are swollen and form a homogeneous mass; this is also present in the subpapillary area. The infiltration is diffuse above, and more localized below.

Fig. 21. Seborrhœa. Drawing. Zeiss oc. 4., obj. DD. a. Dense hyperkeratotic scale. *b*. Irregular and pronounced acanthosis. Note slight infiltration in this illustration and abscence of tendency to vesicle formation usually present in this disease.

Plate XIX.—To Illustrate Article on Histopathology, by Walter J. Heimann, M.D.

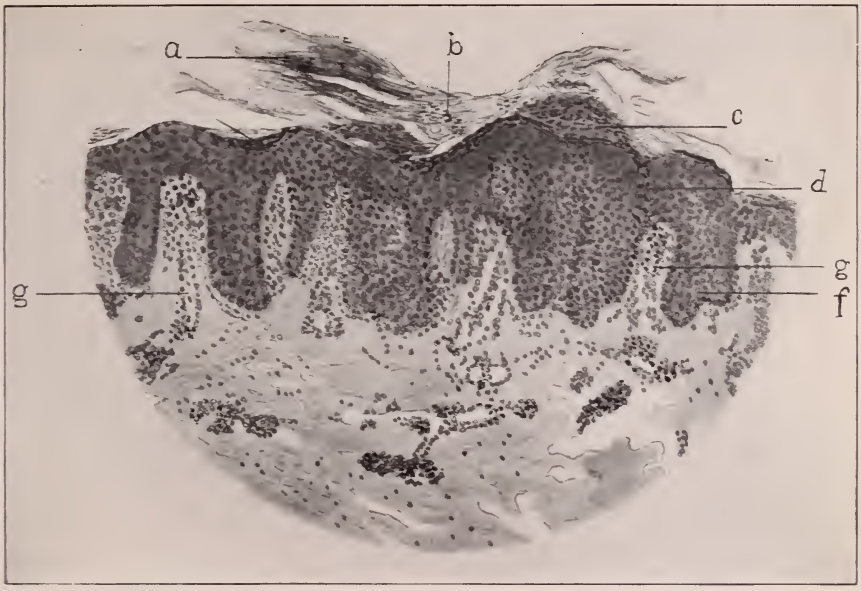

Fig. 12.
Psoriasis. Early lesion.

Fig. 13.
Psoriasis. Late lesion.

PLATE XXIV.—FIGS. 22 and 23.

FIG. 22. Seborrhœa Drawing. Zeiss oc. 4., obj. DD. *a.* Vesicle. *b.* Œdematous, atrophic rete without true pegs. Note the extreme hyperkeratosis, the alteration cavitaire in the Malpighain cells, and the pronounced infiltration and œdema in the corium.

FIG. 23. Seborrhœa. Drawing oc. 4, obj. DD. *a.* Hyperkeratotic scale *b.* Vesicle. *c.* Œdema of rete. *d.* Atrophied hairs, with abscess about hairs (the dotted areas). *e.* Atrophic hair follicle.

PLATE XXV.—FIGS. 24 and 25.

FIG. 24. Pityriasis rosea. Drawing. Zeiss oc. 4, obj. DD. *a.* Leucocytes in hyperkeratotic scalp. *b.* Vesicle in rete. Note the œdema of the rete, irregularly enlarged pegs, œdema of the corium, vascular dilatation and intense infiltration.

FIG. 25. Pityriasis rosea. Zeiss obj. 8 mm., co. oc. 4. Microphotograph from the collection of Drs. Fordyce and MacKee. Note the œdema of papillæ, hæmorrhage at tip of papilla and intercellular œdema in rete and pegs.

(*To be Continued.*)

REFERENCES.

[1] HEBRA, DUHRING, CORNIL AND RANVIER. Text Books.
[2] UNNA. Histopathologie, pp. 265, 273, 404.
[3] ROBINSON. On the Nature and Pathological Histology of Psoriasis. *N. Y. Med. Jour.*, 1879, xxviii, p. 1.
[4] KROMAYER. Zur pathologischen Anatomie der Psoriasis. *Arch. f. Dermat. u. Syph.*, 1890, p. 557.
[5] EHRMANN U. FICK. Histopathologie.
[6] KOPYTOWSKI. Contribution à l'anatomie pathologique de psoriasis. *Ann. d. dermat. e d. syph.*, x, p. 765.
[7] MUNRO. Sur l'histologie de psoriasis. *Ann. d. dermat. e d. syph.*, ix, p. 961.
[8] SABOURAUD. Pityriasis et alopécies pelliculaires. Paris, 1904, p. 539.
[9] GROSS. Mraçek's Handbuch. ii, p. 137.
[10] CILIANO AND WILE. Das Eleidin, etc. *Monatsh. f. prakt. Dermat.*, 1909, xlviii, p. 245.
[11] JARISCH. Hautkrankheiten. Vienna, 1908, p. 579.
[12] MANTEGASSA. Note istologiche sopra alcuni casi di psoriasis. *Giorn. ital. mal. ven. e d. pel.*, 1893, p. 496.
[13] AUDRY. Prat. dermat., iv, pp. 91, 283.
[14] HASLUND. Die Histologie und Pathogenese der Psoriasis. *Arch. f. Dermat. u. Syph.*, 1913, civ, pp. 427, 725.
[15] DARIER. Précis de dermat., Paris, 1909, pp. 82, 93.
[16] BROCQ. Dermat. prat., Paris, 1907, ii, pp. 363, 381.
[17] UNNA, SANTI UND POLLITZER. *Monatsh. f. prakt. Dermat.*, 1893.
[18] CALLOMON. Zur Kenntnis der Brocq'schen Krankheit. *Arch. f. Dermat. u. Syph.*, 1913, cxiv, p. 503.
[19] ARNDT. Ueber die Brocq'schen Krankheit. *Arch. f. Dermat. u. Syph.*, 1910, c, p. 7.
[20] HELLER. Ueber die Beziehung Parapsoriasis zu der Brocq'schen Krankheit. *Arch. f. Dermat. u. Syph.*, 1911, cviii, p. 77.
[21] UNNA. Histopathologie, p. 227.
[22] JACKSON AND MCMURTRY. *Jour. Cutan. Dis.*, 1912, p. 608.
[23] GIOVANINNI. *Ann. d. dermat. e d. syph.*, 1901, p. 1105.
[24] CEDERCREUTZ. *Arch. f. Dermat. u. Syph.*, 1912., cxi, p. 743.
[25] KREIBICH. *Arch. f. Dermat. u. Syph.*, 1913, cxiv, p. 628.
[26] THIBIERGE. Prat. dermat., iii, p. 902.

SOCIETY TRANSACTIONS

MANHATTAN DERMATOLOGICAL SOCIETY.

Regular Meeting, November 12, 1915.

GEORGE M. MACKEE, M.D., *Chairman.*

LUPUS ERYTHEMATOSUS. Presented by DRS. MACKEE AND WISE.

The patient, a male adult, was shown as a case of extensive lupus erythematosus of two years' duration. It involved the mucous membranes of the lip and the skin adjacent to it. There was also a large patch of lupus on the back of one of the ears.

DISCUSSION.

DR. GOTTHEIL said the solid carbon dioxide did very well in erythematous lupus of the mucosæ, but the applications must be light and a good deal of care taken with the tissues afterwards.

DR. WISE said he would administer the obvious treatment of carbon dioxide on the lip in this case. He had treated two cases of this kind, where the mucous membranes were attacked, which was not a large number to judge by, but the two cases so treated had gotten well. The reaction on the membrane had not been very intense, not much more than on the skin.

DR. OCHS said he had had a case of epithelioma, treated seven years previously, where he had used the carbon dioxide on the inside of the lip. He saw the patient a few days before and there had been absolutely no return of the lesion. The carbon dioxide snow was used with very firm pressure for one minute and followed by a second application of thirty seconds.

ANNULAR SYPHILIS. Presented by DR. OCHS FOR DR. HOWARD FOX.

The patient, L. J., was a colored female, aged twenty-five years. She presented a large number of annular lesions, varying in size, on the left side of the face and around the mouth and chin. They consisted of the typical elevated rings with pigmented centres. On the body the patient presented a macular eruption.

DR. OCHS said that usually in these cases, where one found the annular type on the face there was a macular eruption of the body, and very rarely, if ever,

a papular eruption. He recalled one case where the annular eruption was very slight. As regarded an annular eruption on the body, he had seen a few cases of it, combined with the annular form on the face, but the rule was, annular of the face and macular on the body, not annular combined with papular. On the body, the eruption was usually all papular or papulo-pustular.

ERYTHEMA MULTIFORME (?) Presented by Drs. Howard Fox and Ochs.

The patient, L. R., was a married woman, twenty-six years of age, born in England. She was the mother of one child, an apparently healthy girl, nine years of age. She had had several miscarriages, brought on intentionally, according to her statement. There was no further history suggestive of syphilis. Eighteen months ago she was said to have passed a tapeworm. The eruption was first noticed about four weeks ago. About eight weeks ago, her menses had been delayed and had been brought on after taking pennyroyal pills. She suffered severely from constipation. She stated that she had eaten some canned salmon a few days before the eruption appeared. She had not taken any drug, except an occasional cathartic, for many months. The eruption on her thigh had existed about four weeks, that on her forehead ten days and that on the trunk less than a week. Examination showed an elevated, somewhat broken, inflammatory, reddish, smooth circular lesion on the forehead, about two inches in diameter. At the lower portion, between the eyebrows, there was a distinct fleshy lump. On the inner surface of the right thigh there was an area about four inches in diameter, consisting of groups of nail-sized, yellowish-reddish macular lesions. The small patches themselves tended to assume a slightly crescentic outline. On the abdomen there was another circinate lesion, slightly scaling or crusting and on the chest a small group of three erythematous spots. The subjective symptoms consisted of slight burning. The clinical diagnosis of a circinate erythema multiforme was made tentatively, the alternative being a diagnosis of a circinate nodular syphilide. Three possible toxic causes for an erythema were present, namely retained placenta following an incomplete abortion, the eating of the canned salmon and her chronic constipation.*

Discussion.

Dr. Rosen said that to him the lesions looked very suggestive of a late secondary syphilitic eruption. The infiltration, grouping, clearing in the centre and the duration were all in favor of that diagnosis.

Dr. Wise said he based his diagnosis chiefly on the circinate outline of the lesions, the amount of infiltration, the clearing in the centre and the duration of the lesions. There was a disadvantage of not having observed the case during a number of days, but at a first glance he would make the diagnosis of syphilis and exclude all other diagnoses. He thought it was a late secondary syphilide.

Dr. Pisko thought the case one of erythema multiforme.

Dr. MacKee said that the acute onset of the lesions would suggest a diagnosis of erythema multiforme.

Dr. Ochs said his diagnosis was originally erythema multiforme when he first had seen the beginning papule on the forehead. He did not think that syphilis should be considered because of the sudden onset, the sparsity of the rash, the pale color and the succulency of the papules.

* As a Wassermann test, subsequently performed, gave a four plus reaction, the diagnosis of syphilis was apparently corroborated.

ONYCHOMYCOSIS. Presented by Dr. Ochs.

The patient, a small boy, had been shown to the Society some time previously, about one and one half years before, with an onychomycosis or generalized ringworm of the nails. Every nail of both his hands was affected, as well as all the toe nails. Dr. MacKee had taken a photograph of it and Dr. Satenstein made the microscopical examination and demonstrated the fungus. The speaker showed the boy as a case exhibiting the result of treatment. The boy's nails had been treated three times a week with pure carbolic acid, which had not been neutralized. When dry, the nails were painted with tincture of iodine and during the night Ungt. diachylon (Hebra) was applied and each nail was separately bound up with bandages. There was no other treatment. Dr. Mackee, the speaker mentioned, spoke about the affection at the time of the first presentation and said that the X-ray was the best way to cure the case. The treatment had lasted for six months, during which time the patient's attendance had been very assiduous. He had perfect nails on both hands and feet and no trace of the disease was to be seen, nor were any nails deformed. The speaker considered this a complete cure.

DARIER'S DISEASE. Presented by Dr. Ochs for Dr. Howard Fox.

The patient was a male adult, seventy-four years of age. The disease had begun fifty-one years previously, on the abdomen and spread over the entire body. It had persisted all these years, sometimes being worse and then again somewhat improved. At the time of presentation the scalp, ears, arms and anterior part of the abdomen were affected. In these parts there were groups of acuminate, dry, grayish papules. Some parts were blackish. The whole was rough to the touch. Where these groups were thickly aggregated, as conical papules, they presented a slightly papillomatous lesion. The general health was good.

Discussion.

Dr. Gottheil said the title Darier's disease may be permissible, but not the term "psorospermosis," since the "psorosperms" were now recognized by Darier as well as others to be not coccidia, as was at first thought, but merely imperfectly keratinized epidermic cells. "Keratosis follicularis" was a sufficient and characteristic designation.

Dr. George Henry Fox said he had photographed this case over thirty years ago. At that time he had quite a number of cases of lichen ruber and at first made that diagnosis, although it presented some clinical features which were different. Later, Dr. Lustgarten made a biopsy and the diagnosis of Darier's disease or keratosis follicularis. He found that the lower portion of the back looked very much the same as in his old photograph.

Dr. Mount said it seemed curious that with the extensive involvement the man showed comparatively little subjective suffering.

MYCOSIS FUNGOIDES. Presented by Dr. Gottheil.

This case had been presented at the last meeting with a diagnosis of trichoepithelioma, the designation being based on the microscopic findings. The man, for several years, had had what were apparently insignificant patches of seborrhœal eczema on various parts of his body. They had not itched and they had come and gone without attracting much of his attention. One patch however,

on the right side of his scalp, near the temple, remained as a red, dry, scaling and continually growing lesion. It occupied more than half of the left side of his scalp and extended down, on to his cheek. Over this surface the hair was entirely gone. The surface was moderately and evenly infiltrated and reddened, it was sometimes moist, oozing abundant serum and at other times dry and covered with a slight furfuraceous scaling. At the edges of the patch, among the hair on his scalp, there was an extended border of advancing disease with slightly reddened skin, covered with abundant greasy scales.

Clinically, the diagnosis had not been clear. A radiodermatitis had been thought of, as the patient had had X-ray treatment, but only some time after the condition on the scalp had been present and after the lesion had attained some size. A lupus erythematosus had been suggested but the rather rapid progression and the character of the resultant skin change did not seem to fit in with that either. The first biopsy and examination had been made by the pathologist of the City Hospital, Dr. Larkin. On his report of an epithelial proliferation beginning in the hair sacs, the speaker suggested trichoepithelioma. This had left them as much in the dark as regarded the clinical features, as ever. A subsequent biopsy and examination had resulted in a diagnosis of mycosis fungoides, which was a little, though not much more satisfactory. The case was certainly not like any other case of mycosis fungoides that he had seen and he did not yet regard the matter as settled.

Discussion.

Dr. O. L. Levine (by invitation) said he found distinct pathologic changes, with a characteristic infiltration in the corium. The infiltration was uniform everywhere, being just as marked in the papillary bodies and about the hair follicles as about the blood vessels. There were small and large round cells, epithelioid, fusiform and plasma cells. Some were well formed, others were irregular in shape. Polynuclear cells were also present. Some of these showed deeply-staining, red granules in their protoplasm and were probably eosinophiles. Mitotic figures were observed in some of the cells and occasionally, especially in the vicinity of the blood vessels, there were clusters of cells resembling giant cells. The infiltration was limited almost entirely to the upper corium. The blood vessels were enlarged and dilated, contained various types of cells and there was some endothelial proliferation. There was some œdema of the corium, the collagen stained more faintly than normal and the bundles of fibres were more separated. The epidermis showed a marked œdematous condition. There was an extensive parakeratosis of the stratum corneum. There was marked ballooning degeneration of the rete cells, the cells were swollen, enlarged and rounded and had a clear cell body and the nuclei were pushed to one side. An acanthosis of the rete pegs was observed and was quite extensive. Clusters of more or less degenerated connective tissue cells were scattered here and there, in the epidermis.

The skin of the body showed evidence of a condition resembling seborrhœic eczema. The diagnosis of the speaker was mycosis fungoides of the scalp with a probable premycosis of the body.

Dr. MacKee called attention to the fact that Dr. Wise had suggested a diagnosis of localized mycosis fungoides at the last meeting. This suggestion was inspired by the case of mycosis fungoides limited to one foot, reported by Senear from Wile's Clinic, (The Journal, May, 1915, p. 351.) The fact that there was a generalized eruption of scaly plaques, together with the new histological report, which agreed with the clinical appearance, would seem to warrant a diagnosis of mycosis fungoides. The speaker asked Dr. Levine if

he found any multinucleated cells and if he considered the infiltrating cells to be embryonic in type?

The absence of itching did not necessarily speak against mycosis fungoides as there were instances of the disease that during certain stages of evolution did not itch very much, if at all. In this connection, the speaker, together with Drs. Wise and Rosen, had under observation a case of érythrodermie pityriasique en plaques disseminées in which it was difficult, clinically, to exclude mycosis fungoides, largely on account of the pruritus, of which the woman complained.

Dr. Wallhauser said this case presented unusual features, but nevertheless he would be inclined to regard it as a case of mycosis fungoides.

ADDISON'S DISEASE. Presented by Dr. Gottheil.

This patient, a male, aged forty years, had been in the City Hospital three months previously, for a general eczema of moderate severity and had been discharged cured. He came back a month ago with a very slight degree of general eczema, a little thickening of the skin and very moderate itching, but his skin was noticeably dark in color and he said that it was getting darker. The eczematous symptoms soon disappeared under the mildest local treatment, boric acid ointment for the most part, but the hue of his general integument had been progressively getting darker under his eyes. Outside of a complaint of general debility, there were no subjective symptoms. His blood pressure, internal organs and functions were normal. The pigmentation involved the entire skin, but was most marked on his legs. It was a fairly even coloration of the entire integument, though less marked on the face and hands than on the covered parts, and especially upon the legs. It was a warm, brownish-black, not at all the hue of argyria and the patient had not been taking silver or arsenic. Suprarenalin medication, on which he had been put for some time, had not affected the coloration.

Discussion.

Dr. Pisko called attention to the fact that nitrate of silver had been applied on this patient's skin for a number of weeks, on both arms and both inner thighs. These nitrate solutions were applied, sometimes as high as fifteen or twenty per cent., hence the pigmentation.

Dr. Mount said he should never care to make a diagnosis of Addison's disease, unless there be present pigmentation of the mucous membranes. This he considered of greater importance than pigmentation of the skin.

Dr. Wise said this patient had appeared at the Vanderbilt Clinic three months previously. At that time he had no pigmentation whatever, but there was a universal eczema and his lesions gradually softened and cleared up. He thought that the man was susceptible to pigmentation following the lesions of the skin and that the discoloration was due to the preëxisting infiltration.

Dr. Wallhauser said the color of the skin presented in this case was rather in favor of Addison's disease than argyria.

Dr. MacKee said that the universal distribution would speak against argyria and the metallic color, together with a lack of mottling, would tend to exclude arsenical pigmentation.

EPITHELIOMA CURED BY X-RAY. Presented by Dr. Geyser.

The case was a female adult. The speaker said that this case was presented to show the results of X-ray treatment, a few years after application. The patient had been presented before the Society four years previously, at Dr. Kinch's residence. She had been suffering from epithelioma over the bridge of the nose and had been treated by the X-ray with the direct contact method. She had had the lesion eight or nine years before she had come to the speaker. A cure had been effected and she had remained well ever since.

EPITHELIOMA CURED BY X-RAY. Presented by Dr. Geyser.

In connection with the last case, Dr. Geyser showed the case of a male adult. The man had sustained an injury seventeen years previously, being hit in the face with a cotton hook. The trauma refused to heal and the lesion developed the symptoms of epithelioma. He was sent to the speaker's office some time in August and then the lesion reached from the mustache up to the eye, nearly over one-half of the face. The speaker showed the patient for the results of the X-ray treatment since that time. No other treatment was given except direct contact with the Cornell tube. The lesion cleared up in about six weeks. The patient had come twice a week for treatment.

CASE FOR DIAGNOSIS. EPITHELIOMA OR TUBERCULOSIS (?) Presented by Dr. Wise for Dr. Weiss.

The patient was a male adult and the disease had been of four years' duration. He was a chauffeur by occupation and had been thrown out of his automobile four years previously. The upper lip had been split, was sewed up and after that his wound became infected. New skin had been forming on the lip, but the patient always pulled it off again at frequent intervals. He presented a somewhat indurated, pea-sized ulceration of the lower lip, with raised edges and an adherent crust.

Discussion.

Dr. Ochs said he would be inclined to consider the diagnosis of epithelioma instead of tuberculosis.

Dr. Wise said that the absence of adenitis was against epithelioma in the diagnosis. The speaker considered the lesion to be a tuberculous ulcer.

Dr. MacKee said he could not make a diagnosis. The absence of hard induration, the verrucous appearance, the age of the patient and the fact that there was no lymphatic involvement would suggest a diagnosis of tuberculosis. On the other hand, the short duration and the rapid progress suggested the possibility of epithelioma. The speaker had had a case of malignant epithelioma of the lip, which began when the patient was eighteen years of age.

KOILONYCHIA. Presented by Dr. Ochs.

The patient was a male adult. All the nails on the right hand as well as the nails of the thumb, index and middle fingers of the left hand were thin and had a decided concavity, giving them the appearance of spoon nails. The

nails were not brittle nor marked by transverse fissures. The general health was good and the nails of the feet were not affected. The patient stated that the spoon nails had begun about six years previously, upon taking up his occupation, that of manufacturing jewelry.

KELOIDS AFTER X-RAY TREATMENT. Presented by Dr. Geyser.

The patient, a female adult, had been before the Society previously, but the speaker again showed her because, at the last meeting, the question of the treatment of keloids had come up. The patient presented the so-called idiopathic keloids. The speaker said he had used everything except radium on this patient, which had been suggested at the last meeting. The lesions presented various results. The patient first came to the speaker with a lesion on the left side of the neck. She stated that a "pimple" caused the keloid, which was removed surgically and in the line of incision a larger keloid developed. The surgeons told her that sufficient tissue had not been removed. They again operated, but the keloid grew still larger. A third operation was suggested but the patient objected. Dr. Geyser finally began to use the X-ray, but could not obtain any good effect on the keloid unless he produced a reaction. He said he had always condemned this procedure and that one should not substitute a burn or a scar for something else. The patient, however, preferred the scar to the original lesion, as she had gotten rid of the pain by the X-ray. The result of the burn could be plainly seen over the keloid. The last X-ray treatment had been given eight years previously. At one place a lesion had been treated with the solid carbon dioxide snow. Another was treated with electrolysis.

Discussion.

Dr. Gottheil said this case showed the utter confusion of their ideas as to this affection.

Dr. Geyser said he had other cases as much "cured" as this one, but that it was simply substituting one scar for another.

Dr. Wallhauser said that, having recently had a case of keloid that was very resistant to treatment with carbon dioxide snow, and which finally responded, with an excellent result, to the reduction of the tumor with trichloracetic acid, followed by applications of carbon dioxide snow, he felt that any of the lesions presented in this case could be similarly removed.

Dr. Pisko said, regarding trichloracetic acid, he might employ it in the smaller lesions, but he would not use it in lesions having a larger area, especially lesions of this type.

Dr. Geyser said in this particular case, all the various methods had been used and because each method, after it was used proved a failure, the next method was tried. The lesion on the right scapula showed where the snow had been used successfully. Exactly the same technique was used on two other lesions, but they had been complete failures.

ACNE VARIOLIFORMIS. Presented by Dr. Ochs for Dr. Howard Fox.

The patient was a female adult, aged forty-one years. On the left side of the face, extending from the brow to the nape of the neck, were distinct, isolated, superficial, slightly atrophic scars. She presented lesions in all stages of development, some slightly inflammatory, some in full development and others beginning to scar. On the scalp and also on the right side only, were the scars of old lesions and a few isolated new ones. The duration of the disease had been one year.

CASE FOR DIAGNOSIS. PITYRIASIS ROSEA? Presented by Drs. MacKee and Wise.

The patient, a male adult, was from Dr. Fordyce's Clinic. The eruption began on the right side of the abdomen as a silver-dollar sized, red, slightly scaly lesion. After this had existed several days a more or less generalized eruption developed. The lesions were dime-sized and scattered over the chest, abdomen, upper arms, back and thighs. They were pale red in color and covered with coarse scales, similar to those seen in certain types of seborrhœic dermatitis and psoriasis. In this connection the speaker mentioned the fact that the patient had had psoriasis several years ago. In many of the lesions there was a distinct folliculitis and in some of them there was evidence of purpura. Here and there the individual lesions coalesced to form patches. There were a few lesions on the palms. There was some infiltration or œdema in places, so that part of the eruption could be said to be papular. There were no fawn-colored centres and no cigarette paper wrinkling.

The patient had had considerable gastro-intestinal disturbances following the ingestion of shell fish.

The speaker said that the case resembled both psoriasis and seborrhœic dermatitis and particularly a borderline case between these two diseases. But in spite of the fact that the lesions were not typical of pityriasis rosea, he would not rule out the possibility of this dermatosis. The eruption might become more typical later in the evolution, a fact frequently noted in pityriasis rosea. Wile had reported a case of the disease in which the lesions were vesicular and the speaker had reported a case in which the lesions were markedly purpuric. The histology of the disease,—vesiculation, infiltration, dilated capillaries, parakeratosis, etc., would suggest the possibility of clinical infiltration, œdema, vesiculation and hæmorrhage.

Discussion.

Dr. Rosen said he thought the eruption was one of toxic origin (toxic erythema), if one wished to call it so. The character and distribution of the eruption, particularly the involvement of the hands (palms included), was against its being pityriasis rosea. Observation of this case a few days longer would definitely determine the correct diagnosis. If pityriasis rosea, the eruption would spread to other parts of the back and chest and would remain from four to six weeks, during which time, lesions typical of the disease should appear.

Dr. Wise considered the case to be one of erythema multiforme papulatum.

SARCOMA OF THE TOE. Presented by Dr. Ochs.

The patient was a male adult, aged fifty-seven years. In April, 1910, he noticed a watery discharge exuding from under the nail of the big toe, on the right foot. This had been treated for two years as an eczema and later as an "ulceration." In April, 1912, there being no improvement, the entire nail was removed and the base scraped to the bone. The wound healed by granulation, except in its centre, within six weeks, but did not become covered by epidermis except at its edges. In a short time a watery secretion again appeared and exuberant granulations sprang up. At this time a Wassermann test was made, which was negative. In October, 1914, the patient was referred to the speaker. When first seen by him, the patient presented a large, fungating mass, taking in the entire nail bed. The edges were soft and showed no tendency to bleed

when touched, though the granulations were soft and flabby. Wet dressings and later balsam of Peru, in from five per cent., to twenty-five per cent., strength in oily solutions, were applied. The ulcer cleared and it was then noticed that epidermization began, but soon ceased and the watery discharge returned. A biopsy had been made by Dr. Satenstein and the growth was seen to be a sarcoma. The X-ray was applied and the condition at the time of presentation was the same as when the granulations were cleared. Due to the excessive secretion, the neighboring two toes had become eczematous. There was no adenopathy. The case was presented as sarcoma of the toe. Dr. Ochs presented some of the sections under the microscope. The surgeon who removed the nail of the toe said it was done on account of a paronychia.

Discussion.

Dr. Gottheil said that the diagnosis of sarcoma of the ulcerative and fungating type, lasting so many years, with so little progression, did not appeal to him. He did not like to criticize the microscopic diagnosis, but if this were sarcoma they must add still another to their many varieties of the disease.

Dr. Ochs said, while the microscopical diagnosis was sarcoma and as the patient had no subjective symptoms and was in good health, he thought he ought to have further X-ray treatment before amputating the toe was advised. Saccomas of this type were usually very slow in growth and could go on for a long while without causing any serious trouble. If there had been pain or adenopathy they could then recommend radical means to cure the disease.

Dr. MacKee said that he had examined the histological specimen and confirmed the diagnosis of sarcoma, developing probably from the periosteum.

Dr. Wallhauser said that, aside from considering the possible classification of this case, it would seem that on account of the unchanging character of the lesions during a period of five years and the discomfort to the patient, that amputation of the toe was plainly indicated.

PHILADELPHIA DERMATOLOGICAL SOCIETY.

Regular Meeting, October 18, 1915.

Frank Crozer Knowles, M.D., *Chairman.*

DERMATITIS HERPETIFORMIS. Presented by Dr. Stelwagon.

Male, white, aged 46 years. The eruption made its appearance on May, 7, 1915 and had changed in character and distribution several times since then. It had been on several occasions more or less generalized but always with the greatest number of lesions in the genito-crural region, popliteal space, on the ankles, elbows and around the neck. When exhibited, there were on the trunk a few scattered lesions, slightly vesicular in character, with a tendency to grouping. Very few lesions were present in the above named areas but the pigmentation was marked and was unusual in that it was so sharply defined, almost as much so as in a typical case of psoriasis. According to his history, there had been in some of the previous attacks, large bullæ,—a few the size of an egg. There were no constitutional symptoms and the man seemed to be in

fairly healthy condition. One especially interesting feature of this case was that the eruption had made its appearance just four weeks after vaccination and the speaker called attention to the fact that he had seen this type of eruption several times follow vaccination, especially in children.

Discussion.

Dr. Hartzell said that while the eruption on the arms and particularly on the elbows looked very much like an erythema multiforme which had become quiescent, yet he fully agreed with the diagnosis although he felt that many cases of this type which Duhring has designated as dermatitis herpetiformis, were in reality true pemphigus, especially when each outbreak took the same type and was not of the multiform variety that Duhring had described so frequently.

Dr. Gaskill called attention to the fact that this patient had been seen several weeks ago in the Jefferson Hospital with a typical dermatitis herpetiformis but with the lesions much more fully developed, but still more or less confined to the certain areas as designated above.

Dr. Hirschler said that the patient had been treated at the Polyclinic Hospital and that the eruption, while typical in character, was of such unusual distribution that several photographs had been taken by Dr. Schamberg.

LUPUS VULGARIS. Presented by Dr. Walker.

The patient was a female, white, aged 13 years, with a very extensive lupus vulgaris which had been present for the past nine years. She was exhibited at a meeting of this Society last year and was again presented to show the effect of treatment. On each cheek was a solid plaque extending from the lateral aspect of the mandible, upward to within an inch or an inch and a half of the eye. It was very sharply circumscribed with scar tissue in the centre, and a smooth, elevated border on which there were no tuberculous nodules. The lesions were symmetrical and very much inflamed. The treatment had consisted of X-ray exposures and the application of pyrogallic acid.

TUBERCULOSIS CUTIS. Presented by Dr. Walker.

R. H., female, white, aged 24 years. Her father had died of tuberculosis of the lungs and her mother was also suffering from that disease. There was one large plaque on the inner surface of the right thigh, about eight inches by four inches, distinctly nodular in character, with a marked thickening of the epidermis; violaceous in tint and with the diseased area fading off gradually into the surrounding healthy skin. There was no discernible destruction of tissue. On the left leg, on the anterior tibial surface, was another large plaque which bore, in general contour and color and in the formation of deep, large nodules, a very close resemblance to the lesion on the right thigh, but there was deep ulceration and destruction of tissue here, the skin being broken in three or four places with considerable sero-purulent discharge.

Discussion.

Dr. Hartzell said that a diagnosis of Bazin's disease on the left leg must be considered but was inclined to agree with the speaker's diagnosis.

Dr. Stelwagon said that he had never seen as extensive a case of Bazin's disease as this, nor one with so much ulceration.

Dr. Gaskill remarked that this patient had been presented by him at a meeting of this Society last year with the same diagnosis but that there had been no destruction of tissue at that time and that the lesions had apparently not progressed to any great extent.

EXTENSIVE CASE OF LUPUS ERYTHEMATOSUS. Presented by Dr. Hartzell.

Female, white, aged 14 years. The patient had had the eruption on the face for about a year, occupying the typical situation of lupus erythematosus,—across the bridge of the nose and on the cheeks; here, it was not very extensive nor in any way out of the ordinary but the unusual feature of the case was the scalp involvement. Fully two-thirds of the crown of the head was covered with the eruption with only here and there a small area on which the hair still remained. It was remarked by those present how unusual it was to find such an extensive involvement in a patient as young as this one. Fifty per cent. ichthyol ointment had been used with apparently good results. The patient was rather indefinite as to the time the eruption had existed but it must have been for several years.

TUBERCULOSIS OF THE SKIN? Presented by Dr. Hartzell.

Female, white, aged 24 years. This patient was seen for the first time in the Venereal Ward of the Philadelphia General Hospital on the morning of the meeting. The eruption began about ten weeks previously and during that time the patient had been for four weeks in another hospital, where the Wassermann had been taken on three separate occasions, always with negative results, in spite of which she had received mixed treatment and with no appreciable benefit. The eruption consisted of fifteen or twenty scattered lesions on the right foot and ankle; the lesions were all irregular in outline, presented a "punched out" appearance and the more recent lesions were papules, with a central core, firmly and deeply set on an inflammatory base. This latter type of eruption was also present on the arms and bore a very close resemblance to a necrotic tuberculide. The older lesions on the leg were distinctly necrotic, the central portions being almost black, with clean-cut margins. The diagnosis of the lesions on the arm and some on the leg was tuberculosis and there would have been little question of doubt had it not been for a lesion on the left side of the buccal mucous membrane which bore a very close resemblance to a mucous patch. Dr. Hartzell remarked he had seen this same type of eruption where there had been trouble with the wisdom teeth.

TUBERCULOSIS CUTIS. Presented by Dr. Hartzell.

Female, white, aged 15 years. The patient had had an eruption on the right leg since babyhood and about a year ago was admitted to the Venereal Ward of the Philadelphia General Hospital where she was treated for inherited syphilis. A Wassermann test was made and the report was not sufficiently accurate to be of any value. She was in that ward for eight months; was dismissed and one month ago returned and was referred to the Skin Ward of the same hospital. The eruption consisted of numerous lesions extending in scattered groups from the right buttock as far down the leg as the ankle. Those on the buttock were distinctly nodular, brownish in color and soft in consistency, of the "apple-jelly type." The eruption, however, was not so typical on the leg; here, there was more ulceration; the nodules were not so pronounced and the lesions presented much more of a tertiary syphilitic character. The ulceration

was extremely superficial, however, and while, of course, it was not impossible to have the two infections occurring in the same patient, yet there were so many areas that were truly typical that the diagnosis of tuberculosis cutis alone was considered. A biopsy was performed and many giant cells were found to the field but a thorough examination was not made for the tubercle bacilli.

SECONDARY SYPHILIS. Presented by Dr. Davis.

Male, white, aged 30 years. Four years ago the patient, while in New Orleans, had had a more or less generalized eruption and had been treated for syphilis,—twelve injections of mercury had been given and later two of salvarsan. There had been three Wassermann tests, the last two (the latter of which was in July) having been negative. Six weeks ago he noticed an eruption which was generalized, rather "measly" in character, with slight grouping of mildly inflammatory, small papules. The tongue showed several sharp-cut ulcers, whitish and very painful. The Wassermann, taken the day that he was presented before the Society, was negative. There was no history of an initial lesion at that time. It was agreed that the eruption was that of secondary syphilis and the reason for bringing him before the Society was to ascertain if this was a case of reinfection or a recurrence of an eruption of four years ago. The latter was ruled out and Dr. Hartzell remarked that there was a question if the original condition for which he was treated was syphilis, as an error might have been made in the diagnosis. He will be put on anti-syphilitic treatment and reported to the Society at a later date.

CASE FOR DIAGNOSIS. Presented by Drs. Stelwagon and Gaskill.

Male, white, aged 46 years. The patient presented himself at Jefferson Hospital about four weeks ago with an eruption on the forearms and backs of the hands, on the ankles and on the face, where there were only a few scattered lesions. On the forearms, the eruption was intensely inflammatory, consisted of large groups of papules considerably elevated above the surrounding skin. These groups were extremely irregular in outline and the entire masses were covered with a coarse, grayish scaling. The groups were sharply marginated and there was considerable itching at that time. The lesions on the ankles were approximately the same as on the arms but on the face were of an entirely different nature. Over the nose, cheeks and forehead were little dime size groups of inflammation, irregular in contour, with a small papulo-vesicular eruption superimposed, with no itching. There was also a slight eruption on the right ear, of the same character. Superficially, the eruption on the face, in situation and color resembled an acne roseacea before the stage of deep pustulation; but on close examination, it was found that the follicles were wide open; there was some fine scaling and the most probable diagnosis that was offered was that of a lupus erythematosus of the face but no definite suggestions were offered for the eruption on the hands and feet.

SCLERODERMA. Presented by Dr. Walker.

Female, white, aged 17 years. The patient presented a long, streak-like eruption on the left side of the neck, beginning just below the angle of the jaw and extending downwards and inwards; it was approximately a half inch wide and five inches long. The skin had lost its elasticity and felt tense and hard, had a mottled, pinkish-white tint but did not present any of the regular features of true keloid. The patient stated that two months ago, she had had a stiff

neck and had painted it with the tincture of iodine. Whether it was the onset of the scleroderma which had produced the sensation of stiffness in her neck or whether the scleroderma had been produced by the use of the tincture of iodine, was questionable.

NÆVUS PIGMENTOSUS UNIUS LATERALIS. Presented by Dr. Gaskill.

Female, white, aged 20 years. This patient was first seen about a year and a half ago and presented a very remarkable condition on the left side of her neck. There were myriads of small pigmented spots scattered over this area, varying from the size of the head of a pin to a small pea and the entire area was unilateral, starting sharply at the left of the spinal column and extending around the neck, to about the inner third of the clavicle. Anteriorly, the line of demarcation was not so sharp as it was posteriorly, where it looked as though the skin might have been cut away with a knife. The pigmented area extended laterally almost to the outer end of the clavicle. The condition had been present since birth and five applications of carbon dioxide snow had been made with a complete disappearance of the pigmentation and with no scarring whatever. The patient had been very irregular in her attendance at the hospital but was so delighted with the result of the treatment that it will be continued, though she complained bitterly of the applications; this may be accounted for by the close proximity of large blood vessels and nerves in that region.

TERTIARY SYPHILIS. Presented by Drs. Stelwagon and Gaskill.

Male, white, aged 30 years. Two weeks ago, the patient presented himself at the Jefferson Hospital for a lesion on the right side of the face directly over the malar bone. It was the shape and size of a white bean; there was considerable purulent discharge, marked induration, the edges clear out. The Wassermann reaction was 4 plus and there was a history of a chancre eleven years ago. The patient had been under potassium iodide treatment for one week and the discharge had ceased and healing had begun. The unusual feature of this eruption was the smallness of this isolated lesion which bore all the characteristics of a tertiary lues and yet which in some respects resembled an initial lesion.

ERYTHEMATOUS ERUPTION FOLLOWING DERMATITIS HERPETIFORMIS. Presented by Dr. Hartzell.

M. C., female, white, aged 45 years, Russian Jewess. The patient presented an erythematous condition over the entire body, with no normal skin showing in any part. This erythematous rash was more or less covered with a fine scaling and a few days prior to presentation, there had been numerous rings situated over the chest, both anteriorly and posteriorly. There were no distinct papules nor vesicles. The speaker said that his attention had been called to the patient on account of these rings and also on account of her history of having had dermatitis herpetiformis but that it would be impossible for any one to make that diagnosis at the time of presentation.

Discussion.

Dr. Gaskill said that this patient had first come to the Jefferson Hospital in July, 1911, where she had been treated for two years for an eruption which was typically that of dermatitis herpetiformis; that she had been presented to the

Society on one occasion, when the diagnosis was confirmed. He also said that he had reported this case under date of June, 1914, in THE JOURNAL, on account of a transitory bullous eruption which appeared on her leg and ankle and which lasted only for about three weeks. She was afterwards transferred to the Philadelphia General Hospital, where she was treated for dermatitis herpetiformis. Several attempts had been made to give her injections of sodium cacodylate but at each point where the needle pierced the skin, a deep infection would take place as her body was so completely covered with the vesicular eruption that it was difficult to find areas of normal skin. The patient became dissatisfied and returned home. Later, she went to the Jewish Hospital, without presenting the vesicular or bullous type of eruption and it was here that the ringed eruption was noticed. In July, 1915, she was admitted again to the Philadelphia General Hospital under the service of Dr. Gaskill, and none of the characteristics of the dermatitis herpetiformis was present,—only a marked inflammatory condition of the skin, with profuse scaling.

CASE FOR DIAGNOSIS. Presented by DRS. STELWAGON AND GASKILL.

Miss A. R., female, white, aged 66 years. The patient was admitted to the Jefferson Medical College Hospital on April 21, 1915, with the history of having had this eruption on her face since August, 1914. The eruption was confined to the cheeks, nose and chin. It was distinctly inflammatory, of rather violaceous tint and was covered with a yellowish crust of soft consistency. The eyes were very small and there was a marked conjunctivitis, though the eruption at that time did not extend to within an inch and a half of the lower lids. A tentative diagnosis of tertiary syphilis was made and energetic measures were employed at once. Mercury was given intravenously but the patient soon became so salivated that that was discontinued. Later, when this treatment was resumed, one-half grain of the salicylate of mercury would produce marked salivation. Two injections of salvarsan were given, to both of which she reacted very badly, the temperature on one occasion rising to 104° F. and with complete prostration and more or less general neuralgic pains. After the last injection, there seemed to be some slight improvement which lasted only a few days and since that time the disease had progressed slowly but surely. Potassium iodide, 40 grains t.i.d., was given for several weeks and still with no results; the disease extending very slowly and gradually upward to the eyes and outward to the ears. While it was nodular in character and firm to the touch, it at no time presented any tubercles. The crusting continued and could only be kept from forming in large plaques by antiseptic dressings. The patient had lost considerable weight and at the time of presentation weighed only 87 pounds. The von Pirquet test was positive but this would have little value in the point of diagnosis of the eruption on her face, as there were tuberculous foci in the apices of both lungs. About two months prior to admission, the mucous membrane covering the hard palate began to ulcerate as did the upper lip. While the eruption on the face seemed syphilitic in character, yet the ulceration in the mouth was unquestionably so.

DISCUSSION.

DR. HARTZELL said he agreed with the speaker in saying that he had never seen a patient with tertiary syphilis who had had the thorough treatment that this one had, who did not respond at least in a measure, and he felt that a diagnosis of tuberculosis cutis could not be excluded, though it was by no means a typical case. It was suggested that X-ray treatment be given.

REVIEW

OF

DERMATOLOGY AND SYPHILIS.

Under the direction of

FRED WISE, M.D., New York,

Assisted by

CLARENCE A. BAER, M.D., Milwaukee.
WILLIAM H. BAUGHMAN, M.D., New York.
PAUL E. BECHET, M.D., New York.
J. S. EISENSTAEDT, M.D., Chicago.
CHARLES GOOSMANN, M.D., Cincinnati.
ROBERT C. JAMIESON, M.D., Detroit.
M. F. LAUTMAN, M.D., Hot Springs.
OSCAR L. LEVIN, M.D., New York.
VINCENTE PARDO, M.D., Havana, Cuba.
M. L. RAVITCH, M.D., Louisville.
ISADORE ROSEN, M.D., New York.
MAX SCHEER, M.D., New York.
PHILIP F. SHAFFNER, M.D., Chicago.
A. W. STILLIANS, M.D., Chicago.
JOHN H. STOKES, M.D., Chicago.
HARVEY P. TOWLE, M.D., Boston.

DERMATOLOGISCHE WOCHENSCHRIFT.

(November 13, 1915, lxi, No. 46.)

Abstracted by MAX SCHEER, M.D.

TWO CASES OF SYPHILITIC REINFECTION OR PSEUDO-REINFECTION FOLLOWING SALVARSAN AND MERCURY THERAPY. TIÉCHE, p. 1051.

The author reports two cases of primary lues—both had penile chancres—who were treated with neosalvarsan and mercury. The first case received, in the course of eight weeks, 3.5 gms. neosalvarsan and 0.75 gm. of mercury salicylate; the second patient received, during the course of ten weeks, 3.5 gms. neosalvarsan and 1.15 gms, of mercury salicylate. Neither showed secondaries.

The first patient presented, four months after infection and two months after cessation of treatment, a typical chancre of the tongue, with spirochætæ and adenopathy. The second case presented, just after cessation of treatment, a chancre of the upper lip, with spirochætæ and adenopathy. It was impossible to decide whether they were new infections, or pseudo-reinfections from latent deposits of spirochætæ.

CONCERNING CONTRALATERAL ALOPECIA FOLLOWING GUNSHOT INJURIES OF THE HEAD. (*Supplement.*) A. V. KNACK, p. 1060.

In Cases i and iii (previously reported in THE JOURNAL) the injured side of the head was placed on the photographic plate, so that the "contralateral" alopecia must have been caused by the direct effect of the X-ray on the uninjured side of the head. But Case ii does not fit in this category, as the alopecia was present before the X-ray examination.

(*Ibidem*, Nov. 20, 1915, lxi, No. 47.)

ENDOGENOUS FAVUS IN GERMANY. N. I. GOLDKRAUT, p. 1067.

The author notes the rarity of favus in Germany, especially in the western and southern parts. A few cases, imported from Russian Poland, are seen in eastern Germany. The author gives a detailed clinical report of seven cases observed in the University Clinic at Leipzig, from 1897 to 1912. These were endogenous cases; they came from the town or its immediate neighborhood.

(*Ibidem*, Nov. 27, 1915, lxi, No. 48.)

THE DIAGNOSIS OF SYPHILIS FROM THE BLOOD AND THE SPINAL FLUID (INCLUDING THE LUETIN REACTION.) V. KAFKA, p. 1091.

The author makes a plea for a more uniform technique in testing the blood and cerebrospinal fluids for the Wassermann reaction. In this way more light would be shed on its diagnostic, prognostic and therapeutic significance. For details of technique the reader should consult the original article.

(*Ibidem*, Dec. 4, 1915, lxi, No. 49.)

DIFFUSE PIGMENTATION OF THE SKIN FOLLOWING GUNSHOT INJURIES IN THE NEIGHBORHOOD OF THE ADRENALS (TRAUMATIC ADDISON'S DISEASE.) W. FISCHER AND H. LESCHCZINER.

A soldier who received a gunshot injury in the region of the right adrenal showed, about three weeks later, a brown pigmentation of the skin of the abdomen. The pigmentation spread gradually to other areas and there were also fall of blood pressure, asthenia, hypoglycæmia and other phenomena of Addison's disease. In addition, Meirowsky's phenomenon was demonstrated in a piece of excised skin.

Meirowsky's phenomenon consists of marked hyperpigmentation occurring in a piece of skin which has been kept for a few days in warm paraffin or aromatic substances.

MUENCHENER MEDIZINISCHE WOCHENSCHFIFT.

(May 4, 1915, lxii, No. 18.)

Abstracted by ARTHUR WILLIAM STILLIANS, M.D.

A NEW SALVARSAN PREPARATION, SALVARSAN NATRIUM. FABRY AND FISCHER, p. 612.

The authors have found that salvarsan natrium in doses of 0.3 gm. to 0.6 gm., dissolved in from 50 to 150 cc. of sterile normal salt solution, is therapeutically equal to the corresponding doses of old salvarsan, 0.2 gm. to 0.4 gm. They are convinced of this, not only by the beneficial results upon syphilitic lesions, but also by the toxic reactions seen, usually light febrile reactions or Herxheimer reactions; but occasionally quite severe diarrhœa. Because of its resemblance

to old salvarsan, in this respect, they confine its use to hospital cases, still using neosalvarsan in concentrated solution for their ambulant cases.

(*Ibidem*, May 11, 1915, lxii, No. 19.)

DEEP RAYING OF CARCINOMA BY MEANS OF ROENTGEN RAY MACHINES. E. v. SEUFFERT, p. 641.

The author describes the Gehrke oscillograph tube, which, by means of an apparatus rotating synchronously with the interruptions of the primary current, can be made to give readings of the character of the secondary current. This is needed in view of the fact that the filtration of the mixture of rays does not eliminate all rays dangerous to the skin. With this apparatus he tested five different machines, each with tubes of various make, but all of from 10 to 12 Wehnelt penetration. They all gave in one minute, with 2.5 milliamperes, from 2 to 3 X, but their secondary current curves, as registered on the new apparatus, were very different. The best results were obtained with what is called the "laboratory arrangement." No proof is offered that the current from this machine gave any larger deep dose than the others.

ACTION OF LIGHT ON THE LIVING CELL. F. SCHANZ, p. 648.

Dreyer and Hausen have shown that albumins are sensitive to light. By exposing various albumins, in quartz test tubes, to the action of ultra-violet light, they showed that the easily soluble albumins are changed by the actinic rays to albumins more difficult of solution. The author of the present article has measured, with the quartz-spectral-photometer, the absorption of ultra-violet rays by the cornea and lens, and has found that while the cornea absorbs almost none of these rays in ordinary daylight, the lens absorbs a large part of them. After fifty years of age all the ultra-violet rays of daylight are absorbed by the lens. Add to these the modern artificial lights, with their high content of ultra-violet rays, and it is no wonder that the human lens becomes yellow with the approach of age. A lens exposed to the light of a quartz lamp for from two to four hours changed from a composition of 8.5 mg. soluble albumin and 96.1 mg. globulins, to a composition of 48.0 mg. soluble albumins, 40.8 mg. globulins and 79.4 mg. coagulated albumin. A similar effect is produced on egg albumin and serum albumin. He believes that the same effect is produced on any albumin, and thinks that it may be the basic fact underlying the action of light on living tissues. The action on the skin is very probably the same as on the lens, and it may be that sun-stroke is due to some such action on the serum albumins.

THERAPY OF HERPES TONSURANS. A. SALINGER, p. 649.

From a large series of cases of this disease, infected mostly from cattle, the author recommends, in the superficial cases, painting with tincture of iodine twice a day, or if this is not strong enough, spreading thickly upon gauze an ointment of salicylic acid 8%, beta-naphthol 5%, and resorcin 4.0% in lanoline. This is kept on for two days, renewing it at the end of the first day, and by that time the application has usually resulted in a large bleb. This is trimmed off and the raw surface dusted with an indifferent powder, after which it heals promptly.

For the deep cases he removes the crust and washes the part with 1-2000 bichloride solution, then applies daily the above ointment. At each change of

dressing he washes the part with the bichloride solution. This method healed the worst cases promptly. Only one case of his series failed to respond to his treatment, and that case steadily grew worse until it had become sodden with pus, when the patient suddenly had a febrile reaction. The author made a diagnosis of erysipelas, and because the case quickly cleared up after the febrile reaction, he suggests that in resistant cases it might be well to infect them with erysipelas! (Why was it not possibly a reaction to the ringworm infection, resulting in the production of antibodies and the cure of the infection? Reviewer.)

TREATMENT OF PAINFUL CONTRACTILE SCARS. P. Michaelis, p. 649.

The author obtained a good result in a case of painful contracted scar from a shattering wound of the foot, by the injection, every second day, of 2.0 cc. fibrolysin, combined with massage and hot air baths, applied twice daily. Six injections were sufficient.

TREATMENT OF WAR DERMATOSES. C. Bruck, p. 661.

Psoriasis was seen very seldom among the soldiers, whether due to the fact that it is not considered sufficient to need treatment or possibly that the change of habits, since the war began, has had a good effect on the psoriatics, the author does not know. Pityriasis rosea was seldom seen until the beginning of winter, when it appeared with the winter woolens. In the treatment of the staphylococcus infections of the skin he has had excellent results from histopin, an ointment made of dead staphylococci. This, applied twice a day, had a prompt effect and prevented recurrences.

(*Ibidem*, May 25, 1915, lxii, No. 21.)

DEEP RAYING OF CARCINOMA BY MEANS OF THE ROENTGEN RAY MACHINE. F. J. Kock, p. 711.

Commenting on the article of v. Seuffert, in No. 19 of this volume of the *Muenchener medizinische Wochenschrift*, the author reminds v. Seuffert that the tension in the secondary circuit is no criterion for the activity of the tube. Like all interposed resistance, the Roentgen tube changes its resistance with every change in the strength of current, so that no judgment of the penetrability of the rays can be based on the strength of current at any certain instant. The resistance in the tube for each strength of current must be known, which is a practical impossibility with the ordinary deep therapy tubes. The Lilienfeld high vacuum tube, however, maintains a constant resistance during use, and the mixture of rays is the most homogeneous produced by any Roentgen tube. (The Lilienfeld is the German equivalent for the Coolidge. Reviewer.)

(*Ibidem*, June 1, 1915, lxii, No. 22.)

SOME GENERAL PATHOLOGICAL AND THERAPEUTIC PROBLEMS IN THE DOMAIN OF THE DERMATOMYCOSES. Bloch, p. 737.

The author first mentions the two kinds of treatment needed for these disorders: the antiparasitic, useful in the superficial infections, where the drug

can reach the parasite, and the use of wet dressings, advocated especially by Jarisch, which affects the deeper forms of ringworm, by aiding in the production of natural resistance. The cases which resist both these methods are represented by favus and microsporon infections, in which the fungus grows within the hair and has no direct relation to the living cells of the tissue. These cases require epilation, either mechanical or by means of the Roentgen ray. The biological study of the tricophytons has given us the explanation of the resistance to treatment, as well as the long recognized but unexplained ease with which the violent infections like kerion Celsi yielded. Neisser and Plato have shown that a general reaction like the tuberculin reaction occurs when these cases are injected with "tricophytin," an extract of the parasite.

By further investigation along the same lines, Bloch has shown that the deep dermatomycoses are not local diseases of the skin; but that even when only a small area of skin is affected, the whole organism is involved in the process, especially the mechanism of immunity. Every deep mycosis of the skin gives a specific reaction to its own toxine. The toxine consists of two parts: a volatile, undialysable portion of complex molecular composition, and a simply constructed, dialysable body which resists boiling, and is soluble in water but not in alcohol or ether. Only the combination of these will stir up allergy; but if this is already present the second body alone can cause a reaction.

This allergy is manifested by intradermal injection, cutaneous application (von Pirquet) and inunction, most easily by the second of these methods. It corresponds in strength to the tuberculin reaction in the tuberculides rather than in phthisis. Its value for diagnosis is limited to those cases in which the organism cannot be demonstrated. The allergy lasts longer after the cure of the disease, being demonstrable, in lessened intensity, sometimes years afterward. From this fact the author would argue that a positive tuberculin reaction is only an evidence that the patient has once had tuberculosis, and that a positive Wassermann reaction may have the same value in reference to syphilis.

The hypersensitiveness to the toxine of the fungus is not present in the blood, for anaphylaxis cannot be produced by its injection into animals, nor can a reaction between the blood and the toxine be seen in the test tube. This is not at all strange, in view of the fact that the second of the constituents of the toxine, which is able to cause the reaction, is non-albuminous. The theory that tricophyton allergy is a cellular allergy, caused by sessile receptors, was proven by Bloch, for he succeeded in transplanting a piece of allergic skin onto a granulating ulcer of a non-allergic patient, with the result that the graft continued to react to tricophytin for some time afterward.

As was shown by Jadassohn for iodoform sensitiveness, the sensitiveness to tricophytin is only quantitatively different from the reaction of normal skin, for by concentrating one of his tricophytins he obtained one strong enough to produce a mild reaction on an uninfected individual. By an early and strong reaction the allergy protects against reinfection. The inflamed area about the infection is the expression of local allergy. That the hypersensitiveness is general is shown by the fever and enlargement of lymph glands and spleen which accompany the local reaction, and by the fact that the whole skin is sensitive.

The therapeutic use of the ringworm toxines is much easier than the use of tuberculin, for there need be no fear of the release of living organisms from the original focus.

(*To be continued.*)

(*Ibidem*, June 8, 1915, lxii, No. 23.)

SOME GENERAL PATHOLOGICAL AND THERAPEUTIC PROBLEMS IN THE DOMAIN OF THE DERMATOMYCOSES. (*Conclusion.*) BLOCH, p. 773.

The specific therapy is of greater value, especially in the deep forms of ringworm, than is tuberculin in tuberculosis, and it is entirely safe. But it is of no value in favus, microsporon infections, pityriasis versicolor, the endothrix infections of children, erythrasma and the onychomycoses. They can be cured only in one of two ways: either by a change in the horny layer, making it an unsuitable soil for the fungus, as occurs at puberty in the case of favus, or by the mechanical removal of the diseased tissue, as the horny layer in the case of tinea versicolor or the hair in tricophyton endothrix. The Roentgen rays seem to act both by epilation and by the production of resistance, for he has repeatedly seen a mild allergy after the rays had been used, when there was none before. In the onychomycoses, where a change of soil does not occur and removal of the tissue is impossible, cure is not to be expected.

The allergic phenomena of the dermatomycoses are especially clear and are comparable to those of lepra, tuberculosis and syphilis. Chrysarobin is a very weak antiseptic, especially toward the fungi, so that considerable quantities of it may be mixed in the culture medium without interfering with the growth of the fungus. Its action in the body is indirect, by irritation of the skin and an increase or activation of the resistance already present. Therefore it fails in the same class of cases in which the injection of the toxine fails.

Gougerot has studied the action of potassium iodide on cultures of the sporothrix and concluded that because potassium iodide or iodine, added to the culture medium, did not hinder the growth, that the action of these drugs is indirect, probably by the production of phagocytosis. Bloch has repeated the experiment with similar results, but found that the iodine is at once bound by the culture medium. When free iodine is present in the proportion of one to a million parts of the medium, the sporothrix is hindered in its growth, though it requires more than twice this concentration of iodine to show a reaction with starch. He, therefore, believes that the action of potassium iodide upon sporotrichosis is due to the direct antiseptic action of the iodine. On this basis he tried it in deep tricophyton infection, with undoubted benefit.

(*Ibidem*, June 15, 1915, lxii, No. 24.)

DIAGNOSIS OF SPOTTED FEVER. E. FRAENKEL, p. 805.

The author discusses the difficulty of diagnosis which frequently occurs where typhus is in question, and emphasizes the claims he made in the *Muenchener medizinische Wochenschrift*, 1914, No. 2, for the diagnostic value of a histologic examination of the roseola. He describes a rapid method of fixing and hardening the specimens, so that the examination can be completed in a few hours. The characteristic necrosis of the walls of the small arteries in the pars reticularis, or even sometimes in the subcutis, and the infiltration of lymphocytes and cells of the same character, but larger than lymphocytes, about these arterioles, he was able to find in practically all cases from the fifth to the fourteenth day of the eruption. The affected vessels are always at the centre of the macule, and the infiltration about them is not along their whole extent, but bunched at certain points. In the infiltrate he found a few mast cells but never any polymorphonuclears or plasma cells.

(*Ibidem*, June 22, 1915, lxii, No. 25.)

GAS FREE ROENTGEN TUBE OF J. E. LILIENFELD. HOLZKNECHT, H. WACHTEL, C. WEISSENBERG AND R. MAYER, p. 837.

This tube is evidently a copy of the Coolidge tube, except that it has a water cooling arrangement, and that the incandescent heating point is behind the cathode. Its advantages are thoroughly discussed, but no reference to its American predecessor is made.

JAPANISCHE ZEITSCHRIFT FÜR DERMATOLOGIE UND UROLOGIE.

(July, 1915, xv, No. 7.)

Abstracted by M. F. LAUTMAN, M.D.

CONTRIBUTION TO THE KNOWLEDGE OF RADIO-THERAPY. HORIUCHI AND SAKAMURA, p. 522.

THREE CASES OF LUPUS ERYTHEMATOSUS ACNTUS DISSEMINATUS. IJIRI, p. 534.

EXPERIENCES WITH QUARTZ-LAMP THERAPY. FUJITANI, HIROSE AND NAKAYAMA, p. 538.

(*Ibidem*, Aug. 1915, xv, No. 8.)

THE TOXICITY OF TUBERCLE BACILLI TO LEPERS. SUGAI, p. 595.

LUPUS VULGARIS ON THE SOLE OF THE FOOT. KURITA, p. 608.

(*Ibidem*, Sept., 1915, xv, No. 9.)

EXPERIMENTAL STUDY OF SALVARSAN AND NEOSALVARSAN. NAHANO, p. 667.

DIAGNOSIS AND TREATMENT OF SYPHILITIC NEPHRITIS. MUNK, p. 743.

(*Ibidem*, Oct., 1915, xv, No. 10.)

CONTRIBUTION TO THE STUDY OF PARAPSORIASIS BROCQ AND DERMATITIS PSORIASIFORMIS NODULARIS JADASSOHN. HANAWA AND NAGAI, p. 761.

The authors mention the long continued controversy which has existed among many observers concerning the classification of Unna's parakeratosis variegata, Jadassohn's dermatitis psoriasiformis nodularis (pityriasis lichenoides chronica, Juliusberg) and Brocq's érythrodermie pityriasique en plaques disséminées,

either under Török's designation of disseminated scaly erythrodermia or as parapsoriasis of Brocq, and call attention to the great similarity between the above conditions and ordinary psoriasis. They report two cases.

The first case occurred in a 24-year-old woman and disappeared after three weeks' treatment with 10% pyrogallol ointment, leaving no pigmentation. Histologically, they found parakeratosis, absent horny layer, slight acanthosis, a few mitoses in the epidermis, small round cell infiltration as well as a few mast cells in the upper layers of the cutis, especially along the course of the blood vessels. The clinical and anatomical findings were those of dermatitis psoriasiformis nodularis of Jadassohn.

The second case was in a 5-year-old boy and cleared up under pyrogallol; it coincided with Riecke's two cases of pityriasis lichenoides chronica though the latter condition is usually much more resistant to treatment. Histologically there was found considerable parakeratosis and acanthosis, more or less definite evidences of inflammation in the cutis, and moderate leucocytic infiltration in the rete.

A comparison of the two cases reveals the fact that, while morphologically and clinically the two cases reported showed many differences, yet histologically the findings were almost identical. The authors advise, for a matter of convenience, the grouping under the head of parapsoriasis, all the various psoriasis-like dermatoses.

(*Ibidem*, Nov. 1915, xv, No. 11.)

MICROCHEMICAL STUDIES OF ARSENIC COMPOUNDS. TAMURA, p. 839.

There has not, as yet, been described any reaction for the detection of arsenic both in organic and inorganic combinations. Furthermore, there has not been determined any specific reaction for organic arsenic as such, so that tests for its detection demand first a breaking up of the organic combination and then testing for the mineral.

The author believes to have discovered a specific reaction for the detection of trivalent arsenic, either in organic or inorganic combination. The reaction depends upon the fact that if trivalent arsenic, in the form of solid, liquid or gas, is added to a mixture of three parts of 1% aqueous solution of osmic acid and one part of 1% nitric acid, a black precipitate is formed which is not dissolved by the further addition of the reagent. The reaction is very delicate and gives a distinct precipitate with salvarsan combinations, sodium arsenite, arsenopyenylglycin and others, in dilutions of 1:100,000.

Tamura further finds that this reaction takes place in animal tissues as well as *in vitro* and discards a previous method of his which colored fats and lipoids, as well as arsenic. Photomicrographs (four in the text) show the dark granules very distinctly in the tissues. The technique is described as follows:

The fresh tissue of an animal, previously treated with any trivalent arsenic compound, is fixed for 24 hours in absolute alcohol, changing it several times. It is then transferred into chloroform for 45 minutes, changing it a few times, next into paraffin (melting point 45° C.) and finally into paraffin (melting point 58° C.) for from 45 minutes to one hour. It is then cut into sections, 2 to 5 microns thick and fixed on the slide by the Japanese method. When dry, the paraffin is removed by treating the section from 15 to 30 minutes with xylol. This also helps to remove the fats and lipoids from the tissue which is then washed in absolute alcohol and treated with the osmic-nitric acid reagent for one minute. Finally, it is washed in absolute alcohol and xylol and mounted in neutral balsam. The arsenic appears in the form of dark granules of some

arsenic-osmium combination. It is also noteworthy that pentavalent as well as trivalent arsenic, when introduced into the body, can be demonstrated in this way, probably because the pentavalent is reduced to the trivalent form in the body. To support this latter theory, the author states that *in vitro* such combinations as orthoarsenic acid $\left.\begin{matrix}OH\\OH\\OH\end{matrix}\right\}As{=}0$, cacodylic acid $\left.\begin{matrix}OH\\CH_3\\CH_3\end{matrix}\right\}As{=}0$ and arsecetin $\begin{matrix}NHCOCH_3\\ \left\{\begin{matrix}OH\\ON_2\end{matrix}\right.\\0{=}As\end{matrix}$ do not give this reaction unless kept in contact with the osmic-nitric acid mixture for a long period of time. However, when these substances are injected intravenously into animals and the liver then treated according to his method, the brownish-black granules are seen, which granules are identical with those found after the injection of salvarsan or any other trivalent arsenic compound.

The author tested this reaction *in vitro* against 172 non-arsenic containing chemicals, with uniformly negative results.

A STUDY OF THE ANGIOMATA WITH HYPERKERATOSIS. MATSUMOTO, p. 860.

Of the different types of hyperkeratotic angiomata, the angio-keratoma described by Mibelli, in 1889, is most commonly observed. There are, however, certain atypical forms and the author reports a case of this kind. Clinically, the case presented superficial angiomata with hyperkeratosis and acanthosis and hyperidrosis; the lesions were on the margins and dorsal surfaces of both feet, the palms and soles being uninvolved. Microscopically, the lesions showed marked ectasia of the blood vessels of the papillary and subpapillary layers and hyperplasia of all the layers of the epidermis. The article contains a very good review of the literature and tables of the cases reported.

A CASE OF LUPUS ERYTHEMATOSUS DISSEMINATUS. SASAKAWA, p. 866.

RUSSKI JOORNAL KOJNIKH E VENERICHESKIKH BOLEZNEI.

(July and August, 1914, xxviii, Nos. 7 and 8.)

Abstracted by M. L. RAVITCH, M.D.

PRURITUS LINGUÆ ET MUCOSÆ ORIS. ZELENEV, p. 3.

Zelenev states that diseases of the mucosa of the mouth and tongue are often observed in certain skin diseases; they should, however, be separated from specific affections. In works devoted to dermatology alone, with the exception of Brocq's, but little has been said on this subject, except to mention it in a few diseases such as erythema, pemphigus, urticaria, and ulcerative processes. In general medical literature, however, during the past few years, much has appeared concerning diseases affecting the mouth and tongue; especial mention should be made of Trautmann: "Die Krankheiten der Mundhöhle und der oberen Luftwege bie Dermatosen," 1911, and v. Mikulicz and Kümmel: "Krankheiten des Mundes," 1912. Zelenev frequently sees patients with affections of the mouth and tongue, who, while they do not show extreme manifestations, may

have clinical symptoms of a nervous character, such as anæsthesia, hyperæsthesia, paræsthesia, neuralgia, etc. At times they may show only partial phenomena such as hemianæsthesia, hemiparæsthesia, or hemineuralgia. The ætiology of this affection may often be traced to a disarrangement of the nervous system, as, for example, different neuroses, neurasthenia, hysteria, systemic diseases, dementias, etc. Sometimes these attacks are of a serious nature.

Paræsthesia is often met with in attacks accompanied by anæsthesia or motor paralyses; neuralgia of the mouth is often accompanied by hyperæsthesia. Glossodynia is caused by disease of the trifacial nerve, and usually has among the objective symptoms exfoliation of the epithelium and redness and hypertrophy of the papillæ. At times we may have secondary rise of symptoms. Zelenev cites two cases that are of special interest to the dermatologist; both had intense pruritus of the mucous membrane of the mouth, but one showed hyperæsthesia, and the other paræsthesia of the buccal mucosa. One patient had carious processes of the upper maxilla. Both had difficulty in talking and eating and had to hold water in the mouth almost constantly to relieve the pain.

From the two cases reported by him, Zelenev concludes that such cases are usually due to diseases of the trifacial nerve, while alveolar abscess may be the primary cause.

PSORIASIS AND ARTHRITIS. Bogrov, p. 20.

Bogrov cites the case of Ellis and Rolleston to prove there is a relationship between psoriasis and arthritis. The patient gave a non-specific history, with no gonorrhœa, and no acute attack of rheumatism; at the age of fifteen he had an attack of pleurisy, with a traumatism of the left knee at the same time; a few years afterwards, psoriasis made its appearance, and a little later pain and swelling appeared in the left knee. Under prolonged arsenical treatment, lasting two years, both the psoriasis and arthritis disappeared, but with the discontinuance of the treatment they reappeared. The patient had carious teeth and radiography revealed a superficial osteitis of the rib. The carious teeth of the upper jaw were extracted, but his condition did not improve; later one of the carious teeth of the lower jaw was extracted, and a mixed autogenous vaccine, streptococcus and pneumococcus, was made from cultures taken from the pus from the alveolar abscesses. A slight improvement did follow the administration of the vaccine. However, with the renewal of the administration of arsenic, the psoriasis disappeared. The author concludes that there is no doubt of the relationship between psoriasis and arthritis.

SYPHILITIC ELEPHANTIASIS. Petrov, p. 24.

Before going into the description of syphilitic elephantiasis, Petrov gives a résumé and description of nonsyphilitic elephantiasis. He divides elephantiasis Arabum into two forms: elephantiasis filariosa and elephantiasis nostras. The first form is met with in the tropical countries, while the second may be seen everywhere, and especially frequently in Russia. Tropical elephantiasis is due to the filaria sanguinis hominis (filaria Bancrofti or filaria nocturna) which is taken into the stomach in drinking water and from there it enters the lymphatic and blood streams.

Elephantiasis nostras may be due to manifold causes. The chief ætiological factors are: the Streptococcus erysipelatis, acute inflammatory processes of the skin, eczema, lymphangitis, traumatism, furunculosis, excesses in venery, masturbation, malaria, gonorrhœa and venous obstruction. Dujarier and Gay Laroch

observed elephantiasis in tuberculosis of the axillary glands. Weit, Mey Bandler, Waelsch, Fournier, Pokrovski, Romm, Bamberg, Ravogli and others noticed it in syphilis. Goucher and Pospelov attributed it to vasomotor disturbances. Westhal noticed it in dementia præcox. Winkler claims to have discovered in several cases of elephantiasis a bacillus similar to the Bacillus lepræ.

That syphilis is a very important factor in the ætiology of elephantiasis is the belief of Petrov. He supports his views with reports of his own clinical cases and also with the statements of many authorities. It is particularly in tertiary syphilis that it is found. The pathological changes in syphilitic elephantiasis are similar to those of other forms of elephantiasis, but are also characterized by hyperplasia of the subcutaneous cellular tissue, which may result in deformities and contractures.

GALYL IN THE TREATMENT OF SYPHILIS. Mescherski, p. 52.

Mescherski quotes Danel's experiences with this French compound. It was used by him in 40 cases of syphilis in various stages. He found this preparation to be one of the most potent antisyphilitic agents. It caused syphilitic roseola, small syphilides and gummata to disappear more quickly than by the use of salvarsan! Also it is better tolerated and acts more promptly on the Wassermann reaction.

CHANCRE CARUNCULI LACRIMALIS. Jampolsky, p. 65.

Jampolsky describes a case of chancre of the carunculi lacrimalis in a woman, aged 40. Salvarsan treatment in the case was rapid and effective.

BULLETIN OF THE BRAZILIAN DERMATOLOGICAL SOCIETY.

(1914, III, Nos. 1, 2, 3.)

Abstracted by Vicente Pardo, M.D.

BOUBA. Silva Arujo Filho, p. 8.

The author calls attention to the fact that "boubas" is the common name given in Brazil to the disease known as yaws, frambœsia or pian, and not a new clinical entity, as believed by Dr. Breda of Padua. He establishes the distinction between boubas and sporotrichosis, blastomycosis and leishmaniosis (Aleppo boil), upon the fact that boubas never appears on mucous surfaces, and above all, upon Castellani's discovery of the specific treponema in yaws lesions.

In Brazil, boubas is becoming a rare disease, the author having found only fourteen cases in five years; in which cases he confirmed the presence of the specific treponema.

As regards the symptomatology, the author describes an incubation period with fever, general disturbance, headache and rheumatic pains; then the initial lesion which is extragenital in the great majority of cases, appears as a little red papule, breaking down after a few days and giving place to an ulceration; this remains isolated for some weeks, healing slowly and disappearing. The last period of generalization is ushered in with some general disturbance and

the outbreak of a great number of cutaneous lesions exactly resembling the primary one, but undergoing more marked changes with ulceration, crust formation and finally a papillomatous growth. Sometimes there is keratotic degeneration of the palms and soles. The glands are always enlarged.

The third period, commonly known as the period of deep ulcerations, is not considered by the author.

The Treponema pertenuis, detected by Castellani of Ceylon, has been universally considered as specific, and is very difficult to distinguish from Schaudinn's treponema.

The Wassermann reaction is positive in almost all cases of boubas.

The differential diagnosis from syphilis is established on the facts that the courses in both diseases are different, on the benign outlook of boubas, against the uncertain one of syphilis and on the possible coexistence of both diseases in the same patient.

The treatment with potassium iodide solution and with salvarsan and neosalvarsan, has been used by the author, with excellent results.

ZENTRALBLATT FÜR PHYSIOLOGIE.

(1914, xxviii.)

Abstracted by J. S. Eisenstaedt, M.D.

LOCAL VASO-MOTOR CUTANEOUS REACTIONS. N. Ebbecke, p. 724.

The author used a simple apparatus for the quantitative determination of various mechanical stimuli and the effect of thermal, chemical and electrical stimuli. The time required for the blood to return to an area from which it has been mechanically "pressed out" is a criterion for the rapidity in the capillary flow. There are nine different types of color change due to skin irritation, including dermographism and urticaria factitia as physiological for certain stimuli.

VIRCHOW'S ARCHIVS.

(1914, ccviii.)

Abstracted by J. S. Eisenstaedt, M.D.

THE ADRENALS IN CONGENITAL SYPHILIS. M. Simmonds, p. 152.

The most frequent pathological change of the adrenal in congenital syphilis is the so-called perihypernephritis syphilitica. The process is not limited to the capsule but is associated with atrophy of the border of the adrenal cortex. It may be associated with inflammatory processes in the parenchyma with gummata and necrotic areas in the glands. The inflammation of the capsule of the adrenal, however, is much more frequent than any of the other lesions.

MITTEILUNGEN DER GESELLSCHAFT FÜR INNERE MEDIZIN UND KINDERHEILKUNDE IN WIEN.

(1914, iii.)

Abstracted by J. S. Eisenstaedt, M.D.

THE COMBINATION OF ERYTHROMELALGIA AND RAYNAUD'S DISEASE. K. Radonicic, p. 231.

Radonicic reports a case of a young soldier who complained for over a year of pain in the lower extremities, coming on at night, which was characterized as a pulling pain from the toes to the thigh and which was relieved by the application of cold. Improvement followed the use of the faradic current and sedatives. However, under the influence of the various physical and mental traumata incident to active duty in the field, the condition recurred, the skin of the left foot was red hyperæsthetic and swollen. Ulcers had developed on the first three toes at the distal phalanges. Analgesia and hyperæsthesias are developing, stigmata of neuropathic origin.

JOURNAL OF NERVOUS AND MENTAL DISEASE.

(1915, xlii.)

Abstracted by J. S. Eisenstaedt, M.D.

UNILATERAL HYPERTROPHY OR TROPHŒDEMA OF LIMBS. H. T. Pershing, p. 65.

The patient was a young woman of twenty years, whose mother was affected with Raynaud's disease and whose brother had migraine. At the age of three years the patient had typhoid fever. At that time it was noticed that there was a difference in the size of the limbs. The left side appeared weaker and exercises were undertaken to strengthen that side. At the age of seven years she had scarlet fever, later frequent migraine attacks. Once she had an attack of ischæmia of the right index finger, which later recovered. That the right side was the thicker and the abnormal side, was definitely decided at the age of fourteen years. Her voice was husky and deep, the hair dry and fissured and grew more luxuriantly on the left than the right side. Both right extremities are now distinctly increased in size. There is no motor nor sensory disturbance, no increase in blood pressure. Thyroid is negative. No true œdema exists, but pressure leaves marks The case is one of trophœdema.

REVUE NEUROLOGIQUE.

(1914, xxii.)

Abstracted by J. S. Eisenstaedt, M.D.

EXPERIMENTAL CUTANEOUS REACTIONS WITH GLANDULAR EXTRACTS. Parhon and Satini.

Engelhorn and Wintz demonstrated that pregnant women showed a cutaneous reaction with placental extract, in analogy with the Pirquet and Abderhalden reactions. Stimulated by this work, Parhon and Satini attempted to develop specific and characteristic skin reactions with extracts of all the glandular organs. The report of their work is still too indefinite to be of practical use.

JOURNAL OF LABORATORY AND CLINICAL MEDICINE.

(October, 1915, i, No. 1.)

Abstracted by Oscar L. Levin, M.D.

PRECANCEROUS CONDITIONS OF THE SKIN. Martin F. Engman, p. 31.

The clinical factors which predispose the skin to cancer are: (1) Senility; (2) Actinism; (3) Chemical trauma; (4) Mechanical trauma; (5) Chronic inflammatory diseases. The author describes the clinical and histological pictures of the lesions produced in precancerous conditions. The earliest changes in the structure of the integument occur in the connective tissue of the corium and its vessels. Nutritional disturbances follow, and interfere with the normal metabolism and physiological functions, first of the connective tissue cells and later of the epidermis, which ultimately degenerates into cancer cells. Clinical and histological descriptions of the mammary and extra-mammary types of Paget's disease are given. This disease is the principal member of a group of distinct clinical entities exhibiting precancerous changes in the epidermis, without there being any evidence of local contributing ætiological factors.

(*Ibidem*, November, 1915, i, No. 2.)

FURTHER STUDIES IN THE TREATMENT OF SYPHILIS OF THE NERVOUS SYSTEM BY INTRADURAL INJECTIONS (OLD SALVARSAN). Udo J. Wile, p. 119.

The author reports the encouraging results obtained in fifteen cases of syphilis of the nervous system treated by means of intradural injections of small doses of salvarsan. The technique employed was a modification of that described by Ogilvie. No case received more than three injections, but there is a strong indication for further treatment in those cases showing improvement. The method of procedure, when carefully followed, is without danger and none has suffered as a result of the treatment. With full allowance for the possible

suggestive element, there is nevertheless a very marked subjective improvement in the majority of the cases. There is a definite objective improvement and in all but two cases there is a very definite improvement in the spinal fluid. The most marked benefit is noted in early brain and cord syphilis, but encouraging results were also obtained in tabes dorsalis. From three to eleven months have elapsed since treatment and in the twelve cases still under observation none has relapsed. The acute cases seem to have been permanently benefited.

MEDICAL RECORD.

(Oct. 16, 1915, lxxxviii, No. 16.)

Abstracted by I. Rosen, M.D.

SYPHILIS OF THE LUNG. M. T. Easton, p. 652.

The author reports in detail, a case of syphilis of the lung in a man, 51 years of age, who was taken with a severe hæmorrhage of the lungs during the early morning hours, at which time he coughed up a large amount of blood, also a large quantity of foul smelling, purulent sputum. Two weeks previous to this time, he had twenty-one hæmorrhages. He had lost about twenty pounds in the past six weeks.

The patient gives a history of having had a chancre on the penis seven years ago, and his treatment consisted of inunctions and internal medication for about three weeks, and no treatment since.

Physical examination of the chest revealed dullness over the right lower lobe, posteriorly, with increase of tactile fremitus. The pupils reacted very sluggishly to light, reaction to accommodation being normal. Complete absence of patellar reflexes and slight Romberg sign were noted.

Repeated examination of the sputum failed to find the tubercle baccillus.

The patient was treated with sodium cacodylate (three grains, every day for a time, and then every other day); after about fifteen injections, his condition improved markedly. The hæmorrhages ceased, the sputum became less purulent and the cough disappeared.

(*Ibidem*, Oct. 23, 1915, lxxxviii, No. 16.)

THE INTELLIGENT TREATMENT OF DISEASES OF THE SKIN. William S. Walsh, p. 698.

(*Ibidem*, Nov. 13, 1915, lxxxviii, No. 20.)

RHEUMATISM AND THE SKIN. William P. Cunningham, p. 815.

The paper deals with the author's views on acidosis in relation to rheumatism and various skin diseases.

IODIDE OF POTASSIUM IN SYPHILIS. DOUGLASS W. MONTGOMERY, p. 820.

Montgomery states that while iodide of potassium has no particular value as an antisyphilitic in the early stages of lues, this should not carry with it the assumption that it is altogether useless in this stage. It often has an excellent influence on the prodromal symptoms, such as fever, headache and pains in the limbs, in which case it is given in moderate dosage, eight to fifteen grains, three times a day.

As the iodides powerfully stimulate secretion and excretion, they aid in this way the elimination of mercury, and any other foreign matters present in the blood.

The specific therapeutic effect of iodide of potassium can be seen in gummatous and highly proliferative cutaneous lesions; these melt away under its use as if by magic. Furthermore, it is well known that luetic lesions of the nervous system are often directly connected with the blood vessels, and rightly or wrongly, clinicians for years have attributed to iodide of potassium, an easing influence on arterial tension and a beneficial action on the blood vessel walls.

ÆTIOLOGY OF PELLAGRA. B. W. PAGE, p. 826.

Page, after examining 600 specimens of fæces from 158 cases of pellagra, found an actively motile, cell-like body, that develops into a bacillus which at first is very active; it then rolls, turns somersaults, spins, and darts across the field, but soon reaches a state of rest and later presents a beaded appearance. The size of the organism varies from 0.5 to 1.5 microns in diameter (oval form). The rods vary from 2 to 6 microns in length. On agar, it grows primarily as a coccus. On a special medium containing two per cent. each, of beef extract, dextrose, corn and potato, with one and one half times the usual amount of peptone, it assumes the form of a bacillus. End spores are noticed in all cultures from two to six weeks old. The organism has a capsule barely visible, sometimes forming a halo. It stains with the common aniline stains for bacilli. Loeffler's alkaline methylene blue stains the organism very quickly.

(*Ibidem*, Jan. 8, 1916, lxxxix, No. 2.)

Abstracted by FRED WISE, M.D.

MERCURY ELIMINATION IN BICHLORIDE POISONING. VOGEL AND LEE, p. 58.

The paper is based upon the findings in 16 cases of mercury bichloride poisoning, treated at St. Luke's Hospital, during the past two years. Of this number, only two died as the result of the poison. Many interesting points are brought out in reference to the excretion of the mercury by the kidneys, bowels and the skin, and its re-excretion into the stomach. The advisability of making frequent tests on the urine, fæces, stomach washings and colon irrigation fluids, is strongly emphasized. In one case, mercury was detected in the stomach washings, despite the fact that the mercury gained access to the circulation *per vaginam*. The rate at which the drug is eliminated varies greatly in different cases, the cause of this variation being unknown. In eleven of the sixteen cases, the mercury persisted longer in the fæces than in the stomach washings and the urine. In one patient who had been taking frequent vaginal douches with mercurial solution, and had thereby contracted a severe diarrhœa,

the mercury was present in the stool, but absent in the urine, two weeks after the last douche had been used. In two out of four cases, mercury was also detected in the sweat, pointing toward the advisability of using hot packs in these cases.

In nearly all cases, an early leucocytosis takes place, with absolute and relative increase in the polynuclear cells.

Intestinal irrigation and gastric lavage are the important points to bear in mind with respect to the treatment.

THE USE OF STEAM IN THE TREATMENT OF SUPERFICIAL CANCER. W. J. GILLETTE, p. 65.

The author narrates his experience in the use of superheated steam, stating that he finds it of great value in the destruction of fungating growths of cancer and sarcoma, and in subjecting large areas to heat, as after removal of the breast by the Halsted operation. In sixteen patients, he has seen recurrences take place in four; to these he applied the same form of treatment, "with apparently good prospects of ultimate cure."

Steam may be caused to penetrate diseased tissues to the depth of an inch or more, according to Gillette, and appears to have a selective action on cancerous tissue, in that it follows the line of least resistance, the texture of the diseased area being less firm than the surrounding tissues. The author uses metallic shells, fitted with nipples and rubber tubing, through which the steam is forced at a boiler pressure of about fifty pounds.

A PRACTICAL METHOD FOR ESTIMATING THE PROTEIN CONTENT OF CEREBROSPINAL FLUID. J. A. F. PFEIFFER, p. 66.

The author employs sulphosalicylic acid as a precipitant for quantitative work in the examination of the spinal fluid for its protein content. The technique is as follows: "Three cc. of a 4 per cent. solution of sulphosalicylic acid are placed in a test tube 1 cm. in diameter, and 0.5 cc. of cerebrospinal fluid allowed to flow down the side of the tube, on to the surface of the acid. when a characteristic white ring appears, if an excess of protein be present, which reaches its greatest intensity in two minutes. An approximate estimation as to the degree of excess may be obtained by performing the test in several tubes, with dilutions of the spinal fluid from one to five, and comparing the results."

NEW YORK MEDICAL JOURNAL.

(Dec. 11, 1915, cii, No. 24.)

Abstracted by I. ROSEN, M.D.

THE HISTORY OF PELLAGRA. C. H. LAVINDER, p. 1169.

In the review of the history of pellagra, Lavinder regards the paper written by Gasper Casal, of Madrid, in the year 1735, as the first to describe the disease, under the name of mal de la rosa.

The following are the symptoms, (as described in Casal's book) peculiar to this disease and inseparable from it.

1. Constant movements of the head which, though common to all, are in some so continuous that not for a single instant are they free from irregular movements also of the entire body.

2. Painful burning of the mouth, accompanied by vesicles on the lips, and a foul tongue.

3. Distressing weakness of the stomach and lassitude of the whole body, especially the legs; along with profound general depression.

4. The scaling on the metacarpus and metatarsus, and a kind of collar around the neck.

5. Constant, severe burning sensations which torment these patients, especially when in bed.

6. A delicacy and fineness of the skin, which resists neither heat nor cold.

7. Mental depression which, with no adequate cause, assails these patients, provoking mournful tears, a phenomenon which of itself alone is a pathognomonic sign of this affection.

As to the ætiology of mal de la rosa, Casal says, atmospheric conditions and diet combined, in his mind constitute the essential causative factors, the former acting as a sort of predisposing agent, to lower resistance, and the latter precipitating the disease.

(*Ibidem*, Jan. 1, 1916, ciii, No. 1.)

Abstracted by Fred Wise, M.D.

SALVARSAN IN PRIMARY SYPHILIS. Uhle and Mackinney, p. 6.

Since 1910, the writers have treated 57 patients with genital and extragenital chancres, in private patients, and they submit a detailed report of the bacteriologic and serologic findings in these cases. The results of the treatment with salvarsan and neosalvarsan are such as to place the remedies in a very favorable light. With the disease still limited to the chancre itself, accompanied by a negative Wassermann reaction in the afflicted patient, salvarsan therapy in the hands of these authors has been fruitful of radical cures, both clinically and serologically. In the opinion of Uhle and Mackinney, the excision of the chancre before the dissemination of the spirochætæ into the circulation, is a very important factor in the consummation of the radical cure of early syphilis. Experience has taught them, also, that in the pre-Wassermann-positive stage of the disease, energetic salvarsan treatment is, as a rule, productive of cure; but that once the blood reaction becomes positive, the chances of radical cure are greatly lessened. In chancres of less than a week's duration, the Wassermann test was uniformly negative; while in those of more than a fortnight's duration, the opposite held true. Therefore, early intensive treatment is the key-note of success in the successful management of these cases.

The paper is an earnest and conservative effort toward placing salvarsan and neosalvarsan in their proper status in antisyphilitic therapy, and it merits careful perusal.

BOSTON MEDICAL AND SURGICAL JOURNAL.

(Nov. 18, 1915, clxxiii, No. 21.)

Abstracted by I. Rosen, M.D.

GUMMATOUS CERVICAL ADENITIS; ITS RELATION TO, AND MISTAKEN DIAGNOSIS FOR, TUBERCULOUS CERVICAL ADENITIS. Wm. Pearce Coues, p. 777.

The author, in this paper, emphasizes the importance of recognizing gummatous cervical adenitis, without other obvious signs of syphilis, mistaken in some cases for tuberculous cervical adenitis, and treated as such over a long period of time, without result. Coues has been fortunate to have under his observation several unusual and obscure cases of this nature, during the past few years.

The author reports in detail four cases of cervical adenitis, (all of them gummatous) that have come under his observation at the Boston Dispensary.

In his summary, he says that cases of cervical adenitis supposed to be tuberculous, yet not quite characteristic, should be regarded as possibly gummatous, and careful study with all the means at our command should be made to prove or disprove this supposition definitely. It has been proven that after all, the clinician must fall back on consideration of the case, with an exhaustive history pertaining to possible syphilis, to arrive at a correct diagnosis.

OBITUARY

Charles Townshend Dade.

Dr. Charles Townshend Dade died at his home in New York City on December 26th, 1915. He was born in 1859, in Mobile, Alabama. Before studying medicine he was engaged for several years in business. He graduated from the College of Physicians and Surgeons in 1891, after which he served as interne at St. Luke's Hospital and at the Nursery and Child's Hospital. He then studied abroad for a year under Unna in Hamburg and under Besnier, Sabouraud and Wickham in Paris.

Before specializing in dermatology, Dr. Dade served for several years as demonstrator of anatomy at the College of Physicians and Surgeons. He later became consulting dermatologist to Roosevelt, Central Islip, Englewood and Vassar Brothers Hospitals, and visiting dermatologist to St. Luke's Hospital. He also served for many years as clinical assistant in dermatology at the Vanderbilt Clinic of the College of Physicians and Surgeons and as visiting dermatologist to Randall's Island Hospital.

Dr. Dade was one of the pioneers in experimenting with liquid air and carbon dioxide snow in the treatment of skin diseases. Among his dermatological writings may be mentioned a chapter on diseases of the skin in the "Practice of Pediatrics," published by Carr, in 1906. He was a member of the New York Dermatological Society and at one time its president. He also belonged to the Academy of Medicine, the Quiz Medical Society and the Externe Society.

Dr. Dade was a dignified man of strong character and decided opinions. One of his most striking and best characteristics was an unusual degree of moral courage. He never hesitated to publicly declare his stand upon questions of medical ethics or principles. To those whom he considered his friends he was loyal and devoted. He is survived by two sisters and a brother.

H. F.

George Thomas Jackson.

Dr. George Thomas Jackson, who died after a brief illness on January 3rd, 1916, was well known as a teacher and an author. He was born in New York City, Dec. 19th, 1852. He married Miss Caroline G. Weidemayer in 1878, and had four sons, three of whom are living. His only brother, Rev. Dr. Samuel Jackson, was prominent as a writer on theological topics.

Dr. Jackson was educated in private and public schools of this city and after a year in the College of the City of New York and four years in business, began the study of medicine and graduated at the College of Physicians and Surgeons in 1878. He then devoted two years to medical study in Berlin, Vienna and Strassburg, starting in practice in New York City in 1881. He was an interne in the Charity Hospital, 1877-88, Visiting Dermatologist to Randall's Island Hospital, 1889-94, Assistant Surgeon, New York Skin and Cancer Hospital, 1885-89, Consulting Dermatologist, New York Infirmary for Women and Children, 1890-1916, Consulting Dermatologist to the Presbyterian Hospital, 1892-1913, Instructor in Dermatology, New York Polyclinic, 1884-89, Instructor in

Dermatology, Post Graduate Medical School, 1887-88, Instructor in Dermatology, College of Physicians and Surgeons, 1897-1907, Professor of Dermatology, Woman's Medical College of New York Infirmary, 1890-99, Professor of Dermatology, University of Vermont, 1895-1900, Professor of Dermatology, College of Physicians and Surgeons, 1908-1913.

He was president of the New York Dermatological Society in 1889, of the American Dermatological Association in 1901 and was treasurer of the International Dermatological Congress in New York, in 1907. He was also a member of the New York County and State Societies, the Alumni Society of Charity (City) Hospital and the Alumni Association of the College of Physicians and Surgeons. He contributed many practical articles to various medical journals and for many years was a member of the Editorial Board of THE JOURNAL.

His first work on Diseases of the Hair and Scalp was published in 1887. His treatise on Diseases of the Hair, written in conjunction with the late Dr. Charles Wood McMurtry, was published in 1912. His Handbook of Diseases of the Skin was very popular with students and the seventh edition appeared in 1914.

Dr. Jackson was an uncommon man in many respects and exemplified a type which all admire but are apt to associate with a past generation. He was generally recognized as the possessor, in a high degree, of certain solid qualities which are often lacking in men of the present day.

The chief elements of his character were a rugged morality, a transparent sincerity and a never failing loyalty. His ethical standards were high and while charitable to all holding adverse opinions, nothing could ever swerve him from what he considered to be the path of duty. He had both ambition and perseverance but neither the ability nor the desire to pose in any false position or to do anything simply for effect. In his moral and intellectual fibre there was not the least admixture of sham. His opinions when once formed were usually strong. His devotion to his friends and to his principles was even stronger.

G. H. F.

Plate XXVI.—Portrait of the Late George Thomas Jackson, M.D.



George Thomas Jackson, M.D.

BOOK REVIEWS.

SEROLOGY OF NERVOUS AND MENTAL DISEASES. By D. M. Kaplan, M.D., New York. Director of Clinical and Research Laboratories of the Neurological Institute, New York City; Serologist to the Montefiore Home. W. B. Saunders Company, *Philadelphia and London*, 1914.

In this volume the author has managed to condense a large amount of information in a comparatively small space and has written a most interesting and readable book. The first of the four parts into which the book is divided begins with a brief historical introduction of lumbar puncture, the author stating that the credit for first performing this operation properly belongs to an American physician, Dr. J. L. Corning. Under the title of anatomy and physiology is discussed the subarachnoid space and the question of the communication between the ventricular and spinal fluids. The operation of spinal puncture (rachicentesis) is next described in detail and illustrated by photographs. The indications and contraindications are mentioned and the technique, including the position of the patient, preparation for the operation and after care are discussed. The writer also mentions the possibility of a "dry tap" and the disagreeable effects that may attend a spinal puncture. He says that the care of the fluid after withdrawal is important and urges that cells be counted within an hour after withdrawal.

The next chapter deals with the physical and chemical properties of the fluid and the subject of cytology. The physical characteristics of both normal and pathological fluids are described. In the majority of diseased conditions, the writer states that the color is not distinguishable from that of normal fluids. In some fluids, besides giving a strongly protein reaction, a slight yellowish color was noted, such fluids generally coming from paralytic patients. Not much significance can be attached to variations in pressure in health and disease. It is simply important to know when the danger mark of low pressure is reached (100 mm. of mercury), and be prepared to inject salt solution. The writer then discusses the various methods that have been used to detect a globulin excess in the spinal fluid. The method of Nonne and Appelt, which is first described, is, he says, less popular than others, owing to the uncertainty of reading results. The Ross-Jones is better suited, he thinks, for clinical purposes "as the end result is more constant, is less influenced by individual interpretation and is sharper." The Noguchi test, which utilizes butyric acid and sodium hydrate, gives very satisfactory results. The complicated gold chloride reaction of Lange is discussed, after which the author's method is given.

In the chapter on cytology, the writer discusses the morphology of cells that are found in both normal and pathological fluids. He does not think that diagnostic importance should be attached to any form of cell except those from definite forms of tumor. The method of estimating the number of cells is next discussed, with illustrations of the counting chambers used. The writer's experience shows a maximum count for a normal fluid to be 8 lymphocytes per cubic millimeter, 15 for a border line count, 15 to 60 as a pathological increase, 60 to 250 as a hyperlymphocytosis and 250 to 2000 per cubic millimeter as the count of an acute meningitis. The chapter closes with remarks on bacteriological methods of studying the fluid, including search for tubercle bacilli.

The chapter on the Wassermann reaction gives the evolution of the test, beginning with a discussion of the principles of complement-fixation. For those who are not familar, however, with this subject the text is not particularly lucid. The writer discusses rather fully the technique of venesection, well illustrated by photographs. This is well worth reading for those (mostly experienced) who think that blood letting is entirely devoid of technical difficulties. The author's methods of preparing the reagents for the test, titrating amboceptor and antigen, etc., are given in detail. The significance of the controls and the actual performance of the test are explained. A few words are devoted to some of the proposed modifications as those of Bauer, Stern and Tschernogouboff. The chapter concludes with some pointed remarks entitled, "Attitude of the serologist." The author very properly says that "the function of the laboratory is not to diagnosticate syphilis; its duty is to report the results of a test tube experiment that has only a certain amount of specificity." He also thinks that the laboratory investigator should not be acquainted with the clinical symptoms before performing the tests, in order to avoid any possible bias in reading his results. He thinks that every serologist tends to err either in reporting too many positive reactions in non-syphilitic cases, or in finding too many negative reactions in those who are undoubtedly syphilitic. He apparently thinks there is no middle course and as the lesser of two evils prefers to arrange his reagents (using an excess of amboceptor) so that as few positive reactions as possible are reported in innocent non-syphilitic persons, even if this results in giving an inordinate percentage of negative reactions.

Part II is devoted to the consideration of the serology of nervous and mental diseases of non-syphilitic origin, including diseases of the meninges, brain, spinal cord and nerves and various organic and functional psychoses. A review of this chapter will, however, be omitted as it is chiefly the syphilitic affections that are of interest to the readers of THE JOURNAL.

Part III describes the serology of nervous and mental diseases of syphilitic origin. In this, as in part one, is given at the end of each clinical description, the laboratory finding in a horizontal column which the author designates as the "average formula." This includes the serum and spinal fluid Wassermann, the globulin test, the cell count and the reaction to Fehling's solution.

The writer recognizes four distinct types of tabes from the serological standpoint, including the "usual," "hyperlymphocytic," "negative" and "Wassermann fast" types. The "Wassermann fast" cases are those in which treatment is unable to affect the reaction in serum or fluid and which suggests a tabo-paresis. For the diagnosis of the rarer clinical forms of juvenile monosymptomatic tabes, a serological examination is essential. The "hyperlymphocytic" type, representing the greatest amount of meningeal irritation, shows the most marked response to treatment, while the "negative type," in the author's opinion, not only does not respond to, but may even be made worse by antisyphilitic treatment.

In discussing cerebrospinal syphilis, the writer calls attention to the fact that the nervous involvement depends, firstly upon the extent and distribution of the virus and secondly upon whether the changes are meningitic, endarteritic or gummatous in nature. Of the 184 cases of clinical cerebrospinal syphilis which the writer examined, 57.6% were of the Plaut or negative spinal fluid type, 33% of the positive spinal fluid type and 9.3% were of the acellular type, including those that had become acellular after treatment.

In regard to the influence of treatment, he remarks that the higher the cell count and the greater the proportion of polynuclears, the easier it is to improve the serological and clinical symptoms. In regard to a possible transition to general paresis, the writer thinks that evidence of such a change can be shown serologically before it can be detected clinically. The therapeutic test is the

best guide to judge of this transition, the characteristic symptoms being marked persistence of serologic abnormalities.

In the chapter on paresis the writer discusses the "Wassermann fast" phenomenon. He says that it may be regarded as a "migration of the treponema from accessible to deeper, inaccessible brain portions, establishing a depot for reagins and forming the histologic nucleus for future general paresis." When the Wassermann, especially the serum Wassermann, is positive in this disease, it seems to be most intense of any syphilitic disease of the central nervous system. The positive reaction is also somewhat different from that obtained in other syphilitic nervous affections. As a rule, at the conclusion of the test the sheep cells sink to the bottom of the tube quicker than in other forms of syphilis. The serum also shows a lateral constriction, looking like two parenthesis marks, with convex sides toward each other, while the serum at top and bottom is opaque and of old rose color. There is also not the slightest trace of hæmolysis, *e.g.*, the fixation of complement is absolute. Of the 261 cases of paresis examined, 120 were of the full fledged type, their serology showing a positive serum and fluid Wassermann, an excess of globulin and 17 to 50 cells. The other cases were grouped together under five different classes. The writer also gives a chart of the serologic progression in the stages of incipiency, full development and paretic decline. He then discusses the technique and significance of the gold chloride curve in paresis, or "step ladder" curve, as he terms it, accompanied by excellent Lumiére photographs of the cases and the curves as seen in various patients. The test, he says, is very constantly present in paresis, though not characteristic of central nervous syphilis in general. It is not found in either tabes or cerebrospinal syphilis.

The chapter concludes with some remarks upon the serology of early syphilis and its significance. The writer thinks that by the aid of serological examination, the future syphilologist will be able to classify cases that are or are not apt to develop lesions of the central nervous system. He thinks it plausible that the spirochætæ permeate the entire system at first, and gradually tend to settle in certain tissues, such as cutaneous, vascular, visceral, nervous, etc. Not only should treatment in the future be begun as early as possible, but the physician who treats the disease in its early stages must learn to be familiar with the serological conditions that are present at that time.

Part IV deals with the therapeutic use of salvarsan. It begins with an historical sketch of the experiments leading up to the discovery of both salvarsan and neosalvarsan, in which the inevitable formulæ are given. The methods of intramuscular and intravenous injections are fully described and are illustrated by some of the forms of apparatus that have been used. The after care of the patient and indications and contraindications for the use of salvarsan are then described. In cerebrospinal syphilis, especially with a high cell count, the treatment should be energetic. In tabes we should be satisfied to remove subjective symptoms. As to whether paresis is to be treated is yet a mooted question. That the drug is comparatively harmless as to life will be recognized when it is known that over five million injections have been given since 1911. The contraindications are few but they should be recognized. The water error ("Wasserfehler") is briefly discussed, the writer being still impressed with the importance of this possible cause of disagreeable symptoms, which, however, many consider to be entirely mythical. The biologic and the Marsh tests for arsenic are described, by means of which the drug has been found in the spinal fluid after salvarsan injections.

The intraspinal injections, according to the Swift-Ellis technique and the "intensive intravenous" method, as practiced at the Neurological Institute, are discussed in some detail. The local and general by-effects following injections

are then described, considerable space being devoted to a discussion of the Herxheimer reaction. The chapter ends with an exposition of the test for amino-nitrogen content of syphilitic serum. The technique and tabulated results are given.

A voluminous bibliography of 69 pages is appended, the articles being grouped according as to whether they are written in English, French, German or Italian. The work of the publishers is all that could be desired. The paper and print are excellent and the half tone illustrations are unusually good.

H. F.

THE JOURNAL OF
CUTANEOUS DISEASES

VOL. XXXIV. APRIL, 1916 No. 4.

ORIGINAL COMMUNICATIONS.

A CRITICAL REVIEW OF ECZEMA AND DERMATISIS, WITH AN ANALYSIS OF A GROUP OF CASES.

BY WALTER JAMES HEIMANN, M.D., NEW YORK.

Associate Professor in Dermatology, New York Post-Graduate Medical School and Hospital; Instructor in Dermatology, Cornell University Medical School; Attending Dermatologist, Lebanon Hospital; Assistant Visiting Dermatologist, German Hospital.

INTRODUCTION.

IF Willan had lived longer; if Biett and Biett's followers rather than Alibert and Alibert's school had dominated contemporaneous French dermatology; if Hebra and Kaposi had been internists rather than classifiers of dermatoses, and if Unna had never engaged himself with its bacteriological aspect, our understanding of eczema today would be clearer than it is. But Willan died too soon, Biett's views were heeded too late, Hebra and Kaposi made it their business to ridicule the "Willanists". Unna attempted to glorify the pathogenic rôle, in the causation of eczema, of a mythical microörganism called the morococcus, and eczema still remains unsolved. One grows weary of the classifications which render the study of this disease burdensome. Eczema had been differentiated from dermatitis in spite of looking and acting exactly like the latter. It had been subdivided according to its clinical type into vesicular, papular, scaling, crusted, impetiginous, fissured and weeping forms. It has been further subdivided according to its acuity and chronicity, and according to its location. Seborrhœa has been called both eczema and dermatitis. Overrefinement in interpretation of details, and failure to grasp essentials have been responsible for this confusion.

The more one reflects upon the subject, the deeper grows the convic-

tion, first, that there is no difference between eczema and dermatitis of external origin; and second, that all forms and varieties of eczema have common features, or spring from a parent type. The differences depend upon differences of causation and site rather than upon differences of the pathological process itself, and the duration and course of the disease are determined by the persistence with which its pathogenic forces are sustained, or are amenable to modification by therapy. An analysis of cases often reveals lines of cleavage in the entire class which divide subsidiary groups from one another, without, however, disrupting their common bonds. It is about one of these groups that it was deemed possible to build the present paper. Eleven cases presenting similar features developed so consistently and strikingly as to suggest a syndrome, were found in reviewing about two hundred histories. To these were added three more which have many features common to the larger body, and others peculiar to themselves. These serve, however, as links uniting the cases in question with the general class of eczemas. Before proceeding to a study of the cases it will be necessary to review the history of eczema as well as what has been written of its pathology, clinical forms, relation to dermatitis, seborrhœa, the lichens and prurigo. Above all, its ætiology and pathogenesis must be discussed in connection with the several definitions of the malady.

Section A.

History.

Brocq[1] and Besnier[2] have both presented the history of eczema excellently and clearly, and their articles have furnished the basis for this sketch. Willan and Bateman[3] regarded eczema as a vesicular affection caused by external and internal irritants, and they included artificial dermatoses in the group. In France two schools arose, one headed by Alibert, who was partly supported by Hardy; while the other was led by Biett, who was sustained by Cazenave, Schedel and Rayer, and whose views were perpetuated by Dévergie and Bazin. Alibert[4] regarded as eczema such diseases as herpes, urticaria, the erythemas, furunculosis, erysipelas, etc., excluding entirely what his predecessors had called eczema. True eczema he included in his description of the tineas and scaling herpes. His pupil, Hardy[5], classified the disease properly, considered it due to a "dartrous diathesis," and separated himself from Willan's ideas by emphasizing its internal origin and denying its external. Biett, with Cazenave and Schedel[6], and Rayer, subscribing to

Willan's ideas, regarded eczema as a vesicular disease, not always of external causation, but whether of external origin or not, he held that a predisposition must invariably be present. They maintained the same views on dermatitis, which they counted in with eczema.

Dévergie[7] applied narrow strictures to his conception of the disease, in substance that that was eczema which was characterized by redness, itching, the secretion of a fluid capable of stiffening linen, and the presence of small openings yielding this secretion. Bazin[8] regarded these facts as inessential and his article[9], paraphrased by Brocq[1], indicates that he interpreted eczema as a "special reaction of the skin to diverse causes."

Among the Teutons, matters were shaping themselves differently from the way they were in France. Hebra[10] and Neumann[11] regarded the disease as a purely cutaneous one, eliminating with a wave of the hand the remotest possibility of its being in any way related to the general body economy. Unna endeavored to prove that it was caused solely by a bacterium, a view which received but little support in his own country and none at all elsewhere.

In England, Erasmus Wilson[12] regarded the malady clinically very much as Willan had. He called it a chronic inflammation, but allied it with psoriasis, pityriasis, lichen, impetigo, rosacea and scabies, suggesting some of the ideas of Hardy[5] and ascribing the disease to an eczematous diathesis. M'Call Anderson allied himself with Wilson, while Tilbury Fox[13, 14] objected to the close association of lichen and psoriasis with eczema. This period ends that phase in the history of eczema in which explanations of its origin were sought in its clinical aspect and found in conjectural discussions of its nature. From then on, other criteria were brought to bear upon the problem which will be discussed in the section on ætiology.

Summary.

Willan and the English school in general regarded eczema as the cutaneous expression of a general disorder. The French followers of Biett allied themselves with Willan, while Alibert's conception was too crude to merit serious consideration. The highest point of empiric reasoning was reached by Bazin, in 1866, when he called eczema a reaction to diverse causes; the lowest point in 1872, when Hebra disavowed Willan, considering eczema as a purely superficial process capable of assuming various forms, and basing his attitude entirely upon the experimental results achieved by rubbing croton oil into the skin. In the light of microscopic, clinical, pathologic, biochemic, bacteriologic and

anaphylactic studies, we will be able, in the future, to apply sounder standards of reasoning to our work on eczema, but the fundamental views of Willan, Biett and Bazin, it is safe to predict, will be justified.

Section B.

The Pathology of Eczema.

Unna[15] considers eczema an epidermal inflammation, capable of serous saturation. Ormsby[16] thinks that the disease is not always catarrhal, and Walker[17] takes the opposite view. Galloway and Eyre[18] regard it as a cutaneous circulatory disturbance causing either local œdema or malnutrition. Bowen[19] quotes Calomiatti and Leloir, who found changes in the peripheral nerves, and Neisser, who regards the vascular changes as due to a tropho-neuresis; but the last emphasizes that epithelial œdema is the salient histological feature. Unna[15] denies that vesiculation is uniformly characteristic of eczema in the manner that it is of acute dermatitis, maintaining that eczema is frequently a scaling condition in which no vesicles are to be found. In such cases the picture is more like that of an erythrodermia. The clinical stages through which eczema and dermatitis pass, are, first, erythema, then successively papulation, vesiculation, weeping leading to crusting and scaling, or directly to scaling without weeping if the exudation is not profuse. In dermatitis, vesicle-formation is usually conspicuous, while in eczema this need not be the case. The process may be arrested in the erythematous stage whereupon involution occurs without exudation, but with desquamation, as in scarlatina, which microscopically resembles eczema closely (Rach[20]). If the erythematous stage be passed, papules and vesicles develop, or vesicles without papules. Should there be a slight formation of vesicles or only papules, involution takes place with scaling and without crusting. If weeping and crusting supervene, exfoliation is postponed until these symptoms are allayed. At any period the process may be arrested or may advance, and in an extensive eruption different stages may coexist. Thus the clinical picture is a varied one, and the microscopic picture faithfully reflects this fact. It will be simpler to eliminate a discussion of hypertrophic, warty, atrophic, and lichenified as well as elephantiasic eczema, since these forms are coincidences and need not have a place in consideration of the process, pure and simple. The erythema is due to vascular dilatation, both in the papillary body and corium. The vesicles are caused by epithelial œdema leading to local foci of liquefaction and necrosis in the stratum Malpighii. The œdema beginning, according to

Leloir[21], in the perinuclear space of the prickle cells, causes them to become spherical. This is called *alteration cavitaire.* When several neighboring cells become so changed, a space is formed which contains cell detritus, spherical cells in the process of disintegration, serum, bacteria and, at times, pus cells. This space is the vesicle, and its wall consists of normal epidermal cells. The detritus is derived from disintegrated cells. The spherical cells are those which have become hydropic and have survived for a time. They resemble toy balloons and are found at the bottom of the vesicle. They gave rise to Unna's[22] fanciful characterization of "ballooning degeneration." The presence of the bacteria is due to secondary infection of the vesicle, and the presence of pus cells is probably due to that of the microörganisms. Frequently, instead of the intracellular hydrops, the œdema starts in the intercellular spaces which, becoming dilated, separate the cells by a lace work of fine canals, imparting to the prickle layer a spongy appearance. This Unna[22] calls "spongiosis."

In the papular lesion the affected location is usually the papillary body. An infiltration of round cells, and at times polymorphonuclear leucocytes, arranges itself about dilated vessels, and the superjacent epidermis is thickened, œdematous, and frequently contains a vesicle. The weeping forms microscopically resemble the other two, but, in addition, ruptured vesicles are found surmounted by crusts. In the scaling forms which clinically resemble small and large erythrodermal areas, the vascular signs of inflammation are present; the epidermis is thickened, and we find acanthosis, hyperkeratosis, and at times parakeratosis and spongiosis. Vesicles, too, are often found, and at this point it may be stated that vesicles so minute may exist, that they cannot be recognized clinically. To all intents and purposes a vesicle is present even if only one cell exhibits cavernous alteration, for the vesicle in the ordinary sense is simply the sum of cells so changed, and the important feature is the destruction of the single cells. Of course, to suppose that only one cell may be affected is extreme, but interspersed among fully developed vesicles, numerous isolated œdematous cells may be found which never participate in the macroscopic picture of the disease. Such cells are also found in the scaling epidermis. Thus it becomes apparent that sharp differences in the various stages of eczema cannot be determined microscopically, and Unna's idea that vesiculation is not necessary in eczema is not borne out by fact.

It has been asserted that in dermatitis the epithelial changes precede those in the depths and that in eczema the converse is true, thus furnishing a basis for distinguishing the two processes. Such reasoning is

obviously a *tour de force.* In all essentials the microscopic aspect of the two processes, assuming that they are two processes, is identical.

The collagenous fibres in the early stages of eczema and dermatitis are œdematous, the lymphatics are dilated, the elastic fibres are unchanged and, so far as we know, the nerve fibres are not altered, although, as already stated, Calomiatti and Leloir seem to have found nerve changes, a circumstance which has never been corroborated.

Summary.

Eczema and vesicular dermatitis possess the same microscopic aspect, which, in terms of general pathology, is to be included among the exudative parenchymatous inflammations. Vascular dilatation with œdema characterizes the changes in the papillary body and corium, as do also lymphatic dilatation and swelling of the collagenous bundles. At times focal infiltrations develop, forming papules. In the course of events the epidermis is altered through œdema and cellular hydrops. This gives rise to accumulation of fluid, filling spaces left by disintegrating cells which have undergone a colliquative necrosis. These spaces are called vesicles. Either through rupture of vesicles or exudation of serum from the spongy epidermis, weeping with crust formation takes place. And as a regressive phenomenon, capable of occurring after any of the enumerated stages, there is desquamation. All of these stages or any combination of them may be found side by side.

Section C.

The Clinical Forms of Eczema.

Willan[3] recognized three forms of eczema; eczema simplex, impetiginoides and rubrum. Hebra[10] enumerated five types; the squamous papular, vesicular, red and impetiginous. Since then this sort of classification has permeated the literature, constantly growing more extensive and complicated, and always remaining quite as artificial. In the text books, three kinds of classification are found, that based on the course, that based on the clinical appearance, and that based on the regional distribution of the disease. In the first classification we have acute and chronic eczema, and many authors interpose subacute. In the second, taken from Ormsby[16], we find eczema erythematosum, papulosum, vesiculosum, pustulosum, rubrum or madidans, squamosum, fissum, craquelé verrucosum, sclerosum, nummulare, tuberculosum, diabeticorum and parasiticum. It will at once be obvious that this grouping is inconsistent.

The first eleven designations are descriptive of the clinical appearance of the lesions; the twelfth refers to a variety seen in tuberculous infants, and the thirteenth to a variety seen in diabetics. Hence these two border upon an ætiological classification. The fourteenth, in the older works would have included eczema nummulare, not unlike either Dévergie's disease or Pollitzer's[24] eczematoid affection of the hands, but the term parasitic implies the definitely established pathogenic rôle of a micro-organism, and hence would describe the cause but not the form of the eczema. The only parasitic eczema, confirmed by all conventional bacteriological standards, is the infectious eczematoid dermatitis of Engman[25], whose findings were corroborated by Fordyce[26] nine years later.

As to regional classification, Walker's[17] will serve as an example. He mentions eczema of the scalp, face, ear, eyelids, lips, beard, neck and elbow flexures, trunk, nipples, umbilicus, axillæ, genitalia, arms, legs, hands and feet. It requires no untrammelled imagination to realize that the anatomic differences of various body areas are capable of modifying the appearance of cutaneous lesions. An eczema of the scalp, face, axillæ and interdigital spaces would differ as the presence of hair alone, or hair and moisture, or moisture and warmth would mechanically cause changes in any lesion, regardless of its nature. Psoriasis patches of the scalp and knees do not look alike and neither do syphilitic papules of the chest and anus. The variations are not due to histological differences but to accidents of localization.

Summary.

No classification of eczema yet devised is sound, because we have been unable to restrict our conception of the disease according to precise standards. Pathological, clinical, topographical and ætiological factors form the basis for artificial distinctions, and all have been given equal value. There are no gradations for contrasts in such a grouping. An intelligent characterization of a case of eczema or dermatitis might be attained if it included the name of the disease, its clinical stage, its site and, if possible, its cause. The title, "Eczema, acute, in the vesicular stage, on the arms of a diabetic" would fulfil these requirements. For the sake of smoothness of diction this would have to read: "acute, vesicular eczema of the arms, in a diabetic." According to older works we would have four diseases included here, namely, eczema acutum. eczema vesiculosum, eczema brachiorum and eczema diabeticorum. As a matter of fact, it is but one illness, namely eczema, and all the other words simply qualify it.

Section D.

Relationship of Eczema to Other Dermatoses.

A glance at Brocq's[23] diagram will show, in the French master's striking, but somewhat involved manner, the complex relationship of eczema to other dermatoses. It is clear that in each of its various stages the disease must have common features with various other groups of dermatoses. In the erythematous stage it resembles the acute exanthemata and toxic eruptions. In all stages the question arises of its identity with or differentiation from dermatitis. In the vesicular stage it occasionally resembles herpes and dermatitis herpetiformis. In the papular stage its relationship to the lichens, prurigo and urticaria must be defined. The pustular forms border upon suppurative folliculitis and impetigo. Disseminated areas of scaling eczema have features in common with psoriasis and seborrhœa, while universal scaling eczema suggests the erythrodermias, including the premycotic forms. The problems for practical consideration are those involving its relationship to dermatitis, seborrhœa, the lichens and prurigo.

Eczema and Dermatitis.

Willan and Bateman,[3] Biett, Cazenave and Schedel[6] and Hebra[10] unqualifiedly assert the identity of dermatitis of external origin and eczema. Kaposi[27] regards eczema partly due to internal, and partly to external, causes. Anderson[28] states that external agents, such as mercury, provoke eczema, and Tilbury Fox[14] says, "take a given number of persons and apply to their skins the same local irritant, and you will have eczema in some and not in others." Unna[15] objects to Hebra's views and Kaposi's, and states that vesicles are more characteristic of dermatitis than of eczema. Fordyce[29] finds no good way of distinguishing between the two processes either clinically or histologically. Jacquet and Jourdanet[30] assert a relationship between occupational dermatoses and predisposition determined by digestive disturbances. Conklin[31] quotes Bishop's characterization of eczema as the "dermal analogue of coryza." Ormsby[16] differentiates the two rather by the history than by special differences in the appearance and evolution of the lesions. "In many cases," he says, " the two affections are indistinguishable." He adds that, "the subsidence of the symptoms after the removal of the cause will also point to the nature of the affection," and concludes with the observation that eczema is more capricious in its distribution than dermatitis.

Thus Willan, Bateman, Biett, Cazenave, Schedel, Hebra, Kaposi and Fordyce take the unequivocal stand that eczema and dermatitis are identical. Unna opposes this view, but only because his conception of the matter is biased by his belief in the bacteriological causation of eczema, and by efforts at clinical and histological distinctions between eczema and dermatitis, which will not withstand analysis. Anderson, Fox, Jacquet and Jourdanet postulate the doctrine of predisposition as a factor in the ætiology of dermatitis of outside origin. Ormsby admits that the criteria of differentiation between the two diseases are vague, if indeed they exist at all. Bishop considers eczema a cutaneous coryza, which immediately identifies it with dermatitis. In the section on ætiology it will appear that eczema is due both to external and internal causes, and that dermatitis cannot occur without predisposition, bearing out what has already been stated. By the first axiom then, it would follow that dermatitis and eczema are identical, a point of view which will be assumed in the remainder of this article.

Seborrhœa.

Unna[15] collects all forms of seborrhœa under one head, renames them according to their clinical features, and finds that anatomically they are characterized by parakeratosis, and are caused by the bottle bacillus and the morococcus. Their histological and bacteriological features are sufficient, in Unna's mind, to serve as a basis for identification with eczema. Brocq[23] accepts the underlying contention of Unna, but withdraws some of the forms from the latter's comprehensive list. Those of us whose vision is less acute than that of a Brocq or an Unna may see fewer types of seborrhœa than do these two authors, for they have established clinical entities on the basis of the slightest variations in color, outline, grouping and fat content of the lesions, and in other features which seem in the main accidental. Walker[17] does not accept the idea of seborrhœal eczema, but does admit of a seborrhœal dermatitis. Duhring[32] agrees with Unna's pathological findings in seborrhœa, but he conceives of eczema as more extensive in significance than seborrhœa. Neisser, according to Brocq[1] and Tommasoli, exclude seborrhœa from eczema, while Crocker and Jamieson entertain views similar to Walker's. Kaposi[54] accuses Unna of having coined the word seborrhœal eczema. He is willing to use it as a symptom implying a mixture of sebum with ordinary eczema crusts. Unna[15] maintains that seborrhœa is the most important form of eczema because it is the most common, because it frequently passes over to other forms, because it is frequently the ascer-

tainable starting point of eczema. This is not clear. If seborrhœa is eczema, it is difficult to see the necessity of stating that it is the starting point of eczema.

Undoubtedly there is a clinical entity which deserves a special designation, and it has been called seborrhœa. It closely resembles psoriasis, differing from this disease chiefly by the frequency with which it is related to eczema, a fact never true of psoriasis. This relationship may be explained as follows: Seborrhœa may be latent eczema, the starting point of eczema or a predisposing cause to eczema. If it were latent eczema one would expect more individuals with seborrhœa of the scalp, for instance, to develop eczema, but the proportion of people in whom this is the case, is small. The same is true of other forms of seborrhœa. On the other hand, it is true that the proportion of patients suffering with eczema, who have first had seborrhœa, is great. Neisser[33] denies seborrhœal eczema, but recognizes an eczematized seborrhœa. Brooke[34] interprets seborrhœa as the starting point of eczema. Both of these views are consistent with the second and third explanations of the possible relationship between the two diseases. What is gained by the substitution of seborrhœal dermatitis for seborrhœal eczema, as Walker, Crocker and Jamieson advocate, is not clear. If eczema and dermatitis are identical, as the earlier passages in this paper have attempted to prove, there is no difference between the ideas of seborrhœal eczema and seborrhœal dermatitis, and the new term simply replaces one vague concept with another.

To sum up, then, it is clear that a relationship exists between seborrhœa and eczema. Eczema frequently arises in seborrhœal areas. Whether these are its starting point, or simply regions predisposed, makes little difference. Seborrhœal skin is fertile soil for the development of eczema and it will be reasonable to regard such skin as a *locus minoris resistentiæ,* peculiarly adapted for the changes we characterize clinically as eczema.

Relationship of Eczema to Prurigo, Lichens and Lichenification.

Occasionally some of the lesions in eczema suggest wheals, and some of the papular lesions remind one of prurigo. The clinical differences between prurigo and eczema, however, are too clear to cause confusion. In the older days chronic papular diseases were given the name of lichens, of which Willan[35] recognized five types: lichen simplex, a disseminated papular eruption (probably papular eczema); lichen agrius, which corresponds to Hebra's prurigo or eczema; lichen pilaris, lividus

and tropicus. Bateman[3] added to these lichen circumscriptus and lichen urticatus, the latter a papular urticaria related to simple prurigo, the former the historical forerunner of Vidal's disease. Rayer[36] had a similar classification, while Cazenave[37] described only lichen circumscriptus, lichen inveteré, and lichen agrius. He observed a transition from lichen simplex to lichen agrius, and this is the earliest record of eczematization. Hardy[38] enumerated the above forms and mentioned that the circumscribed variety occurred on the external surface of the forearm. Brocq[23] discusses all of these manifestations under the head of "neurodermites, or better, pruritus with lichenification." He states that, in itching diseases, scratching and other traumata gradually cause a modification in the appearance of the skin known as lichenification. This process corresponds to lichen circumscriptus of the old authors, eczema chronicum and papulatum of the Hebra school; lichen simplex chronicus of Vidal and neurodermite of Brocq and Jacquet. Vidal looks upon lichenification as a syndrome developing in the course of several dermatoses at points exposed to traumata. It is the result of the summation of stimuli in predisposed individuals. Brocq[1] contends that it has nothing in common with eczema, "either in aspect, for it is dry and non-vesicular, or histologically, or in development, or in evolution." Neisser[39], on the other hand, groups lichen chronicus simplex among the eczemas, while Török calls the phenomenon lichenization and ascribes it to scratching and chemicals. The French dermatologists, whether Vidal[41] with his lichen simplex chronicus, or Brocq with his neurodermite, incline to the opinion that they are dealing with an independent clinical entity. The Teutons, with Hebra and Neisser as their spokesmen, regards this disease as a form of eczema. It is certain that lichen chronicus simplex has definite characteristics. It is circumscribed, thickened, sharply defined, cross hatched by the exaggerated linear configuration of the skin, shows no tendency to vesiculation and is preceded by itching. It favors the elbow and knee flexures as sites, the nape of the neck, small of the back, and anterior aspect of the wrists, but may develop anywhere else. It must be differentiated from lichenification of Brocq and lichenization of Török[40] and Besnier[42]. Lichenification is a consecutive lesion caused by scratching, trauma or irritants. and it develops in any itching disease, notably in eczema, prurigo, dermatitis herpetiformis, and in neglected cases of scabies. It is a thickening of the skin due to an infiltration. Its site is determined by its cause, and it may be the starting point of fresh vesiculation in eczematous patients. Not every individual exposed to irritation acquires areas of lichenification. This fact implies predisposition. Eczema must

be separated from lichen chronicus simplex or neurodermite, which is a disease entity. On the other hand, eczema is one of the diseases of which lichenification is a consequence.

Section E.

The Ætiology and Pathogenesis of Eczema.

The pathogenesis of eczema has been accounted for in three ways: through internal causation, through external causation, and through the activity of external agents in the predisposed.

1. *The Internal Causation.* In ancient French medicine, when eczema was regarded as a "dartre," its cause was considered a "dartrous diathesis." The expression was vague and had replaced the classic term, herpes, which was equally indefinite. Because of its lack of precision Willan[3] abandoned it, although he retained the idea of the internal causation of skin diseases. Hardy[38] resurrected the expression and used it to signify skin affections constituted of various elementary lesions noncontagious, often hereditary and disposed to invade new regions. The substance causing the "dartre" was a vice or virus but since it was not inoculable this concept was inaccurate. Thus the expression dartrous diathesis was found preferable. The manifestations were supposed to be apparent health, excessive appetite, itching without objective lesions, chiefly about the anus, and cutaneous hypersensibility. Sooner or later, such individuals get vesicles, papules, and scales which extended symmetrically and vanished without trace. The mucous surface of the body orifices were often involved, as well as the external canal of the ear. Hardy quotes Boulan, Fontain and Gueneau de Bussy, who noted alternation between attacks of dartre, and bronchitis, gastroenteritis and gastralgia. For the most part, however, dartres were not supposed to be accompanied by systemic symptoms, except acute eczema which frequently began with malaise, lassitude and fever. A dartre was rarely cured, but the prognosis, as far as life was concerned, was good.

Alibert called eczema a wet and scaling dartre (herpes squamosus madidans). Biett thought it due to a disease of the "vascular membrane of Eichhorn," evidently the papillary body, and Cazenave considered it a malady of the sweat glands. The idea of the dartre crept into later French dermatology in the guise of arthritism, and into the English, in that of the gouty diathesis. The Germans abandoned it entirely, the only hint of it being in Kaposi,[27] who alludes to the occasional febrile onset of acute eczema, suggesting Hardy's observation of the same fact.

Besnier[2] divides the general causes into the following five groups:

1. Predisposition; heredity, syphilitic or alcoholic ancestors, parents with prurigo, urticaria, psoriasis, constitutional weakness, bronchitis, lithiasis, diabetes, etc.

2. Physiological and evolutionary causes; infancy, dentition, pregnancy and lactation.

3. Nervousness.

4. Functional; disturbances of digestion, assimilation and urinary disturbances.

5. Local predisposition; cutaneous anomalies, as ichthyosis, keratosis pilaris, hyperidrosis, seborrhœa, hypersteatosis, skin folds, and body orifices.

This classification possesses no virtue but comprehensiveness. Each of the enumerated conditions has been regarded by some writer or other as the essential cause of eczema. Besnier[2], Anderson[28] and others think heredity may play an ætiological rôle. The majority of writers and most emphatically Kaposi[27], Hebra and Dévergie (see Anderson[28]) deny this. General debility due to cachexia, bronchitis (Fox[14]) and diabetes (Neisser[39]) have been accused, as has also been disturbed vascular tone. Three groups of causes, however, stand out above the others,—the nervous, digestive and metabolic.

Tilbury Fox[14] finds the disease due to "perverted innervation." Anderson[28] mentions mental excitement, grief, over-study, and sedentary habits among causes; Malcolm Morris[46], mental depression and nervous shock, a point of view acceptable to Johnston[47], who denies, however, that there are any demonstrable nerve lesions. Bulkley[50] enumerates neurasthenia, nervous and mental shock, reflex internal neuroses, such as those due to dentition, and reflex external neuroses, such as scratching and irritation, as well as structural and functional neuroses. Hall[45] thinks that the disease is a reaction of the cutaneous nerves to external irritation. Neisser[33] finds a vague relation between the disease and a nerve disturbance. Kesteven[49] recognizes a ganglionic disturbance producing idiopathic, and a peripheral disturbance causing traumatic or external eczema. Bulkley considers the disease a trophoneurosis, as do also Kromayer and Crocker, according to Fordyce[29], and finally Anderson[28] adds the menopause as an ætiological factor.

Many authors agree that the digestive tract plays an important pathogenic rôle. Towle and Talbot[44], who studied infantile eczema, and Anderson[28] are among these. Anderson particularly emphasizes that constipation is associated with eczema of the face, hands and arms, and Walker[17] states that eczema about the anus and mouth is digestive in origin.

Kaposi[27] and Johnston[43] believe that metabolic disturbances are among the causes of eczema. Johnston[43] states that "all eczemas must have a basis of failure of metabolism for their development." He particularizes as far as the internal secretions and nitrogen metabolism are concerned. Neisser[29] emphasizes chemical substances elaborated in the cachexias, gout, diabetes and lymphatic diathesis, and Fox[14] mentions gout and nephritis. Towle and Talbot[44] find disturbed fat and sugar metabolism at fault in infantile eczema. In adults, however, no disturbances could be ascertained by Schwartz and Heimann[51], in a series of examinations conducted to determine the content of sugar in the blood. In a large percentage of seborrhœa patients, however, a hyperglycæmia was found, and in one diabetic with pruritus there was also an increase of blood sugar.

2. *The External Causes of Eczema.* Three groups of external causes of eczema have been described in the literature,—local predisposing causes, irritants and microörganisms. The local predisponents are, according to Besnier[2], cutaneous anomalies such as ichthyosis, keratosis pilaris and hyperidrosis; diseases such as seborrhœa and hypersteatosis; and anatomical features such as folds of the skin, and the vicinity of body orifices. Brocq[1] looks upon dysidrosis as a frequent cause of eczema, while Jadassohn[55] considers it actually an acute recurrent form of the disease. Practically all authors admit the rôle of local predisposing factors. It will be unnecessary to elaborate greatly upon the subject of irritants. These may be mechanical, physical or chemical. The mechanical are traumata, such as rubbing, scratching and the vocational employment of tools and implements. The physical causes are cold, heat and light, particularly the Roentgen and ultra-violet rays. The chemical causes are found in the local application of drugs and cosmetics, in the use of chemicals such as cleansing powders and fluids, disinfectants and substances peculiar to the various trades, arts and sciences. This whole group constitutes occupational, professional and artificial dermatitis or eczema, which has been fully discussed in the section dealing with the identity of eczema and dermatitis.

The part played by microörganisms in eczema is still under discussion. That bacteria are found in the lesions is indisputable. Whether they cause the lesions, or only their toxines do, whether they only irritate the lesions, exciting complications, or whether their presence is simply a coincidence, are the points still to be settled. Unna[52], in 1900, reported at the International Dermatological Congress held in Paris, the results of about ten years' work from which he concluded that a special organism, the morococcus, caused eczema. In the course of his investigations he

isolated twenty-three strains of cocci which fell into three groups. The first group he considered the specific cause of eczema because it produced vesicles, spongiosis, acanthosis, proliferation of the collagen, and, above all, parakeratosis. The second group gave rise to a disease which simulated eczema. The third group caused the formation of crusts, but nothing more. Thus he regarded the first group, or the morococci, as eczematogenic, and the others merely as pathogenic. He described the cultural and morphologic characteristics of the organism, and affirmed that it was not a staphylococcus. All other authors disagreed with Unna, holding, in the first place, that the bacterium he described was nothing but Welch's skin staphylococcus, and in the second, that it did not provoke eczema. The only diseases resembling eczema on which the pathogenic rôle of a microörganism has been universally accepted is Engman's[25] infectious eczematoid dermatitis, caused by a staphylococcus, and Hebra's eczema marginatum, caused by an epidermophyton, discovered by Koebner, in 1864, and confirmed by Pick and Kaposi, five years later (Kaposi[54]). Azua and Mendoza[53] found a Staphylococcus aureus which caused vesiculation. Raab isolated the Staphylococcus aureus from eczema lesions but did not find it pathogenic, and Pertini[58], Neisser[59], Dockrell[61], and Kaposi[27], all absolutely deny Unna's contentions, as do Török, Brocq, Sabouraud, Lerredde, Scholz, and Kreibich (Fourth International Congress).

The writers enumerated find that the staphylococcus common to the skin is usually not pathogenic, and Galloway and Eyre[56] say that "there is no reason for separating these organisms into species, and still less reason for stating that one of these species is the specific cause of eczema." Jadassohn[55] explains their presence in eczema as a "local invasion of banal microbes." Streptococci, according to Fordyce[29], cause a form of eczema madidans, but according to Jadassohn, the only superficial skin lesions these organisms excite are those of impetigo contagiosa, while staphylococci cause Bockhardt's impetigo. Lewandowsky[65] confirmed Jadassohn's views on streptococci in an exhaustive study.

Brocq[57] thinks that some of the complications of eczema are due to staphylococci, a view in which Galloway and Eyre[56] and Norman Walker[17] concur. Whitfield[60] holds that they intensify the process, his conclusions having been drawn from investigations in infantile eczema. Bender and Gerhardt[62], experimenting with bacterial filtrates, found that these caused papulo-vesicular eczema. Cole[63] could not corroborate this. Bockhardt[64] is of the opinion that staphylococci lie dormant in follicular openings until some internal disturbances render the soil

favorable for their toxines to become pathogenic, whereupon there ensues an attack of eczema.

3. *The Combined Internal and External Causation of Eczema.* Willan[3], Rayer[36], Neisser[33] and many of their respective pupils believe that external agents in predisposed individuals, cause eczema. Tilbury Fox[14] and Fordyce[29] hold the same view with regard to forms of the disease caused apparently by chemicals. Jacquet and Jourdanet[30] explain occupational eczema in this manner, and Hall[45] corroborates this view. It seems impossible to escape the logic of such reasoning for otherwise every one exposed to like excitants would have eczema, or no one would.

4. *Summary and Analysis of Facts Concerning the Ætiology of Eczema.* Ignoring the archaic concept of the dartrous diathesis and arthritism, there are internal or general conditions favoring the development of eczema. The most prominent of these are disturbances of either the sympathetic or peripheral nervous system, digestive or nutritional derangements, and metabolic disturbances, including derangements of the glands of internal secretion. Digestive and nutritional diseases might cause an intoxication either through engendering intestinal poisons by some abnormal digestive process, or by rendering the gut permeable to poisons which would otherwise not be absorbed. These noxious substances would act either as toxines in the simple sense of the word, or as anaphylotoxines, a view which seems particularly valid in instances in which the eczematous process possesses urticarial elements. At times, Czerny's exudative diathesis is suggested. Metabolic diseases, and those of the internal secretory glands, would act much in the same manner, by causing the presence in the body of substances which are not normally there, as in gout, nephritis, disturbed nitrogen metabolism, diabetes, or in abnormal fat and sugar chemistry, although, as already stated, hyperglycæmia seems usually more related to seborrhœa than to eczema. The rôle played by the nervous system, chiefly through the peripheral nerves, may be considerable, especially as affecting vascular tone in the sense of Neisser[39], and one cannot help recalling Kreibich's[66] experiences in his studies upon the influence of the nerves on vesicle and bulla formation. It is certainly probable, whatever other internal causes there may be, that the nervous system is involved in the process, if only in a reflex sense, as the appended cases will illustrate. The toxines indicating an internal disturbance must affect the skin either by their presence there in an effort at excretion, or by altering the chemistry of some of the epidermal cells in such a manner as to raise their susceptibility to external irritants. Whereas the first method is

conceivable, the latter appears more likely, or the process would involve the entire surface of the body instead of selected areas.

Not every one exposed to corrosive sublimate, poison-ivy, laundry powders, cosmetics or actinic rays acquires eczema. Thus it is evident that the various irritants mentioned, alone, cannot cause the disease. This implies a predisposition. The theory of the pathogenesis of eczema by bacteria seems to have been disproved. Assuming, however, that we may some day revise our views on this subject, a predisposition here, too, would have to be supposed. Therefore the mechanism of the production of eczema involves two factors, a local irritant, and receptivity. Whether the local irritant is chemical, physical, mechanical, or bacterial, and whether the predisposing cause is inborn or acquired, nervous, mental, metabolic, toxic, reflex or digestive, is all less important than to realize that neither the external nor the internal derangement alone causes eczema, but that the two together are needed to produce this effect.

Section F.

The Definition of Eczema.

Jadassohn[55] finds eczema difficult to define. After excluding prurigo, neurodermite, impetigo, Morris's follicular eczema, seborrhœa and Unna's seborrhœal eczema, he accepts Walker's definition. Wilson[67] says that, "Eczema is a chronic inflammation of the skin attended with desquamation, exudation and pruritus." Unna[15] emphasizes insidious onset, chronicity, itching, scaling and its parasitic causation as the characteristic points of the disease. Tilbury Fox[14] calls it a "catarrhal inflammation of the skin which is characterized by a peculiar discharge, stiffening linen, and drying into yellow crusts, and having its stages of erythema, papulation, vesiculation, discharge," etc. Kromayer[68] regards it as an inflammation of the parenchyma of the skin. Bazin[9] generalizes beyond narrow clinical and pathological points and interprets the process as a "special reaction of the skin to diverse causes." Brocq[23] elaborates this idea. "Eczema," he says, "is a special reaction of the skin produced by the most diverse external and internal causes, and the type of this reaction depends upon idiosyncrasies of the patient." Walker[17], trying to simplify and eliminate, epigrammatically asserts that "Eczema is the term commonly applied to any wet or scaly inflammation of the skin, of the cause or nature of which the observer is ignorant." Johnston[43] calls it a "catarrhal dermatitis."

The last four views together would fill all the requirements of a

comprehensive definition. Jadassohn[55] excludes everything which is not eczema, but he does not define the disease. Wilson and Unna only characterize some of its features. Kromayer's definition is a pathological explanation. Bazin and Brocq indicate the breadth of the pathogenic mechanism of the disease. Walker's definition is excellent so far as it goes, and Johnston's is perfectly accurate providing one knows what a dermatitis is. It has the good feature of indicating the extensiveness of the word dermatitis and the restrictedness of the word eczema, and at once eliminates a discussion of the differences between the two by including eczema in dermatitis. A composite of the views of Brocq, Walker and Johnston would clearly define the disease, and with the hope of having met this requirement the following definition is submitted: *Eczema is a catarrh of the skin possessing the pathological characteristics of an exudative inflammation. It is characterized clinically by redness, swelling, the presence of papules, vesicles, pustules, weeping, crusting and scaling in varying combinations. In its course it may be acute, subacute, chronic, and its origin depends upon an interplay between various known and unknown local and predisposing causes, to which the skin lesions are reactions.*

Section G.

Analysis of Cases.

In describing these cases, only those facts will be recorded which have a bearing on this paper. None of the negative findings will be mentioned. In all of the cases, itching or burning was present, and all involuted by desquamation. In several cases weeping was present.

CASE REPORTS.

Case 1. Mrs. E. H. Sixty years old; first seen on October 31st, 1910.

Past History. Excitable, had undergone prolonged period of mental strain due to personal troubles.

Present Illness. One month's duration, following use of a hair dye which had been employed with impunity for nine years.

Examination. Papulo-vesicular eczema of scalp, papules and lichenfication on nape of neck. Excoriations of elbow and knee flexures.

Course. Gradual improvement; well after twelve days. An attack of urticaria at this time, which rapidly disappeared. Seven weeks later, relapse following use of same hair dye. Well in fourteen days.

Treatment consisted of wet dressings and soothing lotions.

Case 2. Miss H. R. Thirty years old; first seen on December 30th, 1912.

Past History. Chronic asthma and bronchitis for years, chronic constipation. Nervousness of years' duration, for which bromides had been used.

Present Illness. Two weeks' duration, coming on twenty-four hours after the use of a hair dye.

EXAMINATION. Vesiculo-papular eruption on the scalp, face and neck.
COURSE. Recrudescences after thirteen days, and again after twelve days, without use of hair dye.
TREATMENT. Wet dressings and lotions.

CASE 3. Mrs. H. L. Forty-eight years old; first seen on May 12th, 1914.
PAST HISTORY. Nervous, fussy, constipated, frequent attacks of urticaria.
PRESENT ILLNESS. Three weeks' duration, dating from the use of a new hair dye.
EXAMINATION. Erythematous and œdematous papulo-vesicular, weeping and crusted eruption on scalp, face, chest and flexor surfaces of elbows.
COURSE. Œdema disappeared in four days, slight recrudescence two days later. Well in two weeks.
TREATMENT. Wet dressings and colon irrigation.

CASE 4. Miss R. T. Twenty years old; first seen October 27th, 1911.
PAST HISTORY. Chronic constipation.
PRESENT ILLNESS. Erythematous, œdematous, papulo-vesicular, weeping and crusted eruption on scalp, face, neck, eyelids, and in elbow flexures.
COURSE. Well in thirteen days.
TREATMENT. Internally, salts and enemata. Locally, wet dressings and lotions.

CASE 5. Mrs. S. P. Fifty years old; first seen September 11th, 1912.
PAST HISTORY. Nervous, indolent, pampered, fidgety, constipated, and careless in diet.
PRESENT ILLNESS. Five days' duration, following use of a new hair lotion.
EXAMINATION. Papulo-vesicular rash on ears, in aural folds, on scalp, anterior to temporal area. During the ensuing week the entire scalp to the forehead was involved. Indicanuria was present.
COURSE. Well in twelve days. Six months later, after two months of dietary indiscretions, but without use of hair dye, recurrence, which lasted twelve days.
TREATMENT. Lotions and dressing. Colon irrigations: low proteid diet and sedatives.

CASE 6. Miss E. Q. Thirty-six years old; first seen December 12th, 1911.
PAST HISTORY. Irregular and sparse menses, nervous, easily upset.
PRESENT ILLNESS. One and one-half years' duration off and on, in cold weather, well in warm. Present attack of one month's duration, immediately after use of "tri-coperas" hair lotion.
EXAMINATION. Erythematous, scaling, vesicular, weeping and crusted eruption on face, scalp, behind ears and in the elbow flexures.
COURSE. Well in eighteen days.
TREATMENT. Wet dressings and lotions.

CASE 7. Miss L. A. Thirty-three years old; first seen November 4th, 1912.
PAST HISTORY. Nervous. Itching of scalp, three and a half years.
PRESENT ILLNESS. Two and a half weeks' duration, following use of "tri-coperas" hair lotion.
EXAMINATION. Scarlatinoid, vesicular and weeping eruption on neck and breasts.
COURSE. Improvement in sixteen days, seborrhœal patches on scalp on tenth day. Urticaria on thirty-fourth day. Eczema well on thirtieth day.
TREATMENT. Wet dressings and lotions.

Case 8. Mr. A. S. Fifty years old; first seen October 31st, 1911.

Past History. Nervous, emotional artist.

Present Illness. Erythematous-papulo-vesicular eruption on sternum, following ten days' use of a strong resorcin solution, prescribed by his physician for seborrhœa.

Course. Improvement in eleven days; four days later, recurrence; six days later, improvement. Consulted another dermatologist; succession of recurrences, although resorcin was not used again.

Treatment. Wet dressings and lotions.

Case 9. Miss B. C. Twenty-two years old; first seen August 13th, 1912.

Present Illness. Vague history of exposure to rhus. Used a bust developer, after which an eruption appeared upon the chest and extended to the extremities, neck and face.

Examination. The lesions were erythemato-vesicular and squamous in type.

Course. Nearly well in six days. Recurrence two weeks later, following a fresh application of the bust developer. Well in a fortnight.

Treatment. Wet dressings, lotions and an aqueous solution of 50% ichthyol.

Case 10. Mrs. M. R. Forty years old; first seen June 28th, 1915.

Past History. Right-sided nephrectomy for tuberculosis, eight years ago. Chronic constipation, nervous, fussy, poor self-control.

Present Illness. Eighteen days' duration, beginning as urticaria. Lactose had been used for her constipation. An attack of furunculosis of three weeks' duration was present.

Examination. An erythemato-papulo-vesicular, œdematous, weeping and crusted eruption was present on neck, chest, upper extremities and knee flexures. Furuncles on face.

Course. Well in fourteen days. Four days later, wore a new colored silk waist, and an erythematous-papular rash appeared on chest and arms where waist touched skin, and nowhere else. Well in six days.

Treatment. After stopping lactose, furunculosis disappeared, although treated without avail, surgically, until then. Calcium lactate, colon irrigation and sedatives. Wet dressings and lotions externally.

Case 11. Mrs. S. S. Forty years old; first seen April 17th, 1915.

Past History. Nervous and overworked. Hyperidrosis of hands; constipated.

Present Illness. For two years, eruption on hands at onset of spring. Present attack of several weeks' duration.

Examination. Erythemato-vesicular, crusted and scaling eruption on and between fingers, and on palms. Examination of fæces showed a proteid putrefaction.

Course. Always better after resting, and invariably worse after using hands, particularly after garden work.

Treatment. Philippson's[69] method;* wet dressings, lotions, colon irrigations, low proteid diet and calcium lactate.

* Philippson recommends washing of hands in soap and hot water for a half hour, twice a day for a week to ten days. After washing and vigorous drying, a salve consisting of salicylic acid, resorcin and ichthyol in vaseline, is applied and the affected part bandaged with muslin. Then a period ensues of fifteen-minute washings, once daily for a week, and an application of zinc paste, in which birch tar oil may be incorporated. Philippson reports great success with this mode of treatment, a fact the writer has been able to confirm in many but not in all cases.

CASE 12. Mrs. P. H. Thirty- four years old; first seen August 20th, 1913.

PAST HISTORY. Nervous and constipated.

PRESENT ILLNESS. Began suddenly twelve days before, after a prolonged period of trying on new clothes. The onset occurred in the axillæ and the entire trunk soon became involved. The day after the first consultation the process extended to the elbow flexures, face and neck.

EXAMINATION. A papulo-vesicular eruption.

COURSE. Well in eight days.

TREATMENT. Wet dressings, lotions, sedatives, colon irrigations.

CASE 13. Mrs. L. S. Fifty years old; first seen February 5th, 1914.

PAST HISTORY. Nervous, constipated, indicanuria.

PRESENT ILLNESS. Six days' duration, sudden onset on face, neck, breasts, knee and elbow flexures, and lumbar region.

EXAMINATION. Erythemato-papulo-vesicular eruption.

COURSE. Well in seven days. Ten months later, short recurrence on face, arms and neck. Three weeks later, a second short recurrence.

TREATMENT. Colon irrigations, low proteid diet, sedatives, wet dressings and lotions.

CASE 14. Mr. G. D. Twenty years old, first seen August 31st, 1914.

PAST HISTORY. Tendency to eczema since childhood. Five years before, universal eczema. Moderate meat eater, but eats a great many peas and beans.

PRESENT ILLNESS. Three weeks' duration, with sudden onset on backs of hands, wrists and lips.

EXAMINATION. Erythemato-papulo-vesicular, weeping, crusted and scaling eruption. Rhagades of lips. Examination of fæces showed a proteid putrefaction.

COURSE. Well in six weeks. Two weeks later, a nine-day recurrence. Ten days later, a second, lasting six days and ten days after that, another, lasting seven days. During this period an attack of urticaria. Now well for eight months. (After Philippson's treatment and intestinal regulation.)

TREATMENT. Colon irrigations, calcium lactate, low proteid diet. Philippson's treatment, wet dressings and lotions.

An analysis of these cases shows the following facts. Nervousness was present in Cases 3, 5, 6, 7, 8, and 10 to 13, nine in all. Mental anxiety was found alone in Case 1, and in combination with nervousness, in Cases 5 and 10. Intestinal derangement, mostly in the form of constipation, was present in all but Cases 1, 6, 8 and 9, or in ten patients. Proteid putrefaction was ascertained in two, namely in Cases 11 and 14, while Cases 5 and 13 had indicanuria. A combination of nervous and digestive symptoms occurred in Cases 3, 5, 7, 10 to 13, or in seven instances. Urticaria was associated with the eczema in five patients, Cases 1, 3, 7, 10 and 14, and chronic bronchitis, suggesting the so-called exudative diathesis, in Case 2. These six cases possessed features pointing to anaphylaxis. In only one instance, Case 6, was there menstrual disturbance. An ascertainable local irritant caused the outbreak in the first eleven cases. In Case 12, possibly some chemical in the clothes the

patient tried on, may have been the starting point. In the two remaining patients no local causes could be found. The first three cases were apparently excited by some hair dye, the next four by a hair wash, the eighth case by resorcin, the ninth by a bust developer, the recurrence in the tenth by a chemical in a new waist, and the eleventh by vegetable poisons to which the patient was exposed in gardening. Local predisposing causes were found in one-half of the cases; seborrhœa in numbers 1, 3, 5, 7 and 8; intolerance of the skin to winter weather in Case 6, and dysidrosis in Case 11.

Twelve of the patients were women, and the sites involved were as follows: The scalp was affected in six cases, the neck in eight, the face and chest, each in seven, the elbow flexures in six, the knee flexures in two, the hands in two, the forearms in four, and the legs in two instances. A combination of lesions on the scalp, face, neck and elbow flexures was seen in Cases 1, 4, 6, 10, 12 and 13, or in six patients. A résumé of the series shows that vesicles were found in all of the cases, papules in eleven, erythema in nine, weeping and crusting in six, while in all the involution was accompanied by scaling, and in six scaling was a part of the earlier picture of the disease. Lichenification was present on the neck of the patient designated as Case 1, and on the arms of Cases 2 and 14.

As to the course of the disease, the average duration was sixteen days. In Cases 11 and 14 the duration could not be determined because of the number of recurrences. In Case 11 the patient was invariably well when she did not use her hands. In Case 14 the first attack lasted six weeks, the later attacks lasted nine, six and seven days, respectively. In the original attack only local treatment was employed, in the recurrences, internal treatment was added. This would indicate that internal treatment tends to shorten the course of the disease. The average duration of all cases treated locally alone, was just over twenty-two days; and of those receiving internal treatment also, just under nine days. The longest duration of a case treated by the combined method was exactly a fortnight, the shortest duration of a case treated only locally, was six days, while the longest was six weeks. Of six cases in which only local treatment was employed, four had recurrences, of eight in which combined treatment was used, five had recurrences. In two of these cases, 5 and 13, these recurrences took place after the dietetic regulations had been abandoned, added evidence, if anything, of the need for general therapy. Cases 1, 2, and 14, with their lichenified areas, showed evidence of chronicity.

The therapy was simple. Locally, during the acute stages, fomenta-

tions, and lotions such as the calamine and zinc, or zinc and magnesia, with or without ichthyol, were employed. During the period of desquamation, zinc ointment was used. The internal treatment consisted of colon irrigations, low proteid diet, and calcium lactate in massive doses when urticarial features were present. Sedatives, such as valedol and the bromides were employed when symptoms of nervousness were striking. Obviously, when an external agent seemed to have provoked the attack, the patient was cautioned to avoid a reëxposure.

It might be argued that most of these cases were examples of dermatitis of external origin. In the first seven patients, however, in which either hair dyes or hair lotions were the exciting causes, the reaction was not limited to the scalp, but included the face, neck, and in some instances the chest and elbow flexures. In Case 9 the irritant had been applied only to the bust, but the entire body surface was diseased. This is clear evidence that the local irritant was only an instrument for precipitating a disease for which the body must have been prepared. Patient 8, in whom the attack was started by resorcin, was ill for six weeks, or for long after the resorcin alone could have been responsible, and besides, several recurrences, not caused by resorcin, characterized the progress of the disease. In Case 10 the starting point was in the chemicals in a new waist, and the disease certainly did not end with the removal of the cause. The patient described in Case 1 had used a certain hair dye with impunity for nine years before it provoked an eczema. The offending hair dye may have been imperfectly made, but it seems more likely that the patient had changed in some manner, and had become sensitized to the dye. Another patient, whose record unfortunately has been mislaid, gave a similar history. She had, for years, used a scalp cream containing sulphur and resorcin in lanolin, which had been prescribed by a dermatologist. Finally, within twenty-four hours after application of the salve, she developed an eczema of the type reported in the present series, which promptly yielded to external and internal treatment.

The cases in which no external irritant could be determined behaved like the rest of the group, and it is contended that there was probably some local cause in each instance, the failure to find it depending upon ignorance of the vast number of such possible agents. In other words, it is again urged that there is no difference between eczema and dermatitis save that in the latter condition the local offender can easily be demonstrated, and in the former it cannot. Otherwise, clinically and pathogenically, the diseases are identical.

In the group of cases described, well-established general derange-

ments existed, capable of creating a predisposition to eczema. In some instances local predisposing causes were present. In nearly all of the cases the use of an irritant, serving to start the disease, was admitted by the patients. We thus have represented the various factors necessary to produce eczema, as described in the section on ætiology and pathogenesis. As a philosophical problem it is immaterial whether the internal causes are poisons, anaphylotoxines, modified internal secretions, or whether they are derived from the gastrointestinal tract, the urinary system, or anywhere else in the body, through any distubed biochemical process, nor does it make any difference what type of local trauma determines the onset of eczema. The important fact is that neither, without the other, will suffice. It is the practical problem of the student of eczema to try to determine the nature of its causes, for without doing so, he cannot treat the disease rationally.

It is submitted that the group of cases here described, and that a study of the literature support the statement just made. It is further submitted that these cases indicate that there is no difference between eczema and dermatitis, and that they illustrate nicely every point in the definition of eczema essayed earlier in this paper. The cases certainly were examples of an exudative inflammation. They were characterized by redness, swelling, the presence of papules, vesicles, weeping, crusting and scaling in various combination. They represented in their course acute and chronic types (Cases 1 and 14) and finally, their origin depended upon an interplay of various known and unknown, local and predisposing causes, to which the skin lesions were reactions.

Bibliography.

[1] Brocq. La question des eczémas. *Ann. d. dermat. et d. syph.*, Jan. to Mar., 1900.

[2] Besnier. Prat. Dermat., ii, p. 1.

[3] Willan and Bateman. A Practical Synopsis of Cutaneous Diseases. 1815, p. 252.

[4] Alibert. Monographie des dermatoses, 1835, ii, p. 24.

[5] Hardy. Leçons sur les maladies de la peau. 1860, p. 2.

[6] Biett, Cazenave and Schedel. Abrégé pratique des maladies de la peau. 1838, p. 90.

[7] Dévergie. Traité pratique des maladies de la peau. 1863, i, p. 115.

[8] Bazin. Leçons théoriques et cliniques sur les affections de la peau. 1862, p. 138.

[9] *Ibidem.* Examen critique de la divergence des opinions actuelles en pathologie cutanée. 1866 p. 68.

[10] Hebra. Text Book, 1872.

[11] Neumann. Text Book, 1880.

[12] Wilson. On Diseases of the Skin. 1867.

[13] Fox, Tilbury. Skin Diseases. 1873.

[14] *Ibidem.* Eczema: Its Nature and Treatment. 1870.
[15] UNNA. Mraçek's Handb., ii, p. 192.
[16] ORMSBY. Diseases of the Skin. 1915, p. 187.
[17] WALKER. An Introduction to Dermatology. 1911, p. 128.
[18] GALLOWAY AND EYRE. Fourth International Congress, Paris, 1900, p. 48.
[19] BOWEN. Modern Treatment and Theories of Eczema. *Boston Med. and Surg. Jour.*, Oct. 10, 1895.
[20] RACH. Beitrag zur Histologie des Scharlach Ausschlags. *Ziegler's Beitr.*, 1910, p. 457.
[21] LELOIR. *Archives de physiologie*, 1878 and 1880.
[22] UNNA. Histopathologie der Hautkrankheiten. 1894, p. 194.
[23] BROCQ. Dermatologie Pratique, 1907, i, p. 60.
[24] POLLITZER. A Recurrent Eczematoid Affection of the Hands. *Jour. Cutan. Dis.*, 1912, xxx, p. 10.
[25] ENGMAN. An Infectious Eczematoid Dermatitis. *Amer. Med.*, 1902, iv. p. 20.
[26] FORDYCE. An Infectious Eczematoid Dermatitis. *Jour. Cutan. Dis.*, 1911, xxix, p. 129.
[27] KAPOSI. Hautkrankheiten. 1899, p. 449.
[28] ANDERSON. Eczema, Chapter v. 1875.
[29] FORDYCE. The Modern Conception of Eczema. *Jour. A. M. A.*, June, 1903, p. 2.
[30] JACQUET AND JOURDANET. Études des dermites professionelles. *Ann. d. dermat. et d. syph.*, 1911, p. 11.
[31] CONKLIN. Eczema and Faulty Metabolism. Monograph.
[32] DUHRING. Cutaneous Medicine.
[33] NEISSER. Deutsche Dermat. Ges., Discussion. 1892.
[34] BROOKE. Relation of Seborrheal Processes to Some Other Affections of the Skin. *Brit. Jour. Dermat.*, June, 1899.
[35] WILLAN. On Cutaneous Diseases. 1808.
[36] RAYER. Traité thèorique et pratique des maladies de la peau. 1835.
[37] CAZENAVE. Des lesions de la sensibilité de la peau. *Ann d. mal. de la peau.* ii, 1846.
[38] HARDY. Piffard's Translation of the Dartrous Diathesis, 1868.
[39] NEISSER. Ueber den Gegenwärtigen Stand der Lichenfrage. International Congress, 1894.
[40] TÖRÖK. Sur la significance des lesions eczemateuses. *Ann. d. dermat. et d. syph.*, 1896, p. 1397.
[41] VIDAL. Du lichen. *Ann. d. dermat. et d. syph.*, Mar., 1886.
[42] BESNIER. Prurigos diathésiques. *Ann. d. dermat. et d. syph.*, 1892, pp. 634, 641, 644 and 1102.
[43] JOHNSTON. Eczema, a Sketch of its Process and Management, *N. Y. Med. Jour.*, Oct. 20, 1906.
[44] TOWLE AND TALBOT. *Am. Jour. Dis. of Chldr.*, 1912, and *Jour. Cutan. Dis.*, xxxi, p. 54.
[45] HALL. *Brit. Jour. Dermat.*, 1905, xvii, pp. 161, 203, 247, 287.
[46] MORRIS Diseases of the Skin. 1893.
[47] JOHNSTON. *Jour. Cutan. Dis.* 1913, xxxi, p. 3.
[48] CSILLAG. *Arch. f. Dermat. u. Syph.*, lxiii, p. 213.
[49] KESTEVEN. Ætiology and Treatment of Eczema. *Brit. Med. Jour.*, 1908, 27.
[50] BULKLEY. Neurotic Eczema. *Jour. A. M. A.*, Apr., 1898.
[51] SCHWARTZ AND HEIMANN. Blood Sugar in Various Dermatoses. Read before the Amer. Dermat. Ass'n, May, 1915.
[52] UNNA. Parasitic Origin of Eczema. Fourth International Congress; Paris, 1900, p. 9.

[53] Azua and Mendosa. Fourth International Congress, 1900, p. 71.
[45] Kaposi. Fourth International Congress, 1900, p. 18.
[55] Jadassohn. *Ibidem*, p. 22.
[56] Galloway and Eyre. *Ibidem*, p. 49.
[57] Brocq. *Ibidem*, p. 59.
[58] Pertini. *Ibidem*, p. 63.
[59] Neisser. *Ibidem*, p. 65.
[60] Whitfield. *Ibidem*, p. 77.
[61] Dockrell. *Ibidem*, p. 81.
[62] Bender and Gerhardt. *Monatsh. f. prakt. Dermat.* xxxiii, p. 149.
[63] Cole. Pyodermie. *Arch. f. Dermat. u. Syph.*, 1913, cxvi, p. 207.
[64] Bockhardt. *Monatsh. f. prakt. Dermat.*, 1901, p 421.
[65] Lewandowsky. Impetigo Contagiosa. *Arch. f. Dermat. u. Syph.*, 1913, xciv, p. 163.
[66] Kreibich. Die Angioneurotische Entzündung. Vienna. 1908.
[67] Wilson. Lectures on Eczema, 1870.
[68] Kromayer. Was ist Eczem? 1892.
[69] Philippson. *Dermat. Wchnschr.*, 1914, p. 38.

DEEP TRANSVERSE FURROWING OF THE FINGER NAILS FOLLOWING LOCAL ASPHYXIA.

By Douglass W. Montgomery, M.D., San Francisco.

The Word Asphyxia.

Asphyxia is not an old word, yet it has had quite a number of adventures. At first, and in accordance with its derivation, it meant pulseless; later, and even in the present day dictionaries, it signified deprivation of oxygen. Now asphyxia must be taken to mean an overload of carbon dioxide, just as acapnia means a penury of this gas. A writer, in 1881, complained of the curious infelicity of etymology exhibited by this word,[1] although it had not then by any means sounded the depths it has attained to since, when a negative word, having regard to the pulse, takes on a positive meaning, implying an excess of a waste gas.

Local Asphyxia.

By local asphyxia is meant a more or less deep blue or violet discoloration of some part, usually of an extremity, as of the hands, feet, nose, chin or penis. This discoloration is due to an excess of CO_2 in the blood and tissue juices; it is exclusively characteristic of this excess, and is one of the very few pathognomonic symptoms in medicine.

When local asphyxia is marked, it is associated with swelling and severe pain. Local syncope or pallor, followed or preceded by local asphyxia and accompanied by pain, swelling and even death of the part, include the major constituents in the symptom complex called Raynaud's disease.

With this as a preliminary, it may be stated that it was a severe local asphyxic attack of the hands that gave rise to the peculiar deformity of the nails that is the subject of the present paper. The occurrence of transverse ridges following severe local or general disturbances of nutrition, such as eczema or a severe general illness of any kind, or as above indicated, a local asphyxic attack, are among the most common phenomena of disease, and this case is reported not because of the rareness of the symptom, but because of the unusual depth of the furrows, and the definiteness of the ætiologic cause.

As Heller says, the pathologic feature of this symptom is its isolation, as the condition, a pneumonia for instance, that gave rise to it has long since passed by when the deformity comes into view.[2]

The man who subsequently had the severe local asphyxic attack that gave rise to the deep furrowing, first consulted me March 7th, 1914, on account of a severe streptococcic infection with crusting and serous oozing, principally of the legs, and an extensive, acute papular eczema involving a large part of the cutaneous surface. It may also be mentioned as pertaining to his vascular system, and, therefore, to the subject under consideration, that he had marked varicose veins of the legs and large veins coursing over the abdomen. Under appropriate treatment he improved steadily, but there remained a very labile vasomotor system, expressed principally by venous stasis of the hands, legs and feet, with chilblains of the hands and feet. There was also abnormal sensitiveness of the skin both to cold and to the mechanical irritation of rubbing, and there were frequent outbursts of herpes simplex and of fine papular eczema.

In the cool weather of January, 1915, the hands became profoundly affected. Of course the thermometer never sinks very low in San Francisco, but the sea air grows disproportionately chilly. The patient's hands became painfully cold and the hands and fingers assumed a deep red, with a purplish tint; the fingers grew large, clumsy and stiff looking. By spells the finger pulps would become deep blue, often almost black, and so tender that he could not button his clothes. All the digits, including the thumbs, were equally affected. This was noteworthy, as in Raynaud's disease the thumbs almost always escape. The feet had a violet tint that would disappear under light massage. They showed, however, in every way that they were much less affected by the vasomotor disturbance than the hands.

These very severe symptoms occurred in January, a point to be noted in regard to the subsequent appearance of the grooves on the free surface of the nails.

I again saw the patient April 21st, 1915, exactly three months after his January visit, and he was in very good condition indeed. His hands, however, were still blue and his thumbs were cold, but not so cold as they had been. In the patient's naturally good, strong, well-polished nails there was one deep groove, extending completely across each one, just beyond the lunula. The furrows in some instances were as much as 2 mm. deep and had rounded, smooth edges and a concave, smooth, rounded floor. In two instances the floor of the furrow was discolored

a light brown. Distal to the grooves the nails were transversely marked with strips of leuconychia.

By July 27th, 1914, six months after the severe, local asphyxic attacks of January, the grooves had attained in their movement forward, the free borders of the nails, and the patient was paring away the irregular edges.

Nail Growth.

The nail grows from a slot, which is formed by a fold of the integument. In order to comprehend the relationship of the nail to the general integument, it is necessary to regard the skin as one great gland, faced by a horny covering, secreted or elaborated by itself from its own epithelial cells. Out of invaginations in this vast surface there grow modifications of this horny covering; out of invaginations that are holes, hairs grow, out of invaginations that are slots, nails spring. At the bottom of the nail slot there is no papilla as there is at the bottom of the hair hole or follicle, nor is there one needed. The hair has to grow out a long distance as a free floating cylinder, and, therefore, must have a rich supply of nutriment at its base, to be transmitted up its medulla or richly cellular centre. The nail, on the contrary, is a short, flat plate with very little free projecting edge. It is produced back in the previously mentioned slot, and is slid forward on longitudinal grooves in the nail bed, to which it is tightly adherent, and from which it receives nourishment and undoubtedly also some addition to its under surface. Very little nail substance, however, is produced distal to the lunular surface. Any injury received by the nail while it is in the formative stage, deep in the slot, may deform it, and this deformity is gradually slid forward with the natural growth of the nail, and does not become visible until the nail plate is free from the posterior nail fold. In the present instance, the injury was received in January.

By April, the transverse furrows, the result of the injury, were well out on the free surface, and by the end of July they had attained the free edge of the nail. In other words, it took six months for the nail to grow out, which coincides with Heller's estimate of the rate of growth of the nail, about 0.1 mm. a day.[3]

In addition to the interest attaching to such deformities as indicating the time when the malady that produced them occurred, they also may give some idea of the severity of this malady, and in both these respects they may be of medico-legal importance.

In the case under consideration, it gives some idea of the tenesmic convulsion of the tissues caused by their effort to expel the carbon

dioxide gas, and probably also the accompanying lactic and other acids that should be carried away by the blood as formed. The process may be a tenesmus of the muscular walls of the blood vessels, comparable to the tenesmus in the muscular walls of the intestine or bladder when these viscera become over full of expellable contents.

Not long ago, these spasmodic symptoms would have been referred to the nervous system—to the action of the vasomotor nerves. Since the work of Yandell Henderson and others, this view has been changed and now we think of the specific action of CO_2 gas on the tissues. It appears that carbon dioxide is the normal stimulant that supports the circulation, respiration, intestinal tonus and peristalsis,[4] and it is only a step between normal tonus and spasmodic contraction.



Fig. 3.

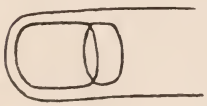

Fig. 2.

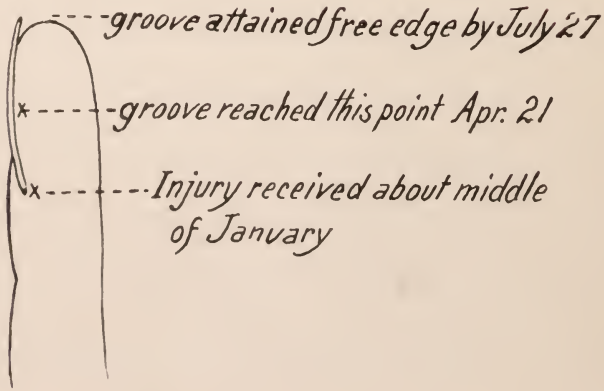

Fig. 1.

FIG. 4.

[1] Syd. Soc. Lex., 1881, Oxford Dict.
[2] HELLER, JULIUS. Nagelkrankheiten in Hautkrankheiten, edited by Prof. Dr. F. Mraçek, 1909, iv, p. 346.
[3] Loc. cit., iv, p. 547.
[4] BRYANT, JNO., AND HENDERSON, YANDELL. Closed Ether and a Color Sign. *Jour. A. M. A.*, July 3, 1915, p. 1.

ACTINOMYCOSIS; CUTANEOUS AND SYSTEMIC.

REPORT OF A CASE.

By E. D. Newman, M.D., Newark.

Dermatologist to the St. James and German Hospitals; Consulting Dermatologist to the Essex County Hospital, Overbrook, N. J., and the Hebrew Orphan Asylum, Newark, N. J.

James Homer Wright gives a most complete and comprehensive description of actinomycosis as it affects the skin and the internal organs. I can add nothing to his description of the disease and will simply report, clinically, a case possessing a number of interesting features.

Case Report.

The patient, P. M., (referred to me by Dr. C. E. A. Ball of South Orange, N. J.) was a man, aged 28 years, born in the United States, a farm laborer by occupation; his work did not include the care of cows, since 1912; he had not taken care of horses since October, 1914. He never had the habit of chewing hay or straw; he uses alcohol, more than moderately. The family and personal history is negative.

About four months ago he noticed a small swelling on the right side of his lower jaw; he consulted a physician and was informed that the swelling might be due to a diseased tooth. Three weeks after the first appearance of the swelling, a tooth was extracted; one week later, he was informed that it was necessary to extract other teeth; following this advice, five more were extracted.

The swelling was very hard to the touch, increased slowly in size for a period of six weeks, when the skin seemed to become thin at the centre of the lesion, ruptured and discharged pus; a few days later more openings were noticed and for the last two months its appearance was about the same as at the time of the first examination. August 20th, 1915.

The patient presented a lesion (see Fig. 1) on the right side of the lower jaw, about four and one-half inches in circumference, composed of a number of separate nodules, united into a dark reddish, nodular and firm mass. The nodules varied from a pea to a walnut in size and were parallel to the line of the lower jaw, resulting in the formation of fissures of varying length and depth. The surface at the middle left side was covered with a thin purulent discharge, containing a few yellowish-gray granules. The whole lesion was studded with a number of pustular openings; the orifices of these openings led into sinuses which honeycombed the mass under the surface, as was evidenced by the injection of peroxide of hydrogen into one of the cavities, resulting in the frothy bubbling through the many orifices over the entire lesion. He had no

* Read before the Clinical Society of the Department of Dermatology, Vanderbilt Clinic, Dec. 16, 1915.

pain in the lesion except on deep pressure. No enlargement of the adjacent glands was noted.

The teeth of the upper and lower jaw on the right side were missing, from the canines posteriorly. A swelling was noticed in the duct leading from the parotid gland. His previous dental condition must have been very poor, judging from the appearance of the remaining teeth.

The patient looked sick, cachetic and anæmic; he complained of a cough with a little or no expectoration and was slightly hoarse; he had had no hæmoptysis nor night sweats. He had lost 20 pounds in weight during the past four months.

Examination revealed the presence of a few râles at the apices of both lungs, more marked over the right side; there was a pleuritic rub over the base of the right lung. No palpable enlargement of the liver or spleen was discernible. The Wassermann reaction was negative.

Subsequent History. September 10th. The patient called my attention to two new growths; one above the right nipple, rounded and elevated, about two inches in circumference, not reddened, of stony hardness, and adherent to the chest wall; three inches below, in a straight line, the second, slightly smaller and of the same general appearance. On palpation, there seemed to be one spot in each of these new growths that was softer than the general mass.

October 2nd. Patient is now confined to his home. The lower chest tumor had broken down; it had become a reddened, somewhat flattened and irregular mass with a small opening, discharging rather thin pus; the upper tumor had increased in size to about four and one-half inches in circumference, was of stony hardness excepting the most dependent portion, which had become reddened; palpation revealed the presence of pus.

October 9th. The lower growth now has the appearance of the original lesion on the jaw; it is dark red in color, nodular and studded with a number of pustular openings; the upper growth had ruptured at its dependent portion and is discharging pus through one opening.

Physical examination. Dullness over both lungs, more marked on right side; a large number of râles over apices and central portion of both lungs; increase of pleuritic signs over bases of both lungs. A marked œdema extending from both knees to toes.

October 11th. Subsequent history (for which I am indebted to Dr. C. E. A. Ball). The upper lesion on the chest wall is very painful and is discharging pus through an opening at its dependent portion; when the pus is wiped off necrotic tissue is seen in the "crater"; at the upper portion of this lesion is a very small opening discharging a thin purulent exudate; the skin surrounding this opening is tense. This opening was enlarged by incision and discharged a large amount of foul, thick and yellow pus. The pain, after this incision, was abated. Bichloride dressing was applied.

October 18th. The lesion on the face is smaller and around the edges the color is not as dark a red as heretofore; there is an entire disappearance of the nodular condition which now is quite flat. The lower chest lesion has the appearance of the lesion on the face. The upper chest lesion is smaller, causes very little or no pain, is discharging large amount of pus from the two former openings and another which has formed, seemingly by sloughing.

The back of the left hand is œdematous, and on the ring finger is a small nodule.

October 23rd. The lesion on the face is somewhat smaller, and at its edges there are thick dark scales. There is no discharge of pus from the lower chest lesion.

The upper chest lesion now has a number of new openings from which pus

is being discharged; the mass has a doughy and œdematous feel. It is not painful.

The nodule on the ring finger has broken down and is discharging pus; the œdema of the back of this hand has disappeared.

On the ulnar side of the flexor surface of the right forearm, just below the elbow, is a swelling with reddening of the skin. Iodine petrogen was applied.

October 30th. The patient looks decidedly cachectic. The lesion on the forearm was incised and a large amount of thick creamy and decidedly foul smelling pus was discharged. The upper chest lesion is still discharging through several openings. The lower chest lesion and the face lesions are in about the same condition as at previous examinations. The lesion on the ring finger of the left hand is still discharging but the appearance thereof has improved.

On the scalp, over the frontal bones and a little to the right of the median line, are three small cyst-like lesions which are exuding pus. The physical signs of the chest examination are now negative.

On November 2nd, the patient drank to excess; on the 4th, another lesion appeared near the vertebral column on the right side, at about the 9th rib; the next day, the 5th, the abdomen seemed swollen, which swelling disappeared after some hours; 2 A.M., the next day, (6th) his family reported that he acted as if suffocating and yelled with pain and felt as if something had broken inside. He died at 3 A.M. Autopsy was refused.

The patient was very recalcitrant and gave little opportunity for examination of the secretions, sputum, blood, etc., and only one specimen of the blood, urine and sputum was obtained. Smears and cultures from the various lesions were made.

October 9th. Blood examination. Red blood cells, 4,200,000, white blood cells, 16,000, polynuclears 40%, large lymphocytes 36%, small lymphocytes 12%, large mononuclears 12%. No change in red blood cells; hæmoglobin 100%.

Urinalysis. Acid, specific gravity, 1004; albumin, a trace, a few leucocytes, and an occasional hyaline cast were observed.

Sputum. The examination of the only specimen obtained was negative as to the ray fungus and tubercle bacillus.

A smear from the original lesion on the jaw showed no fungus but a fair number of clubs and elements; the latter irregularly rounded masses of varying yellowish hue, composed of a number of round, vacuolated bodies in close apposition; at the periphery some of these bodies are shaped somewhat like columnar cells.

In the pus from the lower chest lesion was found the fungus as photographed (see Figs. 2 and 3).

The ray fungi were found in large numbers in the pus obtained from the abscess on the right arm.

Histopathology.

A piece of tissue, 1 cm. in diameter, was excised with a cutaneous punch from the lesion on the right side of the face at the angle of the

jaw, fixed in alcohol, embedded in paraffine and stained in the usual fashion.

Low power, general view. We find two-fifths of either end of the epidermis intact, the central fifth wanting, as is also the subepidermal tissue; this central portion is occupied by a deep cavity (the epidermal opening of a sinus) the walls of which are ragged; the centre of this cavity is partly filled with remains of broken-down tissue, fibrin and cells; near this cavity are spaces communicating therewith and filled with the same material as the cavity itself. The subpapillary tissue is wide-meshed and of spongy appearance and takes a lighter stain; in the deeper tissues, in places surrounding some of the large number of thin and thick walled blood vessels, are found collections of cells. Throughout the entire corium, blood vessels, lymphatics and lymph-spaces appear to be dilated; some are empty; some partly filled with fibrin and cells. The deeper part of tissue is infiltrated with a moderately dense collections of cells; the blood vessels are dilated, the walls of some of them are thickened.

Higher power. The epidermis shows evidence of moderate œdema; the basal cell layer is in most parts intact; the papillæ are markedly œdematous; the connective tissue is degenerated and more or less homogeneous; the blood vessels are dilated and surrounded by plasma cells; the entire tissue is coarse-meshed, the spaces being filled with fibrin and broken-down red blood cells; there are a number of thin, dilated new blood vessels, plasma cells in various stages of degeneration, not only surrounding the blood vessels but scattered throughout, and a moderate number of leucocytes. The walls of the before mentioned cavity are made up of connective tissue in various stages of development.

In the deeper part of the tissue there are a large number of blood vessels surrounded by plasma cells, the endothelium of the vessels showing moderate swelling; some of the plasma cells show various stages of hyaline degeneration, others show complete degeneration; others show only nuclei, with cell body indistinct. The connective tissue is fragmented, in places broken down into granules and does not take the normal stain; as a result of the breaking down of the connective tissue, there are a number of communicating lymph spaces of varying sizes, moderately filled with granular debris.

The elastic tissue is practically wanting throughout the entire specimen. In no part of the specimen are found the fungi or abscess cavities.

The tissue shows very little evidence of an inflammatory process, but an intense degeneration of the connective tissue, with the presence of many newly formed, thin-walled blood vessels.

Cultures.

Cultures from the original growth were unfortunately contaminated. Cultures from the growths on the chest could be attempted only at the home of the patient, therefore, it was almost impossible to make them absolutely anærobic; they showed no growth. A specimen of pus from the abscess on the right arm was given to Prof. Hans Zinsser, who succeeded in obtaining therefrom a pure culture of the actinomyces.

Much confusion exists as to the biology; cultural experiments by different workers were varying and contradictory, the lesions containing, beside the specific microörganism, various bacteria. The results of the attempts to reproduce the disease by inoculation of animals with the material from actinomycotic lesions, have either been negative or so ambiguous that at the present time no positive conclusion can be arrived at.

General Considerations.

Extension of the actinomycotic affection may take place by continuity or metastasis; in the latter case, by rupture of a focal lesion into a blood vessel, thus discharging the parasite into the general circulation, with a possibility of a true embolic pyæmia and resultant secondary abscesses, containing or not containing the ray fungus. The abscesses on the finger, forearm, scalp and back were probably the result of this mode of extension.

The lesions on the chest wall were probably due to extension by continuity through the wall of the thorax, of the actinomycotic process.

Wright[1] states that the presence of an inflammatory swelling of a board-like induration in the wall of the thorax or epigastrium, with suppurative foci or sinuses in it, is very characteristic.

The failure in finding the fungus in the tissue was probably due to the fact that not a sufficient number of slides were examined. Buerger[6] reports a case where he examined twelve blocks, all of which had been divided and in only three specimens was the fungus found. It may be that the vegetations which exist in little cavities or sinuses in the tissue readily escape and are lost, or they elude observation because of the small size of the granules, as compared to the mass of the lesion; or, again, the process being relatively progressive and there being little evidence of resistance on the part of the tissue to the infection, the rays might have been absent. The tissue removed for examination was taken from the necrotic border; the fungi had in all probability already caused destruction and were lost in the early discharge.

Plate XXVII.—To Illustrate Article on Cutaneous and Systemic Actinomycosis, by E. D. Newman, M.D.

Fig. 2.
Microphotograph of the ray fungus.
Zeiss obj. 3 mm., co. oc. 4.

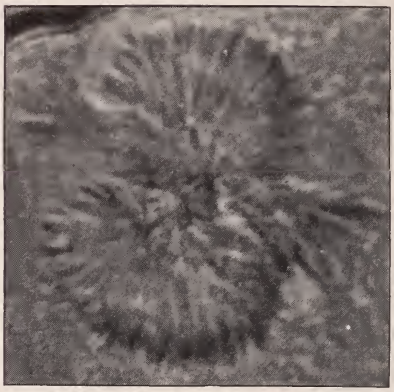

Fig. 3.
Microphotograph of the ray fungus.
Zeiss obj. 3 mm., co. oc. 4.

Fig. 1.
Showing the vegetating lesion over the mandible.

A large number of slides, with pus stained and unstained, were examined by myself and others; only once, at the first examination of the original lesion, were granules found; this specimen showed the presence of the clubs and other actinomycotic elements. The ray fungus was found in the unstained specimens; the pus from these was obtained from the lower chest lesion and from the abscess on the right forearm. A drop of pus (without spreading) was placed upon a slide, a cover glass placed thereon and the specimen examined; the fungi were found in various sizes and colors, a few very small and others larger, made up of aggregations of the smaller ones; the colors varied from the faintest to a dark yellow.

My failure in finding the fungus in the upper chest lesion, I believe was due to the making of smears, instead of using the drop method; although Godlee[3] calls attention to the possibility that for long periods and even after death, no signs of the ray fungus may be present in the discharges. Stelwagon[4] reports a case where reported examinations of the discharge failed to disclose the fungus.

Frequently, degeneration of the fungus in any or all of its parts occurs; then only at the periphery are observed radiating, club-shaped bodies, without a trace of the filaments from which they were formed.

With but one exception, the illustrations of the ray fungus as found in pus, shown in the text books and special articles on actinomycosis, are reproductions of drawings. Mallory and Wright[5] show a photo-reproduction of the ray fungi as obtained from a crushed granule; this illustration depicts a number of the fungi in close apposition. The illustrations accompanying this article show the fungi as found in the free pus with the ray arrangement of the actinomyces, showing a central network of interwoven filaments from which radiate the filaments and club-shaped bodies; the latter develop from the filaments and are usually thickest at or near the distal end. At times there are projecting clubs or filaments, as is shown in Figs. 2 and 3.

I desire to acknowledge my sincere thanks to Dr. George M. MacKee for the excellent photographs, to Dr. D. L. Satenstein for the examination of the tissue, and to Dr. C. E. A. Ball for the history of the case subsequent to the patient's confinement to his home.

REFERENCES.

[1] WRIGHT. Modern Medicine, by Osler. 1907, i, p. 327.
[2] FOSTER. Dictionary. 1890, i, 91. (Illustrations after Marchand.)
[3] GODLEE. Abstract, *Jour. A. M. A.*, Jan. 26, 1901 (from *Lancet*, Jan. 5, 1901.)
[4] STELWAGEN. Diseases of the Skin. 7th Edition, Phil., 1914, p. 1158, footnote.
[5] MALLORY AND WRIGHT. Pathological Technique. Phil., 1915, p. 229.
[6] BUERGER. *Jour. Amer. Med. Sci.*, Nov., 1907, p. 707.

THE COOLIDGE TUBE AND THE CORBETT RADIOMETER.* †

By George M. MacKee, M.D.,
and
John Remer, M.D., New York.

(From the Department of Dermatology, College of Physicians and Surgeons, Columbia University.)

The Coolidge Tube.

In the past few years a great deal of experimental work has been conducted in an endeaver to overcome one of the most serious obstacles to development and efficiency in radiology—namely, inadequate tubes. Exciting apparatuses, measuring instruments, etc., together with technique have been developed to a high degree of efficiency, but the manufacturers and scientists appeared to be unable to produce a tube that would give a high degree of satisfaction, especially for therapeutic work. What was wanted was a tube that was capable of emitting homogeneous rays, one that could be regulated at will to give off rays varying in penetration from the lowest of the Benoist scale to rays approximating the penetrating power of the gamma rays of radium. Another requirement was that the tube would stand heavy currents for long periods of time, without alteration in vacuum.

Before the advent of the Coolidge tube most of the experimental work was in association with gas tubes—tubes that were regulated by allowing gas to lower the vacuum. By the use of hydrogen for the regulator, tungsten for the target and circulating air or water for removing the heat, gas tubes having a wide latitude of usefulness were constructed, but it remained for Coolidge to devise a tube that came nearer to the ideal than any tube previously constructed.

At first glance the Coolidge tube does not differ from any other tube. It consists of the usual glass bulb containing the two terminals—anode and cathode. The anode is composed of tungsten. The cathode, instead

* Read before the 39th Annual Meeting of the American Dermatological Association, New York City, May 13-15, 1915.

† The Corbett radiometer and the Coolidge tube in action were exhibited to the members of the Association.

of being a concave aluminum disk, consists of a filament of wire. The bulb contains no gas—in other words it is as near a perfect vacuum as it is possible to attain with modern methods of exhaustion. The tube is connected to the exciting apparatus in the ordinary manner, excepting that two wires instead of one are attached to the cathode—the filament. These wires, in addition to conducting the high potential current, also carry a current of low potential obtained either from a storage battery or a down-step transformer. The low potential current is controlled by a rheostat. Now the vacuum of the tube or at least the degree of penetration of the ray depends upon the amount of low potential current passing through and heating the filament.

Fig. 1.
Coolidge tube.

To operate the tube the low potential current is first allowed to pass into the filament. The latter becomes red hot or white hot according to the amount of current employed. Then the high potential current is passed through the tube and X-rays are obtained. The tube does not become luminous as does the ordinary tube, so that it is only by observing the milliamperemeter that one ascertains whether or not the tube is in operation. If a heavy current is employed the anode, after a few seconds, becomes cherry red, then bright red, and finally white hot. The tube may be operated with the anode at white heat for hours without danger of being damaged. Barring accident the life of the tube is several years under a heavy strain—in fact it may be almost permanent.

The tube is of the electron instead of the gas variety. The negatively charged electrons pass from the cathode to the anode with a velocity that depends upon the heat in the filament and this velocity governs the penetrability of the ray emitted. The Coolidge tubes that I possess,

excited by my apparatus, have a range of from four to eleven or twelve of the Benoist scale, but I understand that other workers have obtained a much higher penetration. Professor Coolidge is now experimenting with a tube that under proper conditions will emit rays approximating in penetration the gamma rays of radium and connected with a water or air cooling device, the tube can be operated with 20 to 30 milliameters of current for ten to twelve hours at a time.

While the Coolidge tube is not yet perfected it is the greatest advance in radiotherapeutic technique that we have had in years. In simplicity of operation, reliability and exactness it constitutes almost a fool-proof tube.

Its ability to emit unlimited quantities of rays of very high penetration allows of deep applications through thick filters. The tube's greatest value to the dermatologist, however, is the fact that it may be regulated to any degree of penetration and this penetration can, with absolute certainty, be maintained throughout a treatment of any duration. In recent years radiotherapeutists have had no serious trouble in estimating the quantity or quality of ray employed, but it has been impossible to obtain a tube that could be quickly and exactly regulated and particularly has it been impossible, or at least very difficult, to maintain the quality for sufficiently long periods. All these requirements are met by the Coolidge tube. With this tube, so far as quality is concerned, it is possible to place a great deal of faith in indirect measurement. It is a very simple matter to regulate the tube for, let us say, a Benoist 9 ray. The reading of the galvanometer (record of low potential current) of the milliamperemeter (record of high potential current) and the length of the spark gap are carefully noted. These readings may be duplicated at any time and they will always produce the same result. Fluctuations in the source of current will, of course, produce a variation in the quality, but I have never found this to be of any practical importance. The tube is so dependable that many radiotherapeutists administer intensive doses without the aid of a radiometer, but I advise against this, at least in superficial work—not on account of any fault of the tube, but because it is inadvisable to trust the exciting apparatuses, instruments for controlling the current and above all, human infallibility. In other words, the radiometer should be employed as a control in estimating the quantity of every dose administered. A little variation in quality is of no great practical value, but a very little variation in quantity, in connection with the intensive dose, may produce disastrous consequences.

Among dermatologists there appears to be an idea that the Coolidge

tube, on account of its ability to produce very large quantities of rays of high penetration, is exceedingly dangerous to both the patient and the operator. This is an absolute reversal of the truth. In the first place the ordinary Coolidge tube excited by the usual apparatus does not produce rays of higher penetration than can be obtained from many ordinary gas tubes. Even assuming that it is possible to obtain gamma quality it must be remembered that the tube can be regulated for any degree of penetration. The patient's safety depends very largely upon the ability of the operator to measure both the quantity and quality of the ray, and his ability in this respect will be materially increased by the use of the Coolidge tube.

The question of suitable protection is naturally a very important one for both the operator and the patient. The Coolidge tube, like other tubes, does not emit homogeneous rays. That is to say, if it is regulated for Benoist 9 it emits a maximum of No. 9 rays, but rays of much lower and, also, much higher penetrability are emitted. If only a small amount of superficial work is to be done it will suffice to place the tube in a tube stand provided with a heavy lead glass bowl, having a metallic diaphragm. This will provide ample general protection for the patient, but in addition the operator should stand behind a heavily leaded screen during the operation of the tube.

Where a great deal of work is to be attempted and especially in cross-fire, deep-seated therapy, it is advisable to place the tube in a specially constructed tube stand having a heavy lead shield which completely surrounds the tube and which is provided with an air-cooling device. In addition to this, many operators utilize the heavily leaded screen and some of them completely surround themselves with lead (lead-lined booth). For treatment such as the dermatologist gives, however, no more protection is necessary than when employing the ordinary type of tube.

The Corbett Radiometer.

At the present writing there is no absolutely accurate nor perfectly satisfactory method of measuring the quantity of X-ray. Of the many radiometers on the market the Holzknecht radiometer has been the most popular. In some respects the Corbett radiometer is more accurate—certainly it is more scientific, although it, too, has disadvantages. There always has been and there still is a tendency to belittle direct measurement of quantity and to depend largely if not entirely upon indirect estimation. With the Coolidge tube and modern exciting apparatus indirect measurement in experienced hands is surprisingly accurate, but

we still maintain that in addition to the most careful indirect technique the treatments should be controlled by the use of a pastille and radiometer. In accuracy, the estimation of quantity cannot be likened to the measurement of a dose of strychnine by means of a delicate and accurate pair of scales. Fortunately, however, there is considerable latitude in using the X-ray. For instance, 4 Holzknecht units of a Benoist 9 or 10 ray will usually suffice for the production of a defluvium when applied to the scalp without the production of an erythema or a permanent alopecia. As a matter of fact it is perfectly safe to administer H 5 of



Fig. 2.
Corbett radiometer.

the same quality. Anything in excess of this is dangerous. Therefore, it is seen that one has a working latitude of 1 H unit, a margin of safety that should be sufficient to overcome errors of measurements. For practical purposes, therefore, our present methods of measurement, although not scientifically accurate, nevertheless allow of sufficient accuracy for practical purposes.

The Corbett radiometer is based upon the very ingenious use of Lovibond's tintometer. Corbett found that the standard B tint of the Sabouraud-Noiré radiometer varied somewhat in different instruments. This led him to test various B standards with the tintometer in order to estimate the colors and percentages thereof in the composition. By determining this fact he was able to combine the proper percentages of colors to make a standard B tint. The same method was then employed to test different lots of pastilles. He then studied, with the tintometer, the changes in colors and percentages thereof, in pastilles subjected to various doses of the X-ray. In this way he was able to produce color formulæ for the various standard doses which are represented by small pieces of glass containing the required percentages of the proper colors. He made in all eight glass tablets from zero through the various doses to the Sabouraud B standard, or epilating dose. Two sets of tablets are supplied with the instrument—one for use with artificial light and one for daylight. The colors in the tablets are scientifically accurate and they are permanent—two marked advantages over the Holzknecht instrument. The weak point in the radiometer consists in the method of comparison of the tablets with the pastilles. The instrument consists of a box, six inches long and one inch square, and painted black inside. At one end is a single opening for the eye. At the other extremity there are two openings, each of which is the size and shape of a pastille. The glass tablet is placed in contact with one aperture and under this is placed a piece of pure white paper, on a receptacle two inches below the opening. On this same receptacle, under the other opening, is placed the pastille. The light from an 8 candle-power shaded incandescent electric light is then allowed to strike the pastille and, also, the paper under the glass tablet. The reflected light from the pastille passes through one aperture and the reflected light from the paper passes through the glass tablet and thence through the other aperture, to the eye. The objection to this method of comparison is that there is a certain amount of halation which interferes with accurate reading. Personally we have not been able to compare the colors as quickly or as accurately with the Corbett as with the Holzknecht radiometer although it is possible that with more practice this fault will be overcome.

The advantages of the Corbett over the Holzknecht radiometer are in the scientific accuracy, the standardization and the permanency of the colors.

The advantages of the Holzknecht radiometer are the more accurate (to us at least) method of comparison, and the fact that every pastille is its own standard. In other words, a fresh pastille is cut in half—one-half is utilized as the control while the other half is exposed to the X-ray. It is not always possible to obtain pastilles that exactly match a standard tint, a fact that makes the Corbett radiometer a little more difficult to use. It may be argued that pastilles failing to match the standard should be discarded and so they should if there is anything but a very slight difference.

Since the advent of the war it has been impossible to obtain the Holzknecht instrument so that the Corbett radiometer will undoubtfully be very extensively employed. It deserves success and Corbett should receive a great deal of credit for devising such a scientific, accurate and useful instrument.

References.

Coolidge Tube.

Cole, L. G. A Preliminary Report on the Diagnostic and Therapeutic Application of the Coolidge Tube. *Am. Jour. Roentgenol.*, January, 1914.

Coolidge, W. D. A Powerful Roentgen Ray Tube with a Pure Electron Discharge. *Am. Jour. Roentgenol.*, January, 1914.

Shearer, J. S. Measurements with the Coolidge Tube. *Am. Jour. Roentgenol.*, November, 1914.

Corbett Radiometer.

Corbett. *Brit. Jour. Dermat.*, August, 1913; *Proc. Roy. Soc. Med., Dermat. Sect.*, December, 1913; *Lancet*, Feb. 20, 1914.

Plate XXVIII.—To Illustrate Article on Formalin Urticaria, by M. L. Heidingsfeld, M.D.

Formalin urticaria.

CLINICAL REPORT.

FORMALIN URTICARIA.

By M. L. Heidingsfeld, Ph.B., M.D., Cincinnati.

Professor of Dermatology, University of Cincinnati; Dermatologist, Cincinnati General Hospital.

A commonplace and easily recognized form of dermatosis, such as urticaria, should merit at most, passing notice, irrespective of the severity of the attack or other features of ordinary clinical interest. The following case presents features of sufficient unusual character to render them worthy of record and report.

Case Report.

Mr. F. L., aged 38 years, manager of a large corporate interest, presented himself October 30th, 1914, with a well-defined and extensive urticarial eruption, covering almost the entire body. The characteristic pinkish-white wheals, which varied from a split-pea to a thumb nail in size, were abundantly distributed over the neck, trunk and extremities (Fig. 1); scarcely a square inch of skin over these areas was uninvolved. Urticarial lesions were also scattered over the palms of the hands and soles of the feet and over the face and scalp. The lips were thickened, tongue, mouth and throat uncomfortable. Itching over the body was intolerable, breathing difficult, speech irksome and indistinct, pulse rapid (120 per minute) and weak; sense of general prostration was very marked. The patient was unable to walk without aid and required assistance to sit in an arm chair long enough to permit the photograph of a single arm. Immediate bed-rest was imperative, and under the influence of rest, quiet, anti-pruritic and anti-phlogistic lotions and applications, and the internal administration of alkaline salts, the patient gradually regained his customary comfort and well-being.

On the morning of October 30th, in question, the patient arose in a state of customary good health and well-being. He partook his usual simple breakfast, could recall no dietary indiscretion and stated that he had eaten only plain, simple food for a previous period of 24 or possibly 48 hours. After breakfast and a brief stay at his office, he visited his dentist, with whom he had an early morning appointment. The attention at the hands of his dentist was brief in duration and consisted of the preparation of a small cavity for subsequent filling. The patient had scarcely returned to his office when he began to note the uncomfortable eruption and experience a sense of general weakness and malaise. Upon query, the dentist informed the patient that he had placed a tiny pledget of cotton, saturated with formalin, within the tooth cavity, for disinfectant purposes. The patient, who then presented himself to the writer, as above

described, stated that he attributed the attack to the application of formalin, a drug which had proven to be an intense irritant to him in the past, irrespective in what form he came in contact with the preparation.

Formalin is an agent of sufficient wide-spread and common use to elicit special attention to any of its toxic properties. If a minute quantity, placed in an inaccessible cavity, such as a tooth, can call forth symptoms so grave and pronounced, it becomes a matter of special if not general importance. Formalin enjoys very extensive use in medicine, science and the arts. It is a very popular antiseptic and preservative. It is extensively used by physicians, surgeons and dentists, as a disinfectant. It is widely exploited in proprietary form in the nature of a successful throat lozenge. It has become almost indispensable to the anatomist, botanist and undertaker, as a successful preservative. It is extensively used in the trades and arts, particularly in the manufacture of leather, aniline dyes, rubber goods, glass and photographic supplies.

The writer has occasionally encountered well-defined cases of artificial dermatitis, particularly in undertakers, laboratory workers, physicians and fumigators, which could be attributed to local irritation of formalin, from trade or vocational causes.

Galewsky[1] reports such instances in physicians and laboratory workers, in whom, after months of exposure, the nails become soft and discolored and subject to painful fissuring. It is usually accompanied by paronychia, œdema of the surrounding tissues, vesicular dermatitis, with burning and boring pains. He also sounds a warning against the use of formalin in soap or as a 4% to 10% solution as a successful measure against hyperidrosis. An attack of urticaria from formalin, however, has never come to my personal notice. Cases of this character can easily escape detection. That they can occur is evidenced not only by the above report but also by Glaser-Lippehne;[2] this author reports a patient who, at 6 P.M., took two formamint tablets. At 10 P.M., uritcarial lesions were present over the neck. Next day urticaria was present over the arms, accompanied by headache, vomiting and general malaise. Urticaria spread over the entire body and persisted for eight days. After an interim of well-being, for three weeks, administration of a single formamint tablet was promptly followed by an urticarial eruption over the patient's chest. Glaser-Lippehne, granting that idiosyncrasy may exercise a predisposing rôle, voices a protest against the sale of the proprietary tablets at the hands of dispensing druggists.

REFERENCES.

[1] *Muench. med. Wchnsch.*, 1915, No. 4.
[2] *Deutsch. med. Klinik*, 1908, No. 25.

SOCIETY TRANSACTIONS.

NEW YORK DERMATOLOGICAL SOCIETY.

Regular Meeting, Nov. 23, 1915.

HOWARD FOX, M.D., *President.*

CASE FOR DIAGNOSIS. Presented by DR. TRIMBLE.

The patient was a young woman, twenty years of age, born in the United States. She showed on the vermilion border, in the centre of the upper lip, a small lesion about the size of a split pea. It was raised and had existed for two years. She gave a history of the lesion scaling and crusting over. After a variable time this scale or superficial crust would fall off, only to be renewed in a few weeks. On close inspection, the lesion was seen to be raised and somewhat triangular in outline, with a definite line of dermarcation. The upper part of the border appeared to be rolled. The possibility of malignancy suggested itself, and the case was shown on account of the rarity of malignancy in this location and also in so young a patient. Dr. Trimble said he had seen the patient only once before.

DISCUSSION.

DR. JACKSON thought the case was not epithelioma.

DR. POTTER did not favor the diagnosis of epithelioma, and suggested a biopsy as the only means of reaching a positive diagnosis.

DR. TRIMBLE asked for suggestions as to treatment. Even if it were only a keratosis, what would be the best plan of procedure?

DR. WINFIELD saw no reason why the condition might not be an epithelioma. Not long since he had seen a man, under twenty-five years of age, with an epithelioma. As far as treatment was concerned, Dr. Winfield said he would remove it by curettage and cauterization.

DR. WISE considered the lesion to be a tuberculous ulcer. The lack of an indurated pearly border and the comparative absence of infiltration, he thought, together with the slow progress of the disease, would tend to rule out epithelioma.

DR. WILLIAMS saw no sign to convince him that it was epithelioma. There was no pearly edge, no marked infiltration; and he would say it was rather a keratosis. He saw no sign of active ulceration, no moist base, and he would like to know upon what Dr. Wise based his diagnosis of tuberculosis. As for treatment, he suggested simply protection, for a month at least; he would cover it with Lassar's paste, and see what happened at the end of that time.

DR. WINFIELD, referring to the points brought up by Drs. Wise and Williams, that there was no infiltration and no pearly edge, asked if it was not possible that these would be held in abeyance in so young a patient.

DR. TRIMBLE expressed his appreciation of the opinions given. It had not occurred to him that the lesion might be tuberculous. The tuberculous lesions

which he had seen, and which were very few, had been mostly on the tongue and, in his opinion, did not clinically resemble the one in question. The lesion presented was partly on the cutaneous surface and had not enlarged much since the very beginning. He was under the impression that under the magnifying glass, the upper edge was slightly curly and rolled. The fact that it had been there for two years and had gone through the same processes as an epithelioma—crusting over, etc., made him think that in all probability it was a malignant growth. This diagnosis, of course, was purely tentative. Epithelioma in so young a subject, on the upper lip, and in a woman, was rather dubious. The woman wished to be relieved of the condition, and he was in doubt as to the best plan of treatment, to start with. His own idea was somewhat similar to the plan suggested by Dr. Williams, only that he wished to use a strong salicylic acid ointment. If the lesion was keratotic, this ointment would probably take it off; and if it did not, he could go ahead with some operative procedure. In view of the fact that it might be a keratosis, he wondered if curettage would not be preferable to excision. He did not consider the case suitable for biopsy, as the lesion was too small. If a biopsy was to be done, one might as well remove the whole lesion.

Dr. Clark did not see why a very satisfactory result might not be obtained by a single dose of the X-ray, or the application of radium. If it was an epithelioma, he thought the X-ray would remove it.

ALOPECIA AREATA AND ICHTHYOSIS. Presented by Dr. Jackson.

The patient was a male, aged twenty-five years. He had had ichthyosis all his life, and as to this there was no feature of importance. On the anterior part of the scalp, the patient had two irregular, rather oblong, bald patches, in which the hair seemed to be broken off close to the scalp; and here and there short pointed hairs of normal diameter were seen growing from the hair follicles. On the left side of the head were two similar patches. The duration of the disease was three months. There was also a general hair fall.

The patient was presented on account of a little unusual character of the patches, but chiefly that the Society might make a note of the case, as Dr. Jackson intended to treat it with the Alpine sun lamp and present the patient again from time to time. During the past year he had treated four cases of alopecia areata with either the Kromayer or Alpine sun lamp. In two severe and extensive cases in which all the hair had been shed for many months, nothing was accomplished. In two less extensive and more recent cases, the result had been good; in one, the hair returning after three applications. But in this disease, in which the hair usually returned of itself under any or no treatment, it was hard to say whether the cures were due to nature or to art.

EXTRA-MAMMARY PAGET'S DISEASE. Presented by Dr. Potter.

The patient, Mrs. E. B., was a widow, forty-seven years of age, born in the United States. Her family and previous personal history were negative. The patient stated that she has always had a pedunculated fibrous teat, which she called a wart. One day she noticed that the wart had disappeared. It had apparently been rubbed off. This happened five years ago. Soon after that, the site of the wart became sore and slightly red. The redness increased, but the soreness disappeared. There had never been any pain in the area. The patch was the size of a silver dollar, definitely outlined and eczematous in character. The patch had never entirely healed, although on several occasions it had been almost healed.

Discussion.

Dr. Trimble said that if all these very superficial epitheliomata were to be called extra-mammary Paget's disease he would then agree with the diagnosis, otherwise he would say the case was a basal cell epithelioma. If Dr. Potter had found the histological picture of Paget's disease, so-called psorsperms, etc., then, of course, there was nothing more to be said; if he had not found this condition and there was only a down-growth of the epithelium, he would call it the basal cell type of epithelioma. He had exhibited an almost identical patch on the abdomen of a woman before the Society, at its last meeting, which did not show any border, but which had proved epitheliomatous under the microscope. Some would probably have called that case extra-mammary Paget's disease.

Dr. Wise said that without a microscopical examination, he would consider the lesion to be a most superficial type of epithelioma.

Dr. Jackson also believed that the lesion was a superficial epithelioma.

Dr. Winfield said the case resembled one which he had seen several years ago, which looked like the superficial basal-celled epithelioma. The spot had been started by the corset steel, on the scapula, and became eczematous and would sometimes heal under treatment. The patient had been under the care of another dermatologist for a long time before she came to him. She then had a lesion of a shiny, glistening red appearance, and scaly around its edge. A specimen was removed and sent to a pathologist, who made the diagnosis of Paget's disease. This diagnosis was made simply from the microscopical findings, as he (the pathologist) knew nothing of the history of the case.

Dr. Potter said that clinically the case may have looked like a superficial basal celled epithelioma, but that it had more of the characteristics of Paget's disease, although the border was not characteristic. The microscopical findings showed a dyskeratosis, with the involvement of both the prickle cell layer and the basal cell layer. The papillary region of the derma showed inflammatory changes. While there were no psorosperm-like bodies present, the microscopical picture was suggestive of Paget's disease. Dr. MacKee, to whom the section was shown, was inclined to believe the microscopical picture was one of Paget's disease.

DERMATITIS HERPETIFORMIS. (PEMPHIGUS PRURIGINEUX, HARDY.)

Presented by Dr. Winfield.

The patient was a woman, aged fifty years, a native of the United States. Ten years ago, after a long strain of anxiety and worry, she noticed a few small blisters about the shoulders. They were intensely itchy. The eruption kept recurring in successive crops. During the past ten years she had consulted many physicians and had received many kinds of treatment, even salvarsan, but none had given her any continued relief.

Early in the summer of 1915, she entered the dermatological service of the Kings County Hospital. At that time there were crops of blisters all over the body, most marked about the buttocks, shoulders, and legs; the blisters were grouped. The eruption was intensely itchy. The general health of the patient was fair. General tonic treatment was given, and antipruritic lotions and ointments were applied to the skin. After remaining in the hospital for about six weeks, she went to the country. While there, her skin condition improved but did not get entirely well. While in the hospital she received three injections of auto-serum, with but little if any good effect. Since her return from the country, the eruption had been much worse.

Discussion.

Dr. Potter said he had seen this case for a certain length of time when the patient first came to the hospital, and the diagnosis then rested between dermatitis herpetiformis and pemphigus. He agreed with the diagnosis of pemphigus.

Dr. Trimble said that, looking at the case superficially, the clinical picture seemed more like one of pemphigus than dermatitis herpetiformis; however, if the history of intense itching and recurrent crops of bullæ was added, without systemic symptoms, it would bear out the diagnosis of dermatitis herpetiformis. He wondered if the cases of dermatitis herpetiformis of this type did not at some time develop pemphigus, and eventually die. Although this case conformed rather typically to the large bullous variety of dermatitis herpetiformis, numbers of the individual lesions looked very much like pemphigus.

Dr. Howard Fox considered the case typical of the bullous type of dermatitis herpetiformis. The eruption was chronic, relapsing, pruriginous and grouped. He thought the disease would yield to injections of heterogeneous serum, as it had done in a severe case of his, after having received nine injections.

LOCALIZED SCLERODERMA. UNILATERAL PIGMENTATION. Presented by Dr. Howard Fox.

The patient, Mrs. S., was 25 years of age, born in the United States. Twenty-two months ago, when the patient was five months pregnant (for the first time) she began to notice a patch of pigmentation upon the left side of the face, which gradually increased in area and intensity until four months ago. She then felt a thickening of the skin of the left cheek. The latter condition appeared rather suddenly and had not changed much since its first appearance. The pigmentation had also remained stationary. The patient complained of itching at times, but showed no evidence of scratching. According to her statement the general health of her husband, her baby and herself was excellent. Her husband, she said, had suffered from several attacks of iritis. Examination showed the patient to be an apparently healthy woman, weighing 154 pounds. Though she said her skin became usually tanned in the summer, she had blond hair and blue eyes. On the left side of the face and neck were patches of fawn-colored pigmentation; the largest patch, which was upon the left cheek, was about four inches in diameter and near its periphery were small pigmented areas. The patches on the chin and neck were lighter in color and smaller in size than upon the cheek. At the site of the pigmented area of the cheek there was a diffuse, painless induration of the skin and subcutaneous tissues, the skin being too adherent to be pinched between the fingers.

PECULIAR PURPURIC CONDITION OF THE LOWER EXTREMITIES. Presented by Dr. Trimble.

The patient was a married woman, thirty-eight years old, born in the United States. The condition at the time of presentation was of about two years' duration, and was confined to the inner side of both lower thighs and the circumference of both legs. It had begun immediately posterior to the left ankle as a small, red, non-itching spot, about the size of a silver dime. This spot grew in circumference, and other similar spots began to appear further up the leg, growing larger and coalescing, until, as could be seen, most of the leg was uniformly discolored with a light brown pigment, which did not disappear on pressure. On the lower thighs, there were particularly noted web-like interlacings, seemingly of the same nature as the discoloration of the legs. The

microscopical examination showed only blood pigment and a very mild infiltration of round cells around the blood vessels.

The speaker said that at first glance the case looked like one of beginning acrodermatitis atrophicans, but upon a closer examination it could be seen that it belonged in the group of hæmorrhages.

Discussion.

Dr. Potter said he believed it to be a case of purpura. The recurrent attacks at frequent intervals, over a long period, would account for the pigmentation present. In a few places, true purpura spots were noted.

Dr. Trimble said that the case was evidently one of ordinary purpura, the peculiarity being that it was not punctate, but diffuse and uniform on both legs. Hæmorrhage and later pigmentation of this variety was seen as a rule around a long standing ulcer of the leg. The fact that this patient had never had a leg ulcer and that there were no varicose veins, made the case interesting enough to bring before the Society.

CASE FOR DIAGNOSIS. Presented by Dr. Trimble.

The patient was a well-nourished woman, twenty-eight years old. She was married, had two healthy children, and had had one miscarriage. The condition began five years previously, as a "cracked" left nipple. This developed into an abscess, and was opened by her family physician. In six months, after it had apparently healed, another abscess formed in the scar tissue in the line of incision, and was again incised. This time the abscess did not heal, and local treatment was resorted to for two years, without betterment. It was dressed continuously, from the surgical standpoint. By this time the breast had become so undermined and there was so much loss of tissue that it was decided to remove it, which was done in Mount Sinai Hospital.

Present Status: There was a rectangular area, beginning in the left axilla, running down for about three and a half inches and in toward the sternum, for about six inches. On this area the skin was adherent to the ribs and under structure, was smooth scar tissue in most places, but keloidal in others. The whole area was somewhat sunken below the level of the surrounding healthy skin. Beginning at the upper border of this rectangular lesion, ran a depressed line along which there were three circular, dark red, ulcerated lesions, probably exuberant granulations, exuding pus. The upper lesion began as a deep infiltration, very much like a gumma; it eventually broke down, leaving an ulcerated area. The scar was large and flat, and slightly hypertrophic, and seemed to be grafted in. All the area formerly occupied by the breast showed a scarred, twisted, keloidal appearance, cicatricial and stringy. The pathological examination showed only granulation tissue, the specimen being taken at the border of one of the ulcerated lesions. Wassermann negative.

Discussion.

Dr. Jackson said it was probably a case of tuberculosis of the skin.

Dr. Williams agreed with the diagnosis of tuberculosis.

PITYRIASIS ROSEA. Presented by Dr. Williams.

The patient, a male adult, was first seen at the Bellevue University Dispensary. The rash had appeared two weeks previously and was spread over the entire back

and front, also on the arms, forearms, face and scalp. The eruption was intensely itchy, with erythematous patches and a slight amount of scaling. The speaker said that the lesions on the scalp, arms and forearms were rather unusual in their localization.

Discussion.

Dr. Clark considered it a very unusual case of pityriasis rosea, but agreed with the diagnosis. It showed the characteristic cigarette paper lesions, with crinkled centres.

Dr. Potter thought that the man had pityriasis rosea but that it was in an unusual location. It was unusual to have it occur on the face, and rather unusual to have several attacks, as the man claimed to have had. The patient also had a seborrhœa of the scalp and some of the lesions on the body were eczematous in character. The speaker believed the patient had both pityriasis rosea and seborrhœic dermatitis.

Dr. Winfield said that some of the patches on the scalp, back and chest looked like seborrhœa.

Dr. Trimble said that up to this fall he had never seen a case of pityriasis rosea of the face. He had seen a number where the lesions encroached as high as the lower border of the inferior maxilla. He remembered one case where the eruption had appeared a little above the lower border of the jaw, but that was the only one he had seen where it encroached on the face. Since the first of October, however, he had seen three typical cases occurring on the face. These were very definite and could not be confused with seborrhœic dermatitis.

Dr. Jackson would diagnose the case as one of seborrhœic dermatitis, rather than pityriasis rosea. He failed to see any evidence of the latter. The fact that the patient seemed to have had several outbreaks of a similar kind was in favor of seborrhœic dermatitis. So far as he (Dr. Jackson) knew, pityriasis rosea was not a relapsing disease, as a rule. He thought that a resorcin or sulphur lotion would clear the case up, while it would have little or no effect on pityriasis rosea.

Dr. Wise preferred the diagnosis of seborrhœic eczema, stating that the infiltration and marked thickening of the skin, together with the appearance of large areas of affected integument, were not the symptoms of pityriasis rosea.

Dr. Howard Fox thought the case was one of pityriasis rosea. He said that the idea that the disease did not occur on the face was erroneous. He had lately seen and photographed a fine example (patient of Dr. Oulman) of the circinate type of the disease, with a well-marked involvement of the face.

Dr. Williams said that the discussion regarding seborrhœic dermatitis was very interesting. One dermatologist of his acquaintance insisted that there was no such disease as pityriasis rosea and that all cases in which this diagnosis was made, were really cases of dermatitis seborrhœica. He did not concur in this opinion, and believed that in a case of dermatitis seborrhœica of this extent there should be much more greasy scaling. He presented the case on account of the involvement of the face and also the extreme congestion of the lesions. This congestion and the resulting elevation had seemed to him much more frequent in the past year or two than in cases seen before that time, and was not in accord with the classical description.*

* Close questioning of the patient at a subsequent visit failed to elicit any history of repeated attacks.

ANNULAR MACULAR SYPHILIDE. Presented by Dr. Howard Fox.

The patient, M. C., was a married woman, 43 years of age, born in the United States; about two years ago (December, 1913) she went to the Post-Graduate Hospital Dispensary where she was seen by Dr. Parounagian. At that time she presented characteristic symptoms of a fresh infection of syphilis. These included a macular rash, sores in the mouth, malaise, headache, loss of weight, etc. The spirochæta pallida was found in the mouth lesions and her Wassermann was positive. Her symptoms gradually cleared up under treatment, which consisted of two injections of salvarsan and seven of salicylate of mercury. About five months later she was operated upon at the Harlem Hospital, according to her statement for "pus tube." About eight months later she again applied for treatment at the Harlem Hospital. She then presented symptoms characteristic of early syphilis, including a typical macular eruption, hoarseness, headaches, restlessness at night and sores in the mouth, and a positive Wassermann reaction. All of the clinical symptoms promptly disappeared after an injection of salicylate of mercury. About eight months later, *e.g.*, nearly two years after her original infection, she again applied for treatment. She stated that about three weeks previously she had begun to suffer from sore throat, headaches and sleeplessness and that four or five days later the eruption which she exhibited, appeared. It had then existed about a month and consisted of circinate macular lesions of a dull reddish color, situated upon the trunk and thighs. The lesions were not scaly, elevated and did not cause any subjective symptoms whatever. The Wassermann reaction was again strongly positive. The case was presented as one of the rare relapsing annular type of the macular syphilide, in contradistinction to the comparatively common annular papular syphilide so frequently seen in negroes. The case would be reported later in more detail.

Discussion.

Dr. Jackson said that he had seen this case by daylight in Dr. Fox's office. At first glance, he took it to be one of ordinary circinate erythemia, but as the condition had been present for some time without showing signs of clearing up, and the patient was surely syphilitic and had had several relapsing eruptions, he was content to accept Dr. Fox's diagnosis. It was to be noted that this eruption came out with the same kind of symptoms that ordinary erythema might present, namely, sore throat, malaise and pain about the joints.

Dr. Wise said he had seen one or two similar cases, in which he did not hesitate to make the diagnosis of a circinate form of macular syphilis.

Dr. George Henry Fox said he could recall only one case like this one, which he had published with an illustration. In that patient, the lesions had occurred in the second year and were precisely like those of the case presented. He said this form of syphilis was extremely rare and his picture of it was the only one he had ever seen. He further said that no member of the Society had made a more thorough study of syphilis than the late Dr. Robert W. Taylor and yet in two editions of his text-book there were pictures purporting to be of the circinate erythematous syphilide, but they were manifestly of the papular type, such as is so often seen in the negro. One was a wood cut and showed the typical discoid papular syphilide of the annular type. The other, a colored plate, showed the common type of the annular syphilide where the discoid patches healed in the centre and produced rings.

Dr. Clark said that from its history this case might conform to the diagnosis of annular macular syphilide.

Dr. Potter said the eruption resembled erythema multiforme very much, but

two features of the case were decidedly against that diagnosis,—the location of the eruption and its purely macular appearance. The eruption was entirely absent from the hands and forearms, and on palpation it showed no sign of elevation. The speaker agreed with the diagnosis of syphilis.

Dr. Winfield said that, as Dr. Fox had just stated, the presence of these lesions on the classical areas, and also the duration of the eruption, made him think it a macular annular syphiloderm.

Dr. Schwartz said that, in view of the history which Dr. Fox had given, he thought the patient must undoubtedly have had syphilis. The present eruption, however, did not seem to him to be a syphilitic one. He would rather look upon it as a case of toxic erythema, on account of the history of general malaise, the heavily coated tongue, and the fact that the patient was very constipated, her bowels moving only about once a week. He would like to see what effect free cathasis and diuresis, kept up for a week or more, would have on the eruption.

Dr. Howard Fox said that if he had not observed the patient during her second attack of sore throat and macular rash, he would have considered the case to be simply an erythma multiforme. He based his diagnosis of relapsing, annular macular syphilis upon the following points. The patient was known to have previously suffered from syphilis and to have apparently presented a macular syphilide for the second time. There had been no tendency at all for the lesions to disappear during the past month and the eruption was not attended by subjective symptoms of any kind. He would follow the suggestion of Dr. Schwartz and try the effect of thorough purging.

CASE FOR DIAGNOSIS. Presented by Dr. Trimble.

The patient was a male adult, aged forty-two years. The skin lesions had existed four years and were confined to both legs. In this location could be seen a great number of closely aggregated small papules, all of which were about the size of a small match head. Some of these were acuminate, others rounded on top, and all were capped with a very adherent, horny scale. The disease, as a whole, was of the nutmeg-grater type. The skin on the dorsum of the feet was very much thickened and the patient complained of intense pruritus. The patient was suffering from an enlarged liver and in the daytime, jaundice was quite apparent. On his first visit to the clinic the condition was thought to be either Darier's disease or an unusual type of lichenification of the skin.

The speaker said that as the lesions were confined to the legs below the knee, he thought it was a rather unusual type of lichenification of the skin. For the liver condition, the patient had been sent to the general medical department of the clinic, where a diagnosis of cirrhosis of the liver was made.

Discussion.

Dr. Jackson thought the case was one of extreme keratosis pilaris in a man whose circulation was sluggish and who did not keep his skin clean; and he thought the vigorous use of warm water and soap would cure the case.

Dr. Winfield was inclined to agree with Dr. Jackson's diagnosis of keratosis pilaris.

CASE FOR DIAGNOSIS. Presented by Dr. Trimble.

The patient was a male adult, fifty years of age. The duration of the condition was five years. The location was limited to the scrotum. According to

the patient's history, the disease began by chafing, which was further complicated by accidental burning with hot oil of some kind. The lesion showed marked infiltration with deepening and accentuation of the usual furrows; in fact, the condition was nodular. Several nodules were round and seemed cystic. The central part of the scrotum, the raphé, was free, front and back, so the whole lesion was fan-shaped. The itching was intense.

Discussion.

Dr. Jackson said he believed it to be a case of sebaceous cysts. The scrotum was a favorite location for such tumors.

Dr. Wise said that, though he was aware that some of the lesions were ordinary sebaceous cysts, he did not believe all the manifestations were of this type, but rather a form of elephantiasis of the scrotum.

Dr. George Henry Fox thought the lesions were sebaceous cysts. Their unusual number had caused them to become confluent, and they, therefore, presented an appearance somewhat different from the ordinary discrete type.

Dr. Williams said that his first impression of the case was one of a clinical picture of elephantiasis, from the increase in the furrows and the firmness, but that the presence of sebaceous cysts was undoubted. Closer examination showed that it could not be elephantiasis, because in that condition the skin would be tough and leathery and involved throughout its entire thickness; whereas in this case only the superficial layers of the skin were concerned in the disease process. Some of the lesions were sebaceous cysts, but there was also some other pathological condition which he could not identify.

Dr. Clark said that sebaceous cysts, much smaller than the ones presented, often produced an intense pruritus. He questioned if the case was not complicated by the chronic, thick, eczematous condition which had been induced by the patient's scratching, which was combined with the multiple sebaceous cysts.

Dr. Potter thought the condition was one of multiple sebaceous cysts, and said he could not see any eczema there at all. There was no induration and thickening of the skin of the scrotum which would necessarily be present in eczema. The hardening of some of the lesions could be accounted for by the fact that the contents of some of the cysts had become calcareous.

Dr. Winfield did not agree with the diagnosis of eczema. He thought there was another condition present, which had nothing at all to do with the sebaceous cysts. There was some probability of a connective tissue tumor, and he thought there might be two conditions present, independent of each other.

Dr. Howard Fox thought it was a case of multiple sebaceous cysts, and that there were doubtless calcareous deposits in a number of them. He said this was a favorite location for sebaceous cysts, the scrotum being well supplied with sebaceous glands.

Dr. Trimble did not think the lesions were sebaceous cysts at all. He could not conceive of such a nodular condition being due to multiple sebaceous cysts, and he never had seen a sebaceous cyst that itched. The eruption was intensely itchy, like a chronic eczema.

RECKLINGHAUSEN'S DISEASE. Presented by Dr. Howard Fox.

The patient, M. R., was a man, twenty-eight years of age, born in Ireland. To his knowledge, no member of his family had ever suffered from a similar disease. With the exception of occasional indigestion, he had always enjoyed good health, and had worked as a grocery clerk. He stated that the eruption had been present as long as he could remember, that it had never appreciably

changed, and had never caused him any inconvenience. On examination, he presented a general eruption of the scalp, face and neck, trunk and extremities,—the hands, feet and genitals being free. The eruption consisted of a large number of varying-sized tumors and pigmented lesions. The tumors ranged from a pin head to a cherry in size, and showed varying degrees of firmness. Some were pedunculated. They were mostly devoid of abnormal sensation, though a few were slightly tender. From some of the tumors, comedones could be expressed. The skin covering the lesions was normal in some instances, bluish in others. The pigmentation consisted of numerous fawn-colored patches, varying from the size of a pea to an area three inches in diameter.

ACUTE ECZEMA. Presented by Dr. Williams.

The patient was a male adult, thirty-nine years of age, born in Ireland. He was a porter and did very much sweeping. The condition was one of acute eczema, showing a very rapid thickening of the palms. The lesions had begun some six or seven weeks previously, with an itching of the backs of the hands and between the fingers. They remained localized until about two to three weeks previously, when the palms began to crack, but not badly. One week before presentation, the eruption began to spread over the greater part of the trunk and extremities. There was a diffuse redness, thickness and scaling of the backs of the hands, and a localized thickening and scaling of the palms. There were many erythematous, papulo-squamous lesions elsewhere.

The patient had used "Mulligan's ointment" on his hands about three weeks before, and most of the dermatitis was probably caused by this application. The case was interesting on account of the rapid development of the great thickening of the palms.

ACNE OF UNUSUAL SEVERITY. Presented by Dr. Williams.

The patient, a male adult, was suffering from a very severe eruption of acne on the back. He was presented on account of the large size of the comedones and many cysts all over his back. The speaker said he would like to have the opinion of the members in regard to vaccine treatment in a case of this type, where inflammation was not a marked feature.

Discussion.

Dr. G. H. Fox said that vaccine treatment had been used with improvement in such cases, but that he would depend almost entirely on a local and mechanical treatment. With a ring curette he would scrape all the elevated lesions and then remove every comedo with a scoop, which should in a very short time get the skin into a better condition. A cold bath, followed by vigorous friction with a rough towel was of great value, in such cases and the skin improved more rapidly under this plan of treatment than under any other.

Dr. Jackson said it was a case of acne in what used to be called a scrofulous subject. He thought the acne vaccines would be of no service in such a case. He was accustomed to use the stock vaccines in the usual run of acne cases. He believed them of use as adjuvants, but never trusted to them as the sole cure, as the surgical management of acne was of the greatest importance. In this case the best results would be obtained by surgical means, and by doing everything possible to improve the patient's health,—such as cold baths, open air, codliver oil and iron.

Dr. Winfield was rather skeptical about the use of vaccines in any case of

acne. He said that the use of vaccines alone, without any mechanical treatment, would obtain no results at all. He agreed with Dr. Jackson's diagnosis of "scrofulous" acne. Mechanical treatment would give a better result in this case, and strict attention should be paid to the hygienic treatment and food.

Dr. Potter agreed with the other speakers that vaccines would be of little service in this case, but thought that vaccines were of service where there was a great deal of pustular formation, as an adjunct to other treatment. The lesions must, however, be drained mechanically.

Dr. Clark said he had had fairly good results in only a few cases of secondary infections of the skin, with the formation of pustules, and that along with the mechanical treatment, which was more necessary, he would administer a mixture of a form of iron, dilute sulphuric acid and magnesium sulphate, giving the patient a teaspoonful three times a day. The mixture could be taken over a long period without any disturbance to the digestive tract, and it was one of the greatest helps he knew of in these pustular skin infections,—boils, carbuncles and pustular acne.

Dr. Howard Fox said that Dr. Williams had inquired especially about the experience of the members with vaccines in acne. He himself had not used staphylococcus vaccines in treating acne, but had tried the stock vaccines of the acne bacillus. From his own experience with the latter remedy and from cases that he had seen treated by others, he was of the opinion that vaccines of the acne bacillus were practically worthless in the treatment of acne.

Dr. Wise reported that the male adult, fifty years of age, shown at the last meeting, presenting a papular eruption covering the entire body, was proven by biopsy to be a parapsoriasis lichenoides. Most of the members had diagnosed the condition as a probable case of lichen planus.

A middle-aged woman, presenting squamous lesions of the hands, and tentatively considered to present an instance of keratosis blenorrhagica, proved, upon further investigation, to have a scaly syphilide of the hands.

NEW YORK DERMATOLOGICAL SOCIETY.

Regular Meeting, Dec. 21, 1915.

Howard Fox, M.D., *President.*

CASE FOR DIAGNOSIS. Presented by Dr. Williams.

The patient, John V., from Dr. Trimble's service at the University and Bellevue clinic, was an intelligent man, 19 years of age, who first came to the dispensary only the day before. He dated the eruption from an attack of ivy poisoning about two months ago, and was very insistent that each lesion began as a blister. The eruption was scattered over both forearms and hands. The smallest lesion was a tiny white spot, hardly raised above the level of the skin. Larger spots were slightly elevated and were perceptible to the touch. When they reached the diameter of about a quarter of an inch they presented a slightly raised, distinct border, having very much the appearance and color of xanthelasma, with a depressed and apparently atrophic centre which was perfectly dry and which may have shown slight scaling. As these lesions subsided, they left slightly depressed, atrophic scars. The speaker said that the condition suggested a granuloma annulare or an annular lichen, but had characteristics which distinguished it from each of these diseases, and he was not prepared to offer any definite diagnosis.

DISCUSSION.

DR. FORDYCE said that Dr. MacKee had suggested that the condition might be lichen atrophicus. This suggestion seemed to him a good one, and he recalled a case which he had seen several years previously, of which he had made a histological study, included in an article he had written on "The Histology of Lichen Planus."

DR. JOHNSTON, speaking of the lesions on the right forearm, said that a punched-out ulceration ran across the long axis and there was no conformity to any known type either in it or in the circular, punched-out ulcer on the finger. These conditions led him to believe that the man was a malingerer. His story and his evident interest in himself corroborated this belief.

DR. WHITEHOUSE said that the same thought had occurred to him when he first saw the case, on account of its lack of conformity to any known skin disease. That, however, was only a suggestion, derived from the character of the border and the isolated lesion on the finger. It was also suggested by the pleased expression on the man's face at the puzzled study of the case by the members. He thought that possibility was worth considering.

DR. G. H. FOX said he could understand how a man could produce a bruise or an artificial blister, but not how he could produce a lesion with a raised, yellowish border. He himself had never before seen anything like it. The shape and appearance of the lesion on the forearm seemed to be identical with certain lesions in the case shown by Dr. Robinson.

DR. TRIMBLE said that Dr. Johnston's suggestion had not occurred to him. He could not conceive of the lesion on the left forearm being the act of a malingerer. He had thought of lichen planus atrophicus and other maladies in a cursory way but the lesion did not conform to any well-known skin disease. It was certainly an interesting case, and he was sure that Dr. Williams would make a pathological examination and report the result later.

DR. WISE asked if any of the members thought that the little white lesions resembled those of lichen nitidus, a form of tuberculide? In his opinion, the necrotic papules were a form of tuberculide. He did not consider that the patient was a malingerer.

DR. MACKEE said that he could not reconcile the white spots with malingering. White spots, or whitish spots, were not infrequently seen following acne and other affections. The lesions in Dr. Williams' case were porcelain-white and glistening, and were slightly infiltrated. The speaker thought there were only two diseases that could produce such lesions, lichen sclerosus and morphœa guttata (white spot disease). The lesions of the two diseases often markedly resembled one another, but in lichen sclerosus the distribution was likely to be greater and there were usually lesions in various stages of transition. In either disease, the pathology might be very misleading, or the picture would vary according to the type of lesions, its duration, the particular part of the lesion examined, its stage of evolution and involution, etc. The speaker regarded Dr. Williams' case as one of lichen sclerosus.

DR. WILLIAMS said that although the appearance of some of the scars and the evident interest of the patient in his disease might suggest malingering, he had ruled out that diagnosis on account of the yellow border, which was very evident in daylight and which could hardly be produced by any local application. When examined at night, the case seemed almost identical with Dr. Robinson's, but by daylight the color was a very prominent feature and suggestive of xanthoma.

CASE FOR DIAGNOSIS (ERYTHEMA MULTIFORME OR HÆMORRHAGIC ERYTHEMA NODOSUM). Presented by Dr. Whitehouse.

The patient was a girl, eighteen years of age, and this was the fourth attack she had had since June. The attack presented before the Society was only three or four days old. The condition began with joint pains preceding the outbreak of erythematous, infiltrated patches, which subsided, leaving a pigmentation. The lesions were scattered over the body and on the inside of the knee. The girl stated that the lesions reappeared on the same spots, leaving the dark pigmentation as seen. The speaker said he had not seen the lesions when they were active.

Discussion.

Dr. Fordyce said that it suggested purpura, with a rather peculiar distribution of the lesions.

Dr. Wise said that it seemed to him also to be an example of purpura.

CHRONIC INFLAMMATORY CONDITION OF THE SCALP. Presented by Dr. Williams.

The patient, J. S., was a man, twenty-nine years of age, from Dr. Trimble's Clinic at the University and Bellevue Dispensary, where he came for the first time the day before. The disease had been present for four or five years, showing very little change in that time. On the scalp, just above the right angle of the forehead, was an irregular area about an inch in diameter, in which the skin was red and thickened, presenting many small elevations about one-eighth of an inch in diameter. Some of these papules were covered with a thin crust, and in places there was a very little superficial scarring. The papules, while firm, were neither hard nor deep-seated, and there were no pustules. Surrounding this main diseased area were a few smaller ones. There was no marked alopecia. Pruritus was at times troublesome. The condition resembled somewhat folliculitis decalvans except that there was no baldness, while the appearance of the small papules suggested some form of adenoma.

Discussion.

Dr. Trimble said that it was certainly a sebaceous gland disease on the face, but it was his impression that the scalp lesion was a lichen simplex from continual irritation at that point, perhaps from a comb when the hair was continually pushed back, something like that over the occipital region of a woman's scalp, by continual irritation from a comb or by scratching. It was a peculiar condition, and he thought the case was one of ordinary lichenification.

Dr. Fordyce said that the lesions in this case suggested an acquired adenoma of the glands and was not the type of adenoma sebaceum described by Pringle.

LICHEN PLANUS OF THE PALMS AND SOLES. Presented by Dr. MacKee for Dr. Fordyce.

The patient presented a typical but unusual type of lichen planus. The tongue was covered with the eruption. At first glance, the condition of the tongue suggested leucoplakia but upon close inspection there was a mosaic appearance due to the coalescence of a multitude of tiny papules. In areas, too, on the tongue, there were large individual papules of a violaceous-white color with an umbilicated centre. The mucous surfaces of the cheeks were exten-

sively involved, as also were the upper and lower lips and the glans penis. There were numerous lesions on the palms and soles, both discrete and confluent, with considerable scaling. The papules here were unusually large. In color, some were yellow; others were a dull red. The backs of the hands were the sites of a multitude of large, umbilicated papules, and there was a noticeable œdema of these parts. The lesions on the forearms were those of ordinary lichen.

Discussion.

Dr. Elliot said that a colleague had had a very severe example of the disease on the palms and over the whole body in the past year. Curious to say, his daughter also had a generalized lichen planus at the same time, with implication of the palms. Both had been for a year or more under very severe nervous strain and tension. This case did not seem to him to be very unusual. He had seen it on the palms very often, as well as in the mouth. He had also seen a number of cases where it was localized on the penis.

Dr. Fordyce said that the case was noteworthy in the marked keratosis of the palms and soles. He had seen a number of cases of lichen planus involving these regions, but at no time had he seen a case in which the keratosis was so marked as in this instance.

CASE FOR DIAGNOSIS; ATROPHIC LICHEN PLANUS AND SCLERODERMA? Presented by Dr. Robinson.

Isaac S.; age, fifty years, born in Russia, married; he had five children, all healthy; occupation, tailor. He never had had any illness except diabetes, with 7½ per cent. sugar, for which he was treated at the Rockefeller Institute. The eruption appeared several months ago and occupied the left side of the thorax and the axillary region, and extended down the left arm to the end of the fingers. There was a slight eruption on right arm and hand. The speaker said that as it was a case of much interest, he had made sections and had taken photographs, and would publish the case after further observation. It was a very unusual example of lichen planus, in his opinion.

Discussion.

Dr. MacKee said that he regarded this case, as well as Dr. Williams' case, as one of lichen sclerosus.

Dr. Wise said that the appearance of the eruption fitted in with his conception of lichen planus atrophicus. The localization and the color of some of the lesions also suggested lichen planus of the common type.

Dr. Trimble thought there was a difference between this case and the one shown by Dr. Williams. The two lesions looked very much alike, almost identical, but on close inspection and on palpation it would be noted that Dr. Robinson's case had a very thin border, it was atrophied, almost wrinkled, while in Dr. Williams' case there was a decided infiltration. It was possible that Dr. Williams' case would atrophy later on and leave a similar condition.

Dr. G. H. Fox said he thought Dr. Robinson made a mistake in giving up his original diagnosis. Although it looked very much like morphœa, it seemed to be almost identical with the case shown just before. Dr. Fox thought it was a case of lichen planus atrophicus.

Dr. Whitehouse agreed with the diagnosis of lichen planus atrophicus.

Dr. Fordyce said that the histology of lichen atrophicus was different from

the picture presented by a typical case of lichen planus. The infiltration was deeper, the epidermis was atrophic and the collagenous bundles had undergone a degenerative change.

Dr. Trimble said that about two months ago he had presented before the Society a well-nourished young girl, about ten years of age, with a peculiar lesion on the cheek, and all those who discussed the case that night were inclined to think it was tuberculosis verrucosa cutis. It was presented for diagnosis at that time. The case had received a great deal of study, and seemed to be an instance of favus, although that diagnosis was not definitely established. It seemed evident that it was a parasitic condition. He showed cultures from the lesion and also photographs of the favus achorion, as a basis of comparison, and asked the opinion of the members present regarding the specimen.

Dr. Fordyce did not think a diagnosis of the condition could be made from the cultures alone. He stated that the histology should be studied in connection with the cultures.

REVIEW

OF

DERMATOLOGY AND SYPHILIS.

Under the direction of

FRED WISE, M.D., New York,

Assisted by

CLARENCE A. BAER, M.D., Milwaukee.
WILLIAM H. BAUGHMAN, M.D., New York.
PAUL E. BECHET, M.D., New York.
J. S. EISENSTAEDT, M.D., Chicago.
CHARLES GOOSMANN, M.D., Cincinnati.
ROBERT C. JAMIESON, M.D., Detroit.
M. F. LAUTMAN, M.D., Hot Springs.
OSCAR L. LEVIN, M.D., New York.
M. L. RAVITCH, M.D., Louisville.
ISADORE ROSEN, M.D., New York.
MAX SCHEER, M.D., New York.
PHILIP F. SHAFFNER, M.D., Chicago.
A. W. STILLIANS, M.D., Chicago.
JOHN H. STOKES, M.D., Chicago.
HARVEY P. TOWLE, M.D., Boston.
JAMES F. GRATTAN, M.D., New York.
VINCENTE PARDO, M.D., Havana, Cuba.

ARCHIV FÜR DERMATOLOGIE UND SYPHILIS.

(February, 1915, cxxi.)

Abstracted by JOHN H. STOKES, M.D.

THE GERMAN DERMATOLOGICAL SOCIETY, 1889-1914. BETTMANN, p. 3.

ON THE INTRADERMAL REACTION WITH NOGUCHI'S LUETIN IN SYPHILIS. PERKEL, p. 7.

The author used an original Noguchi preparation in 96 cases, 81 luetic and 15 non-luetic, with Wassermann controls. He obtained no positive reactions in non-luetic subjects. Among the luetic patients, 32% exhibited positive luetin reactions, and 64% positive Wassermann reactions. Four *tardive* reactions were observed, at 10, 14 and 22 days. A reaction in a well-treated case was observed. Comparing his own figures for total positives with those of 25 other authors, averaging 59.5%, he finds his own figures rather low (32%) although higher than those of four other authors. By stages of the disease, his results showed, in primary syphilis, 33%; in secondary syphilis, 10%; in latent syphilis, 28%; and in tertiary syphilis, 50%.

Perkel succeeded in lighting up a negative reaction in his own case by a second injection of double the dose, given 10 days after the first and 3 cm. from the original injection site.

A CASE OF SO-CALLED HYSTERICAL DERMATOSIS. RASCH, p. 21.

This is a case of "neurotic excoriation" of the type described by Erasmus Wilson. The excoriations were produced by vigorous rubbing with the thumb. The patient obligingly demonstrated her technique but declined to explain her motives.

BACTERIAL STUDIES OF THE TAEGE METHOD OF STERILIZING WATER FOR INJECTIONS, WITH SPECIAL REFERENCE TO WATER ERRORS AND SALT FEVER. D. LOEFFLER., p. 25.

Loeffler endorses the Taege method of sterilizing water by the addition of dilute hydrochloric acid. The article contains a good review of the investigations of Wechselmann, Muller, Emery and others on *Wasserfehler*. Loeffler's own investigations showed that water containing even so little as 0.5% HCl. sterilized itself on standing, virulent tetanus and anthrax bacilli and spores dying out in a few days. The method is commended as a means of providing for the keeping of water in stock for intravenous injections.

STUDIES ON THE EFFECT OF EXPERIMENTALLY CHANGED LOCAL CONDITIONS ON THE REACTION OF HUMAN SKIN TO ULTRA-VIOLET LIGHT. SOBOTKA, p. 45.

This is an elaborate study, in which the Kromayer quartz lamp was employed as the source of ultraviolet rays. The conclusions, somewhat condensed, are as follows:

Active hyperæmia in general increases the reactivity of the skin to ultraviolet light, while passive hyperæmia had little effect.

Intradermal injections of indifferent substances such as salt solution had no influence on the reaction; the same being apparently true of water.

Pressure before exposure to the rays had a variable effect; during the exposure it markedly increased the subsequent hyperæmia. During the latent period, transitory increase was observed. After the reaction was established, the effect of pressure was uncertain.

Substances such as adrenalin, producing local ischæmia when introduced by cataphoresis, increase the hyperæmia, probably from the galvanic effect and not the adrenalin. During the height of the reaction it produced transient ischæmia.

Wet dressings during the latent period and early reaction did not materially affect the grade of the hyperæmia, but made the venous element and local œdema more marked.

Local anæsthetics such as cocaine and alypin had little effect.

The depigmented patches in vitiligo were resistant to the action of the rays.

(*Ibidem*, April, 1915, cxxi, No. 2.)

EXPERIMENTAL CONTRIBUTIONS TO THE KNOWLEDGE OF DERMATOMYCOSES. I. SAEVES, p. 161.

This is an important contribution to the immunological study of dermatomycoses. The résumé embodies the following conclusions and observations:

(1) In guinea pig trichophytosis the organism can be found growing in the skin during the incubation period. The inflammatory symptoms do not make their appearance until hypersensitiveness or allergy is established.

(2) Reinoculations follow a modified course, and true immunity may be established by frequently repeated inoculations. Corymbose satellites may develop even after the disappearance of a reinoculation, if a virulent strain has been used.

(3) The effort to detect specific lytic ferments for trichophytic organisms in the serum of persons sensitive to trichophyton infection, by the Abderhalden technique, was unsuccessful. On the other hand, it was found that the organisms pathogenic for guinea pigs could produce a marked lysis of guinea pig serum, while organisms to which this animal is not susceptible produce little effect.

(4) Trychophyton organisms such as Epidermophyton inguinale and Microsporon Audouini, which are non-pathogenic for guinea pigs, could be cultivated from the skin of that animal ten to fourteen days after inoculation, so that their non-pathogenicity could not be due to the rapid dying out of the organisms.

(5) Intracardial injections of Achorion Quinckeanum and Trichophyton gypseum gave rise to trichophytic lesions in the skin of the injected animals, which showed the same structure and clinical appearance as those produced by cutaneous inoculation.

(6) Allergic phenomena were developed as a result of these intracardial injections as well as by cutaneous inoculations.

(7) There exists in man a form of corymbose lichenoid trichophytide.

ADDITION TO MY STUDY OF THE CLINICAL MANIFESTATIONS AND PATHOLOGY OF PEMPHIGUS FOLIACEUS. J. Fabry, p. 237.

This is an account of the autopsy findings on a case discussed by Fabry in *Arch. f. Dermat. u. Syph.*, 1914, p. 23 (Doutrelepont *Festschrift*). It embodies nothing especially new. The case ran an unusually protracted course, with bullous lesions occurring only during a period of 6 to 8 weeks.

DERMATLOGISCHE WOCHENSCHRIFT.

(Dec. 11, 1915, lxi, No. 50.)

Abstracted by Max Scheer, M.D.

CONCERNING THE DIAGNOSTIC VALUE OF THE WASSERMANN REACTION. Bendig, p. 1139.

The author analyzes the results of Wassermann tests made from the time of the introduction of salvarsan to Dec. 31, 1913. Of 256 cases of primary lues, the Wassermann was positive in 70%. The age of the initial lesion seemed to have no influence on the reaction. In 34 cases the infection dated back 2 to 8 days; of these, 59% were positive; in four of these cases the chancre was only two days old. In 60 cases the infection dated back 9 to 14 days, the Wassermann reaction was positive in 74%. Of 63 cases in which the infection was 3 to 4 weeks old, the Wassermann reaction was positive in 67%. Of 32 cases in which the infection dated back 5 to 6 weeks, the Wassermann reaction was positive in 69%. Of 8 cases in which the infection dated back 7 to 8 weeks, the Wassermann reaction was positive in 62%. Of 10 cases in which the infection was 3 months old, the Wassermann reaction was positive in 70%. Several cases of primary lues with negative Wassermann reaction became positive during treatment.

In secondary syphilis there was a similar lack of uniformity in the results of the Wassermann test. A negative test during treatment frequently became positive at the end of treatment.

Of 448 cases of latent lues, 61% had a positive Wassermann reaction, most of whom had two or more courses of mercury and salvarsan.

Of 813 girls with gonorrhœa and who had never had lues, the Wassermann reaction was positive in 26%. At first many of these patients received antiluetic treatment; in the later cases they received no antileutic treatment in spite of their positive Wassermann; the reaction, nevertheless, became negative with the subsidence of the gonorrhœa.

Twenty cases of scabies showed a positive Wassermann reaction in 45%.

The author concludes that the Wassermann serum reaction is not a specific diagnostic test for lues. It is frequently positive in all stages of lues, especially in the second period and can be considered as a symptom. A negative result does not mean extinction of the infection. A positive reaction does not necessarily mean lues. it may be present in many other diseases, *e.g.*, lepra, lead poisoning, ulcus molle, bubo, gonorrhœa with complications, scabies, eclampsia, malaria, scarlet fever, in narcosis, pernicious anæmia, nephritis, pemphigus, malignant tumors, etc.

(*Ibidem*, Dec. 18, 1915, lxi, No. 51.)

LUPUS FOLLICULARIS DISSEMINATUS. G. Nobl, p. 1164.

Case 1. A woman aged 35 years, with chronic apical catarrh, had an eruption on her face for 1½ years. The eruption consisted of irregularly disseminated, shot- to pea-sized, brownish-yellow to brownish-red, distinctly raised, firm looking nodules, most marked on the forehead, hair margin and bridge of nose and less numerous on the cheeks and temples. The skin around the nodules was normal. The lesions were soft and covered with a smooth, shiny and thin epidermic layer which could be easily removed; a few lesions were topped by scales. These soft nodules could be easily curetted away. A distinct local reaction was produced in them by 5 mg. tuberculin old. The lesions were cured by curettage and cauterization; after three months they recurred and were finally cured by repetition of the treatment. Microscopical examination of the nodules showed a typical tuberculous structure, but no acid fast bacilli were found.

Case 2. A woman 44 years old had an eruption on her face for three months. In childhood she had had enlarged cervical glands, at the age of 19 pleurisy and for the past two years, lupus of the mucous membrane of the right nostril. The present eruption involved the bridge of the nose, cheeks, forehead and left upper eyelid The papules were hemp- to small pea-sized, distinctly hemispherical and raised above the level of the surrounding skin, isolated and surrounded by normal skin. Their color was in parts darker yellow than the rest of the skin, and in parts reddish-brown: the surface of the lesions was smooth and there was no suppuration. Diaskopy showed brownish-yellow stains. There was an ulcerated and fissured lupus infiltrate of the mucous membrane of the right nasal aperture. Two mg. tuberculin old caused a marked general reaction as well as softening of the lesions with a surrounding erythema. The lesions on microscopical examination showed a typical tuberculous structure; no tubercle bacilli were found.

Case 3. A man, 24 years old, had had suppurating submaxillary glands under the left jaw which took several months to heal. Three months after healing, the present eruption, which was of four months' duration at time of observa-

tion, made its appearance. The eruption consisted of hempseed to buckshot to pea-sized, hemispherical, elevated, discrete and in part grouped papules and nodules on all parts of the face, but most numerous on the chin near the scrofulous scar. The papules were yellowish and brown-red and had a peculiar transparence. Some resembled milia. Peculiar to all of them was their soft jelly consistence. The skin between the lesions was normal. The lungs were negative. On administration of 4 mg. tuberculin old, the temperature rose to 38.9° C. and there was a distinct local reaction in the nodules on the cheeks, chin and forehead. The microscopical picture here also showed a typical tuberculous structure though no tubercle bacilli were found. An emulsion from a crushed nodule on the cheek was injected into the inguinal glands of two guinea pigs; one developed typical tuberculosis of the glands, the other animal remained normal.

The lesions in the above described cases differed from tuberculides in that they showed no central necroses and were not present on the extremities. There was no clinical resemblance whatever to sarcoid.

(*Ibidem*, Jan. 8, 1916, lxii, No. 1.)

PAROTITIS SYPHILITICA. O. HASLUND.

The author gives a brief résumé of the literature dealing with syphilis of the parotid gland and adds a case of his own in a congenital syphilitic, making a total of five reported cases of parotitis in congenital lues.

His case was a boy, eight years old, with congenital lues, who had had adequate treatment for the past four years. When six years old, and while under treatment with inunctions and potassium iodide, a swelling appeared over the right parotid gland; the gland was firm, surface slightly irregular, not painful and only a little tender on deep pressure. Since antisyphilitic treatment was without result, he was transferred to the surgical department where the swelling was incised and some broken-down parotid tissue was removed; this tissue had the gross appearance of a broken-down gumma; the microscopical picture spoke neither for nor against syphilis. In spite of frequent dressings the swelling persisted unchanged for several months; then mercury inunctions and potassium iodide were resumed and finally the gland approached its normal size, about two years after the onset of the affection. Several Wassermann tests during this period were all positive.

The author mentions a case of gumma of the tongue which was cured only after intensive treatment over a long time and reminds us that syphilitic glandular affections (regional adenitis accompanying chancre as well as the generalized adenopathy of the secondary stage) are less influenced by treatment than skin or mucous membrane lesions.

In this case of parotid swelling the only other diagnostic possibilities were malignant tumor, which the course of the case excluded; and chronic parotitis, a rare and indefinite affection. Of the latter only ten cases have been reported, nine of them before the Wassermann era, and the histories of some of them suggest a syphilitic ætiology.

MUENCHENER MEDIZINISCHE WOCHENSCHRIFT.

(July 27, 1915, lxii, No. 30.)

Abstracted by ARTHUR WM. STILLIANS, M.D.

AN OBSERVATION IN CONNECTION WITH ROENTGEN THERAPY. F. JANUS, p. 1009.

The author claims that a hot bath, soon after a massive dose of Roentgen rays (deep therapy under a 3 mm. aluminum filter) brings out in erythema over the treated areas. So sharply are the treated fields outlined that a photograph reproduced with the article shows clearly the inaccurate overlapping of successive exposures on each field. The erythema disappears in a short time. The author believes that this fact may prove useful in testing the irritability of the skin; and in cases previously treated by others, where the data of treatment cannot be obtained, it may enable one to judge whether further treatment is safe.

(*Ibidem*, Aug. 3, 1915, lxii, No. 31.)

MUFFLED HIGH FREQUENCY AS A SCAR-SOFTENING AGENT. F. Becker, p. 1044.

A report of 33 cases of slow healing wounds with callous edges, hypertrophic scars, keloids and contractile scars, treated with very gratifying success in nearly all of the cases. These results were obtained by the use of the finest of brush discharges, sparks being carefully avoided. The effects are said to be due to the hyperæmia resulting from the heat and causing ionic changes in the tissues.

(*Ibidem*, Aug. 24, 1915, lxii, No. 34.)

ACUTE YELLOW ATROPHY OF THE LIVER DURING SYPHILIS. Bendig, p. 1144.

A well-nourished girl in the ninth month of pregnancy was treated for primary syphilis, with 10 mercury inunctions of 4.0 gms. each, then an intravenous injection of 0.4 gm. old salvarsan, which caused no reaction. Twelve more inunctions were followed by a second salvarsan of 0.4 gm., which was again well borne. Nine more inunctions were then given and a third salvarsan of the same size given. Eight hours after the injection she vomited, and the next day seemed mentally disturbed and sighed often during the night. On the third day she was very restless and complained of dyspnœa and a feeling of tension in the epigastrium. On the fourth day she was still more restless, the urine showed a trace of albumin, a few red cells and a few granular casts, and that evening she died. The autopsy revealed acute yellow atrophy of the liver. The author refers to a case seen by him before the salvarsan era, and to two other cases which had received salvarsan. While he does not think that the drug can be entirely to blame for these cases, he acknowledges that it has probably coöperated with the toxines of syphilis, the pregnancy and the mercury, to overpower the excretory mechanism.

THE COOLING OF ROENTGEN THERAPY TUBES WITH BOILING WATER. Bucky, p. 1145.

The cooling of Roentgen tubes has been carried to the limit of cool temperature with very poor success, for the use of liquid air or liquid carbon dioxide makes the tubes "cranky." With the circulating water-cooling, a tube of 11 or 12 Wehnelt can hardly be given more than 2.0 milliamperes. More current than this makes the danger of puncture, especially near the cathode, very great. Impressed with the need of holding the tube at a fairly constant temperature in order to get the best results, the author uses boiling water. No overheating

need be feared, for each gram of water absorbs 537 calories in becoming vaporized. The current seems to pass through the tubes at this temperature much more easily than at the lower temperatures, and the tube in action looks much softer than it really is.

He recommends filling the water chamber with water at nearly 100° C., then passing 5 milliamperes of current until the water begins to boil. The penetrability is then measured, and if the tube, after a few minutes' use with the water boiling, reaches the desired penetrability, it can be relied upon to maintain this condition for hours. He has a special tube made with a water cooling chamber at the cathode, as well as at the anticathode. He claims that he gets regularly 145 X in 10 minutes under 3 mm. aluminum. The Sabouraud pastilles he considers wholly unreliable for hard tubes.

(*Ibidem*, Aug. 31, 1915, lxii, No. 35.)

AN OBSERVATION IN CONNECTION WITH ROENTGEN THERAPY. C. Kaestle, p. 1186.

Remarking on the report of Janus, in No. 30 of this volume of the *Muenchener medizinische Wochenschrift*, in which he described an erythema appearing after a hot bath over the area exposed to the Roentgen rays, Kaestle says that he made the same observation several years ago, but after considerable investigation was unable to obtain results definite enough to make the phenomenon of any value in the estimation of the dose of Roentgen rays that had been applied.

DEUTSCHE MEDIZINISCHE WOCHENSCHRIFT.

(Sept. 23, 1915, xli, No. 39.)

Abstracted by Clarence Allen Baer, M.D.

ARTIFICIAL SUNLIGHT TREATMENT OF LUPUS AND OTHER TUBERCULOUS SKIN DISEASES. G. A. Rost, p. 1152.

The author concludes that by the use of artificial sunlight, lupus and other tuberculous diseases of the skin and mucous membranes can be greatly benefited. This local improvement can be made more penetrating by the combined use of the quartz lamp. The most severe forms of the disease can be improved in this way. The application is painless and less expensive than the Finsen treatment. Lupus of the mucous membranes and surgical forms of tuberculosis are best treated by the combination of the artificial sunlight and filtered Roentgen rays.

(*Ibidem*, Oct. 28, 1915, xli, No. 44.)

SODIUM SALVARSAN AND THE COMBINED MERCURY-SALVARSAN TREATMENT. Erich Hoffmann, p. 1301.

Sodium salvarsan is a good substitute for the old salvarsan, because (1) fewer disagreeable symptoms accompany its use, (2) it is easy to use, (3) it affects the lesions and serum reaction of syphilitics the same as the old salvarsan.

In the abortive treatment of syphilis it seems as effective as old salvarsan. The use of sodium salvarsan is too recent to permit of statements as to the permanency of its effects.

(*Ibidem*, Dec. 2, 1915, xli, No. 50.)

DEATHS FOLLOWING SALVARSAN. F. LUBE, p. 1462.

There are two forms of acute arsenic poisoning, namely (1) the paralytic forms affecting the central nervous system (encephalitis hæmorrhagica) and (2) the ordinary gastrointestinal form that arises from a blood vessel weakening the gastrointestinal tract. Arsenic is primarily a blood vessel and not a nerve poison. Nerve alterations are secondary to repeated small doses of arsenic. Why, following salvarsan, the paralytic form of arsenic poisoning is relatively frequent, while the gastrointestinal form is rare, has not as yet been satisfactorily explained.

ANNALES DES MALADIES VÉNÉRIENNES.

(October, 1914, ix, No. 10.)

Abstracted by PAUL E. BECHET, M.D.

SYPHILITIC PHLEGMASIA ALBA DOLENS. DRUELLE AND BLUM, p. 721.

Druelle and Blum speak of the relative frequency of phlebitis in secondary syphilis. While involvement of the large venous trunks is rare, it has occurred. They report a case coming under their observation, and several others from the literature on the subject.

(*Ibidem*, November, 1914, ix, No. 11.)

MIKULICZ'S DISEASE AND SYPHILIS. THEODORESCO, p. 801.

Theodoresco believes that syphilis is the most frequent causative factor in Mikulicz's disease. He reports a case occurring in a woman, 53 years old. The Wassermann reaction was negative, the patient presented no evidences of syphilis, and gave a negative specific history; 0.10 cgr. of calomel was injected once weekly, with marked improvement after the second injection and complete disappearance of the tumefactions after eight injections.

RUSSKI JOORNAL KOJNIKH E VENERICHESKIKH BOLEZNEI.

(September-October, 1914, xxviii, Nos. 9 and 10.)

Abstracted by M. L. RAVITCH, M.D.

A CASE OF ALOPECIA AREATA MALIGNA OF NERVOUS ORIGIN. TELEGHE, p. 5.

Trichotillomania and alopecia neurotica are diseases of the hair that interested Teleghe, the latter attracting his attention especially. According to Baerensprung, alopecia areata is due to a trophoneurosis, while Lassar, Eichhorst, Holborn, Gruby and others thought it due to some fungus or other parasitic agent. v. Sehen once claimed an "areacoccus" as the cause of alopecia areata, but this theory was refuted by investigations which proved that only the usual microbes of the normal epidermis are found on the scalp in alopecia areata. In 1896, Sabouraud made the bold statement that there

is a relationship between the microbes of alopecia and seborrhœa oleosa, but this theory, too, was exploded by the investigation of many workers, particularly Jacquet. At the present time most of the investigators claim that alopecia areata is due to a trophoneurosis: because (1), there is often atrophy of the follicles and papillæ of the hair and atrophy of the sebaceous glands, true derma and aponeurosis of the scalp; (2), in recurrent cases the baldness occurs on the same place; (3), there are often nervous manifestations, such as loss of sensibility, hyperæsthesia and paræsthesia; (4), one member of the family may suffer from alopecia of long standing without its occurring in other members of the same family; and (5), persons afflicted with alopecia areata are usually suffering from some form or other of nervous disorder. Mibelli, Joseph, Moskalenko, Koster and others have produced alopecia in animals and man by excision of the second cervical ganglion.

Kaposi and Grenden and others hold that some cases are due to neurotrophic disturbances and others to parasitic infections. Trauma is also held to be an ætiological factor, as are neuropathic hereditary tendencies. The author cites a case of alopecia areata, the cause of which he considers to be plainly neuropathic.

He warns us not to confuse the diagnosis of neuropathic alopecia areata with: (1) syphilitic alopecia; (2) alopecia atrophica; (3) lupus erythematosus; (4) alopecia neurotica and (5) trichotillomania. In regard to the treatment of this affection, the author claims Kromayer's quartz lamp has acted admirably in his case, only a few seances being required to produce a successful result.

TAR-CHRYSOPHANIC BATHS IN THE TREATMENT OF PSORIASIS. KARUSKIN, p. 129.

Kakuskin states that Sabouraud obtains brilliant results in the treatment of psoriasis with various preparations of tar and chrysophanic baths. In an ordinary size bath tub he puts a litre of the following mixture: two egg-yolks, 100 grams of oil of cade, sufficient panama extract to make an emulsion, 6 grams of chrysophanic acid, water sufficient to make 1000 cc. Water is run in until the bath tub is full enough to cover all parts of the patient's body and in this mixture the patient sits for about an hour, gently rubbing the skin. Five baths are given weekly. Sometimes he replaces the oil of cade with oil of betula, white cadin. To kill the odor after the bath, the author advises that the body and the scalp be rubbed with a mixture of 150 parts of elix. viscer, Hoffman, and 40 parts of extract of violet.

ERYSIPELAS AND TATTOOING. MESCHERSKI, p. 136.

Mescherski says that Schwald observed a very interesting relationship of an erysipelatous process to a tattooed skin. He noticed that erysipelas developed more rapidly and severely on the skin that has been tattooed with a red color than with a blue color. Judging from such a standpoint he comes to the conclusion that "a red color attracted streptococci." One would think that the antiseptic properties of the materials used for tattooing might be a determinant as to infection, but it very likely is governed by the fact that particles of cinnabar are larger than particles of coal and, therefore, obstruct the lymphatic vessels more, thereby enabling them to harbor a larger number of streptococci, whence the more intense inflammation of the red-tattooed skin.

A CASE OF GENERALIZED SYPHILITIC LEUCODERMA WITH ALOPECIA. BOBOVITCH, p. 144.

Bobovitch states that cases of generalized syphilitic leucoderma are at times

reported in medical literature. Outside of the cases reported by Fournier, Neumann, Chaveau, Tortor and Hudelo, there were a few cases reported and demonstrated by Lesser, Rille, Ehrmann, Danlos, Vomer, Arning, Maess, Porrier and Mandes. In the Russian literature only one case was reported, and that by Poltavzev.

The author reports a very interesting case of generalized syphilitic leucoderma with bare spots all over the scalp. Commenting upon the case, Bobovitch states that leucodermic spots were found all over the trunk and extremities. Syphilitic leucoderma should be differentiated from vitiligo. In vitiligo the spots are pigmented, as is the hair when the scalp is affected; they are but seldom surrounded with pigmented rings and do not disappear entirely, but rather tend to increase in size and depth of coloring. Tuberculous melanoderma sometimes simulates syphilitic leucoderma (cases of Fournier, Thibierge, Laurent, Vignolo-Lutati), but the former is found only in patients with tuberculous cachexia, while in the case reported here, the von Pirquet reaction was negative. Pigmentation in chlorosis and pregnancy also may simulate leucoderma. Sometimes pediculosis may cause pigmentation, but the presence of the pediculi is very easily demonstrated. The coincidental occurrence of alopecia and leucoderma was the most noticeable feature of the author's case. He agrees with Finger and Hoffmann that the spirochætæ are capable of destroying the pigment of the skin.

THE TREATMENT OF TABES, PARTICULARLY THE PAINS AND PARÆSTHESIA. Bogrov, p. 152.

Bogrov states that Hirsch obtained very successful results in the treatment of tabes and its complications. He gives intramuscular injections of 1 to 2 cc. of 1% of oxycyanide of mercury, plus sufficient acoin to make a 0.4% solution. The shooting pains and the paræsthesia disappear promptly. It is interesting, he notes, that he finds the same effect is obtained also in alcoholic neuritis and in nonspecific supraorbital neuralgia.

CLINICAL OBSERVATIONS OF 800 CASES OF ERYSIPELAS. Bogrov, p. 136.

Bogrov quotes Erdman's 800 cases of erysipelas that were treated with vaccines and phylacogens. The average duration of erysipelas of the face is 6 to 7 days, of the body 14 to 44 days, of the extremities, 10 to 88 days. The mortality in erysipelas of the face ranges from 5 to 38%, while in erysipelas of the body and other parts it runs as high as 50%. He treated 95 cases with vaccine and 20 with phylacogen, using at the same time external compresses of ice-cold solution of boracic acid, warm compresses of a solution of alum acetate and boracic acid and local applications of picric acid and ichthyol; none of the remedies had any influence on the course and outcome of the disease.

SYPHILIS OF THE PANCREAS. Walter and Sallis, p. 160.

Reviewing this article, Mescherski says that syphilis of the pancreas has been very little investigated. The authors claim that this form of indurative pancreatitis is usually met with in persons with hereditary syphilis and not so frequently in acquired syphilis. From the standpoint of pathological anatomy we must distinguish three forms of this affection: (1) inflammatory, sclero-indurative, usually leading to atrophy; (2) gummatous, in which the normal tissue of the gland is studded with gummata and (3) sclerotic gummatous.

The clinical features of syphilitic pancreatitis and its differential diagnosis are as yet obscure and should be more thoroughly investigated. From 15

observations made by different authors, Walter and Sallis could not come to any conclusion as to the real nature and cause of the disease. However, they found that syphilis of the pancreatic gland is found in both sexes; mostly in latent stages of syphilis. The symptoms are similar to those of other inflammations of the pancreas: the derangement of digestion, steatorrhœa, jaundice, emaciation, pain in the pancreatic region and swelling of the gland, steatorrhœa not often being present. Glycosuria is met with, while steatorrhœa, when present, usually appears in the later stages. Jaundice is found often and is an indication of syphilitic hepatitis or obstruction of the ducts. Fever is almost always present. Epigastric pain is frequent, often accompanied by radiating pain in the spine; sometimes there occurs hepatic pain, with radiating pain in the right shoulder. Often a hard swelling could be made out, irregular in shape, immovable and not well defined. The diagnosis is aided by the presence of other syphilitic symptoms.

AMERICAN JOURNAL OF THE MEDICAL SCIENCES.

(November, 1915, cl, No. 5.)

Abstracted by R. C. Jamieson, M.D.

LUETIC ARTHROPATHIES. W. H. Higgins, p. 733.

Luetic joint involvement is very frequent, according to reports quoted in this paper, 39% to 63% of congenital syphilitics having arthritis, 7% of children's joint diseases being luetic, one report giving 63 out of 100 cases. Two case reports are given, one of which had been diagnosed acute rheumatic fever. He classifies these arthropathies into (1), congenital syphilitic lesions, including osteochondritis syphilitica, simple synovial effusion and *arthropathie deformante*; (2), secondary syphilitic lesions, such as arthralgia, acute synovitis, hydrarthrosis, bursopathy of Verneuil; (3), late syphilitic lesions—bursopathy of Verneuil, *tumeurs blanches syphilitiques*, acute or chronic synovitis, gummatous osteo-arthritis, Charcot's joint.

The great difficulty lies in distinguishing the specific from the nonspecific joint affections.

THE LUETIN REACTION IN THE DIAGNOSIS OF TERTIARY AND LATENT SYPHILIS. F. M. Hanes, p. 703.

Hanes used this test in two hundred medical cases and believes it superior to the Wassermann in these late cases. He describes his technique and the appearance of the lesion in positive results. He emphasizes the importance of a delayed reaction which occurred in 3% of his cases, the typical lesion appearing in from one to three weeks following inoculation.

While he considers a positive reaction to be absolutely specific and a more delicate test in latent and tertiary syphilis than the Wassermann test, he does not put much faith in its use in the primary and secondary stages.

Visceral syphilitic lesions gave uniformly positive results, especially cases with cardiovascular lesions.

(*Ibidem*, December, 1915, cl, No. 6.)

CERTAIN SYPHILITIC AFFECTIONS OF THE HEART AND AORTA. J. M. Anders, p. 835.

The writer thinks that syphilis has been underestimated as a cause of

cardiac disease, especially as it may cause heart involvement in the early secondaries and it may be congenital.

Mesaorititis is due in many cases to lues, the spirochætæ being often found in the lesions which may appear to be miliary gummata. Aneurysm is most frequently luetic in origin, that type being usually at the ascending arch, and multiple. Lues causes a great deal of aortic incompetency, especially before the age of 45 and frequently produces a combined aortic and mitral lesion. Myocarditis may begin early, periarteritis being frequent, gummata infrequent.

He believes that cardiovascular disease will be lessened by a more vigorous and systematic treatment of lues, although many believe that cure is impossible if there is marked myocardial syphilis or aortic incompetency. Treatment should be extensive enough in the early and secondary stages to prevent this involvement, as salvarsan cannot be as freely used in myocardial degeneration with coronary lesions.

JOURNAL OF TROPICAL MEDICINE AND HYGIENE.

(Oct. 15, 1915, xviii, No. 20.)

Abstracted by R. C. Jamieson, M.D.

THE CAUSATION AND TREATMENT OF PELLAGRA. H. E. Bond, p. 229.

Bond advances the theory of alimentary toxæmia and the actinic rays of the sun as ætiological factors in pellagra. He reasons by analogy of the skin eruptions in disturbances of the gastrointestinal tract, such as acne vulgaris and rosacea, typhoid fever and pigmentations in toxæmias of gastrointestinal origin. He believes that the sympathetic nervous system is capable of exerting great influence, especially through the chromaffine cells and masses of chromaphile tissue, which tissue secretes a substance having a definite action on non-striped muscle fibre. Microscopically the nerve cells in pellagra resembles those seen in toxæmias.

He thinks that pellagra could be due to the absorption of toxines from the gastrointestinal tract, as the fæces of affected individuals contain abnormally large amounts of indol and skatol. He further states as possible that "it is evident that these toxines act on the sympathetic nervous system in the intestines, then on the chromaffine cells and tissue, which by their close connection with the central nervous system, produces the pigmentation called pellagra, with its resulting degeneration and neuritis."

He calls attention to the pigmentation resulting when the glands of internal secretion are affected and regards the actinic properties of the sun's rays as a causative factor in producing a hyperæmia and dermatitis in skins whose vitality is already lowered.

His treatment consists of disinfection of the gastrointestinal tract with calomel, beta-naphthol, acetozone and thyroid tablets; protective or stimulating applications, externally; ripe bananas daily with avoidance of salted fish; protection from the sun.

(*Ibidem*, May 1, 1915, xviii, No. 9.)

ATROPHODERMIA BIOTRIPTICA IN NATIVES IN THE ANGLO-EGYPTIAN SUDAN. A. J. Chalmers and C. M. Drew, p. 99.

Under this title the authors describe the conditions of atrophy of the skin

grouped under atrophodermia senilis. They state that this has been studied in Germany and England, Ceylon and the Sudan.

The condition appears to be a simple atrophy, influenced by several factors, especially old age. Elastic tissue did not seem to be atrophied disproportionately. Hyperpigmentation is associated with the dermal atrophy.

(*Ibidem*, Sept. 15, 1915, xviii, No. 18.)

NILE BOILS IN THE ANGLO-EGYPTIAN SUDAN. A. J. CHALMERS AND ALEX. MARSHALL, p. 205.

Organisms were isolated from three cases of Nile boils, vaccines of which quickly cured the boils. The same organism was found in all cases and is practically identical with the Aurococcus mollis, but differs slightly from the organism of pyosis Corletti.

One or two injections of from one to 500 millions will produce a cure.

JOURNAL OF LABORATORY AND CLINICAL MEDICINE.

(December, 1915, i, No. 3.)

Abstracted by OSCAR L. LEVIN, M.D.

GUMMA OF THE PITUITARY ASSOCIATED WITH LESIONS IN THE SPINAL CORD WHICH MAY REPRESENT EARLY LESIONS OF SYRINGOMYELIA. PAUL G. WOOLLEY, p. 155.

The patient, an adult syphilitic negro, had been ill for three weeks previous to admission to the hospital. He complained of sore throat, pain in the stomach and vomiting. There were no symptoms referable to the cerebrospinal system. No diagnosis was made. Exitus occurred one week after admission to the hospital.

A post-mortem examination of the organs revealed syphilitic lesions in the vascular system, the parenchymatous organs, a gumma of the pituitary body and an uncommon condition of the spinal cord. The changes in the cord consisted of hyperplasias of the cells of the central canal with scattered dilatations of the canal. These lesions probably indicated a beginning syringomyelia from a possible luetic cause.

(*Ibidem*, January, 1916, i, No. 4.)

THE GENERAL PATHOLOGY OF PELLAGRA; WITH SPECIAL REFERENCE TO FINDINGS IN THE THYROID AND ADRENALS. PLINN F. MORSE, p. 217.

The case reported occurred in a female, 38 years of age, in whom the cutaneous lesion appeared five months before death. The post-mortem macroscopic and microscopic examination of the organs revealed pathological changes which corresponded in general with those in cases of pellagra, previously reported by other authors and reviewed by Lavinder and Babcock, in their translation of Marie's book. A careful study of the thyroid and adrenals disclosed striking changes, hitherto undescribed. The former organ showed a chronic productive interstitial thyroiditis with compensatory reaction of the follicles. The picture

presented resembled the diffuse chemical irritant, rather than the focal manifestations of an infection. The adrenals presented a moderate atrophy of the medulla with great dilatation of the blood spaces and a round cell infiltration, localized especially about the blood vessels. There were practically no changes in the cortex. These findings lend support to the tendency to consider the psychoses, gastrointestinal disturbances and dermatoses as expressions of deranged adrenal and thyroid function, from toxic causes.

Lymphocytosis occurs in this disease as is found in hyperthyroidism.

ÆTIOLOGY AND LABORATORY DIAGNOSIS OF SMALLPOX AND CHICKENPOX. J. N. Force, p. 243.

Smallpox is caused by an organism which is filterable and usually occurring as a coccoid form, measuring from 0.2 to 0.5 micron in diameter. It occurs in the lesions of smallpox and vaccinia and when found in epithelial cells, it is enveloped in a substance derived from the nuclei. Attempts to separate it from bacteria accompanying it, in skin lesions, are accomplished with great difficulty and at the expense of its activity. It may be grown in pure culture, especially in media containing epithelial tissue. It may be inoculated in animals. The organism of chickenpox possesses the same characteristics as that of smallpox, but is not filterable.

There are cases in which a differential diagnosis between smallpox and chickenpox is difficult and when this occurs, a laboratory diagnosis may be of infinite value. A microscopic examination of the contents from a chickenpox vesicle may reveal large polynuclear leucocytes, which Tyzzer considers characteristic. A histological examination of the skin lesion may help, but it demands the service of a skilled pathologist. If the corner of a rabbit's eye be scarified and inoculated with the contents of a vesicle, an "air blister" will appear within 36 hours and enucleation and immersion of the eyeball in a mixture of mercuric chloride and alcohol, twelve hours later, will show white, necrotic, circular spots when smallpox material is used. The epithelial cells from the corneal ulcer may be examined for inclusion bodies. Persons suffering from smallpox, variola inoculata or vaccinia, when inoculated with smallpox serum, show allergic phenomena. Specific cutaneous allergy occurs also in chickenpox. No reaction will appear in the skin of a rabbit when inoculated with chickenpox material, but will manifest itself if the rabbit be vaccinated and then inoculated with smallpox material.

The author reviews the literature. A complete bibliography is appended.

NEW YORK STATE JOURNAL OF MEDICINE.

(January, 1916, xvi, No. 1.)

Abstracted by I. Rosen, M.D.

OBSERVATIONS UPON THE CURE OF SYPHILIS. Mathew A. Reasoner, p. 4.

The author studied the effects of the treatment of syphilis among the soldiers of the United States Army, and the percentage of cures obtained by various methods, and the serological findings in the various stages of the disease.

The conclusions were only tentative, as the series was rather small and the time short for more decisive observations.

SYPHILITIC DISEASE OF THE ARTERIES. ALEXANDER MCPHEDRAN, p. 10.

Syphilitic arteritis is almost always due to infection of the arterial wall, through the vasa vasorum, by the treponema pallidum. The arteries most commonly affected are the cerebral, aorta and the coronaries.

Arteritis of the cerebral vessels not only leads to partial closure of the artery, but also to loss of elasticity, and therefore, disturbance of equality of pressure may occur under varying circumstances, as shown by slight dizziness, a dazed mental state, momentary loss of certain functions, such as power of speech, temporary local paralysis of any part, etc.

GASTROINTESTINAL MANIFESTATIONS IN SYPHILIS. HENRY C. BUSWELL, p. 12.

The pathological findings show that syphilis of the gastrointestinal tract occurs most frequently in middle life, and in the early period of the infection (particularly in alcholics).

The following is the author's classification of this affection:

1. Catarrhal syphilis—due to congestion of vascular organs.
2. Hæmorrhages and hæmorrhagic erosions—due either to congestion or as manifestations of a general diathesis.
3. Ulcerations over an area of syphilitic endarteritis.
4. Ulcers due to necrosis of gummata.
5. Gummatous infiltration.
6. Cicatrices—due to fibrous transformation of gummata—*e.g.*, stricture of pylorus.
7. Hypertrophic thickening, either general or localized, of the stomach wall.

Under the heading of symptomatology, the author states that the mere fact that a patient is a syphilitic, and suffers from gastric distress or even hæmatameses, does not prove that the ulcer is of syphilitic origin.

BOSTON MEDICAL AND SURGICAL JOURNAL.

(Dec. 9, 1915, clxxii, No. 24.)

Abstracted by I. ROSEN, M.D.

NOTES OF A CONFERENCE ON THE MEDICAL AND SOCIAL ASPECTS OF SYPHILIS OF THE NERVOUS SYSTEM. ABNER POST, p. 867.

EXAMINATION AND PROPHYLAXIS FOR SYPHILITIC PATIENTS AND THEIR FAMILIES: METHODS OF INVESTIGATION AT THE PSYCHOPATHIC HOSPITAL, BOSTON, MASSACHUSETTS, 1915. HELEN M. WRIGHT, p. 869.

(*Ibidem*, Dec. 16, 1915, clxxiii, No. 25.)

THE BACTERIN TREATMENT OF CERTAIN CHRONIC PYOGENIC DERMATOSES. CHARLES C. DENNIE AND JOHN H. BUFFORD, p. 910.

The authors of this excellent paper selected seventy cases of chronic pyogenic dermatoses for their experiment, and while under the bacterin treatment, all external medication was strictly forbidden. Strict rules were given for the

hygienic care of their bodies, unsanitary conditions were remedied, the bodily functions regulated and a rigid diet prescribed.

Of the cases selected, 35 were acne vulgaris, 21 furunculosis and 14 folliculitis. In order to give the investigators a still broader scope by comparing the relative efficiency of autogenous and stock bacterins, the seventy cases were divided into two groups, one of which was to receive only autogenous, and the other stock preparations.

The administration of bacterins was goverened by the local reaction at the point of injection, such as redness, heat, slight œdema, and tenderness upon pressure, which appeared within four to twelve hours after administration, and sometimes remained as long as forty-eight hours. The initial dose was not less than one hundred million, and not over four hundred million killed organisms. The last injection was often two billion. The total number of doses rarely exceeded ten, and the interval between was from four to ten days.

Of the three pyogenic dermatoses, the best results were secured in furunculosis. In sycosis, the action of bacterins was very erratic; in one case of twenty years' duration, where external treatment was faithfully carried out for five years, and where stock bacterins had been administered, autogenous bacterins were used with remarkable success. On the other hand, two cases of sycosis were very much aggravated by this form of treatment.

ALOPECIA SYPHILITICA. Douglass W. Montgomery, p. 913.

The author, in a short paper, emphasizes the importance of differentiating syphilitic alopecia, from the spotted alopecia caused by pyogenic infection of the scalp, seborrhœic alopecia, alopecia áreata and pseudoalopecia of Brocq. It must also be appreciated that, although typical areolar syphilitic alopecia is as simple as a symptom can be, it is also almost as pathognomonic as a symptom can be; and that it may occur in a class of cases that may easily escape correct diagnosis, and therefore, remain untreated, with consequent increased danger of grave visceral syphilis supervening in later years.

A CASE OF DERMATITIS MEDICAMENTOSA. William S. Walsh, p. 924.

The author reports a case of a generalized papular, slightly scaly, intensely inflammatory eruption, occurring in a patient after a short course of vaginal douches with bichloride of mercury solution, 1 to 5000.

A CHEMICAL AID IN SECURING THE SPIROCHÆTA PALLIDA FROM SYPHILITIC LESIONS. Henry D. Lloyd, p. 925.

Alcohol applied to any ulcerated specific lesion, either primary or secondary, increased greatly the number of specimens of the spirochæta pallida, obtained from the serum. The author advises to clean the lesion carefully, using water or salt solution, and then wash with 95% alcohol. With slight lateral pressure a most abundant supply of serum, presumably from the deeper layers, is secured.

The results have been 95% positive in all primary and secondary lesions, whereas before this method was employed, the percentage was between 60 and 70.

NEW YORK MEDICAL JOURNAL.

(Jan. 22, 1915, ciii, No. 4.)

Abstracted by JAMES F. GRATTAN, M.D.

DERMATITIS FACTICIA. HENRY KENNEDY GASKILL, p. 148.

Feigned eruption is an entity in that the lesions differ from any recognized dermatological disease. The isolated grouping, odd contours, at times linear in arrangement, at times with lines crossing, even at right angles, marked irregularity, often serpiginous outlines with sharp corners and jagged edges, are all characteristics essentially different from those of any known eruption, and serve to identify the condition.

The usual underlying basis is an unstable nervous makeup, especially in those of a pronounced emotional nature, or in those craving sympathy. Occasionally found in the opposite type—the lazy or lethargic—who produce the lesions to avoid the possibility of obtaining work; or in children who desire some excuse to remain away from school. Found at times of life accompanied by psychic disturbances, as the menopause or puberty. Sixty-five per cent. of cases occur in females. Male cases usually occur in adolescence, female during the child-bearing period. Patients are usually very clever in devising means of producing lesions, and equally in avoiding detection. They manage to find some irritant taht will accomplish the desired effect and use all their ingenuity to conceal this material and its use. Associated stigmata of hysteria are often found. Some produce the lesions unconsciously while awake and others while in the hypnotic state. The latter cases are very hard to detect. The author quotes Pernet as believing that some patients possess a dual personality and produce the lesions during a psychic state of which they have no recollection when questioned. Gaskill denies this and claims that the inflictions are performed wilfully and deliberately for a definite reason, usually known only to the patient. Another type is the purely emotional, the unconscious picker, who usually is of sedentary habits, allows the escape of his superfluous nervous energy through some habitual act of which he is scarcely aware until the mirror or some person calls his attention to the lesions so produced.

Errors in diagnosis are referable to gangræne or trophic disturbances, which, in some fairly definite cases, has determined amputation; and recurrence of the old lesions in the stump, treated and cured by occlusion dressings, has proven the mistake. The treatment in these cases is a starch or silicate of sodium dressing, except where moisture demands drainage of the lesion.

The disease is probably becoming more common because of the more strenuous living conditions with their effects on the nervous system.

The author has seen twenty-two cases in six years. He cites five cases in which the causes were respectively, (1) desire to produce grounds for divorce on the basis of syphilitic infections from husband; (2) laziness—eruption did away with the necessity of looking for work; (3) discovery that bichloride of mercury tablets was a convenient irritant—desire for sympathy; (4) self-infliction in nervous type without statable cause; (5) desire to avoid attendance at school.

PROBLEMS OF SYPHILITIC RE-INFECTIONS. M. B. PAROUNAGIAN, p. 153.

The author does not believe that true cases of re-infection are as common as is usually supposed. Errors in reporting are due to enthusiasm over symp-

tomatic cures brought about by salvarsan. Sterilization of the primary lesion after salvarsan is not a cure—a cure means complete destruction of the spirochætæ in the entire host. If re-infection is the test, cases have been reported after mercury alone as well as after salvarsan. According to Benario's postulates, a case of re-infection must show: (1) clinical primary sore; (2) spirochætæ in lesion; (3) enlargement of adjacent glands; (4) positive Wassermann; (5) source of infection must be proven.

The author believes that these postulates are too rigorous because cases are recorded where the Wassermann was positive and re-infection occurred. He claims that for practical purposes re-infection may occur, (1) after a course of salvarsan and mercury; (2) a new primary lesion at a different site; (3) infection during symptomless period. If such re-infections do occur, for all practical therapeutic purposes we are dealing with a new case of syphilis, requiring all the care and precautions as at the time of the first infection.

Among other interesting cases the author reviews a case that came under his own observation and brings out, (1) first primary lesion, February, 1914, on left lateral aspect of the scrotum; spirochætæ found; (2) primary lesion at the meatus urinarius, about Mar. 8, 1914. Mar. 12, Wassermann doubtful, but spirochætæ found in new lesion; (3) maculo-papular eruption and adenopathy on Mar. 26, 1914. Wassermann strongly positive. Treatment, one dose of salvarsan (0.4 gram) and twelve doses of mercury salicylate, between March 17th and May 18th (weekly intervals) followed by three weeks of iodide of potassium. Aug. 19, 1914, Wassermann negative; (4) third primary lesion, Dec. 29, 1914, on pubic region. Ammoniated mercury applied to the lesion. Two days later, search for spirochætæ negative (use of ointment) and Wassermann negative. Because of this some dermatologists refused to admit re-infection. (5) Feb. 20, 1915, roseola; (6) Mar. 11, 1915, two Wassermanns (different laboratories) returned positive. All the lesions were typical indurated lesions and not the soft lesion of autoinoculation and the interval between their appearance was over three weeks. These were not superinfections because all were primary sores and not the lesion of the period in which they occurred.

Fournier's postulate, that "re-infection does not occur until a period of years has elapsed," no longer holds with the newer and rapid methods of sterilization of the host with salvarsan and mercury. The photographs in connection with this case and the general text make the original article well worth referring to.

MEDICAL RECORD.

(Jan. 22, 1916, lxxxix, No. 4.)

Abstracted by James F. Grattan, M.D.

RADIUM. C. Everett Field, p. 135.

By way of introduction, theories of causation and methods of treatment of cardio-vascular hypertrophy and hypertension are discussed. The author reviews von Noorden on the effect of radio-active substances upon biologic processes and refers to the emanation accompanying liberation of the alpha rays as "fluid electricity," permeating the body through the blood stream. He mentions the works of Gudzent, His, Deutelmoser, Klemperer, Falta, and von Neusser as substantiating the effects of radium on metabolic activities, such as the increase in the red and white blood cells, diminution in the viscosity of the blood, increase in the solubility and elimination of uric acid, improvement

in digestive and diuretic processes and in respiration. The author reverts to the subject of hypertension, passing over the old theories (mechanical, and suprarenal hyperplasia) and regards the basis of the change as being of toxic origin.

His review of hypertension cases treated with radium, shows that there is noticeable symptomatic improvement of more or less marked degree, in 95% of his cases. Emanations of radium, he claims, increase cardiac energy and tonicity of the arterial muscle, while at the same time they reduce peripheral circulatory resistance and the viscosity of the blood. He assumes, (1) that all these effects are due to the influence of emanations of radium on ferment actions; (2) that metabolic processes may be improved if recognized early and this treatment holds out a hope of permanent cure; (3) that the development of nephritis can be prevented by checking hypertension; (4) that advanced cardiac and nephritic changes can be held in check; (5) that cases of broken compensation can be sustained in comfort and improved in symptoms.

For methods of administration the reader is referred to the original article.

DURATION OF SMALLPOX IMMUNITY AFTER SUCCESSFUL VACCINATION. W. H. Park, p. 155.

Fourteen to twenty-eight per cent. of cases investigated can be revaccinated in one year, fifty per cent. at the end of five years, eighty to eighty-nine per cent. at the end of ten years. Ninety-nine per cent. of persons can be vaccinated with a vaccine of high potency.

The United States Public Health Service reports that, of 6312 cases in three years, ending June, 1915, only seventy-nine had been vaccinated within seven years, 3386 more than seven years before; and 2839 had never been vaccinated.

The shortest period of immunity in the experience of the New York Department of Health is nine months. Dr. Parks recommends revaccination every five years, if cases of smallpox have occurred in the community.

Plate XXIX.—Photograph of the late James C. White.

James C. White

OBITUARY.

JAMES CLARKE WHITE, M.D.

An American Pioneer in Dermatology.

Of the pioneers in dermatology as a specialty in America, very few are now alive. The American Dermatological Association, the oldest national organization of its kind in the world, was formed in 1876, and chose for its first president one of the leaders of these pioneers, Dr. James Clarke White, the subject of this sketch. With Dr. White's death, which has recently occurred in his eighty-third year, there passes from the scene an eminent figure; a character respected by all, and beloved by not a few.

Dr. White was born in Belfast, Maine, on July 7th, 1833, the fifth of seven children. His father, the Honorable James Pattison White, descended from an English captain, wounded at the defence of Londonderry, Ireland, in 1688-89, was a successful business man of Belfast, serving as mayor, and as State senator during the exciting times of the Civil War. Fortunately for a proper appreciation of the achievements and varied interests of Dr. White's life, he published, in 1914, an autobiographical volume entitled, "Sketches from My Life." From this book, delightfully written and privately circulated among his friends, many of the facts embodied in this article have been taken, and a number of quotations made. It begins with a charming picture of a New England boyhood, from the year 1833 to 1850, passed in a quiet town in Maine, among picturesque surroundings, and in a cultivated community. His description of this life, written in his later years, illustrates the love of nature and keen powers of observation that he always retained.

As the academy in his native town had been burned, it was impossible for him to obtain an adequate preparation for college, and his later school education had to be picked up at the hands of clergymen and old college graduates at his own home. At the age of sixteen he entered Harvard College, where he kept a diary, extracts from which he published in the Harvard Graduates' Magazine, in 1913. This diary gives an admirable idea of student life and customs in the Cambridge of those days, as well as of the college requirements. White was a voracious reader, especially of natural history and of fiction, spending much time in the college library, where, greatly to his advantage, he made friends with the librarian. His taste for natural history is indicated by the remark in the preface to his diary, that he has omitted much that is of merely personal interest, such as his notes of "where and when all the rare wild flowers in Cambridge blossomed, to be sought there in vain to-day; the birds shot and stuffed for our Natural History Society, some of which would be rare visitants to the present city of Cambridge."

In September, 1853, at the age of twenty, he entered the Tremont Medical School in Boston, which had a semi-official connection with Harvard College through its teachers, who were mostly professors in the Medical Department of the University. The functions of this School were usually suspended when the lecture courses of the Medical Department of the College began, which lasted from three to four months. The diary, begun during his undergraduate days, was continued throughout his medical course, and is of much interest. He served a term as house pupil at the Massachusetts General Hospital, and received his degree of M.D. in 1855.

At this time the influence of German scientific thought was just beginning to make itself felt, and Dr. White decided to make Vienna his first and chief place of study in the European course he was planning. Again the diary,—

extracts from which describe his voyage across the Atlantic, his impressions of the people, customs, and scenes of the Old World. Of especial interest and charm is his description of his life in Vienna, both from the social and educational side. He sat under Oppolzer, Sigmund and Hebra, the last of whom was then one of the chief attractions of the Vienna school, and to whom he pays a high tribute.

In 1857, Dr. White began the practice of medicine in Boston. Although he had paid especial attention to the study of diseases of the skin in Vienna, it was because he considered that he had more to learn in this than in many other branches, and because the opportunity for their study was so pre-eminent, rather than from any fixed intention of specializing in them. Nor did he consider it wise to announce himself as a specialist at so early a period in his career. He seems, however, to have begun almost immediately to be to some extent identified with dermatology. But his first acquaintance with medical teaching was as instructor in chemistry in the Harvard Medical School in 1858, from which position he was promoted to be adjunct professor of chemistry in 1866, lecturing on physiological, toxicological and clinical chemistry. This position brought him much medico-legal work, as he made the examinations for the Government in all capital cases, and this work he continued until 1871. Meanwhile, in 1863, a course of University lectures, so-called, had been instituted in the Harvard Medical School, and Dr. Oliver Wendell Holmes and Dr. White were the first lecturers appointed. Dr. White gave a course of six lectures on diseases of the skin, the first recognized instruction in that subject that the Medical School had ever offered. In 1871, after declining an advanced position as teacher of chemistry, he was appointed professor of dermatology, the first chair in this specialty to be established in this country. Meanwhile a department for skin diseases had been instituted at the Massachusetts General Hospital, of which Dr. White had charge for thirty-three years. At this time his private practice had become largely dermatological, and was soon devoted exclusively to this subject.

The professorship of dermatology was held from 1871 until 1902, when this chair, and also the hospital position, was resigned, and he was made professor of dermatology, emeritus. During all these years his punctuality and systematic attendance were almost phenomenal. It was a saying of a long-time janitor of the Medical School that in thirty years Dr. White had been known to miss but two of his scheduled exercises: once when he was married, and once when he attended his father's funeral. His instruction was deliberate, precise and dignified. He pursued to the end of his teaching career the method of a series of didactic lectures touching upon all the diseases of the skin, followed each time by a clinical lecture illustrating as far as possible the subjects treated in the preceding didactic lecture. During this period his constant personal attendance to the duties of treating out-patients for diseases of the skin at the Massachusetts General Hospital, was building up a clinic of great size, and of much variety in its assortment of dermatoses. This material, being available for teaching, strengthened greatly, year by year, the opportunities of the university professor.

Apart from his instruction to successive medical classes, comprising nearly two generations of students, Dr. White was a powerful factor in shaping the policy of advanced general instruction in the Harvard Medical School; and it may be truly said that this work was as useful as anything that he accomplished in his own peculiar field. Those who knew him well concede that this matter lay very near his heart, and this is further attested by the long chapter on Reform in Medical Education that he has embodied in his "Sketches from My Life," as well as the prominence that he has given to this subject in many of his various addresses. Early in 1868 he published two editorials in

the *Boston Medical and Surgical Journal* on "Election in Harvard University," "Medical Education," and "Censorial Duties—Medical Education." These articles, advocating most obvious reforms and principles now long since established, "were regarded as rank heresy by many members of the faculty and of the profession," and soon after, in 1870, in the introductory address at the opening of the winter course of lectures, Dr. White enlarged on the same topics in no equivocal manner. This address stimulated the reformers, and was followed by lively and heated discussions in the faculty, and by conflicting opinions from the governing boards of the University. Party spirit ran high, and all who have known the subject of this sketch will readily believe that his own part was vigorously and uncompromisingly played. It is needless to say that the plan of the reformers was finally adopted, and White remarks that "those who opposed it most bitterly came in time to recognize fully its merits and successful results—even to claim credit for it."

Further reforms, many of which have since been instituted, were advocated in the annual discourse delivered before the Massachusetts Medical Society in June, 1890, entitled "A Plea for Professional Independence," and in an address at the dinner of the Harvard Medical School Alumni Association, in 1892.

Allusion has already been made to Dr. White's interest in natural history while a boy in college. In 1856 he joined the Boston Society of Natural History, and was Curator of Comparative Anatomy from 1858 to 1868. During the earlier years of his professional life he spent much time in this pursuit, arranging several collections for the Society, and taking a prominent part in all its doings. An extensive menagerie on Court Street, in Boston, having perished in a fire, he secured the bodies of all the animals on condition that he would make a chemical examination of them, as the owner suspected that they had been maliciously poisoned. No poison was found, but the mounted skeletons proved a valuable addition to the Natural History Society's collection. He spent many of his leisure hours in botanical expeditions, visiting the country about Boston and other parts of New England in search of interesting specimens to add to his herbarium; and in his later years he took much pleasure in attempting to transplant rare species collected in the Maine woods, to his beautiful summer place at Islesborough.

Many local honors, apart from the recognition of his dermatological colleagues, were naturally accorded to Dr. White. He was, successively, anniversary chairman, orator, and president of the Massachusetts Medical Society; a member of the American Academy of Arts and Sciences, from 1866, and of the Boston Society of Natural History. Of his dermatological offices, it is remembered that he was the first president of the American Dermatological Association, and again held that office in 1897, at its twenty-first annual meeting. It was his well-deserved honor to be chosen president of the Sixth International Dermatological Congress, held in New York, in September, 1907, the first of these congresses to be held in America, and fitly presided over by the first dermatologist of the New World. His presidential address on that occasion was progressive in its suggestions and aspirations, and was expressed with a literary precision that is fast disappearing in our modern discourses. He was a corresponding member of the French and Argentine Dermatological Societies, and honorary member of the Dermatological Societies of Italy, London, Vienna, Berlin and New York.

In the course of his long professional career, Dr. White wrote many articles of interest and value. Of greatest importance, perhaps, was his book on "Dermatitis Venenata," published in 1887, which, as he said, "filled a gap in dermatological literature." The value of this book is much added to by Dr. White's special knowledge of botany and chemistry. It opened up at once a

new field of thought, and has contributed greatly to a recognition of the important part played by the plant world in cutaneous affections. It may to-day be looked upon as a classic. As an illustration of his capacity for seeing the light among the first, his early studies of the question of leprosy may be cited. In 1882, at a meeting of the American Dermatological Association, he read a paper on the "Question of Contagion in Leprosy," giving an account of the disease as it then existed in this country. In the discussion, only one member present shared his belief in its infectious nature. Thereafter several successive papers, up to 1908, reflected his advanced views on this subject, urging measures of prevention and control. He wrote on a great variety of dermatological subjects, and added much to our knowledge of many of the rarer dermatoses, such as keratosis follicularis, angioma serpiginosum, hydroa vacciniforme, etc. He contributed eight books and chapters, one hundred and twenty-five medical papers, ninety-four editorials, fifty reviews, twenty-two papers on natural history, besides miscellaneous addresses and communications.

Dr. White's last illness began nearly a year before his death. He was enabled, however, to obtain much that was agreeable from life during his last year, owing, in great measure, to his courage and serenity. He died in Boston, on January 5, 1916. Dr. White's wife died in 1888. He is survived by two sons, McDonald E. White and Dr. Charles J. White, the well-known dermatologist.

The influence of the pioneers in dermatology must not be underestimated, and foremost among them stands the figure of James Clarke White. Beginning at a time when specialties were unrecognized and repudiated, or at most grudgingly acknowledged, he devoted himself to the task of showing that progress and the best results are to be obtained by concentration of energy and purpose along well-defined lines. This course required courage and pertinacity, with both of which qualities he was highly endowed. If the path of the specialist seems easy and natural nowadays, it must be remembered that those who mapped it out lived under far different conditions. The prejudices that had to be encountered are more than once touched upon by Dr. White in his reminiscences. But he was by nature truthful, fearless, and, like all strong characters, confident of himself and of his cause, and ready to defend it before any tribunal. These very qualities, which exposed him, perhaps, to the occasional criticism of being dogmatic or controversial, were of inestimable value to the causes for which he labored. His influence at the meetings of the American Dermatological Association was always exerted in the direction of high progress, and his dignified example will be remembered with approbation by all his colleagues, even by those who were sometimes inclined to resent his uncompromising adhesion to his principles.

Dr. White possessed a broad, keen mind, capable of interesting itself in many aspects of life, and for this reason his society was always stimulating and welcome. Apart from his knowledge of natural history, that has been alluded to more than once, he was a great reader of general literature, to an extent surprising in one whose regular occupation consumed so many hours. But he was a man of great system and method, and would have surely made his mark in any career that he might have chosen. During the latter part of his life he passed a portion of each year at his seashore house at Islesborough, Maine, where he took great pleasure in entertaining his friends, and was much sought out and appreciated by all the summer residents. His life was a very complete, useful, and happy one. He was favored with strong health up to his last illness, and enjoyed, in his later years, the consciousness of a work well done, and an accomplishment such as he had always hoped for.

J. T. B.

THE JOURNAL OF
CUTANEOUS DISEASES

Vol. XXXIV. MAY, 1916 No. 5

ORIGINAL COMMUNICATIONS.

CLINICAL AND EXPERIMENTAL OBSERVATIONS ON A CASE OF PITYRIASIS LICHENOIDES CHRONICA (JULIUSBERG).

By John H. Stokes, A.B., M.D., Chicago.

Instructor in Dermatology, University of Illinois, Chicago.

The case of pityriasis lichenoides chronica here presented is reported for three reasons. It represents a florid type which even a careful observer may, on objective examination, mistake for a papulo-squamous and pigmentary syphilide. The case was under observation for a considerable time, during which interesting clinical changes occurred, having a possible connection with therapeutic and experimental procedures. In the third place, the case forms the starting point of a series of experiments in intradermal sensitization reactions which would seem to suggest a new basis for the interpretation of familiar tests such as the luetin (Noguchi), pallidin (Klausner), placentin (Engelhorn and Wintz), etc.

The numerous and elaborate clinical and pathological studies of parakeratosis variegata carried out by Brocq, Unna, Pollitzer and Santi, Juliusberg, Colcott Fox and MacLeod, Riecke, Trimble, J. C. White and C. J. White, Corlett and Schultz, Arndt, Sutton, Klausner, Csillag, Werther, Willy Cohn and others, make it unnecessary to review the general features of the condition, or of the guttate variety of the larger group, to which a number of these authors have given detailed consideration. The following is presented as a résumé of the present case.

Case Report.

Laborer, aged 34, married, of negative family and past history. There was a moderate use of alcohol up to three years ago. He discontinued it for a year at the onset of the present trouble, then resuming it in moderation. He avoids meats, finding they disagree with him. There is no history of gonorrhœa or syphilis, although exposure is admitted.

Present Trouble. The eruption began three years ago as small red spots on the neck, suggesting mosquito bites. It became general in a month, lesions coming and going but the condition as a whole, remaining stationary. There were no subjective symptoms. He was treated for syphilis, salivated with pills, and received one intramuscular and two intravenous injections of salvarsan. There was very slight transient improvement. More pills were taken, without effect. He came under the care of Dr. Wm. Allen Pusey, to whose courtesy the writer is indebted for the opportunity to make the present study.

Physical Examination. Practically negative, apart from his skin condition.

Laboratory Examinations. Indicanuria was the only positive finding. The Wassermann reaction, with five antigens, was repeatedly negative.

Dermatological Examination. A rather florid papulo-squamous general eruption, only the scalp, palms and soles being entirely free. The face is somewhat involved. The following types of lesions in all stages of evolution and involution were noted: (1) fleshy, erythematous papules, pinhead to split pea size; (2) larger plaques, a centimeter or two in diameter; (3) occasional annular or reniform papules on the trunk; (4) oval, brownish or yellowish, waxy papules with a scarcely appreciable elevation and an adherent, invisible scale, apparent only on light curettage; (5) striking hyperpigmentation from fawn yellow to a dirty brown, about the periphery of some active lesions and at the sites of involuted lesions; (6) reteform erythemato-squamous patches over the scapulæ and here and there on the extensor surfaces. No gyrate or serpiginous figures. The more recent lesions were often bright red and urticarial in appearance, older lesions dull, dusky purplish or brownish red in color. Mucous membranes were negative.

Histopathology. Material from a typical rose-red, fleshy papule on the neck. The findings topically were as follows.

(1) Nucleated stratum corneum, with an unusual degree of adherence of the horn cells to one another, forming lamellæ.

(2) Stratum lucidum absent.

(3) Stratum granulosum imperfect, absent in places. Point at which these two strata disappear is visible in one of the sections. The stratum lucidum swells and becomes granular and is then replaced by nucleated horn cells.

(4) Rete Malpighii, cells large, layers fewer than normal in some places, increased in number in others. Cells swollen, nuclei distorted, pale and bladder-like or crowded into crescents by the intracellular œdema.

(5) An extraordinary infiltration of small round cells into the epidermis, involving the lower layers of the rete Malpighii.

(6) Integrity of the basal layer of the rete Malpighii largely destroyed by a combination of cellular infiltrate with extra and intracellular œdema.

(7) Distortion of the rete pegs by œdema of the corium and papillary bodies, with infiltration.

(8) Formation of a mesh-work due to œdema, separating epidermis and cutis in places by a chain of vacuolated spaces.

(9) Intense vascular and lymphatic dilatation. In the papillæ, the capillary dilatation is accompanied largely by œdema, but in the subpapillary rete and the deeper parts of the corium, a marked perivascular infiltrate of round cells

makes the vessels stand out conspicuously. Fibroblastic proliferation in this exudate and the surrounding connective tissue shows the process to be a true perivasculitis. The endothelium, however, is apparently normal.

(10) A moderate infiltration of the œdematous network of the upper corium with round cells has occurred, with young connective tissue cells and occasional mast cells. No plasma cells found.

(11) Crowding aside and possibly some diminution in the amount of elastica in the upper corium and papillæ.

Discussion.

Clinically speaking, while certain of the lesions approached the psoriatic type, the resemblance to psoriasis on the whole, was not as marked as that to syphilis. The importance of the latter element is attested by the impressions of several dermatologists who have seen the case. Through the courtesy of Professor Udo J. Wile, the writer had the opportunity, on another occasion, to see the same differentiation become a matter of importance in a syphilitic, who, while under treatment, developed the Juliusberg type of parakeratosis variegata. The patient in the present case had been subjected to vigorous antisyphilitic treatment.

The objective elements in the eruption which were of special value in distinguishing the two conditions were (1) the presence on some parts of the body of the reteform variety of lesion, as over the scapulæ and extensor surfaces, and (2) the waxy type of papule, almost flush with the skin, and covered with a lamellar or closely adherent invisible scale, which became at once strikingly apparent on a light stroke with a curette.

Even with the preponderance of florid, clear red and brownish red papules, a few of these peculiar waxy lesions were always demonstrable, especially over the upper abdomen and flanks and along the lower border of the pectoral muscles. A typical capillary hæmorrhage could not be obtained.

In addition to the clinical differentiation, lymph from papules in the present case was examined by dark-field for spirochætæ, with negative results, and the Wassermann reaction was found to be repeatedly negative. The failure to respond to treatment which would have disposed of a papular syphilide, was a corroborative though not essential aid to the diagnosis.

The histopathological changes conform in all essential particulars to those established by the authors mentioned, for pityriasis lichenoides chronica, and in fact for the parakeratosis variegata group as a whole, in which a decided uniformity of pathological findings seems to be the

rule. Arndt,[1] however, in 1909, expressed the belief that the Brocq type (*en plaque*) and the Juliusberg type were not related. On the other hand, recent studies seem to establish the essential pathological and clinical unity of the group. Werther has described a case exhibiting all the types of lesions characteristic of parakeratosis variegata in the same patient. Klausner[2] believes them related. The microscopic differentiation from psoriasis, in the opinion of Corlett and Schultz,[3] depends upon the much greater œdema, the marked epidermal degeneration and infiltration, and the involvement of the deeper vessels. The writer's own material supports this view of the essential changes. The epidermal involvement parallels, for example, that in Unna, Pollitzer and Santi's[4] descriptions, and those of Juliusberg,[5] and Corlett and Schultz's *lesion C*. The basal layer is, however, somewhat more disorganized by the intense œdema in the writer's case. The changes in the corium are those of Corlett and Schultz's *lesion B*. Vascular changes in the writer's sections were well marked, so far as the dense collar of round cell infiltration with fibroblastic proliferation about the deeper vessels and other signs of periphlebitis were concerned. No definite endarteritis as described by White[6] and Corlett and Schultz could be recognized with assurance. There were no changes suggestive of a tuberculoid architecture, such as have been reported by Civatte, Milian and Pinard. Corlett and Schultz give the vascular changes preëminence in the lesions they studied. The present case, while exhibiting vascular changes, hardly seemed to justify definite conclusions on this matter. It seems not improbable that the œdema and nutritional disturbances in the epidermis might have had their origin in vascular injury.

Clinical Observations.

During the early weeks of an eight months' period of observation, the patient underwent a remarkable improvement without the institution of any significant local measures. Remissions in the course of this notoriously obstinate affection are specially mentioned by Ormsby, Klausner and Pinkus, their occurrence being especially likely during the summer months. Klausner,[2] in particular, believed sunlight to be instrumental in affecting the change. This was hardly a significant factor in the writer's case, since his patient underwent improvement in spite of the fact that he was employed at night-janitor work and slept through the larger part of the day. The improvement in the present case began late in March, and with the exception of an exacerbation which was cleared up by a severe chrysarobin dermatitis, has continued

now, well into December. Cohn[7] used salvarsan and Ringer's solution on his cases, without effect, an experience confirmed in the present case. It had been the writer's intention to employ autogenous serum. The onset of the patient's improvement, however, seemed so exactly coincident with the drawing of about 175 cc. of blood for experimental purposes, that it was decided to test the effect of venesection alone. The patient was bled at the outset, four times at weekly intervals, in amounts varying from 25 cc. to 150 cc., with a total of 320 cc. As a placebo, salt solution was twice injected under the scapulæ, and the patient given rose ointment for the backs of his hands.

A really extraordinary change took place in the eruption during this time. All but a very few scattered lesions disappeared entirely, and the hyperpigmentation began to fade. For the remaining lesions, 5% chrysarobin ointment was employed, with little effect, during a period of forty days after the last bleeding. The local application was then stopped, and the patient, who had exhibited no signs of reaction to the drug, was bled 140 cc. A group of conspicuous plaques still remaining on the trunk, abruptly subsided, becoming flat and losing their erythema by the third day, and disappearing by the sixth, leaving depigmented spots. This represented the high point of the patient's improvement, and was a really impressive change.

Lesions now began slowly to reappear. Although no dietetic régime had been followed, the patient had been abstaining from beer. In order to test its influence, the patient was told to drink two glasses a day for two weeks, and was bled 150 cc. at one sitting. Neither the beer ration nor the bleeding seemed markedly to influence the condition, unless indeed the one compensated for the other.

Autogenous serum was now begun, injections administered one week apart, using a technique which previous experience had shown to be satisfactory in cases of psoriasis. The blood was drawn, allowed to clot at room temperature, centrifuged at 3,000 revolutions, and the serum injected intramuscularly within an hour after the blood was drawn.

Blood Drawn.	Serum Injected.	Local Measures.	Result.
156 cc.	70 cc.	None	None
168 cc.	70 cc.	Chrysarobin 2%	Worse
144 cc.	65 cc.	" "	Lighted up again

The first injection was without effect. After the second, the patient was unquestionably distinctly worse. A crop of new lesions appeared about the waist and on the wrists, scapulæ, trunk and legs, almost over

night. Urticarial lesions, excoriated by scratching, had developed on the buttocks. There was local pain and tenderness at the sites of injection, and stiffness of the legs with general malaise. Deep and superficial infiltrations were palpable in the buttocks. The patient was with difficulty persuaded to take a third injection. No local or systemic reaction followed, but again an apparent lighting up of the lesions, which became more elevated and in places almost urticarial. The patient declined to give the treatment a further trial.

Venesection was now resumed. The withdrawal of 260 cc. in two weeks was without appreciable effect on the lesions present, which were accurately kept track of, on a chart.

In the course of the experimental work, the patient was given at this time, 45 grains of potassium iodide a day, in the effort to light up the sites of intradermal injections. Gastrointestinal intolerance of the drug was marked, and it could be administered only for a week. During this time there was a rapid and unmistakable increase in the number of active lesions, and the drug was stopped just as a rather severe exacerbation developed, the patient's face becoming studded with papules, and a collarette of florid lesions appearing about the neck and shoulders. In view of the fact that the results of this exacerbation were subsequently cleared up by a chrysarobin dermatitis, and that the patient has since remained relatively clear, the instrumentality of the iodide in provoking an outbreak is certainly suggested. As soon as the drug was stopped, the patient was bled 145 cc., and four days later 155 cc., without appreciable improvement within the week.

The patient was now placed on 10% chrysarobin and on the second day after it was begun, had a well-developed dermatitis, which, to the surprise of those who observed the case with the writer, cleared up the recently developed lesions, especially about the neck and shoulders, with gratifying promptness. Those on the face slowly subsided without local measures, and the patient has returned to a condition of comparative freedom from the eruption. The occasional lesions which appear and disappear, seem relatively little affected by the local use of chrysarobin, and the continuance of venesection at intervals of two or three weeks has not produced any definitely recognizable effect.

Experimental Studies.

The experimental studies begun on this case were extended to cover a larger field, and will be reported in detail with a discussion of their significance, in the *Journal of Infectious Diseases.*[13] Summarizing briefly the application to the present case, it was found to be impossible

to demonstrate any interaction between emulsions of the patient's lesions and his serum, in suitably prepared guinea pigs. It was found possible, however, to elicit in the patient himself, by intradermal injection of emulsion of his own or of psoriatic lesions, a reaction resembling a papular luetin reaction, which did not occur, on the injection of an emulsion of normal skin. Sellei,[8] who believed himself to have obtained distinctive allergic reactions on employing a similar procedure in psoriatics, published the results as presumptive evidence of a specific allergic condition in psoriasis. The writer's subsequent experiments, however, led him to place a different interpretation upon such findings, and in fact, to call in question the absolute specificity of several well-known cutaneous tests. Viewed from the conventional conception of the mechanism of allergic reactions, the result obtained in the present case might be regarded as evidence of the basic identity of psoriasis and parapsoriasis. It will be recalled that Brocq believed both conditions to be related expressions of a simple cutaneous reaction. When, however, the recently developed physical theory of the mechanism of anaphylactic phenomena is applied to the interpretation of the present result, it seems reasonable to regard it simply as a local adsorption phenomenon, the result of the action of an antiferment adsorbent. The reaction thus might occur as a result of the uncovering of proteolytic enzymes in serum or tissues, or a disturbance of the normal colloid equilibrium of the body at the site of injection. For the fuller consideration of this point of view and its applicability to other intradermal reactions, reference must be had to the more detailed studies mentioned above.

Summary.

It is apparent from the foregoing account that the differentiation of the guttate form of parapsoriasis and a papular syphiloderm may become a matter of importance and some difficulty. Salvarsan and mercury, administered to the present case under a mistaken diagnosis, had no beneficial effect. It is impossible to decide whether the apparent benefit from venesection was merely *post hoc* in the course of a spontaneous remission, or of actual therapeutic value. Since the patient had never had a remission, and the improvement on the present occasion, was undoubted and striking it might be of interest to give the procedure a further trial. The probabilities impress the writer as in favor of coincidence. Autogenous serum scarcely had a fair trial, but seemed, if anything, to have an undesirable influence. The ease with which a chrysarobin dermatitis was excited, and its prompt effect in a condition notably resistant to such treatment, at least suggest that the patient

had been temporarily rendered more sensitive to the action of the drug, or to the effects of a dermatitis.

The influence of potassium iodide in apparently provoking an outbreak in the course of a remission is problematical, but seemed at the time very direct. All these observations, taken together, suggest a certain instability or liability of the organism at the time the patient was under observation and underwent improvement. Comparatively trivial incidents seemed able to swing the balance one way or another. The effect of the iodide, at least, seems suggestive of certain elements which may underlie the pathogenesis of the disease and the mechanism of its therapeusis. Jobling and Petersen[10] have demonstrated the effect of iodides in lowering the antitryptic titre of the serum of patients receiving it. Supposing for the moment that it had such an effect in the present case, followed by an exacerbation, the relation of ferment-antiferment balance to the pathological mechanism of this disease would merit study. Observations such as those of Luithlen[11] on the effect of colloids in rendering the skin susceptible to agents giving rise to dermatitis, the effect of horse serum in psoriasis, as discussed in a recent meeting of the American Dermatological Association,[12] the still disputed influence of autogenous serum in such cases as dermatitis herpetiformis and psoriasis, the finding of a nitrogen retention in psoriasis (Schamberg and collaborators), constitute a group of as yet unconnected facts which may foreshadow a new conception of the rôle of the physical chemistry of colloid equilibrium, in the ætiology and pathogenesis of obscure cutaneous conditions which have thus far resisted the familiar "infectious" and "atropho-neurotic" lines of investigation. It is no small part of the interest of such a single case as the present one, that prolonged observation of it is able to suggest this point of view.

References.

[1] Arndt. *Arch. f. Dermat. u. Syph.*, c, Nos. 1-3.

[2] Klausner. *Dermat. Wchnschr.*, 1913, lvi, p. 469.

[3] Corlett and Schultz. *Jour. Cutan. Dis.*, 1909, xxvii, p. 49.

[4] Unna, Pollitzer and Santi. *Monatsh. f. prakt. Dermat.*, 1890, x, Nos. 9-10.

[5] Juliusberg. *Arch. f. Dermat. u. Syph.*, 1899, i.

[6] White, C. J. *Jour. Cutan. Dis.*, 1903, p. 153. See also White, J. C., *Jour. Cutan. Dis.*, December, 1900.

[7] Cohn, Willy. *Dermat. Zentralbl.*, 1915, Nos. 4-6.

[8] Sellei. *Berl. klin. Wchnschr.*, 1909, Nos. 34-35.

[9] Brocq. *Annal. de dermat. et de syph.*, May, 1902.

[10] Jobling and Petersen. *Arch. Int. Med.*, 1915, xv, p. 286.

[11] Luithlen. *Wien. klin. Wchnschr.*, 1913, xxvi, p. 653. *Wien. med. Wchnschr.*, 1913, lxiii, p. 2375.

[12] *Jour. Cutan. Dis.*, 1915, xxxiii, p. 628 (discussion).

[13] Stokes. *Jour. Infect. Dis.*, 1916, xviii.

Plate XXX.—To Illustrate Article on Pityriasis Lichenoides Chronica.

by John H. Stokes, M.D.

Fig. 1.

Pityriasis lichenoides chronica, patient before improvement set in.

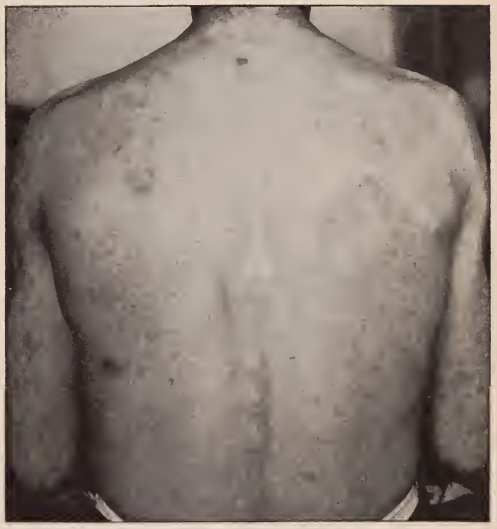

Fig. 2.

Patient at the height of his improvement. The macules remaining are residual pigmentation only.

Fig. 3.

Papular reactions to psoriatic and patient's own lesion emulsions. The negative reaction to normal skin emulsion is marked JHS. Illustrates also the pigmentary changes associated with the eruption.

THE BONES IN CONGENITAL SYPHILIS (WITH LANTERN-SLIDE DEMONSTRATION).*

By Abner Post, M.D., Boston.

The lantern slides which are shown herewith are intended to illustrate changes due to syphilis in the bones in hereditary disease. In order to have a proper understanding of these syphilitic bones it is necessary to begin with the child at birth, or even earlier. The slides demonstrated only those gross changes which may be recognized by X-ray, and not their more delicate pathology. The most characteristic and constant lesion occurs along the line of ossification and is spoken of as osteochondritis. The process of ossification is delayed. The single line of demarcation becomes thickened and enlarged. This pathological process was first described by Wagner, an assistant of Virchow, in 1870. It occurs in at least three different stages which present somewhat different aspects. As seen by X-rays it presents a much wider line than normally, and sometimes in its third stage presents what is practically a subdislocation. At the same time one may observe in these same skeletons, sometimes in the same bones, a periostitis, which resembles the periostitis of acquired disease, with which everyone is familiar.

Wagner also described certain changes in the medulla, which, as pictured by him, are represented by a spot in which the normal bony structure is wanting and the color is changed from a healthy red and white to a dull brown. These three changes are to be found in varying proportions in different individuals and in different bones in the same individual. They explain some of the defects in the subsequent pathology of the child. The osteochondritis limits the growth of the long bones and is probably responsible for the stunted growth. An occasional result in infancy is the pseudo-paralysis which is known by the name of Parrot, and which is sometimes mistaken for the result of violence at birth. These changes are recognized quite early in the infant, by X-rays, and allow one to make a diagnosis of syphilis in some of the cases of stillbirth without an autopsy. How long it is possible to trace the effects of this osteochondritis in the older child, is not yet determined.

* Presented before the 39th Annual Meeting of the American Dermatological Association, New York City, June 13-15, 1915.

The periostitis explains the wonderful tenderness and the tendency to cry at nights in syphilitic infants. It is also important in that it leads to changes in the bone which leave traces which can be recognized years afterwards. The changes in the intimate structure of the bone are, perhaps, of even greater importance in the development of the child. Wagner suggested that these changes interfere with the action of the bone marrow in the formation of red corpuscles, and in this way explain the wonderful pallor which is so prominent a symptom in so many of these children. Later in life we have in the skeleton the sequel of these infantile conditions, and in addition, active processes in the bones themselves.

The first change in childhood to which attention was drawn is the thickening of the cortex of the long bones as a result of the periostitis already mentioned. This is extremely well marked in a great many cases and is of very great value in the diagnosis of doubtful cases. In addition, we may have such periosteal changes as occur in the acquired disease, as well as osteoperiostitis and gummata. These changes in the bone may very well be compared to the better known changes in the skin. They may be simply superficial and recover without leaving a trace behind, or they may be deep and destructive like cutaneous gummata. In addition to these changes there are to be found certain changes in the bone which are analogous to osteomyelitis, which are not always easy to recognize as changes due to syphilis and which are often considered as tuberculosis or purulent infection.

Reference was made to one form of joint disease, described by Clutton in 1886, as symmetrical synovitis of the knee joint. He published a table of eleven cases in which other signs of hereditary syphilis were also to be found. In his volume on Hereditary Syphilis, Fournier quoted Mr. Clutton's description and said that though he could not doubt the accuracy of the description, he himself had never met with cases of this sort. The symmetrical synovitis of the knee seems to be much more frequent than Fournier found it. Symmetrical synovitis occurs also in other joints, but beyond the recognition of their existence no further reference was made. These knees were referred to as illustrating the value of the changes in the long bones for diagnostic purposes. The knees themselves show no change, but the thigh and tibia of the same leg often show marked syphilitic characteristics.

GANGRÆNOUS SYPHILITIC GUMMA OF THE THIGH.*

By A. Ravogli, M.D., Cincinnati.

With the new diagnostic means for the detection of syphilis and with the new methods of treatment, many problems which lacked proof have been confirmed and some false traditional theories have been discarded. The clinical symptoms, however, do not lose their great importance. In some cases the laboratory tests need a certain latitude of interpretation, when in contradiction to the symptoms, in order to dispel possible diagnostic errors, which after a while, are rectified through the results obtained by the treatment.

The following clinical case shows how, in certain conditions of a run down system, there may be lack of agreement in the laboratory reports, which fact, however, will never exclude syphilis as the causative agent

Case Report.

E. K., female, aged 31 years, housewife, was born in the United States. Her mother died from heart disease at the age of 53 years; her father was living but in poor health, aged 72 years. Seven sisters died in infancy; one brother, still living, enjoys good health, while a sister is in poor health.

She had had the diseases of infancy; when adolescent she had pneumonia and later smallpox. At the age of 20 years she complained of attacks of grippe, sore throat and rheumatism.

She had been admitted to the hospital on six occasions: First time 10 years ago, with peritonitis; second time, operated: laparotomy; third time, abdominal abscess; fourth time, wounds from a fall; fifth time, ulcer of the labium vulvæ; sixth time, present admission, May 14th.

The patient, when formerly admitted, had noticed a hard nodule in the left labium, which gradually became inflamed, broken down and ulcerated. The ulcer enlarged in size and in depth, became painful and interfered with her walking, which induced her to enter the hospital. At that time she had an ulcerated gumma of the labium and fossa crurogenitalis.

On Feb. 16, 1914, the Wassermann reaction was strongly positive.

She received two intravenous injections of neosalvarsan, 0.9 gm., and compresses of bichloride of mercury. Through this treatment she obtained a very slight improvement, so much so that the idea of malignant tumor was suggested. Blood was taken for the Abderhalden test and on April 2d, the report was returned positive.

* Read before the 39th Annual Meeting of the American Dermatological Association, New York City, May 13-15, 1915.

For this reason the patient was referred to the gynæcological service, where no abdominal tumor was discovered and she was again referred to the dermatological department, from which she asked to be dismissed, as she was greatly improved.

On May 14, 1914, she was admitted to our service for gangrænous ulcer of the left thigh, inner aspect, extending from the groin towards the knee.

Status Præsens. The woman is very much emaciated, pale, weighs 92 pounds, has slight fever. There is no cough; the lungs and heart are normal, the pulse weak. The abdominal viscera are apparently normal. She has a scar in the linea alba, from a laparotomy wound.

Description of Lesion. A black, gangrænous mass covered the upper part of the inner aspect of the thigh, from the fossa crurogenitalis, running towards the knee, oval in shape, 12 inches in length and 8 inches in width. The whole black mass was dry, hard, irregular in depth, with edges neatly cut, secreting a sero-purulent fluid, emanating a foul odor. The upper portion coalesced with the old ulcer of the left labium, which was irregular in shape and covered by masses of proliferating granulation (Fig. 1).

Fig. 1.
Showing gangrænous lesion on the inner surface of the left thigh.

The patient had previously received two intravenous salvarsan injections; the Wassermann test was negative. This suggested the possibility of malignant growth. For this reason the Abderhalden test was used, which, being positive, conveyed the idea of a possible sarcoma. The case was regarded as one of melanotic sarcoma, and the necessity of having the whole surface removed was seriously considered.

At this point the patient was referred to our service.

In spite of her negative Wassermann reaction and of the salvarsan injections she had previously received, it was not difficult to establish the diagnosis of a gangrænous gumma of the infiltrated type, and it was decided to institute mercurial treatment. She received an intramuscular injection of gray oil, 10 minims, at first twice a week, then once a week; internally, potassium iodide, with a mixture of cinchona, iron and strychnia, was administered. Locally, continuous compresses moistened with a 1 to 2000 solution of bichloride of mercury were applied.

In a few days the gangrænous area sloughed off, leaving an ulcerated surface, which gradually cleaned up and began to granulate. The other part of the old vegetating ulcer of the labium was scraped off and rendered into a condition favorable to healing. When the surface was clean, the bichloride compresses were used only twice a day, and the surface was covered with Wilson's ointment, with 20 grains of calomel per ounce.

Recovery was almost at hand when phlebitis of the internal saphena developed, with thrombosis and periphlebitis. The whole internal surface of the thigh, from the ulcer to the knee, was swollen and red; the veins were dark blue, thick, filled with clotted blood and were bulging out. The condition was extremely painful and was accompanied by fever.

Rest in bed, elevation of the leg and continuous wet compresses with bichloride of mercury brought down the inflammation. A few abscesses were formed and were soon opened. The surface was covered with mercurial plaster, which resolved the infiltrations. The gray oil injections were discontinued, and in their place the Zittmann decoction, two ounces twice a day, was given by mouth, together with potassium iodide.

The granulating surface of the ulcer was touched with silver nitrate, and gradually healed, leaving a regular, superficial scar. The woman left the hospital recovered.

This case prompts us to record a few observations.

The extensive mass, which simulated a malignant tumor, was a gumma. A piece was removed, hardened and cut into sections. It was stained with hæmatoxylin and eosin. A microphotograph showed the typical structure of the syphilitic gumma, consisted of an enormous infiltration of small cells, which have filled every interstice of the connective tissue. The infiltrating elements are much more abundant around the small vessels, studding their walls, some in transverse and some in longitudinal direction. These small cells seem to be migrating elements from the small blood and lymph vessels, showing the granulo-

matous nature of the lesion. The connective tissue fibres are so much crowded by the infiltration that they can scarcely be seen. In examining the same specimen, some large cells are seen, which look like giant cells. Examined with a higher power a blood vessel is seen, cut in transverse section, with its tunics infiltrated by the same cellular elements, some reaching its intima. The connective tissue forming the adventitia and the intima is proliferating. Each connective tissue cell contains more nuclei, and all show a tendency to proliferation. This condition of the blood vessels explains the successive degenerative changes of the granulating elements.

How a gumma is changed into a gangrænous mass, to constitute a particular type of gangrænous gumma, is easily understood. The gumma consists of a mass of small round cells, mononuclear leucocytes. The blood vessels, which carry the infiltrating elements, and for a while nourish them, are affected in their tunics by a chronic, specific inflammation. Their walls are in the same way infiltrated, which produces atrophy of the media and diminution of the calibre of the blood vessels. The affected intima is subject to a proliferation of the endothelium, which causes diminution of the lumen and, in some cases, formation of thrombus and occlusion of the blood vessels.

Every gumma undergoes a process of disintegration and in consequence it becomes softer in the centre and gradually also at the periphery. When at this point, it causes the sensation of a fluctuating mass. In some cases the fluid is gradually reabsorbed, in other cases it undergoes cheesy degeneration, suppuration ending in the form of an ulcer.

In the case under consideration, the lesion was converted into a gangrænous mass, and is termed a gangrænous gumma. The change in general is very rapid, and it is the cause of the destruction of the skin and sometimes of the affected organ.

In a case admitted to the venereal service of the Cincinnati Hospital for phymosis, when the prepuce was opened, the glans penis was found to be a mass of gangræne. To the same condition is to be ascribed the gangræne *foudroyant* of the penis and scrotum.

Individuals affected with syphilitic gumma, being at the tertiary period of such an infectious disease, are generally debilitated and in poor health. They have usually undergone an improper or an insufficient treatment. The gumma may be single or multiple, resembling abscesses; or it may be diffused, extending over a large area and called infiltrated gumma, or gummatous infiltration. This was the condition in our case.

where the extensive gummatous infiltration was converted into a solid gangrænous mass.

If the process had stopped at the disintegration of the tissue elements, it would be an ordinary case of necrobiosis, of mortification of the tissues. In our case we have had gangræne, which, together with the mortification of the tissues, involves putrefaction. Gangræne is the result of the action of microörganisms which are derived from the air or from the surface of the skin, and by invading the decayed tissues, induce putrefaction.

In the production of gangræne, the principal factors are a diminished vitality of the tissues, which may be due to a trauma, or to the nervous system, or to changes in the blood vessels, or of the blood, through infections or toxic elements. Some forms of gangræne of the skin are the result of affections of the central or of the peripheral nerves, as in syringomyelia, lepra, transverse lesions of the spinal medulla, as in tabes, and in the affections of the spinal ganglia, as is sometimes seen in herpes zoster. In this class are included all cases of idiopathic skin gangræne, which, on account of lack of pathological findings, have been classified under the head of trophoneuroses.

Our case, however, must be referred to that type of skin gangræne which is directly produced by the occlusion of the blood vessels, as those due to embolism, thrombosis, infectious endarteritis, or angiospasm. In a few cases of gangræne in Raynaud's disease and of diabetic gangræne, the angiospasm was certainly combined with anatomical alterations of the vascular walls. These alterations, wrought by syphilis in the tunics of the arteries, veins and lymphatic vessels, are of the highest importance in the functioning of the vessels and in the nutrition of the tissues. The blood and lymph vessels are attacked by the treponema and their tunics are subject, in the secondary period, to a hyperplastic inflammation, and later on, to a gummatous infiltration. To a true arteritis of a specific nature are due the degeneration of the tunics and the formative process which cause the occlusion of the blood vessels. These vascular alterations sometimes cause hæmorrhagic eruptions in syphilis which Unna[1] attributed to a specific hyaline hardening of the blood vessels.

The spirochætæ circulate free in the blood (Noeggerath and Staehelin,[2] Nathan Larrier and Bergeron,[3] Raubitscheck[4]) and attack the epithelial lining of the blood vessels, causing their alterations. Spirochætæ were found in colonies in the tunics of the blood vessels by Levaditi and Mamuelian, Buschke and Fischer. Spirochætæ were found in the walls of the veins in sclerotic conditions, and in the small blood vessels forming the superficial network of the capillaries. As a result of the infiltration and of the proliferation of the cellular elements, the epithelial lining of

the lumen of the artery is diminished, or nearly obliterated, or is plugged with a thrombus.

The results in necrobiosis are dependent upon the size and function of the blood vessels affected. When a large vessel is occluded, the whole limb may be affected with gangræne, and when small arteries are occluded, the gangræne appears in superficial spots on the skin. When the arteries which supply with blood all the tissues, normal and abnormal, cease to perform their functions, the tissues depending on them for their nourishment must decay and die. The condition of infected arteries explains the lesions of syphilis in every manfestation and in every stage of the disease. Ulcerative processes as well as gangrænous lesions are the result of an endarteritis.

This same phenomenon of the occlusion of the blood vessels is the cause of gangrænous spots in the centre of large papules. This occurs in small patches, while in a gumma of an infiltrated type, the areas affected are of greater proportions. In such cases, the process of endarteritis affects the small arteries which supply the tissues and the infiltrating elements of the gumma with blood, and, as a consequence, the whole mass is turned into a gangrænous mass. In all cases under our observation where gangræne developed, the gumma was very painful, of a bluish-brown color, hard and resistant to such an extent as to prevent the function of the organ on which it was seated. In a very short time the whole gummatous infiltration was converted into a gangrænous mass. The elements forming the gumma undergo a rapid necrobiotic decay, which, through the presence of the microörganisms, becomes putrefactive. When an area of the nervous system is deprived of its nutrition through the obliteration of a cerebral artery it will degenerate but will not fall into gangræne. The disturbance of the circulation predisposes to gangræne by diminishing or intercepting the supply of the arterial blood. The arterial obliteration is not necessarily complete, but there may be only a diminution of the calibre of the blood vessels, which is sufficient to cause gangræne.

Spontaneous multiple gangræne as a result of syphilis, in a late period, is of frequent occurrence. Hereditary syphilis is often the origin of those cases of gangrænous patches on the skin, which usually do not lend themselves to an easy explanation. The cases of spontaneous gangræne, as reported by Koenigstein and Hess,[6] Paul Heim,[7] Heubner,[8] Erkes[9] and others, seem to be much better explained by ascribing to them the most common causative factor, syphilis. They may be due to endarteritis. They may be caused by vasomotor action, but the hidden factor is the spirochæta pallida in the system.

The phlebitis of the internal saphena, which developed when the resulting ulcer was progressing towards recovery, although possibly connected with the syphilitic condition, is also to be attributed to bacterial infection. Bacteria may have originated from the surface of the ulcer itself or from contact of the sore with the hands.

The veins are often affected by a syphilitic inflammatory process, and many cases of extensive varicosities of the legs may, if not directly, at least indirectly, be caused by syphilis.

Briquet[10] had already stated that, whatever factor may exist for determining a prolonged or a constant increased pressure on the circulation of the legs, it is not capable of producing a permanent dilatation of the veins, unless there are some peculiar anatomical conditions of the walls, which favor their dilatation. This opinion, that the walls of the veins become flabby and dilated on account of the anatomical and biological conditions of their tissues, rather than from pressure, has constantly gained ground. In the same way, the observation of cases of varicosities in several members of the same family has given a hint of some possible hidden diathesis which, affecting the tunics of the veins or their valves, make them unable to resist the pressure of the blood, and consequently they permanently dilate.

Sommer[11] and Schambacher[12] pointed out cases of insufficiency of the veins on account of impaired development of the vascular walls. Durante confirmed their views with a series of histological specimens, showing some parts of the saphena, lacking in muscular fibres. The media and the adventitia in some portions are mingled together to form only one membrane of connective tissue, but with scanty elastic fibres. This explains the easy dilatation of the veins when the pressure of the blood is increased. These anatomical conditions, as A. Rossi[14] maintains, are not always to be attributed to congenital disturbances, but even an acquired inflammatory affection may produce an atrophy of the walls of the veins. Syphilis, which does not spare any tissue in the organism, in the same way that it affects the arteries also shows its deleterious influence on the walls of the veins. Mraçek[15] found alterations of the small and medium sized veins in cases of purpura, in children affected with congenital lues. Proksch[16] showed that an irritative hyperplastic inflammatory process, and a gummatous infiltration of the walls of the veins previously existed, which, after a while, terminated in an atrophic wasting of the tissues. When the walls of the veins have suffered in such a way, they cannot withstand the pressure of the blood, and as a consequence of the flabby conditions, they dilate irregularly, forming varicosities.

Our patient had undergone the ravages of a late syphilis, and the varicosities of the internal saphena may well be ascribed to this diathesis. Staphylococci had made their way into the tissues, causing coagulation of the blood, and thrombosis with acute periphlebitis.

The woman was discharged, cured. The whole ulcerated surface had healed, with a regular, even cicatrix. She had an excellent appetite, had gained ten pounds, and could walk without difficulty. Her skin showed a better color. She was still taking a ferruginous preparation, together with potassium iodide. Mercurial injections had been discontinued for some time.

Conclusions.

From the consideration of this case, from the contradictory negative Wassermann reaction in the presence of severe late syphilitic symptoms and from the results of the treatment, the following conclusions may be derived:

1. Between gummatous infiltration, disintegration and gangræne there is only a step.

2. Gumma is the result of diseased lymph and blood vessels, which are narrowed or thrombosed; and the same condition of the blood vessels in a more advanced stage is the cause of disintegration, necrosis and gangræne of the elements forming the gumma.

3. The rapidity of the spreading of the gangrænous process is mostly due to the quantity of the blood vessels involved, and to the presence of bacteria, together with a debilitated condition of the patient.

4. In the tertiary or late period, when the patient is badly emaciated, the laboratory test may be in contradiction to the clinical symptoms from the inability of the system to produce antibodies, but this must be properly interpreted by the expert.

5. In these conditions, a mild mixed treatment of mercury and iodides, associated with tonics, often gives much better results than the persistent administration of salvarsan.

References.

[1] Unna, P. G. Die Histopathologie der Hautkrankheiten. Berlin, 1874, p. 55.

[2] Noeggerath und Staehelin. *Münch. med. Wchnschr.*, 1905, No. 31.

[3] Larrier, Nathan et Bergeron. Soc. de Biologie, Jan. 27 and Feb. 3, 1906.

[4] Raubitscheck. *Wien. klin. Wchnschr.*, 1905, p. 752.

[5] Ravogli. Gangræne from Syphilitic Endarteritis. *Lancet-Clinic*, Feb. 12, 1910.

[6] Koenigstein, H., und Hess, L. Zur Klinik und Ætiologie einer bisher nicht beobachteten Form von Hautgangraen. *Dermat. Zeitschr.*, 1910, xvii, p. 911.

[7] Heim, Paul. Die idiopathische Hautgangraen im Säuglingsalter. *Berl. klin. Wchnschr.*, 1908. No. 16.

[8] Heubner. Hautgangraen bei Scharlach Rheumatoid. *Berl. klin. Wchnschr.*, 1913, No. 29. Ref. *Dermat. Zeitschr.*, 1908, xv, p. 669.

[9] Erkes, F. Ein Fall von præseniler Gangræn. *Med. Klin.*, 1910, No. 46.

[10] Briquet. Phlebectasies. *Arch. de med.*, 1825; quoted by Rossi: Contributo all'istogenesi delle varici degli arti inferiori. *Lo sperimentale*, 1913, iii, p. 231.

[11] Sommer. Über multiplen Phlebectasien. *Virchow's Arch.*, 1896.

[12] Schambacher. *Deutsch. Zeitschr. f. Chir.*, liii, 1900.

[13] Durante. Trattato di patologia e terapia chirurgica, 1906, ii, p. 279.

[14] Rossi, A. Contributo all'istogenesi delle varici precoci degli arti inferiori. *Lo sperimentale*, 1913, iii, p. 234.

[15] Mraçek. Syphilis hæmorrhagica neonatorum. *Arch. f. Dermat. u. Syph.*, 1887, xix, p. 117.

[16] Proksch, I. K. Ueber venen Syphilis. Bonn, 1898.

THE USE OF MERCURY IN VERRUCÆ PLANÆ JUVENILES.

By Charles J. White, M.D., Boston.

(From the Skin Department of the Massachusetts General Hospital.)

In the November, 1915, issue of The Journal I brought to the attention of the medical public a hitherto apparently undiscovered, successful method of treating verrucæ planæ juveniles by the internal administration of mercury in one form or another. Seven cases were reported, with only one failure, and emphasis was laid upon the fact that this method applied only to this one particular form of wart.

Since the writing of my first communication, the following four cases have been observed by myself and by two of my colleagues, who have kindly allowed me to publish them.

Case 1. (Dr. J. H. Blaisdell). J. M. L., aged 8 years (M. G. H., O. P. D. No. 275,057), presented, on July 21, 1915, numerous flat warts in linear arrangement on the back of the left hand. A pill of green iodide of mercury was prescribed. July 28th, warts flattening out. August 11th, warts decidedly better. On December 18th, I saw the patient, who said the warts had disappeared after the last visit and had not returned. Certainly none was present at this visit.

Case 2. (Dr. C. J. White.) E. J., a schoolgirl, aged 16 years (M. G. H., O. P. D. No. 282,294), presented, on October 16th, 1915, on the chin and very sparsely on the cheeks, isolated or coalescent, pinpoint- to large pinhead-sized, irregularly shaped, flat and striate topped, pink-brown papules. These lesions had been present for two years and had failed to yield to many ointments and "tonics." Pills of green iodide of mercury of one quarter grain in strength, three times a day, were prescribed. October 23rd. No change evident and the patient declared that one new lesion had developed. October 30th, new warts had appeared on the chin and on the forehead and no diminution in the size of the old lesions had occurred. The pills were continued and external applications of mercurial ointment were recommended. November 6th (Dr. Loretta J. Cummins), no apparent change. The mercury ointment had irritated the skin and the patient was requested to omit its use. November 13th (Dr. L. J. C.), improvement of more than fifty per cent. noted. Many of the smaller papules have entirely disappeared and the larger lesions are diminishing in size. ℞: continue pills. November 20th (Dr. L. J. C.), the disease has practically disappeared. ℞: continue pills. November 27th (Dr. C. J. W.), not a lesion left and the patient is very grateful.

Case 3. (Dr. L. J. Cummins.) R. C., a schoolgirl, aged 7 years (M. G. H., O. P. D. No. 228,378), presented, on December 22nd, 1915, on the forehead, cheeks and chin, many pinhead-sized, buff-colored, flat-topped juvenile warts of six months' duration. ℞: Pil. hydrarg. iodid. virid., gr.. ⅛, t. i. d. December 29th, the lesions are somewhat smaller. ℞: continue pills. January 12th, 1916, only one or two warts visible.

Case 4. (Dr. J. H. Blaisdell). O. I., a girl of 8 years (a private patient), presented, on November 11th, 1915, thirty to forty small, flat-topped warts of the juvenile type, situated principally on the forehead and more sparsely on the backs of both hands. The mother stated that these warts had been present without remission for at least one year. Mercury in the form of corrosive sublimate, gr. 1/16, morning and night, was prescribed. November 18th, the warts are decidedly smaller and less raised. November 26th, the warts have disappeared without exception.

Thus, adding the results of this series to those of the first, we find as a final total, ten successes to one failure—an outcome which justifies one in asserting that this new method of treating verrucæ planæ juveniles is the best to adopt when confronted with this disfiguring and hitherto intractable disease.

TRICHOTILLOMANIA. A REPORT OF TWO CASES OF THIS RARE NEURO-DERMATOSIS.

By J. Harper Blaisdell, M.D., Boston.

Physician, Skin Department, Boston Dispensary; Dermatologist, Lynn Hospital; Assistant, Skin Department, Massachusetts General Hospital.

Trichotillomania—the uncontrollable desire in an individual to pull out the hair—is decidedly rare in this country, if the amount of American literature on this neuro-dermatosis may be accepted as a criterion of the frequency of its occurrence. Although discussions of this disease in the French, German and Italian literature are indexed in the yearly issues of the Index Medicus, no reference to American reports is found in this source from 1903 to 1914.

Nearly thirty years ago this disease was noted and discussed by the leading French dermatologists of that period. Hallopeau[1], the first to describe this trouble, lays emphasis upon the intense pruritus associated with its occurrence. Brocq[2] considers the condition to be a true mania and states that no pathological lesions have been demonstrated in either the hair or the affected area. Mewborn[3] speaks of its occurrence in persons addicted to the use of cocaine and morphine. Sutton[4] gives the details of two typical cases. His first case occurred in an American married woman, 27 years old, of nervous temperament, who pulled out the hairs from the inner ends of the eyebrows whenever under mental strain or excitement. In the second case, a boy of 14, the left side of the scalp was attacked under similar circumstances. The pruritus described by Hallopeau was lacking in both these cases. Pernet[5] describes two cases in women, in the early twenties, in which concurrent dermatitis factitia was a striking feature. In the first case, necrosis of the jaw-bone was the result of the efforts of the patient, and in the other the damage to the skin was done by some liquid irritant. Martin[6] reports a case of a year's duration in an otherwise normal American boy of the tender age of four years.

During the past year I have had the opportunity of observing two typical cases of this disease. For Case 1, I wish to acknowledge my indebtedness to Dr. Charles J. White, in whose service at the Massachusetts General Hospital the man presented himself. This is the only case

on record in the dermatological department of this hospital. Case 2 occurred in private practice.

Case 1. The patient made but one visit to the hospital and owing to the fact that he lived several hundred miles from Boston, details other than those given on the records were unobtainable. "Man, 39 years old, married, house painter and paper-hanger. For the last five or six years the patient says he has noticed red spots about the hair follicles. These have itched and burned to such an extent that it has been necessary to pull out the hair, not only of the beard, but of the scalp as well. To-day the man has had a close shave and it is difficult to estimate the loss of hair in the beard but the scalp shows three or four large, irregular areas from which most of the hair has gone and in which scattered hairs are growing. In addition, there is one five-cent piece sized area, which is quite raw, where the patient says he has recently pulled out the hairs. The lesions at first sight suggest alopecia areata but the patient confesses to what has taken place and close scrutiny reveals the fact that the lesions are irregular in outline."

Case 2. The second case occurred in a Boston business man, 43 years old, who had suffered from this trouble for five years. The family history is excellent, the father dying of old age at 79, and the mother still hale and hearty at 80. The patient has no brothers, and his only sister died of cerebral hæmorrhage at the age of 54. There has been no insanity or nervous troubles in his remote or immediate connections. The previous history is negative, pneumonia at 17 being his only serious illness.

The patient is an educated and successful business man of energetic type. The definite onset of the disease is remembered in great detail. While reading one Sunday afternoon, a twitching of a hair on the neck was felt, and inspection in a mirror showed a small nodule with a centrally placed hair, to be the source of annoyance. The patient pulled out the hair at this point and the annoyance ceased, only to return in similar form, involving one to seven hairs, practically each day since that date. The usual sensation is to feel mild twitching or itching in definite hairs, during business hours. When the patient returns home and tries to read or to amuse himself otherwise, the symptoms become so insistent as to demand immediate intervention. He retires to his room and with the aid of mirror and forceps pulls out several hairs. The instruments and area to be operated on are cleaned with alcohol. Five years of this steady procedure have produced beneath the chin an area of superficial scarring and total alopecia, roughly two by three inches in extent. The rest of the bearded area is studded with millet seed to cent-sized, similar lesions. The eyebrows and scalp are not affected. Examination has never shown any of the so-called nodules that accompany the itching of a particular hair, in spite of the patient's insistence that they occur.

The patient firmly believes that he has a definite disease of the hair itself, and demands of each new physician whom he consults, a specific remedy that will relieve him of his trouble at once. The whitish, translucent sheath that surrounds the majority of the hairs he pulls out, is pointed to as evidence of their diseased condition. In his search for health, many physicians have been consulted and every advertised or recommended remedy has been used, all without relief. Suggestions that treatment along the line of psychotherapy be tried are met with skepticism, and, if insisted upon, a trial is absolutely refused.

REFERENCES.

[1] HALLOPEAU. *Ann. d. dermat. et d. syph.*, 1889, x, p. 440; 1894, v, p. 541.
[2] BROCQ. *Dermat. Pratique*, ii, p. 398.
[3] MEWBORN. Transactions, Section on Dermatology, Amer. Med. Asso., 1907, p. 102.
[4] SUTTON. *Jour. A. M. A.*, 1914, lxiii, p. 2126.
[5] PERNET. *Brit. Jour. Dermat.*, 1915, xxvii, p. 85.
[6] MARTIN. *Jour. A. M. A.*, 1915, lxiv, p. 1236.

NEWS ITEMS

THE RADIUM SANITARIUM OF NEW YORK.

The new Radium Sanitarium of New York, organized recently by Dr. Joseph P. Bissell, is to be modeled on the lines of similar institutions in London, Paris and Vienna. The buildings, which are located at 203 and 205 West 70th Street, are being equipped with laboratories for research work in physics, pathology and biochemistry. Two grams of radium will be furnished the Sanitarium during the present year, and a further supply will be secured as needed. Operating rooms of the standard type and rooms for X-ray and diathermia treatments are provided. A large number of patients with malignant disease are already being treated, although the equipment of the Sanitarium is not yet complete.

The entire institution, including the dispensary, will soon be thrown open to the medical profession, who will be invited to send cases for diagnosis and special treatment. The radium will be used not only for the treatment of malignant growths, but also for benign conditions of the skin, fibroid tumors, glandular enlargements, etc. Research work will also be conducted in diseases of faulty metabolism characterized by rheumatoid processes, cardio-vascular-renal degenerations, etc. It is planned to publish semi-annual reports upon the research work that may be of interest to the medical profession, public health organizations, etc.

The Medical staff, in addition to the President, Dr. Bissell, consists of Drs. Cornelius Coakley, Charles N. May, Winfield Ayres, George D. Stewart, Henry C. Coe, Samuel A. Brown, Anthony Bassler, John A. Fordyce, Howard Fox, William H. Stewart, William C. Lusk, and L. D. Boulanger.

OFFICIAL APPOINTMENTS.

DR. WALTER J. HEIMANN has been appointed Adjunct Attending Dermatologist to the Mt. Sinai Hospital.

DR. C. AUGUSTUS SIMPSON has been appointed Associate Dermatologist to the George Washington University Medical School and the Washington City Orphan Asylum, and Dermatologist to the George Washington University Hospital Dispensary.

SPECIAL ARTICLE.

HISTOPATHOLOGY.

(*Continued from March number, page 219.*)

By Walter J. Heimann, M.D., New York.

(From the Departments of Dermatology and Pathology, Cornell Medical School.)

Chapter IV.

Scaling Inflammations of the Erythrodermial Type.

As mentioned in the preceding chapter, this group of diseases consists of those exfoliating dermatoses known as the erythrodermias, Ritter's disease and Leiner's disease. They possess in common the features of generalized scaling and erythema. According to Darier,[1] there are four classes of such disturbances, the primary, the erythrodermial stage of diseases not essentially erythrodermial, the secondary, and the congenital. The primary form includes acute, subacute and chronic types. The acute is the recurring scarlatiniform scaling erythema resembling scarlatina; the subacute type is the generalized exfoliative dermatitis of Wilson-Brocq; the chronic variety includes the chronic exfoliative dermatitis of Wilson-Brocq, pityriasis rubra of Hebra-Jadassohn, and premycotic and leucæmic erythrodermias. The second class, or that of the erythrodermial stages of essentially non-erythrodermial diseases, refers to generalized squamous eczema, psoriasis, pityriasis rubra pilaris, acute lichen planus, and foliaceous pemphigus. The third class, or secondary erythrodermias, is not clearly defined. It is usually characterized by universal scaling, following apparently healed eczema, psoriasis, lichen or pemphigus, and runs either a benign course prone to recurrences, or a severe course with a high mortality. The fourth and last class includes Ritter's and Leiner's dermatoses and Brocq's diffuse congenital hyperkeratosis, which is either benign or malignant.

DARIER'S CLASSIFICATION TABULATED.

I. Primary erythrodermias.
   1. Acute—Recurring scarlatinoid erythema.
   2. Subacute—Generalized exfoliative dermatitis (Wilson-Brocq).
   3. Chronic—Chronic exfoliative dermatitis (Wilson-Brocq).
      Pityriasis rubra (Hebra-Jadassohn).
      Premycotic and leucæmic erythrodermias.

II. Erythrodermial stage of diseases not essentially erythrodermias; or erythrodermias developing in the course of generalized eczema, psoriasis, pityriasis rubra pilaris (Devergie), lichen planus and foliaceous pemphigus.

III. Secondary erythrodermias, or erythrodermias following the diseases mentioned under heading II.

IV. Congenital; Ritter's, Leiner's and Brocq's respective dermatoses of the new-born.

The histologic differences among these classes are ill-defined. For purposes of ease it is proposed to subdivide them as follows:

I. Acquired Erythrodermias.
   1. (*a*) Acute, subacute and chronic scarlatinoid forms.
      (*b*) Savill's disease.
   2. Chronic symptomatic forms, such as pityriasis rubra of Hebra and Jadassohn (a tuberculide), dermatitis exfoliativa of Wilson-Brocq, and premycotic and leucæmic forms.

II. Congenital Erythrodermias.
   1. Dermatitis exfoliativa neonatorum (Ritter).
   2. Erythrodermia desquamativa neonatorum (Leiner).
   3. Erythrodermia exfoliativa neonatorum congenitalis et familiaris (Brocq).

It will be noted that Darier's second and third classes are thus eliminated. In the first place the distinction between the two appears to be untenable and useless. Whether a generalized exfoliation arises in the midst of an attack of eczema, psoriasis or pemphigus, for example, or after their apparent disappearance, seems too flimsy a basis for subdivision, and, after all, these diseases differ from those from which they spring, only in extensiveness. In the second place they are histologically like their parent diseases and not erythrodermias, except in the most superficial clinical sense of the word. There is only one point of contact between the two groups, namely, the premycotic forms, which frequently start as either scaling eczemas, psoriasis or seborrhœa, but most frequently as parapsoriasis. Lichen planus and pityriasis rubra pilaris have no connection with the subject. As to the congenital sort, the three diseases mentioned seem completely to embrace the subject. Brocq's malignant hyperkeratosis is seen only in premature infants, and these survive but a few days; while the benign form is compatible with life

and clinically possesses some features of ichthyosis, but more of Hebra's pityriasis rubra.

The acquired erythrodermias all start as an acute inflammation, and pityriasis rubra and the leucæmic forms end up with atrophy. The premycotic type has many clinical features in common with Hebra's disease, but microscopically very few. From the outset it appears to possess characteristics prophetic of the granulomatous phase, and thus the proper place to consider its histology is in connection with mycosis. For similar reasons the leucæmic erythrodermias will be described in connection with leucæmia of the skin. This leaves to be considered in the present chapter the scarlatinoid forms of the disease, Savill's disease, dermatitis exfoliativa (Wilson-Brocq), pityriasis rubra (Hebra-Jadassohn), and the three congenital forms mentioned. Of these, by far the most important are Hebra's and Ritter's diseases, and they will serve as types with which to compare the others of the acquired and congenital forms, respectively.

From the literature dealing with erythrodermias, as a whole, the following facts stand out: Kaposi[2] briefly emphasizes in his microscopic description of erythrodermias a disappearance of the rete, sclerosis of collagen, increase in pigment, obliteration of the skin organs and elastica. Brocq[3] finds the basal layer normal, the rete not increased, but invaded by leucocytes. He quotes Girode, Audry, Petrini and Oro Mario, however, who find the suprapapillary rete thin, with the cells immediately above the germinative layer flattened. The granular and lucid layers are absent. The papillary and subpapillary regions, particularly about vessels, are infiltrated with fibroblasts, and contain many chromatophores. Vidal and Leloir, according to Brocq, find the collagen intact. Girode notes atrophied sebaceous and normal coil glands, while Oro Mario finds the latter atrophic and infiltrated. Leloir and Vidal observe no changes in the nerves. Oro, however, says they are infiltrated with round cells. Polland[4] finds the corneous layer thickened, the granular layer broken, the rete increased in depth, the pegs long and thin, and the papillary body infiltrated. In later lesions he notes thinning of the collagen in the papillæ, vascular dilatation, less infiltration and absence of follicles. Török's[5] findings are similar, except that he mentions vascular dilatation as being present early.

Thus the salient features of the erythrodermias in general are:

1. Slight hyperkeratosis, extensive parakeratosis, thinning or thickening of the rete and diminution or absence of the granular layer.
2. Elongation of the pegs.
3. Presence of leucocytes and increased pigment in the epidermis.

4. Thinning or thickening of the papillary collagen.
5. Dilatation of the vessels.
6. Lymphocyte infiltration.
7. Chromatophores in the infiltration.

PITYRIASIS RUBRA. (HEBRA-JADASSOHN.)

The literature on this disease is extensive, and for the sake of simplicity each feature of the minute structure of the lesion will be dealt with separately. Forster[6] finds a laminated hyperkeratosis, but no parakeratosis. A slight degree of hyperkeratosis, and distinct parakeratosis are found by all other authors, notably Petrini and Babes,[7] Ehrmann and Fick,[8] Jadassohn,[9] Brocq,[10] and Wallhauser.[11] The stratum granulosum is interrupted in continuity according to Forster,[6] and Petrini and Babes[7]; diminished in thickness, according to Jadassohn.[9] and absent according to Török.[5] The rete is found slightly thickened by Ehrmann and Fick,[8] narrowed by Brocq,[10] Jadassohn,[9] Forster,[6] and Fabry.[12] Wallhauser[11] notes stretching of the epithelial threads caused by intercellular œdema. Unna,[13] Brocq,[10] and Jadassohn[9] emphasize the presence of leucocytes in the epidermis. The basal layer is infiltrated, according to Jadassohn,[9] and according to Fabry[12] the columnar cells are tilted. No other writers observe changes in this stratum. The pegs, according to Unna,[13] are absent in advanced cases. They are present and found abnormally long and thin by Cahn,[14] Ehrmann and Fick,[8] Fabry,[12] and Wallhauser,[11] and this is a view fairly universally accepted. In Fabry's[12] case no pigment was observed. All other authors note its presence. Unna,[13] in particular, observes it in both epiderm and corium, while Wallhauser[11] and Jadassohn[9] draw attention to its presence in the infiltration in the corium.

The papillary body is usually present, and its outline is determined by that of the pegs. Wallhauser[11] and Fabry[12] find the collagen sparse and lacy; Petrini and Babes,[7] in their report at the International Congress held in Paris in 1890, mentioned the opposite fact, as did Tschlenow (Fabry[12]). Accordin gto Jadassohn,[9] the elastic fibres appear increased because of the shrinking of the corium. The vessels in and below the papillary body are found, by all writers, to be dilated and engorged. In Fabry's[12] case there was vascular thrombosis; in Petrini's[7] obliteration, and Wallhauser[11] mentions thickening of the vessel walls. An infiltration is found about and near the vessels. It consists almost entirely of round cells of the lymphatic type, and fibroblasts, with a few mast cells and chromatophores. Elsenberg[15] finds these cells arranged in foci, a fact which Jadassohn[9] disputes, and which has been supported by no one else. Ehrmann[5] notes a slight infiltration, as does Jadassohn,[9] who also mentions the presence of mast cells and connective tissue cells with multiple nuclei. Polland[4] says that the infiltration is dense. Forster[6] points out the absence of plasma cells. As to the organs of the skin, Cahn[14] finds them normal, Forster[6] and Fabry[12] mention that they tend to atrophy and finally disappear. Wallhauser[11] finds cystic enlargement of the coil glands.

The descriptions of Török,[5] Polland,[4] and Jadassohn[9] are the completest of the more recent writers, and they are substantially identical. All three emphasize the presence of parakeratosis, interruption or absence of the granular layer, thinning of the rete, except Török, with flattening of the cells, elongation of the pegs, dilatation of the vessels, a variable degree of infiltration, the presence of mast cells, and an increase of pigment both in the infiltration and epidermis. A comparison of these features with those of the erythrodermias in general will show no essential differences.

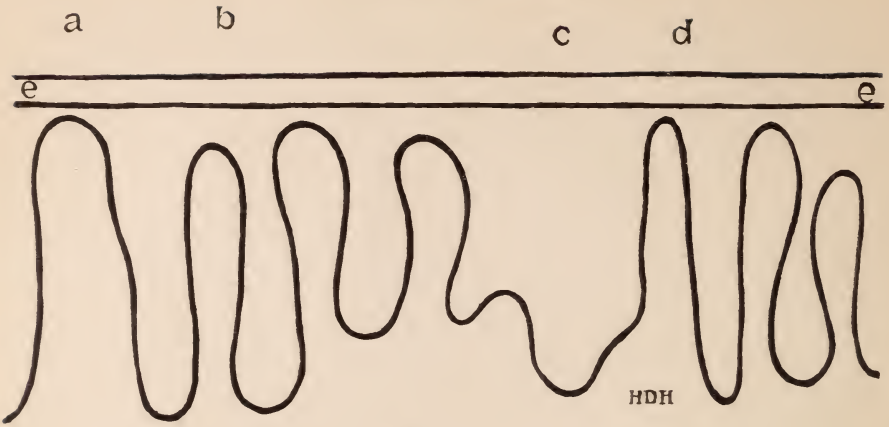

FIG. 4.

Pityriasis rubra pilaris. Diagram.
a. Papilla nearly reaching the scale.
b. Narrowed rete.
c. Broadened peg, or confluence of pegs.
d. Long, narrow peg
ee. Scale.

A young lesion shows changes in both epidermis and corium. A laminated scale surmounts the epidermis. It is flaky and constructed of nucleated cells (Fig. 1). The stratum corneum is nowhere normal (Figs. 1, 2 and 3). All of the cells are nucleated (parakeratosis), as is to be expected in a process so luxuriantly exfoliative. There is no, or little stratum granulosum (Fig. 1). These two processes are characteristic of hyperkeratinization. The suprapapillary rete is narrower (Figs. 1 and 4) in some places, in others of about normal breadth (Fig. 2), and the intercellular spaces are widened because of œdema. The epithelial threads are stretched and conspicuous, as in Wallhauser's[11] case (Fig. 5). The Malpighian cells tend to flatten at lower levels than in healthy skin (Figs. 1, 2 and 3). The staining properties of the cells are normal. An occasional leucocyte is to be seen. The basal layer shows no pathological changes. Some pegs are confluent and slightly elongated, while others are extremely long, narrow and tongue-like. Thus the boundary line between the epiderm and corium is irregular, here and there deeply notched, elsewhere only slightly wavy.

The papillary body is œdematous and the site of a marked, if not dense, infiltration (see illustrations). The infiltration consists entirely of fibroblasts and lymphocytic cells, with a few mast cells bunched within the fibres of a rarified and lacy web of collagen. The minute capillaries in this region are dilated and their endothelium is swollen. In the sub-

papillary area the infiltration is less dense (Figs. 1, 2 and 3), and of the same composition, but there is not so much œdema of the collagen, or separation of the fibres. On the contrary, this tissue seems denser and the fixed cells more numerous, indicating a sclerosis. Vascular dilatation, endothelial swelling and hypertrophy of the media are to be seen (Fig. 3). Still lower in the corium no infiltration is found, the collagen is normal, but the blood vessels show changes similar to those just mentioned. The coil glands are normal.

The specimen which furnishes a basis for the following description of the more advanced stage of this process was procured from Dr. Mitchell's case (Fig. 1), shown by Dr. Pollitzer at the December meeting of the Section on Dermatology and Syphilis of the New York Academy of Medicine. The patient had been afflicted for upwards of twenty years. The microscopic picture is classic and corresponds to the findings of Jadassohn, Török and Polland. The scale is parakeratotic, as is that portion of the horny layer adherent to the epiderm. The granular layer is thin and dicontinuous. The rete above the papillæ is narrow and in places only two or three rows of cells cover the basal layer. These cells are huge and flat. Elsewhere six or eight tiers are found. Numerous mitotic figures may be seen and a few leucocytes and chromatophores. A marked intercellular œdema (Fig. 5) exists. The pegs are irregular, long, extremely thin, and their basal layer and Malpighian cells are like those in the suprapapillary portion. Mitoses, chromatophores and leucocytes abound here. The shape of the papillary body is determined by that of the pegs. The collagen is rarefied and web-like. Its vessels are dilated and their endothelium swollen. A marked infiltrate is present composed of lymphatic cells, fibroblasts, a few mast cells, and numerous chromatophores. The subpapillary vessels are dilated and engorged, showing the same inflammatory changes as seen higher up, and the collagen changes and cell types noted above, are seen here also. The coil glands are normal.

A still later or atrophic stage is present in pityriasis rubra, which is microscopically characterized by a thinning of the epidermis and an almost complete loss of rete pegs. The epidermis consists of a basal layer above which lie four or five rows of swollen, flat rete cells. The stratum granulosum is present but thin, and the cells seem more granular than usual. The stratum corneum is thin, and perhaps somewhat less parakeratotic than in the earlier stages. The papillary body, of course, is lost, and the entire corium consists of sclerosed connective tissue, somewhat œdematous, containing a few fibroblasts and fixed cells. Very little infiltration is seen in the younger types of lesions, but such as there

is, consists of lymphatic cells and mast cells. If anything, the vessels are more dilated than in the earlier stages and show such other changes as have already been mentioned, to a more marked degree. All the skin organs are atrophied or gone.

Pityriasis rubra of Hebra, then, represents a dermatitis in which three features predominate,—parakeratotic scaling, infiltration with connective tissue diminution, and vascular dilatation. Thus an anomaly of keratinization and congestion with œdema are present. These features explain the clinical phenomena of exfoliation and erythema which characterize the malady. In terms of general pathology the process is to be classed as a subacute, atrophying, cutaneous catarrh.

DERMATITIS EXFOLIATIVA. (WILSON-BROCQ.)

Girode,[16] and Vidal and Leloir[17] find the rete thin, the stratum granulosum absent, the pegs long and narrow, the capillaries surrounded by a more or less dense infiltration, the vessels dilated and the cutaneous organs distorted or wanting. Girode[16] notes hypertrophy of the coil glands. Unna[13] confirms this picture. Ormsby,[18] quoting Bowen's article in THE JOURNAL (Vol. xxviii, p. 1), mentions hyper- and parakeratosis, leucocytes in the epiderm, and a sharply differentiated cell in this layer which is distinctly stained with eosin.

Save for this finding of Bowen's, the description of Wilson's dermatitis is not unlike that of Hebra. The epidermal changes, even to the flattening of the Malpighian cells, and peculiarities of the granular layer and pegs, correspond exactly with those seen in pityriasis rubra. Nor does the picture seen in the papillary body and corium offer any definite differential points. The epidermis is irregularly thin, in places appearing as a columnar layer and corneous layer with a few rows of Malpighian cells separating them. In other cases there is somewhat more breadth, perhaps the equivalent of eight or ten tiers of cells. Nowhere is the epiderm normal in its dimensions. The pegs are wanting in some areas, and here the epidermis appears as a fine ribbon. In other areas still the pegs are suggested, and finally there are long and narrow ones projecting deep into the corium below. No abnormalities are present in the basal layer. The Malpighian cells soon become flattened as in pityriasis rubra. The granular layer is wanting entirely or discontinuous. The corneous layer and scale are parakeratotic. The latter shows a few areas of pure hyperkeratosis. The papillary body is œdematous and the collagen fibres are separated into a delicate tracery in the midst of which are seen enormously dilated capillaries and an infiltration of round cells, lymphocytic in character, and fibroblasts. The infiltration is marked, but not dense. It fades out lower down, but the character of the vessels is the same, even in the depths. They are

engorged and greatly dilated, some even resembling small lakes. The endothelium is swollen. No abnormalities are present in the organs of the skin. It must be clear that there are no more essential microscopic differences between Hebra's and Wilson's erythrodermia than might be found in either disease itself in a study of a series of specimens.

THE SCARLATINIFORM ERYTHRODERMIAS.

Brocq's[10] description and his citations from the literature indicate that in this disease there is a distinct conformity in type to that of the erythrodermias in general, a fact pointed out by Suchard. Petrini and Babes[7] say that the stratum corneum is thickened, the granular layer sharp, and that there is an acanthosis, particularly in the pegs. Leucocytes are found in the epidermis, and at the tips of the papilliæ the basal layer is obliterated by an infiltration coming up from below. Suchard says that the granular layer is absent, as in the other erythrodermias. Leredde and Dominici point out a tendency for some of the Malpighian cells to take the eosin stain with unusual intensity, suggesting Bowen's findings in Wilson's dermatitis. Leloir's description (Brocq[10] p. 232) reads as if it were one of Hebra's or Wilson's diseases.

SAVILL'S DISEASE.

Ormsby's[18] description and quotation from Echeverria indicate that this disease in all points corresponds microscopically to the general type. Echeverria notes a change in the Malpighian nuclei which he calls peridiaphania, and which he regards as pathognomonic. This may, however, be merely an artifact produced in fixation.

DERMATITIS EXFOLIATIVA NEONATORUM (RITTER).

The precise place, from the standpoint of classification, of Ritter's dermatitis is not yet established. Brocq[10] and Behrend (see Della Favera[19]) regarded it as a form of pemphigus, and Skinner's studies, as well as Luithlen's, would appear to give this view some force. The consensus of opinion at the Fifth Congress of the German Dermatological Association, held in Graz in 1895, was against this. There is a definite formation of blebs and this is entirely uncharacteristic of the erythrodermias. On the other hand, the rest of the microscopic picture conforms to that of the latter type. Della Favera[19] finds a marked hyperkeratosis, and an acanthosis due to œdema within and without the cells. The pegs chiefly are involved and the Malpighian cells are large and flat. A colliquative necrosis with cell degeneration takes place, and portions of the stratum granlosum are lost. The vessels are dilated and the corium and papillary body contain a fibroblast infiltration. Luithlen[20,21] adds to these findings the following facts: the papillary body swollen by virtue of œdema of the collagen, dilatation of the blood and lymph vessels, and the presence of an infiltration. The elastic fibres parallel the collagen. The infiltration is both perivascular, and in bands, which are independent of the vessels, and run parallel to the connective tissue bundles. It consists of fibroblasts, lymphocytes and mast cells. Plasma cells are absent. Hæmorrhages are occasionally seen in the corium. The epidermis is at times raised from the papillary body by a bleb. Winternitz[22] and Skinner (Ormsby[18]) confirm this. Ehrmann and Fick[8] give a similar description and also mention that mast cells are found in the infiltration.

Intense vascular changes, and general œdema, with striking epidermal alterations are the microscopic features of this disease (Fig. 6). The epidermis is variable in breadth (Fig. 6). Above the columnar layer, which is present throughout, the Malpighian stratum is found, consisting of from one to two rows of cells. These cells are flattened in the lower tiers and extremely œdematous in the upper, where both the nuclei and cytoplasm in definite islands stain faintly, suggesting small blebs (Fig. 6) in the formative stage. Still higher up the stratum granulosum, but one cell row deep, is found complete throughout; and the scale, surmounting this, is relatively thick, consisting of nucleated cells. A few leucocytes are found in the rete above and within the pegs (Fig. 6), which vary greatly in development. For long stretches they may be entirely wanting, or only suggested by a wavy line, or they may be present and very long and narrow.

The papillary body is shaped to conform to the outline of the pegs. It is œdematous, and immediately below the epiderm are numerous small narrow spaces suggesting beginning subepidermal blebs. Down to the subpapillary vessels the collagen fibres are loose, separated by the œdema, and they lie amidst dilated capillaries and a sparse infiltration of fibroblasts, round cells and some mast cells. The subpapillary vessels themselves are enormously enlarged. Some are thrombosed and all show a swelling of the endothelial wall. Below this the collagen is compact, the skin organs are normal, and the elastic fibres unchanged. In the later stage there is an atrophy in all layers (Fig. 7). Dermatitis exfoliativa neonatorum departs from the picture of the erythrodermias only by virtue of the presence of blebs, and forms a morphological link with the bullous dermatoses by its similarity to foliaceous pemphigus, a form which will be more fully discussed in the chapter on this disease.

ERYTHRODERMIA DESQUAMATIVA NEONATORUM (Leiner) and ERYTHRODERMIE CONGENITALE UNIVERSELLE FAMILIARIE AVEC HYPEREPIDERMATROPHIE (Brocq).

Leiner's disease appears to be a distinct entity, and from the little written upon its microscopic structure, it is evidently of the erythrodermial type. Brocq's disease, too, is distinctly in this group. Schonnenfeld[23] finds the stratum corneum thick, hyperkeratotic but not parakeratotic, the rete two or three layers broad and containing pigment only. The pegs are either entirely wanting, or, when present, shaped like those in the other diseases of this group. A round cell infiltration and chromatophores, as well as dilated vessels, are found in the corium. Rasch[24] notes a parakeratosis, the absence of the stratum granulosum, and a few mast cells in the infiltration. Galewsky[25] emphasizes the great dilatation of the vessels. Thus, the composite of the descriptions of these three authors clearly indicates the conformity of this disease to the others discussed in the present chapter.

If the psoriasiform dermatoses (see Chapter 3) and the erythrodermias are compared, certain microscopic similarities and differences stand out. The former group is characterized by hyperkeratosis and slight parakeratosis, a tendency for the granular layer to be normal or thickened, an enlargement of the pegs, and the formation of epidermal abscesses without true vesiculation, except in seborrhœa, and occasionally in pityriasis rosea. The collagen is not destroyed and a dense infiltration of fibroblasts and lymphocytes is found in most of the diseases, save pityriasis rosea, in which the infiltration is slight. In the erythrodermias, perakeratosis is prevailingly present, but little hyperkeratosis, a thin or absent granular layer, a thin rete of flat cells, elongated pegs and an epidermal œdema. In the papillary body and corium the vascular changes and œedma are more or less marked in both groups, but in the erythrodermias the dilatation is more striking than in the other.

The two groups are united by erythrodermie pityriasiques en placques disséminées. The psoriaform group is linked to eczema histologically by the seborrhœal diseases and to the multiforme erythemas by pityriasis rosea. The erythrodermial group is linked to pemphigus, as mentioned, by Ritter's disease; to the exanthemata by the scarlatiniform dermatoses, and both groups are linked to granuloma fungoides and leucæmia, respectively, by their similarity to the premycotic and preleucæmic exfoliative dermatoses.

References.

[1] Darier. Précis de Dermatologie, Paris, 1909, p. 97.

[2] Kaposi. Hautkrankheiten, 5th ed., 1899, Vienna, p. 458.

[3] Brocq. Erythrodermies, Prat. Dermat., ii, p. 588.

[4] Polland. Beitrag zur Klinik und Pathogenese der exfoliativen Erythrodermien, *Arch. f. Dermat. u. Syph.*, 1910, ci, p. 333.

[5] Török. Die exfoliativen Erythrodermien, Mraçek's Handb., ii, p. 785.

[6] Forster. Beitrag zur Klinik der Pityriasis rubra (Hebra), *Arch. f. Dermat. u. Syph.*, 1908, xciii, p. 388.

[7] Petrini and Babes. Pityriasis rubra, *Jour. d'Anat. et de Physiol.*, 1890, xxvi, p. 63.

[8] Ehrmann and Fick. Histopathologie, p. 32.

[9] Jadassohn. Pityriasis rubra, und ihre Beziehung zur Tuberculose, *Arch. f. Dermat. u. Syph.*, 1891, xxiii, and 1892, xxiv, pp. 941, 85, 273, 463.

[10] Brocq. *Dermat. Prat.*, 1907, ii, p. 256.

[11] Wallhauser. Pityriasis rubra, Hebra, *Jour. Am. Med. Assn.*, 1912, lix, p. 10.

[12] Fabry. Nachtrag zur Arbeit von O. Mueller, "Ein Fall von Pityriasis rubra (Hebra) mit Lymphdrüsen Tuberkulose," *Arch. f. Dermat. u. Syph.*, 1908, xci, p. 85.

[13] Unna. Histopathologie, 1894, Berlin, p. 276.

[14] Cahn. Ueber Pityriasis rubra, Dissertation, Würtzburg, 1884.

[15] Elsenberg. Pityriasis rubra universalis, *Vierteljahresschr. f. Dermat.*, 1887.

[16] Girode. Dermatitis exfoliativa generalisata et primitiva, *Ann. de. dermat. et de syph.*, 1888, p. 519.

[17] Vidal and Leloir. Anatomie pathologique de dermatite exfoliative, *Bull. des hôp.*, March 24, 1882.
[18] Ormsby. Diseases of the Skin, 1915, p. 322.
[19] Della Favera. Dermatitis exfoliativa (Ritter), *Arch. f. Dermat. u. Syph.*, 1909, xcviii, p. 234.
[20] Luithlen. Dermatitis exfoliativa (Ritter), Mraçek's Handbuch, i, p. 757.
[21] Ibid. Dermatitis exfoliativa (Ritter), *Arch. f. Dermat. u. Syph.*, 1899, xlvii, p. 323.
[22] Winternitz. Ein Beitrag zur Kenntniss der Dermatitis exfoliativa neonatorum, *Arch. f. Dermat. u. Syph.*, xliv, 1898, p. 397.
[23] Schonnenfeld. Ein Fall von Erythrodermie Congenitalis Partialis, *Arch. f. Dermat. u. Syph.*, 1914, xcviii, p. 101.
[24] Rasch. Erythrodermia exfoliativa congenita familiaris, *Dermat. Zeitschr.*, 1901, viii, p. 669.
[25] Galewsky. Erythrodermia Congenita Ichthyosiformis, *Arch. f. Dermat. u. Syph.*, 1912, cxiii, p. 377.

Explanation of Plates.

Fig. 1. Pityriasis rubra (Hebra) as seen with the Zeiss ocular 8, objective 3 mm. (Dr. Mitchell's case.)
- *a.* Parakeratosis.
- *b.* Elongated peg.
- *c.* Papilla touching parakeratotic scale.
- *d.* Broadened peg.
- *e.* Dilated vessel.

Note the intercellular œdema in the epiderm, the infiltration chiefly in the papillary body, the œdema of the collagen, and the various elevations of the papillæ, some touching the scale, others separated from it by narrowed rete.

Fig. 2. Pityriasis rubra (Hebra). Microphotograph from the collection of Drs. Fordyce and MacKee, showing substantially the same features as Fig. 1. Note the patches of parakeratosis, and the granular layer of varying thickness. In places it is discontinuous. Zeiss. obj. 8 mm., co. oc. 4.

Fig. 3. Pityriasis rubra (Hebra). Microphotograph from the collection of Drs. Fordyce and MacKee, showing the features seen in Figs. 1 and 2, but also the presence of leucocytes in the epidermis, marked infiltration in the papillary body, and marked vascular dilatation. Zeiss obj. 8 mm., co. oc. 4.

Fig. 5. Pityriasis rubra pilaris. Drawing of cells of peg.
- *a.* Malpighian cell with stretched epithelial threads.
- *b.* Leucocyte.
- *c.* Intercellular space dilated through œdema.

Fig. 6. Dermatitis exfoliativa neonatorum. Drawing as seen with Zeiss ocular 8, objective 3 mm.
- *a.* Hyper- and parakeratotic scale.
- *b.* Normal rete to the right, atrophied to the centre and left.
- *c.* Œdematous and slightly infiltrated papillary body.
- *d.* Bleb in scale.
- *e.* Œdematous, slightly infiltrated collagen with vascular dilatation.

Fig. 7. Dermatitis exfoliativa neonatorum (atrophic stage). Drawing as seen with Zeiss ocular 8, objective 3 mm.
- *a.* Thin hyperkeratotic scale.
- *b.* Atrophic rete with absence of pegs.
- *c.* Atrophied but somewhat œdematous collagen with slight infiltration and dilatation of vessels.

Plate XXXI.—To Illustrate Article on Histopathology,

by Walter J. Heimann, M.D.

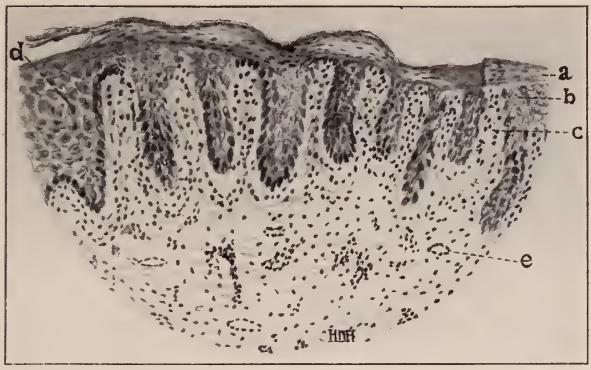

Fig. 1.

Pityriasis rubra (Hebra). Drawing. Zeiss obj. 3 mm., oc. 8.

Fig. 2.

Pityriasis rubra (Hebra). Microphotograph from the collection of Drs. Fordyce and MacKee. Zeiss obj. 8 mm., co. oc. 4.

Plate XXXII.—To Illustrate Article on Histopathology, by Walter J. Heimann, M.D.

Fig. 3.

Pityriasis rubra (Hebra). Microphotograph from the collection of Drs. Fordyce and MacKee. Zeiss obj. 8 mm., co. oc. 4.

PLATE XXXIII.—To Illustrate Article on Histopathology, by WALTER J. HEIMANN, M.D.

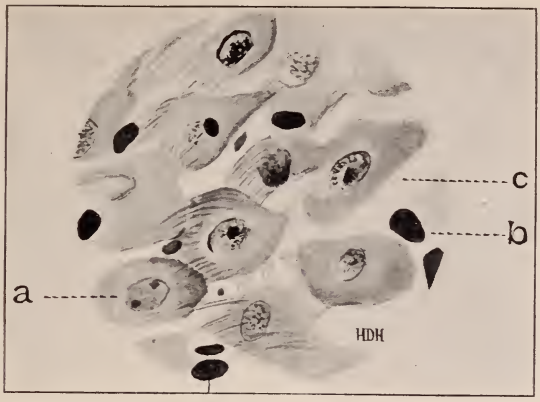

FIG. 5.

Pityriasis rubra pilaris. Drawing.

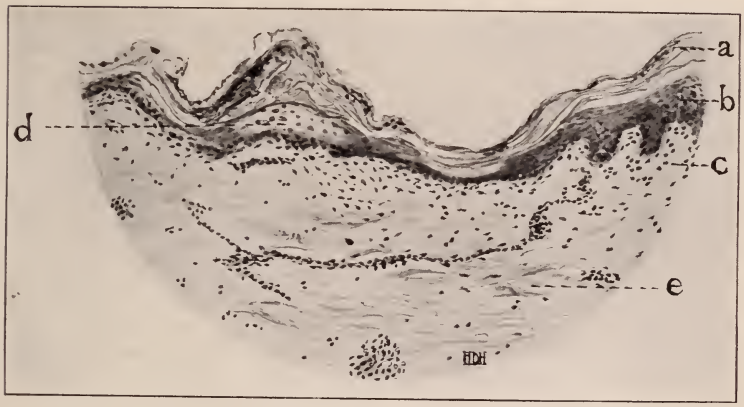

FIG. 6.

Dermatitis exfoliativa neonatorum. Drawing. Zeiss obj. 8 mm., oc. 4.

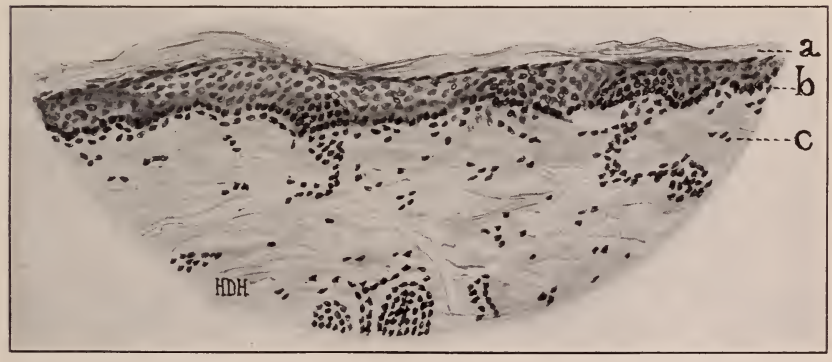

FIG. 7.

Dermatitis exfoliativa neonatorum. Drawing. Zeiss obj. 3 mm., oc. 4.

SOCIETY TRANSACTIONS.

CLINICAL SESSIONS OF THE THIRTY-NINTH ANNUAL MEETING

OF THE

AMERICAN DERMATOLOGICAL ASSOCIATION.

New York, May 13th and 14th, 1915.

CASE FOR DIAGNOSIS (PEMPHIGUS FOLIACEUS?). Presented by Dr. Gilchrist.

The patient was a man, 42 years of age. The eruption which he presented was of two and a half years' duration and began as a small, scaly spot on the left temple. The diagnosis at that time was eczema. The lesion gradually spread peripherally. He received seventy X-ray treatments without any benefit, the lesions continuing to spread. Later, X-ray treatments gave some temporary improvement. Following cacodylate of soda injections, twelve in nine days, vesicles and bullæ appeared over the body, and the patient was confined to bed for six weeks. Lesions then appeared on the right side of the face and scalp. Later, autoserum injections were tried and again a bullous eruption was produced. No benefit resulted. The patient was seen by the speaker three weeks ago. He showed large, well-defined areas over the entire left side of the face and scattered, nickel-sized lesions over the scalp, right side of the face and upper two-thirds of the body. The lesions on the face were superficial in character, with slightly adherent, yellowish scales or scabs, the removal of which caused pain. Most of the diseased area was covered with light, pie-crust-like scabs. Other single lesions and especially the most recent ones, presented an appearance like superficial keratomata; but on examination the yellowish, superficial part could be removed and the superficial layer of the skin easily torn off, for some distance round the red lesion (Nikolsky's sign) and a red, raw surface exposed. There were no signs of any vesicular or bullous lesions. The patient's health was good in every respect, all internal organs, including the alimentary canal, were normal. When the patient was first seen, one month ago, a culture of a short bacillus and a coccus was obtained from his blood. A vaccine was made of this and two injections had benefited him somewhat. On clinical grounds and a positive Nikolsky's sign, the case was thought to be an unusual type of pemphigus foliaceous. A section from a very recent lesion showed a microscopic picture like that of an epidermolysis bullosa and not a pemphigus foliaceous. The case would be reported later.

Discussion.

Dr. Schamberg said that he referred to Dr. Gilchrist's opinion in regard to the microscopic findings in this case, but he would nevertheless hesitate to classify this case in the group of pemphigus foliaceus. He was inclined to re-

gard it as a case of dermatitis herpetiformis, a disease which was, to be sure, related to pemphigus.

Dr. Pardee agreed with Dr. Gilchrist in the diagnosis of pemphigus foliaceus, citing a parallel case in which the skin manifestations began as in the present instance, with a lesion over the region of the temple which lasted eighteen months before characteristic bullæ developed as a generalized eruption.

Dr. Gilchrist said he did not know how else to classify the case, but it was certainly not dermatitis herpetiformis. The lesion on the left cheek had a crusted appearance. It imitated pemphigus foliaceus more closely than any other disease.

CASE FOR DIAGNOSIS. PITYRIASIS RUBRA (HEBRA?). Presented by Dr. Wise.

Previously presented (See The Journal, 1914, p. 715, and 1915, p. 314.)

Discussion.

Dr. Pusey called attention to the fact that this case with its universal exfoliative dermatitis, did not resemble mycosis fungoides; that on the contrary, the combination of the general exfoliative dermatitis with infiltrated plaques in the skin, such as the patient had on his face, strikingly suggested leukæmic manifestations of the skin.

Dr. Wise stated that the patient's blood had been examined on three or four occasions, and never showed any abnormality. A general physical examination of the patient revealed normal conditions, aside from the cutaneous disease and a generalized lymph-adenitis. Biopsies of the skin and of a gland in the groin were recently studied by Drs. Larkin and Fordyce. These were to be studied for the purpose of reporting the case in detail, at a future date.*

Dr. Fordyce said he had not seen the patient in the early stages, but had him under observation at the City Hospital for two or three months and if he were examined carefully, a universal atrophy of the skin could be seen which could not be distinguished from idiopathic skin atrophy. In the deeper portion of the skin there was an obliterative endarteritis. Dr. Larkin, of the Department of Charities, had examined sections and said that what he had been most impressed by was the changes in the blood vessels; and that the changes in the glands of the groin were different from anything he had seen before. They resembled the endothelioma type of growth. The most impressive features were the atrophy of the skin and the histological changes in the vessels. Dr. Fordyce said he thought the condition of œdema and infiltration on the forehead was secondary.

Dr. Schamberg said that he hesitated very much to differ from the opinion expressed by Dr. Fordyce and Dr. Wise for they had had an opportunity to study the patient for a long time. He had been impressed with the fact that the skin on the forehead and cheeks presented the appearance of a neoplasm and he felt that this case might ultimately show more characteristic symptoms of mycosis fungoides. The entire clinical picture was not in conformity with this conception but it was possible that the other changes might be purely secondary. He felt that further observation of the case would disclose its real nature.

Dr. Wallhauser said that, having observed a similar case to its termination, he agreed with the diagnosis of pityriasis rubra (Hebra). His patient presented

* Sections from the skin of this patient, together with fresh blood smears were exhibited at the meeting, on the following day.

the same generalized pigmentation, atrophy and scattered oval patches seen in this case, the thickened, keratotic areas referred to by Dr. Zeisler, were likewise present, and a diagnosis of mycosis fungoides was suggested, but was not substantiated, as no further change occurred.

Dr. Fordyce mentioned obliterative endarteritis as the underlying process. This was well established in the speaker's case, in which the microscopical findings showed a decided hyperplasia of the vessel walls, with complete obliteration in some locations, accounting for the late manifestation, in his case, of ulcerations over bony prominences.

Dr. Heimann said that the possibility of its being a generalized tuberculosis, a tuberculosis of the lymphatic glands, or Hodgkin's disease, had not yet been considered. These should be very seriously considered, as factors in the solution of the condition. He did not think they could be definitely excluded without study.

XANTHOMA PLANUM DIABETICORUM. Presented by Dr. Wallhauser.

The patient, W. G., was a woman, 60 years of age, married, born in the United States. She had enjoyed good health until about five years ago, when she began to lose weight, accompanied by a feeling of weakness and depression. (She lost about 40 pounds in a few months). The eruption appeared about one year before this period, as several circular and irregular-shaped, sharply defined, yellowish patches with violaceous borders, measuring from one-half inch to several inches in either direction. The surface of the lesions presented a peculiar smooth and glossy appearance, dotted in several locations and with depressed atrophic areas, covered with firmly adherent scales. The patient had been under observation for the past two years, during which time, no very material change had occurred in the general appearance of the lesions, and no new ones had developed. The eruption had remained limited to the lower extremities, especially below the knees, with a single lesion on each buttock. The urine, at the beginning of treatment, showed about 5% of sugar, which had gradually diminished under a restricted diet. In the last two examinations, at four-month intervals, it was entirely free.

Discussion.

Dr. Wile thought that the case was one of morphœa rather than xanthoma. The yellowish color alone suggested xanthoma, but the violaceous border and the atrophy were typical of morphœa.

CASE FOR DIAGNOSIS (YELLOW LESIONS ON THE NECK.) Presented by Drs. Kingsbury and Heimann.

The patient was a girl, 21 years of age, born in England, and had been living in the United States for the past six months. The lesions had been present upon the sides of the neck for five years. They were rounded or oval, slightly elevated, bluff-colored patches, about one-half inch in width. Urinalysis two months ago, showed 0.92 glucose. Two subsequent examinations were negative. The microscopical examination was as follows: "The epidermis was normal, as was the contour of the papillary body. The collagen was swollen at all levels, and there was a slight numerical increase of the fibroblasts. Vessels were not increased in number but were slightly dilated, without being engorged. Their endothelial lining was somewhat swollen, and outside of a few of the vessels was a trifling infiltration, consisting entirely of fibroblasts, arranged in

one or two concentric rows. The most significant changes were in the elastic tissue, which was fragmented, curled back and formed in clumps of disrupted fibrils, or found isolated in broken strands. Some of the fibres stained blue with Unna's polychrome methylene blue dye. No plasma cells, giant or xanthoma cells were found."

DISCUSSION.

DR. HEIMANN said that he had examined the tissue without having seen the case. The epidermis was perfectly normal; there was an increase of fibroblasts in the tissue, but not in any particular form of grouping, excepting in a few instances, where there were a few fibroblasts about the vessels. The most significant feature was the disturbance of the elastic fibres, as described in pseudoxanthoma; and some of the elastic fibres had undergone degeneration, forming the so-called elacin, so he concluded that the probable diagnosis was pseudoxanthoma elasticum. There were no xanthoma cells and no infiltration of any kind whatever.

DR. POLLITZER asked if there was any objection to labeling the case pseudoxanthoma elasticum.

PRURIGO NODULARIS. Presented by DR. WILLIAMS.

Previously presented. (See THE JOURNAL, 1915, p. 461.)

DISCUSSION.

DR. RAVOGLI said that he had been much interested in the case reported under this nomenclature, because one of his patients, a lady, had had similar skin lesions. These showed no thickening or hardening, which was characteristic of prurigo. He felt that he had to deal with a papular form of lichen, the papules being very hard, with tiny holes and grayish discolorations. The mucous membrane of the mouth and tongue, especially that of the cheeks, showed peculiar grayish folds which were characteristic of lichen affections, and for that reason he would prefer to call it lichen planus verrucosus corneus. In his own case, he gave injections of cacodylic acid, which improved the condition. The lesions were very hard and spontaneous involution was scarcely to be expected, but the application of resorcin plaster had helped a great deal. In some cases, the carbon dioxide snow had been applied to single lesions.

DR. SCHAMBERG said that the case presented by Dr. Williams was a replica of several cases published some years ago by Dr. Hirschler and himself. He believed that the term "prurigo nodularis," which was so aptly suggested by the late Dr. Hyde, was the best and most descriptive term for this multi-named affection. As regarded the treatment of this condition, he reported a case which had been communicated to him by a surgeon in Philadelphia who had given 15 grains of sodium cacodylate, hypodermically, three times a week, to a patient suffering from this affection, under which there was a great improvement in the itching and a partial disappearance of some of the lesions.

DR. ZEISLER said that the case was practically a counterpart of the one which he had presented before the St. Louis meeting, two years ago, and which had resisted all therapeutic efforts. These cases were identical with those classed as urticaria perstans, but the name prurigo nodularis seemed preferable.

DR. TRIMBLE said that Dr. G. T. Jackson had shown a case of prurigo nodularis at one of the meetings of the New York Dermatological Society, some time ago. The lesions were confined to the outer side of one thigh This case after-

ward fell into his hands, and after trying many kinds of treatment with no results, he excised all of the lesions. That was three years ago, and up to the present time none of them had returned.

Dr. Stelwagon said that he knew of cases,—including one of his own,—where excision was practised for biopsy, not for the purpose of a cure, and in these cases the lesions recurred. He therefore thought that surgical treatment was not indicated, his experience differing from that of Dr. Trimble.

PARAPSORIASIS (?). Presented by Dr. Brand for Dr. Trimble.

The patient, D. K., was a man, 29 years of age, born in Russia. The condition began one year ago, as two small, reddish spots on the forearms, which gradually increased in size and number. At the time of presentation, there were dark reddish, gyrate patches, slightly raised above the surface of the skin, located on the forearms, thighs and right buttock. The lesions were slightly itchy. The Wassermann reaction was negative.

CASE FOR DIAGNOSIS (LESIONS UNDER THE EYES.) Presented by Dr. Pollitzer.

The patient, Mrs. H., was 48 years of age, born in Austria. One year ago the lesions first appeared on the right, and four weeks later on the left side of the face. They caused slight pain and burning. Examination showed under each eye a semilunar, straw-colored patch, the upper border being one-half inch below the margin of the eyelid. The patches measured one-half inch in width and extended almost to the inner canthus. There was a faint elevation of the surface and on palpation, a dense infiltration, extending under the skin for a considerable distance beyond the surface of the discolored portion, in a sharply defined line, was noted. On the right side there were faint indications of teleangiectases at the border.

Discussion.

Dr. Pollitzer said that the diagnosis of xanthoma had been considered, but that it did not occur in these extensive patches. He knew of no case in the literature of extensive patches under each eye. Xanthoma tuberosum might occur on the face but it was rare in that location and always associated with nodules, disseminated over a large part of the integument. It was possible that it was a rapid infiltration with lipoids which gave a condition like xanthoma, but it was not the clinical picture of xanthoma tuberosum, and from the firmness and depth of the infiltration, xanthelasma might be excluded.

HYDROA VACCINIFORME. Presented by Dr. Whitehouse.

The patient was a girl, 6 years of age. She had suffered for four summers from the complaint, following sunburn or irritation from reflected light, thrown from the surface of a river, on the banks of which she lived. Each attack lasted a week to ten days, with about ten days' freedom. The eruption presented, her first winter's attack, began three months ago, during a warm period. The child was very susceptible to sunburn. The eruption was confined to the dorsum of the hands and extensor surface of the forearms, the ears, cheeks and bridge of the nose. Numerous scars marked the sites of former lesions. The lesions were vesicular, and would soon become necrotic and form scabbed areas which, upon falling, would leave characteristic scars.

RETICULATED SCARRING FOLLOWED BY COMEDO, Presented by Dr. MacKee for Dr. Fordyce.

Previously presented. (See The Journal, 1915, p. 494.)

MONILETHRIX. Presented by Dr. Rosen for Dr. Fordyce.

The patient, Helen B., was 12 years of age, born in New York City. She was one of four children, the others having normal hair and skin. The patient's disease started early in life. As an infant she had very little hair. When presented, the scalp was tight and thin. Over the temporal regions and on the back of the neck there was a well-marked keratosis pilaris. The hair was very sparse on the scalp. There were coarse, rather wiry hairs, five or six inches in length and similar hairs of about three or four inches in length. Most of the hairs, however, were of the lanugo variety and it was in these that the nodes or beads were found under the microscope. The scalp was of a mouse-gray color. The girl was of normal physical development but the mentality was a little below normal, probably because she had not attended school regularly. The Wassermann and von Pirquet tests were negative.

PAPILLARY DERMATITIS OF AXILLA. Presented by Dr. Trimble.

The patient was a factory girl, 22 years of age, born in the United States. The eruption had existed for seven years, and consisted of pale, intensely itchy, follicular lesions, about the size of the head of a small match. The lesions were mostly confined to the axilla, a few being present upon the pubes. The histological picture showed nothing especially characteristic. Considerable improvement had followed the use of strong resorcin lotion. The patient had a goitre that had developed in the past six weeks.

Discussion.

Dr. Engman said that he had seen two cases of this type in St. Louis and had been much interested in them. There was a destruction of the sweat glands and there seemed to be a preliminary hyperkeratosis of the epidermis and a plate-like horny layer which dipped down into the follicles and caused a dilatation of the sweat follicles, which produced the itching. This was so marked in the cases he had investigated that it was thought the women might have been using something to destroy the odor in the axillæ, but that was not found to be the case.

CONGENITAL ICHTHYOSIFORM ERYTHRODERMIA. Presented by Dr. Rosen for Dr. Fordyce.

The patient, Ethel McC, was a girl, 14 years of age, born in New York City. Her mother had died of pulmonary tuberculosis. Her father's death was the result of an accident. She had three sisters, all of whom were healthy. When the patient was an infant it was noticed that her skin was somewhat red and rough. This condition had steadily grown worse up to the time of presentation. This was the same patient who had been presented by Dr. Bulkley at the Sixth International Congress of Dermatology and at the September, 1909, meeting of the New York Dermatological Society, (*Jour. Cutan. Dis.*, 1910, p. 93), under the diagnosis of acanthosis nigricans. When presented to the Association, the skin of the face and neck was slightly thickened and of a brownish-red color.

The arms, back, part of the abdomen and chest were covered with a very much thickened, brownish-black, horny layer. The appearance was that of an exaggerated ichthyosis. When this thickened horny layer was removed the underlying skin was a red color. On parts of the abdomen and chest the skin was only slightly thickened but was red in color. The color was especially noticeable along the margin of the ichthyotic portions. The skin of the hands, feet, lower legs and forearms was red and thickened. There was no perspiration. The nails and hair were normal. The general health was good and the mental development was normal. The internal organs were sound. The Wassermann reaction was negative.

Discussion.

Dr. Whitehouse said that he was much interested to see the case again, as it had been under his observation at the Skin and Cancer Hospital for a number of years, and a number of diagnoses had been made. They finally concluded that it was erythrodermia ichthyosiforme. At one time it was presented as a case of acanthosis nigricans, but the character of the lesions changed from week to week, clearing up and then developing somewhere else, conforming to the clinical type described under the diagnosis as presented. It responded to no form of treatment, and had developed much since he last saw it.

WHITE SPOT DISEASE. Presented by Dr. Heimann.

The patient, C. M., was a woman, 25 years of age. The illness began within the last year. There were no subjective symptoms. During three months of observation, there was no extension of the disease. There appeared to be a tendency for the lesions, particularly on the back, to atrophy. The histological examination was as follows: Epidermis thin, papillary body gone, apparently due to loss of rete pegs. Collagen swollen and glassy and poor in nuclei, elastica fragmented and in places lacking, very slight dilatation of some of the deeper vessels, with a slight nondescript infiltration about them, consisting of young fibroblasts. The picture suggested that of scleroderma after atrophy had set in. No infiltration indicating lichen planus was to be seen.

ACRODERMATITIS CHRONICA ATROPHICANS. Presented by Drs. Kingsbury and Bechet.

The patient was a woman, 27 years of age. The condition had appeared simultaneously on the lower legs and the right forearm about one and a half years ago. When she first came under observation, she was in an advanced state of pregnancy and the legs were of a dark red color. Since the birth of the child this color had largely disappeared. The condition on the right forearm had not changed. The Wassermann reaction was negative.

SCLERODERMA. Presented by Dr. Gottheil.

The patient, Annie H., was a married woman, 39 years of age. She had had the affection for more than eight years. It began as reddened, raised, hard patches on the backs of the hands, which subsequently became white and atrophic. Similar patches appeared on the arms, feet and legs, and finally upon the trunk, until the fully developed picture of scleroderma and sclerodactylia was developed. The interesting feature of the case was the fact that the affection was a definite scleroderma from the beginning, not a dermatitis atrophicans

with subsequent atrophy and contractures. On the shoulders and neck and thighs were the most recent lesions, sclerodermatous patches and infiltrations, in otherwise apparently unchanged skin. There was absolutely no trace of any antecedent or preceding inflammatory process.

CASE FOR DIAGNOSIS. (Bullous eruption.) Presented by Dr. Stevens for Dr. Fordyce.

Previously presented. (See The Journal, 1914, p. 145.)

DISCUSSION.

Dr. Wile said that he felt that this case was to him the most interesting shown at the meeting, and he desired to ask Dr. Fordyce and Dr. MacKee whether a neurological examination had been made in this case. The extensive atrophy and distinct localization of the bullæ to the fingers and hands were at least suggestive to him of the changes which occurred with syringomyelia or erythromelalgia.

Dr. Zeisler said that the case had interested him very much also, and he had intended to ask about it, until Dr. Wile and Dr. MacKee had spoken about it. One important point to be observed was the formation of milium on the face. He had seen this in many cases.

Dr. Fordyce said that the case had been under his observation for six or seven years. Preceding the development of her skin lesions she had an arthritis of the wrist, which had resulted in ankylosis. After this she developed bullous lesions on the skin and mouth. Later on, her gums became spongy and bled easily. She had presented, at various times during the period of observation, recurring bullæ, purpuric lesions and eruptions like erythema multiforme. Her general health had not materially suffered. He had been unable, by any investigation, to determine the nature of the affection. Cultures from the bullæ were sterile, and the blood examination was negative. The case impressed him as one owing to sensitization of the skin, by some unknown agent.

GENERALIZED TELEANGIECTASIA with SYPHILIS. Presented by Dr. Goldenberg.

The patient was a woman, 40 years old, born in Russia. The family history was negative. She had been married 20 years and had had one child, 19 years old, one miscarriage in the second month, 9 years ago, one still-born child at full term, 3 years ago. Following the last confinement the patient noticed discoloration over both elbows, later upon the face and ears and breasts, abdomen and lower extremities. For the last two years she had complained of pain and difficulty in swallowing, and headaches. X-ray examination of the chest was negative. There were no signs of substernal struma, no mechanical œsophageal obstruction. There was no exophthalmos. Tachycardia was present. The Wassermann reaction was three plus. The affected parts were the face, ears, elbows, abdomen, breasts, knees and lower legs and hands. The eruption was in the main symmetrical and diffuse, and consisted of a bluish-red erythema of the face and ears and dark livid discoloration of the other parts, resembling post mortem hypostasis ("cadaver skin"). On closer inspection, especially on pressure, a network of capillary vessels was observed. On the flexor surface of the right arm and on the chest, a few pin point angiomata were observed; over the fifth finger of the left hand, an irregular teleangiectatic macule the size of a dime, was found. There was slight atrophy of the skin over both breasts. There was no scaliness and there were no subjective symptoms. The weight of the patient was 190 pounds. She had lost 30 pounds during the last year, under thyroid treatment.

DISCUSSION.

Dr. Zeisler said that it was difficult for dermatologists to label some cases accurately and he thought this one was diagnosed in an unfortunate way. Teleangiectasis meant an enlargement of the ends of the blood vessels. In this case we had primarily a venous stasis of considerable extent, while the teleangiectatic spots were merely an incident.

Dr. Pusey said that he had been interested in these cases lately because of Dr. Stokes's paper, to which Dr. Goldenberg had referred. The probable explanation of the pathological process was very interesting. As a result of syphilitic endarteritis in the small vessels, many of them were obliterated and there resulted compensatory dilatation of other small vessels, giving rise to the clinical changes seen in this condition. The pathology thus was similar to that of teleangiectasia in X-ray scars.

Dr. Ravogli thought the condition was not dissimilar to that described by Hermann as cutis marmorata, often found in syphilis. There was rather an effusion of the coloring matter of the blood, than a true dilatation of the blood vessels. He had not infrequently found that condition in syphilitic women with a tendency to be fat and well-developed.

Dr. Wile thought it a counterpart of the case described by Dr. Stokes in the *American Journal of the Medical Sciences*. In the case Dr. Stokes described, it was thought that the pathological condition might be due to an aneurysm of the capillaries.

CASE FOR DIAGNOSIS (SARCOID OF BOECK? NÆVUS?). Presented by Dr. Goldenberg.

The patient was a boy, 3 years of age. He was first seen in December, 1913. He presented four tumors on the face, one on the chin, about the size of a bean, and three smaller ones, the size of a split pea, on the cheeks. The first tumor had appeared at the age of three months. The diagnosis of sarcoid was then made. The von Pirquet test was negative. The patient then disappeared until one week ago, when he presented a number of new lesions, firm, elastic, red in color, with purplish teleangiectases on the face, body and arms. The first lesions, seen one and a half years ago, had not undergone any involution. A peculiar feature was that the lesions were found on the left side of the body only, and that freckles were found on the left side of the face. A biopsy was refused. (After presentation, the mother consented to have a small lesion excised. Microscopical examination showed a fibroma.)

DISCUSSION.

Dr. Schamberg said that the distribution of the eruption in this child, involving as it did the left side of the face, the left hand and arm, suggested in the strongest manner possible, a pigmentary papillary nævus. While some of the individual lesions, taken by themselves, suggested sarcoid, yet the unilateral distribution and general appearance of the eruption would, in his mind, negative such a diagnosis.

LICHEN RUBER ACUMINATUS, ASSOCIATED WITH LICHEN PLANUS. Presented by Dr. Goldenberg.

The patient was a woman, 21 years old. The duration of the eruption was three years. She was first seen six weeks ago, with typical lichen planus lesions on the interscapular region and a linear patch on the forehead, composed of

lichen planus papules. Under treatment with protiodide of mercury, the latter had been improved to such an extent that they could hardly be recognized at the time of presentation. There was, however, no doubt as to the presence of typical lichen planus. On the upper and lower extremities, more on the extensor than the flexor surfaces, were disseminated patches of acuminate, follicular; papular lesions. In the interscapular region a patch of fading lichen planus papules were still present. The itching was very pronounced. There were no lesions on the dorsum of the fingers or on the mucous membranes. A small lesion of the acuminate type was excised and showed microscopically the changes of "lichen ruber acuminatus follicularis." The corneous layer was thickened, especially around the mouths of the follicles, which were filled with horny, laminated cells. The stratum granulosum was thinned and in most places composed of two or three layers of cells. The Malpighian layer showed no œdema but a few inflammatory and a few wandering cells. The subpapillary region showed small round cell infiltration. Around the follicle was a moderate round-cell infiltration and increase in the connective tissue cells was found.

DISCUSSION.

Dr. McEwen said that Dr. Goldenberg's case was very similar to one which he had seen in Chicago. The patient was a woman in whom the spinous lesions developed after lichen planus had disappeared. The case had been shown at the Chicago Dermatological Society, and there had been no unanimity as to the diagnosis, in the discussion which followed. There was great need for a classification of names which might be attached to conditions like this, *i.e.* lichenoid lesions about the hair follicles. He was not convinced that this case should be called one of lichen ruber acuminatus.

Dr. Zeisler said that the case showed that, after all the efforts that had been made to clear up the lichen question, we were occasionally confronted by cases which showed that our forbears were right in establishing two varieties of lichen ruber. In the present instance we had both varieties, simultaneously, in the same patient and we had no right to consider them as separate conditions. Morphologically, the lesions on the back were typical of lichen planus, the others were those of lichen ruber acuminatus or pityriasis rubra pilaris.

Dr. Engman deprecated the war of words in relation to names. He did not see why there should be any great dissertation in relation to the names of a syphilitic papule, whether it be miliary or lenticular. Lichen planus was a definite thing, clinically and histopathologically,—one of the few things the histopathologists could recognize without a clinical diagnosis. This was a polymorphic disease, and therefore had many phases, both in its clinical manifestations and some of its histological features; but the fundamental infiltration was a distinct entity in its location, type of cell, distribution of cell and several other features. Lichen planus was a constitutional disease in that it resembled syphilis, therefore it might have a plain papule or pointed papule, situated according to its relation to various anatomical positions in the skin. It might produce rings from a papule which spread peripherally, sink in the centre, form atrophic areas, and in fact its whole clinical ensemble was that of the specific infectious disease. He, therefore, believed the process should be looked upon, not in a narrow clinical or morphological way, but with a broader view of a systemic disease with polymorphic cutaneous symptoms.

Dr. G. H. Fox said that he had had the pleasure of studying under Hebra, who first described lichen ruber, but it was from the study of numerous cases in this country that he was led to question the diagnosis. He thought this was a case

of circumscribed follicular keratosis, which usually remained stationary, and did not tend to spread over the body. In lichen ruber the conical lesions, which looked somewhat like the lesions in this case, soon became tipped with the white scale, and by confluence produced scaly patches or bands. He ventured to say that this case would never present the diffuse scaly patches which were invariably found, sooner or later, in Hebra's disease.

Dr. Goldenberg remarked that there was no doubt that the patient had presented typical lesions of lichen planus which, though greatly modified by the treatment, were still present. He took exception to the statement, made by one of the speakers, that the presence of lichen planus lesions itself spoke against the diagnosis of lichen ruber acuminatus. The case belonged to the follicular type of lichen ruber.

POLYGLANDULAR SYNDROME. Presented by Dr. Goldenberg.

The patient was a man, 28 years of age, born in Austria. He was admitted to the medical service of Mt. Sinai Hospital (service of Dr. E. Libman) in October, 1914, on account of general malaise, headache, enlargement of the hands and feet and tumors of the face, trunk and extremities. Seven months before admission, he had noticed that his hands and feet were becoming larger. While he formerly wore a 7½ size shoe, he required a size 9 shoe. At the same time he noticed a mass over the bridge of the nose, soon followed by similar masses on other parts of the body. There was no history of syphilis and the Wassermann reaction was negative. The features of the face were distorted by bony masses along the bridge of the nose and by semisolid tumors of the skin, of normal skin color and without signs of inflammation. They varied in size from a small pea to a chestnut. Similar tumors, partly osseous, partly located in the skin, were found over the left metacarpal bone, over the phalanges, over the heads of the radii, the acromial ends of the scapulæ, the hips, knees, heads of fibulæ and dorsal surfaces of the feet. The body tumors, about twenty in number, were all symmetrical, the skin tumors less so. Beside the distinct tumors of the skin, there was a diffuse infiltration of both forearms and hands. On the extensor surfaces of the forearms and hands were noted a large number of pea-sized papules, not unlike those seen in lymphatic infiltration of the skin. In short, we had to deal with bony tumors, with skin tumors and with infiltrations of the skin. The urine examination was negative. No Bence-Jones albumin. The blood count was as follows: White blood cells, 17,200; polynuclears, 84%; small lymphocytes, 10%; large lymphocytes, 3%; eosinophiles, 2½%; basophiles, ½%. The isthmus of the thyroid gland could be felt. X-ray examination showed marked gaping of the lambdoid and coronal sutures. The sella turcica was not enlarged, but the anterior and posterior clinoid processes were unusually thin. The frontal sinuses were enlarged antero-posteriorly. There was a marked thickening of the soft sinuses in the frontal regions. The long bones of the extremities showed enlarged heads and bases.

A small tumor was excised from the skin over the left elbow. The microscopical picture showed a myxomatous degeneration of the corium without any infiltration or tumor formation. The diagnosis of acromegaly and polyglandular syndrome (dyspituitarism and dysthyroidism) was made and the patient put on thyroid extract. At the time of his stay in the hospital the dose was increased to 25 grains a day. After his discharge, the dose was decreased to one grain twice daily. Under this dose, given for the last three months, a wonderful improvement was noticed, the patient had lost his general malaise, diarrhœa and headaches, and was able to resume work. The skin tumors and even the bony tumors had decreased to about one-half of their size when the patient had been

admitted to the hospital. The rapid yielding of the bone and skin tumors to the thyroid medication was comparable to luetic lesions yielding to antispecific treatment, although much slower.

DISCUSSION.

Dr. Schamberg said that some comment should be made upon this most interesting case. He could add no word of enlightenment to the already splendid elucidation of the case, by Dr. Goldenberg. If the diagnosis of diseases of the thyroid and pituitary glands was ultimately substantiated, it would shed an important illumination upon the relation of the ductless glands. The fact that the patient had improved so remarkably under the use of small doses of thyroid extract was a very important communication.

ERYTHEMA MULTIFORME PERSTANS. Presented by Dr. Robinson.

The patient was a girl, 11 years of age. At the age of five she had had a similar eruption on the face, arms and legs, lasting five and a half months. The eruption was of six months' duration. It was generalized and tended to form large, circinate areas. New lesions were constantly forming, while the older ones had not yet disappeared. One month ago, all the lesions were of circinate form with clear centres, ranging from one to two and a half inches in diameter. The red margins were about a quarter of an inch in width. The patient complained of intense itching.

DISCUSSION.

Dr. Wendt said that he was strongly inclined to include this case among the anomalous types of erythema multiforme. He had met similar conditions of persistency in an adult, the disease having existed for more than a year. He said that it had been suggested that this case corresponded to a group of cases reported by him in The Journal, 1906, XXIV, p. 241, under the term erythema figuratum perstans. Under the general heading of erythema perstans, several disorders had been described, including some instances of unusual erythema multiforme. He believed there should be a distinction between the case under discussion and those reported in his article, the latter being instances taken from the literature, which offered an individuality sufficient to form a group by themselves. The group which he reported began with papules, which tended to fade in the centre, while extending peripherally, forming circinate outlines the size of a twenty-five cent piece or even as large as the palm of the hand; they showed all sorts of configurations, circinate, discrete, confluent, gyrate or zigzag. Exacerbations occurred three or four times a year. Subjective sensations not infrequently occurred. Most of the cases began in childhood. He said that verbal descriptions of these cases made them strikingly resemble the case presented, but if placed side by side the difference would be very apparent, so that it was his belief that they were separate and distinct conditions.

Dr. Stelwagon said that this was known to be a rare condition, but from its objective character we had to acknowledge the possibility of chronic erythema multiforme. He had seen two of these cases. The attack might be more or less general, beginning as papules, sinking in the centre and developing into rings, eight, nine, ten or more inches in diameter, and finally disappearing after lasting for six, seven, eight, nine or more months. There was an entire absence of constitutional symptoms, but troublesome itching was usually complained of. One of his patients had had an attack several years before, which lasted eleven or twelve

months and then disappeared. The second case had lasted five or six months and looked like the case presented by Dr. Robinson, but was now practically well. The speaker could not say that treatment had the slightest effect on the disease, and what produced the disease and why the patient got well, he did not know. In the belief that a gastro-intestinal origin was possible, his treatment had been based upon that suggestion.

Dr. Haase cited a similar case which gave a positive Wassermann, and cleared up under treatment. When the treatment was stopped it recurred, and again disappeared under treatment.

Dr. G. H. Fox said that we all know that erythema multiforme usually disappeared in a few weeks. Years ago he had noticed that cases of circinate erythema were more persistent than the paplar erythema on the face and arms. He thought that Dr. Robinson had added one to the many forms of erythema multiforme.

PARAPSORIASIS IN PATCHES. Presented by Dr. Wallhauser.

The patient, H. W., was a man, 50 years of age, born in the United States. He presented an eruption on the upper and lower extremities which appeared about twenty years ago and remained practically unchanged, varying only in color intensity. It consisted of variously shaped, quite sharply defined, pale brownish-red plaques with moderate scaling, varying from one-half to several inches in diameter. The eruption was superficial in character, generally even with the skin surface; in a few locations, however, it was slightly raised and more sharply defined, but entirely devoid of infiltration. There were no subjective symptoms, except a slight burning sensation, at rare intervals. The patient was of a robust, healthy type.

LICHEN RUBER ACUMINATUS (?) Presented by Dr. Trimble.

Previously presented. (See The Journal, 1914, p. 722.)

DISCUSSION.

Dr. Pusey said that in his opinion, Dr. Trimble's case simply showed lichenification of the skin as the result of some chronic dermatitis. He did not think it was pityriasis rubra pilaris.

Dr. G. H. Fox said that this was another case in which he was confident that the characteristic symptoms of lichen ruber (pityriasis rubra pilaris) would never occur. It was very strange that Hebra, with his immense experience, never saw or at least never described lichen planus. Wilson, who gave such a fine description of lichen planus, was apparently not familiar with the lichen ruber of Hebra. Kaposi, who wanted to include the English disease with that described by Hebra, erroneously described them as two phases of the same disease under the names lichen ruber acuminatus and lichen ruber planus. The speaker said he thought that nearly all dermatologists were agreed that lichen ruber and lichen planus were distinct diseases. When this was admitted, there would be no necessity of using the term lichen ruber acuminatus for the lesions of lichen ruber were always acuminate at the outset, nor the term lichen ruber planus, for the flat papules of lichen planus had nothing to do with lichen ruber.

Dr. Schamberg said that the case presented as lichen ruber acuminatus exhibited as its most striking manifestation, lichenification and severe itching; he thought that the case should be classified in the group described by the French "neurodermite," or the "Neurodermatitis" of the German authors.

EPIDERMOLYSIS BULLOSA. Presented by Dr. Trimble.

Previously presented. (See The Journal, 1915, p. 493.)

DISCUSSION.

Dr. Pusey agreed with the diagnosis, and he took part in the discussion only to bring up the point of the value attached to milium bodies, in the diagnosis of pemphigus. In his experience, milium not infrequently occurred in various inflammatory conditions of the skin, particularly if bullæ had formed, as after X-ray burns, and, indeed, in epidermolysis bullosa itself. He did not believe the existence of milia could be urged as confirming a diagnosis of pemphigus.

Dr. Engman said that the case seemed to him to be a typically severe one of epidermolysis bullosa. He and Dr. Mook had studied five cases, histologically. According to the findings, the diagnosis could always be made by microscopic examination of the skin, in which elastic tissue was found to be absent or deficient in the upper part of the derma. This was the characteristic feature. In regard to the miliary bodies, they were merely cysts caused by atrophy of the skin. They were seen in pemphigus, and in burns and in any superficial scarring of the skin.

Dr. Gottheil said that he saw perhaps half a dozen cases of pemphigus a year, one or two usually during his six months' term of service at the City Hospital, and the others among the Russian and German immigrants on the east side of the city. Apparently the disease was commoner among these people than in the rest of the community, and next commonest among the Italians. He could recollect but two cases in many years, that had appeared in native-born Americans. Every one of these cases had died, and some of them in quite a short time. In two recent private cases the entire time from the appearance of the first bullæ, in both cases on the buccal mucosæ, to the fatal termination, had not been longer than three months. On the other hand, two or three cases of apparent pemphigus, one of which he had himself recorded as benign pemphigus, and in which there was absolutely no systemic involvement, were still alive and in good general health; and careful and extended observation had led him to the conclusion that these were not cases of pemphigus at all, but cases of epidermolysis. He would restrict the term pemphigus to the cases of more or less acute course, with marked sepsis; and in these he regarded the prognosis as absolutely hopeless. Arsenic in any form, and pushed to any extent, had done no good in his hands; salvarsan had even seemed to be hurtful. Stimulated by the published record of 18 cases of pemphigus treated with autoserum injections in Vienna, and all cured, he was now using that treatment in these cases; but the most that he could say was that it seemed to do good sometimes; it improved the patients' condition and postponed the fatal termination. The speaker had heard, from private sources, a possible explanation of the astonishing Viennese statistics; it is stated to be the custom there to call every case showing bullæ, pemphigus. If that were so, the 18 cured cases might include cases of bullous impetigo, epidermolysis bullosa, and other affections that were not true pemphigus at all.

CASE FOR DIAGNOSIS (BULLOUS ERUPTION IN A CHILD). Presented by Dr. Howard Fox.

Previously presented. (See The Journal, 1915, p. 481.)

SARCOID (BOECK). Presented by Dr. MacKee for Dr. Fordyce.

Previously reported. (See The Journal, 1915, p. 770.)

Dr. Pollitzer said that a case in which a diagnosis of sarcoid could not be made under the microscope could not be sarcoid, as the picture under the microscope was perfectly characteristic. He thought that diagnosis should be ruled out.

CUTANEOUS TUBERCULOSIS. Presented by Dr. MacKee for Dr. Fordyce.

The patient was a negro, 20 years of age. The eruption began eight years ago, as an ulcer of the mucous membrane of the hard palate. Later, the disease involved the mucosa of the fauces and nose. Later still the disease involved the skin on the nose, where a large vegetating lesion developed. When presented to the Association there was a serpiginous lesion, involving both cheeks, the nose and the upper lip. The edge of the lesion was of the ulcerating and vegetating character. The upper lip was markedly œdematous. The mucosa of the hard palate and fauces was studded with vegetations and small ulcers. There had been no improvement under tuberculin injections, but the X-ray had caused a disappearance of the vegetating lesion on the nose.

DISCUSSION.

Dr. Gottheil said that this case had been under his observation and care at intervals for two years past, during which time there had been a steady progression in the disease. When first seen, it was present on the hard palate, where it had begun, and on the alæ nasi; and it presented the picture of a typical lupus tumidus. Treatment had been varied and energetic, and had included a very large number of tuberculin injections, pushed to the point of tolerance, and local destructive measures. Though there had been some apparent recession of the tumor masses in the centre of the lesion, it had steadily progressed peripherally; until practically the entire face was involved. A moulage in the collection that the speaker had exhibited at the meeting showed the condition as it was about a year ago; and it was evident that the disease process had extended to about twice its area during the intervening time. He regarded the case as a rather hopeless one.

CASE FOR DIAGNOSIS. Presented by Dr. Hailperin for Dr. Trimble.

The patient, A. S., was a man, 29 years of age. He was under treatment for spinal syphilis. He had had several intravenous and one intraspinous injection of salvarsan. Recent treatment had consisted of mercury and potassium iodide. The eruption for which the patient was presented began about three months before, first at the bend of the elbows, then over the arms and then on the trunk and lower extremities. Recently several patches had appeared on the neck. The eruption consisted of numerous circular, oval and irregularly shaped, reddish patches, somewhat infiltrated and most of them slightly scaly. Fresh lesions were distinctly oval, and except for the more marked infiltration, might have been mistaken for pityriasis rosea. The patient stated that the eruption itched at times.

DISCUSSION.

Dr. Ravogli said that he had often seen cases resembling psoriasis following, and at times accompanying, a syphilitic condition. There was no doubt that this

man had syphilis. The Wassermann was positive, his mouth showed syphilitic lesions and the eruption had not even been modified by salvarsan. It was known that in psoriasis salvarsan had no effect whatever. He had noted some peculiar scaly eruptions on the elbow, described as keratosis psoriasiformis, which were extremely obstinate and difficult to remove. He had always maintained that some scaly eruptions and also some kinds of psoriatic affections might be related to an old syphilitic process.

SARCOMA (PERITHELIOMA). Presented by Dr. Baughman for Dr. Trimble.

The patient was a man, born in Austria, a window cleaner by occupation. About two years ago the nose had begun to enlarge, until it was four to five times its original size. The enlargement had been preceded by headaches, bone pains and alopecia. There was no history of syphilis, the Wassermann reaction was negative, and there had been no improvement under antisyphilitic treatment. The diagnosis of sarcoma was made from a histological examination, by which rhinoscleroma had been definitely excluded.

DISCUSSION.

Dr. Zeisler said that he had thought it closely resembled rhinoscleroma. The location, the hypertrophied condition of the nose, involving also the upper part of the lip, corresponded to rhinoscleroma.

CASE FOR DIAGNOSIS (BULLOUS ERUPTION IN A YOUNG CHILD). Presented by Dr. Howard Fox.

Previously presented. (See The Journal, 1915, p. 481.)

LUPUS ERYTHEMATOSUS. Presented by Dr. Gilchrist.

The patient was a man, 38 years of age. The attack had lasted, off and on, for three years. The lesions appeared as dull reddish, well-defined areas on the right cheek. The patient was first seen six months ago. He then had five variously sized, well-defined, deep reddish, smooth, dry, erythematous lesions on the right cheek and right side of the neck, just below the jaw. They varied from a dime- to dollar-sized patches. During the last six months no form of treatment had produced any benefit. New lesions had appeared on the left side of the face and neck, similar in character to the first ones. There was never any scaling, atrophy, or subjective symptoms. His health was good. There was no history or signs of tuberculosis, no history or signs of syphilis. The most probable diagnosis was lupus erythematosus, although the clinical appearance was somewhat against this diagnosis.

ACRODERMATITIS CHRONICA ATROPHICANS. Presented by Dr. Wise for Dr. Fordyce.

Previously presented. (See The Journal, 1914, p. 143.)

ACRODERMATITIS CHRONICA ATROPHICANS. Presented by Dr. Wise for Dr. Fordyce.

Previously presented. (See The Journal, 1914, p. 377.)

ADENOMA SEBACEUM. Presented by Dr. Gottheil.

The patient, Vera H., was a girl, 6½ years of age. Minute puncta had been noticed on the forehead, when she was three years of age, which had slowly increased in size and number. She had suffered from measles five weeks ago, at which time the eruption had rapidly increased, lesions on the chin and nose having appeared during this time. The patient was mentally deficient and an epileptic, having had frequent attacks of petit mal, since she was seven months of age.

PRESSURE ATROPHY. Presented by Dr. Anderton for Dr. Fordyce.

The patient was a young girl who presented a deep transverse sulcus at the bridge of the nose, due to the pressure of the nose-piece of her spectacles. There had never been any abrasion or ulceration. The skin was intact, although trophic and slightly red. The depression was caused mainly by an atrophy of the deeper tissues.

CAVERNOUS ANGIOMA OF HARD PALATE. Presented by Dr. Weiss.

The patient, J. G., was a man, 18 years of age, born in Russia. No member of his family had suffered from a similar condition. On the left side of the hard palate there was an irregular cavernous mass, about an inch long by a half inch wide, nodular, spongy and bleeding easily. A year ago he had noticed bloody expectoration. His speech was somewhat impaired and when the lesion became swollen there was slight pain.

CAVERNOUS ANGIOMA OF THE LOWER LIP. Presented by Dr. Weiss.

The patient, I. S., was a man, 20 years of age, born in Austria. He thought that his father had suffered from a similar condition. He presented a congenital, diffuse cavernous angioma on the right side of the lower lip, extending from a point near the centre, toward the mouth and occupying the right border of the tongue and part of the buccal cavity.

BLASTOMYCOSIS. Presented by Drs. Kingsbury and Bechet.

The patient, P. C., was a man, 70 years of age. He stated that the eruption had appeared about one year ago, first as a small "pimple" on the right cheek, which he constantly wounded in shaving. Within a few months, other lesions appeared, gradually assuming the condition presented. The patient was in good health and there were no indications of constitutional involvement. He had been a horse car driver for thirty years and a motorman for eighteen years. The Wassermann reaction was negative. The pathological report was as follows: "January 16th, 1915. Complement fixation reaction, positive (three plus), using a saccharomyces organism (Everett) for antigen. March 15th, 1915. Section removed from lesion on forehead, one half cultured, other half run through entire. Slight hyperplasia of the rete, polynuclear cells and nuclear fragments and few spores in spaces between cells of rete, which, in places, showed flattening. Subacute inflammatory changes in the corium. Small abscesses showed polynuclear cells, round cells, fibroblasts, mast cells and spores, varying in size between small and large lymphocytes, which, with special staining, showed a faint capsule. Some of the smaller spores were refractile. The organism grown from the piece of tissue cultured, belonged to the saccharomycetes and was a

cryptococcus. It had been injected into two guinea pigs. April 4th, 1915. Complement fixation reaction, using the organism isolated in making the antigen, was to be tried when an immune serum had been obtained."

EPIDERMOLYSIS BULLOSA ACQUISITA. Presented by Dr. Ochs.

The patient was a man, 41 years of age. The condition had existed for two years. Following a traumatism, bullæ would appear within three to eight hours, many of them becoming hæmorrhagic. After disappearing, pigmentation was left. The lesions were present upon both hands and on the feet and legs. (For a full report, see The Journal, June, 1915, No. 6.)

ERYTHEMA MULTIFORME PAPULOSUM. Presented by Dr. Weiss.

The patient, S. S., was a man, born in Austria, 42 years of age. He stated that he suffered every spring and fall, especially the former, from an attack of sore throat and swollen uvula, after the cessation of which the eruption would make its appearance, accompanied by headache and general malaise. The eruption consisted of papules on the dorsal surfaces of both hands and upon the ears and nape of the neck.

FIBROMA MOLLUSCUM (2 CASES). Presented by Dr. Rothwell for Dr. Trimble.

Previously presented. (See The Journal, 1910, p. 186.)

FOLLICULITIS DECALVANS. Presented by Dr. G. H. Fox.

Previously presented. (See The Journal, 1915, p. 855.)

GRANULOSIS RUBRA NASI. Presented by Dr. Trimble.

The patient was a boy, 13 years of age. The duration was as long as he could remember, probably five years or more. He presented numerous pin point, deep red papules upon the nose. Drops of perspiration were constantly present, and if by chance they were wiped off, they would almost immediately reappear. The case corresponded closely with the usual description of the text books.

KELOID OF THE EARS. Presented by Drs. Howard Fox and Ochs.

The patient was a colored girl, 17 years of age. Her ears had been pierced when she was ten years old. Two years later, keloids began to appear. They had steadily increased in size up to the time of presentation, when she presented pendulous masses hanging from the lobules, the size of a small mandarin orange. They had been removed four times by operation and she stated that she had received forty X-ray treatments, without appreciable benefit.

KERATOSIS FOLLICULARIS (DARIER). Presented by Dr. Whitehouse.

The patient was an Italian girl, 23 years of age. The trouble began ten years ago with a roughness on the sides of the neck. Later, a roughness appeared in the axillary region and groins, and a year or two later, lesions appeared on the body, palms and soles and a scaly condition of the scalp. On examination, the

scalp showed a seborrhœic condition with tendency to crusting, with no loss of hair. On the sides of the neck, temples, chest and abdomen were numerous brownish, keratotic papules, tending to become confluent and form warty areas. In the groins and axillæ were papillomatous keratotic masses, softened and macerated by the secretions, with some odor. The palms and soles presented a moderate, yellowish, keratotic condition with minute punctate depressions over the thickened areas.

KERATOSIS FOLLICULARIS (DARIER). Presented by Dr. Trimble.

Previously presented. (See The Journal, 1913, p. 113.)

The patient, Augustus S., was born in the United States, a driver by occupation. Four other members of his family, his mother, his sister, brother and nephew, suffered from the same disease. The eruption in his case began on the feet, six years ago. He showed lesions on the face, ears, chest and arms. There was also marked keratosis of the palms and soles. Microscopic examination showed the presence of so-called psorosperms.

KERATOSIS FOLLICULARIS (DARIER). Presented by Dr. D. M. O. Robinson.

The patient was a woman, 18 years of age. There was no history of a similar disease in any member of her family. The eruption began at the age of nine, appearing first upon the hands. It was worse during the summer, at which time itching was present. The diagnosis had been confirmed by a microscopical study of a large number of sections. It seemed probable that the disease had formerly resembled a seborrhœic eczema, as that diagnosis had been made by a number of dermatologists.

KERATOSIS FOLLICULARIS (DARIER). Presented by Drs. Howard Fox and Ochs.

Previously presented. (See The Journal, 1916, p. 222.)

KERATODERMIA PALMARIS AND PLANTARIS. Presented by Dr. Wallhauser.

The patient, W. C. C., was a man, 31 years of age, born in the United States. He presented a marked hypertrophy, limited to the palms and soles. The palmar and plantar surfaces were greatly thickened, smooth, and of a translucent, grayish-white color. The natural lines were exaggerated, presenting depressions of about one-eighth of an inch in depth. The only unpleasant feature regarding the condition was a disposition to fissuring. An hereditary history was strongly manifested on the maternal side, the grandmother, mother and two aunts having had a similar condition. In the present generation, a brother and sister were affected, also a brother's child. In all, eight cases were noted.

LEPROSY (NODULAR TYPE). Presented by Dr. Dearborn.

The patient, Sam V., was a man, 50 years of age, born in Russia, a shoemaker by trade. His mother-in-law was said to have been a leper, and lived with his family. The disease first appeared twelve years ago. The first symptoms were tingling, burning and sweating of the palms and soles, which lasted for two years. Large macular areas then appeared on the right leg. The hands and

face were next involved. He became blind three years ago. He presented a marked form of the nodular type of the disease.

LEPROSY (NODULAR TYPE). Presented by Dr. Dearborn.

The patient, Percy B., was a colored boy, 13 years of age, born in the West Indies. He had resided in the United States during the past nine years. The family history was negative. Five years ago, nodules appeared on the nose and cheeks, and two years ago, upon the leg. At the same time a nodule, which had appeared on the right elbow, ulcerated. The feet were anæsthetic. He never complained of pain.

LEPROSY (NODULAR TYPE). Presented to Dr. Dearborn.

The patient, Wilfred R., was a white man, 22 years of age, born in the West Indies. The family history was negative. The disease first appeared five years ago as a nodule on the side of the nose, other nodules appearing later on the lips, chin and cheeks, successively.

LEPROSY (MIXED TYPE). Presented by Dr. Dearborn.

The patient, A. T., was a man, 40 years of age, born in Greece. The family history was negative. Ten years ago the patient had a macular eruption on both legs. Later nodules appeared which became ulcerated and finally healed. Areas of anæsthesia then appeared on the legs and arms. The mucous membranes of the mouth, throat and nose were severely inflamed. Both hands were badly swollen. There were no nodules on the face. The patient suffered no pain.

LEPROSY (NODULAR TYPE). Presented by Dr. Trimble.

The patient was a young man, 18 years of age, born in Italy, a fish dealer by occupation. He had been in this country ten years. The duration of the disease was about three and one-half years. He had, scattered over the face and extremities, deep-seated, citron-colored nodules, varying in size from a match head to a split pea. The patient had recently suffered from an attack of leprous fever, accompanied by an acute outbreak of lesions, which were quite erythematous at first, but later took on the usual character as to color, etc. The pathological specimen showed the usual picture, with great numbers of the Hansen bacillus present.

LEPROSY. Presented by Dr. Blancard for Dr. Fordyce.

Previously presented. (See The Journal, 1913, p. 780.)

LICHEN PLANUS OF MOUTH AND TONGUE. Presented by Drs. Pollitzer and Satenstein.

The patient, I. S., was a man, born in Russia, a cabinet-maker by occupation. The eruption first appeared four months ago, on the tongue, attaining its full development in five weeks. It was situated on the tongue, buccal mucosa, uvula and anterior pillars of the fauces.

LICHEN PLANUS ANNULARIS LIMITED TO THE PENIS. Presented by Dr. Wise.

The patient was a colored man, born in the United States. The eruption was

limited to the shaft of the penis and consisted of a number of annular lesions and raised plaques, which had existed for five months.

LICHEN PLANUS OF PENIS AND TONGUE. Presented by Dr. MacKee for Dr. Fordyce.

The patient was a man, 33 years of age, born in Austria, a painter by trade. The eruption had existed one year. There were numerous white, flat, square, coalesced papules on both sides of the dorsal surface of the tongue. There were, also, a number of violaceous, flat-topped, polygonal, discrete and confluent papules on the penis. There were no lesions on the skin. The patient stated that he had never had a previous eruption. There were no subjective symptoms.

LICHEN PLANUS VERRUCOSUS. Presented by Dr. Bechet.

The patient was a woman who had suffered for the past five years from a single patch of lichen planus upon the neck. There had been little or no change since the first appearance. The diagnosis was confirmed by a biopsy, performed by Dr. Satenstein.

LUPUS ERYTHEMATOSUS OF MUCOUS MEMBRANE OF THE MOUTH. Presented by Dr. Leviseur.

The patient, L. G., was a girl, 18 years old. She noticed an affection of the skin of the face in February, 1912, a spot of the size of a silver quarter, appearing on the left malar region. The affection gradually spread, but finally disappeared after treatment in a hospital, lasting two months, leaving only a very shallow, whitish scar. A few months later, lesions of the same character appeared on the right side, in a symmetrical position. These lesions disappeared without treatment, with the exception of a small spot which was still present and could not be taken for anything else but a lupus erythematosus. On February, 1914, a dentist accidentally discovered lesions in the patient's mouth. They had persisted since then with very little change; they were located opposite the right and left upper molar teeth and on the mucous membrane of the upper lip, opposite the incisors. The patch located in the latter region was bordered by a gyrate line of mother-of-pearl appearance. The two other spots represented red, slightly infiltrated, well-defined, superficial patches, approximately the size of a dollar. They were painful only when grossly irritated, and did not bleed. The Wassermann reaction was negative and no glandular enlargement or other physical signs of tuberculosis were present.

LUPUS ERYTHEMATOSUS DISSEMINATUS. Presented by Dr. Abramowitz for Dr. Fordyce.

Previously presented. (See The Journal, 1915, p. 768.)

LUPUS ERYTHEMATOSUS OR VULGARIS? Presented by Dr. Fraser for Dr. Trimble.

The patient was a woman, 27 years of age, born in Ireland. At the age of eight, a symmetrical eruption appeared behind the ears. At twelve, the eruption appeared on the nose and both cheeks and gradually extended until the areas marked by the lesion on the left cheek and the scar areas on the nose and right cheek became involved. At the end of five years there was complete healing of

the lesions on the nose and right cheek, leaving the scars. The lesion presented never healed, and eight years ago it began to break down in places. It assumed its smooth, glistening appearance only three years ago. Previous to this it was rough and scaly. The von Pirquet test was positive.

LUPUS VULGARIS. Presented by Dr. Trimble.

The patient was a woman, 50 years of age. The whole middle third of the face was covered by the lesion. The skin was dusky red, indurated, with a coppery hue, and exhibited many areas of scar tissue. A small margin of both alæ of the nose had been destroyed and ectropion of a mild degree existed in both lower lids. When the patient was seven years old, she had had an ulcerating gland in the neck, just under the angle of the jaw. This eventually healed, but was followed by the skin condition, which gradually spread over the location mentioned. The case was shown merely on account of the disease occurring in the area usually occupied by erythematous lupus.

LUPUS VULGARIS. Presented by Dr. Hailperin for Dr. Trimble.

The patient was a girl, 20 years of age, born in Russia. Her father was said to have died of pulmonary tuberculosis. She presented a lesion on her left ear, which first appeared as a small spot at two years of age and which had gradually increased in size, until it involved part of the anterior and posterior surfaces of the ear. The lesion was a thickened, soft growth, reddish-brown in color and covered with loose, dry scales, like those of seborrhœa. She complained of occasional itching.

LUPUS VULGARIS SERPIGINOSUS. Presented by Dr. Howard Fox.

Previously presented. (See The Journal, in press.)

LUPUS VULGARIS HYPERTROPHICUS SERPIGINOSUS. Presented by Drs. Howard Fox and Ochs.

Case previously presented as a case of Dermatitis Vegetans. (See The Journal, 1915, p. 144.)

LYMPGANGIOMA CIRCUMSCRIPTUM. Presented by Dr. D. M. O. Robinson.

The patient was 2½ years of age. The eruption appeared first at the age of seven months as a small patch, extending gradually to the size presented. It appeared first as vesicular lesions, the darker ones following later. There was no history of injury or pathological condition previous to the appearance of the eruption.

CAVERNOUS LYMPHANGIOMA combined with a CUTANEOUS PAPILLARY LYMPHANGIOMA. Presented by Dr. Leviseur.

The patient, C. V., was a girl, 6 years of age. She presented a small tumor on the right renal region, somewhat changeable in size, but gradually increasing. The integument above the deep-seated swelling showed a group of vesicular-like lesions, arranged in lines and forming a band about six inches in length and one and a quarter inches in width. Some of the lesions looked like individual ves-

icles on a perfectly normal skin, others were of a bright red color, evidently due to secondary hæmorrhage. The subcutaneous tumor had of late enlarged, and had formed a soft and easily palpable swelling of the right lumbar region. The superficial lesions did not rupture easily but, on the contrary, were very persistent. A biopsy was refused.

MELANOSE EN GRAINS. Presented by Dr. Newman.

The patient was a man, 58 years of age, born in Austria, a merchant by occupation. Eight years ago, the eruption first appeared over the left eyebrow, since which time new lesions appeared at irregular intervals, varying from a pin point to pea size, and from a bright red to a dark purple in color. Some of them appeared to be set deeply in the skin, others upon the surface and a number were elevated. Pressure on the elevated lesions drove the blood into the capillaries, leaving a wrinkling of the epidermis. None of the lesions had disappeared. There were about twenty on the face, ten on the neck, one on the mucous membrane of the lower lip, one on the dorsum of the tongue, five or six closely aggregated on the under surface of the tongue, seven on the chest and one on each arm. There were no subjective symptoms. Physical examination showed arteriosclerosis, bronchial asthma, no hypertrophy of the liver, no color changes in the eye ground, sexual powers good. Knee reflexes were exaggerated. Argyle-Robertson was negative. Microscopic examination (by Dr. Satenstein) showed "in the mid-portion of the corium and in the deeper parts of the corium a number of dilated vessels; surrounding these vessels were a large number of large, rounded, pigmented cells, resembling nævus cells."

MOLLUSCUM CONTAGIOSUM. Presented by Dr. Potter.

The patient, R. S., was an Italian boy, 12 years of age. He was one of four members of a family to suffer from the disease. The eruption had first appeared two months ago as a small papule on the left forearm. This increased in size and new lesions appeared. There were twelve of them scattered over the left forearm, varying in size from a pinhead to that of a pea. One lesion had become encysted by a surrounding inflammatory process.

MORPHŒA. Presented by Dr. Trimble.

The patient was a woman, 38 years of age, an Italian by birth. She had six children, all living, and had had two miscarriages. The lesion was an area, six inches by one inch, of hardened integument under the left breast. The Wassermann reaction was negative, as was also the therapeutic test.

MORPHŒA. Presented by Dr. Heimann.

The patient, Miss C. M., was a woman, 25 years of age. The eruption consisted of white spots, unaccompanied by any subjective symptoms, and had insidiously appeared during the past year. The lesions were grouped and situated chiefly on the back, although some were present on the flanks and sternum. A few were markedly atrophied, but the majority were slightly raised, rough and surrounded by a narrow violet zone. The diameter of the spots varied from two millimetres to two centimetres. A microscopic examination showed atrophy of the epidermis, obliteration of the papillary body and destruction of the elastic tissue, with its total absence in many areas. A slight increase in the number of young connective tissue cells was found about some of the vessels.

MORPHŒA. Presented by Dr. Trimble.

The patient was a woman, 39 years of age, born in the United States. She was married and had had seven children, four of whom are living. She had had thirteen miscarriages. The lesions consisted of rather thin, atrophic spots, varying in size from a twenty-five cent piece to a silver dollar, and several were even larger. They were irregular in outline, marble-like in color, with a distinct violaceous hue at the border. The locations were the abdomen, back and thighs. There were no subjective symptoms and the Wassermann reaction was negative.

MORPHŒA. Presented by Dr. Parounagian.

The patient, C. C., was a girl, 6 years of age, born in the United States. The lesion, which was situated on the right side of the face, had existed for more than a year.

MORPHŒA AND WHITE SPOT DISEASE. Presented by Drs. Pollitzer and Satenstein.

The patient, M. N., was a girl, 9 years of age, born in the United States. She had had the disease for one year. It began as red areas, later turning white and slowly increasing in size. The lesions were situated on the right dorsal, right infracostal, left inguinal regions and the right thigh. They were of varying size, white, firm, with smooth centres and violaceous borders (morphœa lesions). Numerous small, whitish areas were scattered, especially on the right side of the chest and abdomen. They had slowly increased in size and in number. Recent white spots had appeared behind the ears.

MYCOSIS FUNGOIDES (PREMYCOTIC STAGE). Presented by Dr. Trimble.

Previously presented. (See The Journal, 1914, p. 810.)

MYCOSIS FUNGOIDES (PREMYCOTIC STAGE). Presented by Dr. Trimble.

Previously presented. (See The Journal, 1915, p. 533.)

NEURODERMATITIS (LICHEN CHRONICUS OF VIDAL). Presented by Dr. Trimble.

Previously presented. (See The Journal, 1914, p. 809.)

ONYCHIA AND PARONYCHIA, FOLLOWING SALVARSAN. Presented by Dr. Stetson for Dr. Fordyce.

The patient was a young woman who was under treatment for malignant syphilis. After the first dose of salvarsan (0.3 gm.) there was a slight cutaneous reaction. Through a misunderstanding of directions, the patient received a second dose (0.3 gm.) of salvarsan, a week later. This was followed by a very severe eruption of the bullous erythema multiforme type. The fingers, especially near the nails, were markedly involved. After the eruption had disappeared, it was noticed that the finger nails, at their proximal ends, were markedly deformed. They were atrophic and ridged transversely.

PARAFFINOMA OF THE FACE. Presented by Dr. Goldenberg.

The patient was a man, 23 years of age, who had consulted a plastic surgeon for cosmetic treatment of scars following smallpox. Liquid paraffine was injected at six different places in the face, in January, 1915, and followed by permanent tumors at the sites of the injection, causing marked disfiguration. An attempt to remove the paraffine by suction, with a needle, was fruitless.

PARAPSORIASIS IN PATCHES. Presented by Dr. Wise for Dr. Fordyce.

Previously presented. (See The Journal, 1915, p. 212.)

PARAPSORIASIS, LICHENOID TYPE. Presented by Dr. Wise for Dr. Fordyce.

Previously presented. (See The Journal, 1915, p. 212.)

PITYRIASIS RUBRA PILARIS. Presented by Dr. Berger for Dr. Trimble.

The patient was a girl, 16 years of age, born in Austria. The eruption began seventeen months ago, as a scaliness of the palms and soles, later becoming thickened and fissured. Grayish papules then appeared on the dorsal surfaces of the fingers, forearms, arms, neck, scalp, chest and legs. The papules were acuminate and capped with horny scales, pierced by broken hairs.

PITYRIASIS RUBRA PILARIS IN A COLORED BOY. Presented by Drs. Howard Fox and Pisko.

Previously presented. (See The Journal, 1915, p. 722.)

RHINOSCLEROMA. Presented by Dr. Remer for Dr. Fordyce.

The patient, C. P., was a woman, 26 years of age, born in Russia. She had been in the United States for the past eight years. She was a dressmaker by occupation. She had had the disease for three years. The family history was negative. Five years ago, the patient had had severe headaches and an operation was performed on the nose, the nature of which could not be ascertained. Two years later, she noticed a nasal discharge. One year later, she became aware of an obstruction inside the right nostril, which gradually became worse. When presented to the Association, there was a growth involving the circumference of the right ala. The tumor was exceedingly hard and there was no ulceration. The lesion was just about large enough to fill the nostril, and as a result, there was no marked swelling of the nose. The Wassermann reaction was negative.

SARCOID (BOECK). Presented by Dr. MacKee for Dr. Fordyce.

Previously presented. (See The Journal, 1915, p. 770.)

SARCOMA (KAPOSI). Presented by Drs. Kingsbury and Bechet.

The patient was a man, 59 years of age, an Italian by birth. The condition began four and a half years ago, on his left ankle. Since then the tumors had slowly increased in number and size. In the past few months their development had been much more rapid. He presented for examination several masses of

aggregated tumors, scattered over the lower leg, from the knee to the foot. They varied in size from a marble to a large walnut. A number of them, particularly at the ankle, were undergoing ulcerative changes. A biopsy confirmed the diagnosis. The patient had a four-plus Wassermann.

SARCOMA (KAPOSI). Presented by Dr. Potter.

The patient, G. C., was a man, 64 years of age, born in Sicily, by occupation a longshoreman. He came to the United States 14 years ago. The family history and previous personal history were negative. He first noticed the eruption 15 years ago, at which time a small purplish spot, the size of a dime, appeared on the right ankle. The lesion was not painful, and never disappeared. At about the same time, the sight of the right eye became gradually impaired. From the time of the appearance of the first lesion until five years ago (10 years) a few purplish spots appeared, from time to time, on the right ankle and outer aspect of the right leg and also a few on the left ankle, extending up the outer border of the left leg as far as the knee. The patches varied in size from a pea to a dime. The older ones were more dense and nodular, and were slightly tender on pressure. None of them ulcerated. Five years ago, the feet began to swell at times and walking became somewhat difficult. When the patient was first seen, a year ago, both limbs were involved from the knees down. The skin of the entire limbs was thick, leathery and of a greenish-yellow color. Both ankles were a mass of small nodules, from the size of a pea to that of a small cherry. There was a great deal of swelling and the function of the joint was greatly impaired. The skin on the soles of the feet was thick and scaly, but no lesions appeared on that location. Walking was difficult, even with a cane. The feet were painful even when at rest. The nodules and infiltrated purplish patches extended in a continuous line up the outer aspect of both legs, as far as the knees. One spot appeared on either leg, on the inner aspect of the thigh. The glands in the groin were not enlarged. The hands were œdematous and the dorsal surfaces were of a dark brown color. The skin of the hands was thick and dry. The face and neck were also of a dark brown color. The sight of the right eye was entirely destroyed and that of the left was greatly impaired.

SARCOMA (KAPOSI). Presented by Dr. Snyder for Dr. Fordyce.

Previously presented. (See The Journal, 1915, p. 493.)

MELANO-SARCOMA OF THE THUMB. Presented by Dr. Oulmann.

The patient was a man, 63 years of age, a pianist by occupation. Eight years ago, he had noticed a brown spot on the palmar surface of the thumb. Two years ago, it became painful, the thumb became larger and finally ulcerated, the nail being exfoliated. Histological examination showed a melanotic, small round cell sarcoma.

MULTIPLE SCARRING FROM MORPHINE INJECTIONS (BLUE ATROPHY OF THE SKIN). Presented by Dr. Scheer for Dr. Fordyce.

Previously presented. (See The Journal, 1914, p. 811.)

SCLERODERMA. Presented by Dr. Heimann.

The patient, Mrs. S., was a woman, 50 years of age. She had been troubled

with her disease for seven years. The lesions began on the shins and extended gradually, involving the entire surface of both legs, on the right side, including the skin over and above the patella. The progress of the disease was marked by intense itching and burning of the involved skin, and from time to time, large blisters and rhagades would form. The skin was atrophied, glazed. tense and in places denuded of epidermis. The veins, some of which were dilated, rested in gutters with hard walls formed by the hardened cutis. The surface of the skin felt cool to the touch.

SCLERODERMA. Presented by Dr. Recque for Dr. Fordyce.

Previously presented. (See The Journal, 1915, p. 210.)

SCLERODERMIA CIRCUMSCRIPTA; SCLERODACTYLIA. Presented by Dr. Rostenberg.

The patient was a woman, 50 years of age, born in Russia. She had had three healthy children and three miscarriages. The last one occurred seventeen years ago and was followed by a "milk-leg," since which time she had had more or less pain and swelling in the leg at times. The lesion presented developed five years ago, starting with severe itching on the lower right extremity. The skin became gradually thinner and there was a feeling of tension and pain, this condition growing steadily worse. At the same time she found it difficult to move the fingers of both hands, which increased to total inability to extend them. Examination showed, on the middle of the right lower limb, a circular band about one and a half inches wide, of atrophic, shiny and glossy skin, totally "hide bound," sharply defined by a raised margin from the healthy parts and small teleangiectatic areas in places. On the inner aspect there was a small, round, sharply defined, moderately deep ulceration. The skin on the rest of the body was normal, except the hands, which were slightly œdematous. The fingers were somewhat atrophic, and there was a rigid palmar flexure of the first phalangeal joints of all the fingers. The Wassermann test was negative and the urine showed nothing abnormal.

CONGENITAL SYPHILIS(?) WITH TUBERCULIDE AND RECENT ATTACK OF ERYTHEMA NODOSUM. Presented by Dr. Heimann.

The patient, L. C., was a woman, 28 years of age. She had suffered from some disease of the eye at the age of five years, resulting in the loss of sight on the right side. Her family history was apparently negative. She was first seen three years ago, when she presented small nodules and scars on the forearms, fingers and right thigh. Rhagades were present at the corners of the lips and there was keratitis of the right eye and atrophy of the right nostril. The Wassermann reaction was not performed, but all the lesions healed under internal administration of mercury, other therapy being refused. From that time there had been no activity until about three weeks ago, when she was suddenly attacked with a painful eruption on the lower extremities. This was fading, but was still painful and tender and there was also some arthralgia. Microscopically, neither syphilis nor tuberculosis was suggested, the picture resembling that of an acute inflammation with great infiltration.

TUBERCULOUS DACTYLITIS IN A SYPHILITIC CHILD. Presented by Drs. Howard Fox and Ochs.

The patient, Rosalie B., was a colored girl, 2½ years of age. Eight months ago she had presented a fusiform swelling of the index finger of the right hand, which later broke down and ulcerated, bad deformity resulting. An X-ray examination showed the dactylitis to be tuberculous. There was also an irregular swelling of the metatarsal region of one foot, which showed the presence of a syphilitic periostitis. Both the child and her mother gave positive Wassermann reactions.

SYRINGOCYSTADENOMA. Presented by Dr. MacKee for Dr. Fordyce.

The patient was a colored woman, 20 years of age, a domestic, born in the United States. The eruption had existed for two years. It began on the chest and later appeared on the back. It was limited to the chest and back. Scattered over the chest were a large number of pinhead-sized, irregularly round, considerably elevated, smooth, firm papules of a yellowish-brown color. A few similar but smaller lesions were scattered over the back. There were no subjective symptoms. A histological study revealed a flattening of the rete pegs, a marked œdema of the collagen and dilated blood vessels. There was no cellular infiltration. Scattered throughout the lesions were numerous cross sections of dilated sweat ducts and there was a budding of the epithelium of the coil glands.

TUBERCULOSIS CUTIS. Presented by Dr. Winfield.

The patient was 49 years of age. The eruption began three years ago, as an abscess of the cheek. The Wassermann reaction was negative and the tuberculin test was positive.

TUBERCULOSIS VERRUCOSA CUTIS. Presented by Dr. Weiss.

The patient, J. W., was a man, 46 years of age, born in the United States. He presented, on the radial side of the right index finger and over its whole length, from the head of the metacarpus to the last phalanx, warty, elevated, dendritic growths, which, in coalescing, had formed a long serpiginous area of papillary hypertrophy. There was a tendency to peripheral extension and atrophy in the centre, where the affection first appeared. The patient had had pulmonary tuberculosis and the case was obviously one of auto-infection due to his habit of wiping his mouth, nose and mustache with the back of his index finger, after coughing. Curettage and two applications of 20% salicylate plaster, conjointly with iron and arsenic internally, was bringing about a cure.

TUBERCULOSIS OF THE SKIN AND BONES. Presented by Dr. Steinke for Dr. Fordyce.

Previously presented. (See The Journal, 1915, p. 319.)

PAPULO-NECROTIC TUBERCULIDE. Presented by Drs. Pollitzer and Satenstein.

The patient, J. M., was a man, born in Austria, a tailor by occupation. The eruption appeared first, eight to ten years ago, on the hands, later on the face and ears, and then on the body and lower extremities. There were numerous

lesions in all stages of development and numerous scars on the ears, from previous lesions. The condition was worse in winter.

URTICARIA PIGMENTOSA. Presented by Dr. Trimble.

The patient, Thomas B., was a boy, 7 years of age, born in the United States. The eruption had been present since he was one year of age. The lesions were generalized, of various sizes and light brownish in color. A microscopical section showed large numbers of mast cells.

URTICARIA PIGMENTOSA. Presented by Dr. Trimble.
Previously presented. (See The Journal, 1914, p. 151.)

XANTHOMA. Presented by Dr. Trimble.

Previously presented. (See The Journal, 1915, p. 531.)

XERODERMA PIGMENTOSUM. Presented by Dr. Ochs.
The patient, Edith W., was a girl, 5 years of age. When a year and a half old, she had been sunburned and freckled, the freckles never having disappeared. There were various sized, fawn-colored to blackish spots and teleangiectases scattered over the face and neck. Slight scaling was also present. Small nodules were present upon the cornea of both eyes.

CASE FOR DIAGNOSIS. PSORIASIS OR LICHEN PLANUS? Presented by Dr. Brand for Dr. Trimble.

The patient was a man, 33 years of age, born in Russia and a resident of the United States since the age of five. Eight years ago, dry, scaly, crimson colored patches appeared on the scrotum and penis. These lesions itched considerably and remained more or less constantly. Two years ago, the patient contracted syphilis.

CASE FOR DIAGNOSIS. Presented by Dr. Brand for Dr. Trimble.

The patient was a young man, about 25 years of age. He presented on the glans penis, dark, reddish patches, capped with scales. These lesions appeared six years ago and disappeared under treatment, several times. Only one patch was to be seen on the glans, near the meatus. Lichen planus was suggested. The Wassermann reaction was negative.

CASE FOR DIAGNOSIS (BULLOUS ERUPTION). Presented by Dr. Stevens for Dr. Fordyce.

Previously presented. (See The Journal, 1914, p. 145.)

CASE FOR DIAGNOSIS. Presented by Dr. Whitehouse.

The patient, C. T., was a girl, 6 years of age, born in the United States. The eruption, which first appeared three months ago, was confined to the extensor surfaces of the upper extremities, including the backs of the hands and fingers, the cheeks, bridge of the nose, ears and neck. It was a scar-producing eruption, with absolutely no subjective symptoms, such as itching, pain, soreness, etc. The primary lesions resembled those of molluscum, except that they were transparent and had gelatinous contents.

CASE FOR DIAGNOSIS; PARAPSORIASIS. Presented by Dr. Brand for Dr. Trimble.

The patient, D. K., was 29 years of age, born in Russia. The condition began one year ago, as two small, reddish spots on the forearms, which gradually increased in size and number. There were dark reddish, gyrate patches, slightly raised above the surface of the skin on the forearms, thighs and on the right buttock. The lesions were slightly itchy. The Wassermann reaction was negative.

Howard Fox, M.D.,
Chairman, Committee on Clinics.

REVIEW

OF

DERMATOLOGY AND SYPHILIS.

Under the direction of

FRED WISE, M.D., New York,

Assisted by

Clarence A. Baer, M.D., Milwaukee.
William H. Baughman, M.D., New York.
Paul E. Bechet, M.D., New York.
J. S. Eisenstaedt, M.D., Chicago.
Charles Goosmann, M.D., Cincinnati.
Robert C. Jamieson, M.D., Detroit.
M. F. Lautman, M.D., Hot Springs.
Oscar L. Levin, M.D., New York.
M. L. Ravitch, M.D., Louisville.
Isadore Rosen, M.D., New York.
Max Scheer, M.D., New York.
Philip F. Shaffner, M.D., Chicago.
A. W. Stillians, M.D., Chicago.
John H. Stokes, M.D., Chicago.
Harvey P. Towle, M.D., Boston.
James F. Grattan, M.D., New York.
Vicente Pardo, M.D., Havana, Cuba.

DERMATOLOGISCHE WOCHENSCHRIFT.

(Jan. 15, 1916, lxii, No. 2.)

Abstracted by Max Scheer, M.D.

CONTRIBUTION TO THE THERAPY OF PEMPHIGUS CHRONICUS AND OF DERMATITIS HERPETIFORMIS (DUHRING). Adolph Fischer, p. 25.

The author describes a case of pemphigus vulgaris chronicus in a girl, twenty years old, who had had attacks, on and off, since childhood. In the last attack there were bullæ on the forearms and legs; the rest of the skin and the mucous membranes were free; she was given an intravenous injection of 20 cc. of blood obtained from a healthy adult female. The following day the patient's temperature rose to 40.2° C., new lesions appeared on the thighs, arms and trunk, though not on the mucous membranes; her general condition became distinctly worse; the lesions themselves assumed more the appearance of pemphigus foliaceous. Five days after the blood infusion, the patient received 0.45 gm. neosalvarsan, dissolved in 3 cc. distilled water, intragluteally. The next day the temperature dropped to normal, no new lesions appeared and the existing lesions began to dry up. The patient was discharged well, 19 days after admission, and when seen three months later, she was still well.

A case of dermatitis herpetiformis in a neurotic man, 36 years old, was treated with intragluteal injections of blood serum and also of neosalvarsan, but with very little improvement. After a phlebotomy of 200 cc. of blood, he was transfused with 500 cc. of Ringer's solution; this caused an immediate and marked aggravation of his subjective and objective symptoms. He finally improved under subcutaneous injections of 1% arsenious acid, 1cc. three times weekly and local applications of 2 to 5% tar pastes.

Some cases of pemphigus are benefited by arsenic or salvarsan, or quinine (by mouth or intravenously) or by blood or serum injections. The variety of successful therapeutic agents suggests the presence of many ætiological factors operative in the conditions called pemphigus. Improvement following injections of human blood serum suggests that an alteration ("Umstimmung") in the tissues was the cause of the pemphigus; improvement after salvarsan suggests an infectious ætiology; and improvement following prolonged treatment with arsenic or quinine suggests a sort of dyscrasia or a neurosis. On this supposition the author surmises that his case of pemphigus had an infectious origin.

A CONTRIBUTION TO THE CALCIUM TREATMENT OF SKIN DISEASES. HUGO HECHT, p. 34.

The author reports good results with calcium in a case of urticaria acuta recidivans, in a case of derographismus and in two cases of pemphigus vulgaris; he admits that the benefit in the pemphigus cases will probably be only temporary.

The formula he uses is:

Calcii lactici, 20.0
Mucilag. gummos., 30.0
Aquæ Fortis, ad., 200.0

Syrup aurantii may be added to disguise the taste. He gives two to six teaspoonfuls, three times a day.

CASE REPORTS FROM THE DERMATOLOGICAL CLINIC OF THE LELAND STANFORD, JR., UNIVERSITY SCHOOL OF MEDICINE. H. E. ALDERSON, p. 31.

Read before the 66th annual meeting of the American Medical Association, June, 1915. Translated from the *Jour. A. M. A.*, by A. Philippi.

(*Ibidem*, Jan. 22, 1916, lxii, No. 3.)

SKIN CANCER OF THE EXTREMITIES. H. H. HAZEN, p. 49.

Read before the 66th annual meeting of the American Medical Association, June, 1915. Translated from the *Jour. A. M. A.*, by A. Philippi.

(*Ibidem*, Jan. 29, 1916, lxii, No. 4.)

THE TREATMENT OF BURNS. A. RAVOGLI.

Read before the 66th annual meeting of the American Medical Association, June, 1915. Translated from the *J. A. M. A.*, by A. Philippi.

JOURNAL OF THE AMERICAN MEDICAL ASSOCIATION.

(Nov. 27, 1915, lxv, No. 22.)

Abstracted by WILLIAM H. BAUGHMAN, M.D.

THE ROENTGEN-RAY TREATMENT OF SKIN DISEASES. G. M. MACKEE, p. 1886.

To secure the best results it is advisable to adhere to one of the following schemes: "For the dermatologist to employ the Roentgen-ray; for the Roentgenologist to have at least a clinical knowledge of dermatology; or for both to combine their skill in behalf of the patient."

The methods now employed are the intensive dose and the divided dose. In the first, the quality of ray is ascertained by direct measurement and maintained by indirect measurement. Quantity is directly measured by a reliable radiometer. An intensive dose may produce "a second degree Roentgen dermatitis, a simple erythema, a loss of hair without erythema, or a dose that is too small to produce a visible effect on the normal skin, but yet too large to allow of its repetition within three or four weeks." Excellent results are obtained with the intensive treatment of ringworm and favus of the scalp. A "hard" ray (B 8 to 10) is preferred for routine work. True idiosyncrasy is very uncommon, but hypersusceptibility is common. Important factors to be considered are the location of the lesion, the age of the patient, the previous use of certain chemicals, the nature of the disease.

The indications for the intensive dose and for the divided dose differ. The present divided dose is obtained by the use of certain established and fixed "constants": that is, all adjustable parts, as the distance of the anode from the skin, the milliamperage, the spark-gap distance, etc., are employed in exactly the same manner for every divided dose treatment.

Among the affections which respond well to the intensive dose method are: erythema induratum; granuloma annulare; lichen planus; hypertrophies, as clavus callositas and verrucæ; new growths, as keloid, nævus vasculosis (cavernous angioma especially), rhinoscleroma; the more benign forms of tuberculosis cutis; certain types of epithelioma, the squamous-cell type being usually dealt with surgically, the Roentgen-ray being used post-operatively and in inoperable cases. Included in the conditions responding better to the divided dose method are: psoriasis; prurigo; certain forms of eczema; lichenification and lichen circumscriptus; and phompholyx.

The text is illustrated by numerous excellent photographs.

RADIANT ENERGY IN THE TREATMENT OF DISEASES OF THE SKIN. E. S. Lain, p. 1892.

The most common forms and sources of radiant energy for therapeutic use are: the Finsen light, ultra-violet ray, high-tension current effluvia, radium, and Roentgen-ray. The visible reactions of these forms of radiant energy are very nearly alike, hence he divides them into the same divisions previously applied to the effects of the Roentgen-ray alone. These effects, when produced by radium, ultra-violet ray, and Roentgen-ray, are not so prompt in their appearance as when produced by high-frequency effluvia, fulguration, and diathermy.

Cellular life and metabolism are stimulated by the first degree reaction; in the second and third degrees, cell life undergoes degenerative changes, the pathologic cells being more quickly affected than normal cells. In these facts may be found the secret of successes and failures in treatment. A more careful study of histopathology of diseases and the acquisition of a more accurate technique will produce more and better results. The writer has prepared a tentative classification of skin diseases which coincides with his experience in the application of electrotherapeutic methods. The first class includes those which have been favorably influenced only in the region of its local application, as dermatitis herpetiformis and psoriasis. The second includes cases influenced favorably by radiotherapy, but treated with better results by medicinal means combined with radiotherapy, as hyperhidrosis and herpes zoster. The third class includes most of the superficial local infectious conditions, as acne vulgaris and erysipelas. In the fourth class are put practically all diseases characterized by increased development of pathologic cells, both benign and malignant, as fibroma molluscum, keloid and epithelioma.

The most uncertain results have been obtained in the treatment of sarcomas.

THE USE OF MERCURY SALICYLATE IN SYPHILIS. A RECORD OF ITS INFLUENCE ON THE WASSERMANN REACTION IN FIFTY CASES. K. NELSON AND E. A. ANDERSON, p. 1905.

The cases selected had had no previous treatment, forty-three being "latent" cases, seven were in the secondary stage of the disease. The dose of mercury salicylate was always 1½ grains. The smallest number of injections given was seven, the largest twenty-three. Objective symptoms yielded to this treatment, but they yield more rapidly to salvarsan. The serum reactions varied from the strongest positive to minus, later returning to strongly positive, during the course of the treatment: being brought about in the authors' opinions by other factors than the treatment.

The authors consider, after their investigation, that mercury salicylate has little, if any, value in the treatment of syphilis. The value of more than one serum reaction is emphasized.

THE TREATMENT OF CEREBROSPINAL SYPHILIS: THE OGILVIE TECHNIQUE. F. EASTMAN, p. 1909.

NEW YORK STATE JOURNAL OF MEDICINE.

(January, 1916, xvi, No. 1.)

Abstracted by OSCAR L. LEVIN, M.D.

OBSERVATIONS ON THE CURE OF SYPHILIS. MATHEW A. REASONER, p. 4.

The author made a careful study of the histories of 104 old syphilitics who had not received any treatment for at least one year, showed no active manifestions of the disease and repeated negative Wassermann tests of the blood serum. As a result of this investigation he concluded:

1. That the dark ground illumination method for determining the presence of the Spirochæta pallida in a suspected lesion is of infinite importance in making an early diagnosis of syphilis.
2. Syphilis is curable.
3. The prognosis is best when treatment is begun early.
4. The spirochæta differs in its invasive power and its predilection for certain tissues. This fact affects the ultimate prognosis.
5. The best results are obtained by intensive treatment with salvarsan or neosalvarsan, administered intravenously and mercury given by injection or inunction. Salvarsan is more powerful and is superior to neosalvarsan.
6. The Wassermann best serves as a valuable guide to treatment.
7. A case should not be considered cured until the patient has not been treated for at least one year and then shows repeated negative Wassermann and provocative Wassermann reactions, luetin tests and a normal spinal fluid.

SYPHILITIC DISEASE OF THE ARTERIES. ALEXANDER MCPHERDAN, p. 10.

A discussion of the pathology and symptomatology of syphilitic arteritis.

GASTRO-INTESTINAL MANIFESTATIONS IN SYPHILIS. HENRY C. BUSHWELL, p. 12.

The lesions produced by syphilis of the stomach, intestines, liver and pancreas are enumerated. The clinical manifestions of these pathooglical conditions are described. Several cases are cited.

(*Ibidem*, February, 1916, xvi, No. 2.)

SPINAL MANIFESTIONS OF SYPHILIS. M. ALLEN STARR, p. 59.

Spinal syphilis constitutes about 20% of all cases of cerebrospinal syphilis.

The pathological conditions produced by the Spirochæta pallida in the spinal cord may be divided into two classes:

1. The meningitic vascular lesions.
2. The degenerative lesions.

The meningitic vascular lesions consist of single or multiple, minute or extensive deposits of new tissue on the surface of the cord and gummata. The walls of the blood vessels are thickened, causing a diminution in the calibre of the vessels or an actual thrombosis resulting in a condition of malnutrition or softening of nerve tissue.

The degenerative lesions are caused by the destruction of the neurones and their processes.

The clinical manifestations depend upon the pathological conditions present. These may be:

1. Symptoms of pachymeningitis, leptomeningitis, localized gummous deposits or transverse myelitis.
2. In softening of the cord the picture is that of a transverse myelitis.
3. The symptoms caused by the degenerative lesions are those of locomotor ataxia or lateral sclerosis.

BOSTON MEDICAL AND SURGICAL JOURNAL.

(Dec. 23, 1915, clxxiii, No. 26.)

Abstracted by OSCAR L. LEVIN, M.D.

SYMMETRICAL SYNOVITIS IN HEREDITARY SYPHILIS. ABNER POST, p. 941.

This condition occurs frequently in cases of hereditary syphilis, but is often not diagnosed because the joints are seldom fully distended and there is little pain or loss of function. The author considers the triad, symmetrical synovitis, interstitial keratitis and Hutchinsonian teeth, as valuable as that of Hutchinson in making a diagnosis of congenital syphilis.

MENTAL FEATURES OF CONGENITAL SYPHILITICS. J. H. BAZELEY AND H. M. ANDERSON, p. 952.

The mental phenomena observed in children born with lues, were compared with those in non-syphilitic children. Among the congenital syphilitics there were more cases of backwardness, feeble-mindedness and retardation. Defects in vision, hearing and speech were also more marked. It was noticed that the earlier children in some families were exceptionally bright while those following a syphilitic infection of the parents were feeble-minded and showed rapid deterioration of mentality.

DIAGNOSTIC VALUE OF LANGE'S GOLD SOL. TEST. (BASED ON 500 EXAMINATIONS OF THE SPINAL FLUID.) HARRY C. SOLOMON, HILMAR O. KOEFOD AND EDWARD S. WELLES, p. 956.

The authors conclude that no cerebrospinal fluid examination is complete for clinical purpose without the gold sol. test.

If more than one sample of the fluid from a case of general paresis be examined, a strong characteristic curve will be obtained, the so-called paretic curve. This curve may also be found in the fluid from cases of cerebrospinal syphilis, locomotor ataxia and chronic inflammatory conditions of the central nervous system. If a fluid with a positive Wassermann test does not show this reaction, it is good presumptive evidence that the case is either cerebrospinal syphilis or tabes, and not paresis.

The gold sol. test in conjunction with the Wassermann reaction, chemical and cytological examinations, offers information aiding toward the differential diagnosis of general paresis, cerebrospinal syphilis, tabes dorsalis, tuberculous meningitis and purulent meningitis.

(*Ibidem*, Dec. 30, 1916, No. 27.)

THE SIGNIFICANCE OF CHANGES IN CELLULAR CONTENT OF CEREBROSPINAL FLUID IN NEUROSYPHILIS. HARRY C. SOLOMON AND HILMAR O. KOEFOD, p. 996.

Contrary to the findings of other investigators, the authors assign no prognostic value to the number of cells present in the cerebrospinal fluid of syphilitics.

The cell count is of no importance in determining whether irritative or degenerative changes predominate.

(*Ibidem*, Jan. 6, 1916, clxxiv, No. 1.)

LATENT NEUROSYPHILIS AND THE QUESTION OF GENERAL PARESIS-SINE PARESI. E. E. SOUTHARD AND H. C. SOLOMON, p. 8.

Four cases are reported, presenting no signs or symptoms of cerebrospinal syphilis but showing a positive serum Wassermann test. The spinal fluid in each showed a positive Wassermann reaction pleocytosis, an excess of globulin, an excess of albumin and a gold sol. reaction, indicative of neurosyphilis. The investigators regard these cases as belonging to a group of latent neurosyphilitics or paretics.

(*Ibidem*, Jan. 13, 1916, clxxiv, No. 2.)

THE DEVELOPMENT OF THE GOLD SOL. "PARETIC" REACTION AS COMPARED WITH THE "CEREBROSPINAL SYPHILITIC" TYPE, CONSIDERED FROM THE TIME NECESSARY TO FORM A COMPLETED REACTION. H. C. SOLOMON AND E. S. WELLES, p. 50.

SYPHILIS AND THE PSYCHOPATHIC HOSPITAL; NOTES ON MEDICAL AND SOCIAL PROGRESS, ESPECIALLY IN NEUROSYPHILIS; BOSTON, MASSACHUSETTS, 1915. E. E. SOUTHARD, p. 50.

(*Ibidem*, Feb. 10, 1916, clxxiv, No. 6.)

THE OCCURRENCE OF THE WASSERMANN REACTION AMONG HOSPITAL PATIENTS. ALBERT A. HORNER, p. 194.

The author emphasizes the importance of performing the Wassermann test as a routine measure in diagnosis. Among 500 patients in the general medical service of the Boston City Hospital, 16% showed a positive reaction, and in only 2% was a diagnosis of lues previously made.

TREATMENT OF CENTRAL NERVOUS SYSTEM SYPHILIS. I. CHANDLER WALKER, p. 195.

As a result of his observations, the author arrives at the following conclusions: The best treatment of syphilis of the central nervous system consists in the combined administration of mercury intramuscularly and salvarsanized serum intraspinally (Swift-Ellis method). Syphilitic meningitis may be cured by the intravenous use of salvarsan alone, but this may be obtained in a much shorter time by employing the intraspinal method. Cases of neurosyphilis not responding to intravenous injections of salvarsan may react to the Swift-Ellis method of treatment. Improvement occurs in some paretics from the combined treatment. The spinal fluid, previously positive, may become negative after salvarsan treatment but this has been noticed more often after intraspinal injections of salvarsanized serum.

THE TREATMENT OF SYPHILIS. C. MORTON SMITH, p. 198.

Smith describes the treatment of the various manifestations of congenital and acquired syphilis. He suggests three ways of preventing the spread of this disease: 1, by teaching the young the dangers of the disease. 2, by prompt, intensive and intelligent treatment of the infected individual. 3, by enforcing the health laws.

THERAPEUTIC GAZETTE.

(Jan. 16, 1916, xxxii, No. 1.)

Abstracted by OSCAR L. LEVIN, M.D.

DIETETIC AND MEDICAL TREATMENT OF CANCER. L. DUNCAN BULKLEY, p. 1.

Cancer is a disease of civilization. The stress and strain of modern life, errors in diet, especially an excess in meat consumption and lack of proper exercise in the fresh air produce disturbances in the metabolism of the body. This produces a disordered blood stream which predisposes to the development of abnormal cells and growths.

As a prophylaxis against cancer, Bulkley advises a return to the simple life and a plain, wholesome, vegetarian diet with proper proportions of proteid carbohydrates and fats, conducive to food metabolism. In active cancer he advises local treatment combined with those measures observed in phophylaxis.

Constipation should be relieved by the judicious administration of vegetable purgatives, proper food and abdominal massage. The kidneys should be encouraged to eliminate the toxic products of the disordered metabolism and alkalis should be administered.

ATLANTA JOURNAL-RECORD OF MEDICINE.

(December, 1915, lxii, No. 9.)

Abstracted by OSCAR L. LEVIN, M.D.

SYPHILITIC SERPIGINOUS ULCERATION OF THE RECTUM AND BUTTOCKS. E. P. MERRITT, p. 432.

Report of a case.

NEW YORK MEDICAL JOURNAL.

(Mar. 4, 1916, ciii, No. 10.)

Abstracted by JAMES F. GRATTAN, M.D.

PROGRESS IN THE TREATMENT OF SKIN DISEASES. G. M. MACKEE, p. 441.

A broader conception of dermatology, brought about by recent researches, has caused us to regard conditions formerly considered as entirely local and related to the integument, as manifestations of general internal disorders. Diseases of which the ætiology is not yet known continue to be treated empirically. Eczema, formerly regarded as a local condition, is now thought to be due to sensitizing of the patient by products of the local infection and a production of susceptibility to infection in the entire skin. The occupational types are regarded as cases of sensitization to the particular dye or chemicals. The tendency of modern research in dematology is to add to the number of dermatoses with internal pathological bases, and, at the same time, detract from the number of those considered as purely local in significance. The vaccine therapy of acne and ringworm and the tuberculin therapy of erythema induration are cited as examples of progress in the field of biologic therapy. Topical applications of actinic rays, X-rays and radium are reviewed and effects compared. The autoserum methods in psoriasis, urticaria, vesicular and bullous eruptions, are regarded by the author as "not warranting the time, trouble and expense." Carbon dioxide treatment should be limited to lupus erythematosus and the various nævi. The older methods of treating lupus erythematosus with quinine and tincture of iodine should not be neglected. Trichloracetic acid is recommended as the best caustic in xanthelasma, lupus erythematosus and certain nævi. Sherwell is quoted as being successful in the treatment of epitheliomata with acid nitrate of mercury, where X-ray and radium had failed.

Collaboration of the dermatologist, internist, physiological chemist, bacteriologist and pathologist, in future dermatological researches, will bring about advances in therapy.

REVISTA CLINICA DE MADRID.

(Nov. 15, 1915.)

Abstracted by VICENTE PARDO, M.D.

A CASE OF ADDISON'S DISEASE TREATED WITH X-RAY. J. RATERA, p. 357.

The author narrates a case of renal tumor, which, after obtaining a radiograph of both renal regions, showed marked improvement and later a complete recovery. This patient had the symptoms of Addison's disease, with cutaneous pigmentation, general weakness and digestive disturbances; the X-ray was employed only as a diagnostic measure, the back being exposed to the radiation.

Some time afterwards, the author had occasion to treat a similar case in which the diagnosis of Addison's disease was undoubted; the patient was 25 years old, a female, who had complained of hæmoptysis, arthritis of the right knee joint and muscular pains, general weakness, diarrhœa, and a brown pigmentation, scattered in irregular patches all over the cutaneous surface.

This time therapeutic use of the X-ray was deliberately made and after two treatments, the muscular pains disappeared and the patient recovered, the cutaneous pigmentation being the last to subside. The patient left the clinic after two months, in good health.

THE JOURNAL OF
CUTANEOUS DISEASES

VOL. XXXIV JUNE, 1916 No. 6

PRESIDENTIAL ADDRESS

HOW CAN WE IMPROVE OUR HOSPITAL SERVICE?*

BY CHARLES J. WHITE, M.D., BOSTON.

Edward Wigglesworth Professor of Dermatology in Harvard University.

GENTLEMEN:

This is the fortieth birthday of the American Dermatological Association, surely a landmark in the history of one of the oldest constituents of the American Congress of Physicians and Surgeons, and to commemorate, in a way, this event you have seen fit to elect to your highest office the son of your first president, who now in all gratitude begs you to accept his sincerest thanks for this signal distinction, and takes pleasure in confessing to you that his election to this well-coveted post of honor permits him to attain one of the three dermatological goals to which he has aspired since boyhood. To this son, brought up, so to speak, in the atmosphere of dermatology, it was only natural that a halo of awe and respect should surround the name and fame of the American Dermatological Association, and when in the course of the years a kindly telegram bearing the legend "congratulations" was received from Dr. Hyde, a thrill of pride and pleasure swept over him for he knew that the keenly desired gift of membership in this distinguished company had been offered him. Now, in this memorable year,

* Read before the 40th Annual Meeting of the American Dermatological Association, Washington, D. C., May 13, 14, and 15, 1916.

the highest honor of all has been conferred upon him and his cup of happiness is full; and yet, alas, there is, to this son, a reverse side to this bright picture, for when he notes how few of the pioneers, whose names were the household companions of his youth, are left, how very few of these well-known men are here to-day, it is only proper that he should pause for a moment in this address out of respect to their memory. Of the twenty-nine men who in 1876 constituted the charter members of this Association, Dr. Bulkley, Dr. Fox, Dr. Hardaway, Dr. Robinson, and Dr. Van Harlingen alone survive, and of these five veterans in membership only two continue their active part in our deliberations, but let us hope that these two still young colleagues will be spared to us for years to come and link us with our honored Past.

Gentlemen:

This would have been a fitting year to prepare an historical address, but a former president has performed this service so comparatively recently and so much better than I could do it now, that it has seemed wiser to leave this topic, suitable as it is, to my successor, perhaps ten years from to-day. There is, however, a subject which weighs rather constantly on my mind and that is, how we can better the care and treatment of our hospital patients. I know that sympathy is nowadays being directed principally toward improvement in the medical care of the lower middle classes, but much as I agree with this agitation my feelings go out chiefly to the really poor—those unfortunates to whom cold and filth and hunger and degradation are more or less constant companions. To keep up appearances is the difficult task of those in receipt of a modest salary, but to keep body and soul together is the still weightier burden of the ultra poor; and possible improvements in the hospital treatment, and its now recognized incumbent social care, of these unfortunates are the burden of my theme to-day.

Let us, therefore, receive the representative of this class at the door of our out-patient department and conduct him through the many and varied and intricate steps of his medical and social journey until in the end we discharge him, better able to cope with his life problems.

The patient enters the waiting room of the hospital, and in his proper turn is conducted by a page, who can speak his language, to the admitting physician. I have used the term physician advisedly, for in my opinion this preliminary interview should not be delegated to a layman, or even to a nurse. If the hospital can afford it, the physician should have by his side a trained social worker. There is much to be determined by these two officials. It is the duty of the administration first of all to

try to detect a person's financial fitness for hospital care, and this is decidedly a difficult problem, one requiring experience in this special work, knowledge of human nature, acumen, sympathy, good manners and tact, and I believe that this function should be allotted to the social worker. She should surely bear in mind the fact that shabby apparel and dirt do not always mean poverty and misery, for they may be purposely a deceitful ruse; and that neatness and cleanliness and relatively good clothes do not signify comfortable circumstances, for inherent self-respect may account for the former and charity for the latter. With the financial considerations settled, there then arise the medical questions as to the nature of the individual's illness, for the exanthemata and certain other infectious diseases must be detected and properly isolated at the earliest possible moment and the appropriate department for the patient's care must be promptly determined. The last two problems are in themselves sufficient to demand expert service, and should, of course, be delegated to the physician. I repeat then, that these duties, which require so quick a wit under really difficult circumstances, should be deputied only to first-class individuals possessed of adequate medical and social knowledge, because my experience and recollections of the last twenty years lead me to think that our hospital authorities do not always fully appreciate the importance of this question.

When the patient has been accepted, he should be conducted to a recorder who will typewrite upon his record card the data which physicians and statisticians now require. The record is now despatched to the appropriate clinic by means of a lift and by hand service, and the patient is directed by maid or page to the proper room to await his medical examination. If there is not universal elevator service, permission for its use should be granted to those needing this assistance—women carrying babies should not be obliged to climb one or more flights of stairs, nor should this effort be demanded of the feeble.

On reaching the appropriate department, the patient is met by what we at the Massachusetts General Hospital call a clinic secretary. This office, with us, is usually filled by a volunteer worker who thus gives her mornings gratuitously to the cause of charity, but if such an assistant is in need of money she should be paid for her services. The post is generally filled by a young woman of education, one in whom the spirit of social service is awakened. Such an individual may begin and end her active charitable career in such a post, or the work may prove but the stepping stone to a life devoted to the comparatively new form of philanthropy known as social service. I would like to state at this point that we in Boston regard social service as a distinct career, one

which demands special fitness and long months of training in a special course devoted to this purpose. I have laid stress on the necessity that the clinic secretary have the instinct of helpfulness and the love of her fellow men, for I have known young women serving in this now rather fashionable capacity who have not known how to control their tempers, and have tended rather to demoralize and to alienate the stranger than to help and to serve him.

The clinic secretary, as I have said, takes the new-comer under her wing. It is her duty to see that he is made comfortable; that his history is taken as soon as possible; that he passes into the examining room in his proper turn, or earlier, if he be feeble or have some valid reason for preceding others; that his record card and history, when written, be ready for the attending doctor when the patient reaches him; and, in case the necessary delay has been over-long and the patient, who has come a long distance without a sufficient breakfast, becomes faint, that food be provided for him from the lunch counter in the building. These are her duties toward the arriving patient; her subsequent functions will be mentioned later.

The patient's history must be taken, and it is a question in my mind as to how this can best be done. In the first place an interpreter, if necessary, should always be present. This arrangement can be readily accomplished by the hospital in the selection of its pages. There is now in Boston an abundance of Jews, Italians, Greeks and Armenians available for this service—young men who know English and are of presentable appearance. Most of us in charge of out-patient skin clinics are apt to perform this task of history-taking ourselves. I believe that this is not the best method to pursue. We physicians have not the time to do this work as thoroughly as it should be done; long years at this routine work perhaps are apt to make us somewhat careless of details; and finally, recognizing as a rule at a glance the disease before us, we are prone to ask the patient only those questions which we think are appropriate. I am going to emphasize somewhat this last point. With our ideas rather fixed by long experience, we have come to believe very much in *post hoc, propter hoc.* We are, therefore, in a rut and we tend to remain in this rut if we continue to pursue the same methods year after year.

For some time now I have conducted a fourth-year elective course in dermatology in which students are allotted to me from nine o'clock until twelve every day for four weeks. Every morning each student is assigned a patient, whom he interviews and examines and when ready, demonstrates to me and the class. Every detail of the patient's history,

clinical description, differential diagnosis, diagnosis and treatment is presented to us by the students in turn and afterwards criticized and discussed; and finally at eleven-thirty one patient is given the class as a whole, an historian in daily rotation is appointed who elicits the story, the students make their own observations, and then go home to write up with all possible aid from books, but not from each other, the full record of the patient. The result is a four or five page daily thesis, which is corrected by me the following night, and on the ensuing morning the various mistakes of each man are explained to the writer and to the class. A written examination on book knowledge at the end of the month completes this course. From this rather long and intimate experience with fourth-year students I have been impressed by the fact that the young, eager, plastic medical student can take a much better history than can the hardened, hurried, seasoned campaigner, because this history is based on a more universal, thorough, modern medical knowledge than the older specialist can command and because, best of all, it is free from bias. To my mind it has become clear that the older a man grows the less capable he becomes of asking questions.

I offer another course to fourth-year men of the Harvard Medical School, in which they give themselves up to the dermatological department of the Massachusetts General Hospital from nine o'clock in the morning until five in the afternoon. Such a student for the first hour and a half of his day's work would serve us well as historian *pro tem.* He has had previous training in history-taking in his prescribed four months' course in the medical and surgical out-patient departments of the hospital and, after a few days of coaching in our special needs, would serve our purposes well.

Here again I want to pause to lay stress on two comparatively modern requirements in history-taking. A dermatological history nowadays, which does not contain the full account of the patient's social condition and environment and the minute details of his daily occupation, is no longer regarded as complete. To prescribe medicines which can't be paid for, to detail methods of procedure which can't be carried out, to advise food which can't be obtained, are solecisms which modern clinics no longer commit. To continue treating dermatitis venenata and eczema without knowing the exact methods of the patient's occupation, to persist in our endeavors to cure chilblains without asking the nature of a person's work or play, to strive to do away with a workman's calluses without inquiring into his necessary daily postures, are methods no longer condoned. I have cited in these occupational instances the disease chilblains because of a very illuminating instance in this year's

experience in history-taking. A young girl came for advice because of very blue and cold and moist hands and feet—a condition which had persisted summer and winter for some years. Careful questioning revealed the fact that this girl stood for hours in a cold room, unheated in winter and chilled in summer, picking chocolates from a moving belt upon which was directed a constant blast of cold air. If there is time and ambition such contributing causes can be found and elicited in many more instances by the history taker, than we really appreciate.

Among the many branches of hospital efficiency which the Massachusetts General Hospital is trying to instil into all its services, I believe none to be more important than these two,—the complete social and occupational knowledge of the patient. The reputation of the hospital's social service work is too well known to require any further mention here, but I want to say a word about its new occupational disease clinic.

For the last two years, at the request of Dr. D. L. Edsall, all departments have been sending their occupational suspects to one special worker, who has gathered together a valuable mass of knowledge and statistics. This year the hospital feels justified in establishing a special clinic to study these cases most minutely, and has placed at its head a recent graduate, Dr. Wade Wright, who is peculiarly fitted by his knowledge and his keen "social" point of view to carry this work successfully forward. I am personally satisfied that his four months' service in the skin ward has peculiarly adapted him to the cutaneous requirements of the position.

When the patient's history has been written and his proper turn has been reached, the clinic secretary conducts him and his history card to the physician, or if he needs to disrobe the clinic secretary requests the clinic nurse to take him to a dressing room and see that he prepares himself promptly and assist him, if necessary, and then tell the physician that the patient is quite ready. The nurse also remains to chaperone and to assist the women patients.

When the new patient is examined by the physician, it is to be hoped that at the same time he comes under the knowledge of an expert social worker. It is unnecessary to-day for me to speak of the proved value of such an aid both to the physician and to the patient—that is an accepted fact. She softens and humanizes the doctor's point of view and proves a veritable godsend to the patient.

In this connection it is interesting to note how many skin clinics in America have availed themselves of social service, a practice which had its foundation perhaps in the "Lady Almoner" of the London Hospitals in 1890, was instituted among volunteer students in Baltimore in

1902, and was further amplified and started upon its present basis in Boston in 1905. A recent canvass among the members of the American Dermatological Association reveals the fact, as based on a knowledge of forty-eight replies, that eighteen skin clinics enjoy the privilege of their own social worker, that seven have social workers connected with the hospital whose assistance can be invoked in cases of need, and that twenty-three clinics are as yet wholly without this modern adjunct of efficiency.

Both physician and social worker read the patient's history and both make their peculiar mental notes. The clinical descriptions and the prescriptions are now dictated to a stenographer (who typewrites them on the history card in the afternoon) by the physician, who then explains as fully as possible to the patient the methods of procedure of treatment, supplementing his advice with full printed direction if necessary, and the social worker adds still further to these directions, if she deems it suitable, and above all gets acquainted with the patient and tries to discover any individual facts bearing on his case. It is at this point that a firmer foundation for successful treatment can be laid.

Before the patient leaves, the doctor tells him the exact day on which to return and designates whether or not the clinic visiting nurse or the social worker is to follow him to his house in order to examine the home conditions, to oversee the treatment and to win his confidence if he needs mental or physical stimulation or financial assistance.

I have said above that the doctor tells the patient the exact date for his return. This is important for two reasons—it permits "follow-up" work (a function performed by the clinic secretary), and enables the first consultant to see the patient again if desirable. The readily visible card system designed for this follow-up work by the Boston Dispensary and since adopted by so many hospitals, serves its purpose admirably and allows the clinic secretary at a glance to note that the patient has failed to return on the day specified, when she at once writes asking for his early return to the hospital, or perhaps sends the social worker or the clinic visiting nurse to ascertain the cause of his absence. The adoption of this method has, one might almost say, revolutionized out-patient practice—a careless or indigent patient is literally forced to get well if it is possible, and diseases interesting for study and desirable for teaching are not lost to the clinic. In such an affliction as syphilis one cannot estimate the value of this service to the patient, to his wife, his children and intimates, and to the community.

At this point it is appropriate to discuss the really vexing and perplexing question as to the best method to adopt for the examination and

treatment of patients. It is now a fact, I believe, accepted by all, that each department of a hospital should have its chief, nominally on duty the year around, who shall direct the permanent policies of the department. But what is to be the policy as to the examination of the out-patients? Shall the second in command see all the new patients and depute the care of the old ones to the third and fourth in rank? Or shall the physician who begins the care of a patient see him through his illness, if possible, to its end? Or again, shall the members of a clinic, even a special clinic, subdivide their activities still further and assume individually the care of all examples of certain diseases or at least groups of diseases? This seems to be a growing tendency in many departments of the Massachusetts General Hospital, and in my service, for the time being at least, Dr. Burns is given general charge of the operative diseases, Dr. Blaisdell of the radium cases, Dr. Cummins of all cases of psoriasis, and I have been interesting myself for the last two years particularly in eczema. I believe this to be an excellent idea, if not carried too far; but, on the other hand, that this idea has been carried too far in a certain instance I am equally well assured. These are questions which have not yet been wholly and satisfactorily solved. All these methods have their advantages, but their disadvantages as well. For instance, it is rarely possible for a clinic to be composed of men equally capable in diagnostic and therapeutic ability. Is it fair to deny any patient the privilege, sooner or later, of coming under the best man's care? It is not unknown for a department to carry on its roll a man guilty of making frequent diagnostic errors. Is it a square deal for an invalid to start and end his hospital career under this man, when he might at the second or third visit come under the best man's care? One might answer these questions by saying that such an inferior man should not be allowed to remain a member of the hospital staff, but in these modern days of great and serious exactions on the part of our hospitals, it is not always possible, in the smaller specialties at least, to find and retain comparatively perfect men for every staff. The old hospital method of rotation in office, by which the passage of time brought each man to the top, has been abandoned by most institutions, and its passing has taken away many good men of middle age who, seeing a younger man promoted over their heads, have given up their hospital positions and retired to private practice. This new method will, or perhaps has already, proved to be the best, but it has undoubtedly robbed clinics of many useful and experienced men who would have continued for some years to serve the public and serve it well. The result of these unhappy early changes has forced the heads of departments to bring into their services younger men who have, in

certain instances, been given positions of responsibility which they are not at first quite able to fill.

There are at present in our hospital practice at least two checks on inefficient work; I refer to the clinic conference and the "round-up." Let me explain these phrases. Once a week the members on duty in the skin department of the Massachusetts General Hospital, under the chairmanship of the ranking physician on duty, meet together in conference and are joined by the house officer, the social service worker, the clinic secretary, the clinic visiting nurse, the clinic nurse and the clinic stenographer. Here, in parenthesis, I want to emphasize the exact relationship of the clinic social worker to the clinic visiting nurse. The social worker bears the same relation to the visiting nurse that she does to the physician. Her work, for the most part, runs along purely social lines, while the duties of the doctor and the nurse are mainly in the direction of medicine. To this regular group is added, from the resources of the general social service of the hospital, the special worker in the field of medicine which concerns the given patient whose case is before the conference for discussion. This may be the tuberculosis worker one day, the occupational disease worker another or again a worker or representative from some other institution. At these conferences, stenographic reports are taken, read and corrected at the next meeting, and preserved for future reference. Then in turn each member of the group, medical as well as lay, is consulted as to any difficulties which have beset his path in the previous seven days. These difficulties are discussed most freely and informally, but according to parliamentary procedure, and it is quite surprising, in looking back over the records of these weekly conferences, to see what a variety of subjects concerning the welfare of the patients and of the clinic have been discussed, and, if I may say it, how much more the department has been able to accomplish since the inception of this work. Let me cite four illustrative examples occurring in my last service.

1. The question of improving our treatment in cutaneous tuberculosis. For a long time some of us have been much disturbed over our poor therapeutic results in lupus vulgaris. We have tried every known method except the Finsen lamp, and the final outcome has been in a large majority of the cases a return of the disease. In several conferences the subject was argued and discussed, and the general verdict evolved was that a radical change must be made—in other words, we decided that the Rollier method of treatment of surgical tuberculosis held out the best prospects. The chairman of the State Board of Tuberculosis was interviewed and he could promise no sanitarium help to our

patients, as accommodations for pulmonary tuberculosis were still far below requirements. We then turned to the Executive Committee of our own hospital and asked for a hearing. The request was granted, and to this meeting were invited representatives of the Skin, Orthopædic and Genito-Urinary departments. As a final result a bill was prepared asking for an investigation by the State of the subject of non-pulmonary tuberculosis and presented to the General Court, and I am glad to say that this bill has thus far in its political progress met with signs of favor.

2. The question of the treatment of scabies. Certain members of our department have been noting for some time that among our really poor hospital patients it was perhaps a comparatively easy matter to rid a child of his scabies, but that it was a very difficult matter to keep him from reinfection. For some time it has been our rule that the social service worker or the clinic visiting nurse shall go to the house of every indigent patient with scabies, send to the hospital for examination every suspect found at the home, and see personally that each infected member of the household and his body and bed linen are properly treated. I want to illustrate some of the difficulties in the execution of this good rule, by the following incident: A reinfection of scabies came to our notice, and in consequence our clinic visiting nurse was sent to a small New England village, perhaps twenty-five miles distant from Boston. At the next clinic conference Miss Olsen made the following report, which I quote verbatim:

"The people were clean, apparently fairly comfortably well-off Americans. The father, mother and four children had scabies. Mrs. B. seemed sure that she knew the source of their infection, and this is the gist of the story:

"A family named A. live near the B's. The former family is neither neat nor clean. A daughter works occasionally for the women of the village. At the time of the B's'. first attack, Miss A. was there and was seen scratching. Another A., a son, works with logging gangs on the road, and is intimate with many of the boys in the village, with whom he goes on hunting and camping trips. Recently, just before the B's.' second attack, this boy stayed overnight with the C's., neighbors of the A's., and parents of Mrs. B. Several days afterward, Miss C. began to itch. She visited her sister, Mrs. B., and played with the children, etc. A few days later, the B's. began to scratch, and at this time were visited by the niece of Mrs. B. from the town of X. Mrs. D. wrote to Mrs. B. that she and her children itched, and that she had visited her husband's mother, Mrs. E., in a nearby town, who had also been infected. With the

C's. lived a boy, F., who goes to school in Boston, and this boy was also itching. Another family, neighbors of the A's., named G., were desperately trying to rid themselves of the common plague, and Mrs. B. stated that she was 'pretty sure' that several other families in the vicinity had been infected, primarily through the A's., who, she says 'never take a bath,' and who have had an 'itch' for a number of years.''

Thus, you see, our nurse has traced the infection to at least seven families scattered about in neighboring towns of Massachusetts. Such an epidemic was, of course, beyond our control and we presented the facts to the Chairman of the local Board of Health and asked that he take action at once.

At times our visiting nurse encounters considerable lack of coöperation and even hostility in her efforts to eradicate scabies from a household. In such cases we have found it a very telling expedient to report the contagion to the School Health Inspector, who immediately excludes the infected child from school. This strikes home, and the usual result is a speedy surrender of the recalcitrant parent and an early disinfection of the household and its members. Then follows the clean bill of health, and the child is allowed to return to school.

3. Better procedure as to the admittance of patients to our skin ward. We had been annoyed by the existing methods of admitting patients to our ward. We seemed either to have a long waiting list of very eligible patients and no empty beds or to have a number of empty beds with no available persons to fill them. When our grievances were brought to the notice of the hospital authorities we met with active and hearty response, and were told that the ''Front Door'' would adopt any feasible scheme which we would present. Time in several conferences was given to the discussion of this really ''live topic'' and a serviceable method, very elastic in its working, was evolved and subsequently adopted by the Admitting Physician of the hospital.

4. The difficulty of securing suitable homes for worthy patients incapacitated by chronic dermatoses. We had treated in our skin ward a very deserving Englishman, afflicted by constantly recurrent, distressing and conspicuous attacks of eczema psoriasiforme with elephantiasic thickening of the ears. The man had been in our ward so often and so much that the hospital authorities quite properly began to remind us that the institution was intended and must be used for acute cases of disease. The question then naturally arose as to where this patient could go and be properly cared for. We regarded him as not quite fit socially for any of our pauper establishments. The man's case was discussed at several conferences and several of our members interested

themselves in the matter, all to no avail, unfortunately, as in the end we were obliged to send the man to the State Hospital in Tewksbury. It is interesting, perhaps, to note the number of people involved or consulted in this one case:

Massachusetts General Hospital (medical and social)	12
Social Service (social disposition)	1
General Electric Co. of Lynn (wage adjustment)	2
Lynn Hospital (medical disposition)	1
City Physician of Lynn (medical disposition)	1
Associated Charities of Lynn (financial aid, private charity)	2
Doctors in Lynn (medical disposition)	2
Overseers of the Poor (local public charity)	1
Sons of St. George (lodge insurance)	1
Tewksbury Hospital (public charity)	2
State Board of Charity (public charity)	1

A total of 26.

A second check on inefficient work is provided by one or all of the following methods, *i.e.*, the "clinic survey," the "round up" and "the end result" catalogue—all perhaps rather synonymous terms.

The Clinic Survey. When the clinic secretary or any other member of the clinic staff notes that a given patient has returned frequently or over a long period of time to the hospital without any marked benefit, she draws the attention of the ranking physician to the fact. Someone is asked to write a résumé of the case as gleaned from the patient's history. The patient is then requested to return on a certain day when the senior physician alone, or in consultation with one or more of the clinic medical staff, or before the whole clinic conference, reviews the case and an intensive study of the individual is then instituted. Such a case as the Englishman with eczema psoriasiforme, previously described, illustrates this point very well.

The Round-Up. When some member of our working force is not satisfied with the results the clinic or any of its members is obtaining in a given disease, he can, by the aid of the clinic secretary, summon to the hospital on a given day or at stated intervals one or more representatives of the disease in question, and by this group method study the malady more advantageously or try in this more intensive way, any new form of treatment which he or his colleagues may have planned or discovered. We had this past winter such a "round-up" of our lupus vulgaris patients. Each one in our catalogue was requested to appear

and was asked if he would be willing to go to a sanitarium, if such a health resort could be found. In addition to this information, so necessary to our future action in the matter, we took the opportunity to note the physical condition of each patient, and in some instances began inspection of the home conditions, the results of which were in some cases illuminating, to say the least.

The End-Result Catalogue. This term is too well known to need any elucidation. It is, I believe, a status to which we must all follow suit or else lag behind in the march of progress.

In the skin ward, conditions for effectual work are more or less the same in kind as in the out-patient department, only of course efficient service is more easily at hand. We must remember one fact, however: The comfortable and sanitary and easy life in a well-equipped hospital may produce a rapid cure or a distinct amelioration of symptoms, but will the home conditions permit the continuance of these favorable results? Not always, as we of experience know. I remember so well a case of prurigo mitis in a young French girl. She would come to us in a most distressing condition; she would be bathed, properly clothed, suitably fed and comfortably rested and in a few weeks go home apparently cured. A few months later, however, the drama would be repeated, and in those earlier and unenlightened days we seemed powerless to help ourselves. Now, social service and visiting nurses, with funds for the needy at their disposal, have more or less done away with such unfavorable results. The same conditions exist in other dermatoses. Adults and especially babies with chronic eczema, for instance, would in previous days be sent home cured or patched up, only to return in the same diseased state after a few days or weeks of home life. It is a standing rule now, that our visiting nurse go to the home of every patient admitted to our ward with eczema and scabies, inspect the premises, clean them if necessary and institute with tact and by instruction and demonstration, exactly what we want for the patient's home-coming and future maintenance. A weekly visit and consultation of the whole staff is a very valuable procedure, alike to the patient and to the physicians.

Teaching. Thus far I have said nothing about teaching, which I believe to be one of the greatest incentives, perhaps the greatest, to thorough and efficient work in our hospitals. No teacher of the modern, thoroughly grounded medical student would have the effrontery to meet these keen young men in the small sections, now demanded in the upper classes by the up-to-date medical school, without knowing that he is conversant with the latest knowledge of his special field, for the intelligent

and searching questions of these classes would soon reveal his ignorance and force him to resign his teaching post or else to fit himself better for the work. I believe, therefore, that every member of a hospital clinic should be given the opportunity to teach in order to force him, if necessary, to keep up the theoretical side of his training. I believe, also, and I speak from an experience of eighteen years of teaching, that this work is in the best interests of the patients, for I am always impressed with my own increased knowledge of a given individual's disease after I have devoted a half hour or more to the discussion of his case with one of my fourth-year elective classes.

This rotation of teaching duty can be arranged without interfering with the conduct of the clinic if we can provide an ample working force.

I have reached the end of my theme. To some of you I have presented, perhaps, some new ideas; to others only familiar facts, but I feel sure that these facts, new or old, are facts worth knowing, and if adopted by us all would lead to better work on our part and better results to our patients.

One word and I am finished. These new ideas require money, considerable sums of money, but I feel convinced that these sums should be raised by the hospital authorities and not by us physicians. The modern hospital rightly requires, and is beginning to demand, efficiency. Efficiency means longer hours of duty and more concentrated work on our part, and when these new burdens have been added to our already crowded day of teaching, private practice, correspondence, study, and possibly research and committee work, we should not be expected to go out into the world and play the rôle of beggars—that is not our province and it should not be expected or required of us.*

And now, gentlemen, an inviting programme awaits us and I will yield the floor to those who are to present to us the fruits of their recent labors.

* I wish to thank Miss Lewis, the social worker of the syphilis department of the Massachusetts General Hospital (Miss Oiesen, the skin social worker, being ill) for her kindness in looking over my manuscript.—C. J. W.

ORIGINAL COMMUNICATIONS.

REPORT OF TWO CASES OF IDIOPATHIC HÆMORRHAGIC SARCOMA (KAPOSI), ONE PRESENTING UNUSUAL FEATURES, WITH SPECIAL METHODS OF TREATMENT AND INVESTIGATION.*

By T. Caspar Gilchrist, M.D., and Lloyd W. Ketron, M.D., Baltimore.

(From the Department of Dermatology of the Johns Hopkins University.)

Case 1. The patient was a man, aged 65 years, who was in fairly good health when first seen by us, except that he complained of swelling of his legs, feet and hands, and had a fairly generalized skin eruption.

His family and previous cutaneous history were unimportant. The disease began three years previous to examination, at which time he noticed a dollar-sized, deep-reddish lesion on the outer side of the right leg, near the ankle. There were no premonitory symptoms of any kind. The lesion slowly increased in size for about five months, assumed a dark, purplish red color and became much indurated. Then, gradually, other similar lesions began to appear on both legs, accompanied by swelling of the lower extremities. After this the buttocks, thighs, hands, arms, face and ears gradually became involved. (See Fig. 10.) The lesions usually began as reddish, nickel-sized areas, which gradually became darker in color and more and more indurated, until large, raised, deeply pigmented, flat nodules were formed. The patient said that the areas had increased rapidly in number in the last four months while he was under treatment in another city. This treatment consisted of the application of X-rays, twice a week (17 treatments) and the ingestion and the intramuscular injection of Fowler's solution.

When the patient was first seen by us, he had about four to five hundred nodules scattered chiefly over the whole of both upper and lower extremities, including the toes, soles of the feet, fingers and palms and a few reddish patches on the nose, cheeks, chin and ears. The lesions

* Read before the 39th Annual Meeting of the American Dermatological Association, New York City, May 13-15th, 1915.

Editor's Note: This article was received too late for publication in the Transactions of the 39th Meeting of the American Dermatological Association which were concluded in the last (May) issue of The Journal.

varied in size from the quite recent, deeply situated, indurated, pea-sized or smaller shot-like papules or nodules, up to quite large confluent areas which reached the size of 7 by 5 cm., and were raised about 1½ cm. above the surface of the skin.

The majority of the nodules on the thighs and arms were round or oval in shape and about 2 cm. in diameter. They were raised, flat, deeply pigmented, of a brownish or purplish red color and were markedly indurated. The disease appeared to extend deeply into the corium, and on the toes, especially on the margin, the eruption had assumed a definite papillomatous character. On the back of the right thigh the areas were so numerous that the middle portion of the thigh formed one large, purplish, indurated plaque. The most interesting lesions were the recent ones on the upper arms which were not visible but could just be palpated as small, deeply situated, almost shot-like nodules lying beneath the skin. Around many of these there was a hæmorrhagic area 2 to 3 cm. wide, which resembled a bruise. On the face were a number of cyanotic areas situated over the tip of the nose and on the cheeks, chin and ears, all of which were flat, irregular in size and deeply infiltrated. Both ears looked as if they were affected with chilblains. The hands were so swollen that they could not be closed. The fingers were almost entirely involved with deep, reddish, infiltrated areas which gave to them a tense, shiny, swollen appearance. Many flat nodules were found on the backs, sides and palms of the hands. The hands, forearms, legs and feet were markedly œdematous. No lesions were found on the trunk or in the mouth and the internal organs seemed to be unaffected. The patient's blood was normal and all the natural functions were practically unaffected.

Three different methods of treatment were used and with excellent results. The patient was given daily intramuscular injections of ¾ gr. of the cacodylate of sodium, and after ten days this was gradually increased to 2 gr. The hands, legs and feet were exposed daily to mild, soft X-rays, and radium (10 mg. old measure) was applied for 24 hours to one nodule after another, on the arms and legs, until about 90 lesions were treated. After six weeks, the patient was remarkably better. The œdema of the hands and feet had almost completely disappeared after three weeks' treatment, and the hands could be closed. Where the X-rays were applied, the induration had disappeared but the pigmentation remained. The radium applications gave decidedly the best results, causing the induration and pigmentation both to entirely disappear, leaving the skin practically normal.

The patient said that he never felt better in his life, and one could say, after six weeks' treatment, that his skin lesions were 75% better. He then returned home, as he could remain in Baltimore no longer.

Case 2. The patient was a very healthy looking farmer, 58 years old, who was brought to one of us by his physician for consultation for a persistent skin trouble of the face. The disease was thought to be rosacea.

The family history was unimportant but the patient had had, for some years at various times, scaly patches on the elbows, knees and shins.

On the face there were six distinct lesions, five of which, at first glance, would be taken for chronic localized patches of rosacea. The majority of the lesions were situated on the lower third of the nose; two on the right side and three on the left. The two on the right side were semiglobular, firm, raised reddish-brown nodules, about 4 mm. in diameter and were of 2 years' duration. Those on the left side were deep red, smooth, flat, rather linear-shaped elevations which showed deep infiltration on palpation and measured about 3 by 6 mm. The patient did not know the exact duration of these, but it was probably about 6 to 8 months. About the middle of the cheek and the centre of the chin were the most recent lesions, which were of about one month's duration. These consisted of dark red, slightly raised, deeply infiltrated patches, which measured about 1 by 1½ cm. and the color could not be pressed out of them. No dilated vessels or hæmorrhages were present and there were no subjective symptoms. The appearance of the lesions reminded one of us most strongly of the facial outbreak in Case 1 which had been seen earlier in the day, otherwise the diagnosis might have offered considerable difficulty.*

The diagnosis was confirmed by microscopical examination, which is described later.

The patient was treated with filtered X-rays and the lesions entirely disappeared and there has been no recurrence within the last ten months.

Vaccine Therapy. In order to test the effect of an autogenous vaccine and also the possibility of transmitting the disease to animals, the following experiments were carried out on Case 1 of Kaposi's disease.

A quarter-sized, pigmented, deeply infiltrated lesion on the thigh of the patient was excised and immediately placed in sterile Ringer's solu-

* This case appears to be unique in the fact that the disease began on the face and that the diagnosis was made when only seven small lesions were present. The usual history, as Crocker describes it, that the condition begins as diffuse cyanotic spots which pass into infiltrations and then into nodules, with or without preceding œdema, shows that the disease had an unusual beginning as well as location.

tion. The piece of tissue was then divided into small bits with scissors and forceps and afterwards thoroughly ground up in a mortar with sterile sand. To the resulting mixture, about 15 cc. of Ringer's solution was added and the whole shaken for 10 minutes in a glass-stoppered bottle. The solution was then centrifugalized for 15 minutes, leaving a translucent, whitish supernatant fluid (SOLUTION A). This supernatant fluid was then pipetted off from the mixture of sand and tissue fragments and a portion of it was passed through a Berkfeldt filter, resulting in a perfectly clear solution (SOLUTION B).

All of these steps were carried out with sterile technique and the material was kept, as far as possible, at body temperature.

One cc. of SOLUTION A and one cc. of SOLUTION B were injected both intradermally and subcutaneously in the skin of the patient's back, between the scapula and the spine. A similar amount of the Ringer's solution was also injected in other areas, as a control. The patient was carefully followed for several weeks after, but no appreciable effect was observed on the course of the disease, nor was there any development of lesions in the areas where the vaccine was injected. One cc. of SOLUTION A and one cc. of SOLUTION B were injected on either side, deeply into the pectoral muscles of a chicken, but no growth resulted from these injections and the health of the fowl was in no way impaired, as far as could be observed.

HISTOLOGICAL EXAMINATION. For the purpose of histological study, three lesions were excised from CASE 1 of Kaposi's disease, representing clinically different stages in its evolution and one lesion was also taken from the face of CASE 2.

PREPARATION NO. 1 (CASE 1). These sections were made from a deeply situated, pinhead-sized, invisible nodule on the arm, which was barely palpable and over which the skin was not discolored.

Under low magnification (Fig. 1), one saw five or six irregular, rather sharply defined formations of new tissue which lay in the lower depths of the corium and in which could be seen portions of the sweat glands. These new formations consisted of two types of tissue, the one (1) resembling an angioma and the other (2) a richly cellular connective tissue. Each type could be recognized in its pure state and also transitional stages between the two, showing the gradual replacement of the angiomatous by the richly cellular type. The individual blood spaces constituting the angiomatous areas (see Fig. 2) were filled with well-preserved blood cells and varied in size from the smallest capillaries to 200 to 300 mm. in diameter. The interstitial net-work was composed of a single strand of connective tissue or, as the transitional stages were

approached, the bands became wider and more cellular and the blood spaces became smaller. In the areas showing the transitional stages, the largest of the blood spaces lay at the periphery of the new formations, supported on one side only by a single layer of endothelium and the normal compressed collagenous tissue (see Fig. 3). Towards the centre, the interstitial tissue became denser and the blood spaces comparatively smaller. The endothelial lining of many of the blood spaces showed active signs of proliferation and swollen cells were seen growing off from the walls. In some areas the bands of interstitial network had ruptured and the free ends were lying loose in the lumen of the vessel (see Fig. 3).

The second type of tissue was arranged, in some areas, in bundles with large, spindle or oval nuclei resembling newly-formed connective tissue (Figs. 3 and 4). In other areas the nuclei, which were much more abundant and lay in irregular groups of cords, varied in size and shape from those which were small, irregular or round, to the large or oval, vesicular ones of the endothelial or fibroblastic type.

All stages could be recognized between tissue types (1) and (2). At one end were seen the widely dilated capillaries with practically no supporting wall which represent the first stage of the development of the individual lesions; in the second or intermediate stage, the blood spaces were much smaller and the interlying stroma much more abundant, and later in the third stage of the development, the angiomatous areas were completely replaced by the newly-formed spindle or oval-celled tissue which had its origin in the endothelium and the interstitial connective tissue of the blood spaces.

The small arteries in the new formation showed a pronounced fibrous thickening of their coats, to complete obliteration in some cases (Figs. 4 and 5). In the surrounding normal tissue the collagenous bundles showed no definite changes, except probably here and there a swollen fixed tissue cell, but marked changes were seen in some of the capillaries and small vessels, which were widely dilated. Endothelial cells were seen growing off from the vessel walls into the lumens and at various places there seemed to be newly-forming capillaries and delicate offshoots of newly-forming connective tissue. Almost all of the vessels in the surrounding area showed a certain degree of perivascular infiltration. The cells were of the small lymphocytic type, with here and there an occasional plasma cell. Small areas of blood pigment were scattered in the normal as well as in the abnormal tissue, some of which had been taken up by the cells.

Preparation 2 (Case 1). Sections were made from a hard, purplish-red, pea-sized, elevated papule on the abdomen (Fig. 6). In these sec-

tions were seen none of the angiomatous areas as in the sections first described. Comparatively few blood vessels were observed at all, and most of these were represented by fibrous cords. The endothelial cells, in some cases, seemed to be changing into the fibroblastic type of cell and growing out into the surrounding tissue. There was a general diffuse infiltration of all the layers of the cutis, by a very richly cellular tissue with large oval or spindle nuclei resembling a young connective tissue overgrowth. In some areas, especially in the deeper layers about the remains of the sweat glands, the cells were arranged in irregular strands and the intercellular substance had an older, fibrous appearance. In other areas small cords or strands of endothelial or fibroblastic cells grew out into the collagenous tissue in a manner resembling newly-forming blood vessels. The elastic and collagenous tissues were broken up and, to a great extent, replaced by the new growth. Here and there were seen a few small round cells or nests of plasma cells. In the deeper layers the larger blood vessels showed an extreme grade of thickening, especially in the media portion of the wall, which, in the case of one artery, projected into the lumen as a large protuberance (Fig. 7). This ingrowth was also observed in some of the smaller vessels directly under the epidermis.

Preparation 3 (Case 1). This was a cherry-sized, somewhat pedunculated, dark red tumor of a very soft consistency, excised from the foot (Fig. 8). In the sections from this tissue very active signs of degeneration were present. Towards the centre of the preparation the tissue ran in strands or bundles in various directions. The nuclei were round, oval or spindle shaped but many of them were long, narrow, with blunt ends, in which case the bundles resembled those of a myoma. Towards the periphery of the section the cellular substance had degenerated into a finely granular, pinkish staining reticulum and the nuclei were very much fewer in number. Here the cells resembled a myxomatous or embryonic connective tissue. The surrounding epidermis had degenerated until, in some areas, no nuclei at all were seen and in the lower layers of the remaining substance there was an infiltration of polymorphonuclear leucocytes. In no place was there a trace of elastic tissue.

Preparation No. 4 (Case 2). This was taken from one of the small, shot-sized, reddish growths on the face. Here was seen a rather sharply circumscribed new growth lying directly underneath the epidermis (Fig. 9). Towards the periphery there were many large blood spaces which became smaller and fewer in number as the centre of the section was approached. The interstitial tissue showed active signs of proliferation in some areas. Here the cells were mostly spindle shaped with

oval or spindle nuclei, many of which showed swelling and increase of their chromatin net-work, with here and there mitotic figures. In these fields the resemblance to angiosarcoma was striking (Fig. 11, a). In other areas the nuclei were more deeply stained, irregular, shriveled and of the older connective tissue type (Fig. 11, b).

ÆTIOLOGY AND PATHOLOGY. GENERAL CONSIDERATIONS. The pathological findings of most investigators of Kaposi's disease have been, in general, similar. Two types of tissue have been found, namely, a cavernous angiomatous tissue and a spindle cell tissue. The individual lesions may consist entirely of either type, but there is usually a mixture of the two; the spindle cell tissue becomes more prominent as the lesions grow older. There is also a variable amount of perivascular infiltration of lymphoid and plasma cells. In regard to the origin of the spindle cell tissue, however, there has been a wide divergence of opinion. Some investigators trace its origin to endothelium, some to connective tissue, others to the perithelial vascular tissue, and still others from smooth muscle tissue and finally, one writer, from the plasma cells. There is also a difference of opinion in the interpretation of the pathological findings. Some workers consider the disease a form of sarcoma, others think the tissue too highly organized for sarcomatous tissue, and attribute to it more the characteristics of organizing granulation tissue.

The adherents to the infectious nature of the disease support their arguments mostly on its clinical behavior, notably, its preponderance in certain countries, its location and symmetry, long duration and tendency to involution.

Kaposi (Lehrbuch der Hautkrankheiten, Hebra and Kaposi, 1876), who first described the disease, found histologically a small cell sarcoma. He thought it was a general disease because it began at the same time on both the hands and feet.

Semenow (*Monatsh. f. prakt. Dermat.*, 1897, xxv) examined two of his cases post mortem and, besides nodules in the skin, stomach and intestines, liver, pancreas and kidneys, found the spinal ganglion cells filled with pigment and a swelling of the neuroglia nuclei and a proliferation of the connective tissue in the peripheral nerves. He thought the disease was related to changes in the trophic nerves, induced, in some cases by the action of cold and exposure.

Campanna, and later, Saphier (*Archiv. f. Dermat. u. Syph.*, 1914, cxviii) also, found the disease spreading along the peripheral nerves of the skin.

Fordyce (*Amer. Jour. Med. Sci.*, 1900, cxx) considered the disease one of the best illustrations of a true angiosarcoma, *i.e.*, one made up of connective tissue elements which apparently originated from the adventitia of the vessels. Development of blood vessels was also a marked feature.

Lieberthal (*Jour. A. M. A.*, 1902, xxxix) found primarily a proliferation of the endothelium and adventitia of the blood vessels and considered the condition a slowly growing sarcoma which might become malignant.

Philippson (*Virch's Arch.*, 1902, clxvii) believed in the infectious nature

of the disease. The pathological changes were a new formation of capillaries and spindle cell tissue. The virus, according to the author, gets into the blood, after an incubation period, where it may call forth either type of reaction, *i.e.*, the spindle cell or the hæm- or lymphangiomatous type.

Bernhardt (*Arch. f. Dermat. u. Syph.*, 1902, lxxii) found the condition to be histologically an "angiosarcoma periteliale fusocellulare," but believed its origin best explained by the parasitic theory.

Unna (Histopathology of Diseases of the Skin) classes the disease with the sarcomata and gives to it the name "acrosarcoma multiplex cutaneum teleangiectodes."

Halle (*Arch. f. Dermat. u. Syph.*, 1904, lxxii) found the process first developing as an angioma and later, due to the proliferation of the vascular perithelium, it took on the characteristics of an angiosarcoma. He considered it a peculiar form of sarcoma.

De Amicis (*Monatsh. f. prakt. Dermat.*, 1897, xxv), who has examined more cases than any other investigator, thought that the relation of the disease to sarcoma was a close one, and that the primary lesions must be considered a type peculiar to itself, lying between a granuloma and a sarcoma.

MacLeod (*Brit. Jour. Dermat.*, 1905, xvii) believed that whatever the initial cause of the disease may be, it attacked first the blood vessel, causing a proliferation of the endothelium and perithelium, a dilatation and extravasation of blood, and a proliferation of the fixed cells in its zone of reaction. "It has more the appearance of a proliferating connective tissue than a sarcoma and still less does it resemble a granuloma."

Pick (*Arch. f. Dermat. u. Syph.*, 1907, lxxxvii) thought that the spindle cell tissue had its origin in the plasma cells which accompany the blood vessels. These plasma cells were capable of developing into endothelioid-like cells, which, after exhausted energy, ended in fibrous tissue. He classed the disease with the sarcoid growths.

Sequeira (*Brit. Jour. Dermat.*, 1913, xxv) considered the pathological reaction to be more of the nature of an inflammatory reaction than a blastoma.

Hartzell (*Jour. Cutan. Dis.*, 1908) thought the disease a sarcoma of special type.

Sternberg (*Archiv. f. Dermat. u. Syph.*, 1912, cxi) was able to study the nodules in the submucosa of the intestines, in one of his cases. The new formation corresponded in every way to the surrounding muscular coat. He considered the disease pathologically a combination of "lymph and Hæmangiectasien" associated with proliferation of the smooth muscle tissue.

Dalla Favera (*Arch. f. Dermat. u. Syph.*, 1911, cix) has studied the pathology of the disease very thoroughly in two cases which came to autopsy, showing nodules in the trachea, bronchi, lungs, stomach and intestines, lymph glands, and the skin. He believed that the spindle cell tissue originated from the connective tissue and, in the skin lesions, was able to trace the gradual change of the spindle cell bundles into the collagenous tissue of the corium and to demonstrate fibrils in the spindle cells. In the lungs, the small pin-head sized nodules had developed almost entirely around the small bronchi and the accompanying branches of the pulmonary arteries. The author believed that the exciting cause of the disease might call forth both types of reaction simultaneously, *i.e.*, the new formation of capillaries and the spindle cell growth. The quantitative relation between the two was variable but the angiomatous tissue became less pronounced as the lesions grew older.

A case of Kaposi's disease which was not recognized as such was reported by Winternitz and Boggs (*Johns Hopkins Bulletin*, 1900), under the title, "A Unique Coincidence of Multiple Subcutaenous Hæmangio-endothelioma, Multiple

Lymphangioma-endothelioma of the Intestinal Tract and Multiple Polypi of the Stomach, Undergoing Malignant Changes, Associated with Generalized Vascular Sclerosis and Cirrhosis of the Liver."

The patient was a man, 65 years old, and his condition was followed, off and on, at intervals for a period of three years. The first diagnosis made was cirrhosis of the liver and ascites. The cutaneous lesions did not appear until one year later, and then followed the usual course of Kaposi's disease. At autopsy, the pathological findings were most thoroughly investigated. The lesions of the skin were considered to be hæmangio-endothelioma and those of the intestines lymphangio-endothelioma. Their relation to these two systems was proven by the post-mortem injection of the vascular system with Berlin blue and carmin gelatin and the lymphatic system with India ink. Their most interesting findings were associated with the study of the blood vessels. There was a generalized sclerosis of the arteries and veins, which showed either a thickening of all the coats or an irregular proliferation of the intimal tissue in nodes or strands, which divided the lumens into narrow channels or completely obliterated them. The cavernous angiomata and the solid tumors were traced to the vegetative outgrowth of the endothelium. The authors believed that the extreme grade of arterial sclerosis in the subcutaneous tissue had resulted in the compensatory formation of new vessels. But in many places the endothelium lost its power of organization, resulting in cavernous angiomata or with a still further loss of organizing force, the vegetative function of the cell predominated and one had the formation of solid endothelial tumors. In the intestinal tract, the extreme portal obstruction, associated with cirrhosis of the liver, proliferative peritonitis and ascites, were thought to play a part somewhat analogous.

From our studies of Kaposi's disease we can offer nothing new as to its ætiology. The type of cellular reaction or growth corresponds undoubtedly more to that of a new growth than to the usual reaction to bacterial stimuli, but, as Rous has shown that certain sarcomata of the chicken may be transmitted by a filterable virus, so the tissue type of this disease cannot exclude its infectious nature.

From a study of the series of sections from the earliest perceptible and recent lesions to the oldest degenerated forms, one can trace the different stages in the evolution of the disease. First, there is a new formation and dilatation of the capillaries, due to some unknown cause. This is followed by proliferation of the interstitial tissue between and around these angiomatous areas, which gradually disappear. This tissue proliferation may be reactive or protective to the invasion of the angiomatous growth or it may be partially due to the malignant overgrowth of endothelial cells. As endothelial cells and connective tissue cells are very closely related,* both endothelium and connective tissue are most likely concerned in the development of the solid tumors.

* Adami sees a close relation between endothelium and connective tissue, and the observations of Waldeyer, Cornil, Baumgarten and others have shown that the connective tissue of organizing thrombi is almost wholly, if not entirely, derived from the endothelium. (Adami, Principles of Pathology, 1910, i.)

This new cellular growth, in the early stages, is identical with young connective tissue, or the cells may be of a more vegetative type, resembling a sarcoma. If the disease is not of infectious origin, metastasis takes place, no doubt, from lesions containing cells of this latter type. As the nodules grow older, the tissue assumes a more fibrous structure and may undergo resolution.

As to the cause of the spontaneous healing of the tumors, Kaposi thought it due to the hæmorrhage and fibrin deposits with subsequent organization and contraction. This idea is disputed by Philippson and Favera, who claim that the hæmorrhages stand in no direct relation to the involution of the tumors and that deposits of fibrin are very seldom seen. We would suggest that this involution is due to the gradual blocking of the small arteries, supplying the lesions by sclerotic processes.

The more vegetative a growth, the greater is the amount of blood required. As this supply is decreased, the tissue gradually reverts to the more resistant fibrous type, with, later, a complete involution in some cases. If the width of the source of blood supply is more narrow than usual, as in the case of the pedunculated tumor, our PREPARATION No. 4, then degenerative changes may occur in the new growth.

CONCLUSIONS (1). Two cases of Kaposi's disease are recorded, one showing the usual course and type, the other unique in that there were only six small lesions present, which were situated on the nose and cheeks.

(2). The cause of the disease is unknown; our results however, with an autogenous vaccine, suggest that it is not auto-inoculable.

(3). Our studies show that the lesions begin in the skin as angiomata, due to a proliferation and dilatation of the blood capillaries, which are very frail at first and liable to rupture. This is followed by a proliferation of the interstitial connective tissue and endothelium, which gradually obliterates the blood spaces, forming solid tumors. In the early stages these resemble, in some areas, young connective tissue, in other areas, sarcomata. As the lesions grow older they assume a more fibrous aspect, and may undergo involution. Coexistent with the formation of the tumors there is a sclerosis of the small arteries supplying them, causing a gradual decrease in the amount of blood. To this is due, most likely, their later evolution as well as involution.

(4). From this beginning, then, as a cutaneous angioma or later angiosarcoma, the disease spreads by metastases which first appear in the neighborhood of the primary lesion, and later become widespread both in the skin and internal organs leading, in many cases, to death.

Plate XXXIV.—To Illustrate Article on Idiopathic Hæmorrhagic Sarcoma, by T. Caspar Gilchrist, M.D., and Lloyd W. Ketron, M.D.

Fig. 1.

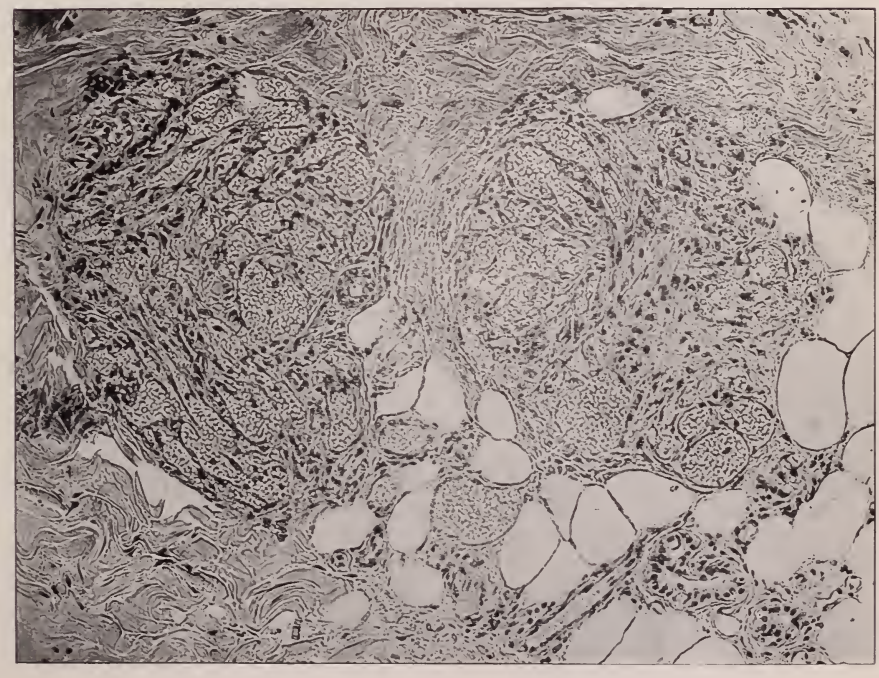

Fig. 2.

Plate XXXV.—To Illustrate Article on Idiopathic Hæmorrhagic Sarcoma, by T. Caspar Gilchrist, M.D., and Lloyd W. Ketron, M.D.

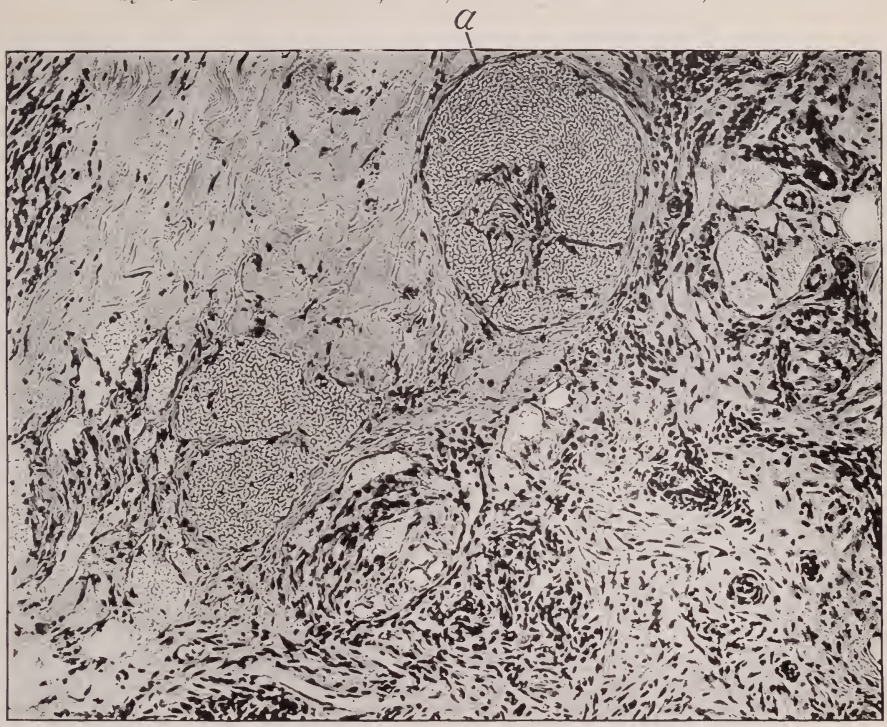

Fig. 3.

Fig. 4.

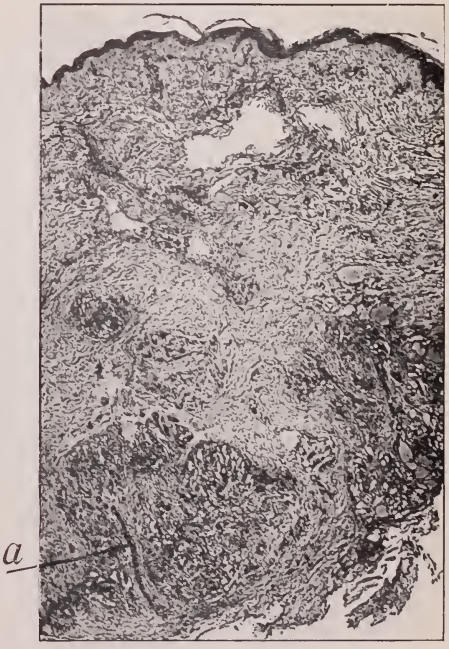

Fig. 5.

Plate XXXVI.—To Illustrate Article on Idiopathic Hæmorrhagic Sarcoma, by T. Caspar Gilchrist, M.D., and Lloyd W. Ketron, M.D.

Fig. 6.

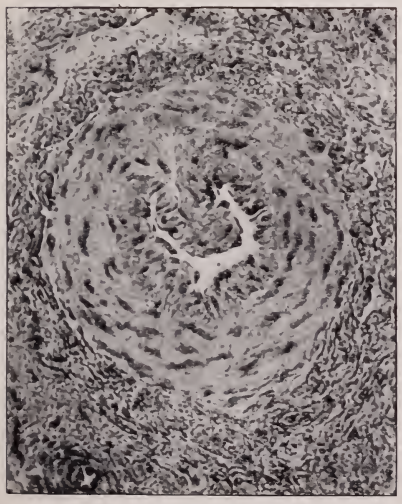

Fig. 7.

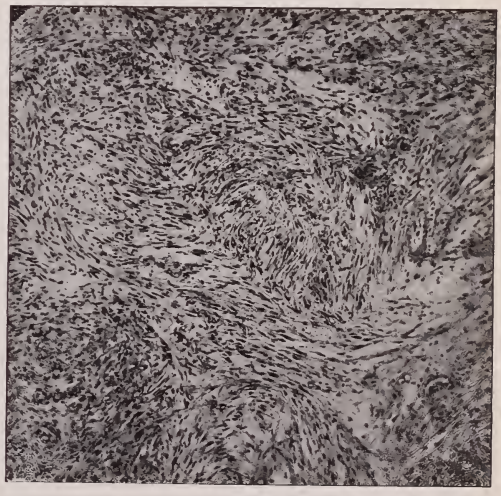

Fig. 8.

Plate XXXVII.—To Illustrate Article on Idiopathic Hæmorrhagic Sarcoma, by T. Caspar Gilchrist, M.D., and Lloyd W. Ketron, M.D.

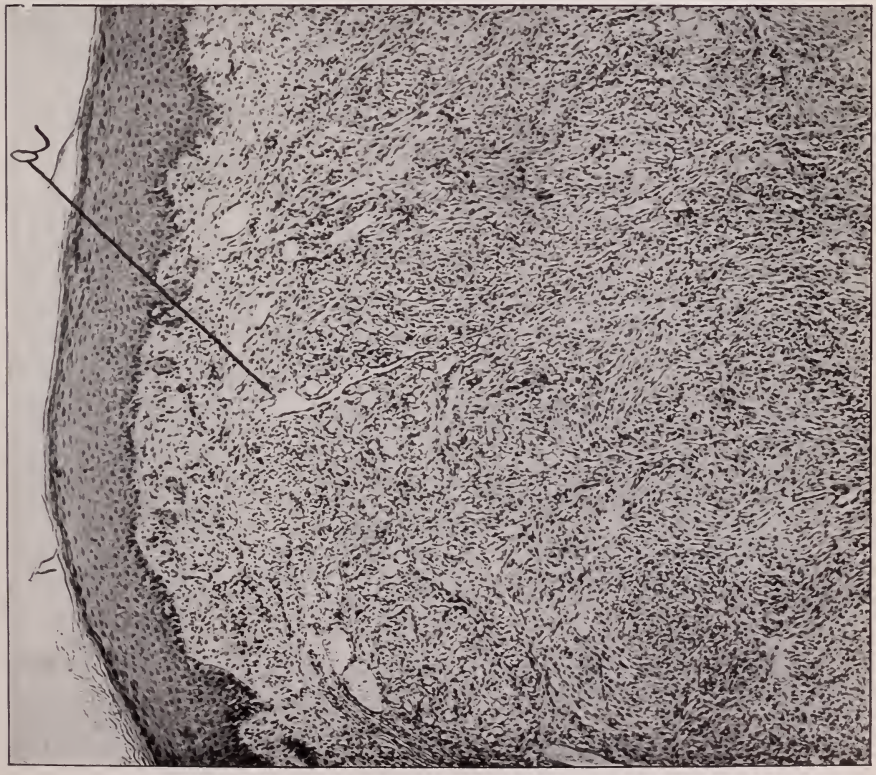

Fig. 9.

Plate XXXVIII.—To Illustrate Article on Idiopathic Hæmorrhagic Sarcoma, by T. Caspar Gilchrist, M.D., and Lloyd W. Ketron, M.D.

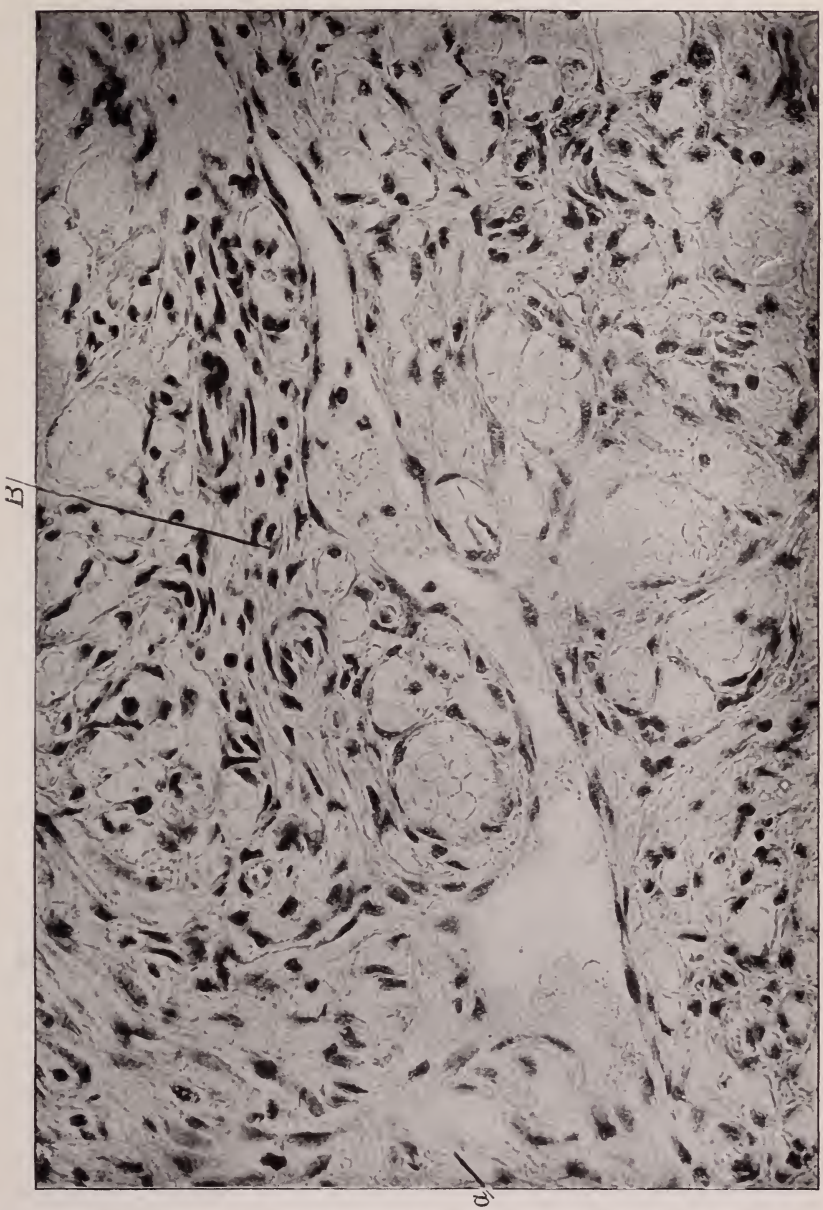

Fig. 11.

(5). The individual lesions of Kaposi's disease are very amenable to treatment by X-rays and radium.

Explanation of Illustrations.

Fig. 1. (Preparation 1) Taken from the smallest lesion which could be found in Case 1 of Kaposi's disease. Section shows position of the small new-growths in the lower depths of the corium.

Fig. 2. High magnification of Fig. 1 at *a*. Here is seen the angiomatous tissue representing the beginning stage of the disease.

Fig. 3. High magnification of Fig. 1 at *b*. Shows transition from the angiomatous to the mixed type of tissue.

a. Large blood space formed by rupture of walls of dilated capillaries.

Fig. 4. Shows sclerosed blood vessel in one end of the sections of Preparation 1. For low magnification and relation see Fig. 5.

Fig. 5. Low magnification of thickened blood vessel *a*, shown in Fig. 4.

Fig. 6. Low magnification of one of the sections of Preparation 2. Here the angiomatous areas have entirely disappeared leaving only the richly cellular connective tissue type.

Note artery at *a*, an enlargement of which (from another section) is shown in Fig. 7.

Fig. 7. Shows growth into lumen of artery. See *a*, Fig. 6.

Fig. 8. (Preparation 3). From one of the older lesions of Kaposi's disease, resembling in some areas a fibro-myoma and showing degeneration and myxomatous-like tissue.

Fig. 9. (Preparation 4). Taken from Case 2 of Kaposi's disease, which showed only six small lesions on the face. Section shows transitional stages of the lesions and in some areas resembles angiosarcoma (see Fig. 11).

Fig. 10. Case 1. Kaposi's sarcoma.

Fig. 11. Enlargement of Fig. 9 at *a*. At the extreme left, *a*, the cells resemble those of a sarcoma and seem to be continuous with the endothelium of the large dilated capillary. Towards the right, *b*, the cells are more of a connective tissue type.

Discussion.

Dr. Wallhauser said that about six years ago he reported a case (*Jour. A.M.A.*, No. 13, 1909) which corresponded in microscopical findings with Dr. Gilchrist's case. In this case apparent cure resulted, following enucleation of the growths and application of a strong solution of bichloride of mercury. After three years, a recurrence developed on the thigh, but before treatment could again be applied, the patient died. The cause of death was interstitial nephritis; post-mortem examination failed to show any metastases from the growth.

Dr. Engman said that the names describing the morphology of tumors had proved to be a great handicap in the study of malignant growths. From the investigation and study of this group in animals, we must broaden our views greatly. It was accepted by investigators that in all of this group of tumors there was possibly some chemical stimulant or some micoörganism which stimulates certain tissues; therefore, there will follow various morphological appearances. So, when it came to the causes of the so-called sarcomas at the present time, we were very much at sea. Possibly we could go on with these terms until we knew better. Rous' so-called chicken sarcoma was generally believed to be an infective granuloma; the sarcomas which were symptomatically cured with the X-ray, etc., must be considered differently from the groups that were

not affected by such treatment. Dr. Mook and himself had just treated two cases, one of them recurrent from the testicle, and the other one in a woman, which was diagnosed as lympho-sarcoma. Under three massive doses of X-rays, the sarcoma on the neck of the woman had almost entirely disappeared. In the other, several massive doses were given and the lesion had entirely disappeared. At the present time we were not justified in drawing any conclusions in relation to any of these groups of sarcoma, as to their morphology.

Dr. Schamberg said that two years ago a patient had been referred to him with sarcoma of the Kaposi type, involving the sole of the foot. There were about a dozen nodular lesions present. A surgeon had desired to remove the leg. Dr. Schamberg counselled that the individual lesions be excised and the foot subjected to X-ray treatment. This was done and the man was free of lesions and well at the end of two years.

Dr. Ravogli said that he had had occasion to see two cases of sarcoma of the hæmorrhagic type (Kaposi), where no papular eruption was present, nothing but a thick, brownish, hæmorrhagic discoloration. One of the cases had been seen by Dr. Lustgarten, who also agreed that it was sarcoma of Kaposi's type. Another type of sarcoma, which he described as carcinoma, in a lady about fifty years old, was distributed all over the body, in the form of small black points. She had been operated upon and large pieces of skin removed, without benefit, and she died a few months after. It seemed to him that these cases of sarcoma traveled through the blood vessels and also through the interstices of the tissues. He had seen one case beginning as a nævus on the chest; it grew in the form of small black papules, forming large patches. He believed that these cases of sarcoma grew much more as a consequence of spreading through the interstices of the tissues; while, in the other class,—like the case where the small black spots had spread all over the face and body,—there was probably a dissemination through the blood vessels, causing much more rapid infection, and the death of the patient.

PSORIASIS AS A SEQUEL TO ACUTE INFLAMMATIONS OF THE TONSILS: A CLINICAL NOTE.

By James MacFarlane Winfield, M.D., Brooklyn.

The tonsils are suspected of being the portals through which many diseases gain entrance into the general system, but as far as I have been able to learn, there are no reported instances where the development of psoriasis seemed to be in any way dependent upon tonsillar inflammation or disease.

The first time acute psoriasis was observed following immediately after an operation on the tonsils, I dismissed the occurrence as a mere coincidence; but when six cases had accumulated, where acute psoriasis developed after inflammations of the tonsils, it was thought that a brief report might be of interest to the profession, especially to any one who is trying to solve the ætiology of this intractable dermatosis.

Case Reports.

Case 1 was a boy aged 5½ years; from the age of three he had been subject to tonsillitis. From these repeated inflammations the tonsils had become enlarged, and he began to have difficulty in breathing through his nose when lying down. There was also a thin, watery nasal discharge; otherwise he was a well-developed and healthy child.

The family physician advised removing the tonsils and adenoids, which was accordingly done.

Three days after the operation the patient's temperature suddenly rose to 104° F. and the throat became inflamed and swollen; twenty-four hours later, the temperature dropped to 101° F., remained at this point for a week, and then became normal. Simultaneous with the sudden rise of temperature, a fine papular rash appeared over the trunk, thighs and arms. I was asked to see the patient ten days later.

The eruption consisted of small, split pea-sized patches distributed over the trunk, thighs and arms. The attending physician said that the original papular eruption had rapidly become tipped with scales and that many of the original papules had disappeared or had coalesced. The eruption was most marked over the back. The base of each patch was inflammatory, and upon removing the scales, minute bleeding points were observed.

Although the eruption resembled acute psoriasis of the guttate type, in view of the throat symptoms and the absence of any previous skin disease, a positive diagnosis was withheld until more time could be had for further observation.

After two months there was no doubt about the disease being psoriasis; the patient eventually was cured of that attack but has had two recurrences.

Case 2. Female, aged 23 years. She was a first-year student in the training school for nurses. She was a large, well-developed girl, born and brought up in the country, used to good, wholesome food and apt to over-indulgence in eating.

The patient had never had rheumatism, but from early childhood has been subject to tonsillitis. Except for some slight acne at puberty, she has never had any skin disease.

While very tired and run down from a month of hard work in the hospital, she developed what was, both clinically and bacteriologically, follicular tonsillitis. This ran a typical course, excepting that the temperature was rather high, and did not become normal as soon as usual.

Ten days after the beginning of the tonsillitis, she noticed a number of itchy, scaly spots on the arms, back and abdomen. The spots rapidly increased in size and number.

The diagnosis of acute psoriasis was made, the correctness of which was proved by the subsequent behavior of the eruption. Eventually the patient was obliged to discontinue her profession, on account of the frequent recurrences; the slightest over-indulgence in eating, or getting over-tired would bring on a fresh attack or aggravate an existing one.

Case 3. Girl, aged eleven years; she had been subject to follicular tonsillitis for several years.

The tonsillar attack, previous to the advent of the skin eruption, had been unusually severe, accompanied by high temperature and cervical adenopathy. There was no history of any previous skin disease, either in the patient or family.

Three weeks after the last attack of tonsillitis, an eruption developed all over the body; at first it consisted of fine, pinhead-sized, red papules, which rapidly enlarged and became scaly. When I saw the patient, three weeks later, the eruption was more pronounced over the back and scalp, although there were a few patches over the abdomen, arms and thighs. The patches were frankly psoriatic in appearance, and varied from a pinhead to a twenty-five cent piece in size.

The cutaneous eruption ran the typical course of psoriasis, the patient finally recovering from the attack.

Case 4. Boy, aged 8 years. He was taken ill with a severe membranous sore throat; the illness began with a chill, followed by a high temperature. Bacteriological examination showed the disease to be streptococcic angina. Along with other remedies, the patient received subcutaneous injections of autogenous vaccine. At the beginning of convalescence, the attending physician noticed a papulo-squamous eruption about the sites of the injections. Little, if any, attention was paid to the eruption until it spread over the entire trunk and arms.

The character of the eruption remained the same, excepting that the lesions gradually grew larger and showed a tendency toward grouping over the extensor surfaces. There was no history of any previous cutaneous disease.

A diagnosis of psoriasis was made, the correctness of which was affirmed by further observation.

Case 5. This was a trained nurse, aged 26 years. She had for many years been subject to tonsillitis, and although her tonsils were enlarged and fibrous, she would not have them removed.

The attack of tonsillitis previous to the cutaneous eruption was unusually severe, and came on while she was run down and tired from three months of hard professional work.

The eruption, consisting of a few scaly, seborrhœa-like patches distributed over the back, elbows and thighs, appeared about a week after her recovery from the tonsillitis.

The patches were about the size of a dime, inflammatory and abundantly covered with greasy scales.

This patient has been under observation for over a year, and during all that time she has never been entirely free from lesions that are now typically psoriatic. She is positive that she has never had any skin disease that in any way resembles either psoriasis or seborrhœa.

Case 6 was seen during the summer of 1915. She was a healthy girl of 19 years. In June she was taken ill with an attack of follicular tonsillitis, her first attack.

While her throat was still very sore, and her temperature was 102° F., a papulo-squamous and intensely pruritic eruption appeared over the trunk, thighs and arms.

I was asked to see her while her throat was still inflamed; the eruption was thicker over the back, arms and thighs; the size of the lesions varied from a split pea to a dime.

Under treatment, many of the smaller ones disappeared while others gradually enlarged, some of them clearing in the centre, presenting a typical psoriatic appearance.

After a month of intensive treatment and autogenous serum injections, all except six of the lesions had disappeared.

Two months later there was a recurrence of the skin disease, which was frankly psoriatic.

These six cases all followed some inflammation of the tonsils. In one case the skin disease followed enucleation of the tonsils. Examination of smears taken from the throat failed to show any reason for the high temperature. In another case the skin disease was the sequel of a streptococcic sore throat. Psoriasis followed an attack of follicular tonsillitis in four cases.

No ætiological light was thrown upon the cause of the skin disease by bacteriological examinations of the follicular contents and other secretions from the throat. If any special organism had been repeatedly found in all of the cases, one might think that it had gained entrance into the system through the tonsil, and thus produced the dermatosis; but as no such organism was found it is fair to assume that the tonsillar inflammation and the high temperature disturbed the metabolic balance sufficiently to produce the skin disease, in one predisposed.

MONILETHRIX.*

A Clinical and Histological Study, with a Report of Six Cases and a Review of the Literature.

By George M. MacKee, M.D., New York, and I. Rosen, M.D., New York.

(From the Department of Dermatology, College of Physicians and Surgeons, Columbia University.)

History.

Walter G. Smith, in 1879, presented a patient before a meeting of the British Medical Association, held in Cork, Ireland, who exhibited a peculiar nodose affection of the hair. In the early part of 1880 Smith published a description of the case under the title, "A Rare Nodose Condition of the Hair." In this report he included an identically similar case that was under the observation of his colleague, Liveing. To Smith, we must give credit for reporting the first example of this condition that was ever recognized. The literature previous to 1879 contains no reference to a disease of the hair that can be identified as monilethrix. Later, in 1879, Luce, of Paris, reported what is now known to have been a case of monilethrix. But, although he was aware of Smith's case, he did not classify it as the same affection, but employed the title, "Researches on a Case of Curious Alopecia."

Since 1880 there have been 39 articles written on this subject, which embrace about 113 cases of the disease, not including the present report.

For a few years there was considerable confusion regarding the proper nomenclature. The disease was given different names by various observers, and it was not infrequently confused with other affections of the hair, such as Wilson's intermittent grayness of the hair, trichorrhexis nodosa, lepothrix, piedra, etc. Lesser called the condition "ringed hair," a term that was also applied to intermittent grayness; McCall Anderson, hereditary trichorrhexis nodosa. Virchow suggested aplasia pilorum intermittens, to which Behrend added moniliformis

* Read before the 40th Annual Meeting of the American Dermatological Association, Washington, D. C., May 13 to 15, 1916.

(from *monile*, neckband). Later, Crocker employed the word monilethrix, and this is the title that is universally employed to-day.

With six exceptions, all the reported cases have been observed in England, Germany, Hungary, France, Italy and Brazil. The six exceptions are a doutbful case seen by Bulkley in New York in 1881, a probable case reported by Morrow in 1899, two positive cases encountered by Schuyler Clark in New York in 1915, and the well-known cases published by Gilchrist and Ruggles, in 1898 and 1900 respectively.

A Synopsis of the Disease.

Monilethrix is an affection of the hair that is noticed either at birth or develops within a few weeks or months subsequent to birth. There are a few exceptions to this, however. In Gilchrist's case the affection was said to have begun at the age of 17, and in Smith's case at the age of 15. The child may be born bald or it may possess normal hair at birth. If the latter, the infantile hair falls out in a very short time. In any event, sooner or later after birth, usually a few weeks or months, the adult type of hair begins to grow. This hair, either over the entire scalp, or only in areas, becomes brittle, lustreless, and breaks off before it has attained a very long growth. A hyperkeratosis of the follicles (keratosis pilaris) develops in almost all cases, either before or shortly after the affection is noticed in the hair.

As the children grow older the affection becomes more noticeable, especially in girls, on account of the shortness and sparseness of the hair. The disease may involve the entire scalp or only portions thereof; it may also affect the eyebrows and eyelashes, the axillæ, hair of the external genitals and even the trunk and extremities (Gilchrist, Ruggles).

When the entire scalp is involved the individual is either totally bald or, what is more common, short (¼ to 1 inch), twisted, curved, broken, lustreless hairs are sparsely scattered over the scalp, with here and there an apparently normal hair, several inches in length. In such cases and in individuals who have only patches of the disease, the normal hair does not, as a rule, attain a luxuriant growth in length, quality or quantity.

When the affection occurs in patches on the scalp, the favorite sites are the frontal and temporal regions, the vertex and the nape of the neck.

Associated with, or as part of the disease, there is almost always a pronounced keratosis pilaris which may involve the entire scalp and the extremities, or only the areas where abnormal hairs are noted.

The most notable feature of the disease, however, is the peculiar condition of the affected hairs. Not only are they short, brittle, lustreless, twisted, curved or kinked, but on close inspection, they are seen to be beaded at regular intervals. If a hair is viewed by transmitted light, the beads or nodes will appear dark and the constrictions a much lighter shade, almost if not quite white. This phenomenon is due to a large air-content in the spindles. If, on the other hand, the hair is viewed by reflected light, the nodes will appear light and the internodes dark.

For the most part the nodes occur at absolutely regular intervals along the root and shaft of the hair, beginning at the bulb and extending to the distal end, and they are all of the same size and shape. Many hairs, however, depict varying degrees of irregularity in the distribution of the nodes. Also, the constrictions may vary from a slight to an extreme degree of attenuation, so that the nodes may seem to vary considerably in diameter. Some hairs may be uniformly atrophic or they may exhibit an occasional more or less marked node or constriction. Such hairs are usually poorly supplied with pigment and, therefore, are lighter in color than the normal or the moniliform hairs.

It may be seen, then, that while the typical hair of monilethrix is regularly beaded, yet there may be various transitional types.

The so-called nodes have the diameter of the normal hair of the individual; they also possess a normal cuticle, cortex and in most instances, a normal medulla and pigment content. In other words, the thick part of the hair, or node, is normal hair. On the other hand, the constriction is composed of thickened cuticle, reduced cortex and practically never contains any medullary substance. It will be manifest, therefore, that the constriction is the atrophic or pathological portion of the hair, and to speak of nodes in connection with this disease, while convenient, is incorrect.

In addition to the symptoms and features already enumerated, there may be more or less pityriasis of the scalp, and if the affection has existed for several years, a generalized atrophy may manifest itself. The general health of the individual is usually good and the affection (including both the moniliform hairs and the keratosis pilaris) is not associated with other congenital anomalies.

There are several instances of but a single example of this affection occurring in one family. On the other hand, there is, in many cases, an hereditary influence; a distinct family history of the disease. In one report (Sabouraud) as many as 17 individuals in 5 generations of the same family were affected. Monilethrix is, therefore, very decidedly a familial disease.

The cause of the disease is not known. It affects males and females, blondes and brunettes (brunettes mostly), and people residing in various parts of the world. It has occurred after attacks of influenza and subsequent to severe emotional excitement. The bacteriological findings are negative. The pathology of the disease does not throw much light upon the causative factors. The affection consists of an intermittent arrest of function in the hair-producing apparatus, and the defect is thought to be in the nerve centres that control this function. There is no indication that either syphilis or tuberculosis enters into the ætiology of the disease. The tropho-neurotic theory is generally accepted.

There should be no difficulty in differentiating monilethrix from trichorrhexis nodosa, intermittent grayness, etc. This subject will be considered in detail in another section of the article.

The pathology of the affection is not complicated. The hair follicles are dilated and tortuous. There is usually a marked increase in keratinization at the upper end of the follicle, with the formation of horny plugs. In passing through the keratinized orifices of the follicles the hair is often obliged to pursue a serpentine course, and may form a coiled mass. The excessive hyperkeratosis, through pressure, may cause a thinning of the epithelial coat of the follicle. The connective tissue sheath of the follicle, with the exception of slight signs of inflammation, is usually normal. The outer border of the external root sheath may or may not present a wavy line. The sheath itself is always well developed and there is little if any proliferation of epithelial cells. The inner margin is usually wavy, the undulations corresponding to the nodes and internodes of the hair. The inner root sheath is, in most cases, thickened at the constrictions and compressed or normal at the nodes. Huxley's and Henle's layers are well differentiated at the hair bulb but they are likely to lose their identity a very short distance from the bulb so that the inner sheath forms a homogeneous band. No important alterations have been noted in the cuticle, the matrices, the bulb or the papilla. There are usually signs of a mild low-grade inflammation in the upper corium, manifested by a slight dilatation of the vessels and a moderate infiltration of small round cells and in one case (Low), mast cells. The sebaceous glands are undeveloped and are not numerous. The sweat glands, subcutaneous tissue and collagen are normal. The elastic tissue (Low, Bering, MacKee and Rosen) is not well developed. The epidermis is likely to be atrophic between the follicles and acanthotic in their immediate vicinity, with a very prominent granular layer.

Case Reports.

Case 1. J. W.; married; male; 32 years of age; born in Russia. The patient's mother, brother and the patient's four children (2 brothers and 2 sisters) were living. One of the girls and the patient's brother had monilethrix, but all other members of the family were unaffected.

Past History. The patient at birth was completely bald and when the hair grew, at about the third month, it was very sparse. He never developed sufficient hair to cover the scalp and it had never been necessary to trim the hair.

Status Præsens. The patient was normal, both physically and mentally. The Wassermann and von Pirquet tests were negative.

The scalp was slightly atrohpic and very sparsely covered with hair, of which there were three types. There were black, wiry hairs which were two or three inches long and which appeared normal on close inspection. Then there were very stiff black hairs, normal in appearance, which never attained a length of more than about one inch. Finally, there were very short hairs, ranging from ¼ to ½ inch in length, which were curved, sharply bent, lustreless and brittle. For the most part they were black in color, although some were of a grayish-black. The black hairs of this variety did not appear as dark as the normal hairs on account of the lack of lustre. They broke off very easily. These hairs were all beaded, most of them regularly, some irregularly. Many of the apparently normal hairs were also moniliform in character when examined under the microscope. In addition, there were numerous uniformly atrophic hairs containing comparatively little pigment.

There was a keratosis pilaris of the entire scalp, the nape of the neck and the bearded portions of the face and neck. There were no moniliform hairs on any part of the body excepting the scalp. The microscopical characteristics of the hair will be described under the section on pathology (Fig. 1).

Case 2. S. W.; unmarried; male; 30 years of age; born in Russia. The patient was the brother of J. W. (Case 1). The description and history of J. W., applies in every way to S. W., excepting that in the latter there was no keratosis pilaris of the bearded parts of the face and neck.

Case 3. L. W.; female; 8 years of age; born in New York City. She was the daughter of J. W. (Case 1).

Past History. The child, like its father, was devoid of hair at birth. The hair never grew well and the father soon recognized the fact that his daughter suffered from the same congenital anomaly with which he was afflicted. When the patient was four years of age her father consulted Dr. Goldenberg at the Mt. Sinai Clinic, and we are indebted to Dr. Goldenberg for the privilege of studying and recording these cases.

Status Præsens. The child was normal, both physically and mentally. The scalp was sparsely covered with short, wiry, black hairs, none of which was over one inch in length. Interspersed among these hairs, especially over the parietal and occipital regions, were numerous very short, grayish-black, lustreless, crooked, brittle hairs. It was the latter hairs that presented the spindles. There was a keratosis pilaris of the parietal and occipital regions. The eyebrows were thin, but there were no beaded hairs in these regions. The eyelashes were normal. There was some atrophy of the scalp (Figs. 2 and 3).

Case 4. Helen B.; 12 years of age; born in the United States of German parentage; one of four children; mother died of tuberculosis. No other case of monilethrix in this family. The disease was present at birth.

STATUS PRÆSENS. The child was normal physically, but a little undeveloped mentally, probably because she had not attended school regularly. Both the Wassermann and von Pirquet tests were negative. The patient's hair was fairly thick and for the most part appeared normal, with the exception that it did not attain a length of more than from two to four inches. The color was a dark brown. At the vertex and occiput, the nape of the neck and to a slight extent on the parietal regions, there were many extremely short, lustreless, brittle, kinky hairs ranging from ⅛ to ½ inch in length, of a grayish-brown color and showing the beaded appearance so characteristic of monilethrix. The scalp over the occiput and the nape of the neck showed a marked keratosis pilaris with some scaliness. The eyebrows were rather scanty but the hairs were not beaded. The rest of the cutaneous surface was normal. As in all the other cases, the scalp was in close contact to the cranium and quite tight (Figs. 4, 5 and 6).

CASE 5. Josephine P., 9 years of age; born in New York City of Italian parentage. Her father and mother were living and well. There was only one other child, an infant, who also had monilethrix. The mother stated that there were never any other cases in the family. The patient was bald at birth. In a few months the hair began to grow, but the mother noticed that the growth was very thin and that before a hair attained a length of an inch it would break off.

STATUS PRÆSENS. The girl was normal mentally and physically. There was an extreme degree of alopecia and the scalp was atrophic and not very movable. The long hairs were dark brown in color, ranged from one to three inches in length and were very coarse and wiry. These hairs, for the most part, were not beaded. There were numerous, extremely short, brittle, lustreless hairs, however, that did depict the characteristic nodes. There was a keratosis pilaris of the scalp, especially at the occiput, temporal regions and nape of the neck. The hairs of the eyebrows were scanty and short, but they did not possess any beads. There was a keratosis pilaris of the extensor aspects of the forearms and legs. The Wassermann reaction was negative (Fig. 7).

CASE 6. Mary P.; 10 months old; sister of Josephine P. (CASE 5); born in New York City.

The infant was bald at birth. A few weeks after birth the mother noticed a generalized keratosis pilaris of the scalp. A little later hair began to grow slowly on the top of the scalp.

STATUS PRÆSENS. The baby was robust and normally developed. The most marked features were the almost total absence of hair and the very conspicuous keratosis pilaris which was distributed over the entire scalp. There were scattered, coarse hairs, about ½ inch in length, over the top of the head. Most of the follicles were keratotic and contained lanugo-like hairs, many of which were regularly beaded. There was no atrophy. The eyebrows were totally absent (Fig. 8).

HISTOPATHOLOGY.

A small piece of tissue was obtained from CASE 4, for the purpose of histological study. It was removed by means of the cutaneous punch, after the area had been anæsthetized with cocaine. The tissue was taken from the nape of the neck and included several hair follicles which

Fig. 9.
Zeiss obj. 8 mm., co. oc. 4. Dilated hair follicle containing atrophic portion of hair. Transverse section.

Fig. 10.
Zeiss obj. 8 mm., co. oc. 4. Transverse section. Follicular horny plug. Thickened granular layer, and acanthosis in neighborhood of follicle.

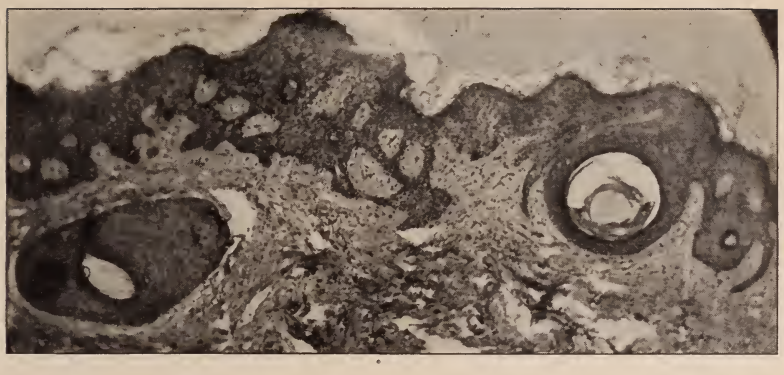

Fig. 11.
Zeiss obj. 16 mm., co. oc. 4. Acanthosis in neighborhood of follicles. Dilated hair follicles.

contained horny plugs and short, broken-off hairs. The tissue was fixed in alcohol, imbedded in paraffin, cut both longitudinally and transversely (in relation to the hair follicles) and stained with hæmotoxylin-eosin, orange-G-hæmotoxylin, van Giesen's stain and Weigert's elastic tissue stain. Serial sections were prepared.

The epidermis as a whole was thinned, but in the neighborhood of the follicles it was markedly thickened and showed an anastomosing of the rete pegs. Where the epidermis was thin the horny layer was normal; the granular layer here consisted of a single layer of cells. Some of these cells depicted swollen nuclei and densely packed keratohyaline granules, which obscured the outline of the cell body. Similar cells were noted in which there was a clear space between the swollen nucleus and the keratohyaline granules.

In the acanthotic portions of the epidermis, the granular layer was from 4 to 6 layers deep. The cells were irregular in shape, some being polyhedral, others spindle-shaped. The granules, too, were irregular in size—in places there were masses of keratohyaline.

The stratum lucidum was nowhere in evidence.

The rete, in the thickened portions, showed a slight intercellular œdema. The cells of the lower portion of the rete were small and crowded. No mitotic figures were detected. The basal layer was somewhat disorganized.

In the thin parts of the epidermis the rete was reduced to 3 or 4 layers of cells. Here, too, the basal layer was somewhat disorganized.

In the true skin there was a dilatation of the superficial blood vessels. They were surrounded by a moderate infiltration of small

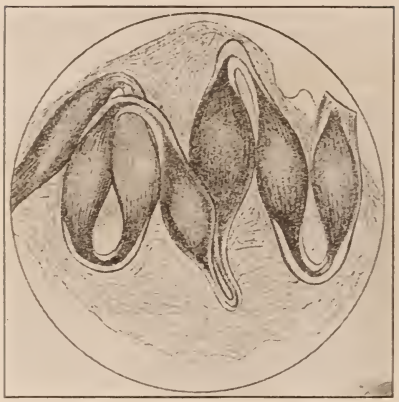

Fig. 12.
After Archembault. Shows a nodose hair of monilethrix coiled up in a follicular orifice and surrounded by horny tissue.

lymphocytes. There was no marked change in the connective tissue. Elastic tissue for the most part was abundant and well developed. It was diminished and fragmented in places.

The sebaceous glands were small and poorly developed. In fact, most of the follicles had no sebaceous glands at all. The arrectores muscles were normal. The coil glands appeared to be rather small for this part of the body, but they were numerous. The adipose tissue was normal.

The most striking features in the sections were in connection with the hair follicles. They were markedly dilated, the dilatation being especially pronounced at the mouth and diminishing as it extended downward, to disappear at the lower third of the follicle. There was a marked increase and irregularity of keratinization in the upper part of the follicle. This produced large, hyperkeratotic masses which encroached upon the wall of the follicle and reduced this structure to one or two layers of flattened or compressed epithelial cells. On account of the enormous amount of horny tissue occluding the follicle, the hair was obliged to pursue a tortuous course, which gave rise to a picture, on vertical section, of a transverse instead of a parallel disposition of the hair. On cross section the dilated follicles often had the appearance of horn retention cysts. A decided twisting or axial rotation of the hair in the follicle was also noted. The hyperkeratosis extended down the follicle to the junction of the middle and lower third.

The follicles extended to the subcutaneous tissue and were decidedly

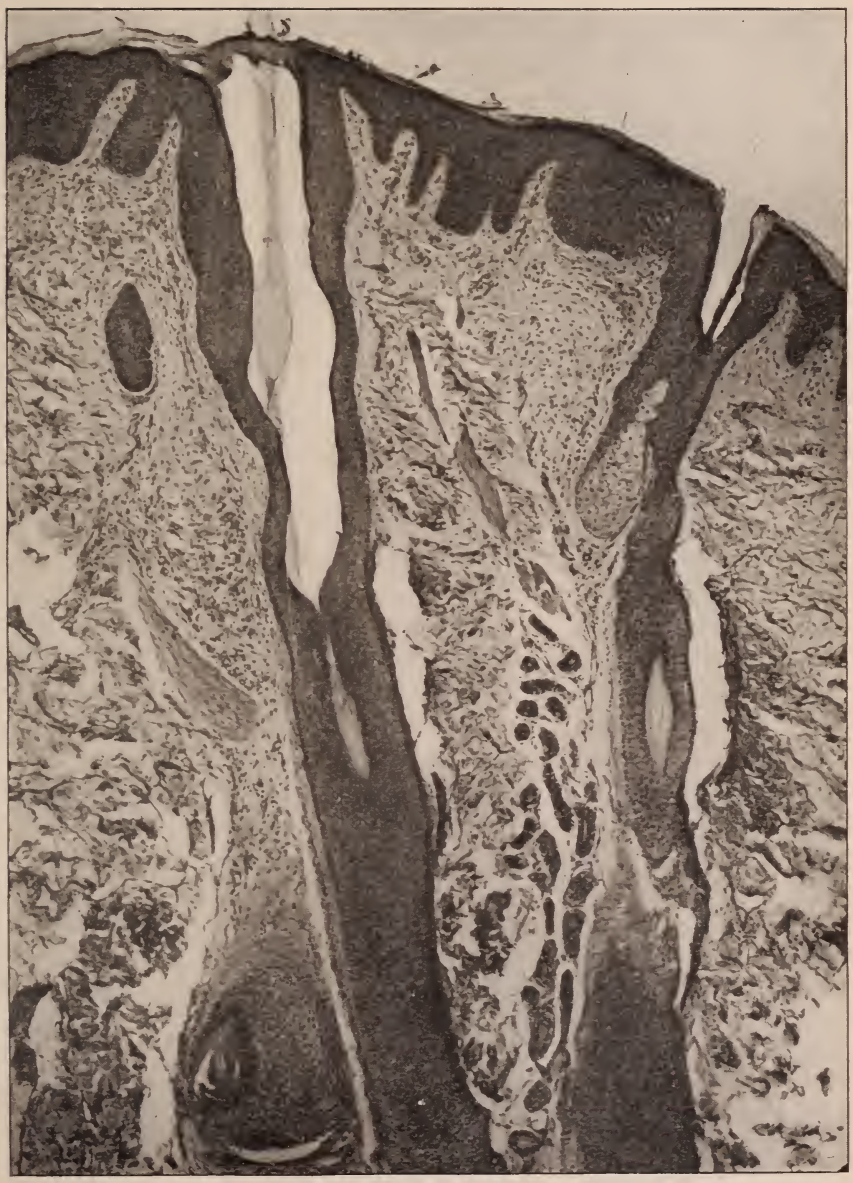

Fig. 13.
Zeiss-Planar obj. 20 mm. Acanthosis. Tortuous follicles. Beaded hair in follicle. Underdeveloped sebaceous gland.

tortuous. This tortuosity was noted both in the keratinized and epithelial portions of the follicle. The lower end of many of the follicles was almost at right angles with the vertical portion.

The atrophic areas were noted in the follicular portion of the hair and were seen immediately above the hair bulb. As many as six nodes were counted in some of the tortuous follicles.

The minute histology of the follicle was studied in both transverse and vertical sections, but no important alteration was noticed.

The connective tissue coat of the follicle was not greatly altered. In some areas it appeared broadened. There was here and there a slight or moderate infiltration of lymphocytes, and connective tissue nuclei were rather plentiful.

Both the external and internal root sheaths were well developed. The outer border of the external sheath was irregular, the irregularity being a part of the general tortuosity of the follicle. The inner border of the external sheath was also tortuous, but this tortuosity corresponded to the thick and thin portions of the hair. Although, in places, the external sheath seemed to be somewhat thickened, due to a proliferation of epithelial cells, yet, for the most part, there did not seem to be any abnormal proliferation. The thickness of the sheath opposite the constrictions in the hair was probably due to lack of pressure, while opposite the thick portions of the hair and in the neighborhood of the increased keratinization, the sheath was compressed in accordance with the amount of pressure exerted.

The inner root sheath was normal at and near the hair bulb. The two layers (Huxley and Henle) were well differentiated and the cells appeared normal under high power. As this sheath ascended in the follicle the nuclei and keratohyaline granules disappeared from Huxley's layer rather quickly so that, at a very short distance from the hair bulb, the inner sheath became a homogeneous mass. At every internode there was a decided increase in the width of the inner sheath as compared with that portion of the sheath lying opposite to the nodes. At the internodes there was a space between the inner sheath and the hair, usually on one side of the hair only, but occasionally on both sides. At the nodes the hair and the follicle were usually in contact.

We found one follicle (vertical section) in which the papilla, hair bulb and lower end of the follicle could be followed through a number of serial sections. The hair bulb was well-formed, but a constriction occurred in the hair immediately above the bulb, and this in turn was followed by a normal portion of hair (node). The internodal portion was fractured both transversely and longitudinally. This fracturing

possibly occurred during the preparation of the sections. Here, the inner sheath and the cuticle of the follicle were increased in width, apparently due to absence of compression, as the individual cells seemed to be swollen rather than increased numerically. On one side of the hair, at this internode, the two cuticles were interwoven, but on the other side the cuticle of the hair had been torn from the hair and remained connected to the cuticle of the follicle, leaving a space between the hair and the inner follicular wall. The papilla seemed a little small for such a large follicle, but this appearance might be explained by the fact that none of the sections showed the centre of the papilla. For this reason, also, it was impossible to study the vascular supply of the papilla. However, the vessels in the fatty tissue in the neighborhood of the hair papilla were perhaps somewhat dilated and they contained red cells and serum.

Examination of Hairs.

A large number of hairs were examined. When viewed by transmitted light, either with the lens or with the unaided eye, the nodes appeared black and the internodes white, but when reflected light was employed the nodes were light and the internodes dark. As many as twenty nodes were counted in one hair which was a little over one-half inch in length.

For the most part the nodes were distributed at regular intervals along the course of the hair, and each node and internode was of the same width. This arrangement, however, was not constant. Some hairs were rather thin throughout, without areas of constriction. Such hairs contained no medulla, were rather poorly supplied with pigment and possessed a relatively thick cuticle. Similar hairs were found showing here and there more or less attenuation. Some of the heavier hairs showed a decided irregularity in the distribution of the nodes and internodes and a marked variation in the degree of attenuation. In a single hair, for instance, one found large and small nodes, nodes that began and ended very gradually or rather suddenly, and internodal portions that depicted only a slight degree of thinning or the most extreme attenuation.

In some of the heavier hairs the medulla was entirely absent, in others only a trace was seen in the nodes. Sometimes the medulla was a deep brown or black—at other times it was a very pale brown. For the most part, however, the nodes, in or near the root of the hair, contained a well-developed medulla. The internodal portions, as a rule, contained

Fig. 14. Fig. 15. Fig. 16. Fig. 17.

Fig. 14. Monilethrix hair showing atrophy at hair bulb. The nodes in this hair are not at regular distances. Removed by electrolysis.

Fig. 15. Normal hair removed by electrolysis.

Fig. 16. Monilethrix hair, showing regular size and distribution of nodes. Medulla in nodes. Absence of medulla in internodes.

Fig. 17. Monilethrix hair. Total absence of medulla. Nodes are irregular in size and distribution. Slight fracture in centre of hair.

FIG. 18.
Monilethrix hair. Atrophic in its entirety. Slight nodular formation. Irregularly distributed medulla. Incomplete, transverse fracture.

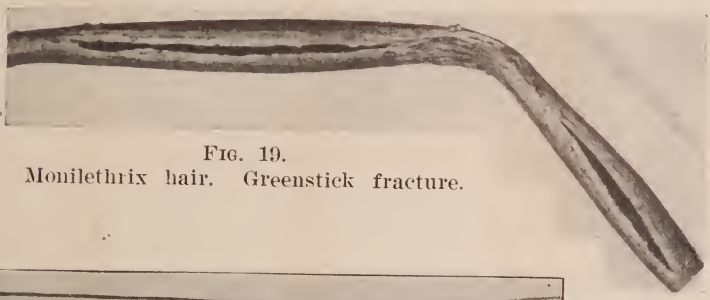

FIG. 19.
Monilethrix hair. Greenstick fracture.



Monilethrix hair. Atrophic hair without medulla.
FIG. 20.

FIG. 22.
Monilethrix hair. Transverse fracture suggesting the paintbrush type.

FIG. 21.
Monilethrix hair. Universally atrophic. Scanty and irregular medulla. Longitudinal fracture.

Fig. 23.
Monilethrix hair. Regular nodes. Three fractures, all at internodes and of different types. The one in the centre is frayed and suggests the brush-like fracture seen in trichorrhexis nodosa.

no medullary substance; a trace of this substance was detected occasionally.

The cuticle was very thin (normal) at the nodes and decidedly thick at the internodes. The cortex was normal at the nodes and markedly diminished at the internodes, so that the atrophy was at the expense of the cortex. In other words, the so-called "node" is normal hair, while the "internode" is undeveloped hair and, therefore, is the pathological portion.

A few hairs were slightly macerated by means of a weak solution of caustic potash. In such hairs spaces could be detected in the cortex of the nodes and these were considered to be air spaces. These spaces were numerous in the nodes and were seen only occasionally in the internodes.

In the thin hairs and in some of the coarse hairs there was a paucity of pigment, but most of the hairs were well supplied with this substance, both in the nodal and internodal portions. In fact, in most of the hairs, the pigment was smaller in amount in the internodes, only because there was a diminished amount of cortical substance. Relatively the pigment appeared to be about the same in both the nodes and the internodes.

Many of the hairs exhibited fractures, which always occurred at an internode. They were of all varieties. At times there was simply a fissure through the cuticle. In other hairs the cuticle was fractured and there was a little bulging or displacement of the fragments. Occasionally, in this type of fracture, there was a separation of the fibres of the

Plate XXXIX.—To Illustrate Article on Monilethrix, by George M. MacKee, M.D., and I. Rosen, M.D.

Fig. 2. Case 3.
Short, scanty, coarse hair on scalp. Atrophy of scalp. Paucity of hair on eyebrows.

Fig. 1. Case 1.
Scanty, coarse hair on scalp. Keratosis pilaris of bearded region.

Plate XL.—To Illustrate Article on Monilethrix, by George M. MacKee, M.D., and I. Rosen, M.D.

Fig. 4. Case 4.
Short hair over entire scalp. Alopecia on temporal regions—also keratosis pilaris.

Fig. 3. Case 3.
Thin, coarse, short hair on scalp. Keratosis pilaris of vertex and neck.

Plate XLI.—To Illustrate Article on Monilethrix, by George M. MacKee, M.D., and I. Rosen, M.D.

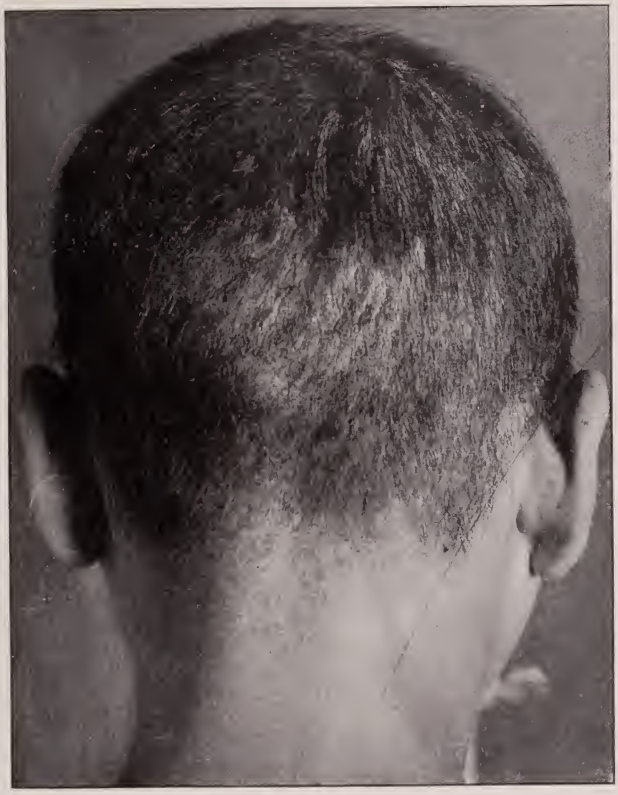

Fig. 5. Case 4.
Alopecia over vertex. Short hair all over scalp.
Keratosis pilaris of vertex and neck.

Fig. 6. Case 4.
Keratosis pilaris, extensor surface of forearm.

Plate XLII.—To Illustrate Article on Monilethrix, by George M. MacKee, M.D., and I. Rosen, M.D.

Fig. 8. Case 6.
Almost total baldness. Keratosis pilaris of entire scalp.

Fig. 7. Case 5.
Alopecia of vertex. Keratosis pilaris of neck.
Poor head of hair.

Plate XLIII.—To Illustrate Article on Monilethrix, by George M. MacKee, M.D., and I. Rosen, M.D.

Fig. 24.

Zeiss obj. 8 mm., co. oc. 4. Internode just above bulb; node higher up. Fracture at internode. Inner sheath and cuticle of follicle widened. Cuticle of hair torn away with resulting space between hair and follicular wall.

Plate XLIV.—To Illustrate Article on Monilethrix, by George M. MacKee, M.D., and I. Rosen, M.D.

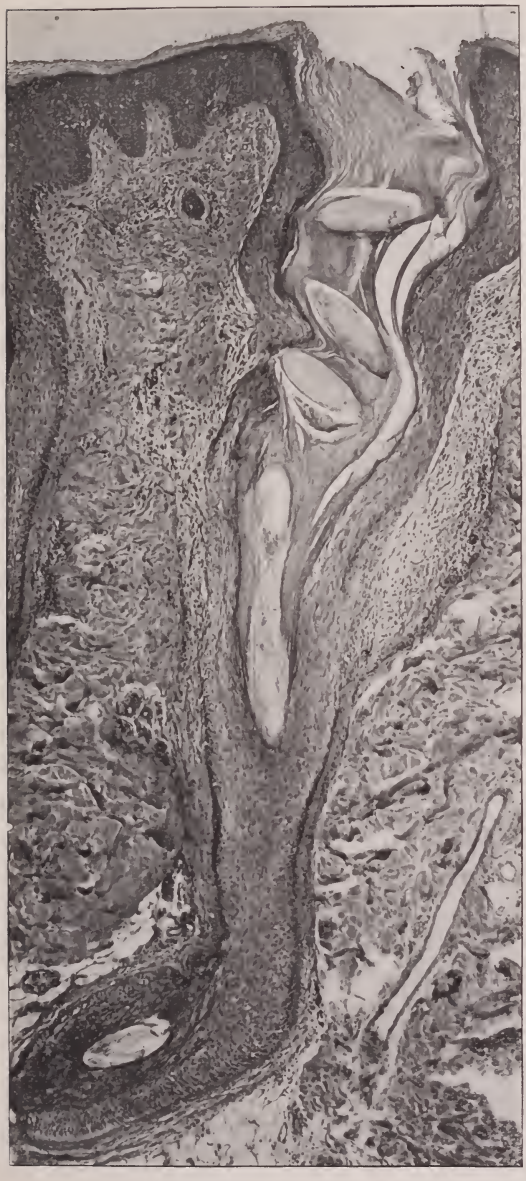

Fig. 25.
Zeiss-Planar obj. 20 mm. Follicular keratosis. Nodes and internodes. Tortuous follicle; serpentine course of hair.

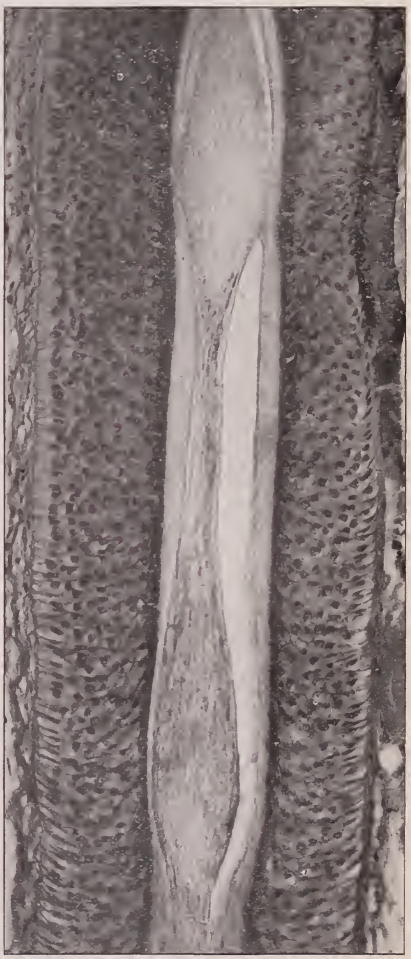

Fig. 26.
Zeiss-Planar obj. 20 mm. Homogeneous Huxley layer low down in follicle. Empty space on one side of hair, opposite both a node and one internode. Thickened inner sheath between nodes.

Plate XLV.—To Illustrate Article on Monilethrix, by George M. MacKee, M.D., and I. Rosen, M.D.

Fig 27.
Zeiss- Planar obj. 20 mm. Follicular keratosis. Intrafollicular nodes. Tortuous follicles. Serpentine course of hair.

Plate XLVI.—To Illustrate Article on Monilethrix, by George M. MacKee, M.D., and I. Rosen, M.D.

Fig. 28.
Zeiss obj. 8 mm. co. oc. 4. Follicular keratosis. Several nodes placed at different angles denoting serpentine course of hair. Tortuous inner and outer follicular walls.

broken cuticle instead of a clean or smooth break. At times a clean transverse fracture through both the cuticle and cortex was noted. Occasionally, too, oblique and even vertical or longitudinal lines of cleavage were seen. The usual fracture, however, was of an irregular transverse type with considerable fraying of the fragments and more or less separation, giving rise to a brush-like appearance, not so marked but, nevertheless, suggesting the typical fracture of trichorrhexis nodosa.

The hairs fractured so easily that it was impossible to obtain a single example in its entirety by ordinary means—that is, epilation by force. However, one diseased hair was successfully removed in its entirety by means of electrolysis (for which we thank Dr. D. L. Satenstein). This hair, like the one studied in connection with the follicle, showed the first constriction occurring immediately above the hair bulb.

(To be Continued.)

DISCUSSION FOLLOWING PAPERS COMPRISING A SYMPOSIUM ON THE INTERNAL SECRETIONS.*

Dr. C. J. White said that the papers formed a series of extraordinary interest and of the greatest value. The study of the functions performed by the secretions of the internal glands in disease of the skin was a subject of extreme difficulty and complexity, and the fixing of our knowledge to date by Drs. Foerster and McEwen was of great value, while the work of Drs. Kendall and Engman was of fundamental importance. The Association was to be congratulated upon having such a demonstration.

Dr. Johnston said that he had a keen appreciation of the labor involved in the preparation of the papers and would like to add a hint along the lines of the data contained in Dr. Kendall's and Dr. Engman's communications, on the subject of scleroderma. It was curious that all the papers except Dr. Engman's left the topic of scleroderma untouched. Several years ago he had seen a woman whose scleroderma left her during pregnancy. This had suggested to his mind the possibility of influencing scleroderma under ordinary circumstances. It had occurred to him that the pituitary body presided over the development of all mesenchymal tissue, and finally, the subject of pituitary therapy was broached by Dr. Thomas Hastings, of Cornell. Two cases came to the speaker at the same time, one a generalized type on the trunk and limbs, ankles and wrists having been ankylosed; the other, a morphœa, confined to one side of the face, in a young woman. Both were given pituitrin after it had been determined that both had great sugar tolerance, the boy up to 300 gm. Both were given the dessicated pitutiary extract, anterior part. The morphœa had disappeared from the woman's face entirely, except a spot the size of a quarter. In the case of the generalized scleroderma, the disease was not only arrested, but it had entirely disappeared from the arms, trunk and buttocks. It was still present over the thighs and the feet and hands, which were partly falsely ankylosed by the thickening of the superficial tissue. The stiffness had greatly improved. Neither case was yet ready to report upon, but the results were so striking, that it seemed well to report the progress made, in order that others might try the same therapy and report on the results.

* See editor's note, p. 461.

The preparation used, which seemed to be most active was that put up by Burroughs and Wellcome. He had given up to eight tablets a day, two grains each to both patients. The boy was sixteen, and the woman twenty-five, and their body weights were about the same. If this dose was increased, congestive headaches followed. A point in the further development of the therapy was the separation of the active principles of the *pars anterior*. There was no question but that in the administration of internal secretions in cases in which they were indicated, when you reached a point where the condition seemed to cease to improve using the thyroid in addition as an adjuvant, helped. Then, a tonic dose of thyroid was given. Dr. Johnston said that he had used Dr. Kendall's B-thyroid in two cases, but had used as a rule another product, Beebe's nucleo proteid, now on the market (P. D. & Co.) In overdose it will cause tachycardia.

Not only was the hyperglycemia present in scleroderma not influenced by pituitrin, when the condition was improving, but there was no effect on the blood pressure.

Dr. Schwartz reported a recent case of scleroderma treated along the lines suggested by Dr. Johnston, in which a glucose-tolerance test had been made. This case had been shown at the clinical meeting in the afternoon. The patient was a woman, sixty-nine years of age, with scleroderma confined mainly to the right leg, who has a glucose tolerance of 300 grammes. Her blood, taken half an hour, one hour, two and four hours after a glucose feeding of 300 grammes did not show any departure from the normal. What became of the glucose under the conditions, he could not say, but there seemed to be an increased ability to store glucose in these cases and the ingested glucose was absorbed by and deposited in the tissues very rapidly. The case had only recently come under observation, and he had not yet had an opportunity to try the pituitary extract upon it.

Dr. Pusey expressed his great interest in the papers and said that he could recall no summary of the subject in dermatology that was more interesting or more suggestive than that presented by Drs. McEwen and Foerster.

Dr. Sherwell said that he had been greatly interested in the papers read by Drs. Foerster and Engman, and in the discussion following, and by the remarks and experiences of Dr. Johnston. For some months past, at meetings of the New York Dermatological Society, he had to many of the members made statements that he was expecting to reveal shortly his results in the use of a new agent for the treatment of psoriasis (pituitrin extract, in fact) whose employment had been quoted by Dr. Johnston in cases of scleroderma and morphœa. In many cases of psoriasis, particularly in children and young adults, he had used this remedy with results that often had surprised and astonished him, showing its apparent good effect after other treatment had failed, either relatively or absolutely. The treatment had been entirely clinical and empirical, —no element of ratiocination except, perhaps, the knowledge that the thyroid powder and extract was occasionally beneficial. He had used it also in other kinds of cases with good effect, notably in one of dermatitis herpetiformis of some years' duration, in a young female child. The relief had been absolute, both objectively and subjectively. He expressed the hope that some of the members of the Association would give it a trial.

Dr. Stelwagon said that doubtless all present had made clinical and experimental use of thyroid extract. He had seen somewhat favorable results from its use in cases of chronic urticaria and in scleroderma; and he had also believed he had seen suprarenal gland extract exceptionally hold vitiligo in check; but the point that interested him most in these papers and their discussion was the evidence of the gradual turning away of members of our specialty from being purely externists. He had received his education in Vienna under

Hebra and Neumann, and was taught that the local condition was alone to be considered; but his own observation since had taught him that in the management of many skin cases the patient himself was often to be investigated as well as his skin disease. He had been largely influenced in this belief by Dr. Duhring, who taught that it was quite frequently the system or the patient that demanded attention as much as, or more, than the local disease which presented.

Dr. Schamberg expressed deep appreciation of the value of the splendid theses that had been presented and said that all present would go home stimulated to observe more closely the various lesions of the skin which were thought to be associated with disturbances of the ductless glands. Only by doing this and by educating ourselves more broadly in general medicine shall we be able to contribute our fund of knowledge to this important subject. In the event of death of patients suffering from diseases associated with disturbed activity of the ductless glands, we should endeavor not only to secure autopsies, but to have them made in a modern and scientific manner, so that the clinical findings before death, and the histological findings after death could be studied together and proper deductions made therefrom. The subject that had been presented was one of transcending importance.

Dr. Zeisler said that he wished to repeat a remark he had made last night even before hearing these papers, to the effect that it had been worth while for him to come to New York to receive new ideas on the importance of the internal glands and of organotherapy. He had spent several hours in conversation with Dr. Frankel, the New York neurologist, a sort of prelude to this discussion, and had received a wonderful inspiration, including some thoughts which had not been expressed at the meeting. He felt that our attitude toward skin diseases would have to be modified considerably. No longer shall we be satisfied with the labelling of dermal conditions with this, that, or some other name, but would have to look behind the curtain and try to find out what was going on there. Not only the thyroid and the pituitary, but the whole system of the ductless glands, as well as the liver and the spleen and intestinal tract would have to be considered. We shall look upon that whole system of secreting organs as an orchestra in which all the different instruments must play in the same tune and with the same rhythm, so that when one got out of tune or rhythm there was disharmony and trouble. We must not try to blame everything on the thyroid, but to keep in mind the interchange of these organs and to individualize in every case of disease, and apply our treatment accordingly. The subject was of such importance and fascination that he felt the Association had never had presented before it a subject of like magnitude.

Dr. C. J. White said that we were only on the threshold of this subject, and were not yet ready to enter and take possession of all the marvels within.

Dr. McEwen said he was much impressed with the value and aptness of Dr. Zeisler's remarks. He believed the study of the correlation of these glands was most important, and warned against the tendency to regard the thyroid as the only important gland of internal secretion; the discussion of the evening, he said, showed very plainly that the modern dermatologist must be a thorough internist as well.

Editor's Note: Two of the papers of this symposium, those by McEwen and Foerster, were published in the January, 1916, issue of The Journal. This discussion was being held until the publication of the papers by Engman and Kendall, which have not yet been received. The symposium was a part of the program of the 39th Annual Meeting of the American Dermatological Association, held in New York in May, 1915. The discussion is now published by request.

SOCIETY TRANSACTIONS.

NEW YORK ACADEMY OF MEDICINE, SECTION ON DERMATOLOGY.

Regular Meeting, Dec. 7, 1915.

CHARLES M. WILLIAMS, M.D., *Chairman.*

EXFOLIATIVE DERMATITIS WITH MULTIPLE LARGE ULCERATIONS. Presented by DR. POLLITZER.

L. K. was a Belgian, forty years of age, and a patient of Dr. Mitchell. The ulcers which he presented began 20 years ago with a few scaling papules on the back, which, in the course of five years, became universal and itched slightly. A year and a half ago, swelling and subsequent ulceration began in the right inguinal region, and in the course of a few months, several more such lesions developed in other places. The lesions were small at first, but had increased in size to a diameter of from four to eight inches. The patient was married and his wife had had seven healthy children, the fifth and sixth pregnancies, however, having resulted in miscarriages. The blood count was normal, the Wassermann test had not been performed, and he had had no internal treatment.

DISCUSSION.

DR. POLLITZER said that the case was not, in his opinion, one of mycosis fungoides because the exfoliation was not of the mycotic type, but of the pityriasis rubra Hebra variety, and did not itch; that its long duration and universality were also against the diagnosis; that the ulcerations were not those of mycosis fungoides for they did not arise, fungate and involute rapidly enough. He said that they began as nodules, necrosed, and spread phagedænically as gummata did, and had the serpiginous outline and foul discharge of gummata. He said that tuberculosis might be a possible diagnostic consideration in view of the erythrodermia, but that this was not likely, and that the probable diagnosis was syphilis and dermatitis exfoliativa. One large lesion over the scapula showed a raised rolled margin and a rather dry surface that strongly suggested epithelioma, and the diagnosis of multiple epithelioma for all the ulcerative lesions must be considered as possible, extraordinary as such a combination would be. The patient had been seen only once but the case would be carefully studied and further report made.

DR. KINGSBURY said that clinically alone, no diagnosis could be made with certainty, but that tuberculosis and cancer could be excluded, and that either mycosis fungoides or syphilis was the likely diagnosis. He said that he had seen this type of exfoliation in mycosis, and that it was not necessarily characteristic of pityriasis rubra.

Dr. Lapowski said that he has seen tuberculosis of the skin with the clinical aspect of gummata, greatly resembling the lesions shown in this case, and that their phagedænism could be accounted for by secondary infection. He said that clinically the lesions were either epitheliomata or tuberculous ulcers; that the red, non-infiltrated margins of certain lesions ruled out syphilis; and that the diagnoses he would suggest in their order of probability were tuberculosis, epithelioma and syphilis.

Dr. MacKee said that he was unwilling to exclude carcinoma since he had seen several cases of multiple epitheliomata resembling this one, and that many of the lesions had rolled margins, and some the mother-of-pearl edges of cancer.

Dr. Williams said that the case suggested mycosis fungoides, because of the scaling and ulcers, but that pseudoleukæmic infiltrations with scaling, in the sense of Arndt, were not to be excluded without study.

ECTHYMA. Presented by Dr. Lapowski.

W. M., aged 15 years, had an eruption on the scalp, forehead, face, chest and back, leaving scars. The family and personal histories were negative. The first eruption had started on the forehead three years ago, and on the back, about six months ago. Other areas had become affected, on and off, since. On the back and shoulders, down to the lumbar region, a mass of superficial ulcerations with granulations springing out from the floors of the lesions, were shown. The lesions were arranged in various shapes and forms—longitudinal, irregular, serpiginous. The primary lesions appeared in the form of pustules larger than hempseeds, superficial, elevated, surrounded by a reddish border and slightly infiltrated. The vesicles contained, from the start, a thin purulent fluid, and either underwent absorption without spreading, leaving scars; or spread with undermined edges, and a red advancing border. The central portion was covered with bloody crusts, under which pus gathered. If the lesion were left without treatment, during the period of repair, soft granulations sprang from the floor, and gradually epidermization took place. The tuberculin test was positive.

Discussion.

Dr. MacKee said that he thought that ecthyma should be applied to this case as an adjective rather than a noun, that it did not resemble an ecthyma so much as a disease which had become ecthymatous. He said that it was an acne in a cachectic individual, and that he had seen several similar cases, in which the face, chest, back and buttocks were involved.

Dr. Lapowski said that Jadassohn and Lewandowski had described a form of ecthyma of the type shown in this case.

RETICULATED ATROPHY OF THE SKIN OF THE FACE. Presented by Dr. Parounagian.

The patient was a boy, aged 9 years, born in the United States. The duration of the trouble was about four years. The lesions were situated on both cheeks, in the "flush area." No subjective symptoms were noted; the patient had pulmonary tuberculosis. The lesions consisted of numerous reticulated, scar-like depressions, sprinkled with a few comedones. There were a few atrophic patches in the centre of the large area on the right cheek. No scaling was found at the time of presentation. The younger brother had a similar condition but in a milder form.

DISCUSSION.

DR. MACKEE said that he had presented a similar case at another society, and that it had presumably begun with comedo formation, and subsequently had atrophied in a reticular manner, the red portion representing the atrophy, and the white or raised points the normal skin.

The following cases were also shown:

ULCER OF THE LIP. Presented by DRS. MACKEE AND REMER.

ACNE WITH KELOID FORMATION. Presented by DR. LAPOWSKI.

BROMODERMA. Presented by DR. LAPOWSKI.

GRANULOMA ANNULARE. Presented by DRS. GOLDENBERG AND CHARGIN.

PHILADELPHIA DERMATOLOGICAL SOCIETY.

Regular Meeting, Nov. 15th, 1915.

FRANK CROZER KNOWLES, M. D., *Chairman.*

CASE FOR DIAGNOSIS. Presented by DRS. STELWAGON AND GASKILL.

K. L., aged 40, white; occupation, paper-folder in a mill. The eruption first made its appearance eight weeks ago and consisted of very small vesicles on the lateral aspect of the mandible and just below the ear, on each side of the face. Within a very short time, a question of hours or a few days, there would be complete absorption of all the serum, leaving a depression in the centre. This eruption next made its appearance on the dorsal aspect of the hands and extensor surfaces of the arms. The lesions were exactly similar in every instance, with none larger than the head of an ordinary pin; while the more recent eruptions were vesicular, those which had been present a few days were umbilicated; some that had been in existence several weeks showed a very thin crust formation and still others were slightly hæmorrhagic, this having occurred, as the patient said, when she opened the vesicles with the point of a pin. There was little or no inflammation around the individual lesions. The patient stated that no lesions had entirely disappeared; that while new ones were coming out slowly, all of the old ones were in evidence. On the arms they had a tendency to occur in regular lines of five or six There was a very slight itching sensation but no other subjective symptoms. When the patient was first seen by the local practitioners, she was treated for "grass poisoning," as the eruption had been preceded by a marked swelling of the face. The Wassermann reaction was negative. She had been under the speaker's observation for the past four weeks and the only change that had occurred was a slight involution of some of the lesions on the face. The patient had been folding paper for several years, in the same mill, and had always done the same kind of work and there had been no change made in either her occupation or the character of the paper folded, prior to the time of the appearance of this eruption. She said that they had used some kind of "poison" in the making of this paper but what it was she did not know nor did she know whether any change had been made in the formula. At one visit which

she made to Jefferson Hospital, she presented a few vesicular eruptions in the palm of the hand, on account of which Dr. Stelwagon felt that a diagnosis of secondary syphilis must not be overlooked, though he did not look upon that as the real diagnosis.

Discussion.

Dr. Hartzell said that he had never seen a condition which resembled this in the slightest but he felt the suggested diagnosis of vesicular syphilis could be absolutely discarded on account of the absolute uniformity of the lesions.

Dr. Schamberg also stated that he had never seen such a condition and suggested a diagnosis of hydroa vacciniforme, which it resembled, but it was not a typical instance of that disease.*

SCLERODERMA. Presented by Dr. Gaskill.

J. G., male, aged 23; white; miner by occupation. About seven or eight months ago, the patient noticed on the left leg a whitening of the skin. The pigment had disappeared in small areas, closely grouped. This was quickly followed by a loss of elastic and fatty tissue and spread rather rapidly until the skin of the entire left foot and leg and half way up the thigh was firm and rigid, with numerous areas of brownish pigmentation alternating with a dead white color. As the disease advanced, a line of hyperpigmentation was pushed upward and then consisted of a band, about three inches wide, extending partly around the thigh, midway between knee and groin. On the inside of the left leg was a large plaque of sclerotic tissue which was distinctly yellowish in color; later this color would change to a reddish tint and then become almost colorless. The right leg was also involved but only up as far as the knee. The dorsal aspects of both hands showed the sclerodermic areas and when the patient was first seen, there was considerable board-like firmness here, but that had disappeared to a considerable extent. On the left side of the neck just back of the ear, was an area which the patient stated was typical of the onset of the lesions on the other parts of the body. It was a solid dead white plaque, about the size of an egg, irregular in outline, with numerous small, pinhead size, white spots surrounding it. There was considerable itching and burning and the skin was extremely tender over the entire tibial surface. It was here where the skin felt more "hide-bound" than in any other part of the body. The patient had had the usual diseases of childhood but otherwise always considered himself a very healthy man. He had gonorrhœa four years ago; he denied syphilis, but the Wassermann reaction was plus 2.

Discussion.

Dr. Schamberg said that he felt that as long as so many of these cases showed a positive Wassermann reaction, they were nearly all syphilitic in origin.

* Note. This patient was seen two weeks later and the face was very much swollen, as were the hands and feet. She had returned to work and the swelling began two days after she went back. At one time, it was so extensive that the eyes were absolutely closed and her face twice the normal size, accompanied by an intense burning sensation. She also presented in the palms of her hands the deep vesicular eruption which was suggestive of pompholyx. There were probably thirty or forty "sago-like" lesions in each palm but this eruption differed from the other in that it entirely disappeared in a week or two, while all of the lesions on the arms and face remained.

Dr. Hartzell, on the contrary, said that he thought that many of them were due to some pathological change in some of the ductless glands, particularly in that of the thyroid.

Dr. Gaskill said that some recent observers had found that not only were pathological changes found in thyroid, but in the pituitary body as well.

YAWS (FAMILIAL). Presented by Dr. Davis.

Girl aged six and brother aged eleven. Both parents were born in Brazil; they had come to this country about fourteen years ago, stopping for several months at Porto Rico. These children, who were two out of eight, were born in the United States but in different places, as the father was an itinerant coppersmith. Last July, the entire family was in Porto Rico, remained there over a month and the eruption, which became manifest about the middle of September, appeared after their return to this country. The little girl showed one lesion on the lower lip, two in the right popliteal space and one typical cauliflower growth, about three inches above the right popliteal space and one a few inches below. The boy had a few lesions of the same character on the legs. There was one sister at home who had a very large lesion on the buttock.

NÆVUS TREATED BY DESICCATION. Presented by Dr. Pfahler.

Girl, aged eleven, who, until April 1, 1915, had a black birthmark covering the outer half of each of the left eyelids. The child was anæsthetized, and the whole nævus destroyed by electrical desiccation. On May 24, 1915, there remained a black edge on the lower portion of the upper lid. Under chloroform anæsthesia this was destroyed. On July 9, 1915, and October 23, 1915, she was given X-ray treatment to counteract any tendency towards contraction of the scar. The result was almost perfect. Dr. Pfahler also showed a number of photographs of patients whom he had treated for nævi of different types, by the desiccation method, and the results were most satisfactory.

TERTIARY SYPHILIS. Presented by Dr. Schamberg.

Female, white, aged fourteen. This patient was shown as a result of the treatment by means of the arseno-benzol which had been made in the laboratories of the Polyclinic Hospital. Photographs were produced of the condition of the patient when she first presented herself at that hospital and was that of a typical inherited syphilis of the nose and upper lip. The resulting scar was very smooth. The nasal bones had been partly destroyed and where the nose should have been, the skin was on the level with the cheeks with only one opening for the nares. The patient had been under treatment for two months and the results were equally as good as one would obtain under the use of salvarsan.

SYCOSIS VULGARIS. Presented by Drs. Stelwagon and Gaskill.

Male, white, aged 37. This patient had been apparently successfully treated over a year ago at the Jefferson Hospital for sycosis of the upper lip, and was then lost sight of. When he was again seen, however, the eruption on the upper lip was just as marked as at first and there was another spot of sycosis on the right side of the chin. On the forehead, stopping abruptly at the median line, was a good sized area composed of numerous pustular lesions, on a

markedly inflammatory base, several of which were necrotic. At the outer edge of the left eyebrow was a single lesion about the size of a dime, crater-like, punched out and filled with a purulent material. On the right leg was a lesion about the size of a silver quarter, resembling an ecthyma. The lesions on the forehead resembled, to some extent, a herpes zoster which had become infected or, as was suggested, might have been pyodermic through contamination from the condition on the upper lip, though it was impossible absolutely to exclude a tertiary syphilis. The patient gave a history of an initial lesion for which he was treated in Germany for over a year. About two years ago, he had a Wassermann test made, which he said was positive and he was given two injections of salvarsan.

LUPUS ERYTHEMATOSUS. Presented by Dr. Schamberg.

Male, white, aged 30. This patient had been presented to this Society fifteen years previously with typical lesions of lupus erythematosus. Several times during the interval, the eruption entirely disappeared and at the time of presentation, there was no sign of it except the rather faint scarring. At times, however, the eruption had been treated by X-ray and external applications. He had not had any treatment, however, for the last two years and the eruption had apparently disappeared of its own accord.

CASE FOR DIAGNOSIS. Presented by Dr. Gaskill.

E. M., aged 38; white; fireman. Below the right popliteal space were two pigmented areas about the size of a silver quarter, irregular in outline and with no elevation. At the uppermost point was scarring, where a piece of tissue had been removed for microscopical examination. This patient had first been seen July 30th, 1915, having been referred to the Jefferson Hospital by Dr. J. Chalmers Da Costa, with the history of having had this trouble on the leg for several months. At the time of his admission, the leg was markedly swollen and very much inflamed, this having been produced by a "baking" by a local physician for the relief of pain radiating from the knee down to the ankle. The lesions at that time were distinctly brownish in color, slightly elevated and considerably indurated but were freely movable under the skin. There was also a lesion of the same type just below the left nipple and one on the calf of the left leg. The patient had lost considerable weight; had been a heavy drinker until four months prior to admission and had had gonorrhœa six years ago and while he denied a syphilitic infection, there was a plus 2 Wassermann. His wife had had no miscarriages and had four children, living and well. During his stay at Jefferson Hospital, the original diagnosis of sarcoma cutis was maintained but as there was a question of the malady being syphilis, he was put on very strong anti-syphilitic treatment—mercurial injections and three full injections of salvarsan at intervals of a week, after which time he had been given potassium iodide. There had been considerable improvement. The induration was less marked; the purplish color had disappeared, leaving in its stead brownish pigmentation with some atrophy; but in spite of the energetic treatment employed, the condition was not entirely well after a period of four months and, in fact, new lesions were making their appearance around the original one.

CASE FOR DIAGNOSIS. Presented by Dr. Hartzell.

Mulatto, male, aged 26. The entire trunk, from the waist line upward, was covered with a multitude of pigmented areas, varying from the size of a pea

to a fifty cent piece. These large areas also were present all over the lumbar region; there was very slight elevation and no scaling was discernible at the time of presentation. The patient had been seen that morning for the first time and there had been no opportunity for studying the eruption carefully. The speaker said he considered it a case of secondary syphilis but there was no suggestion of chancre on any part of the body. The Wassermann test was negative. There were several of these pigmented spots scattered over the legs but not in such close proximity as on the trunk. Interspersing these pigmented areas were erythematous spots very bright in color, in spite of this man being largely negro.

The eruption first began on the leg, two weeks previously, and Dr. Davis said that if it were not for the history of the short duration, one would be justified in thinking of a tinea versicolor. Dr. Stelwagon said that many of the lesions bore a very close resemblance to pityriasis rosea.

CASE FOR DIAGNOSIS. Presented by Dr. Schamberg.

Male, white, aged 28. The trouble, which was strictly confined to the nose, was of a year and a half's duration. At the beginning the nose began to enlarge and became very red until it was probably twice the normal size, very thick, indurated and glistening, with markedly dilated blood vessels. The patient gave the history of having had, about eight years previously, a "pimple" on the end of the nose which he picked and which left quite a depression and for which he was given paraffin injections by a "beauty specialist."

Discussion.

Dr. Stelwagon said that he had seen this patient three weeks ago and while he did not at that time look upon it as a positive case of tertiary syphilis, he gave the patient 20 grains of potassium iodide, t.i.d., and he said that there had been considerable improvement; but during that interval, the patient had been treated by two other physicians with the X-ray and ultra-violet ray. At one time, he had been treated in another city by the electric needle for rosacea.

Dr. Davis said that he had seen this type of large nose with marked teleangiectasia, following the injection of paraffin.

Dr. Schamberg looked upon this as a paraffinoma, with its infiltration of new fibrous tissue and the proliferation of new blood vessels to nourish the tissue. There was a history of a syphilitic infection ten years ago and the nose had been very sore on the inside for the last two and a half years.

NEUROFIBROMATOSIS. Presented by Dr. Knowles.

Female, white, aged 43. Scattered all over the neck and arms were numerous fibromata, with many more on the chest. None of these lesions was large and there were many areas of pigmentation scattered over the same situation. It was agreed that this was a case of von Recklinghausen's disease. Dr. Schamberg said that he thought this condition was due to some derangement of one or more of the ductless glands.

LUPUS ERYTHEMATOSUS. Presented by Drs. Stelwagon and Gaskill.

Female, white, aged 18. On the alæ of the nose were a few pinkish spots covered with a fine scaling and with some dilatation and widening of the

capillaries and follicles. This eruption had existed for the past two months and was very much improved by the treatment she had received at the Jefferson Hospital.

DISCUSSION.

DR. HARTZELL said that he would never have agreed with the diagnosis had it not been for a lesion on the inside of the ear.

DR. SCHAMBERG said that he would look upon this more as an acne rosacea than lupus erythematosus.

MANHATTAN DERMATOLOGICAL SOCIETY.

Regular Meeting, Dec. 17, 1915.

GEORGE M. MACKEE, M.D., *Chairman.*

CASE FOR DIAGNOSIS. Presented by DRS. MACKEE AND WISE.

The patient, a female adult, had come to the Vanderbilt Clinic on the day of presentation for the first time and there had not been time for any extensive investigations. The condition was a papular eruption appearing on the back of the hand and dorsum of the thumb. The papules had coalesced, forming a large patch. The color was dusky red. Infiltration was moderate. There was no exudation on the surface. The woman was presented with two tentative diagnoses, granuloma annulare or possibly an ordinary pompholyx. A biopsy had been taken and the case, the speaker said, would be reported later. Itching was not a marked symptom.

DISCUSSION.

DR. ROSEN thought the case was one of granuloma annulare. The absence of itching, the color, location, the semi-lunar like arrangement of the infiltrated papules, all spoke in favor of granuloma annulare.

DRS. BECHET AND PISKO agreed with the last speaker.*

TUBERCULIDE. Presented by DR. WALLHAUSER.

The patient, A. B., was a male adult, aged thirty-seven years, whose wife had died of laryngeal tuberculosis about eight months previously. About eight years ago the patient developed an adenopathy of the lymphatic glands at the angle of the jaw and post-occipital glands, limited to the right side; and about the same time, or shortly following, the patient noticed a few "sores" on his elbows which gradually disappeared, and then new ones developed at varying intervals of several weeks. During the past two years the intervals had become lessened so that the patient was never free of the eruption. Though mostly limited to the region of the elbows, other locations, as the lobe of the ear, the neck, and the anterior surface of the knees, had been involved. In these locations, however, only one or two lesions had developed.

* Subsequent observation of the patient's lesions proved them to be pompholyx.

DISCUSSION.

DR. WALLHAUSER said that he had nothing to add to the case clinically, but that as the glands may have caused this condition, he thought of surgical removal.

DR. MOUNT said he had been interested in looking up the possible relationship between lupus erythematosus and tuberculosis. There was one case of Delbanco's, where there had been enlarged cervical glands, and upon the removal of these glands the lupus erythematosus promptly disappeared. The condition reappeared when some other glands became inflamed.

DR. GEYSER said that he did not see the case, but on general principles he was absolutely opposed to the removal of glands of any kind. Glands were not present for the purpose of being removed. He said glands could be treated so as to perform their physiological functions and this could be done by the high-frequency method or diathermia.

DR. WALLHAUSER thanked the gentlemen for their discussion and said that he would have the high-frequency method of treatment tried on this patient. He said that if this did not improve the condition he might consider the removal of the glands, as he felt them to be the primary seat of the infection.

DR. GEYSER said that he had treated one case of Dr. Wallhauser's, where the glands all disappeared by the diathermia treatment.

DR. WEISS said that when tuberculin was in fashion, years ago, there had been a number of patients affected with lupus erythematosus, treated in Berlin with tuberculin, and nine out of ten reacted with a temperature of 102° to 103° F. There had been much strife among dermatologists as to whether lupus erythematosus was a tuberculous affection or not. He believed that lupus erythematosus was caused by the toxines of the tubercle bacilli and not by the tubercle bacilli themselves.

DR. MOUNT said that Bloch and Fuchs had succeeded, a couple of years ago, in demonstrating positively the presence of the tubercle bacilli in lupus erythematosus by inoculation experiments. Two or three positive inoculations had been recorded by them.

DR. FOX said that in the old tuberculin days he had injected a number of cases of lupus erythematosus, with a marked reaction, which would seem to show that it was of tuberculous nature. At the same time, he remembered one case of leprosy which also had a marked reaction of the lesions.

LUPUS ERYTHEMATOSUS? Presented by DR. WEISS.

The patient was a female adult, thirty years old, who had been treated by a colleague with a selenium ointment. The lesions were located all over the face and also occupied the lobe of one of the ears. There were small, atrophic scars visible between the lesions, which appeared to be flat patches. The speaker was inclined to think the case to be one of lupus vulgaris. The lesions had been treated with the Finsen light, ten years ago, in Scotland. He presented the patient to show the effects of the selenium ointment, which certainly had acted very beneficially in this case and merited a trial.

The speaker said that this case was not his own and that he had taken it to be one of lupus vulgaris, although his colleague looked upon it as lupus erythematosus. He wondered whether there was not any radio-activity in the selonium ointment, and if that had something to do with the healing of the lesions.

LUPUS VULGARIS. Presented by Dr. Weiss.

The patient was a female adult, twenty-four years of age, who was presented to show the effects of the different treatments she had received. The duration of the disease had been two to three years. The lesion was located on the right cheek and had been treated several years ago with the cautery and later with the solid carbon dioxide, which had, however, in this case, yielded a very hypertrophic scar. The use of carbon dioxide in lupus vulgaris was not one of promising results, and the doctor would rather use one of the old classical procedures or the X-ray.

Discussion.

Dr. Wise said that the scar had been produced by the carbon dioxide snow.

Dr. Satenstein said that Prudden had proved that the tubercle bacillus would live in ice indefinitely and that was one reason why there was no beneficial therapeutic action in lupus vulgaris from the carbon dioxide.

LUPUS ERYTHEMATOSUS. Presented by Dr. Weiss.

The patient was a female adult, who showed the effects of the solid carbon dioxide snow treatment. The lesion was situated on the nose. The treatment yielded a very favorable result.

LICHEN PLANUS UNIVERSALIS. Presented by Dr. Gottheil.

A. B., male adult, entered the City Hospital, November 26th, 1915. The eruption had begun three weeks before, appearing on the hands, forearms and neck, and gradually spreading. Itching was not marked, but the redness and swelling and burning had gradually spread up the arms and down the trunk, until the greater part of the skin of the body was involved. There was a general diffuse redness in the midst of which innumerable obtuse, shiny, slightly darker colored papules were discernible. On the thighs and legs, where the eruption was most recent, its lichenoid character was plainly evident. The patient was an electroplater and attributed his trouble to the fumes of hydrocyanic and hydrochloric acids, to which he was much exposed. He said that he had seen others doing the same work affected in the same way, which was not of much value in determining the ætiology of the affection, but the fact that the affection began on the hands and neck—exposed parts—and then spread on to the rest of the skin, was to some extent evidence of the possibility of his assumption.

Discussion.

Dr. Fox said that he agreed with the diagnosis. In the daylight he would base it largely upon the color but at night he based his diagnosis upon so many of the individual lesions. They were punctate, had increased and coalesced and had become confluent and there was a general dermatitis, which concealed the individual lesions, so that it would be very difficult indeed to find any true lesions of lichen planus. Shiny papules could often be found in cases of chronic eczema, but a flattened shiny papule did not necessarily mean lichen planus. Umbilication must be present to have a good basis for the diagnosis.

Dr. Milleg (by invitation) said in his opinion this eruption of lichen planus was but superinduced upon a violent general toxicodermia which still remained, and might have been the excitant cause.

Dr. Weiss said that the condition looked to him as one of either cause or effect. He said that two such cases had been presented that night, of dermatitis, with impetigo, in which lichen planus developed. The speaker reminded those present of the fact that lichen planus lesions could be produced artificially by the scratching of a pin. He said in these cases, where there was a general dermatitis, one could not tell whether the lichen was cause or effect.

Dr. Geyser said he thought there were two distinct eruptions present, that the lichen planus was there in the first place and the other lesions were secondary.

Dr. Gottheil said that when the case first entered the hospital there was a general diffuse redness of the entire body surface, and individual papules were hardly visible. It looked like a general dermatitis due to some internal or external irritant. In the course of a few days, however, the general erythema subsided to some extent and then the individual characteristic lichen papules became visible.

GUMMA OVER CLAVICLE. Presented by Drs. Howard Fox and Pisko.

The patient, E. B., was a colored woman, fifty years of age. The lesion for which she was presented appeared first about two months previously and was situated at the sterno-clavicular junction. It was a semi-solid, somewhat tender, hemispherical tumor, about two inches in diameter, covered by normal, unbroken skin. It was not apparently connected with the articulation or the bony structure. The Wassermann reaction was strongly positive. She had received several injections of salicylate of mercury.

LICHEN PLANUS OF UNUSUAL DISTRIBUTION. Presented by Dr. Wise.

The patient was a female adult, from the Mount Sinai Hospital Dispensary. She showed two types of lesions, one being the ordinary lichen planus encircling the abdomen and the other apparently a lichen planus atrophicus beneath and on the breasts. The lichen planus lesions had appeared subsequent to the cure of an impetiginous eczema. The lesions on the back showed a more typical lichen planus of the annular type. The atrophic lesions were smooth, glistening, polygonal and apparently imbedded into the healthy skin surrounding them.

Discussion.

Dr. Fox said that the irritation of tight clothing around the waist may have caused this location of the lichen planus. He had seen many cases where the eruption presented itself in this location and used to speak of it as the lichen planus girdle.

CASE FOR DIAGNOSIS. MELANOSARCOMA? Presented by Dr. Bechet.

The patient, a male adult, presented for examination a lesion on his palate, which he stated had been present for three weeks only. It was absolutely painless and gave him no discomfort whatever. Most of the hard and soft palate was occupied by a tumor mass of doughy consistency and blackish color. A number of isolated nodules, jet black in color, were noticeable at the periphery of the mass. The patient's general health was good. His nutrition was unimpaired.

DISCUSSION.

DR. WEISS said he believed it to be sarcomatous.

DR. MACKEE, in reply to a query, said that the X-ray might cause a disappearance of the lesion, as the effect of this agent on sarcoma was rather favorable. The ultimate prognosis was, of course, very bad.

LUPUS ERYTHEMATOSUS. Presented by DR. BECHET.

The patient, a male adult, had been presented before the Society two and one-half years previously. He was shown again because the condition had remained stationary and had not increased in extent. The lesions were entirely confined to the lower lip. As the case had been so chronic and had showed no tendency to increase, the speaker thought the chances for complete recovery were good if the lesions could be efficiently destroyed. He therefore asked for some therapeutic suggestions. The patient had had ordinary dispensary treatment.

LICHEN PLANUS HYPERTROPHICUS. Presented by DRS. HOWARD FOX AND PISKO.

The patient, J. L., was a Russian, fifty-three years of age, a clerk by occupation. The eruption had first appeared over four years ago, when he noticed a few "pimples" on his wrists. These lesions gradually enlarged and others appeared on the forearms, backs of the hands, along the shins and on the abdomen, the glans penis and buccal mucous membrane. Many of the lesions had coalesced and formed hypertrophic and somewhat verrucous patches. The clinical diagnosis was apparent from the violaceous color and the presence of a few isolated typical papules of lichen planus. On the hypogastric region there was a circumscribed, elevated, flattened mass, about an inch in diameter. There had been some improvement by treatment with pure carbolic acid.

DISCUSSION.

DR. MILLEG (by invitation) said that he had seen this case for some time and it had given little or no reaction to internal or external treatments. He would be pleased to receive suggestions as to treatment.

DR. PISKO, in reply to a query, said that he had seen this patient for almost four years and he was quite sure that the pubic lesion originated at the same time and grew in the same way to the hypertrophic form, as those on the forearm, and he did not think they had any independent origin.

DR. WISE believed that it was safe to say that these tumors would not disappear until they had received X-ray treatment in massive doses and that carbolic acid would not remove the larger tumors. Cauterization would have the same effect as carbolic acid—it might flatten down the condition but would not act radically upon the deep seated tumors. He could not conceive of a weak cauterant, such as phenol, having the power to destroy such large masses.

DR. MACKEE said that he had tried chemical caustics and irritants and stimulants, the solid carbon dioxide and the Kromayer lamp, in the treatment of hypertrophic lichen planus. In cases where the verrucous element was not extremely marked these measures, especially the Kromayer lamp, and mild applications of the solid carbon dioxide, were very efficacious.

In stubborn cases and even in instances where the verrucous element was very excessive, he had never failed to produce a cure with one or two intensive X-ray applications.

Dr. Weiss said he wanted to draw the attention of the Society to an old remedy which he had lately used on a case of lichen planus, intramuscularly, consisting of arsenic two per cent.,—two or three drops— up to six drops—and the lesions cleared up wonderfully. As good a result had been produced with small doses as with larger ones, which caused a severe reaction.

SYPHILITIC PERIOSTITIS. Presented by Drs Howard Fox and Pisko.

The patient, S. F., was a chauffeur, twenty-three years of age, born in the United States. Both of his parents had been treated by Dr. Pisko in former years, before the patient's birth. The man claimed that he had never had any initial lesion or any other signs or symptoms of syphilis until seven months ago, when the right forearm became swollen and painful. He presented a marked bowing of the right forearm on the ulnar aspect, the X-ray picture showing a typical syphilitic periostitis. The Wassermann reaction was four plus. It was not possible to say whether the infection was hereditary or acquired.

The speaker said that the condition in the brother was acquired; he presented a gumma of the tongue.

PERSISTENT APHTHOUS STOMATITIS. Presented by Dr. Howard Fox.

The patient, L. M., was a woman, twenty-six years of age, born in Hungary, a waitress by occupation. Four years previously she had suffered from ulceration of the lip, lasting three weeks. During the past nine months she had suffered from numerous ulcerations of the lower lip and buccal mucous membrane. Some of these lasted for a day and others for weeks. The lesions were mostly situated on the mucous membrane of the lower lip near the vermilion border. Two of them were moderately deep and indurated. They had persisted for six weeks. There were no signs or symptoms of syphilis. The Wassermann reaction, which had been performed on eight different occasions, at various clinics, was always negative. On one occasion a provocative injection of salicylate of mercury had been given. The appetite was poor, the tongue coated and the patient had suffered a long while from indigestion.

Discussion.

Dr. Satenstein said he thought the case distinctly tuberculous and very similar to a case presented by Dr. Wise at the last meeting.

Dr. Bechet said he agreed with the diagnosis of very extensive stomatitis, notwithstanding the duration of the lesions.

Dr. Satenstein said he could not understand a stomatitis involving the lip lasting five or six weeks. He said that the excavated, undermined edge struck him as tuberculous and that a biopsy ought to reveal the nature of the malady.

CHEILITIS EXFOLIATIVA. Presented by Dr. Howard Fox.

The patient, W. M., was a man, twenty-eight years of age, born in the United States. The eruption upon the lips had first appeared fifteen years before and had been the cause of losing his position as a clerk. He had since spent most of his time at sea, as an engineer. He had suffered from a most persistent and annoying exfoliation of both lips, mostly confined to the vermilion borders. The scars, which were superficial and friable, were easily detached but would appear within five to seven days after their removal. They constituted a disagreeable annoyance, especially during eating. The patient had never smoked in his life and had been formerly a very moderate drinker. He was in apparent good

health, the appetite was good, the bowels regular, and there was no indigestion. He weighed about one hundred and ninety pounds.

On examination he presented, upon the vermilion borders of both lips, yellow-blackish, friable and dirty loooking crusts. These were very easily removed by slight traumatism. When removed, a somewhat reddened surface was left, studded with pin point to pin head elevations. From these could be expressed tiny drops of clear viscid mucus. Both lips, especially the lower, were swollen. Treatment with collodion, silver nitrate, X-ray and innumerable salves had given no relief. The speaker had given him one treatment with radium.

Discussion.

Dr. Wise said he thought the X-ray, given in one measured dose, should cure the case.

CASE REPORT. PSEUDO-DIPHTHERIA OF THE SKIN. Reported by Dr. Gottheil.

This case could not be exhibited, since she was running a temperature and was confined to bed. The patient was a female of about thirty-five years, who had begun to complain of sore mouth and throat, and trouble in the vagina, a few days before admission. She began to feel very feverish and sick and was brought into the hospital on a stretcher. On admission, a week ago, she had fever running up to 104° F., with corresponding pulse and respiration. There was great prostration and she complained much of her mouth and vagina. Internal organs, blood, urine, etc., were normal. The mucosa of her lips, tongue, cheeks and pharynx was studded with circular and circinate erosions, from pea to bean size, and confluent in many places. The pharynx and tonsils, so far as they could be examined, were in the same condition, but her voice was not hoarse and she complained of no dyspnœa. The vaginal mucosa and that covering the labia minora was in exactly the same condition. The bladder mucosa and that of the respiratory and digestive tract, was apparently unaffected. Most interesting, however, was a lesion on the skin of the inner surface of the thigh, seated just below the edge of the labium majus, on the left side. It was a sharp cut, bright red erosion, one inch by half an inch in size, and with its long axis parallel to that of the leg. There was hardly any inflammatory border to it and it looked as if it had resulted from a large, deep seated bulla. The patient could give no history of the outbreak other than the facts above recorded. Examination of scrapings from the lesions in the mouth, the vagina and on the skin showed the presence of practically a pure culture of a pseudo-diphtheria bacillus, morphologically resembling the true Klebs-Loeffler organism, very closely. Under no treatment at all, save ordinary cleanliness, the malady rapidly ran its course. The oral and vaginal mucosa improved, the erosion of the skin became epidermidized, in three days the fever gradually subsided and in a week the patient was well.

Epicrisis. Five days after the patient's discharge from the hospital she re-entered with another attack, similar to the first one. There were the same lesions in the mouth and the vagina but nothing on the skin, only a discolored mark remained to show the site of the former dermal affection. The general symptoms were the same, though the fever was not so high. This second attack ran its course in a shorter time than the first one. In five days the patient was discharged. Precisely the same organisms were found in the lesions of the second as in those of the first attack.

Dr. MacKee asked Dr. Gottheil whether the pathologist had called the organism the diphtheria or the pseudo-diphtheria bacillus?

CASE REPORT. TERTIARY CIRCINATE SYPHILODERM, WITH NEGATIVE WASSERMANN AND WITH NODULES AND BREAKING DOWN IN THE SCAR. Reported by Dr. Gottheil.

This patient, a male adult, had been in the hospital a year ago for trouble similar to that present. The entire perineal, perianal and scrotal region was occupied by scar tissue and the penis stunted and deformed by cicatricial atrophy. The present condition, which had been coming on and getting worse for several months, consisted of a very large circle of more or less confluent, circinate, ulcerative lesions, the individual members of which were quarter-dollar sized on the average and which extended from the anterior margin of the anus, in two large circular sweeps, over both buttocks, on to the edges of the perineum and then in two anterior semicircular sweeps, on to the surface of the abdomen, above the penis. The entire mid-portion of this extensive area was occupied by cicatricial tissue, the remains of his previous ulcerative attack and in this cicatricial tissue, at various points, were nodules, breaking down and ulcerated and smaller circinate ulcerated lesions, precisely similar to those composing the advancing margins of the lesions. Around the anus were small, papillomatous growths more or less filiform and not of the broad condyloma type and there was more or less ulceration at their bases and margins. The history, as given by the nurses, was that when the patient was in the hospital a year ago, he had had precisely similar lesions at the same site, but less extensive in area, that he had had a dozen Wassermann reactions, with uniformly negative results, that anti-luetic treatment had done him no good, that the affection had finally been regarded as a tuberculosis and that treatment in that direction had done him good. Blood tests made now were also negative. For that reason, as well as because of lesions that might be well regarded as lupoid, were apparent in the scar tissue, he was put on the Kromayer lamp treatment. It did not improve his condition at all. He was then by "accident" and without the knowledge either of the Visiting or of the House Staff, dressed with a ten per cent. solution of the oleate of mercury in olive oil, and the lesions began to improve at once. Under antisyphilitic treatment, both general and local, he has been steadily getting better, but his mouth and stomach became so affected that both iodine and mercury had to be abandoned lately and he is now taking arsenic in large doses. The improvement was continuing under this medication and he will soon be cured of his lesion. After the first provocative mercurial injection, his Wassermann became feebly positive.

Here, then, was an extensive tertiary ulcerative syphilitic lesion with a persistently negative Wassermann, and with the appearance of new nodules and ulcerations in the scar tissue, already traversed by the serpiginous specific ulceration.

Discussion.

Dr. Wise said that Dr. Fordyce had removed a piece of tissue from this patient's lesion; the microscopic changes were characteristic of tuberculosis of the skin.

Dr. Mount said it was a well known fact that tuberculous lesions of the skin responded to the same medication that syphilis does up to a certain point, but then proceeded no further in the healing.

Dr. Howard Fox said that the negative Wassermann reaction and particularly the histological report of tuberculosis fitted in perfectly well with the clinical picture, which, he thought resembled tuberculosis fully as much as it did syphilis.

CASE REPORT. ERYTHEMA MULTIFORME (?). Reported by Dr. Howard Fox.

Dr. Howard Fox reported upon a case previously shown before the Society by Dr. Ochs, as a possible circinate erythema multiforme. The patient presented a circinate lesion of the forehead and grouped macular lesions of the thigh. He had changed his diagnosis to one of late syphilis, as the Wassermann was strongly positive.

PROGRAM.

Fortieth Annual Meeting of the American Dermatological Association, Held in Washington, D.C., May 8, 9 and 10, 1916.

President's Address, How Can We Improve Our Hospital Service?
Charles J. White, M.D.
The Follicular Type of Seborrhœic Eczema .....William B. Trimble, M.D.
The Treatment of Acne .....Ralph A. McDonnell, M.D.
Diffuse Pigmentation of the Scrotum in Lichen Planus.
Douglass W. Montgomery, M.D.
Acnitis in the Negro.....Frank Crozer Knowles, M.D.
The Dermatologist the Proper Teacher of Syphilis .....Joseph Zeisler, M.D.
Congenital and Bone Syphilis .....Abner Post, M.D.
Syphilis of the Viscera.....Udo J. Wile, M.D.
Syphilis of the Nervous System .....John A. Fordyce, M.D.
The Treatment of Syphilis .....Sigmund Pollitzer, M.D.
Further Observations on So-called White Spot Disease, or
Circumscribed Scleroderma .....Fred Wise, M.D., and I. Rosen, M.D.
Acrodermatitis Hiemalis .....Milton B. Hartzell, M.D.
The Importance of Visceral Symptoms in Dermatoses of the
Exudative Erythema Type .....Burnside Foster, M.D.
An Apparently Unique Case of Cutaneous Disease Due to Peculiar
Fat-cell Degeneration .....T. C. Gilchrist, M.D., and Lloyd Ketron, M.D.
Monilethrix .....George M. MacKee, M.D., and I. Rosen, M.D.
Experimental Studies of the Toxicity of Dioxydiamino-Arsenobenzol
Dichlorhydrate:
(a) Toxicity of Concentrated Solutions.
(b) Toxicity of Acid Solutions.
(c) Toxicity of Alkaline Solutions of Varying Degree.
(d) Toxicity of Solutions Made with Water from Different Sources.
(e) Age of the Solution as Affecting Toxicity.
(f) Relation of Lethal Dose to Reactive Manifestations.
(g) Nature of the Reactive Symptoms.
(h) Discussion of the Causes of Toxicity.
Jay Frank Schamberg, M.D., John A. Kolmer, M.D., and
George W. Raiziss, M.D.
Annular Macular Syphiloderm.....Howard Fox, M.D.
An Unusual Variety of Vitiligo (Leucoderma Acquisita Centrifugum)
Richard L. Sutton, M.D.
Demonstration of Cases of Visceral Syphilis .....H. H. Hazen, M.D.

REVIEW

OF

DERMATOLOGY AND SYPHILIS.

Under the direction of

FRED WISE, M.D., New York,

Assisted by

Clarence A. Baer, M.D., Milwaukee.
William H. Baughman, M.D., New York.
Paul E. Bechet, M.D., New York.
J. S. Eisenstaedt, M.D., Chicago.
Charles Goosmann, M.D., Cincinnati.
James F. Grattan, M.D., New York.
Robert C. Jamieson, M.D., Detroit.
Frederick T. Lau, M.D., New York.
M. F. Lautman, M.D., Hot Springs.
Oscar L. Levin, M.D., New York.
M. L. Ravitch, M.D., Louisville.
Isadore Rosen, M.D., New York.
Max Scheer, M.D., New York.
Philip F. Shaffner, M.D., Chicago.
A. W. Stillians, M.D., Chicago.
John H. Stokes, M.D., Chicago.
Harvey P. Towle, M.D., Boston.
Vicente Pardo, M.D., Havana, Cuba.

BRITISH JOURNAL OF DERMATOLOGY.

(December, 1915, xxvii, No. 12.)

Abstracted by I. Rosen, M.D.

THE RELATION OF THE STAPHYLOCOCCUS ALBUS AND THE ACNE BACILLUS TO THE EPIDERMIS AND THE EXCRETIONS OF THE SKIN—WITH SPECIAL REFERENCE TO THE LESIONS OF ACNE VULGARIS. T. H. C. Benians, p. 436. (*Continued.*)

The second part of this paper consists principally of some clinical observations on physiological and pathological conditions, and the theoretical application to these conditions, of the experimental data already cited.

The skin normally is provided with certain protective properties:

1. The keratinous covering of the skin; this horny layer covers the entire surface of the body, and under certain circumstances it is apt to hypertrophy,

2. The presence of fats on the skin. The author's experiments have shown that the function of the fats upon the skin is to inhibit the bacterial enzymes, which enzymes would otherwise be able to act injuriously on the horny layers of the skin.

3. The antibodies of the tissues and the tissue fluids.

The comedo is considered to be a hyperkeratosis in some localized region, as of a hair follicle, arising as a result of the action on the tissues of the products of bacterial growth, notably those of the staphylococcus. The pigment in the comedo is formed from fatty substances present in the keratinous cells.

There are three distinct types of pustulation that commonly occur in a case of acne vulgaris.

1. Acute—follicular pustule.
2. Subacute—pericomedonal abscess.
3. Chronic—(*a*) Thin-walled tracking abscesses. (*b*) Fibrotic masses enclosing a small bead of pus and degenerated comedo.

The author has always found the acne bacillus in the acute-follicular, and the chronic tracking forms of suppuration; and the Staphylococcus albus in the pericomedonal and the chronic indurated abscesses.

SCLERODERMIA GUTTATA. F. Silva Jones and Hubert M. Turnbull, p. 450.

The authors report a case, in a woman, 55 years of age. The lesions were located on the abdomen, between the umbilicus and the groin; there were seventy-odd in number, of pearly white color, having a mosaic-like arrangement, flush with the surrounding skin; some were discrete, others joining with neighboring spots to form an irregular pattern where fusion was present; on pinching up the skin the division could be made quite plain. Most of the solitary lesions were the size of a pinhead, and between them, except where they joined, was a band of normal skin. Each plaque was indurated, showed no umbilication, was anæsthetic, and showed no inflammatory zone.

In about half the number of the separate lesions, there were one or two minute teleangiectatic red spots; in one instance, two connected by a fine red line.

There was a group of lesions on the left leg, just below the knee, on the outer side. This consisted of about forty individual spots, and only one lesion showed minute teleangiectases. Several of the spots appeared umbilicated; none showed an inflammatory halo. The color of these lesions was not as white as that on the abdominal lesions, and the induration not as marked.

This case differs clinically from any of the reported cases in the literature, in its association with teleangiectases which appear around the lesions, and which are also seen in the spots themselves.

The authors report in detail their histological findings, in sections removed from the abdomen and the leg.

RUSSKI JOORNAL KOJNIKH E VENERICHESKIKH BOLEZNEI.

(November and December, 1914, xxviii, Nos. 11 and 12.)

Abstracted by M. L. Ravitch, M.D.

THE TREATMENT OF LUPUS VULGARIS BY CARBON DIOXIDE SNOW. Levchenkov, p. 213.

Levchenkov gives a résumé of the development of methods of treating lupus vulgaris by physical means. Cold applications in one form or another have been used since Gebhardt, in 1885, showed that the growth of the tuberculosus bacillus ceases at a temperature lower than 28° C. Gebhardt himself used various methods of securing low temperatures in the treatment of lupus vulgaris; Hansen used ice applications with considerable success; Dethlefsen, in 1900, recommended ethyl chloride as a most successful agent, and Arning employed a mixture of ethyl and methyl chloride. Dreuw, of Hamburg, used the

following method: After freezing the lupus tissue with ethyl chloride, he rubbed into the frozen area a strong solution of crude hydrochloric acid, the hydrochloric acid acting on the frozen tissue selectively, destroying the lupoid areas and sparing the healthy tissue. Juliusberg made use of liquid carbon dioxide, while later, White, Dade, Whitehouse and Saalfeld used liquid air. To Pusey belongs the honor of using the carbon dioxide in snow form, instead of as a liquid. Levchenkov describes the technique and cites clinical cases. His technique is about the same as that employed in this country, with very similar results.

HEMISCLERODERMA. Josephovitch, p. 232.

Out of 17 cases of hemiscleroderma gathered by Josephovitch, three were his own. According to Troitzki, particular attention should be drawn to the following case: In a child 4 years old there appeared convulsive attacks in the muscles of the right half of the body, beginning in the muscles of the right side of the face; these attacks seemed to belong to the Jacksonian type of epilepsy; one and one-half months later there appeared an anæsthesia of the muscles of the right side of the back and a sclerodermic patch on the right side of the body, right arm and the right side of the hairy part of the head, and also a small area on the left side of the right scapula. Later on there was also noticed atrophy of the right half of the tongue. Such cases, according to the author, are of cerebral origin.

SERUM AND VACCINE THERAPY IN DISEASES OF CHILDREN. Nabarro, p. 233.

According to Nabarro, vaccine therapy in diseases of children has more value than serum therapy. An interesting case of a chronic erysipeloid inflammation of a recurrent nature was aborted by four injections of stock streptococcus vaccine. The doses ranged from 5 to 75 millions per injection. In the treatment of pyuria, a careful determination of the bacterial cause is essential. The dose is also a very important item and should be carefully regulated.

MULTIPLE DERMATOMYOMATA. Abramson, p. 243.

Troitzki quotes Abramson's thirty-second case of multiple dermatomyomata. A patient, aged 35, noticed a swelling on his right arm, 17 years ago. Later, knots and swelling appeared on the surface of the skin all over the head and upper part of the body. These knots and tumors ranged in size from a pinhead to a walnut. The smaller knots were pale in color, the larger ones reddish or pale violet; the tumors were spheroid or oval in form. The growths were hard and imbedded quite deeply in the cutis. They increased in size quite slowly, 16 years being required for their development. As the tumors grew larger the patient began to feel "rheumatic-like" pains in the affected areas. This pain soon became intermittently dull and lancinating and interfered greatly with the patient's sleep. Under chloroform anæsthesia, sections from a great many tumors were secured, but revealed nothing more abnormal than is usually found in fibrous tumors.

LATE PRIMARY SYPHILIS. Zelenev, p. 246.

Zelenev says that the primary manifestation of syphilis may appear very late, just as is the case with the secondary stage. Early settlement of this point is

very important, and may bring forward facts of importance as to the possibility of reinfection with syphilis. At present, according to the clinical data and the published cases of Zelenev, Stern, Hoffmann, Bettman and others, there is no doubt of the possibility of reinfection in syphilis. However, whether this is a true reinfection is very hard to prove, since neither clinical, bacteriological nor serological data and investigations can be brought to that degree of accuracy necessary to produce an undisputed solution. Syphilitic chronic infection is so insidious that it gives the specialist in syphilis a great many surprises. Zelenev claims to know of many cases which were seen by specialists and pronounced cured, only to get a hemiplegia before reaching home, and other cases treated at sulphur springs, pronounced cured and sent home, only to turn up shortly with an iritis or other syphilitic manifestations. He therefore advises that a prognosis should not be given in many cases of syphilis. He also claims to have seen many cases in which the site of primary inoculation remained quiescent for many years, to break out suddenly in the same place. Such cases were also seen by Puche, Verneuil and Record. Zelenev has seen two cases where the chancre recurred at the old location after 6 and 12 years, respectively, had passed since the primary inoculation. These cases he vouches for as authentic, as both of them have been under his observation. No other symptoms were found in either case: neither dermal, nor of the mucous membrane, nor of the glands; the Wassermann in each case was negative. Several bacteriological examinations at different times failed to reveal the Spirochæta pallida. Under injections of mercuric bi-bromide and sulphur baths, the chancres quickly disappeared. Zelenev concludes that the ætiology of the return of local syphilides is as yet unknown and cannot be satisfactorily explained. It may be, as Gaugeroth said, that "spirochætæ may remain latent in a saprophytic form in the skin or the spirochætæ may assume a spheroid form that under certain conditions may turn into virulent spirochætæ."

JOURNAL OF EXPERIMENTAL MEDICINE.

(February, 1916, xxiii, No. 2.)

Abstracted by R. C. Jamieson, M.D.,

EXPERIMENTAL SYPHILIS IN THE RABBIT, PRODUCED BY THE BRAIN SUBSTANCE OF THE LIVING PARETIC. Udo J. Wile, p. 199.

Wile followed the experiments of Forster and Tomasczewsky in this work, obtaining material from a living, typical paretic. A rabbit was inoculated with material from five or six cases, nodules subsequently developing in two weeks. Spirochætæ were found in the lesions, and were inoculated in other rabbits for three generations.

He states that these spirochætæ differ from the ordinary spirochætæ in being shorter and thicker, resembling the refringens.

He concludes that tissue from the brains of living paretics can easily produce syphilis in rabbits.

AMERICAN JOURNAL OF THE MEDICAL SCIENCES.

(February, 1916, cli, No. 2.)

Abstracted by R. C. Jamieson, M.D.

PATHOGNOMONIC CHANGES OF THE CEREBROSPINAL FLUID IN SYPHILIS OF THE NERVOUS SYSTEM. Joseph Collins, p. 222.

The author reviews some of his work in the examinations of the cerebrospinal fluid and states that in meningeal syphilis, the most pronounced change, in addition to the positive Wassermann, is an increase in the cells, particularly mononuclear. These cases, he thinks, usually yield promptly to treatment. In cases where the connective tissue is particularly affected, the blood Wassermann is usually positive, the cerebrospinal fluid showing comparatively few positive reactions (about 30%).

In tabes, the Wassermann test is usually positive, cells moderately increased, particularly lymphocytes. In general paresis the cerebrospinal fluid is positive and cells are increased in about 80% of cases; globulin in 65% and the colloidal gold test in 97% are positive.

ARCHIVES OF INTERNAL MEDICINE.

(November, 1915, xvi, No. 5.)

Abstracted by R. C. Jamieson, M.D.

THE COAGULATION TEST FOR SYPHILIS, AS DEVISED BY HIRSCHFELD AND KLINGER. H. N. Cole and S. Eng-Kiu Chiu, p. 880.

The originators thought there might be a deviation of cytozymes and devised this method, which depends upon the coagulability of the blood. The authors give in detail the methods followed in preparing each ingredient used in the reaction, consisting of patient's serum, antigen, calcified sodium chloride, serozyme and oxalate plasma, and also the method of combining them to obtain the reaction, the reading depending upon the time elapsing before coagulation takes place. The technique is too elaborate for abstracting but their conclusions are of interest, their results showing this test to be as characteristic as the Wassermann test. Many cases (10.5%) gave positive results with negative in the Wassermann test, the cases comprising all stages of syphilis, including cerebrospinal and latent syphilis.

All serums which had been inactivated at 58° C. for one hour will keep on ice for at least one week, without deterioration.

If properly executed, this test is equal to the Wassermann and cases of treated syphilis will give negatives, as does the Wassermann test. Some primary cases gave positive results with the coagulation test, while still negative to the Wassermann.

(*Ibidem*, December, 1915, xvi, No. 6.)

OIDIOMYCOSIS IN CALIFORNIA, WITH ESPECIAL REFERENCE TO COCCIDIOIDAL GRANULOMA. E. C. Dickson, p. 1028.

The author gives a complete and detailed description of the disease, stating that the origin of the organism is unknown, but that with few exceptions all cases reported had lived in, or visited California—27 of them in the San Joaquin valley.

The first lesions appeared either on the skin, in the lungs or in the joints, all simulating tuberculosis. The skin lesions appeared as small nodules, which gradually enlarged, broke down and discharged pus, became crusted and slowly enlarged peripherally, resembling a localized cutaneous tuberculosis.

In the lung infection, the picture is tuberculosis with its concomitant symptoms, except that there are no tubercle bacilli. Others may begin as an arthritis in which the joints become swollen, red, painful and later fluctuate.

Almost all cases progress to general infection and terminate fatally.

Pathologically, the picture is that of a tuberculosis, the microscopic examination being necessary to prove the diagnosis. The disease has a marked tendency to involve testicular tissue.

The organism is found in the pus and sputum, is spherical, 30 microns in diameter and contains a slightly granular protoplasm. It is highly refractile and can easily be distinguished if the microscopic examination is made with but little light. Reproduction is by endosporulation.

The prognosis is grave, a fatal termination following a few weeks or months after generalized infection. Various forms of treatment have been tried without success, but in cases having the initial lesion on an extremity, amputation may prevent general infection. Spontaneous recovery is rare.

(*Ibidem*, January, 1916, xvii, No. 1.)

THE INTRASPINAL TREATMENT OF SYPHILIS OF THE CENTRAL NERVOUS SYSTEM, ACCORDING TO THE METHOD OF SWIFT AND ELLIS. Richard Dexter and C. L. Cummer, p. 82.

The authors review the literature on the subject and give tabulated reports of the cases treated by them. They have seen no ill effects or symptoms which could be attributed to injury of the central nervous system, but those patients who had the severest pain in the reaction following the injection showed the most pronounced and rapid improvement.

Spinal fluid Wassermann and increased globulin content were very persistent but pleocytosis quickly disappeared. Pains either disappeared completely or were much less severe, while the whole general economy showed great improvement. They feel that in early tabes and cerebrospinal lues the best results will be obtained and consider the Swift-Ellis method safe, if correctly administered.

BOSTON MEDICAL AND SURGICAL JOURNAL.

(Feb. 24, 1916, clxxiv, No. 8.)

Abstracted by Oscar L. Levin, M.D.

RINGWORM OF THE HANDS AND FEET. J. E. Lane, p. 271.

THE TREATMENT OF PSORIASIS WITH HORSE SERUM. Arthur P. Perry, p. 274.

The results obtained by the author in the treatment of psoriasis with horse serum corresponded to those observed with autoseropathy. Injections of autogenous and exogenous sera, combined with local or internal treatment, seem to exercise a favorable influence on the disease, but when given alone are of little value. It is therefore suggested that horse serum replace autogenous, in the serum treatment of dermatological conditions.

NASHVILLE JOURNAL OF MEDICINE AND SURGERY.

(November, 1915, cix, No. 2.)

Abstracted by Oscar L. Levin, M.D.

PELLAGRA—ITS HISTORY, SYMPTOMS, CAUSES, TREATMENT, PREVENTION. S. E. Cox, p. 489.

(*Ibidem*, January, 1916, cx, No. 1.)

THE PRESENT CONDITION OF SYPHILITIC THERAPY. A. Rostenberg, p. 1.
(Translated from *New Yorker Medizinische Monatschrift.*)

VIRGINIA MEDICAL SEMI-MONTHLY.

(Jan. 7, 1916, xx, No. 19.)

Abstracted by Oscar L. Levin, M.D.

A SPECIFIC CASE GIVEN ENERGETIC, PERSISTENT ANTISYPHILITIC TREATMENT WITH NO EFFECT ON THE BLOOD TEST. H. G. Fuller, p. 485.

UNITED STATES PUBLIC HEALTH SERVICE.

(Oct. 22, 1915, Reprint No. 307.)

Abstracted by Oscar L. Levin, M.D.

THE PREVENTION OF PELLAGRA. JOSEPH GOLDBERGER, C. H. WARING, DAVID G. WILLETS.

The diet in two orphanages and the Georgia State Sanitarium was modified to include an increase in the fresh animal and the leguminous protein food and a reduction of the carbohydrate food. No change was made in the hygienic and sanitary conditions. The institutions had been for years endemic foci of pellagra. Following the change in the diet, no new cases appeared, and of 244 pellagrins, only one showed evidence of a recurrence.

During the period of observation, 15 of 32 control pellagrins, whose diet was not modified, presented recurrences.

The writers conclude that pellagra seems to be caused by a faulty diet, which is deficient in animal or leguminous protein food, but over-abundant in starchy material. The disease may be prevented by an appropriate diet.

(*Ibidem*, Nov. 12, 1915, Reprint No. 311.)

EXPERIMENTAL PELLAGRA IN THE HUMAN SUBJECT BROUGHT ABOUT BY A RESTRICTED DIET. JOSEPH GOLDBERGER AND G. A. WHEELER.

The experiment was planned to test the possibility of producing pellagra in a healthy individual by a restricted, one-sided carbohydrate diet. Twelve white, adult, male prisoners at the Mississippi State Penitentiary were segregated and put on the restricted diet. At the end of six months, six out of the eleven men who had persisted, showed evidence of pellagra. The dermatitis in all the cases first appeared on the scrotum. Gastro-intestinal and nervous symptoms were mild. Previously, pellagra had never been observed at the institution. None of the other men confined in the prison, living under the same sanitary environment as the volunteers but on the regular mixed diet, developed signs of the disease. The authors conclude that pellagra has been caused in six of eleven volunteers as the result of the restricted diet on which they subsisted.

JOURNAL OF THE MEDICAL ASSOCIATION OF GEORGIA.

(November, 1915.)

Abstracted by OSCAR L. LEVIN, M.D.

PRINCIPLES AND PRACTICE IN THE TREATMENT OF CANCER. M. B. HUTCHINS, p. 151.

The successful treatment of a malignant growth demands complete removal or destruction of the growth and all metastatic foci. In carcinomata, the active cells are at the periphery, hence during manipulation for purpose of diagnosis or treatment, gentle handling is essential to prevent extension of the disease. Cancer in its early stage can always be cured. Doubtful symptoms should not be ignored and all suspicious lesions promptly removed. In cases where there is room for operation or where metastasis has occurred, excision, en masse, is the treatment par excellence. Cutaneous epitheliomata are amenable to treat-

ment with X-rays, radium, diathermia, dessication or cautery. Radiation should not supersede operation, but may render a case operable and may prevent recurrence, if employed immediately after operation.

NEW YORK MEDICAL JOURNAL.

(Jan. 29, 1916, ciii, No. 5.)

Abstracted by JAMES F. GRATTAN, M.D.

IRRITATION AS A FACTOR IN MALIGNANT TUMOR DEVELOPMENT. G. N. ROHDENBURG, p. 201.

This is a review of four cases where irritation had apparently been a factor in producing malignancy. Case 1; a girl, fifteen years old. Laparotomy and removal of simple cyst of right ovary. Tiny cyst of left ovary punctured with scalpel, at the same operation. Two weeks later she complained of abdominal pain on the left side. Cystic masses were now felt on the left side. A second laparotomy revealed a tumor of the left ovary, with masses of omentum. The tumor and omental masses were small spindle-cell sarcomata. Case 2; a woman of 29 years, with Bartholinian abscess and several sinuses, one leading to the perineum. Abscess incised and patient discharged. Two weeks later, a mass of 1.5 cm. by 0.5 cm. was removed from the mouth of the perineal sinus. Examination showed adeno-carcinoma, its origin undoubtedly epidermal, of the sweat and sebaceous glands. Case 3; a recurrence of a fibrous osteitis following tooth extraction, with fracture of the alveolar process and incomplete removal of one of the fragments. Case 4; a rapidly recurring corn on small toe. Finally extirpated surgically. Ovoid in shape, 1.0 cm. by 0.5 cm. Papillomatous hypertrophy of skin, with ulcerations. Pathology: basal-cell epithelioma, originating either in epidermis or lining of sebaceous glands, or of hair follicles.

(*Ibidem*, Feb. 12, 1916, ciii, No. 7.)

RECENT DEVELOPMENTS IN THE TREATMENT OF LEPROSY. VICTOR G. HEISER, p, 289.

An excellent paper, showing the value of chaulmoogra oil in leprosy.

(*Ibidem*, Feb. 19, 1916, ciii, No. 8.)

AUTOLYSIN. S. P. BEEBE, p. 360.

The introduction is a counter-attack upon those who have attempted to discredit the method of the treatment with autolysin. The author denies any claims of cure, but states that a large majority of the patients are relieved of pain and odor, where such is present, as in ulcerating, inoperable cases. He has seen 2000 cases treated and has noted benefit of some degree in 80%. The formula and method of preparation of the extract are outlined. He makes a final appeal for fair-mindedness in judging a new method which holds out hope, comfort and relief, at least, in inoperable cancer cases.

PROCEEDINGS OF THE ROYAL SOCIETY OF MEDICINE, LONDON, DERMATOLOGICAL SECTION.

(January, 1916, ix, No. 3.)

Abstracted by Frederick T. Lau, M.D.

GRANULOMA ANNULARE WITH A WIDESPREAD FOLLICULAR ERUPTION. E. G. Graham Little, p. 35.

The author presented a case with typical lesions on the dorsum of each hand and on the knees. The case was worthy of more than passing interest, because the patient, who was in good health, also presented a follicular eruption on the thighs, legs, arms and forearms, which had been noted from early childhood. Exaggerated lichen pilaris and abortive acneiform tuberculide were suggested by the author, in describing the follicular eruptions, also its association with a possible tuberculous condition of the patient.

LICHEN PLANUS(?) E. G. Graham Little, p. 36.

A patient of delicate physique presented bluish, somewhat verrucose inflammatory patches on the forearms, back and scalp. On the dorsum of the right foot and plantar surface of both feet there was a granular, warty condition. An area of regressing lichen planus was found on the abdomen. A section of the condition, from the arm, showed a very extensive and uniform infiltration of mononuclear cells, just below the rete, interpapillary processes of which were flattened down by the pressure of the cells. The granular layer was not increased and there was little or no acanthosis. No foci of deep-seated infiltration nor giant cells were present. The Wassermann test was negative. The author will report later the result of further investigation and experimental inoculation of a guinea-pig with tissue from one of the lesions.

In the discussion of this case, the majority favored a tuberculous condition, preferably acute multiple lupus. It was conceded, however, that a few lesions upon the feet were suggestive of lichen planus.

CASE FOR DIAGNOSIS (TUBERCULOSIS)? W. Knowsley Sibley, p. 38.

Th patient, aged 27, had a negative family and past history, other than the death of his mother, of pulmonary tuberculosis, at the age of 42. The skin condition started eight years ago, with a lesion full of pus, on the knuckle of the left hand, which after a time healed and left a scar. The appearance of similar lesions on other parts of the body incapacitated him since, for a period covering at least six months every year. The lesions left circular, pigmented scars, about the size of a silver quarter, resembling vaccination marks, and were formed chiefly on the arms, forearms, palms, legs, especially about the knees, also the soles. A few minute, punctate, vesicular lesions were present on the dorsum of the hands. The mucous membranes had never been affected. Except for the loss of teeth, from caries, early in life, the patient appears to be a well-preserved man.

The Staphylococcus albus was isolated from one of the lesions. The Wassermann was negative and von Pirquet doubtful. The blood count and urine were negative.

Investigation revealed no history of bullæ. The healing of so many of these lesions without treatment and their circular and clean cut character, tended to discredit their tuberculous origin. The author excluded sporotrichosis and der-

matitis artefacta. There had been no affection of the nails or mucous membranes. The author did not make a biopsy.

In the discussion, the following diagnoses were suggested: angioneurosis, tuberculide, dermatitis artefacta, and persistent erythema, but the predominant opinion favored tuberculosis. The most helpful point in the presentation of this case was that tuberculous manifestations will, under certain conditions, heal spontaneously, without treatment.

SCLERODERMIA OCCURRING IN A CASE OF MYXŒDEMA WHILE UNDER THYROID TREATMENT. J. H. SEQUEIRA, p. 41.

In this case, the author showed a middle-aged woman, fifteen years ago, with typical myxœdema. After being continuously treated with thyroid extract, to toleration, the woman appeared to be normal, with the exception of patches of typical sclerodermia on the anterior surface of both legs. It was interesting to note that the patient developed a condition for which thyroid was strongly advocated as a remedy.

RECURRENT HERPES ZOSTER OF THE FACE WITH HEMIATROPHY. WILFRED TROTTER, p. 43. (Shown by Dr. A. M. H. Gray.)

The case was a girl, aged 11, with repeated attacks of herpes on the right side of the face, every two or three months, since infancy, with no local pain. Previous to the present attack, all lesions had been along the course of the second division of the fifth cranial nerve. In the attack presented, the lesions were distributed over the areas of the buccal and submental branches of the third division of the fifth nerve. There was very marked pitted scarring at the site of previous lesions and a marked atrophy of the cheek on the affected side.

With the exception of measles, chicken pox and scarlet fever, the child's past history was negative. There was a question, in this case, as to both ætiology and nomenclature.

Varied interesting suggestions and illustrations were given in the discussion, the general opinion seeming to be about evenly divided between recurrent zoster and herpes simplex, as the diagnosis. Inflammatory lesions in the region of the Gasserian ganglion and a peripheral pathological condition were the two most plausible theories as to ætiology.

MORPHEOSCLERODERMIA WITH RECENT ACUTE SYMMETRICAL INVOLVEMENT OF THE SOLES OF THE FEET. GEORGE PERNET, p. 46.

The patient, a girl aged 14, was first seen in July, 1914, when she presented a typical patch of sclerodermia on the outer side of the right thigh. This condition had progressed symmetrically.

On November 12th, 1915, the patient presented an acute symmetrical involvement of both soles. The condition was at first swollen and painful to the touch. This has disappeared and there remained a toughness of the parts with marked hyperidrosis. The concensus of opinion favored sclerodermia as the condition existing on the soles.

ACTINOMYCOSIS. W. K. SIBLEY, p. 48.

A typical case of actinomycosis was presented, with a lesion about the size of a walnut, in the right cheek. The ray fungus was demonstrated in the exuding pus. Large doses of potassium iodide and a strong solution of iodoform, in sterilized vaseline, used hypodermatically, were recommended in the discussion, as therapeutic measures.

THE JOURNAL OF
CUTANEOUS DISEASES

Vol. XXXIV JULY, 1916 No. 7

ORIGINAL COMMUNICATIONS.

A PECULIAR FORM OF POROKERATOSIS.

By Shin-Ichi Matsumoto, M.D., Kyôto,
Assistant Professor of Dermatology.
(From the Dermatological Clinic of the Imperial University of Kyôto, Japan.)

Case Report.

The patient, a man (H. Y.), aged 26 years, exhibited, on the palmar surface and both margins of the ring finger of the left hand, especially on the first and second phalanges, and on the palm at the base of this finger (see Fig. 1) a large number of minute, horny, conical elevations and slight depressions, showing comedo-like, horny plugs, which were very adherent and could not be easily squeezed out; when forcibly detached, they left a funnel-shaped depression. The smallest lesion was hardly visible, and the largest was almost the size of a small millet seed. Here and there were seen simply dilated sweat-pores. The lesions were here irregularly dispersed, standing apart, and they gave to the touch a slight, file-like sensation. The affected skin was of a faintly yellowish color, presenting uneven surfaces, occasionally somewhat sieve-like in appearance (horny hypertrophy). Almost the entire palmar surface of the ring finger was the seat of this peculiar, horny eruption, consisting of single papules more or less closely aggregated. Similar lesions were

observed on the ulnar side of the middle finger, on the first phalanx, and on the radial side of the little finger, involving the first and second phalanges to the extent of about thirty papules; but they were not so numerous nor so developed as those on the ring finger. The nails showed a normal condition. The dorsum of the hand was entirely free.

This abnormal condition began to appear at the age of 21, or earlier, perhaps, and had progressed ever since. The lesions were extremely slow in appearing and in growing.

The general health of the patient was always good. An examination of the thoracic and abdominal viscera revealed nothing of importance. The past history, previous to the development of the disease, was negative.

The family history revealed no cutaneous anomalies. The patient had been observed frequently for a half year, but no noteworthy change in the general appearance of the lesions had been perceived, excepting the occurrence of a few fresh eruptions, here and there. The patient, beside his cutaneous trouble, was afflicted with impotentia sexualis.

Histopathology.

Five small fragments (Nos. I-V) were excised for histopathological study and were cut serially, embedded in paraffine and stained in various ways. The microscopical changes were practically identical in all specimens, with one or two exceptions. To render our description clearer, we will describe separately the results obtained by our examination of those sections.

No. 1 (see Fig. 2). The fragment was excised from the radial side of the little finger and was fixed in Flemming's fluid. It exhibited two (see Fig. 2, A and B) small (almost of the size of a grain of poppy), round, horny elevations with a crateriform depression in the centre, where the minute, horny plug was to be seen. The section showed that the horny elevation was due to hyperkeratosis of the mouth of the sweat gland.

For the sake of brevity we will omit the details of the microscopical changes in the epidermis and demonstrate a number of serial sections of the specimen (Fig. 2 represents the changes in two affected sweat pores, A and B, in serial sections). Since the excision was made only superficially, the alterations of the sweat glands could not be pursued.

No. II (see Fig. 3; specimen excised from the fourth interdigital space).

The piece of tissue contained three horny excrescences which were grouped, slightly raised on the surface and filled with minute plugs.

The horny elevations showed, on section, a hyperkeratosis over the opening of the sweat duct and neighboring epidermis. The plugs, which were to be seen in the centre of the elevations, consisted of closely laminated, horny material, and evidences of remains of nuclei were seen in them (parakeratosis). In the neighborhood of the plug, there was hypertrophy of the epidermis, especially of the horny layer; and the papillæ were here usually somewhat elongated. Under the plug, in the mucous layer, the original shape of the intra-epidermic course of the sweat duct was still retained; it appeared to be compressed, obviously in consequence of the pressure of the compact horny plug. The sweat duct was not dilated in the region of the plugs, and around the ducts of the affected sweat glands there was a slight infiltration of lymphoid cells, which may perhaps have been due to the abnormal pressure of the horny plugs. The hyperkeratosis had not extended down into the dermal portion of the sweat duct. Marked changes did not occur in the corium. No pathological process was observed in the immediately closed sweat pores, except that the epidermal portion of the duct, on account of the hyperkeratosis, appeared somewhat elongated.

No. III (see Figs. 4 and 5). This specimen was excised from the radial side (near the palmar surface) of the little finger, which shows five (a to e) slightly raised lesions. It was fixed in formol.

Microscopically, these did not show anything markedly different from what has been already described, excepting that the hyperkeratosis was sometimes more marked. The neighboring epidermis showed, on section, a not very pronounced hyperkeratosis, but no parakeratosis; otherwise it was normal. The mucous layer, beneath the plugs, was compressed and much thinner than normal.

One of the affected pores appeared to present the simplest change in the disease. Histologically, the sections showed also a slight degree of hyperkeratosis of the horny layer around the sweat pore (see Fig. 5). The centre was depressed, and the intra-epidermal portion of the sweat duct was here still fairly well marked (Fig. 5). The duct and glandular portion of the sweat apparatus was not dilated, and the collection of cells in the region of the sweat pore was not evident.

Beneath the hyperkeratotic sweat pore and around the duct there were usually a few infiltrations consisting of lymphoid cells; the number of young connective tissue cells was greater than normal. Plasma cells and mast cells were not increased. The elastic tissue appeared to be normal in the sections examined. The sweat apparatus itself did not appear to be much disturbed. The sweat pores immediately surrounding the plug were free from the hyperkeratosic process.

In Nos. IV and V (the lesions were excised from the radial side of the little finger and were fixed in alcohol) similar changes were observed. The incisions were made only superficially. The epidermis presented appearances like those already described.

Clinical and Anatomical Résumé.

The initial lesions, the clinical characters of which we have already described, appear in the absolutely unaltered epidermis, remain isolated and show no tendency to increase in size, after a duration of five years. Where the excrescences are crowded together, they represent a sieve-like appearance. Diffuse hyperkeratosis is not present. There is neither wall nor peripheral "dike." There is no sign of an inflammatory area. No trace of an eczematous lesion is seen at any period. Atrophy is absent. The trouble began at the age of 21, or perhaps earlier; spontaneous cure has not taken place. The ætiology is obscure.

The microscopical appearances in this skin affection were constantly typical and characteristic. The external appearance of the minute elevations suggested the diagnosis of hyperkeratosis of the sweat pores, and a careful examination showed that the disease had undoubtedly commenced about the sweat pores. The process is, therefore, essentially a hyperplastic growth of the horny layer, combined with a modification of the cornifying process. With reference to the corium, this appears to be affected secondarily. In the new growth, there was a scarcely visible cell infiltration, and in the fully developed lesion was to be seen a slight infiltration of lymphoid cells, accompanied by dilatation of the blood vessels in the region of the plug. No marked changes in the sweat gland itself occurred. The process appeared isolated; in the adjacent sweat duct orifice, there was no noticeable hyperkeratosis. In short, the case represents a peculiar form of porokeratosis, in the strictly histopathological interpretation of the term.

Differential Diagnosis.

The entire pathological picture, together with the clinical findings, must be considered in order to arrive at the diagnosis. As before mentioned, the most striking change in the skin was a hyperkeratosis about the openings of the sweat ducts and there was no trace of eczematous lesions at any period. We know well that a histological porokeratosis is recognizable in a relatively large number of affections, particularly those forms of chronic inflammation which are accompanied by a mild

degree of hyperkeratosis; for example: lichen ruber planus and acuminatus, psoriasis, eczema, keratosis follicularis, Darier's disease, etc. Such affections and other keratoses, as ichthyosis and arsenical keratosis, can be easily excluded.

Pollitzer published, under the title, "Punkt-und strichförmige Defecte im Hornstratum der Palmæ und Plantæ," a peculiar condition of the palms and soles. The lesions had no hyperkeratosic character and they had nothing to do with the sweat ducts.

Brauer recently reported a peculiar form of hereditary keratoma of the palms and soles, which he had studied very carefully. We found that his cases somewhat resembled our own. They showed, however, no resemblance with regard to the histological findings.

The case of Colley can be differentiated by the absence of any changes in the sweat duct.

The cases of Vörner, reported as helodermia, differ radically from my case.

Samberger described an instance of keratosis of the palms and soles, appearing in a man at the age of 40, who was afflicted with tabes(?). No microscopical investigation, however, was carried on, in this case.

The keratodermia maculosa disseminata of Buschke and Fischer shows no resemblance to the lesions of porokeratosis and microscopically there is nothing to suggest that disease.

The microscopic appearances in our case are somewhat suggestive of porokeratosis Mibelli. The parakeratosis, the funnel-shaped dilatation of the sweat gland orifices and the cell infiltration are in favor of this diagnosis, but against it is the absence of a peripheral "wall," etc. Further, the lesions show no tendency to eccentric growth, which is so characteristic of so-called porokeratosis* of Mibelli. (The name "hyperkeratosis eccentrica" is more appropriate, at least from a clinical point of view, than porokeratosis.) The hyperkeratosis in our case, as above described, remains isolated and represents a porokeratosis in a strictly histological meaning of the term.

We are of opinion that this form should be separated and differen-

* I have had the good fortune to observe and to study, histologically, some examples (10 cases) of porokeratosis Mibelli and have found that the hyperkeratosis is not so limited to the sweat pore as in the present case. Porokeratosis of the palms and soles is observed only rarely. Hutchins reported, about 10 years ago, a case of the affection on the palm; and I have observed in a case of porokeratosis systematisatus (see Fig. 6) several plaques on the sole. The character of the disease on the palm or sole agreed perfectly with the clinical descriptions of Mibelli, Respighi, etc. We add the case simply for the purpose of comparison.

tiated from the so-called porokeratosis Mibelli. The clinical appearances, rather than the microscopical findings, appear to us to determine the classification.

Mantoux described a peculiar form of keratosis of the palm and sole with the title 'porokératose papillomateuse.'' It cannot, however, be demonstrated histologically, that the efflorescences have any special relation to orifices of the sweat ducts, although macroscopically this may appear to be the case. His case is characterized by the formation of papilloma-like lesions (angiokeratoma). The name ''porokératose'' does not therefore indicate the pathological alteration.

The case of Balzer and Germain presented a picture somewhat similar to that of porokeratosis, such as described by Mantoux. The microscopical examination, however, was not performed.

Beurmann and Gougerot demonstrated a case of hyperkeratosis of the palms and soles, in which the efflorescences progressed in a chronic manner. There was no microscopical examination. The relationship of the sweat duct to the hyperkeratosis was not therefore proved.

The case of Balzer and Boyé bore no resemblance to mine.

Besnier and Hallopeau observed a somewhat similar hyperkeratosis (nævus porokeratodes, Unna), where the orifices of the sweat duct play an important rôle. These forms, however, are all accompanied by diffuse hyperkeratosis and show a peripheral red halo. Without histological proof, I cannot recognize the relationship of sweat orifices to the hyperkeratosis. Nævus porokeratodes may perhaps be excluded from the absence of the red halo and diffuse hyperkeratosis.

Respighi (1894) described a case of hyperkeratosis and considered it to be identical with Besnier and Hollopeau's cases. Microscopical researches were made, and it was found that the keratosis was localized to the mouth of the sweat duct. Unfortunately, I was unable to obtain Respighi's original report. Without having read his article, I am not able to decide whether his case is exactly identical with mine. If that case is analogous to those of Besnier and Hallopeau, I think it shows a different appearance, at least clinically, from mine. It seems, also, to show a somewhat different histological picture. For comparisons of such minute changes, it would be necessary to have exact descriptions of the clinical appearances and histological structure of the lesions.

Mendez da Costa reported a case of nævus porokeratodes. The details are not described.

Fabry described a case of nævus unis lateris, in which the hyperkeratosis of the sweat pores was recognizable. He named the process nævus porokeratodes (Hallopeau-Claisse). His case showed an abnormal hyper-

Plate XLVII.—To Illustrate Article on A Peculiar Form of Porokeratosis, by Shin-Ichi Matsumoto, M.D.

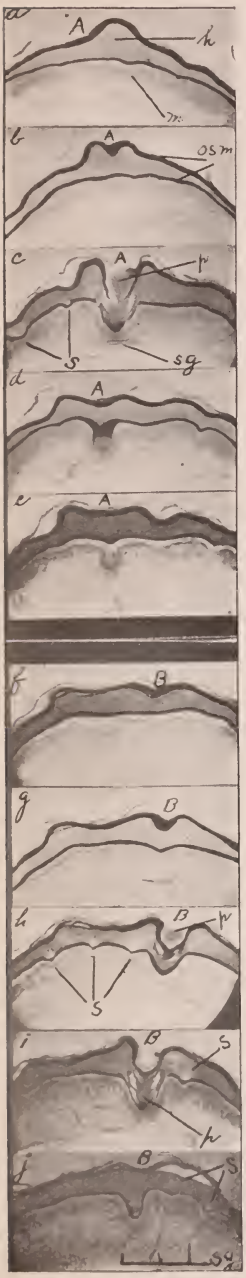

Fig. 2.

Fig. 1.

Fig. 3.

Fig. 4.

Fig. 5.

Fig. 6.

trophy of the coil-glands, accompanied by nævus cells, and was therefore not of the pure and simple type.

Résumé.

The hyperkeratosis begins in our case, definitely and absolutely, only in the orifices of the sweat glands.

The case is unquestionably to be distinguished, quite sharply, from porokeratosis Mibelli and the porokératose of the French authors.

Although the anatomical changes in Respighi's case suggest a relationship to mine, clinically it presents a different appearance, and I am not yet able to compare his case with mine, in a logical way. I am, however, inclined to consider the present case as a new, peculiar form of porokeratosis.

Explanation of Figures.

Fig. 1. Peculiar form of porokeratosis. Showing the peculiar lesion on the palmar surface.

Fig. 2. Fragment No. 1. Fixed in Flemming's solution. Represents the hyperkeratosis of the mouths (A and B) of two sweat glands in serial sections (a-j).

h: Horny layer.
m: Mucous layer.
s: Normal sweat orifice.
sg: Sweat duct.
p: Horny plug distending the orifice of the sweat duct. (Neighboring sweat pores are unaffected.)

The relationship of the hyperkeratosis to the sweat duct is well shown.

Fig. 3. Fragment No. II. Zeiss, Oc. 1, obj. AA. Demonstrates the large V-shaped opening of a sweat duct filled with the cone-shaped keratinous plug.
p: Horny plug. (Its diameter, 0.3 mm.; length, 0.9 mm.)
sg: Sweat duct.

Fig. 4. Fragment No. III. Zeiss, Oc. 1, obj. AA. Oblique section, showing the well-marked hyperkeratosis of a sweat duct opening.

p: It consists of concentric layers of flattened, horny cells, many of which still retained their nuclei.
s'g: is the intra-epidermal portion of the sweat duct.

Fig. 5. Fragment No. III. Zeiss, Oc. 1, obj. AA. Represents perhaps earliest stage of the lesion.

p: The centre has become depressed. The hyperkeratosis is only slightly marked.
s'g: Intra-epidermal portion of the sweat duct.
i: Collection of lymphoid cells (mild degree).

Fig. 6. Porokeratosis Mibelli (Hyperkeratosis eccentrica Respighii).

Typical plaques on the surface of the sole. Demonstrated for the purpose of comparison to the peculiar porokeratosis just described. (Compare Matsumoto: Zur Histologie d. sogen. "Porokeratosis" Mibelli, *Kyôto-Igaku-Zassi*, 1915, xii, No. 4.)

BIBLIOGRAPHY.

[1] BALZER AND BOYÉ. Kératodermie palmaire avec porokératose. *Bull. de la soc. fr. de dermat.*, 1909. p. 9.

[2] BALZER AND GERMAIN. Kératodermie avec porokératose en godets épidermiques localisés à l'ostium sudoripare et disseminés à la paume des mains. *Annal. d. dermat., et d. syph.*, 1905, p. 633.

[3] BESNIER. Uebersetzung d. Kaposischen "Hautkrankheiten", 1891.

[4] BESNIER. Kératodermie symmétrique des extrémités. Atlas Internat. d. maladies rares de la peau, ii, 1889.

[5] BETTMANN. Die Missbildungen der Haut, 1912.

[6] BEURMANN AND GOUGEROT. Porokératose papillomateuse palmaire et plantaire. *Annal. d. dermat., et d. syph.*, 1905, p. 629.

[7] BOECK. Internat. Congr., Wien., 1892. *Annal. d. dermat., et d. syph.*, 1892, p. 1035.

[8] BRAUN. Ueber eine besondere Form. d. hered. Keratoms (Keratoma dissipatum, hered. palmare et plantare). *Arch. f. Dermat. u. Syph.*, 1913, cxiv, p. 211.

[9] BUSCHKE AND FISCHER. Keratodermia maculosa disseminata symmetrica palmaris et plantaris. *Ikonographia Dermatologica*, 1910, p. 183.

[10] COLLEY. Disseminated Clavus of the Hands and Feet. *Trans. Pathol. Soc.*, Lond., 1879, xxx, p. 451 (cited by Vörner).

[11] DARIER. Grundriss der Dermatologie, 1913.

[12] DUBREUILH. Des hyperkératoses circonscrites. *Annal. d. dermat., et d. syph.*, 1896, p. 1158.

[13] EMERY, GASTOU AND NICOLAU. Cas de verrues famil. héréd. avec dyskérat. systémat. dissém. et à répétitions. *Annal. d. dermat., et d. syph.*, 1902, p. 1014.

[14] FABRY. Ueber einen seltenen Fall von Nævus unis lateris (Nævus porokeratodes). *Arch. f. Dermat., u. Syph.*, 1907, lxxxiii, p. 113.

[15] GASSMANN. Histologische u. klinische Untersuchungen über Ichthyosis, etc., 1904.

[16] GIOVANNINI. Ueber einen Fall von Ichthyosis mit Hypertrophie d. Schweissdrüsen. *Arch. f. Dermat. u. Syph.*, 1894, xxvii, p. 3.

[17] HALLOPEAU AND CLAISSE. Sur un cas de kératodermie palmaire et plantaire occupant les orifices sudoripares. *Annal. d. dermat., et d. syph.*, 1891, p. 221.

[18] HALLOPEAU. Sur une hyperkératose palmaire et plantaire localisée aux orifices sudoripares et sur le rôle des orifices glandaires dans les néoformations épidermiques. *Annal. d. dermat., et d. syph.*, 1895, p. 480.

[19] HUTCHINS. A Case of Porokeratosis (Mibelli). *Jour. Cutan. Dis.*, 1896, xiv, p. 373.

[20] LEWIN. Clavi syphilitici. *Arch. f. Dermat., et u. Syph.*, 1893. xxv, p. 3.

[21] MANTOUX. Porokératose papillomateuse palmaire et plantaire. *Annal. d. dermat., et d. syph.*, 1903. p. 15.

[22] MANTOUX. *Annal. d. dermat., et d. syph.* (see Brauer, p. 226).

[23] MATSUMOTO. Zur Histologie d. sogen. Porokeratosis (Mibelli). *Kyoto-Igaku-Zassi*, October, 1915, No. 4.

[24] MENDES DA COSTA. Nævus porokeratodes de la main. Vereenigung van nederland'sche Dermatologen. *Annal. d. dermat., et d. syph.*, 1899, p. 489.

[25] MIBELLI. Die Ætiologie u. die Varietäten der Keratosen. *Monatsch. f. prakt. Dermat.*, 1897, xxiv, p. 345.

[26] POLLITZER. Eine eigentüml. Karzinose d. Haut. Nebenher: Punkt. u. strichf. Defecte im Hornstratum d. Palmæ u. Plantæ. *Arch. f. Dermat. u. Syph.*, 1905, lxxvi, p. 333.

[27] RATTONE. Contribuzione allo studio della patologica chirurg. dei nervi. Tesi di aggregazione, Torino, 1882. (Cited by Mibelli. *Monatsch. f. prakt. Dermat.*, xvii, p. 446.)

[28] Respighi. Sulla transformabilità dei nei in tumori maligni. *Giorn. ital. d. mal. ven. e d. pelle*, 1894, No. 1; Ref., *Annal. d. dermat., et d. syph.*, 1895, p. 156.
[29] Samberger. Zur Pathologie d. Hyperkeratosen. *Arch. f. Dermat. u. Syph.*, 1905, lxxvii, p. 180.
[30] Unna. Histopathologie.
[31] Vörner. Helodermia simplex et annularis. *Arch. f. Dermat. u. Syph.*, 1911, cviii, p. 161.

POISONING BY CRUDE COAL TAR.

By Charles J. White, M.D., Boston.

(From the Skin Department of the Massachusetts General Hospital.)

For several years we have been making an ever-increasing use of crude coal tar in certain moist dermatoses, with only happy results to our patients and satisfaction to ourselves. At first we began by applying this substance in full strength, but soon learned that this was not a wise method, as many lesions were over-stimulated. We then reduced the strength of the medicament, and since then have employed the following formula:

℞	Crude coal tar	
	Zinc oxid.,	āā 2
	Amyl. maidis	
	Vaselin.,	āā 16
	S. Black paste.	

This paste has been applied twice daily under one layer of thin compress, until the moist lesion has dried up and disappeared; or until, as happens in a certain small proportion of the patients, papules begin to develop *in situ*. Then we stop, for we have learned by experience that these papules denote subsequent pustules.

We have become so wedded to this form of medication that it has become our routine practice, when confronted with almost every moist, non-pustular condition of the skin. Up to a few weeks ago we have never had cause to criticize unfavorably this procedure.

1. On January 10th, 1916, a man entered the Skin Ward of the Massachusetts General Hospital, on account of an eczema madidans of

the face, trunk and extremities. He was given crude coal tar in the proportion of 4:32; but two days later the strength of the tar was reduced to 1.30:32 because the skin seemed slightly irritated. On January 15th, the patient complained of some hoarseness. On the following day there was a temperature of 101.5° F., and a general itching, burning and irritation of both legs, together with œdema and purpura. The crude tar was stopped, but the severe cutaneous reaction and the naso-pharyngitis did not subside for a week or more.

2. On January 13th, a man was treated in the ward for a more or less generalized, moist eczema. Crude coal tar, 4:32, was applied in the morning, and that same evening severe headache developed, and repeated vomiting took place. There was, however, no unusual skin reaction.

On withdrawal of the crude coal tar, all pathological symptoms ceased rapidly.

3. At 10 A.M., January 13th, crude coal tar, 2:32, was applied to multiple, small, semi-moist lesions of dermatitis herpetiformis, on the back of a woman. During the day the patient noticed a slight headache and a tendency to nausea and had no desire to eat. About 6 P.M., a tingling, itching sensation developed on both arms, and a fine macular eruption appeared on the forearms, and spread rapidly to the shoulders. No more tar was applied.

On the following morning, January 14th, the patient's face was very pale and œdematous, and the skin of both arms was very tense and covered with fine, red macules. Curiously enough, there was no cutaneous reaction over the back where the tar had been applied. The pulse was 110 and the white count of the blood 12,000. That evening there was marked improvement in the general condition.

On January 15th, the œdema of the face was still somewhat in evidence, but the arms had regained their normal size. The patient was nauseated all day and vomited during the afternoon.

January 16th passed without incident, save that the patient desired no food and ate but little. White count, 10,400.

On January 17th, the œdema returned to the face and slight headache and general malaise persisted throughout the day, but toward evening the tide turned and the patient made an uneventful recovery. White count, 8,400.

The conjunction of these three extraordinary reactions to a drug which we had hitherto used with impunity and constant satisfaction, even on the youngest babies and over the largest surfaces, drove us at once to a consultation with the hospital apothecary, who said that he had

just received a new supply of the incriminated drug. On close questioning of the chemical company which provides the institution with its crude coal tar, the officials stated that the substance was brought to their factory from the gas houses in all sorts of receptacles, without any due regard to cleanliness, and that they supposed some contamination must have crept into the poisonous lot in this way.

It seems, therefore, that such untoward accidents are liable to happen when we physicians make use of crude products, but in the case of the present most useful, and, to our minds, almost indispensable drug, we can only confess that after the purchase of a fresh supply of the drug we returned to its daily use, and have experienced no further unfortunate results.

DIFFUSE PIGMENTATION OF THE SCROTUM IN LICHEN PLANUS.

By Douglass W. Montgomery, M.D., San Francisco.

Hyperchromia is one of the striking features in lichen planus. At first the lichen papules are a bright red, later to become violet, and when they disappear a mottled brown patch is left, often quite characteristic of the disease. I have never seen the florid, fresh papule pigmented. The pigmentation begins before the papule quite flattens out.[1] For instance, in a patch now under treatment by X-rays, one can see the brown pigmented border appearing as the papules fade away. In blondes with a light skin there is very little pigmentation, whereas in brunettes with a dark skin it is often pronounced. It frequently seems as if treatment with arsenic accentuates the pigmentation, but there is no doubt that it does appear when no arsenic is given, and this fact, together with its prominence in brunettes, shows it to be a natural cutaneous reaction.

Another curious feature is that papules in one region may leave deep brown patches, while in the same patient in other regions they may be as free of color as those of lichen nitidus, as in a case demonstrated by Dryer.[2]

La Mensa brought out a curious characteristic in reporting a case in which lentil-sized, irregularly bordered, blackish, bluish or slate gray spots would appear, around which would develop rings of lichen annularis[3]. In his case, therefore, the pigment preceded the appearance of the characteristic lichen papules.

As a further pigmentary anomaly, depigmentation may occur after

the disappearance of an eruption, and Kaposi considered that depigmentation, resulting from bleb formation occurring in the course of lichen planus, was an evidence that the blebs in question were a constituent part of the lichen eruption and not adventitious, as from arsenic. In an interesting case seen by Bettmann the papules were followed by hyperchromia, and the blebs by depigmentation[4].

The discoloration in the case, the subject of the present paper, was grayish-blue and was evenly diffused over the entire scrotum. It may or may not have been preceded by a papular eruption, but it certainly did not have the patchy distribution that usually is seen in the post-papular pigmentation in this disease.

Case Report.

A Japanese, thirty-two years of age, a stoker, consulted me July 9, 1914, on account of a generalized itchy eruption. He had resided eleven years in the United States, partly in Salt Lake City and partly in San Francisco and its neighborhood. As a child he had had measles. In 1905 he acquired a venereal sore, followed by a chill, but had no symptoms directly indicative of syphilis. Since the venereal sore, however, he had had occasional small sores on the penis that were evidently herpetic. Three years ago an itchy papular eruption began in the crotch, which was aggravated by the sweat while at work. At about the same time there appeared on the face a persistent eczema-like eruption.

The patient had the reddish, bronze. pigmented skin, resembling the skin of the North American Indian, that is so often seen in the Japanese. On his first visit the face was profoundly affected, which in itself is an unusual occurrence in lichen planus. In the front view it looked like a slightly reddened, papular, desquamating eczema with patches of deep brown pigment in the cheeks. The skin here was decidedly thickened. On the neck there were many flat-topped angular papules with the characteristic glitter, and there were some shiny ones over the upper part of the chest in front. There was a more characteristic papular eruption in the bends of the elbows, with some distinctive lichen papules on the anterior surface of the forearms, and on the inner surface of the thighs.

The patient had a marginal gingivitis, and there was a white patch, just behind the last left lower molar, that might have been lichen.

The patient ate a large quantity of sugar and candy, and he used to drink considerable alcohol. He took tea without sugar or cream about four times a day, and his diet was chiefly, as is usual with Japanese, of fish and rice.

The particularly interesting features of his skin were the scrotal condition, and some beautifully formed papules that remained on the right side of the base of the neck, after most of the eruption in other regions had cleared up. These papules were beautifully formed, and were arranged in little rows of three, six or eight individuals each. These rows were straight, but ran in different directions, and were quite artificial looking, as if put on for ornament.

The scrotum was thickened, rugous, and had a peculiar bluish-gray color, resembling exactly that of some clays. This gave the part a strangely artificial appearance. The slate-blue color gradually faded away coincidentally with the other cutaneous manifestations, but an almost reptilian glitter still persisted after five months of treatment.

The characteristic lesion of lichen planus is a papule of peculiar shape and color. It would be singular, however, if this were the sole manifestation of such a great disease. I believe this disease to be due to some one well-defined cause, that acts on the skin and mucous membranes, giving rise to symptoms, that however diverse, show a family resemblance to one another, in general as strong as the family resemblance of the cutaneous manifestations of syphilis. With Klingmüller, I also believe that among other symptoms, there are diffuse superficial infiltrations[5]. These infiltrations would necessarily have their favorite seat in the papillary layer of the skin, as is the nature of lichen planus; the same anatomical situation, in fact, as the circumscribed infiltration that we call the papule of lichen planus. These infiltrations would also probably bear the same relation to pigment formation as the papules do.

I, therefore, conclude that probably this Japanese had a diffuse lichen planus infiltration into the upper connective tissue layers of the scrotum that gave rise to hyperchromia and to increased activity of the stratum germinativum, causing active desquamation, but no appreciable thickening or papulation.

The situation of this manifestation on the scrotum, exposed as it was in the patient's occupation of a stoker to the irritation of the sweat, may have had something to do with its occurrence in this region and also with the intensity of its color. In fact, Sachs has demonstrated before the Vienna Dermatological Association, a case in which the sweat, by irritation, provoked on outburst in the genito-crural and axillary regions, and changed the characteristic color of the eruption[6]

REFERENCES.

[1] EHRMANN, S. Die Pigmentanomalien. Hautkrankheiten von Prof. Dr. F. Mraçek, 1905, ii, p. 766.

[2] Versammlung deutscher Naturforscher und Aerzte, Sept. 21, 1908; Report in *Dermat. Ztschr*, 1908, p. 700.

[3] LA MENSA, N. Ein Fall von Lichen planus annularis mit vorhergehenden Pigmentflecken bei einem Psoriatiker. *Arch. f. Dermat. u. Syph.*, Jan., 1911, p. 235.

[4] BETTMANN. Lichen ruber pemphigoides. Cited by Dr. F. Tann: Ueber das Auftreten von Blasen bei Lichen ruber planus. *Dermat. Ztschr.*, 1915, p. 403.

[5] KLINGMÜLLER, VIKTOR. Ueber Lichen ruber verrucosus vegetans. *Arch. f. Dermat. u. Syph.*, May, 1912, p. 526.

[6] Wiener Dermat. Gesellsch., Dec. 3, 1913; Report in *Dermat. Ztschr.*, 1914, p. 346.

AN INSTANCE OF VERRUCÆ PLANÆ JUVENILES COMPLICATED WITH LICHEN PLANUS.

By George D. Culver, M.D., San Francisco.

An association of ideas as to therapeutic possibilities in two widely different skin diseases, namely verrucæ planæ juveniles and lichen planus, was stimulated by the excellent results obtained by Dr. Charles J. White in the treatment of the former disease with protoiodide of mercury[1]. This association recalled the following case, which came under my observation about two years ago.

Case Report.

A married woman, twenty-two years of age, consulted me, Aug. 16, 1913, for an eruption on the face, including the upper eyelids, on the back of the neck and on the fingers, which appeared one year before. Each individual lesion was a verruca plana and there were hundreds of them present. They were removed by the following method:

After thorough soaking with hot boric-acid solution each lesion was curetted, as many as convenient being removed at one sitting. Again the hot boric-acid solution was applied until bleeding stopped, when each raw surface was touched with glacial acetic acid. This was followed with still another soaking, the face was then dried, and covered with a bland powder. The patient soaked her face once a day while healing was taking place, and applied a mild antiseptic salve after the soaking.

On Nov. 20, 1913, three months after the patient first came in, she telephoned that her face, which had been almost free from eruption for some time, had become covered with what she thought was a recurrence, by the hundreds, of verrucæ planæ, and this had occurred almost over night. On being advised to come in she did so, and when she removed a heavy veil, a most interesting picture was shown. Her face, neck and chest were covered with closely set, shiny, angular, intensely itchy papules with grouping on the neck and chin. Some of the papules were slightly pitted. Rare as is lichen planus of the face, it was as typical an instance as one could wish to see[2]. The patient had a coated tongue, the conjunctivæ were distinctly yellow and she was anæmic. She was given the following medication internally:

℞ Hydrarg. chloridi corrosiv..... 0.13
Aq. menth. pip., q. s., ad..... 120.00
M.
Sig. 4 cc. p. c., t. i. d., in water.

Also,

℞ Rhei pulv..... 0.13
Mag. carb.....
Ferri. carb. āā..... 0.65
M. et ft. pulv. tal. dos. No. XXX.
Sig. One powder p. c., t. i. d.

And externally:

℞ Acidi boric..... 2.00
Camphoræ 2.00
Ceræ albæ 3.50
Cetacei 4.00
Ol. amygdal 28.50
Aq. rosæ 14.00
M.
Sig. Local use, several times a day.

The lichen papules disappeared rapidly under this medication, and when next she called, three weeks later, there was no vestige of eruption remaining, nor has there ever been a recurrence either of warts or lichen papules.

The coexistence of lichen planus and verruca plana in the same case must be rare. I have found notes on only one instance[3].

It is because of the effectiveness of mercury, as shown by White in the treatment of verrucæ planæ juveniles and the similar effectiveness of the same drug in the treatment of lichen planus that the notes on this case are given. Whether or not all of the warts were gone before the lichen papules appeared, I cannot say, but as she had not been in for some time, and as she was a sensitive girl, it is probable that at any rate there were not many. If any remained until the lichen planus eruption appeared, they were masked by the papules of the latter affliction, and even had they disappeared coincident with the administration of mercury, it cannot be affirmed that the mercury caused their disappearance, for they might have cleared up with the subsidence of such an intense eruption as the lichen planus was. I have seen warts of a much more stable variety on the palms disappear, and had occasion to watch their disappearance from day to day, during two weeks' time, while an acute papulo-vesicular eczema was clearing up. Just a few weeks previous to the appearance of the eczema, my attention had been called to the warts, and they had not been treated in any manner whatever. The only treatment applied to the hands at any time was the later treatment for the eczema. The active congestion, caused in the first instance by an intense lichen planus and that in the second by as intense an eczema, were similar, and it is well known that one of the best aids to the removal of chronic sluggish skin affections is a conges-

tion, whether brought about by natural causes or by artificial means.

We are still left with the consideration of one of the main points of the paper, the mercury end of the question. How common it is to see a patient with an itchy eruption, which at first is not characteristic of lichen planus, but which later,—a few weeks, a month, or more,—shows positive characteristics of the disease! Treatment for eczema, which the early eruption may simulate, proves ineffective, and not until the diagnosis of lichen planus is established, and a definite line of treatment for the latter disease is laid down, does the patient improve. The radical change in the medication for the lichen planus is the addition of bichloride of mercury, which so frequently and so definitely seems to be the turning point toward improvement, that one must conclude it has near to a specific action.

The protoiodide of mercury would seem to have even a more definite specific action against verrucæ planæ juveniles, judging from White's experience, than has the bichloride against lichen planus papules. Is it the ion Hg. that does the work in both, and if it is the mercury element where the protoiodide is used, is it because it has an effect as a parasiticide upon some special microörganism that is the cause of the verrucæ?

There is undoubtedly a marked contrast, ætiologically, between the cutaneous lesions of verrucæ planæ juveniles and those of lichen planus, though in neither disease has the cause as yet been determined. While in the former all evidence points to a protozoön, as mentioned by White, as the cause, lichen papules are probably the result of a skin reaction stimulated by some internal derangement, most probably within the intestinal canal.

The hepatic disturbances so often accompanying lichen planus, the almost invariable presence of bile in the urine, and the gastric derangement point to the upper portion of the intestinal canal as being at fault. No doubt it is in this end of the canal that the bichloride has its greatest effect as an antiseptic and antifermentative.

A very interesting condition was presented by the subject of this article, which may give a clue to the good effect obtained by the medication. She had been on an exclusive vegetable diet for six months, and had recently become very nervous. She had an oily skin and oily hair with a bad odor, bromidrosis of the axillæ, a heavily coated tongue and a heavy, dark deposit on the teeth. Her stomach was dilated and atonic, as evidenced by marked splashing in the stomach region; the liver dulness was increased downward; and there was dulness in the left inguinal region, this last indicating incomplete alvine evacuations. The

functional derangements of the skin were apparently associated with, and probably dependent upon, the functional disturbances within the abdominal organs. Different forms of mercury often have excellent effects upon faulty intestinal fermentations, and in lichen planus the bichloride seems almost invariably to aid in producing a more normal intestinal status. I have never depended upon it alone, but as stated before, when added to other medication after having treated the patient for a time, either short or long, without it, the bichloride, in the dose of 1/24 to 1/16 of a grain, seems to be the necessary element to beneficially influence the disease.

This discussion cannot lead to an absolute conclusion as to how mercury acts in either disease, nor does any one know. It is an interesting fact that this metal, with its numerous salts, which has such an important place in the therapeutics of skin diseases, has been adapted to its numerous uses very largely through empiricism, and it seems destined to find new fields in the same manner. Would any of the other mercurial preparations have as good an effect upon verrucæ planæ juveniles as has the protoiodide been found to have in the few cases reported by Dr. White? His results were so convincing as to stimulate medication along that line, and, as the lesions are external, there should soon be definite results.

REFERENCES.

[1] WHITE, CHAS. J. *Jour. Cutan. Dis.*, Nov., 1915, p. 738.

[2] For instance, Ledermann, at a meeting of the Berliner Dermatologische Gesellschaft, Nov., 1913, mentioned how rare it is to have the face extensively implicated, even in generalized lichen planus. Report in *Arch. f. Dermat. u. Syph.*, Apr., 1914, p. 847.

[3] PAROUNAGIAN, M. B. Lichen Planus et Verruca Plana. *Jour. Cutan. Dis.*, November, 1908, p. 529.

MONILETHRIX.*

A Clinical and Histological Study, with a Report of Six Cases and a Review of the Literature.

By George M. MacKee, M.D., New York, and I. Rosen, M.D., New York.

(From the Department of Dermatology, College of Physicians and Surgeons, Columbia University.)

(*Continued from page 459.*)

Discussion of the Clinical Aspects, Based upon a Review of the Literature.

The characteristic feature of the hair in monilethrix is the peculiar beading, which, as has been pointed out by numerous observers, is an optical illusion. In other words, the so-called nodes represent the normal hair, while the constrictions are the abnormal parts. The numerous constrictions along the root and shaft of the hair cause an irregularity in contour and produce an appearance that may be likened to a string of beads. The affected hairs are short, lustreless and break very easily. It is on account of the fragility that the moniliform hair never attains a growth of more than a few fractions of an inch. The affected hairs are straight or curved and even acutely bent. They usually are a little lighter than the normal hairs, but as they contain, for the most part, normal pigment content, the loss of color is only apparent and is probably due to lack of lustre. The fractures always occur at a constriction and may be of various types. Under a lens one may observe incomplete and complete transverse lines of cleavage, with or without separation of the fragments. Very often, in fact usually, there is a distinct fraying out

* Read before the 40th Annual Meeting of the American Dermatological Association, Washington, D. C., May 13 to 15, 1916.

of the fibres at the site of fracture with the production of a paint-brush-like fracture very similar to, but not so conspicuous as, that of trichorrhexis nodosa. Green-stick fractures are also common. With a very few exceptions all the authors have observed the above-mentioned features.

If a moniliform hair is held against a light (viewed by transmitted light with or without a lens) the nodes are distinctly seen. They appear black, while the constrictions, in contrast, seem white. On the other hand, if the light is allowed to fall upon the hair (viewed by reflected light) the nodes are white and the internodes are black. As pointed out by Lesser, Karsch, Landois and others, this phenomenon is due to the presence of air in the nodes and more or less complete absence of the same in the constrictions. Lesser also emphasizes the fact that the inclusion of air is not necessarily a pathological condition.

While Francis and one or two other observers have noted normal hairs in cases of monilethrix, possessing a length of over 16 inches, it is generally agreed that, as a rule, the apparently normal hairs are coarser than they should be and especially that, in spite of the fact that they are not brittle, they do not attain a growth of more than two or three inches. In two of our cases the hair, while being short, was thick. There are several instances like this in the literature, but in most cases there is a pronounced alopecia. In most of the recorded examples of the disease the beaded hairs were not depigmented, although many observers mention the presence of some thin, colorless, more or less beaded hairs. In Abraham's case all the hair was short, broken and almost colorless.

With the exception of Hallopeau, Lèpinay, and Bering, there is no direct mention made in the literature of atrophy of the scalp, although several observers noticed that the scalp had the appearance so often seen after favus. In two of our cases there was a very distinct clinical atrophy and our pathological specimens showed a thinning of the epidermis between the follicles.

In one of our cases there was some scaliness of the scalp. Arndt noted an erythema in his case; Anderson reports a scaly, coarse scalp; Abraham calls attention to follicular inflammation with a few pustules; Bering, to inflamed follicles.

McCall Anderson.

Mr. L.—Mrs. L.



SABOURAUD.

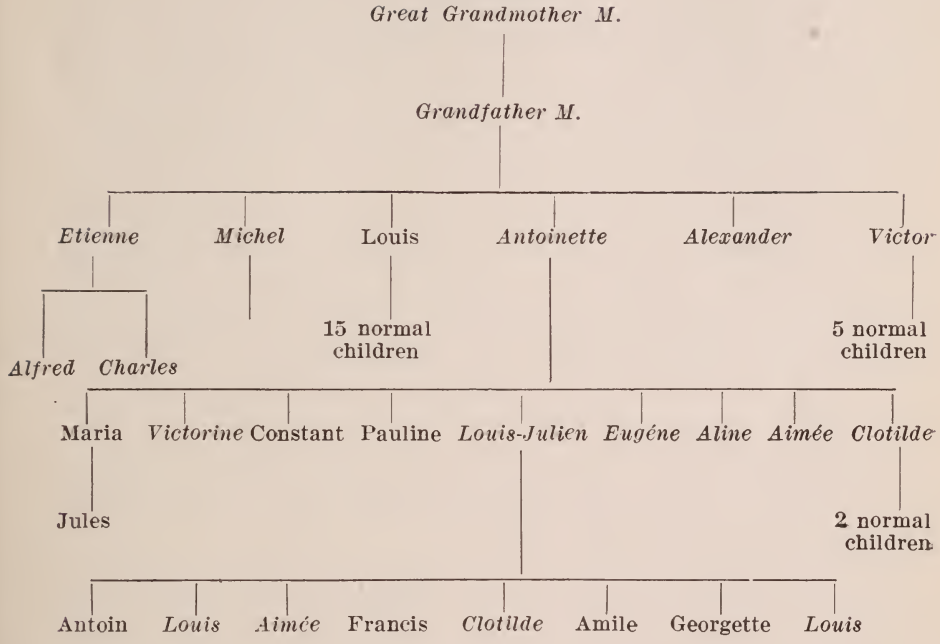

HALLOPEAU AND LÈPINAY.

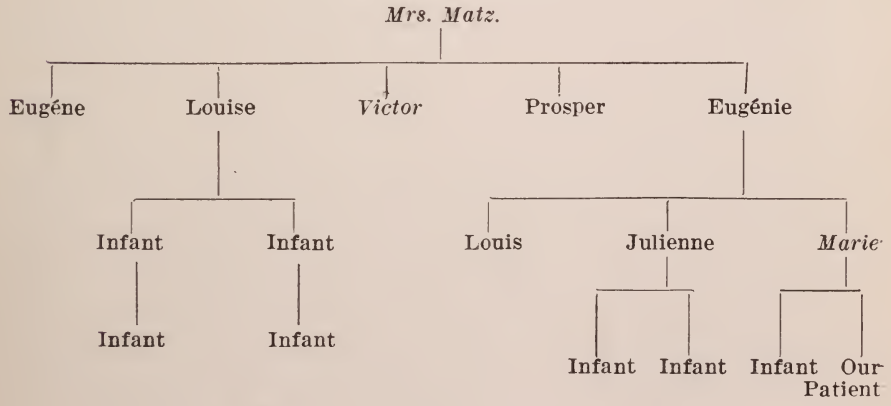

Keratosis pilaris of the whole scalp or of the frontal, temporal regions, occiput, or nape of the neck was noticed in nearly all the reported cases. In Francis' and Bering's cases there was no hyperkeratosis of the follicles, and in several instances no observation was made regarding this phenomenon. Mention is made of keratosis pilaris of the extremities in 11 cases, while this feature is not considered in most of the reports. Hallopeau and Lefèvre noted keratosis pilaris in the bearded region of a man, in the axillæ and on the extremities.

Scanty eyebrows were noted in 14 cases. In Ciarrocchi's case there were beaded hairs in this location. Hudelo noted beaded hairs in the eyelashes, Guszmann, Hallopeau and Lefèvre and Bering, in the axillæ. Hallopeau and Lefèvre found moniliform hairs in the bearded region of the face and they, together with Gilchrist, Ruggles, and Morrow, found the hairs of the lower extremities to be similarly affected. The mother of the patient reported by Hallopeau and Lèpinay presented brittle and broken hairs in the axillæ and pubic region. In one of Smith's cases there were beaded hairs on the genitals of a woman, while Bering noted them in the pubic region.

The affection was congenital in all of our cases and in 10 of the complete reports found in the literature. In 12 instances it began a few weeks after birth—ranging from 2 weeks to 6 months. Gilchrist's patient was 17 years of age when the condition began; Low's case, 9 months; Arndt's cases, in the first year; Smith's case, 15 years.

The 44 cases forming the basis of this discussion were under the personal observation of the various writers and were published in detail. We do not include the many cases reported by the patients as occurring in their families, nor the cases mentioned as having been seen by the various writers.

In 11 cases there was no other member of the same family affected; in 7 reports this important feature was not mentioned. In all other instances, however, a family tendency was definitely established. Beatty and Scott report 6 cases in 3 generations; Tenneson, 6 in 2 generations; Hudelo, 5 in 4 generations; Low, 9 in 4 generations; Hubschmann, 4 in 1 generation; Anderson, 14 in 5 generations; Sabouraud, and Jeanselme, 17 in 5 generations, etc. The family tendency is well illustrated in genealogical tables or family trees, a few of which appear herein. The italics represent monilethrix patients. The asterisks signify the patients seen by the observer.

In the 44 cases there were 20 males and 21 females—in 3 instances the sex was not given. In regard to nationality, 5 of the 46 cases were reported from Germany, 9 from France, 14 from England, 2 from Italy, 1 from Brazil and 10 from the United States. Of our cases, 2 were born in Russia; 4 were born here—1 of German, 1 of Russian, and 2 of Italian parents.

With a very few exceptions the patients were all normal physically and mentally and there were no subjective symptoms. Polland's case was feeble-minded and physically below the normal standard. This patient's brother also had monilethrix, but he was only slightly below the average physically and mentally. In Ciarrocchi's case there was a slight generalized ichthyosis. The general health in Thin's case was fair; in Payne's patient it was poor and the child had rickets. Lupus vulgaris was present in Low's case. The disease began after influenza and severe nervous shocks in a few instances.

Pathological Changes Observed by Other Authors, with Comparison and Discussion.

While almost all the authors who have reported cases of monilethrix have studied the diseased hairs microscopically, biopsies were made in only seven instances—Guszmann, Polland, Gilchrist, Beatty and Scott, Low, Ciarrocchi, and Bering. A brief review of these histological examinations follow:

Guszmann found the epidermis normal with the exception of an overdevelopment of the granular and corneus layers in the vicinity of the follicles. There were evidences of a moderate inflammation in the upper corium. The mouths of the hair follicles were widely dilated and filled with a horny plug, through which the hair pursued a spiral course. The follicle, generally speaking, was normal in its course—the external contour describing a uniform line. The inner border of the root sheath undulated in accordance with the thick and thin portions of the hair. The two layers of the internal root sheath and the cuticle of the follicle were blended together in a homogeneous mass. The inner sheath was thickened opposite the internodes and was often separated from the hair, while opposite the nodes it was about normal in thickness and in contact with the hair. Nodes and internodes were found in the follicular hair down to the bulb. At the lower end of the bulb everything was normal. At the upper end of the bulb, however, he encountered both normal coarseness and abnormal fineness of the hairs. Where an aplasic portion of hair developed out of the matrix, the cell elements of the inner root sheath formed a proportionately dense and extensive layer. A merging of several follicles into one large follicle containing several hairs was noted. There was a reduction in the number and size of the sebaceous glands.

Polland found the nodes in the follicular portion of the hair, hyperkeratinization of the follicular orifices and curled up masses of hair in these horny plugs.

CLINICAL

CASE.	AUTHOR.	DATE OF PUBLICATION.	AGE.	SEX.	NATIONALITY.	DATE OF INCEPTION.	RELATIVES.
1.	Smith	1878	15 yrs.	F.	English	15 yrs.	Normal
2.	Luce	1879	8½ yrs.	F.	French	Birth	?
3.	Smith and Liveing	1880	13 yrs.	F.	English	Birth	Normal
4.	Smith	1880	7 yrs.	M.	English	?	Normal
5.	Thin	1881	4 yrs.	?	English	6 mos.	2 in 2 generations
6.	Anderson	1883	3½ yrs.	M.	English	Birth	14 in 5 generations
7.	Bury	1883	8 yrs.	M.	English	Birth	?
8.	Lesser	1885	4½ yrs.	F.	German	Birth	Normal
9.	Payne	1886	2 yrs.	M.	English	4 mos.	2 in 1 generation
10.	Breda	1887	20 yrs.	M.	Italian	8 mos.	2 in 1 generation
11.	Hallopeau and Lefèvre	1890	Infant	F.	French	Birth	6 in 3 generations
12.	Archambault	1890	13 yrs.	M.	French	Birth	Normal
13.	Sabouraud	1892	?	F.	French	Birth	17 in 5 generations
14.	Abraham	1892	2 yrs.	F.	English	Birth	Normal
15.	Hudelo	1892	11½ yrs.	F.	French	2 mos.	5 in 4 generations
16.	Tenneson	1892	17 yrs.	M.	French	6 wks.	6 in 2 generations
17.	Beatty and Scott	1892	7 yrs.	M.	English	Birth	6 in 3 generations
18.	Francis	1894	17 yrs.	F.	English	6 wks.	Normal
19.	Jeanselme	1897	2½ yrs.	F.	French	Soon after birth	?
20.	Fox	1897	5 yrs.	F.	English	6 mos.	Normal
21.	Gilchrist	1898	Adult	M.	American	17 yrs.	Normal
22.	Morrow	1899	Adult	M.	American	In adult life	?
23.	Ciarrocchi	1900	2 yrs.	F.	Italian	Few weeks after birth	2 in 1 generation

CHART.

IDENTIFICATION.	GENERAL HEALTH.	NODOSE HAIRS.	KERATOSIS PILARIS.	ALOPECIA.
M.M.	Normal	Scalp Monsveneris		Scalp
S.	Normal	Scalp	Scalp Extremities	Scalp
?	Normal	Scalp		Scalp
F. W.	Normal	Scalp		Scalp
M. S.	Fair	Scalp Eyebrows	Scalp Extremities	Scalp
J. B.	?	Scalp	Scalp	Scalp
?	?	Scalp		Scalp
A. R.	Normal	Scalp	Scalp	Scalp
E. K.	?	Scalp	Scalp	Scalp. Eyebrows
S. A.	Epileptic	Scalp, Axillæ Pubes	?	Very little on scalp
?	?	Scalp	Scalp	Scalp
L.	Normal	Scalp	Scalp	Slight; scalp
M.	?	Scalp	?	?
G. N.	?	Scalp	?	Scalp
J. G.	Normal	Scalp	Scalp Extremities	Scalp. Eyebrows. Eyelashes
S.	Normal	Scalp	Scalp Extremities	Scalp Eyebrows
N. W.	?	Scalp	Scalp	Scalp Eyebrows
A. B.	?	Scalp	None	Scalp
L. M.	?	Scalp	Scalp Extremities	Scalp
B. C.	Normal	Scalp	Scalp	Scalp
Physician	Normal	Legs	Legs	?
?	Normal	Right leg		?
?	Normal	Scalp	Scalp Extremities	Scalp

CLINICAL.

CASE.	AUTHOR.	DATE OF PUBLICATION.	AGE.	SEX.	NATIONALITY.	DATE OF INCEPTION.	RELATIVES.
24.	Schutz	1900	3½ yrs.	M.	German	4 mos.	Normal.
25.	Ruggles	1900	36 yrs.	M.	American	?	?
26.	Bureau	1901	3 yrs.	M.	French	6th week	?
27.	Arndt	1904	4 yrs.	?	German	In first year	2 in 1 generation
28.	Guszmann	1904	16 yrs.	F.	Hungarian	Birth	Normal
29.	Bering	1905	5 yrs.	M.	German	Soon after birth	3 in 2 generations
30.	Hallopeau and Lèpinay	1906	6 yrs.	M.	French	Birth	6 in 5 generations
31.	Hübschmann	1906	10 yrs.	F.	German	3 mos.	4 in 1 generation
32.	Low	1909	11 yrs.	F.	English	9 mos.	9 in 4 generations
33.	Havas	1909	Child	?	Hungarian	1 yr.	2 in 2 generations
34.	Trillat	1910	3 mos.	M.	French	3 mos.	2 in 2 generations
35.	Dore	1910	Infant	M.	English	4 mos.	?
36.	Polland	1912	12 yrs.	M.	German	Birth	2 in 1 generation
37.	Savatard	1912	19 yrs.	M.	English	17 yrs.	?
38.	Juan de Azua	1914	Child	F.	Brazilian	2 yrs.	?
39.	Clark	1915	11½ yrs.	F.	American	Soon after birth	2 in 2 generations
40.	MacKee and Rosen	1916	32 yrs.	M.	American	Birth	3 in 2 generations
41.	MacKee and Rosen	1916	30 yrs.	M.	American	Birth	3 in 2 generations
42.	MacKee and Rosen	1916	8 yrs.	F.	American	Birth	3 in 2 generations
43.	MacKee and Rosen	1916	12 yrs.	F.	American	Birth	Normal
44.	MacKee and Rosen	1916	9 yrs.	F.	American	Birth	2 in 1 generation
45.	MacKee and Rosen	1916	10 mos.	F.	American	Birth	2 in 1 generation
46.	Kingsbury	1916	10 mos.	F.	American	5 days	2 in 3 generations

CHART.

IDENTIFICATION	GENERAL HEALTH.	NODOSE HAIRS.	KERATOSIS PILARIS.	ALOPECIA.
K.	Normal	Scalp	Scalp	Scalp. Eyebrows Eyelashes
Physician	Normal	Legs	Legs	
L. M.	Good	Scalp	Scalp	Scalp
?	Normal	Scalp	Scalp	Scalp. Eyebrows
J. P.	Normal	Scalp Axillæ	Scalp	Scalp. Eyebrows
H. F.	Normal	Scalp	Scalp Extremities	?
A. V.	Normal	Scalp	Scalp Extremities	Scalp. Eyebrows
E. G.	Normal	Scalp Eyebrows	Scalp Eyebrows Extremities	Scalp. Eyebrows
R. S.	Normal	Scalp	Scalp Extremities	Scalp
?	?	Scalp Eyebrows	None	?
?	?	Scalp	?	?
?	?	Scalp	Scalp	?
?	Defective physically and mentally	Scalp	Scalp, back Extremities	?
?	Normal	Scalp	Scalp	None
?	?	Scalp	Scalp	?
?	Normal	Scalp	Scalp Extremities	Scalp
J. W.	Normal	Scalp	Scalp Face	Scalp
S. W.	Normal	Scalp	Scalp	Scalp
L. W.	Normal	Scalp	Face Scalp	Scalp
H. B.	Slightly defective mentally	Scalp	Scalp	Scalp
J. P.	Normal	Scalp	Scalp Extremities	Scalp. Eyebrows
M. P.	Normal	Scalp	Scalp	Scalp. Eyebrows
E. P.	Normal	Scalp	Scalp	Scalp

There was no evidence of inflammation in the papillary body—the rete pegs were somewhat elongated. The external root sheath followed the swellings and constrictions of the hair. No alterations were found in the papilla or hair bulb.

Low found that the constrictions were present in the hairs from the very beginning of their growths. There were four or five nodes in each follicle. The first constriction was seen while the hair was still very cellular and it showed a green-stick fracture. The connective tissue around the follicle was normal. The layers of the root sheaths were all well developed. The outer border of the external root sheath was straight but its inner border showed a slight tortuosity which corresponded with the nodes and internodes. There was no abnormal proliferation of cells, but opposite the constricted part of the hair, the sheath was broader owing to the cells being more spread out. The inner root sheath was slightly sinuous, corresponding to the curves in the outline of the hair. It was normal in thickness throughout its extent. Henle's layer was normal. Huxley's layer was composed of cells with large oval nuclei and clear, somewhat hyaline-looking masses were seen with the oil-immersion lens inside the cells. The follicle was in contact with the thick portions of the hair, but opposite the internodes there was a separation, a space, which was bridged across by the very loosely arranged cells of the cuticles of the hair and root sheath. The sebaceous glands were small and few in number. There was a marked infiltration of small round cells and mast cells around the vessels in the corium. There was a pronounced dilatation of the mouths of the follicles which contained a horny plug. There was a cellular infiltration around these follicles similar to that in connection with the blood vessels. The elastica was rather poorly developed. The sweat glands were fairly well developed.

Gilchrist found that the epidermis between the follicles was thinner than normal. There was a marked hyperkeratosis in some of the follicular orifices. The fusiform swellings of the hairs were traced down to the lower fourth of the follicle and corresponding to these there were constrictions in the follicle. The sebaceous glands were underdeveloped or atrophied. In the part of the corium surounding the follicle there were large numbers of connective tissue and lymphoid cells, the latter being massed around the vessels. The hair papilla, the arrectores and the sweat glands were normal.

Beatty and Scott found the constrictions and fusiform swellings in the follicular hair down to the hair bulb. The fibrous coat and external root sheath of the follicle were normal. The external root sheath did not vary in thickness opposite the nodes and internodes. The internal root sheath was thickened opposite the internodes. The cuticle of the follicle was normal.

Bering. The collagen was poorly supplied with nuclei. The elastic tissue was considerably reduced. There was a round-celled infiltration around the vessels and the sebaceous glands; the latter were atrophic and their ducts were distended. The follicular orifices were completely closed by excessive keratinization. The hairs ran a very tortuous course through the upper part of the follicle. Nodose hairs were found deep in the follicle. Several hairs were noted in the same follicle.

Ciarrocchi found the follicle to be practically normal. It did not undulate with the nodes and constrictions. There were empty spaces at the constricted portions. He found dilated follicles, but no increase in the horny layer, which does not correspond with his clinical observation. Nodes were seen immediately above the hair bulb.

It will be seen from the foregoing that the findings of the various authors are much the same. There were signs of moderate or slight

inflammation in the corium in Guszmann's, Gilchrist's and our case. Low remarked a pronounced infiltration of round cells with many mast cells. There was no evidence of inflammation in Polland's case and Beatty and Scott made no observation in this respect, so it is to be assumed that there were no signs of inflammation in their specimens. Nevertheless the evidence would warrant the assumption that a slight low-grade inflammation is part of the pathology of the disease.

In Gilchrist's sections and in ours there was a distinct thinning of the epidermis between the follicles. Guszmann found the same increase in thickness of the granular layer near the follicles as was observed by us. The literature offers no confirmation for the acanthosis near the follicles in our case, but all the authors, excepting Ciarrocchi, noted a marked dilatation of the follicular orifices with a pronounced hyperkeratosis, giving rise to a horny plug.

Low, Guszmann, and Ciarrocchi found the external contour of the follicle to be normal, and while the other authors do not say so, yet one gains the impression from their descriptions and illustrations that they, too, considered the outer border of the follicle to be normal. In our case this external contour was exceedingly undulating, and suggested the possibility of a "buckling" on account of the increased size of the follicle due to the excessive keratinization.

With the exception of Beatty and Scott, Ciarrocchi, and Bering, all the observers noted a tortuosity of the inner margin of the external root sheath which was due to a loss of compression opposite the internodes, rather than to a proliferation of cells. The inner root sheath was found in all the cases to be thickened opposite the internodes. We were able to confirm Guszmann's observations regarding the blending of Huxley's and Henle's layers with the consequent production of a homogeneous membrane. A separation of the hair from the follicle at the internode was frequently noted.

With the exception of Guszmann, and Low, who detected minor changes in the lower part of the inner root sheath, none of the investigators was able to observe anything abnormal with the papilla, bulb or matrix.

All the histological examinations revealed nodes and constrictions in the follicular portion of the hair. In the sections examined by Guszmann, Low, Beatty and Scott, Ciarrocchi, and in our specimens, the aplasia was detected at the hair bulb.

Low, Guszmann, Luce, Lesser and Archambault found either a collection (heaping up) of nodes, or a coil of hair in the horny mass of the follicular orifice, an observation that we were able to confirm. Sev-

eral of the reports mention a twisting or rotation of the hair in the follicle. Low detected a fracture just above the bulb, as in our case. Most of the reports indicate a poor development of sebaceous glands, while the sweat glands were normal. In Low's and Bering's cases and in our sections the elastic tissue was slightly reduced.

A review of the literature in respect to the appearance of the moniliform hairs under the microscope would be monotonous and superfluous as the findings are almost identical. However, there are a few very complete investigations that merit special consideration.

Guszmann noted that the distance between the nodes was not always the same. In one hair possessing a length of 2 mm. there were 5 nodes, while in another hair 9 mm. in length there were 6 nodes. There were long, short, thick and slender nodes. The average coarseness of the normal hair of a woman of 22 years was found to be from 78 to 96 microns; the thickest nodes in Guszmann's case ranged from 90 to 95 microns. He found the average thickness of a pronounced internode to be from 25 to 30 microns, while the very thinnest portion was in proportion to the node as 1 to 5. The average length of the spindles was 0.77 mm. The nodes usually contained a medulla which pursued a spiral course and which frequently contained considerable air. Medullary substance was never found in the constrictions. The cortex was normal in the spindles but very much attenuated and even entirely wanting at times in the internodes, so that this portion of the hair was composed entirely of cuticle. The pigment was not in any way altered. It was always in proportion to the cortical substance. The cuticle was normal over the nodes and much thickened at the constrictions. The author observed paint-brush-like fractures, which always occurred at the internodes. Hairs showing a generalized aplasia with loss of pigment and various other transitional types were found.

The author tested the cohesion of both moniliform and healthy hairs. The normal hairs stood a weight of from 88 to 122 gm. Transitional hairs broke under an average weight of from 65.6 gm. to 75.5 gm. The uniformly aplasic hairs fractured under a strain of 30 gm. The cohesive qualities of the regularly spindle hairs were very variable. Some of them would break under a weight of only 8 gm.

Low observed thin hairs, without nodes and with loss of pigment. Other hairs appeared normal in areas and regularly or irregularly beaded in other parts. The typical hair possessed nodes at regular intervals. The medulla was usually but not always present in the nodes. The nodes were about the thickness of the normal hair. The internodes were about 1/4 the thickness of the nodes and showed a slightly thickened cuticle with a condensed cortex which was free of pigment. Various types of fracture, including the brush-like type, were seen. They always occurred at the internodes.

Schutz found air in the spindles. The nodes contained a medulla which described a zig-zag line. The constrictions possessed very little or no medulla and either no cortex or very little. There was no change in pigment excepting in the internodes that were composed of cuticle only—here, it was wanting. The fractures, always at an internode, were for the most part smooth—occasionally a brush-like break was noted. The diameters of the hairs were as follows: at the narrowest part of the spindle, 55 to 68 microns; at the thickest part of the spindle, 95 to 100 microns. The length of the nodes averaged 1/22 mm. and the length of the constrictions was about 1/3 that of a spindle. For the most part, the nodes were regularly distributed along the hair.

Behrend, who was one of the first to carefully study moniliform hairs, using hairs obtained from Smith for this purpose, observed hairs in various stages of aplasia. There was abundant pigment in the nodes, while this substance was much reduced in the constrictions. Air spaces were numerous in the spindles, but none was seen in the narrow portions. The author found that the number of nodes in many hairs corresponded to its length—a 10 mm. hair had 10 nodes; a 30 mm. hair, 30 nodes, etc. He found the diameter of some of the nodes to be greater than the normal hair of the same individual.

Lesser found the nodes at regular intervals along the course of a given hair. In comparing one hair with another, however, there was a difference in the distance between the spindles. This difference varied from 0.4 to 0.8 mm. The same variation was found in regard to the comparative diameter of the nodes and internodes. The diameter of the constrictions averaged 43 microns; of the nodes, 76 microns. The nodes were lighter in color than the internodes with reflected light and darker with transmitted light. This effect was due to the presence of air in the medulla of the nodes which could be released by the use of potassium hydrate. The author emphasizes the fact that the presence of air is not necessarily pathological. There was no change in pigment. The medulla ran a serpentine course. Occasionally there was some medullary substance in the constrictions but this either contained no air or very little. The cuticle was greatly thickened at the constrictions. Various types of fractures including the paint-brush variety, occurred at the internodes. In regard to cohesion, the author found that normal hair would stand a strain of 70 gm. before breaking, while the moniliform hair fractured under a weight of 42 gm.—a proportion of 10 to 6. The diameter of the nodes was 76 microns; that of the normal hair from the same individual was 74 microns.

Ætiology.

The ætiology has been well summed up by Low as follows:

"Unfortunately these microscopic findings do not give us much assistance as to the causation of the condition. Numerous theories have been brought forward to explain it. Heredity plays an important, but, as has been seen, not essential part. The association with keratosis pilaris, which is looked upon by Brocq and others as a localized manifestation of ichthyosis, also points in this direction. Payne blamed rickets in his case. Francis's case had gland and lung tuberculosis, and in this connection it is noteworthy that one of our cases (William S.) had a patch of lupus vulgaris on the back of his neck.

"The three chief theories may be summarized as the parasitic, the mechanical, and the tropho-neurotic.

"The parasitic theory has practically nothing to support it. The nodes on the hairs in trichorrhexis nodosa are admittedly due to the action of a bacterium, and in piedra and lepothrix to the accumulation of bacteria and fungi, respectively, but in monilethrix no one has ever found any signs of bacteria or fungi either on or in the hairs or in the follicles.

"The mechanical theory has been brought forward by several persons. Bonnet found, on examining microscopically the skin of horses during the casting of their coat, the young hairs coiled up upon themselves, showing spindle-like thickenings here and there. These he explained as due to a constriction at the level of the sebaceous gland, around which are numerous elastic and longitudinal and circular muscle fibres. These by their contraction cause a narrowing of the follicle, and the soft growing hair has difficulty in getting past this constriction and accumulates as a spindle-shaped mass below. This mass, when it reaches a certain size, is pushed up past the narrow area till it slips through, and, once through, the hair grows for a time as a very thin hair which readily becomes coiled up upon itself. Then the constriction, by contraction of the muscle fibres, becomes too great and another spindle is formed, and so on. In the case of monilethrix, however, the conditions are not similar. There is no constricted area of the follicle through which the hair must pass. There is no muscular tissue and only poorly developed elastic tissue around the areas where the constrictions are produced. Bering and others have tried to explain it by the presence of the keratosis pilaris at the orifice, blocking the outlet and causing the hair, which is being pushed up from below, to form spindles. Bering put a thin cylinder of wax in a glass syringe, and packed it fairly well round with sand to prevent bending, heated the syringe in a water-bath till the wax was pliable, and then pushed the piston of the syringe slowly in and found that the wax on cooling showed regular spindles. I have repeated this experiment, but failed to get the same results. The wax coiled up upon itself but never showed the least tendency to form spindles. An exactly similar coiling up of the hair, as is well known, occurs in keratosis pilaris, where the coiled-up hair lies in and just below the horny plug at the orifice of the follicle. To the keratosis of the follicle in monilethrix I attribute the coiling up of the hairs as reported by Archambault and others. Therefore the mechanical obstruction, at the outlet, while explaining the coiling up, does not explain the spindle formation.

"The tropho-neurotic theory is the one which seems, so far as our present knowledge goes, to be the most feasible. The alternate thick and thin part of the hair can be explained by assuming an alternate normal and abnormal activity of the cells of the hair bulb. This is the view expressed by Walter Smith, Virchow, Morris, and others. Why the cells should not proliferate regularly is difficult to explain. Thin puts it down to some congenital defect in their structure, but microscopically they look like the cells of normal hair bulbs. Unna locates

the fault in the cells which produce the medullary part of the hair, and thinks that they proliferate at regular intervals only. When they proliferate, a normally formed part of hair with a medullary canal is produced, but when they cease to proliferate for a time, a piece of hair is formed with only a cortex and no medulla, and this cortex becomes compressed together to form the constricted parts of the hair. He also suggests that some vasomotor change at regular intervals in the hair papilla might account for the intermittent growth. Beatty and Scott, Sabouraud and Breda think the intermittent growth is due to some abnormal nerve control of the hair bulb itself. In favor of this nervous theory are the facts that in Unna's case the condition began after a mental shock and in Breda's case, an epileptic, the formation of moniliform hairs coincided with the occurrence of fits. [Cases have occurred after influenza.] Behrend suggested that the thick parts of the hairs were the growth during the day, and the constrictions the growth during the night. Ciarrocchi found by shaving the head and watching the growth that a spindle and a constriction were formed in each 24 hours. It may be that the loss of nerve control during sleep is sufficient to cause a temporary cessation or diminished activity of growth in the cells of the hair bulb. [This does not take into account the fact that many hairs are irregularly beaded and some are uniformly atrophied.]"

Nosology. In text-books monilethrix is usually described under diseases of the hair or of the appendages. It is classified by many as a trophoneurosis. Apparently the disease is due to a congenital defect and it is associated with keratosis pilaris, an affection considered by many as being closely related to ichthyosis. In addition, at least one case of monilethrix has accompanied a mild, generalized ichthyosis. In this connection, Nicholas and Jambon, in their article on erythrodermie congenitale ichthyosiforme (*Ann. de dermat. et de syph.*, 1909, 4 ser., x, p. 481) place monilethrix in the same group with ichthyosis—as a distant relative. On account of the keratosis pilaris the disease might be placed under the congenital keratodermata, but the hyperkeratosis of the follicles is either secondary or it is a concomitant—it is probably not a causative factor. The disease might be grouped with the congenital dystrophies, but it is doubtful if it should be considered as ichthyosis or as a keratoderma, because the intermittent aplasia of the hair is the most important feature of the affection and the deciding factor in the diagnosis.

Differential Diagnosis.

Trichorrexis Nodosa. The hairs are beaded in the shaft only—not in the root or follicular portion. The nodes are produced by a splitting of the fibres with a very marked brush-like formation, therefore the fractures are always through the nodes. The diameter of the nodes is greater than that of the normal hair. The internodal portions consist of unaltered hair. The hair is not regularly beaded. The disease is due to a microörganism. It occurs most frequently in the hairs of the male face. It is not congenital nor hereditary. There is no keratosis pilaris nor alopecia.

Intermittent Grayness. (Nelson, Karsch, Landois; Ringed Hair, Lesser.) In this affection there are intermittent light and dark rings occurring in a hair that is not moniliform, or there may be a very slight bulging at the white part. There is no atrophy of the cortex. The white appearance is due to air in the medulla. The hairs are not brittle, do not fracture and are of normal length. It occurs on the scalp hairs of adults and is not, as a rule, hereditary. There is no alopecia, atrophy of the scalp nor keratosis pilaris.

Lepothrix. (Trichomycosis Nodosa.) This disease usually occurs in the axillæ and genital regions. In one type of the affection there are nodes along the shaft of the hair which consist of concretions ensheathing the shaft. At times the concretions may produce a fracture which may be clean-cut or brush-like, especially when they do not entirely surround the hair. The nodular masses are firm, gluey, red, reddish-brown or blackish in color and are firmly adherent. The nodes contain chains of spherical or elliptical micrococci. They penetrate into the ortex which becomes disorganized. A homogeneous substance, similar to chitin, by which the egg of the pediculus is cemented to the hair, forms the bulk of the concretion or node (Ormsby).

Piedra. This is a tropical disease with minute nodes scattered irregularly along the hair shaft. The nodes, as in lepothrix, are concretions on the hair, and may be due to microörganisms or to a mucilaginous dressing employed by the natives.

Nodes are found on the hair in various conditions—tinea nodosa (a concretion), trichonodosis (knotting hair), fragilitas crinium, etc. As a matter of fact, occasional nodes may be found in apparently normal hair.

Prognosis and Treatment.

Various local stimulating remedies have been tried without benefit. Ciarrocchi, Guszmann, and Low produced a temporary depilation with

the X-ray. Guszmann failed to notice improvement as a result of the treatment, while Ciarrocchi claims to have cured one case. Low noted a disappearance of the keratosis pilaris, and after the hair returned there seemed to be more normal hairs than before. The improvement,

Fig. 24.
Trichorrhexis nodosa (after Crocker).

Fig. 25.
Intermittent grayness (after Ziemssen). *a.* Transmitted light. *b.* Reflected light.



Fig. 27.
Lepothrix (after Darier).

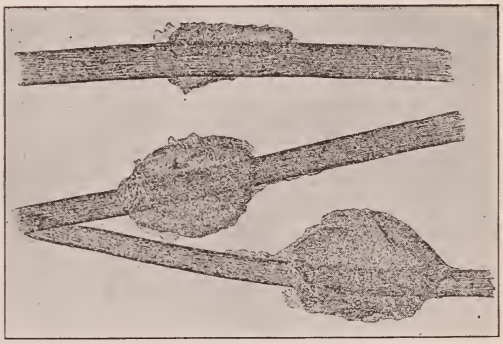

Fig. 28.
Piedra nostras (after Darier).

however, was not marked. Low also tried the static breeze and Clapp's cup without benefit. Several authors have noticed improvement as the individual grows older, but spontaneous recovery has never occurred. The disease, therefore, at the present moment, must be considered incurable.

Appendix.

We regret to say that we overlooked the fact that Dr. Goldenberg had previously presented our Cases 1 and 3 before the midyear clinical meeting of the Amercian Dermatological Association in 1910 (The Journal, 1911, xxix, p. 553) and also exhibited some hairs from our Case 2. Dr. Goldenberg should, therefore, be placed among Gilchrist, Ruggles, Bulkley, Morrow and Clark, as the first Americans to report cases of monilethrix. Goldenberg's report follows:

KERATOSIS FOLLICULARIS CAPITIS (Two cases, father and daughter). Presented by Dr. Goldenberg.

"The first patient (the father) was 31 years of age, the oldest of six children. His parents and two sisters were free from any disease of the scalp. Three brothers and two cousins had suffered from a similar disease. One of his four children also presented a condition of the scalp possessing the same characteristics. This child (the second patient presented) was a girl 2 years of age, who had suffered from the condition of the scalp since she was 5 weeks old. Both of the patients presented an eruption on the scalp and neck, the rest of the body being free. This consisted of a hyperkeratosis of the follicular openings, covered with small, horny, grayish-white cones and giving the impression of a nutmeg grater. The hairs had lost their lustre and were dry and broken off a short distance from their point of exit from the scalp. There were only a few hairs that were normal in length. The typical appearance of spindle hairs could not be detected. The patient, however, stated that such hairs had been found during his stay at a dermatological hospital in Vienna where a biopsy had been made. Dr. Goldenberg considered the affection to be a local ichthyosis pilaris and that the condition of the hairs, described as monilethrix, was secondary and due to the presence of the horny masses.

"In connection with the presentation of these two patients, a histological preparation from the scalp of one of the patient's brothers (the father's brother) was shown. This patient showed a similar follicular keratosis with changes in the hair, consisting of nodular thickenings, a condition described as aplasia pilorum moniliformis. The microscopical section showed horny, epithelial masses filling the follicles and occluding their openings. In one follicle there were four hairs spirally coiled upon themselves."

We desire to place on record another unrecorded case of monilethrix:

Case 7. E. P.; 10 months old. Referred to Dr. MacKee by Dr. Samuel Weiss on June 5, 1916. This patient was presented at the May, 1916, meeting of the New York Dermatological Society, by Jerome Kingsbury, under the title of monilethrix.

The family history was negative with the exception that the maternal grandmother had always had short hair.

The patient's hair was normal at birth. The hair fell out on the fifth day, and at this time it was noticed that the scalp was assuming the appearance of a nutmeg grater. Three or four weeks later the hair began to regrow, but this new hair was brittle and broke off close to the scalp.

When the infant came under observation, there was a very marked keratosis pilaris of the entire scalp. Most of the follicles contained coarse hairs which were broken off almost on a level with the scalp. There were no hairs more than one quarter of an inch in length. When the hairs were held against the light or against a white background, the beaded appearance was plainly seen, especially when viewed through a lens. The few hairs examined under the microscope showed the nodes to be evenly distributed along the shaft. One hair presented a well-formed medulla in the atrophic portion of the hair. This is an unusual occurrence.

Bibliography.

Abraham, Phineas S. A Case of Monilethrix. *Brit. Jour. Dermat.*, 1892, iv, p. 21.

Anderson, McCall. Diseases of the Skin, p. 56; and *Lancet*, July 28, 1883, ii, p. 140.

Archambault. Notes on a Case of Monilethrix. *Ann. de dermat. et de syph.*, 1890, i. ser. 3. p. 393.

Arndt. Aplasia pilorum moniliformis. *Dermat. Ztschr.*, 1904, xi, p. 530.

Arnozan. *Bull. de la soc. franc. de dermat. et de syph.*, 1890, p. 81.

Beatty and Scott. Moniliform Hairs. *Brit. Jour. Dermat.*, London, 1892, iv, p. 171.

Behrend, G. Nodose Formations of the Hair Shaft. *Berl. med. Geselsch.*, Feb. 18, 1885; *Deutsch. med. Wchnschr.*, 1885, xi, p. 139; Real-Encycloped. d. ges. Heilk., ix, p. 382; xiii, p. 655; *Virchow's Archiv*, 1886, ciii, p. 437; *Berl. klin. Wchnschr.*, xxii, 1885, p. 270; Naturf.-Ges. z. Wien. Verhdl., 1894.

Bering. Pili moniliformis. *Arch. f. Dermat. u. Syph.*, 1905, lxxv, p. 11.

Berthold. Observations on the Quantitative Relationship Between the Growth of Nails and Hair in Human Beings. *Müller's Archiv*, 1850, p. 156.

Breda. Pili moniliformi. *Riv. ven. d. sci. med.*, 1887, vii, p. 457.

Bulkley. Tr. Internat. Med. Congress, 1881.

Bury. Nodose Malformation of the Hair. *Brit. Med. Jour.*, March 3, 1883, i, p. 417.

Ciarocchi. Monilethrix. *Ann. de dermat. et de syph.*, Paris, 1900, i, p. 1028.

Clark, Schuyler. A Case of Monilethrix. *Jour. Cutan. Dis.*, Apr., 1915.

Crocker, Radcliffe. Diseases of Skin, 1903, ii, p. 1121.

DeAzua, Juan. Monilethrix. *Rev. clin. de Madrid*, 1914, xi, p. 214; *Actas dermosifilograficas*, Feb.-Mar., 1913.

Dore, S. E. Monilethrix in a Male Child of 16 Months. Proc. Roy. Soc. Med., 1910-11, iv-i, Dermat. Sect., 71.

Fox, Colcott. A Case of Monilethrix, *Brit. Jour. Dermat.*, 1897, ix, p. 31.

Francis. A Case of Monilethrix. *Brit. Jour. Dermat.*, 1894, vi, p. 363.

Galloway. *Brit. Jour. Dermat.*, 1896, viii, p. 437.

Gilchrist, T. Caspar. A Case of Monilethrix, with an Unusual Distribution. *Jour. Cutan. Dis.*, Apr., 1898, xvi, p. 157.

Goldenberg, H. Keratosis Follicularis Capitis (2 cases, father and daughter), case presentations. *Jour. Cutan. Dis.*, 1911, xxix, p. 553.

Guszmann, Josef. Clinical and Histological Study of Monilethrix (Aplasia pilorum intermittans), *Dermat. Ztschr.*, 1906, xiii, p. 33.

HALLOPEAU, M. Moniliform Aplasia of the Hair. *Ann. de dermat. et de syph.*, 1890, i, ser. 3, p. 129.

HALLOPEAU AND LEFÈVRE. Moniliform Aplasia of the Hair. *Ann. de dermat. et de syph.*, 1890, i, p. 427.

HALLOPEAU AND LÉPINAY. A New Case of Aplasia Moniliformis of the Hair. *Bull. soc. franc. de dermat. et de syph.*, Nov. 8, 1906, xvii, p. 436.

HAVAS, A. A Case of Monilethrix. *Pest med.-chirurg. Presse*, 1909, xlv, p. 37.

HÜBSCHMANN, CLARA. A Study of Aplasia Pilorum Intermittans (Monilethrix; Spindelhaare). Monograph, 1906, Conzett and Co., Zürich.

HUDELO. Familial Moniliform Aplasia of the Hair. *Ann. de dermat. et de syph.*, 1892, iii, ser. 3, p. 1144.

JEANSELME. A Variety of Hereditary and Familial Alopecia Produced by the Extension of Keratosis Pilaris to the Scalp. *Bull. et. mém. Soc. méd. d. hôp. de Paris*, 1915, ser. 3, xxxix, p. 385. Moniliform Aplasia of the Hair. *Ann. de dermat. et de syph.*, 1897, viii, ser. 3, p. 213.

KINGSBURY, JEROME. Case presented before the May, 1916, meeting of the N. Y. Dermat. Soc., to be published in *Jour. Cutan. Dis.*

LANDOIS, SIR LEONARD. Eramus Wilson's Case of Intermitting Grayness of the Hair of the Head. *Virchow's Archiv*, 1869, xlv, p. 113.

KARSCH AND LANDOIS. Ringed Formation in the Hair Shaft; Intermitting Grayness. Real-Encyclopedie der ges. Heilk., ix, p. 381.

LESSER. Ringed Hair. *Arch. f. Dermat. u. Syph.*, 1886, xviii, p. 50; *Vierteljahrschrift f. Dermat. u. Syph.*, 1885, xii, p. 655; *Monatsh. f. prakt. Dermat.*, 1885, iv, p. 304. Aplasia Pilorum Intermittens. *Arch. f. Dermat. u. Syph.*, xx, 1888, p. 1010. A Case of Moniliform Hair. *Berl. klin. Wchnschr.*, 1911, xlviii, p. 1484.

LIVEING. Tr. Internat. Congr. Med., London, 1881. See, also, Smith.

LOW, R. The Pathology and Ætiology of Monilethrix. *Jour. Pathol. and Bacteriol.*, 1909-10, xiv, p. 230.

LUCE. Researches Upon a Curious Case of Alopecia, Thèse de Paris, 1879, No. 579.

MAGELHAAS. A Case of Monilethrix. *Rev. med. de St. Paulo*, 1902, p. 7.

MICHELSON, PAUL. Ziemssen's Handbook of Diseases of the Skin, p. 435.

MORROW, P. A. A Case for Diagnosis. *Jour. Cutan. Dis.*, 1899, xvii, p. 41.

PAYNE. Hairs Showing a Remarkable Nodose Condition. Trans. Path. Soc. Lond., xxxvii, 1886.

POLLAND, R. Aplasia Pilorum Moniliformis. *Arch. f. Dermat. u. Syph.*, 1912, cxi, p. 827.

RUGGLES. *Jour. Cutan. Dis.*, 1900, xviii, p. 500.

SABOURAUD, R. Moniliform Hair. *Ann. de dermat. et de syph.*, 1892, iii, ser. 3, p. 781.

SAVATARD. A Case of Monilethrix. *Brit. Jour. Dermat.*, 1912, xxiv, p. 319.

SCHÜTZ, JOSEPH. A Case of Spindle Hair. *Arch. f. Dermat. u. Syph.*, 1900, liii, p. 69.

SMITH, WALTER G. On a Rare Nodose Condition of the Hair. *Brit. Med. Jour.*, 1879, ii, p. 291; May 1, 1880, i, p. 654.

SUTTON, R. L. Keratosis Pilaris of the Scalp. *Am. Jour. Med. Sci.*, Mar., 1915, cxlix, p. 424.

TENNESON. Keratosis Pilaris and Aplasia Moniliformis of the Hair. *Ann. de dermat. et de syph.*, 1892, iii, ser. 3, p. 1146.

THIN. A Case of Congenital Abnormality in the Hair Production on the Scalp. Trans. Internat. Med. Cong., 1881, iii, p. 190.

TRILLAT. A Case of Moniliform Aplasia of the Hair. *Lyon méd.*, 1910, cxv, p. 708.

UNNA. Histopathology of the Skin, p. 1058; Tr. Internat. Med. Congress, 1887.
VIRCHOW. *Deutsch. med. Wchnschr*, 1885, xi, p. 140.
WILSON. On a Remarkable Alteration of Appearance and Structure of the Human Hair. Proc. Roy. Soc. London, 1866-1867, xv, p. 406.
ZIEMSSEN. Handbook of Diseases of the Skin, p. 401.

We desire to thank Prof. John A. Fordyce for placing the facilities of the Department of Dermatology at our disposal. We are indebted to Dr. E. C. Jagle for help in studying the pathological specimens. We also express our appreciation for help and advice received from Dr. Wise, Dr. Satenstein, Dr. Freeman and other members of the Staff of the Department.

SPECIAL ARTICLES.

HISTOPATHOLOGY.

(*Continued from May number, page 376.*)

By Walter J. Heimann, M.D., New York.

(From the Departments of Dermatology and Pathology, Cornell Medical School.)

Chapter V.

The Lichens: Lichen Planus.

Perhaps there is no more difficult group of diseases in dermatology to analyze clinically and histogenetically than that of the lichens and allied dermatoses. From the time that Willan introduced the term into dermatological literature, until 1889, when the identity of lichen ruber acuminatus and pityriasis rubra pilaris was established, the concept was vague. Without attempting to review each advance leading to the restrictions with which we to-day employ the expression, the important steps will require brief, chronologic emphasis. The scientific contest in question involved three generations of dermatologists and was laid in England, France and Austria, the standard-bearers having been Willan, Bateman, Wilson, Devergie, Hebra and Kaposi. To a lesser extent, too, the names of Vidal and von Zumbusch must be included, while Brocq finally divested the discussion of many of its complexities, clarifying, arranging and analyzing; discarding what was foreign and adopting what appeared pertinent, with that rare appreciation of values, and that painstaking philosophy so characteristic of the Parisian master's Gallic imagination.

Willan[1] described five types of lichen,—lichen simplex, agrius, pilaris, lividus and tropicus, while Bateman[2] added lichen urticatus. Brocq[3] pointed out that Willan's lichen simplex corresponded to what Vidal later called lichen simplex acutus; lichen agrius, to Unna's lichen acuminatus neuroticus; lichen pilaris, to Brocq's perifollicular sebor-

rhœa; lichen lividus, to purpura; lichen tropicus, to prickly heat, and lichen urticatus, to mild prurigo. Rayer[4] omitted lichen tropicus from his classification, included lichen urticatus and added lichen circumscriptus. His description of lichen agrius corresponded to the disease subsequently removed from this group by Hebra and called prurigo ferox. Lichen simplex corresponded to prurigo mitis, and lichen circumscriptus to what Vidal subsequently termed lichen chronicus circumscriptus.

Thus it will be seen that not a single one of the diseases originally designated as lichens to-day retains this characterization. Brocq[3] has pointed out with what vagueness the term had been applied, indicating clearly how differently from the Viennese school it was considered by the schools of England and France. The latter applied the designation to diseases partly papular, but also associated with patches of thickening of the integument; and the former to dermatoses which remained papular from onset to end. Hebra and Kaposi maintained that a lichen never became vesicular or pustular, and this criterion has become the standard. Thus, the only true representative of this class to-day is lichen planus and its varieties. Vidal,[5] nevertheless, in 1886, and again at the International Congress held in Paris in 1889, endeavored to revise and re-adapt the ancient order of things, and return the chronic urticarias and eczemas to their pristine group. He failed, but stimulated Brocq, in a series of articles from 1890 to 1896, to study the question critically. This bore more than mere polemic fruit, for the entire class of infiltrating eczemas was finally separated from the lichens, the theory of lichenification (Brocq) was formulated, and the important doctrine of cutaneous reactions postulated.

In the mean time the dispute about Wilson's lichen planus, Devergie's pityriasis rubra pilaris and Hebra's lichen ruber had been fought out during the two decades from 1869 to 1889, the French having sullenly retired to Paris in the firm belief that pityriasis rubra pilaris was the better term; the Teutons triumphantly to Vienna, cherishing similar illusions regarding lichen acuminatus. Both agreed as to the identity of the diseases, but no more ludicrous example of chauvinism in science has ever been presented than was, and in some quarters still is, revealed in this little comedy, rendered the more ridiculous because, if the designations vie with each other at all, it is in inaptness.

The index of any extensive work on dermatology includes the following lichens: lichen acuminatus, circumscriptus, nitidus, pilaris, planus and its varieties, ruber, scrofulosorum, simplex, spinulosus, syphiliticus, tropicus, urticatus, and that process known as lichenification. Lichen

acuminatus is not a lichen, but is essentially a folliculitis with hyperkeratosis; lichen nitidus is clinically a lichen and microscopically resembles tuberculosis; lichen pilaris is a pure hyperkeratosis, possibly in the ichthyosis group; lichen scrofulosorum is a tuberculide; lichen simplex is a primary lichenification; lichen spinulosus is an exaggerated lichen pilaris; lichen syphiliticus is a syphiloderm; lichen tropicus represents a sweat duct occlusion; lichen urticatus is a papular urticaria; and lichenification is a consecutive lesion developing, as Brocq has proven, in connection with numerous itching diseases. Lichen planus is the only true lichen. It is proposed for practical purposes to classify these dermatoses as follows:

I. True Lichen.
   1. Lichen planus (Wilson).
   2. The varieties of lichen planus.
   3. Lichen ruber acuminatus of Hebra, or Pityriasis rubra pilaris of Devergie. (This is included out of respect for tradition.)

II. False Lichens.
   1. Follicular.
      (*a*) Lichen pilaris (Bazin), also called ichthyosis anserina and keratosis pilaris simplex. This is widely considered a form of ichthyosis.
      (*b*) Folliculitis rubra (Wilson), related to Unna's ulerythema ophryogenes; an atrophying hyperkeratosis, in some respects suggesting lupus erythematosus.
      (*c*) Lichen nitidus, possibly tuberculous.
      a follicular hyperkeratosis, but evidently not ichthyotic. Possibly it bears a remote relationship to Darier's disease.
   2. Sweat duct lichen or lichen tropicus. This is a red miliaria caused by a cyst of the duct, and absolutely no lichen in the remotest sense of the word.
   3. Toxic lichen.
      (*a*) Lichen agrius—Hebra's prurigo.
      (*b*) Lichen urticatus—chronic urticaria in children, common prurigo infantum, strophulus.
   4. Specific lichen.
      (*a*) Lichen syphiliticus.
      (*b*) Lichen scrofulosorum.
      (*c*) Lichen nitidus, possibly tuberculous.

III. Lichenification.
   1. Primary: Lichen simplex chronicus of Vidal or neurodermitis (Brocq).
   2. Secondary; Lichenification (Brocq) or lichenization of Bésnier, found in itching dermatoses.

In the present chapter will be discussed lichen planus and its varieties. Lichen acuminatus, which is here included among the true lichens, as already stated in deference to the past, and also because there is no

more logical place to include it, will be described in the next chapter in connection with the first group of false lichens, namely, the follicular. Lichenification and the neurodermites will constitute the third chapter of the lichens. Lichen tropicus belongs to the dysidrosis group, lichen urticatus to the urticarias and prurigos, lichen syphiliticus, scrofulosorum and lichen nitidus to the chapters dealing with syphilis and tuberculosis.

Lichen planus was described in 1868 by Wilson, and in the same year Hebra described lichen ruber, noting two types of lesions, one of which was a flat papule and the other a conical one. The majority of cases consisted entirely of either type of papule alone, but occasionally a mixture of both was seen. Pityriasis rubra pilaris had already been described by Devergie (1857). At the International Congress in Paris, in 1889, and in Vienna, in 1892, it was finally recognized by Kaposi that Devergie's disease corresponded with Hebra's acuminate lichen, and incidentally the identity of the latter's lichen ruber planus and Wilson's lichen planus was established. Since this time many varieties of lichen planus have been recognized, as the ensuing table will show.

I. Lichen planus (Wilson).
II. Hypertrophic forms:
  1. Lichen planus hypertrophicus (Vidal and Leloir).
  2. Lichen planus verrucosus.
  3. Lichen planus obtusus (Unna).
III. Atrophic forms:
  1. Lichen planus sclerosus et atrophicus (Hallopeau).
  2. Lichen planus morphœicus (Crocker).
  3. Lichen albus (von Zumbusch).
  These are probably identical.
IV. Lichen pemphigoides.
V. Forms varying as to distribution, arrangement and in anatomic respects:
  1. Lichen of the mucous membranes.
  2. Lichen annularis.
  3. Lichen ruber moniliformis (Kaposi).
  4. Lichen striatus or linearis.
  5. Lichen planus erythematosus.

Lichen Planus (Wilson).

The Developing Papule. The microscopic changes in the ordinary form of lichen planus are characteristic and uniform, and the numerous writers upon the subject are in virtual accord in their descriptions. It is both in the epiderm and papillary body that the distinguishing features of the process are found, and to a lesser degree in the lower cutis also.

In the epiderm, hyperkeratosis, an increase in the thickness of the granular layer, relative thinning of the rete, broadening without lengthening of the pegs (Figs. 2, 3, 7, 8), and colloid degeneration of some Malpighian cells are noted.

Unna[6] particularly emphasizes that the broadening of the pegs may cause them to coalesce, forming a wide band of epiderm. Favera[7] points out both an interstitial and parenchymatous œdema. Engman[8] mentions swelling (Fig. 8) of the prickle cells. The stratum granulosum is found thickened (Figs. 2, 3, 7, 8) by all authors, and all find an extensive hyperkeratosis except Kaposi,[9] who mentions parakeratosis, an observation in which he stands alone. Civatte, in an unpublished paper quoted by Brocq,[3] states that the stratum lucidum is present and intact. Many authors speak of colloid degeneration of some of the Malpighian cells. Among these are Unna,[6] Biesiadecki, quoted by Kaposi,[9] Bruck,[10] Darier,[11] and Fordyce.[12] The basal layer varies. It is intact in places and destroyed, or at least distorted, elsewhere. Favera[7] finds but few mitoses in the germinative layer.

Between the epidermis and infiltrated papillary body, peculiar spaces or lacunæ are found. All writers have observed them and the explanation of their origin is varied. In connection with this phenomenon, another peculiarity of the lesion must be discussed. The typical papule is characterized by a central depression, dell or umbilication, the origin of which has been ascribed to the lacuna. Let the latter be discussed first. It is obvious that a space may develop in but a few ways; first, through destruction of tissue; secondly through a disparity in the contiguous surfaces of two juxtaposed tissues, causing the more redundant to leave its anchorage; thirdly, by the accumulation of fluid at a given point. In lichen planus the first and third of these views have been advanced. As already mentioned, the basal layer (Figs. 3, 8) is often found destroyed, particularly over the lacunæ, so that some justification exists for regarding its loss as, at least, the first stage of lacuna formation. Civatte[3] is of this opinion. He states that since the basal layer adheres to the papillary body by fine threads, a destruction of these fibrils causes the space to develop. Destruction of the upper portion of the infiltration and the connective tissue containing it, might produce the same result, as pointed out by Caspary (Joseph[13]). Joseph's own explanation corresponds with Civatte's, with the qualification, however, that the rupture of the threads is due to an accumulation of fluid and that the space is actually a congestive vesicle. He bases this assumption on the presence of fibrin and a few leucocytes in the space. and supports his view by referring to lichen pemphigoides. Fordyce[12] endorses this idea. Unna[2] thinks the lacunæ indicate a colloid degeneration, but he has found no support in this theory. Hebra considers it a phenomenon of involution, and some authors think that arsenical therapy is responsible, since arsenic in capable of causing bullous dermatoses. This idea is mentioned only to be dismissed, for there is no reason to believe that everyone suffering with lichen is intolerant of arsenic. As a matter of fact, lacunæ are present in patients before arsenic has been given.

Although speculation of this sort is unprofitable, the author cannot refrain from pointing out that both explanations are partly correct, but that they depend upon the second factor mentioned, a disparity between the epidermis, which becomes redundant (Fig. 1) and the papillary body which, because of the dense infiltration, remains rigid. Thus, the epithelium would tend to be raised from its base, and at such points the solution in continuity would be marked by the formation of spaces or rifts (Fig. 1). In addition to this, since an œdema exists, fluid would tend to accumulate in the lacunæ, the epithelial threads binding the two tissues together would stretch and then rupture (Figs. 1, 8), and the basal cells would disintegrate, partly because of intercellular œdema, partly because of inflammation and partly because of the pressure of fluid. The size of the spaces would depend primarily upon the degree of inequality between the epiderm and papillary body, and secondarily upon the

amount of fluid accumulated. The extreme of this process is found in the pemphigoid variety (Fig. 14). The lacunæ usually make a flaccid impression, and this would hardly be likely if their origin depended upon fluid excess, but would be wholly compatible with the explanation just offered.

The dell or depression has been accounted for in quite as many ways as the lacuna. Jarisch[14] quotes Joseph, who thinks the condition is caused by the sagging of the epidermis into the subjacent lacuna, during involution; Crocker and Robinson, who believe that the centre of the papule is fixed by a hair so that it is unable to rise as high as the margin; and Boeck, who states that the stratum corneum increases at the expense of the rete, the surface thus becoming cupped. Fordyce,[12] in addition to the views mentioned, adds those of Rona, who ascribes the dell formation to a lifting of the epiderm in some parts and smoothing in others, or to acutal atrophy of the papillæ; and Crocker, who emphasizes his idea of hair fixation by stating that the thickened epidermis folds on itself, causing the hyperkeratotic wedge to fall out and leave a funnel-shaped depression. Fordyce accepts the last theory.

Here, too, the field is largely speculative, but it is striking that no umbilication is found in the pemphigoid form in which the lacuna is tense. At the same time it is impossible to escape the conviction that the presence of the dell and lacuna have some common bearing. When a drumhead slackens, it sags centrally, remaining (Fig. 2) fixed at the rim. This is substantially what occurs in a lichen papule. The excessive epidermis overlying the basin of the lacuna, is capable either of projecting, if the basin is sufficiently full; or of collapsing, if the basin is not; the point of fixation being the ring of normal or acanthotic epiderm, forming the margin of the lesion. In the former case, as in lichen pemphigoides, a lenticular elevation is created; in the latter, a concave depression, varying in size with the degree of disparity between the epiderm and derma, and the depth of the lacuna. Even though Crocker's and Fordyce's views as to the falling out of the scale may be correct, they do not explain why the epidermis sinks in the first place. The loss of the plug would obviously exaggerate the umbilication, but could not account for it. The essential feature of the process is the folding, the only sound mechanical explanation of which seems to the author to be the one he advances, and which is substantially implied in the views of Rona and Joseph.

Concerning the changes found in the derma, the site and composition of the infiltration, views are practically unanimous. Thus it will be unnecessary to quote the various writers in detail. The papillary body, to an extent involving from ten to twenty papillæ, is infiltrated, œdematous, and the blood and lymph vessels are slightly dilated. The infiltration is limited below by a fairly sharp (Figs. 1, 2, 3, 7), horizontal boundary, lying just above the subpapillary vessels. These vessels and a few of the lower ones are encased in an infiltration two or three rows of cells broad. Thus, the picture exhibits two elements: a more or less solid deposit of cells in the involved papillæ, and vessels cut longitudinally or transversely, scabbarded in an infiltration similar to that in the papillary body. These infiltrations consist entirely of round cells. Unna[6] describes round cells of an undetermined type, probably not leucocytes. They have large nuclei and very little cytoplasm. Favera[7] says that there are two varieties; the first of which, found among the collagen fibers and in the lymphatics, have a large nucleus and a somewhat irregular outline: the second of which resemble either mononuclears or small lymphocytes. Similar cells are present in the epiderm. Mast and plasma cells are usually absent, although Fordyce[12] mentions that he has seen them in lichen. Bruck[10] says that the infiltration consists prevailingly of lymphocytes with a few polymorphonuclear leucocytes.

In addition to these changes, Bruck[10] mentions the presence of colloid masses within the infiltration, as do Darier[11] and Fordyce.[12] Other authors also note this and all agree that the elastic tissue is normal, that there is slight, if any, disturbance of the collagen, and that there is distention of the coil ducts forming minute cysts. A great deal has been written dealing with the question of whether the onset of the process is in the epidermis or corium. Since all cutaneous lesions must begin in either of these layers, and since the very earliest lichen papules studied show changes in both areas at one and the same time, a discussion of this point seems useless if not, indeed, absurd. Until we definitely understand the pathogenesis of lichen, it will be impossible to settle its point of origin.

During the stage of disappearance (Fig. 10) the lichen papule presents a variety of phenomena in a multitude of combinations. In one, the granular layer is normal, in another the corneous layer; again, the rete may retain its usual dimensions, or the pegs begin to reappear. The infiltration and the vascular dilatation diminishes. One feature, however, is practically constant, an increase in melanin (Fig. 10) due to an increase in the number of chromatophores, both in the papillary body and germinative layer.

The different groups of lichen planus may be arranged as follows, according to whether their clinical differences are due to accidents of arrangement, distribution, or distinctive microscopic structure.

I. Accidents of Arrangement.
   1. Lichen annularis.
   2. Lichen striatus or linearis.
   3. Lichen ruber moniliformis.

II. Accidents of Distribution.
   1. Lichen of the skin (already described).
   2. Lichen of the mucous membranes.

III. Accidents of Microscopic Structure.
   1. Hypertrophic forms; lichen hypertrophicus, verrucosus and obtusus.
   2. Atrophic forms; lichen sclerosus, morphœicus and albus.
   3. Exudative forms; lichen pemphigoides.
   4. Congestive forms; lichen planus erythematosus.

Lichen Annularis may be formed in two ways, either by the arrangement of lichen papules in a ring (Fig. 4, B), or by the central involution and peripheral advance (Fig. 4, A) of a single papule. The first is by far the more frequent. The margin presents the changes seen in the papule, as already described. Lichen striatus or linearis is formed by papules grouping themselves into lines or striæ. The microscopic anatomy of such lesions, too, corresponds to that of the papule. It must be remembered, however, that atrophic, hypertrophic or pemphigoid lichen may be found in rings or straight lines, also, and their structure

will be that of these varieties of lesions. Lichen moniliformis is an arrangement of papules in a row, resembling a necklace. Its microscopic picture will depend upon that of the type of papule entering into the grouping. Large patches and plaques of lichen are simply the sum (Fig. 5) of papules, and this is reflected in their minute structure. Lichen of the mucous membrane is histologically no different from the ordinary lichen of the skin, as Favera[7] has shown.

In hypertrophic lichen there is simply more (Fig. 12) acanthosis; in verrucous lichen, acanthosis associated with hypertrophy of the papules; in lichen obtusus also more acanthosis; and according to Unna, more marked cystic changes in the sweat ducts than are found in the simple papules, which they otherwise closely simulate. In lichen pemphigoides (Fig. 14) the lacuna is inordinately developed, and in lichen erythematosus there is more dilatation and engorgement of the blood vessels than in the common papule from which it does not otherwise differ.

Lichen Atrophicus (Figs. 6, 9, 13), however, merits special consideration, since it presents distinctive points of real significance, and because of its clinical resemblance to macular scleroderma and Unna's "cardboard" variety of circumscribed scleroderma. Vignolo-Lutati[15] examined a fresh papule, a fully developed papule and an atrophied area, excised from a patient suffering from lichen albus. In the first he finds a destruction of the Malpighian cells due to œdema, the columnar layer is destroyed for the same reason, and pigment is absent. The derma is œdematous and the site of a round celled infiltration. The fully developed papule microscopically resembles the ordinary variety, but is more œdematous. The atrophic area shows thickening of the epiderm, hyperkeratosis, absence of elastica, some residual features of the lichen papule and some of an atrophodermia. He quotes Hoffmann's discussion of a case presented at the Tenth International Congress. The stratum corneum is thick, the papillæ absent, rete thin, lacunæ are present, the collagen is sclerosed, and the elastica absent in the papillary layer. Below this is an infiltration. Csillag[16] and Hoffmann[17] find substantially the same changes. Lutati's case was one of lichen albus, Csillag's of lichen atrophicus, Hoffmann's of lichen sclerosus. Microscopically they were identical. Darier's classical description is too well known to require emphasis. He describes three zones in the lesion; first, an atrophic area corresponding to the papillary body, below this a band of infiltration such as is seen in the lichen papule, sharply demarcated by a horizontal inferior margin, and still further down, the type of infiltration about the vessels seen in the subpapillary areas in common lichen.

The first impression imparted by the microscopic view of a lichen papule, as seen under low magnification, is one of a lesion characterized by a confluence of changes in the epiderm and papillary body. The abnormal area is limited by a horizontal line above, two more or less vertical boundaries laterally, and a nicely demarcated horizontal margin below. The total breadth of the lesion corresponds to between ten and twenty papillæ. About half way down the lesion and set in its midst, horizontal rifts may be perceived, either of a breadth just sufficient to allow clear light to shine through, or so wide as to make them appear as veritable clefts. Below the inferior limit of the lesion, bands may be seen, consisting of dilated spaces surrounded by deeply stained cells in an otherwise normal cutis.

An analysis of the lesion under higher power brings out the various distinctive elements which compose it. The epidermis is not actually one with the infiltration below, but separated from it by the rifts, known as lacunæ, and where these are present the basal layer is destroyed (Fig. 3). The epidermis shows characteristic changes. It appears as a thickened band in spite of the fact that either no pegs are seen; or if present, that they are in a stage of partial absorption. The rete itself is thin (Figs. 3, 7, 8) and its upper layers flattened and granular, so that its cells closely simulate those of a fully matured stratum granulosum. The latter is from three to ten (Figs. 3, 7, 8) layers deep, intensely stained, and surmounted by a scale (Figs. 2, 3, 7, 8) of varying depth, consisting of hyperkeratotic cells. At times the corneal and granular layers are separated by a well marked stratum lucidum. The upper surface of the papule bends (Figs. 2, 3, 10) at its centre. At this point the rete is thinnest. The entire epidermis presents intracellular (Fig. 8) œdema, but some Malpighian cells are swollen, some are dyskeratotic and others show a colloid-like degeneration, while wandering leucocytes are seen all over and mitoses are few and far between.

The lacunæ below the epidermis are usually empty, but occasionally fibrinous strands and a few leucocytes (Fig. 8) are found in this space. The infiltration (Figs. 1, 2, 3, 7), which is partly surmounted by lacunæ and partly by adjacent epiderm, is sharply defined, below, by a horizontal (Figs. 1, 2, 3, 7) termination, corresponding to the level of the subpapillary vessels. Thus it is found in the papillary area, but the papillæ are gone. The infiltration consists of round cells and fibroblasts in a proportion of between five or ten to one, and the former are small lymphocytes and nothing else. Plasma and mast cells are wanting, or, if present, are so few in number as to be devoid of significance. Occasionally, also, in the midst of the infiltration, swollen collagen

fibrils, dilated and engorged vessels, and sometimes colloid bodies are found. The band-like figures (Fig. 3) below the infiltration are vessels cut longitudinally and surrounded by sleeves of cells of the type noted in the main infiltrations, and two or three rows deep. When the vessels are transected they appear as circular spaces (Figs. 7, 10) with a concentric envelope of infiltrating cells. The sweat ducts are often dilated. When follicles are included in the area of a papule, a follicular hyperkeratosis is seen, and the changes in and about the follicle are analogous to those found in and below the flat areas.

Nothing need be added to what has already been said of involuting, annular, striated, moniliform, pemphigoid, obtuse and mucous papules, as their points of departure from the common type have been adequately noted. Hypertrophic and verrucous lichen are distinguished solely by the fact that the pegs and papillæ survive, the former becoming acanthotic, the latter almost papillomatous. Otherwise the changes seen, conform to the usual type.

Atrophic Lichen presents two fields for study, the advancing margin and the atrophying internal area. The margin (Figs. 6, 9) corresponds microscopically to the usual picture, but seems to contain a great many more follicular plugs than ordinarily observed. The atrophying areas show a thin epiderm, flat, without pegs, and a narrow (Figs. 9, 13) stratum corneum. The germinative layer is present. Where the papillæ were a band of sclerotic collagen without elastic tissue is seen, and below this a narrow layer of infiltration, such as is found in the common papule. Still lower down, the vessels show the usual changes.

The main points, then, may be summed up as follows:

The Simple Papule:

1. Hyperkeratosis.
2. Increase in the stratum granulosum.
3. Decrease in the rete, intercellular œdema and the presence of wandering cells.
4. Destruction or distortion of the germinative layer and a few mitoses.
5. Lacunæ and dells.
6. Infiltration consisting prevailingly of lymphocytes in the papillary body.
7. Horizontal limitation below, of the infiltration.
8. Infiltration about dermal vessels.
9. Cystic dilatation of the sweat ducts.

Hypertrophic Lichen:

1. Acanthosis of the pegs.
2. Hypertrophy of the papillæ.
3. Otherwise like the simple papule.

Atrophic Lichen:

(*a*) Advancing margin: typical papule.
(*b*) Atrophying area showing:
1. Atrophy of the epiderm.
2. Sclerosis of the papillary body with destruction of elastica.
3. Zone of infiltration below this.
4. Still lower zone of vascular dilatation and perivascular infiltration.

The differential diagnosis of the lichen papule must be considered with reference to psoriasis, seborrhœa, parapsoriasis and neurodermitis. If the characteristic features of lichen planus be borne in mind, confusion is almost impossible. In psoriasis the presence of Munro's abscesses, the elongated pegs and less dense infiltration; in seborrhœa, the epidermal vesicles and *alteration cavitaire,* fat distribution, atrophy of the hairs and less dense infiltration; in parapsoriasis, the parakeratosis, elongated pegs, very thin rete, mild infiltration and presence of mast cells, are further significant features. In the chapter on lichenification and neurodermitis, their differences from lichen planus will be considered. Lichen atrophicus and its various forms must be differentiated from morphœa, white spot disease and Unna's "cardboard" variety of circumscribed scleroderma. Until these lesions have been described, however, it will be unprofitable to take up these questions.

References.

[1] Willan. On Cutaneous Diseases. London, 1808, p. 36.

[2] Bateman. A Practical Synopsis of Cutaneous Diseases, According to Willan. London, 1819, p. 90.

[3] Brocq. Les lichens. Prat. dermat. Paris, 1902, iii, p. 119.

[4] Rayer. Traité théorique et prat. des mal. d.l. peau. Paris, 1835, ii, pp. 51 and 52.

[5] Vidal. Du lichen. *Ann. de. dermat. et de syph.*, 1886, p. 133.

[6] Unna. Histopath. d. Hautkr. Berlin, 1894, p. 308.

[7] Favera. Beitr. zur Histol. d. Papel des Lichen planus. *Monatschr. f. prakt. Dermat.*, xlviii, No. 7, p. 293.

[8] Engman. Annular Lichen Planus. *Jour. Cutan. Dis.*, 1901, p. 209.

[9] Kaposi. Hautkrankheiten. Vienna, 1899, p. 476.

[10] Bruck. Ueber Hyperkeratosis striata et follicularis u. Lichen ruber atrophicus. *Arch. f. Dermat. u. Syph.*, cvi, p. 91.

[11] Darier. Précis d. dermat. Paris, 1909, p. 118.

[12] Fordyce. The Lichen Group of Diseases. *Jour. Cutan. Dis.*, February, 1909.

[13] Joseph. Hautkrankheiten. Leipzig, 1898, p. 87.

[14] Jarisch. Die Hautkrankheiten. Wien u. Leipzig, 1908, p. 621.

[15] Vignolo-Lutati. Ueber die sogenannte Lichen albus von Zumbusch. *Dermat. Wchnschr.*, liv, No. 23, p. 661.

[16] Csillag. Lichen chronicus atrophicus. *Ikon. Dermat.*, 1909, iv, p. 147.

[17] Hoffmann. Lichen sclerosus. *Ikon. Dermat.*, 1909, iv, p. 152.

To Illustrate Article on Pathology, by Walter J. Heimann, M.D.

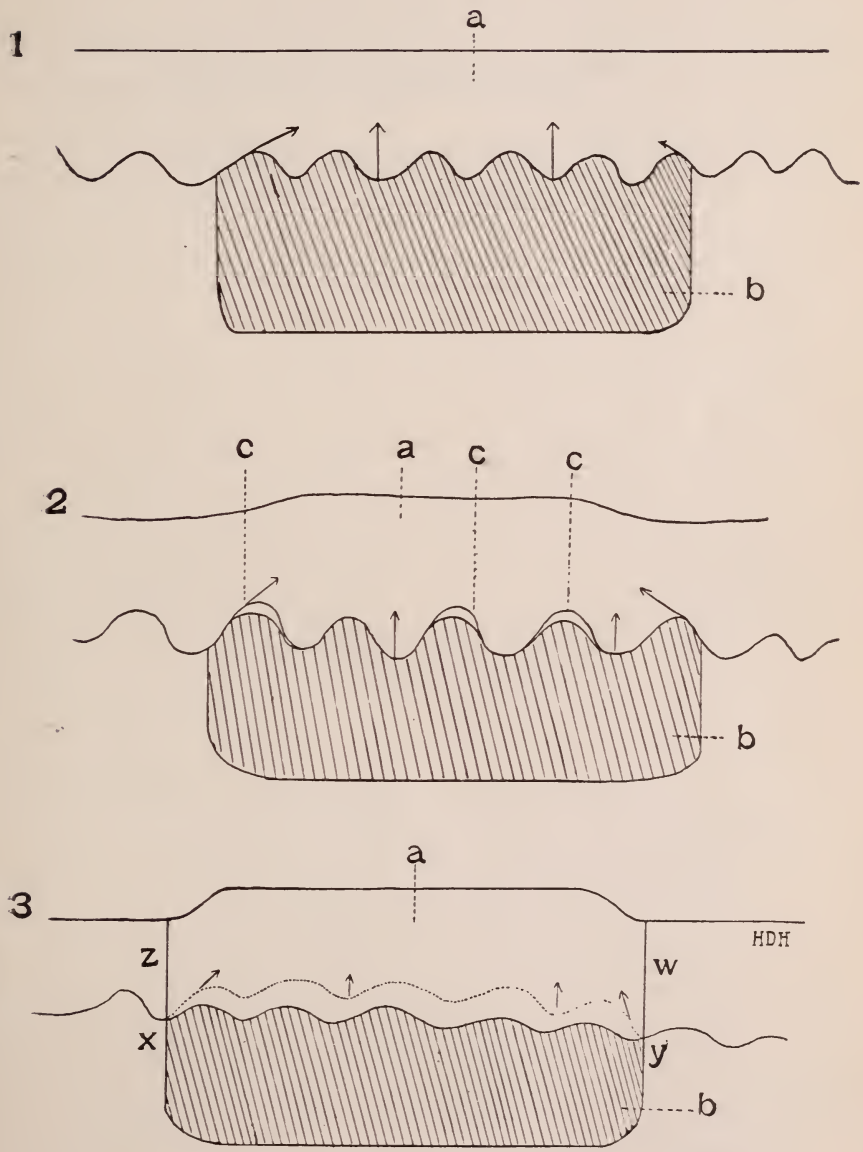

Fig. 1.

To Illustrate Article on Pathology, by Walter J. Heimann, M.D.

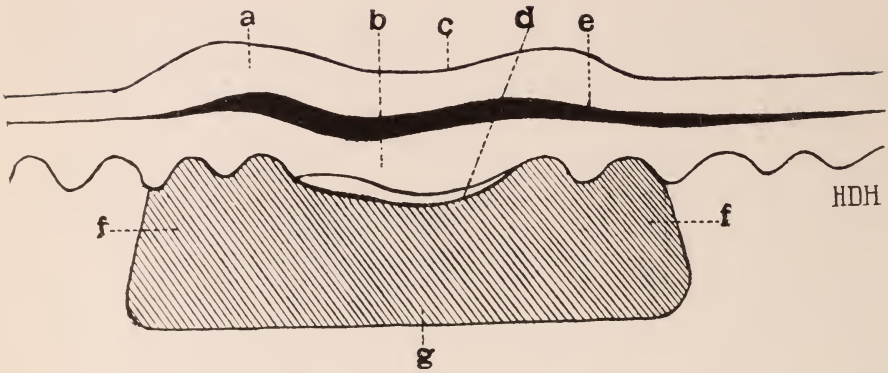

Fig. 2.

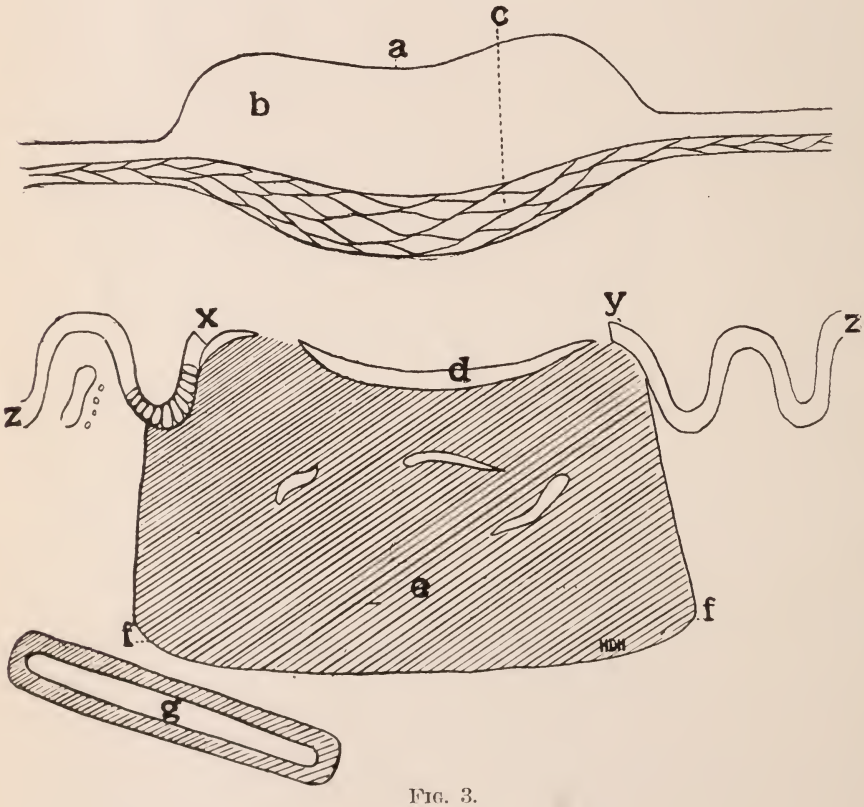

Fig. 3.

To Illustrate Article on Pathology, by Walter J. Heimann, M.D.

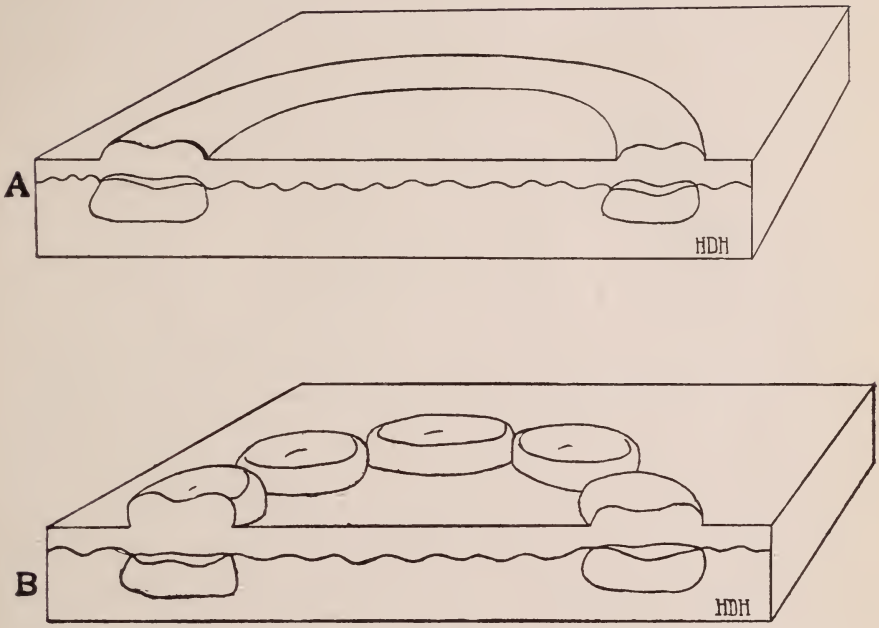

Fig. 4.

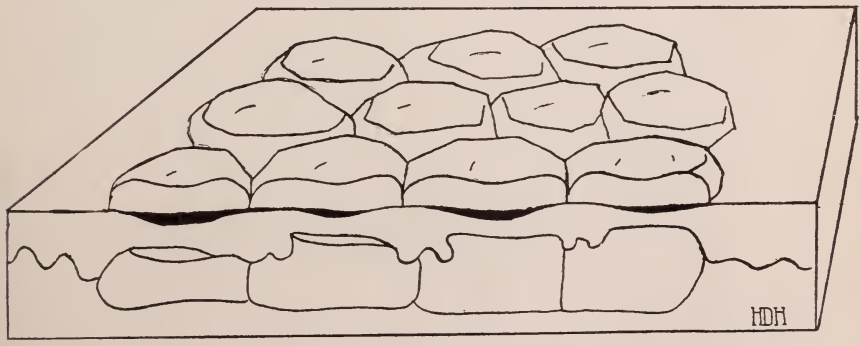

Fig. 5.

To Illustrate Article on Pathology, by Walter J. Heimann, M.D.

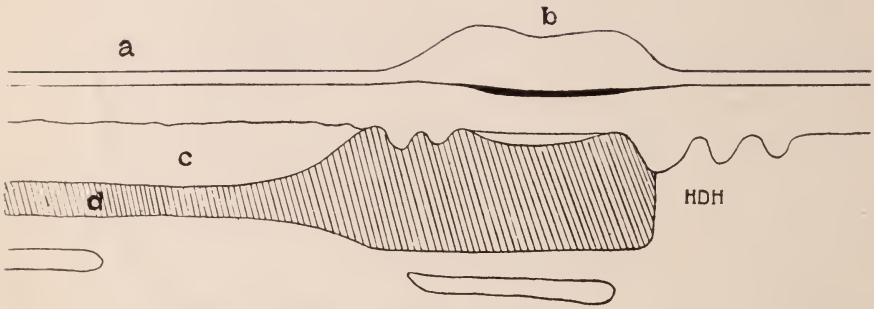

Fig. 6.

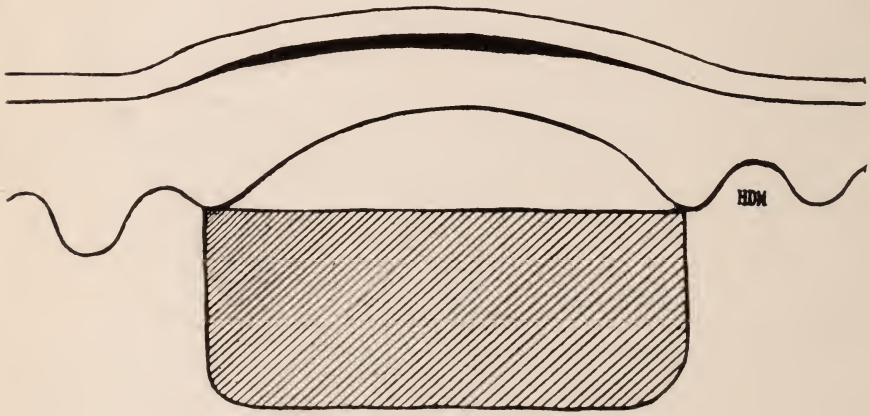

Fig. 14.

Plate XLVIII.—To Illustrate Article on Pathology, by Walter J. Heimann, M.D.

Fig. 7.

Plate XLIX.—To Illustrate Article on Pathology, by Walter J. Heimann, M.D.

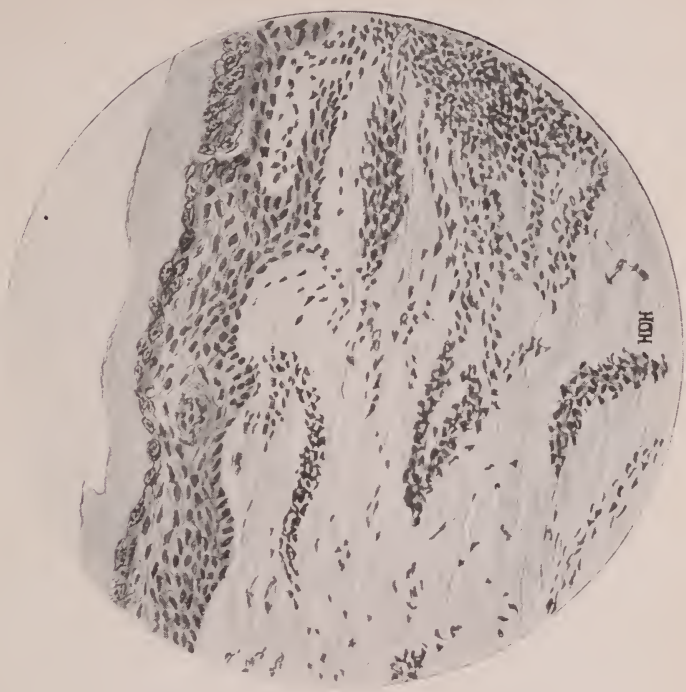

Fig. 9.

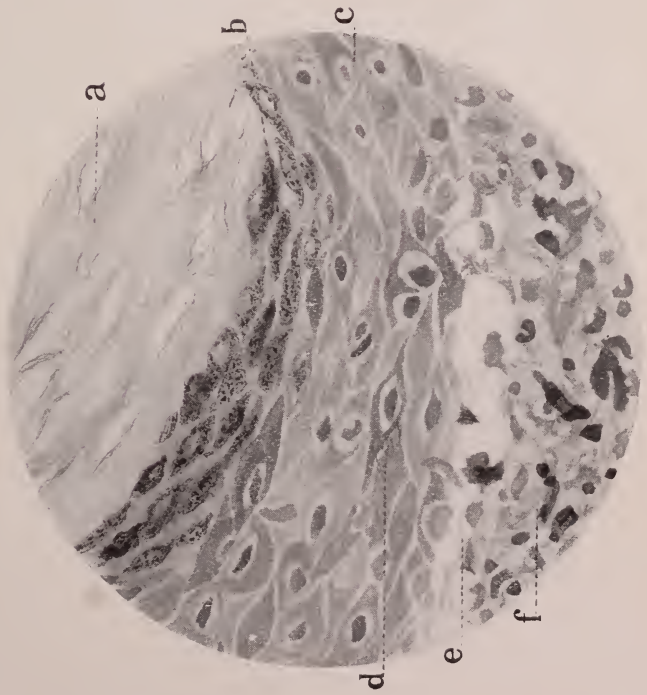

Fig. 8.

Plate L.—To Illustrate Article on Pathology, by Walter J. Heimann, M.D.

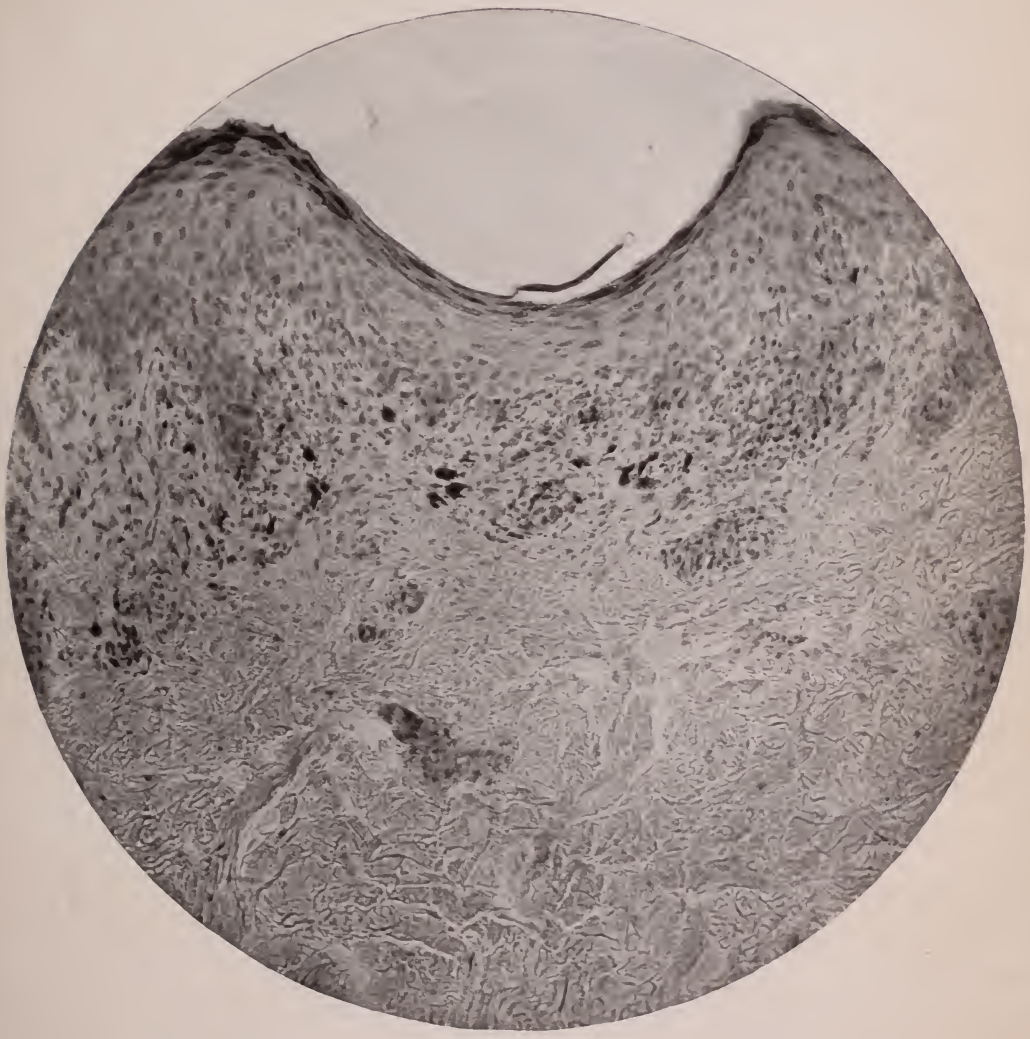

Fig. 10.

Plate LI.—To Illustrate Article on Pathology, by Walter J. Heimann, M.D.

Fig. 11.

Plate LII.—To Illustrate Article on Pathology, by Walter J. Heimann, M.D.

Fig. 12.

Plate LIII.—To Illustrate Article on Pathology, by Walter J. Heimann, M.D.

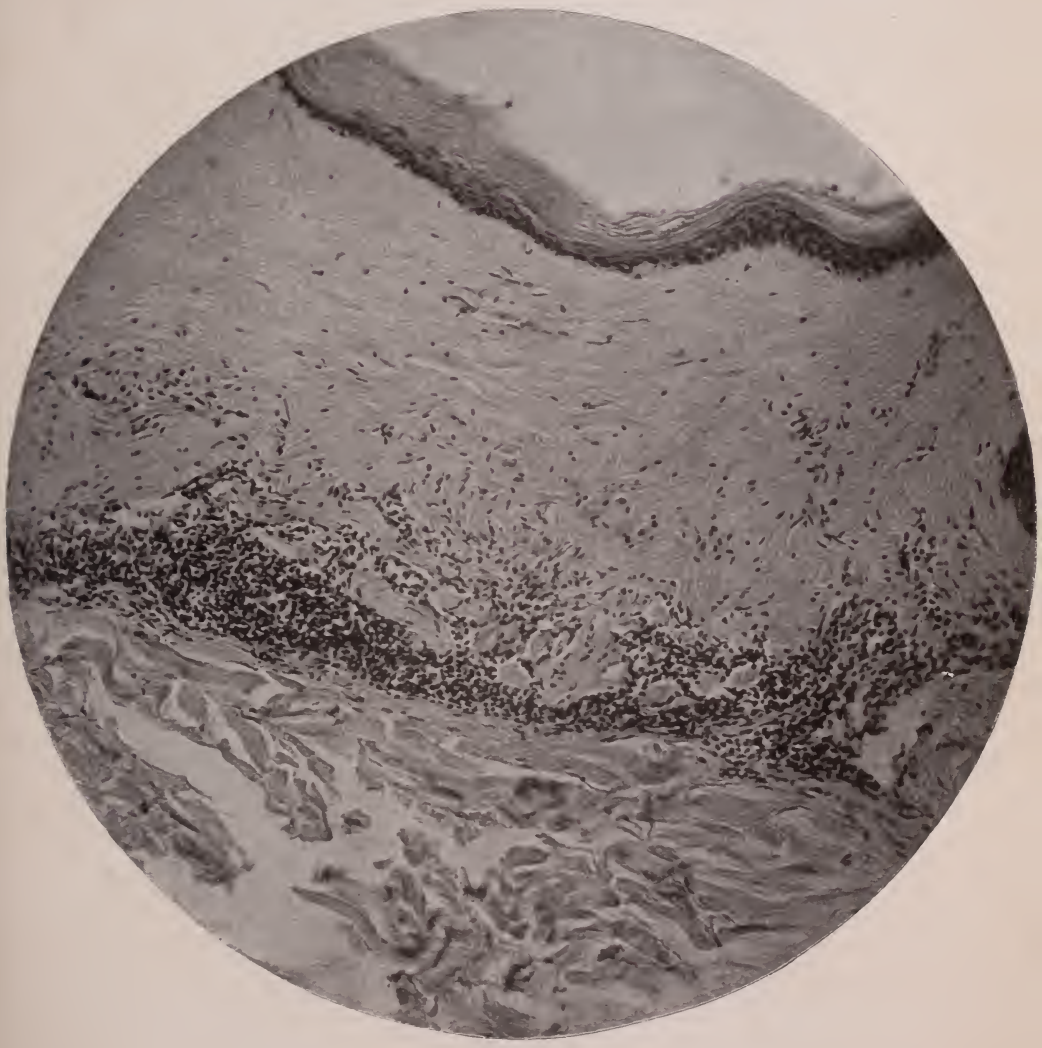

Fig. 13.

Explanation of Plates.

Fig. 1. The development of the lacuna according to its various stages. Diagram.
1. *a*. Epidermis. The arrows indicate the direction of growth.
b. Infiltration.
2. *a*, *b*, and arrows as above.
c. Spaces developing at tips of papillæ.
3. *a*, *b*, and arrows as above.
x-y. Rigid line of infiltration.
z-w. Redundant epidermis separating from infiltration, and increasing lacuna.

Fig. 2. Dell formation. Diagram.
a. Hyperkeratotic area.
b. Thinning rete. Shaded line between *a* and *b*, thick granular layer.
c. Dell caused by sinking of entire epiderm caused by sagging into lacuna.
d. Lacuna.
e. Margin of papule.
f-f. Points at which epidermis is fixed to infiltration from which the former bends into lacuna, forming dell.
g. Infiltration.

Fig. 3. Mature lichen planus papule. Diagram.
a. Dell.
b. Hyperkeratotic layer.
c. Thickened granular layer.
d. Lacuna.
e. Infiltration, containing dilated vessels.
f-f. Horizontal, sharp inferior margin of infiltration.
g. Dilated deep vessel surrounded by sheath of infiltration.
z-z. Germinative (basal or columnar) layer.
x-y. Site, above lacuna, at which the basal layer has been absorbed.

Fig. 4. Lichen annularis. Diagram.
a. Development of ring by marginal extension and central involution.
b. Formation of ring by circular arrangement of separate papules. This is the commoner mode of formation.

Fig. 5. Lichen plaque. Diagram.
This shows the mosaic manner of arrangement of the patch by the crowding together of the papules.

Fig. 6. Lichen atrophicus. Diagram.
a. Atrophic centre.
b. Lichen papule at margin.
c. Atrophied collagen corresponding to former papillary body. Above this the epidermis is thin, atrophied and the pegs are gone.
d. Infiltration, thin, and below the atrophied collagen in the atrophic area, widening out to its usual proportions in the papular margin.

Fig. 7. Lichen papule. Microphotograph, Zeiss obj. 8 mm., co. oc. 4; Fordyce, *Jour. Cutan. Dis.*, 1910, xxviii, p. 66. There is a thick scale of unnucleated cells (hyperkeratosis), a thickened granular layer, and obliteration of the germinative layer. The pegs are gone, and the papillæ are replaced by infiltration. Compare these features with the normal condition of the unaffected skin at the margin. The lacuna is not present. This is probably due to the fact that this section is not very deep in the lesion. The lower, sharp, horizontal margin of the infiltration is clearly shown.

FIG. 8. Lichen papule, showing centre of dell. Drawing with Zeiss apochr. obj. 3 mm., co. oc. 8. Specimen from Dr. Trimble's collection.

a. Hyperkeratosis.

b. Thickened granular layer, the curve of which shows the contour of the dell.

c. Rete with dilated intercellular spaces. The pegs are gone.

d. Two rete cells joined by stretched epithelial threads.

e. Lacuna.

f. Infiltration consisting of lymphocytes and fibroblasts.

FIG. 9. Lichen atrophicus. Zeiss obj. DD, oc. 4. Drawing. Specimen from Dr. Udo Wile's collection. To the right, infiltration; to the left, atrophying area. Note the thin epidermis, the absence of the papillæ, the sclerosis where they had been, and the band-like infiltration about the deeper vessels.

FIG. 10. Lichen planus. Involuting lesion. Microphotograph, Zeiss obj. 8 mm., co. oc. 4; Fordyce, *Jour. Cutan. Dis.*, 1910, xxviii, p. 66. Note the absence of the scale, the thinning of the infiltration, and the increase in the darkly stained pigmentary cells.

FIG. 11. Lichen planus involving follicles. Microphotograph, Zeiss obj. 8 mm., co. oc. 4; Fordyce, *Jour. Cutan. Dis.*, 1910, xxviii, p. 66. Note the follicular plugs, infiltration, lacunæ between epidermal portions and infiltration.

FIG. 12. Lichen hypertrophicus or verrucosus. Microphotograph, Zeiss obj. 16 mm., co. oc. 4; Fordyce, *Jour. Cutan. Dis.*, 1910, xxviii, p. 66. Note the striking acanthosis, a feature never present in the usual types of lichen. Otherwise the dells, hyperkeratosis, increased granular layer, character of the infiltration, etc., as in ordinary lichen.

FIG. 13. Lichen atrophicus. Microphotograph, Zeiss-Planar obj. 20 mm.; Fordyce, *Jour. Cutan. Dis.*, 1910, xxviii, p. 66. This corresponds to the central or atrophic area. (See diagram Fig. 6, *a*, *c*, *d*.)

FIG. 14. Lichen pemphigoides. Diagram showing bleb. Note bleb at site usually occupied by lacuna. The epidermis is thinned, the granular layer thickened, and the infiltration characteristic of lichen planus. (Unfortunately the specimen from which this diagram has been constructed has been mislaid, otherwise an actual drawing would have been shown.

PREPARATION OF SKIN TISSUE FOR MICROSCOPICAL STUDY.*

By Nathan Freeman, New York.

Technician, Dermatological Laboratory, College of Physicians and Surgeons, Columbia University.

(From the Department of Dermatology, College of Physicians and Surgeons, Columbia University.)

From time to time pieces of skin fixed in various agents, are brought or sent to the laboratory. When put through and blocked in paraffin, the tissue often cuts unevenly, sometimes with great difficulty; good clear stains, as a rule, are difficult to obtain. When examined, more or less distortion of the elements is noted and the finer details are sometimes lost. Occasionally, stained sections are brought or sent in and similar faults are noted. In this laboratory, for a long time, we have had the same trouble so long as we employed the methods usually recommended for skin tissue.

After repeated trials for many months, we have perfected a satisfactory procedure which we are pleased to recommend to all workers in dermal pathology. The tissue cuts smoothly and evenly, without any damage to the microtome knife. (The sections in our routine work are cut at six to seven microns, which is thin for skin tissue.) The finished sections show no distortion, are evenly stained and clear, and the fine details very readily noted. They are admirably suited for high power study and for high power micro-photography.

The method as employed by us is as follows:†

Upon removal, the tissue is immediately put into the fixative, Bouin's solution (Lee, the Microtomist's Vade-Mecum, 1913, p. 65)

Formula of Bouin's solution:	Picric acid, sat. aq. sol.....	75 parts
	Formol, 40%.....	25 "
	Acetic acid, glacial.....	5 "

Fixative, six to eight hours, depending upon the size and consistency of the specimen.

Dehydration, clearing and paraffin infiltration.

(1)	alcohol 70%.....	8 to 12 hours (2 to 3 changes).
(2)	alcohol 95%.....	8 to 12 hours.
(3)	alcohol abs. (1).....	8 to 12 hours.
(4)	alcohol abs. (2).....	8 to 12 hours.
(5)	alcohol abs.	
	carbon disulphide, equal parts until tissue sinks to bottom.	

* Read before the Clinical Society of the Dermatological Department of the Vanderbilt Clinic, April 20, 1916.

† Large quantities of fluid should be used in each and every step of the procedure.

(6) carbon disulphide c. p..... 8 to 12 hours.
(7) carbon disulphide, 1 part.
paraffin 4 parts... 8 to 12 hours at 37° C., in incubator.
(8) paraffin melt. pt. 52° C., (1) 1 hour } in oven.
(9) paraffin melt. pt. 52° C. (2) 1 hour }
(10) tissue is imbedded in paraffin in flat dish; the paraffin is allowed to film over on surface, then the dish is put into cold water, where the setting of the paraffin is completed; imbedded specimen is put into icebox until ready to trim and block.

The superfluous paraffin is cut away and the block is cemented with melted paraffin, on to a small cube of wood. (Best done by heated, broad, flat knife, placed between paraffin block and wood, and as soon as the paraffin melts sufficiently, the block and wood are pressed together). The mounted block is put on ice or into cold water for a short time to thoroughly harden the paraffin. The imbedded mounted tissue is placed in the microtome and is ready to be sectioned.

The knife is so placed as to cut at right angles through the tissue; the block should be so placed that the epidermis comes in contact with the knife edge first (this is important). The ribbon obtained is floated into a pan of distilled water, heated to about 10° C. below the melting point of the paraffin, i.e., 42° C. When the sections appear perfectly flat, free of all wrinkles, they are floated onto a clean slide, the excess water wiped off and the slide placed into a box. The slides should rest on edge to allow the water under the tissue to drain off (important). The box containing the slides resting on edge is put into the incubator at 37° C., for 12 to 24 hours, to dry the sections thoroughly. They are then put into the oven at 56° C., for one hour.

This fixes the dried sections to the slides and does away with cements of all kinds. The paraffin is removed by successive changes of xylol, the xylol by successive changes of absolute alcohol, then to alcohol 80% and to water; the slides are passed through many changes of water, or better still, running water, until all the picric acid has been washed out of the sections. The sections are then ready for staining.

I wish to acknowledge my indebtedness to Dr. D. L. Satenstein, the Assistant Pathologist of the Department, for his suggestions while working out the technique above described.

Discussion.

Dr. Heimann said that, from the standpoint of the microscopist, the requirements were a good specimen in which, in the first place, the structure of the component elements was as nearly that of the fresh tissue as could reasonably be expected after fixation; and secondly, in which cell details were clear. The proper method of fixing tissue favored these ends, and made it possible properly to imbed, and then to cut thin sections in which minuter features of interest or significance stood out. The particular stain selected for given purposes was of less moment than the perfect clearing of the slide, a matter that can be beautifully accomplished when the tissue was prepared, by the technique described in this paper. From start to finish, the specimens that he had examined, which had been prepared according to the instructions herein outlined, had been among the best he had ever seen.

Dr. MacKee stated that he had never had such satisfactory sections for microphotographic work. They offered every possibility for detail, contrast, definition and a flat field for both low and high power work.

ELEMENTARY INSTRUCTION

A TABULATION OF THE LAYERS OF THE SKIN.

By George Manghill Olson, M.D., Minneapolis.

The increasing value of the biopsy in dermatological diagnosis gives considerable importance to the study of histopathology of the skin. In dermatology we have perhaps the best field in medicine for the study of pathology, as sections from diseased parts of the skin are readily obtainable; and, undoubtedly, it is due to this fact that so much valuable work in pathology has been done by dermatologists. This study of sections from the skin has been responsible, to a very great extent, for the progress in correct dermatological diagnosis, so that at the present time dermatology, in all probability, leads all other branches of medicine as regards the proportion of patients in whom an early and correct diagnosis can be made.

The study of histopathology of the skin has been considerably retarded by the multiplicity of names given to the layers of the skin. While synonyms are by no means an unmixed evil, as some synonyms are valuable for the purpose of forming derivative words, etc., in the case of the layers of the skin, this synonomy has become exuberant, so that it is unusual to read any two papers or text-books that employ the same terms for these layers of the skin.

The following tables give the names that are used for the layers of the skin, the most desirable term being placed at the head of each list.

Table I.

The Skin.

Synonyms: External skin. Tegument. Integument. Integumentum commune. General integument.

Table II.

The Three Main Layers of the Skin.

1. Epidermis.

   Synonyms: Epiderm. Cuticle. Scarf skin. Epithelial layer.

II. Corium.
Desirable synonyms: Derma. Cutis.
Derm. Dermis. Cutis vera. Cutis propria. True skin. Leather skin. Sensitive skin. Connective tissue layer.

III. Stratum subcutaneum.
Desirable synonyms: Subcutaneous layer. Subcutaneous tissue. Hypoderm.
Tela subcutanea. Tela cellulosa subcutanea. Subcutis. Panniculus adiposus. Stratum adiposum.

TABLE III.

LAYERS OF THE EPIDERMIS.
1. Stratum acanthosum.
2. Stratum granulosum.
3. Stratum lucidum.
4. Stratum corneum.

1. Stratum acanthosum.
Desirable synonyms: Prickle layer. The rete.
Rete mucosum. Rete Malpighii. Rete Malpighianum. Stratum mucosum. Stratum Malpighii. Stratum spinosum. Stratum spinulosum. Stratum dentatum. Stratum filamentosum. Corpus mucosum. Corpus Malpighii. Mucus Malpighii. Mucous layer.

THE LOWEST LAYER of the stratum acanthosum forms the Stratum basilare.

Synonyms: Basal layer. Stratum germinativum. Generative layer. Stratum cylindricum. Palisade layer.

Above the stratum basilare there is found the cuboidal or transitional cell layer.

1. The stratum acanthosum is sometimes divided into two portions.
A. Superpapillary portion. Above the cutaneous papillæ.
B. Interpapillary portion. Between the cutaneous papillæ.

2. Stratum granulosum.
Desirable synonym: Granular layer.
Langerhan's layer. Kerato-hyaline layer.

3. Stratum lucidum.
Synonyms: Septum lucidum. Oehl's layer.

3A. Stratum intermedium (Ranvier).
Part of the stratum lucidum.

4. Stratum corneum.
Desirable synonyms: Corneous layer. Horny layer.

4A. Stratum disjunctum.
Part of the stratum corneum.

TABLE IV.

LAYERS OF THE CORIUM

1. Stratum papillare.
2. Stratum reticularis.

1. Stratum papillare.
   Desirable synonym: Papillary layer.
   Pars papillaris. Corpus papillare. Pars papillaris corii.

1a. Stratum subpapillare.
   Subpapillary layer.

2. Stratum reticularis.
   Desirable synonym: Reticular layer.
   Pars reticularis. Tunica propria. Pars reticularis corii.

COMMENT.

As far as possible the most desirable term selected has been in the Latin or Latinized form. There are very many advantages in having the accepted or formal term in Latin or Latinized form. It forms an international word, easily read by dermatologists in other countries. Derivative words are easily formed from Latin or Latinized words, and much valuable information is obtained in this way. Thus stratum acanthosum, acanthosis and acanthoma all relate to the prickly layer. The Latin form does not prevent the use, often advantageously, of the local or national term, as prickly layer for stratum acanthosum, granular layer for stratum granulosum, etc.

PHYSICAL DIAGNOSIS IN DERMATOLOGY.

BY D. L. SATENSTEIN, M.D., NEW YORK.

(*Continued from Oct., 1915, xxxiii, No. 10, p. 704.*)

(4) VESICLES are small, of various shapes and colors, tense or flaccid, circumscribed elevations of the skin, containing clear, colored or opaque fluid.

Size: Varies from pin-point to that of a small pea.

Shape: Base may be circumscribed, circular, angular or irregular (linear or oblong); summit may be more or less acuminate, evenly rounded (dome-like), or irregular with slight depressions on top or sides.

Color: Depends upon character of contents, thickness of covering walls and degree of accompanying inflammation; may be dull or glistening, depending upon degree of tension; may be translucent when containing sweat, yellowish with serum, yellowish-white with sero-pus, reddish to reddish-brown to black with recent or old blood.

Occurrence and evolution: Vesicles are common to a number of diseases and their presence due to various causes; may accompany constitutional diseases, or be due to constitutional disturbances; may be due to ingestion of drugs; may be due to local causes, as traumatism (friction), to chemicals, to light and heat rays, to infections; may be result of nerve disease or part of a new growth, either congenital or acquired. They may start as vesicles or develop from preceding papules; may occur alone or in association with other primary and secondary lesions; rarely occur singly, usually in numbers; they are most common where the skin is thin, but may occur anywhere; they may be superficial or deep (situated in any or all the layers of the epidermis, or be associated with skin appendages or lymphatics); when superficial the covering walls are thin, rupture either spontaneously or mechanically, readily (in short time, either few hours to few days), and discharge contents over surrounding surface. The character of the base of the ruptured lesion depending upon its ætiology and anatomy. When deep seated the walls are thick and do not rupture readily; the contents are usually absorbed and the walls dry into crusts or remain for variable time as thin scales; upon violence the contents may be forced to undermine the surrounding epidermis. Vesicles may be localized or general; scanty or abundant; discrete or grouped, or confluent so as to form bullæ; they may be small or large; some have a tendency to umbilication; they may be single or compound (according to their mode of development); may be tense (fully distended) or flaccid (partially distended). They may remain as vesicles until they are absorbed or pass progressively into vesico-pustules or pustules; may or may not have an inflammatory base or be surrounded by an inflammatory areola, but not so marked as is present with inflammatory papules and pustules. They may leave stains more or less persistent and some may even leave scars. May or may not be accompanied by subjective symptoms as pain, burning and itching, depending upon the ætiology and nature of the lesion.

Types: Not many, but differ from each other not so much in their clinical appearance as in their anatomy and evolution.

(A) Inflammatory, superficial, localized; at first discrete, later tendency to coalesce so as to form irregular patches; usually begin as vesicles from the start; little or no inflammatory areola; at first small, rounded, contents clear, increase rapidly in size, become somewhat flattened or may be depressed in the centre; contents rapidly become sero-purulent; they are thin walled, rupture readily and early, the base exuding a puriform fluid; tendency to early crust formation; crust yellowish, slightly adherent, falls off in few days, leaving a slight redness which fades rapidly; little if any subjective symptoms; example, impetigo contagiosa.

(B) Inflammatory, superficial, localized and usually limited to exposed parts and genitals; appear in (small or large, few or many) groups, upon a slight inflammatory base; usually vesicles from the start; at first small, discrete, clear and glistening, early increase in size and a tendency to coalesce; contents soon become cloudy but never purulent; do not rupture readily; tendency to dry into thin yellowish crusts, which fall off in short time, leaving no trace; usually accompanied by slight burning; example, herpes simplex.

(C) Inflammatory, superficial, limited to a nerve trunk; sudden appearance, in groups, upon a slight inflammatory base; at first papular,—rapidly change to

vesicles; usually discrete, later may become confluent; usually all the lesions in the individual group of the same character and size; new crops appear at other areas supplied by the same nerve. The vesicles are rounded, clear, later milky but never purulent; no tendency to spontaneous rupture; in varying time the contents are absorbed, the walls dry into yellowish or brownish crusts, which in a few days drop off, leaving a slight erythema or in some instances a slight depression (atrophy). Usually accompanied by neuralgic pains; example, zoster.

(D) Inflammatory, usually limited to uncovered parts, exceptionally general; usually discrete but may become confluent; individual lesions vary in size; at first rounded and clear; soon increase in size with tendency to umbilication; always become cloudy but never purulent; may dry up or rupture spontaneously or accidentally; usually umbilicated centre dries into reddish or blackish crust; remains variable time, falls off, leaving a reddish, pitted, permanent depression; this later turns white. Little or no subjective symptoms; example, hydroa vacciniforme (æstivale).

(E) Inflammatory, superficial, usually limited to exposed parts or to where the skin is thin; may become general; lesions at first discrete, later crowded or confluent and have a considerable inflammatory areola; they may begin as papules or as minute vesicles; they are yellowish, translucent or glistening, thin walled; rupture readily (spontaneously), leaving a weeping base; may be accompanied by other primary or secondary lesions, some of them as result of previous lesions; crust formation results, remain variable time and disappear, leaving a slight erythema to mark the site of the lesions; usually accompanied by intense itching and burning; examples, vesicular eczema and dermatitis venenata (ivy).

(F) Inflammatory, deep seated, limited to hands and feet; at first discrete, but closely crowded together, the vesicles vary in size from pin-point to that of bean; contents clear or translucent; they are firm, intensely itchy, show no tendency to spontaneous rupture; contents later becomes milky; there is a marked tendency for the lesions to coalesce and either form blebs or to undermine the surrounding epidermis; may either be absorbed with new lesions appearing or go on to a secondary impetiginous eczema; example, dysidrosis.

(G) Inflammatory, superficial and general from the start; may begin as vesicles, or other primary lesions as macules, papules or wheals and develop into vesicles and pass into bullæ or pustules; appear on slight erythematous base; occur in groups, but individual lesions are discrete and of varying size and irregular in shape; may be tense or flaccid and show little tendency to spontaneous rupture. They are as a rule intensely itchy; may disappear by absorption, or dry into crusts, or be scratched to form abrasions which rapidly crust over; in variable time crusts drop off and leave a red area or a more of less persistent brownish pigmentation; example, dermatitis herpetiformis (Duhring).

(H) Inflammatory, superficial and general; always discrete and disseminated; begins as small papule upon a slightly inflammatory base; rapidly changes into vesicle and areola disappears; the lesions are of varying size, clearly defined, usually rounded, later umbilicated, contents at first clear or translucent, later milky; are tense or flaccid, thin walled with tendency to rupture readily; they may be absorbed, or dry into crusts, leaving no permanent remains, or may become impetiginous (infection); may be accompanied by very slight or severe constitutional symptoms; example, varicella.

(I) Inflammatory, superficial, and very early general; at first deep-seated papules upon an inflammatory base; papules very rapidly change into vesicles; these are round and tense and at first contain clear fluid which very rapidly

becomes cloudy and vesicles soon become pustules; as the vesicles increase in size, show a distinct umbilication; usually accompanied by an inflammatory œdema of the surrounding tissue and more or less severe constitutional disturbances; the papulo-vesico-pustules are as a rule discrete and disseminated but very early become confluent; they show little tendency to spontaneous rupture; example, variola.

(J) Non-inflammatory, superficial or deep, usually limited to upper part of body but may occur anywhere; smaller or larger, few or many irregular patches; composed of either discrete or closely crowded vesicles of varying size and colors (depending upon thickness of walls and character of vessels, either within the vesicles or beneath the vesicles); usually no tendency to spontaneous rupture but may, if very superficial, rupture readily; some may even bleed; remain indefinitely, may or may not increase in size; usually cause no discomfort; example, lymphangioma circumscriptum.

(K) Non-inflammatory, usually deep seated, persistent affection, occurring anywhere but usually on face and chest; usually discrete, but may be crowded together; lesions are rounded, yellowish to white, may be glistening, tense and firm; vary in size, never very large, show little change, no inflammatory areola, no subjective symptoms, little tendency to rupture; remain variable time, but may be absorbed with other similar lesions to develop slowly; example, hydrocystoma.

Diagnostic value: From the character of the lesion, its relation to other lesions present, the history of its evolution, taken all together, the observer will be enabled to classify the eruption.

(*To be continued.*)

SOCIETY TRANSACTIONS.

NEW YORK DERMATOLOGICAL SOCIETY.

Regular Meeting, Jan. 24, 1916.

HOWARD FOX, M.D., *President.*

ECZEMA AND GENERALIZED VACCINIA FROM AUTO-INOCULATION.

Presented by DR. POTTER.

George N., five years old, born in the United States. The family history was negative. The child had always been well and had never before had any skin disease. Three months ago he was vaccinated. The vaccination took nicely and ran the usual course. Three weeks after the vaccination the child complained of itching of the arms and body. A papular eruption appeared on the arms and body, which he scratched considerably. Later, small vesicles appeared over the affected areas. These vesicles very shortly became pustular, and were finally coated with a crust. The boy was sick for three or four days after the eruption became pustular. His temperature was 102° F. At the time of presentation there were multiple depressed scars over the abdomen, back and arms.

DISCUSSION.

DR. TRIMBLE said that, on superficial examination, the lesions looked like the scars following varicella, but that he was willing to accept Dr. Potter's diagnosis, except in regard to the cause. He would accept the case as one of vaccinia, but rather doubted the question of the auto-inoculation. He understood Dr. Potter to say that all the lesions had been inoculated from the original lesion. It is not always easy to get the original lesion to "take," and it seemed to him that it would be most unusual to have such great numbers of vaccination points scattered over the body.

DR. HOWARD FOX said he understood that there were two kinds of generalized vaccinia, one of which was caused by auto-inoculation. He had seen several examples of the latter type at the Willard Parker Hospital. In these cases there had been only a few lesions scattered over the body. He did not think that the present case could have been caused by auto-inoculation, as the lesions were so numerous. Possibly the eruption was a varicella.

DR. POTTER said that it was not at all a picture of varicella. The eruption in varicella appeared in crops, first appearing on the face and scalp; then, too, the pitting was too deep for the pitmarks of varicella. He would not for a moment consider it varicella. Answering Dr. Trimble's argument, he thought the inoculation came from the fact that the child had a slightly eczematous condition, and the scratching of the eczema caused the inoculation of the virus, resulting in the vaccinia. While he was willing to admit that the original vaccination almost always runs a course in three weeks, at the same time he did not think the patient could be considered absolutely immune to inoculation from the

original vaccination at that time. He believed persons may become inoculated by the virus three weeks after the original vaccination and that such inoculation could be produced by scratching.

LUPUS VULGARIS. Presented by Dr. Potter.

L. A., nine years old, born in the United States, of Italian parents. The family history was negative; the child had measles when a year old. The present trouble started when the child was two years old, first appearing on the left cheek, as a small brownish papule which broke down and ulcerated, leaving a scar. A second area appeared on the inner aspect of the right thigh when the child was three years old. Three years ago, several areas of superficial, apple-jelly nodules appeared on the right forearm. All the lesions were superficial, progressed slowly, and showed but slight tendency to ulcerate. The von Pirquet reaction was positive; Wassermann reaction, negative.

PURPURA HÆMORRHAGICA. Presented by Drs. MacKee and Wise.

The patient, R., was a white boy, born in the United States. He was presented from Dr. Fordyce's clinic. The duration of the condition was four months. The lesions consisted of a punctate hæmorrhagic eruption scattered over the face, body, and extremities,—some isolated and others grouped,—presenting various stages of absorption, together with patches of ecchymosis; the lips and tonsils showed patches of superficial hæmorrhage. The eruption was said to have followed an injection of diphtheria antitoxine, given four months ago. The speaker asked for suggestions for treating the condition.

Discussion.

Dr. Schwartz was inclined to regard it as a case of purpura hæmorrhagica due to a streptococcus tonsillitis. He had had a similar case last spring. The first sign that developed in the child was a marked hæmatoma, and examination showed a streptococcus tonsillitis to be present. Later, the child developed an acute hæmorrhagic pyelo-nephritis. He thought the child presented had an infection of the tonsils, to which the purpura and hæmatoma were secondary. The child had a rapid, thready pulse, and from a rather hasty examination of the heart he thought that a lesion was present,—also probably secondary to the tonsillitis infection. As to treatment, he thought it advisable to make a culture from the tonsils so as to learn the exact type of organism present, and then give a course of injections of an autogenous vaccine.

Dr. Trimble asked whether in using the term "purpura hæmorrhagica" Dr. Wise had reference to Werlhoff's disease. He himself had seen several of these cases, and all the patients died; this was the mildest case he had ever seen.

Dr. Howard Fox thought that this would be a suitable case for treatment with intramuscular injections of human blood,—a method reported in a recent issue of the *Jour. A. M. A.*

PEMPHIGUS. Presented by Dr. Potter.

W. M., sixty years of age, born in Ireland, had always enjoyed good health. The trouble for which he was presented started two months ago; the skin was perfectly clean and smooth up to that time. The patient first noticed an intense itching on the inner aspect of the right thigh. Immediately after rubbing to relieve the itching, large vesicles appeared. These vesicles gradually broke and

the surface healed, leaving a pigmented area. About three weeks after the appearance of the trouble on the thigh, the same condition appeared in both groins. In this area, the skin has not healed after the eruption of the vesicles. No other area on the body had been affected, excepting the mouth, which showed several vesicles.

DISCUSSION.

DR. FORDYCE suggested that the affection be treated with lysol baths, after the method used by Dr. Baum, of Syracuse.

DR. WISE asked why the condition was called pemphigus vegetans rather than vulgaris. What were the symptoms which would make one call it pemphigus vegetans?

DR. FORDYCE, replying to Dr. Wise's inquiry as to the symptoms which led him to call it a pemphigus vegetans, said he was chiefly led to this opinion by the localization of the lesions about the genital region, the axilla and the mouth. The occurrence of pemphigus lesions in these localities led, not infrequently, to the subsequent appearance of papillomatous growths.

DR. TRIMBLE did not entirely accept the diagnosis of pemphigus. It might very well be some other form of bullous dermatitis. He said he did not like to prophesy, but that the case did not show sufficient evidence of pemphigus to call it that, at the time of presentation.

DR. HOWARD FOX said that he had recently treated a severe case of acute pemphigus at the Harlem Hospital. About half of the surface of the body was involved. He had given the patient, who was a woman of about fifty years, four intramuscular injections of whole blood obtained from her daughter. The injections were given twice a week, in doses of twenty cc. The treatment did not cause any improvement, the patient dying at the end of the seventh week, of the disease.

DR. HEIMANN said that in an article published in the *Jour. A. M. A.*, the suggestion had been made that salvarsan be given intravenously and pyocyaneus vaccines subcutaneously, and that that might be tried on this patient. The rationale of such treatment was not evident, but, since very little was known about the therapy of pemphigus, any new therapeutic suggestions should receive attention.

DR. TRIMBLE said he had not used the combined treatment referred to by Dr. Heimann, but that he had tried salvarsan in several cases and the patients seemed to be improved for a time, but later relapsed. He had also used the pyocyaneus vaccine, which brought the temperature down and seemed to have a good effect for a while; but these patients also had relapsed and followed the usual course.

DR. POTTER did not see why Dr. Trimble thought the vesicle might have been caused by an irritation of some kind, for the condition first arose from a perfectly healthy skin. That was the point that favored the diagnosis of pemphigus. As for treatment, he had in his service, at the King's County Hospital, a case of pemphigus vulgaris which received sixteen injections of autogenous serum and no other treatment, excepting saline baths and protective ointments. After fourteen months, the patient recovered absolutely; his pemphigus disappeared entirely. Later, he had an attack of dermatitis exfoliativa, and that, too, cleared up after the persistent use of pilocarpine. He made a complete recovery and had been well for six months.

EPIDERMOLYSIS BULLOSA. Presented by DR. TRIMBLE.

The patient was a young woman, twenty-six years of age, born in Germany; she had been in the United States for twenty years. The condition began when

she was sixteen years old, a few bullous lesions then appearing on the face, later in the mouth, and still later on the hands and body. Lesions occurred upon the slightest trauma, and at times without any injury. The patient had claw hands from skin atrophy, and many milium-like bodies were scattered over the old lesions. Repeated Wassermann tests were negative, and salvarsan had been administered without effect. The case had been shown previously by Dr. Fordyce.

ECZEMA OF THE LEGS. Presented by Dr. Williams.

The patient, Mrs. B. B., was a woman, seventy years of age, and had been presented recently before the Academy of Medicine. The eruption began ten years ago in the popliteal spaces as an eczema. Exudation was not a feature of the disease, except where the area was badly scratched. The legs and lower part of the thighs were included in the area affected. When presented, the condition was more like lichen planus than eczema.

Discussion.

Dr. Heimann said he could not conceive of its being a case of lichen planus on account of the eczematous condition. He was inclined to think it the type described by Brocq, in which the order was either lichenification upon eczema, or *vice versa*. He thought that lichenification of an eczema of this type was very unlikely. On the other hand, eczematization of a lichen simplex was a recognized entity, and this was the more likely sequence. He was inclined to think that the underlying condition was a neuro-dermatitis.

Dr. Williams said that the scratching was a very important feature and was very extreme.

CASE FOR DIAGNOSIS. Presented by Dr. Williams.

The patient, Mary W., forty-eight years of age, was born in Vilna, Russia. She had been married for twenty-five years and had had eight children, all healthy excepting one, an orthopædic case. The third child died. The patient gave no history of illness. She came to the United States in 1912. The lesion presented began, at eighteen years of age, as a small mass, gradually increasing in size, with no periods of subsidence. Pruritus was severe; there was no alopecia. The lesion was about two by three inches in area, situated at the base of the scalp, the lower part consisting of firm, close-set, dry, red papules, covered with closely adherent, silvery scales; above these, the patch was without papules, smooth, and covered with silvery scales. There were no pustules, no scarring, no keloids.

Discussion.

Dr. Whitehouse was inclined to think that it was a case of lichen planus; it could very well remain for that length of time. It was made up of hypertrophic plaques, fused together. He had seen several cases which looked like chronic infiltrated eczema, but they did not yield to treatment. In such cases, some of the characteristic papules were seen at the edge of the patch. He had had cases which had lasted for six years, resisting all kinds of eczema treatment, disappear in less than a month under the treatment devised by him, namely; Phenol, grs. xx; bichloride of mercury, grs. vi; diachylon ointment (Hebra) oz. i.

Dr. MacKee said that in the last ten years he had observed a number of cases of dermatitis occurring on and limited to the nape of the neck of women, inside the hair line. Sometimes it was a relapsing dermatitis, which responded to ordinary eczema treatment; at other times, it was exceedingly chronic, and the skin became infiltrated. He had never noted the very marked infiltration observed in Dr. Williams' case.

Dr. Sherwell believed it to be an eczema with not uncommon phenomena—a characteristic induration and proliferation on a long-continued chronic process. He had seen such an eczema that lasted a number of years and looked like the case presented. It was a long-continued eczematous process, with provisional healing and retrogression.

LICHEN ANNULARIS. Presented by Dr. Whitehouse.

The patient presented only a few lesions with marked pigmentation, and only slight subjective symptoms. She was thirty-five years of age, and the condition had been going on for a year. There were not more than half a dozen lesions altogether. They were scattered on the abdomen and upper and lower extremities and consisted of pigmented patches, with depressed centres and raised, pink-colored edges.

Discussion.

Dr. MacKee thought the condition was a serpiginous epithelioma. The lesions had a slightly rolled, semi-translucent edge. The pigmented centre and the spontaneous disappearance of some of the lesions did not rule out epithelioma, but the fact that there was no typical lichen planus lesion certainly spoke against a diagnosis of lichen planus.

Dr. Fordyce agreed with Dr. MacKee that the condition was one of superficial flat epithelioma. Such multiple lesions were not infrequently seen about the trunk. The case, however, was well worth histological study.

Dr. Wise agreed with Dr. Whitehouse's diagnosis. He had seen lesions of the same character with slightly raised, reddened margins, and depressed, pigmented interiors, associated with lichen planus on the anterior surfaces of the forearms. He considered the lesions to be those of the annular form of lichen planus and did not believe that they would show the morphology of epithelioma, when examined microscopically.

Dr. Trimble was inclined to agree with Dr. Whitehouse's diagnosis, although there were not enough clinical features to speak positively. When he first glanced at the case, the same thoughts came to his mind as expressed by Dr. MacKee, *i. e.*, it had somewhat the appearance of the superficial epitheliomata; but, after thinking it over, he recalled that multiple epitheliomata of the skin were very unusual, and spontaneous disappearance was still more uncommon. The lesion on the abdomen, the size of a ten-cent piece, had more the appearance of lichen planus annularis than anything else, although there were no typical flat papules.

Dr. G. H. Fox said that in certain cases of lichen planus one saw a pigmented centre with raised edge, forming a peculiar lesion, which he had called the lichen planus crater. It was generally seen on the lower part of the back, and generally with typical lichen planus elsewhere. He did not, however, think this a case of lichen planus, in spite of its resemblance to the lichen planus crater. It seemed more like a superficial epithelioma than the lichen circinatus which Wilson first described. A microscopical examination would doubtless settle the matter.

Dr. Whitehouse said he was very glad he had brought the case up. That it might be a superficial type of multiple epithelioma had not occurred to him. The characteristic raised border, the inflammatory character of the same, and the itching, together with the pigmentation and the spontaneous disappearance of some of the lesions, however, made him feel that it was more likely to be lichen planus annularis. He had under observation a case of general lichen planus in a man, with lichen annularis on the glans penis, indistinguishable from the lesions presented in this case. He intended to study the case further and see if there were any signs of it in the mouth. He hoped the diagnosis might be cleared up by a biopsy, which of course would readily distinguish the two diseases in question.

GUMMA OF THE LIP. Presented by Dr. MacKee for Dr. Fordyce.

The patient was a widow, forty-three years of age. She was married twenty-three years ago, and gave a history of having had sores in the mouth for a year. Sixteen and twenty-one years ago she had had two natural miscarriages, and had three healthy children living. A Wassermann test was made some time ago at St. Luke's Hospital, which was strongly positive. The lesion was situated on the left side of the upper lip. This side of the lip was red and smooth, over an area the size of a silver dollar. There was some crusting at the vermilion border. The duration was four months, and the general appearance was that of a chancre. There was, however, no involvement of the lymph glands, and the lesion was not indurated. The lesion extended through the lip and involved the buccal surface. Here, there were three deep fissures which suggested tuberculosis.

LICHEN PLANUS TREATED WITH X-RAYS. Presented by Dr. MacKee for Dr. Fordyce.

The patient was a man, fifty years of age. The eruption, which first developed five months ago, was limited to the flexor and extensor surfaces of the forearms and the backs of the hands. It was a typical case of lichen planus, with very small, red, flat-topped, umbilicated, violaceous papules, some of which formed linear lesions.

The right hand had received a single intensive dose of the X-ray, five weeks ago. The left hand had received fractional doses of the ray, one application being made each week, over the same period of time. The total dosage in the fractional method was the same as that of the intensive method. Roughly speaking, the result was about the same on both hands. The lesions had entirely disappeared, leaving a pronounced pigmentation. The left hand looked better than the right, because the disease had been less severe there, and because the intensive applications to the right hand had produced an erythema.

In this connection, the speaker called attention to the fact that when an erythema dose was divided into four or eight treatments (fractional method) no erythema would result.

The patient also illustrated another point in X-ray technique. There was an erythema of the right hand which did not develop until five weeks after the intensive dose of the X-ray. The reaction almost always developed within eight or ten days; so this was an instance of a delayed reaction. The speaker wished to emphasize the importance of this point, because it was customary to repeat intensive applications in three or four weeks, if there had been no erythema. If this had been done in this case a second degree radio-dermatitis would have been the result. Instances of delayed reaction were not common, but he had seen several of them.

The patient's arms had been treated with ointments, and arsenic had been administered internally, but there had been no improvement.

The speaker said that as a result of numerous experiments with the fractional and intensive methods, he had found that the latter was the method of election when stimulation was to be avoided, as in epithelioma, tinea tonsurans, lupus vulgaris, etc. The fractional method gave a little better result when stimulation was advantageous, in acne, eczema, etc.

MYCOSIS FUNGOIDES? Presented by Dr. Fordyce.

This patient was from the City Hospital, and presented a slightly reddened and œdematous area, involving the right side of the scalp, the temporal region, and a part of the face. The area was about six inches in its long diameter, and where it involved the scalp it had produced a total alopecia. Scattered over the body, the patient had a number of scaling patches and papules, suggesting a possible mycosis fungoides. The patient had been treated with X-ray, but stated that the loss of hair antedated its use. A piece of tissue had been excised and examined. Several competent histologists had suggested the possibility of the infection being a mycosis fungoides.

Discussion.

Dr. MacKee said he had seen the patient on two occasions, when Dr. Gottheil presented him before the Manhattan Dermatological Society. When first presented by Dr. Gottheil, the lesion was the same size as when presented by Dr. Fordyce, but the skin was very thick and there was considerable crusting and exudation. At that time no X-ray treatment had been given but there was complete loss of hair. A piece of the skin had been removed and studied by a general pathologist, who reported epithelioma originating from the hair follicles. A month later, the patient was shown again, but in the meantime Dr. Gottheil had discovered lesions on the body which had been present for a long time and which resembled parapsoriasis of the Brocq type. At the first presentation, Dr. Wise suggested a localized mycosis fungoides, similar to that reported by Dr. Senear, about a year ago, in The Journal. On the second presentation of the case, Dr. Gottheil had more pathological material, and the pathologist suggested mycosis fungoides. The pathological report, which was read at the meeting, was very suggestive of mycosis fungoides. There was a diffuse superficial infiltration of small round cells and plasma cells with karyokinetic figures and a few multi-nucleated cells.

Dr. Heimann said he has seen the case when it was in Dr. Goldenberg's service at the Mount Sinai Hospital, and that he had examined a slide given to him by Dr. Goldenberg. At that time, the microscopic picture suggested three possibilities, mycosis fungoides, sarcoma, and endothelioma,—the first seeming the most likely. Since then, other specimens prepared by Dr. Levin for Dr. Gottheil confirmed this view. It was difficult to imagine, however, that a granuloma of this type could last so long and change so little, and this feature was against the diagnosis of mycosis fungoides.

BILATERAL SYPHILITIC ULCERATION OF THE TONSILS. Presented by Drs. MacKee and Wise.

The patient, E. W. S., from Dr. Fordyce's clinic, was nineteen years of age, born in the United States, and gave a history of having had a chancre four and a half months ago. There was a very extensive bilateral ulceration of the tonsils, and the glands in the neck were enlarged, due to secondary infection.

RHINOPHYMA AFTER OPERATION. Presented by Dr. Howard Fox.

The patient, M. D., was a man, fifty-eight years of age, born in Ireland, a driver by occupation. The nose had begun to be inflamed about fifteen years ago. Since then, it had gradually increased in size. He had always been a fairly heavy drinker of beer and whiskey. The patient had recently been operated upon at the German Hospital by Dr. Rehling, for the removal of a well-marked rhinophyma. The operation consisted of ablation of the tumor masses without subsequent skin grafting. Before operation, he presented three large masses upon the nose, two of these being somewhat pedunculated. The follicles were patulous and, upon pressure, numerous sebaceous plugs and a thin yellowish bad-smelling fluid could be expressed.

SEBORRHŒIC ECZEMA. Presented by Dr. Trimble.

The patient was a young man who came to the clinic for the first time that afternoon, so that only a cursory clinical examination had been made. The condition seemed to be a seborrhœic eczema on both legs. The lesions were circinate, and the rings were amalgamated, as in the condition occasionally seen on the chest. The location and the configuration of the lesions were interesting.

Discussion.

Dr. Wise considered the eruption to be one of livedo reticulata (or cutis marmorata), the surface having become eczematous from exposure to cold.

Dr. Howard Fox thought that the condition showed all the symptoms of an eczema, except moisture. He thought it corresponded to the clinical type of eczema *craquelé*, described by French writers.

OCCUPATIONAL DERMATOSIS. Presented by Dr. Heimann.

The patient, a young man of thirty, was shown to illustrate an unusual type of lesion. Five days previously, he had taken a position as dishwasher, and had worked steadily for thirteen hours, using a white soap paste. That night the eruption suddenly appeared, attended by severe burning. The hands, chiefly the right, which had been used more, were œdematous and covered with vesicles, containing serum and blood. The latter characteristic was the unusual one, to illustrate which the case had been shown.

PITYRIASIS RUBRA PILARIS. Presented by Dr. Heimann.

The patient was a man, about thirty-five years old, and had always been well. The eruption had appeared seven months ago, and was attended by a very slight itching. The lesions from the start had been disseminated, but were increasing in number. The lesions resembled those of either lichen acuminatus or spinulosus, but on his buccal mucosa there were lesions open to no other explanation than that of lichen planus.

Discussion.

Dr. Trimble said that if one could make a diagnosis of lichen planus by mouth lesions alone, he would say that the lesions in the mouth resembled lichen planus, but making diagnoses of cutaneous eruptions by what was seen in the mouth was simply guessing. The spines that projected on some of the lesions

fitted quite closely to the clinical description of lichen spinulosus, and he thought the disease was one of that nature.

Dr. G. H. Fox said that from his study of pityriasis rubra pilaris, he felt confident that this case would never present the characteristic features of that disease, and he agreed with Dr. Trimble that lichen spinulosus was a good name for the condition. It seemed to be a follicular keratosis.

Dr. Heimann said that he had considered these two conditions and had ruled out lichen spinulosus on account of the condition in the mouth.

NEW YORK ACADEMY OF MEDICINE, SECTION ON DERMATOLOGY.

Regular Meeting, Feb. 1, 1916.

Charles M. Williams, M.D., *Chairman.*

HORNY GROWTHS OF PENIS. Presented by Dr. Lane.

The growths followed circumcision for congenital phimosis, on Aug. 30, 1915. At the time of circumcision, the inner side of the prepuce was covered with a large mass of acuminate condylomata. The glans was smooth but somewhat macerated. About six weeks after circumcision, the growths presented began to appear, one in the sulcus and the other on the end of the glans, close to the meatus. They had steadily increased in size. The horny growths had dropped off spontaneously, two or three times, being shortly replaced by new ones.

PAPULO-NECROTIC TUBERCULOSIS. Presented by Dr. Chargin for Dr. Goldenberg.

The patient, M. G., was 23 years old, single, and a clothing cutter by trade. The father died of cancer(?), the mother probably of tuberculosis. He had one brother and two sisters, living and well. The personal history was negative. There was no evident tuberculosis. The von Pirquet test was positive, and the urine showed a trace of albumen. The affection made its appearance, for the first time, three years ago, during the cold weather, and recurred every winter, disappearing during the summer. It consisted of pinhead- to pea-sized nodules imbedded in the skin, which gradually came to the surface, and developed slight pustules in their centres, finally producing ulcerations and leaving superficial, round, or oval scars, the entire cycle being about two to three months. Some of the lesions cleared up without pustule or scar formation. The areas affected were the forearms (extensor surfaces) especially in the region of the olecranons, dorsum of hands and fingers, ears, with a few areas on the lower extremities and back. At the time of presentation there were isolated and grouped active lesions on the dorsum of both hands and fingers, a few over the olecranon processes, and lower extremities. Scars, the remnants of former lesions, were discernible at the above noted locations. A biopsy showed the picture of hydradenitis destruens.

Discussion.

Dr. Chargin asked whether the process in this disease was essentially tuberculous, or just a disturbance of the sweat glands due to tuberculosis. He requested suggestions on treatment.

Dr. Pollitzer said that he had described the disease first, in 1891, and had not called it a tuberculide, that term having been originated by Darier about eight years later. The speaker stated that in his early descriptions he had noted marked changes in the coil-glands which he had ascribed to an effort at elimination, but that no one had ever proven the relation of the disease to tuberculosis. Philippson had shown that an endo-phlebitis was the starting point of the pathological process, which slightly resembled tuberculosis. There was no satisfactory therapy, but the speaker mentioned that the first case he had seen was permanently cured after a course of mixed treatment.

Dr. Heimann said that he had examined a specimen from Dr. Chargin's case, and that it corresponded microscopically to Dr. Pollitzer's original description.

URTICARIA PIGMENTOSA. Presented by Dr. Rothwell for Dr. Kingsbury.

The patient, H. J., was 6½ months old. Two and a half months ago, there appeared on the upper right thigh a "pink spot," the size of a little finger nail. It seemed to persist, and during the next two months others appeared all over the body (both legs, trunk, arms, neck and face). There remained, after each spot, a brownish pigmentation. There might have been between 100 and 150 such spots of pigmentation, generally of about the size of the end of a match, though the original spot was considerably larger. The mother did not know of any itching. Except for green stools for two months preceding the eruption, the general health was unaffected.

BAZIN'S DISEASE AND SCROFULODERMA. Presented by Dr. Parounagian.

The patient was a man, aged twenty-nine years, an Armenian laborer. His father was living and in good health; his mother was dead. She had had a cough for a long time. His skin affection began on the right leg, about five years ago, and a year later, lesions on the chest and neck appeared. He had scars of broken-down glands in the neck, upper part of the sternum and both axillæ. The lesions on the right leg, beginning from the knees, extended to the ankle. They were mostly on the lateral surface, consisting of pigmented scars and a few active lesions on the upper portion of the leg. The Wassermann reaction, in August, 1915, was negative. He had had two salvarsan injections without any benefit.

Discussion.

Dr. Oulmann said that he considered the case one of syphilis despite the absence of the positive Wassermann reaction, and failure to yield to specific therapy.

Dr. Pollitzer said that he considered the case one of tuberculosis of the skin, but not erythema induratum.

LUPUS VULGARIS SERPIGINOSUS. Presented by Dr. Howard Fox.

The duration of the disease was eleven years, beginning with gradual enlargement of the lesions on the forehead and cheek, in a serpiginous manner. A biopsy showed a typical tuberculous structure. The case had been previously presented before the New York Dermatological Society.

Discussion.

Dr. Fox said that he had considered the possibility of the case being one of lepra, syphilis, lupus vulgaris or lupus erythematosus. Lepra could be ex-

cluded by the absence of the Hansen bacilli in the sections, lupus erythermatosus by the absence of scaling, and syphilis by its clinical course. By elimination, the diagnosis of lupus vulgaris had been made and this conclusion had been borne out by the microscopic examination.

Dr. Trimble said that but for the history he would have favored a diagnosis of lupus erythematosus.

Dr. Williams said that the case impressed him as an aberrant form of skin tuberculosis, but that it lacked the scarring and nodules of lupus.

LEUCODERMA PALPEBRARUM. Presented by Dr. Bechet.

The condition had been present for five years. The patient, an adult male, stated that the disease had been limited to the lesion in question, no other part of the body being involved. The vitiliginous area had been steadily improving; it had first involved the entire orbicular region, but had faded gradually, until at the time of examination, only one half of the original lesion was discernible. The line of demarcation between the white and black hairs on the eyelashes and brow was very marked. The case came from the service of Dr. Kingsbury at the Skin and Cancer Hospital.

Discussion.

Dr. Williams said that he considered the case one of alopecia areata.

Dr. Oulmann said that the history confirmed the diagnosis of alopecia areata.

CASE FOR DIAGNOSIS. Presented by Dr. Rothwell for Dr. Trimble.

The patient, H. E., was 42 years old. Four years ago, there appeared on the left leg, outer side, a small, colorless elevation, which gave no subjective symptoms, and to which he paid no attention. During the following two years, others appeared and he gradually noticed itching, which became more and more troublesome. The patient had cirrhosis of the liver. Covering pretty generally both legs, below the knees, there was an eruption of closely aggregated, follicular plugs, forming colorless papules. They were generally rounded at the top, though some seemed rather more acuminate. No other involvement of the surface was apparent. The patient complained of itching, though it was thought this was not very troublesome. He said he "never bothered about it."

Discussion.

Dr. Pollitzer said that the thickening of the skin, the horny papules, indicated a form of lichenification, with especial involvement of the follicles. The two diagnoses which suggested themselves were lichen circumscriptus of Vidal or mild pityriasis rubra pilaris, but the former was the more likely.

Dr. Trimble said that one interesting feature of the case was that the patient had some hepatic disease. This was supposed to be cirrhosis, but personally he thought it might be carcinoma of the liver. If such was the case, the cutaneous manifestation might be remotely caused by it. He said that at the clinic, a provisional diagnosis of Darier's disease had been made, and some specimens were taken with that idea in view. Lichen simplex had also been considered, but not very seriously.

Dr. MacKee said that he agreed with Dr. Pollitzer's views, but that Darier's disease could not be entirely excluded, and mentioned that he had seen a case with similar papules in the elbow flexures and groin which proved to be psorospermosis.

In addition, the following cases were presented:

CHEILITIS EXFOLIATIVA. Presented by Dr. Gilmour.

LICHEN HYPERTROPHICUS. Presented by Drs. MacKee and Wise.

LUPUS VULGARIS. Presented by Dr. Parounagian.

LUPUS VULGARIS. Presented by Dr. Goldenberg.

PAPULO-SQUAMOUS SYPHILIDE. Presented by Drs. MacKee and Wise.

CONGENITAL HYPERTRICHOSIS. Presented by Dr. Howard Fox.

NEW YORK ACADEMY OF MEDICINE, SECTION ON DERMATOLOGY.

Regular Meeting, March 7, 1916.

Charles M. Williams, M.D., *Chairman.*

MÖLLER'S GLOSSITIS. Presented by Dr. Heimann.

The patient, Mrs. D., was aged forty-two years. The illness was of two years' duration, and consisted of a salmon red, glistening area on the tip of the tongue. The lesion was rounded, the size of a ten-cent piece, extending backwards over the dorsum of the tongue, and was studded with minute, bright red dots, corresponding to inflamed papillæ. Contact with acid foods caused severe pain, and the hard palate also hurt, but showed no lesions.

Discussion.

Dr. Clark said that the actual cautery had cured a similar case he had observed.

SUBCUTANEOUS GUMMATA. Presented by Dr. Graeser.

The patient, Mrs. G. S., was forty-four years old, married and childless. No history of an initial lesion or secondary syphilis could be obtained. Two years ago, she had had similar painful swellings, which disappeared without treatment. On November 9th, 1915, several swellings, the size of a pea, appeared in the skin on the inner side of the right thigh. These were painful to the touch, not reddened, and the pain came on in attacks, especially at night. They increased in size and number, three on the right thigh, two on the inner surface of the left, and one over each gluteal region, the largest having been about the size of an unshelled almond, the smallest that of a pea. They felt like fibromata in and under the skin. They slowly disappeared under potassium iodide, until only one was left on the inner surface of the right thigh, which was dividing into smaller nodules and was nearly gone on presentation. Microscopic section of the excised nodule showed gumma. The Wassermann test was 4 plus.

LICHEN SCROFULOSORUM. Presented by Dr. Clark.

L. K. was a male, 4½ years old, born in this country. One uncle had tuberculosis. Eight months ago, very small "pimples" appeared in small patches on both hips. Gradually the patches enlarged by new lesions forming at the periphery. The loins, interscapular area, back of neck, upper part of chest, lateral aspect of the upper arms, and posterior aspect of the forearms, near the elbow, were next involved. These patches were circular and irregular in outline. The papules were round or flat, yellowish-brown or red, or almost flesh colored. They did not coalesce. Some of the papules over the lumbar region were shiny and appeared to have a suggestion of an umbilicated centre. The papules did not appear to have a small scale on top. They did not itch much. The patient had a few enlarged cervical glands but not of a scrofulous character. A few of the lesions seemed to have resolved, leaving a brown stain.

Discussion.

Dr. Clark said that, clinically, the case impressed him as one of lichen scrofulosorum. Against this view was the good health of the child, and favoring it was the fact that a paternal uncle was tuberculous. The absence of scaling was due to the cleanliness of the patient. Some of the lesions were umbilicated and suggested, but only remotely, the possibility of lichen planus.

Dr. Aitken said that he thought the case one of lichen planus. He added that the cases of lichen scrofulosorum he had seen had disseminated and isolated lesions over the trunk; that they were flat, occurred in children in institutions, and had decided evidences of scrofula, associated with the eruption.

Dr. Chargin said that he agreed with the diagnosis, considering that the small reddish papules and the grouping were characteristic.

Dr. Rosen said that the case was typical as to color and distribution, and that it was not necessary for the patient to be frankly tuberculous, in order to have lichen scrofulosorum.

Dr. Heimann said that he regarded the case as a classic example of lichen scrofulosorum. He disagreed with Dr. Aitken's views regarding the distribution of the lesions and stated that in this disease discrete papules were rarely if ever present, but that grouping of the sort exhibited here, was a constant feature. The umbilication noted by Dr. Aitken was due to the process of involution. As regarded institutional and cachectic children, lichen scrofulosorum was often seen in such, but more commonly in apparently healthy children, lacking other signs of tuberculosis, of which the dermatosis was actually a forerunner.

PARAPSORIASIS EN GOUTTES. Presented by Dr. Lane.

The patient was a girl, aged twenty-one years. The eruption began four years ago, on the arms. She had been treated in various places, but the skin had never become entirely clear. After an attack of grip, two months ago, the eruption became less prominent for a week or two. The arms, legs and trunk were studded with the typical eruption of parapsoriasis en gouttes.

PHILADELPHIA DERMATOLOGICAL SOCIETY.

Regular Meeting, Mar. 20, 1916.

FRANK CROZER KNOWLES, M.D., *Chairman.*

DERMATITIS HERPETIFORMIS. Presented by DR. HARTZELL.

Male, white, aged 49, iron worker. The patient presented over the entire back and neck, numerous groups of lesions that were papulo-vesicular in character, with some of the vesicles so large as to be bullæ. There were numerous excoriations and considerable inflammatory tissue from the effect of scratching, the itching being intense. While there was some eruption on the anterior surface of the chest, it was not nearly so general as on the posterior nor was there so much grouping. Around the waist line and on the buttocks were several very large bullæ. The speaker said that when he first saw this patient, a few days previously, there were distinct ring formations, but on presentation, however, only the faint pigmentation remained.

The patient stated that he had the first attack on the 14th of June, 1914, and he could give the exact date of each subsequent attack as the onset was so extremely abrupt. About a year ago, the lesions, according to his statement, had been distinctly serpiginous. The eruption presented, had appeared ten days ago, after a two weeks' interval of freedom. When arsenic was given in large doses, the lesion would entirely disappear.

DISCUSSION.

DR. SCHAMBERG remarked that the bullous eruption so frequently seen after vaccination indicated a possible infection and *a priori*, he felt that dermatitis herpetiformis might arise from some infection.

DR. HARTZELL acknowledged the possibility of this but said that it had not been proved as yet.

ECZEMA. Presented by DR. GASKILL FOR DR. STELWAGON.

Male, white, aged 26; book salesman. For ten weeks the patient had had an eruption on the forehead, directly along the line of the hat band. It was papulo-squamous in character and had been extremely rebellious to treatment. For eight years he had had a similar type of eruption on the hands and wrists but this was the first time in which it had made its appearance on the forehead. He had had various treatments and on one occasion the eruption on the wrist had been completely cured by means of the X-ray and at other times by various kinds of drugs.

DISCUSSION.

DR. SCHAMBERG said that he felt that eczema should be separated from chronic dermatitis.

DR. HARTZELL remarked that a dermatitis was due to a local irritant and an eczema was nothing more than a chronic dermatitis. It was suggested that this patient should use very soothing lotions rather than stimulating ones and that the wearing of a soft hat, thereby avoiding the friction that comes from the tight hat band, might be of value.

CASE FOR DIAGNOSIS. Presented by Dr. Schamberg.

Female, white, aged 42. The patient had had the eruption for eight days; it consisted of large, flat papules and vesicles with intervening healthy skin, situated mostly on the trunk, anteriorly and posteriorly, while the face was only slightly involved. There was considerable grouping in certain areas and the skin over the entire trunk was very inflammatory. It was thought by some that this was a case of pityriasis rosea, particularly as there were several lesions of a yellowish tint, irregular in outline; this was especially noted under the chin. Upon closer examination, however, it was found there were numerous vesicular lesions, particularly around the waist line; but Dr. Hartzell remarked that he had seen several cases of typical pityriasis rosea transformed into other types of skin diseases by the use of irritating lotions; in this case, the patient had, in the eight days, been seen by seven or eight different general practitioners and had had at least one preparation containing tar, as the odor was very noticeable.

LUPUS VULGARIS. Presented by Dr. Strauss.

Female, white, aged 16. On the tip of the patient's nose there was a large cauliflower-like projection, distinctly warty in character, fissured and extremely red, though the speaker said that when he had first seen the condition, it was covered with a thick, yellowish-brown crust. The lesion had had its onset about one year previously and has been growing steadily ever since. On the right cheek, near the malar eminence, was a small group of pea-sized nodules, covering an area of about the size of a five cent piece; between the individual lesions was considerable scar tissue, though there had not been any attempt at treatment. This scarring was much more suggestive of a tertiary syphilis than that of lupus vulgaris, but the diagnosis was clearly that of the latter condition and the lesion on the nose was of the hypertrophic variety.

SECONDARY SYPHILIS. Presented by Dr. Schamberg.

Female, negro, aged 24. On the arms of the patient were numerous circinate lesions with pigmented centres which bore only a remote resemblance to a typical annular secondary syphilis, but on the back and buttocks were numerous pigmented lesions, flat, rather irregular in character, each of which, according to the history, was preceded by a single large pustule. The case had been under observation for some time at the Polyclinic Hospital and in spite of the negative Wassermann, the patient has been given a one-eighth grain of protoiodide of mercury, t. i. d. There was marked adenopathy but no mucous patches nor condylomata; and there were not more than thirty lesions on the entire trunk and probably an equal number on the arms, with also a very few on the legs. While it was by no means a typical case, yet the speaker's diagnosis of secondary syphilis was corroborated.

TERTIARY SYPHILIS. Presented by Dr. Gaskill.

Male, white, aged 46. This patient presented on the scalp numerous nodular lesions, some occurring in groups and others isolated; in all, perhaps about thirty. Extending from the median line to the left ear at the hair line, was a serpiginous border, more or less nodular in character, which, as Dr. Hartzell remarked, was sufficient to enable one to make the diagnosis, even without any other evidence. The eruption had been extremely itchy and the patient had been treated for several months by a local practitioner, for an eczema of the scalp,

the syphilitic nature of the eruption not having been recognized. He had been under observation for two weeks and had been given potassium iodide with considerable improvement, except in the question of itching, which was still a marked feature. The patient was a heavy drinker, which might account for some of the inflammatory symptoms around the lesions.

EXTENSIVE CASE OF SYCOSIS VULGARIS. Presented by Dr. Gaskill.

The patient had had the eruption, which was typically that of sycosis vulgaris, on the bearded portion of the cheeks and chin for about three years and on the upper lip, where it first made its appearance, several months previously. About six months ago, it developed on the eyebrows where it was not absolutely confined to the heavy hair line but there were numerous pustules above, surrounding the fine hair follicles.

PRURIGO NODULARIS. Presented by Dr. Schamberg.

Female, white, aged 38. This patient had had the eruption for three years. It consisted of numerous nodular lesions, varying in size from a small pea to a bean, on both thighs and a few scattered ones on the lower limbs. There were also a few on the arms, and the tops of many of them had been removed in the frantic efforts to relieve the intense itching. According to the patient's statements, none of the lesions had ever entirely disappeared, though this was questionable as there were numerous small, pigmented spots which were indicative of previous lesions.

Discussion.

Dr. Knowles remarked that he had given this patient X-ray treatment at the Pennsylvania Hospital for two months; and Dr. Gaskill said that he had seen the case at the Jefferson Hospital over a year ago, had taken numerous photographs and excised several nodules which he had examined thoroughly, with the idea of reporting the case in a future article.

COMBINED PORT WINE AND CAVERNOUS TYPE OF NÆVUS. Presented by Dr. Gaskill.

Male, white, aged 37. Beginning at the lower third of the left scapula and extending downward until it covered an area six inches by four, at the widest point, was an unusual type of nævus. It followed almost exactly the outline of the map of Africa with the apex downward. It combined the type of the port wine nævus with small areas of the cavernous type, here and there, over the entire lesion. This cavernous type was much more noticeable around the margin where there was, in places, considerable elevation. About six months ago, when this patient was first seen by the speaker, there was considerable degeneration of the skin at the apex. The question of excision was considered at that time, but on account of its large size, and the inability to draw the skin together and the desire to avoid skin grafting, operative measures were postponed for the time being, carbon dioxide snow being used instead. Several applications were made, with apparently very satisfactory results. There was considerable diminution of color, with some flattening where the snow was applied. At the time of presentation, at the base of the triangle, was another small area which seemed to be undergoing the same type of degeneration with maceration of the skin and considerable softening.

LUPUS VULGARIS AND EPITHELIOMA. Presented by Dr. Schamberg.

Male, white, aged 62. Five years ago, an eruption made its appearance on the left side of the patient's neck and at the time of presentation there was remaining considerable scarring, following very extensive treatment by various methods. At the lower border, however, there was distinctive lupus tissue of a very superficial type. The greatest improvement had taken place under intensive X-ray treatment. On the tip of the nose, however, an epithelioma had developed, which probably had been planted on the lupus tissue. This had been treated by massive X-ray exposures, with apparently perfect recovery, though with considerable scarring.

VITILIGO. Presented by Dr. Gaskill.

Female, negro, aged 40. On the right side of the forehead at the hair line, was an irregular shaped lesion, about the size of a hen's egg, in which there was an entire absence of pigment, not only in the skin, but in the hair as well, the contrast between the jet black hair and the pure white being even more striking than that between the brown skin and the white spot. This patient had been seen about four months ago by the speaker, with a history that the disease began seven months prior to that time, it having required just about one year to produce the change which was present. The appearance was so startling that the patient felt obliged to wear a wig to avoid being conspicuous.

REACTION OF FOOD PRODUCTS. Presented by Dr. Strickler.

Male, white, aged 26. The patient had had an exudating dermatitis which would recur at frequent intervals and which at the time of presentation was seen on the dorsum of the hands and arms; the nose and ears were both very much inflamed and œdematous. The extract of beef had been injected under the right arm, with the control very near to it, and there was a marked area of inflammation around the first injection.

CASE FOR DIAGNOSIS. Presented by Dr. Hirschler.

Male, white, aged 30. The eruption was more or less generalized; rather more pronounced on the trunk, arms and face than on the lower extremities. It consisted of isolated, flat papules, occurring, at times, in small groups. There was considerable itching, and glistening was also a marked feature. The eruption made its appearance about four weeks ago and had become progressively worse. While the lesions were mostly of the flat papular type, some of them had had the tops scratched off in the effort to relieve the intense itching. It was thought by some that the eruption might be a secondary syphilis, but by others was thought to be too inflammatory; and in addition, there were no concomitant symptoms and the diagnosis of lichen planus was much more seriously considered.

Henry K. Gaskill, M.D.,
Secretary.

REVIEW

OF

DERMATOLOGY AND SYPHILIS.

Under the direction of

FRED WISE, M.D., New York,

Assisted by

CLARENCE A. BAER, M.D., Milwaukee.
WILLIAM H. BAUGHMAN, M.D., New York.
PAUL E. BECHET, M.D., New York.
J. S. EISENSTAEDT, M.D., Chicago.
CHARLES GOOSMANN, M.D., Cincinnati.
JAMES F. GRATTAN, M.D., New York.
ROBERT C. JAMIESON, M.D., Detroit.
FREDERICK T. LAU, M.D., New York.
M. F. LAUTMAN, M.D., Hot Springs.
OSCAR L. LEVIN, M.D., New York.
M. L. RAVITCH, M.D., Louisville.
ISADORE ROSEN, M.D., New York.
MAX SCHEER, M.D., New York.
PHILIP F. SHAFFNER, M.D., Chicago.
A. W. STILLIANS, M.D., Chicago.
JOHN H. STOKES, M.D., Chicago.
HARVEY P. TOWLE, M.D., Boston.
VICENTE PARDO, M.D., Havana, Cuba.

MUENCHENER MEDIZINISCHE WOCHENSCHRIFT.

(Sept. 7, 1915, lxii, No. 36.)

Abstracted by ARTHUR WILLIAM STILLIANS, M.D.

THE SERODIAGNOSIS OF SYPHILIS WITH CHEMICAL SUBSTANCES (COAGULATION REACTION). VON DUNGERN, p. 1212.

Credit for most of the work connected with this research is given to Jaudas, the author's laborant. Luetic sera, diluted with water and mixed with various chemicals, coagulate on heating much more readily than other sera. The reagent for the new test is made by adding 1 gm. indigo to 4 cc. concentrated sulphuric acid, and the mixture diluted to 100 cc. with distilled water. Within fifteen minutes of the time of the test, 1 cc. of this reagent is mixed with 0.25 cc. of Fehling's solution B. Of this combination, 0.2 cc. is added to 0.3 cc. of the serum to be tested and allowed to stand a half hour. Then it is put in a small, thin walled test tube and held in boiling water for one minute. After again standing two hours, the reaction is read. Positive sera are jellied. Negative sera are liquid. In 250 cases, the test corresponded closely with the Wassermann. Six cases of bone tuberculosis, one carcinoma of the larynx and two cases of gout, gave positive tests. The author thinks that the test may be useful as a preliminary orienting reaction, when a Wassermann cannot easily be obtained.

THE CONSTRICTOR AS AN AID IN THE DIAGNOSIS OF TYPHUS. C. DIETSCH, p. 1231.

The difficulty of differentiating typhus from typhoid with abundant rose spots is dwelt upon, and also the difficulty of detecting typhus with a sparse eruption, in the frequent cases in which the eruption is hidden by the abundant lesions of pediculosis. The author describes the effect upon the lesions of typhus, brought about by the use of an ordinary arm constrictor. The pink macules of the first stage become deeper in color and more distinct, so that macules appear that were not seen before. The lesions of the second stage become still darker, while the pigment macules of the third stage take on a more cyanotic appearance, returning to the appearance of the lesions of the second stage. No such changes occur in the lesions of pediculosis or of typhoid. After removal of the constrictor, the lesions return to their former color. When the only lesions are on the trunk, a dry cup may be used; but it must be allowed a longer time because its action is weaker. The constrictor brings out the change in about a minute. This procedure has clinched the diagnosis even in convalescent cases.

Another help to diagnosis is the use of soothing applications, which hasten the clearing up of the lesions of pediculosis but do not affect those of typhus. He mentions also the histologic findings of Frankel and the emphasis laid upon the palmar lesions by Brauer. The author has often noticed the lesions especially numerous in the bend of the elbow.

POISONING FROM PROPHYLACTIC USE OF SULPHUR AND ITS PREVENTION. E. HESSE, p. 1236.

Neumayer has repoprted a cholera-like attack after the use of sulphur in his clothing to prevent lice. After a long, hard march, during which he sweated profusely, he had a severe attack of diarrhœa, increasing in severity for three days and ending in collapse. Hesse reports the case of a three months' old child with a slight eczema but otherwise healthy, which, after each application of a 10% sulphur-zinc paste, had an attack of fever and diarrhœa. Another case, using a 15% sulphur soap ointment for scabies, was taken with diarrhœa and fever after the third application of the ointment. For those who sweat freely, he recommends diluting the sulphur used to prevent lice, with an equal quantity of talcum, or the use of a lotion of 10 parts each, of zinc oxide and talc, and 20 parts each, of sulphur and glycerine.

(*Ibidem*, Sept. 14, 1915, lxii, No. 37.)

ARSENICAL KERATOSES AFTER SALVARSAN. C. PHILIP, p. 1248.

A woman of 22 years was delivered of a child, in February, 1915. After the birth of her child, the sore throat which she had had for several months grew worse, and in April, 1915, she had typical luetic ulcers on the palate and tonsils, a papular eruption on the legs and a positive Wassermann. She was given 0.45 gm. of neosalvarsan, a course of inunctions and a second dose of neosalvarsan of the same size, eleven days after the first one. On the day after this second injection, she broke out with a dark red, papular rash over the whole body, accompanied with a temperature from 38° to 40° C. On coming under the care of the author, three and a half weeks later, she had a dark red to bluish-red, confluent eruption, with many bullæ from the size of a quarter to that of a silver dollar, some of them containing a bloody fluid. The scalp was covered by a weeping dermatitis and the hair was rapidly being lost.

The skin of the palms and soles was exfoliating in large sheets. No urine had been passed for 24 hours; 300 cc. were obtained by catheterization, containing neither sugar nor albumin. In a few days the skin cleared up and the urinary output became normal; but typical arsenical keratoses developed on the palms and soles, and the finger nails became brittle and fell off. The scalp was almost entirely bald. The temperature was practically normal when the author first saw her and did not rise again.

The author bases his diagnosis of arsenical poisoning on the keratoses, and explains that the dosage was too high for this patient, a small woman (about 78 pounds), who had an old phthisis and who had recently been delivered of a child.

ECZEMA AFTER THE USE OF PELLIDOL SALVE. A. Stoerzer, p. 1270.

Since October, 1914, the author and his colleagues in one of the military hospitals in Freiburg have been using an ointment of pellidol (diacetylamidoazotoluol), to stimulate epithelialization of wounds, with good results. Recently it was used on a large wound of the thigh, and on the same day the patient began to complain of itching and on the next day the area covered by the dressing was affected by a bright red, papular eruption, with outlying lesions over the rest of the thigh. In order to determine whether the pellidol was responsible, the author applied a similar dressing to the left forearm with the same result, and in spite of his efforts to control it, the eruption spread over the whole body, except the face. The original area became vesicular and the groins, axillæ, umbilical region, flexor surfaces of the knees and the palms were more severely involved than the rest of the body. He believes that there has been no previous report of an artificial eczema from pellidol.

(*Ibidem*, Sept. 28, 1915, lxii, No. 39.)

THE VALUE OF THE HISTORY, THE CLINICAL FINDINGS AND THE WASSERMANN REACTION IN THE DETECTION OF SYPHILITIC INFECTION AMONG THE GENERAL POPULATION. G. Hubert, p. 1314.

The author presents statistics of all patients treated in the Romberg medical clinic, in Munich, between October, 1912, and July, 1915. Care was taken to inquire into the possibility of a syphilitic infection and into all points in the history raising a suspicion of such an infection, and a Wassermann test was done on every case. Of 8652 cases, 739 were clinically diagnosed as luetic, in 19 cases of luetic aortitis and in one case of tabes, the diagnosis was made only post-mortem. This gives 8.8% syphilitics among their patients. The histories were entirely negative as to syphilis in 52% of the men and 75% of the women who were shown to be luetic. The tabes cases were absolutely negative as to history or signs of lues other than the nervous symptoms in 50% of the men and 65% of the women. The author warns against neglecting the most careful search for signs and history indicative of syphilis; but his experience shows that the Wassermann reaction is the only means, in many cases, of establishing a connection between the existing disorder and an old lues.

ANNALES DES MALADIES VÉNÉRIENNES.

(January, 1915, x, No. 1.)

Abstracted by PAUL E. BECHET, M.D.

RAYNAUD'S DISEASE AND SECONDARY SYPHILIS. GAUCHER, BIZARD AND BRALEZ, p. 7.

Gaucher, Bizard and Bralez believe that secondary syphilis plays a more important rôle in the causation of Raynaud's disease than it has heretofore been credited with. They quote Hutchinson as having observed several cases of acroasphyxia which were cured under antisyphilitic treatment. A clinical report of a case of Raynaud's disease in a luetic, markedly improved by specific treatment, is appended.

SYNDROME OF RAYNAUD'S DISEASE AND SYPHILIS. NICHOLAS, MASSIA, GATE AND PILLON, p. 13.

The authors report a case of acroasphyxia in a woman, forty years of age, with no syphilitic manifestations, and a negative Wassermann reaction. Her husband denied syphilis but had suspicious lesions on the hands and a positive Wassermann reaction. The acroasphyxia almost completely disappeared, following antisyphilitic treatment.

(*Ibidem*, March, 1915, x, No. 3.)

NOTES ON THE MODE OF CONTAGION IN SYPHILITIC CHANCRES AND INDIVIDUAL PROPHYLAXIS IN SYPHILIS. BALZER AND BARTHÉLEMY, p. 129.

Balzer and Barthélemy believe that, besides by direct inoculation, syphilis can be transmitted without abrasion. The spirochætæ can be deposited on normal integument, and under favorable conditions of warmth and moisture, proliferate, and penetrating the epidermis, result in a typical chancre. They believe that the long period of incubation in certain cases can only be accounted for in this way. Another method of contagion is through vehiculation; the spirochætæ are deposited on the lips and are carried by the tongue and saliva to the tonsils. All cases of tonsillar chancre are not due to unnatural sexual acts. They believe that the spirochætæ are able to travel by aid of their own movements; this would account for the chancres which occasionallly occur in the *cul de sac* of the eyelids, the endometrium of the cervix, etc.

INITIAL LESION ON THE CONJUNCTIVA. ANTONELLI, p. 134.
Report of a case.

ACTAS DERMO-SIFILOGRAFICAS.

(Oct. and Nov., 1915, viii, No. 1)

Abstracted by VICENTE PARDO, M.D.

TWO CASES OF CUTANEOUS LEISHMANIOSIS FROM PERU. I. MORAN, p. 1.

The author describes two cases of the disease, patients from the shore of a Peruvian river named "Madre de Dios," where different forms of Leishmaniosis are endemic.

He divides the cutaneous manifestations of Leishmaniosis into a benign form, known under the names of Oriental Sore, Aleppo Boil, Biskra Boil, Tash-Kend Sore, etc., ending always in recovery and producing immunity, not only in the cutaneous form of the disease, but also in the visceral (Kala-Azar), which is considered to be due to the same parasite; and a grave form, endemic in South America, known under the names of Peruvian Uta, Brazilian Sore, Spundia, Bauru, etc., which creates serious and destructive cutaneous troubles, leading sometimes to extensive and irreparable mutilations of the mucous membranes of the mouth and nose and the cutaneous surface.

The author's cases belong to the latter group and the diagnosis was verified by microscopical examinations; he detected in both cases, round bodies, clearly stained with Giemsa, lying midst numerous bacteria. These bodies are believed by the author to be Leishman organisms. No flagellated forms were found.

The first case, B. F., 30 years of age, Spaniard, farmer, was working in Peru for 4 years; in 1913, a small boil appeared on the left forearm, which, after suppuration, left a fungating, atonic ulcer of the size of a silver dollar; 20 days later, the same kind of lesion appeared on the tip of the nose with destructive tendency, and invading the mucosa of both nostrils; a few days later, another similar lesion broke out on the left nipple and two months afterwards, on the right leg. The resulting ulcers were treated with the actual cautery locally and with salvarsan and mercury injections internally, all of them healing but that on the tip of the nose, which has continued its destructive process. The general health has not been affected, the Wassermann test is negative and the blood count is normal. The lesion has, notwithstanding, a striking resemblance to either lupus vulgaris or gumma. It is very remarkable that five brothers of this patient, working at the same place, have suffered of the same disease at different times.

The second patient, M. F., 40 years old, married, has several healthy children. In 1912, he emigrated to Peru and there used to work at the same rural occupation as the first patient; six months after the beginning of his work, he noticed a little tumor on his right wrist and gradually similar formations appeared on the left side, arms, forearms, lower extremities, face and lately on the mucosa of the palate and pharynx. The treatment employed in Peru was tincture of iodine and several ointments locally, and internally, potassium iodide and salvarsan, without results. The lesions were never ulcerated but remained in the shape of hard nodules, spreading out in some places with a serpiginous outline; and on the palate they appeared as multiple granulations, accompanied by enormous infiltration and œdema of the surroundings; the Wassermann test was negative.

The patients are still under treatment, the author's therapy being as follows: locally, CO_2 snow every week, pressure being exerted for one minute, and as general treatment, injections of emetine, administered on account of the brilliant results obtained by Drs. Viana and Aragao, of Brazil, in the treatment of Leishmaniosis and Kala-Azar; all cases of this type have perhaps the same ætiology, although the verification of this point is not yet accomplished.

STUDY OF THE VEHICLES FOR INSOLUBLE MERCURIAL SALT INJECTIONS. SAINZ DE AJA, p. 17.

The author believes that in most of the cases, the pain and nodules observed after the injection of insoluble mercurial salts are due to the vehicle. On account of this belief, he has injected 227 patients with different vehicles, without mercury, and his conclusions are as follows:

The best painless excipient is solid vaseline, liquid petrolatum being second in line, "almost painless." Lanoline is quite painful and causes, in most instances, nodules and abscesses. The vegetable fats, as castor oil and olive oil, are inferior to the animal and mineral products used; they are painful and not well absorbable.

A NOTABLE CASE OF MULTIPLE HYDATID CYSTS IN THE SUBCUTANEOUS TISSUE. VICENTE JIMENO, p. 29.

After a well condensed study of the human lesions caused by the Tinea echinococcus, the author expresses the opinion that the location in the subcutaneous tissue is due, in most instances, to the rupture of a large hydatid cyst and the dissemination of the scolices through the circulation. The prognosis is always very serious and the only treatment is surgical, when practicable.

His case, a male, 34 years of age, was operated on, a few years before, for a hydatid cyst of the liver; seven months later he noticed the presence of numerous pea-sized nodules on his neck, and gradually identical lesions appeared, scattered all over the body, reaching 71 in number; they were movable under the skin, painless and of the normal color of the epidermis.

The blood cell examination showed a marked increase of eosinophiles. The diagnosis was verified by the microscopical examination of the biopses.

(*Ibidem*, Dec., 1915, and Jan., 1916, viii, Nos. 12 and 1.)

TWO CASES OF SCROFULODERMA AND TUBERCULOUS FISTULAS, CURED BY RADIOTHERAPY. RATERA, p. 100.

The author relates two cases of tuberculous adenitis of the neck with chronic suppuration and fistulas, treated successfully by the X-ray; after 12 doses of 5 to 6 Benoist units, the lesions subsided and the suppuration disappeared, leaving a solid scar. The cure has remained complete one year after the treatment.

HELIOTHERAPY IN DERMATOLOGY. FERNANDEZ PARTILLA, p. 102.

The author calls attention to the fact that, although artificial light may be used as a therapeutic source, its effects can not be compared with those of sunlight.

He divides the effects produced in the organisms by heliotherapy, into local and general; among the first the most notable and common is the pigmentation of the skin, considered as a reaction of the organism against certain particular rays of short wave (chemical rays): among the second, it is possible to produce an increase of the leucocytes to 6% as well as of the hæmoglobin and red cells, and an increase of the metabolism of nitrogenous products in the tissues.

The author emphasizes the good results obtained by him with this form of therapy, in the treatment of sluggish, varicose ulcers and sores, but chiefly in cases of tuberculosis of the skin: lupus, scrofuloderma, etc. He has treated 23 cases of lupus vulgaris, the results being 14 cases cured, 7 improved and 2 unaffected.

SYPHILITIC CHANCRE OF THE UPPER GUM IN A WOMAN. SICILIA, p. 110.
Case report.

GIORNALE ITALIANO DELLE MALATTIE VENEREE E DELLA PELLE.

(February, 1916, i, No. lvi.)

Abstracted by VICENTE PARDO, M.D.

PRIMITIVE ELEPHANTIASIC TUBERCULOSIS OR DIFFUSE HYPERTROPHIC TUBERCULOMA. BOSELLINI, p. 458.

First of all, it is necessary to establish that the word elephantiasis does not mean a particular disease with a constant ætiological factor; it is only a medical term, applied to some changes in the morphology of the cutaneous tegument.

The author considers as capable of producing elephantiasis, besides the Filaria sanguinis hominis, a great number of microörganisms, as: streptococcus, staphylococcus, pneumococcus, pseudodiphtheritic bacillus, Micrococcus tetragenous, bacillus of Koch, Treponema of Schaudinn, bacillus of Hansen, gonococcus (?), etc.

His case, a woman, 36 years old, married, has an interesting history; her mother, alive, is affected with tuberculosis of the lungs, her father died of an unknown disease. The patient has had 11 pregnancies, 3 of which ended in miscarriages, 4 children are alive and the others died of different diseases; there is no history of malaria and syphilis.

The present disease began with an inguinal adenitis, running its course in about a week, followed by a discharge of pus for some time; since then, the entire lower limb of the left side began to increase in volume from the ankle to the hip, and in the course of a year reached the enormous size of 65 cm. around the knee and 98 cm. at the middle of the thigh; the evolution of the process has been insidious, has been without attacks of lymphangitis, without pain or fever; actually the diseased area is not painful at all and its surface is free from squames, verrucous formations, ulcerations, etc.

The examination of the internal organs shows that they are in a good, healthy state, the urinalysis shows the presence of a slight quantity of albumin, the Wassermann test is negative and the blood-cell count is normal.

The cutaneous tuberculin test being strongly positive, inoculations were made in guinea-pigs, injecting a part of removed tissue peritoneally; the result was highly interesting, insofar as 2 of the 3 injected animals died in 50 to 60 days, with a typical peritoneal tuberculosis.

The histological examination showed acanthosis, cellular infiltration of the corium and numerous tubercle formations in their typical form; the search for the tuberculosis bacillus was negative.

JOURNAL OF THE AMERICAN MEDICAL ASSOCIATION.

(Dec. 4, 1915, lxv, No. 23.)

Abstracted by Wm. H. Baughman, M.D.

THE WASSERMANN TEST IN THE MEDICAL DISPENSARY. J. J. Moore, p. 1980.

A STATISTICAL STUDY OF SYPHILIS AS SEEN IN THE OUT-PATIENT DEPARTMENT OF THE UNIVERSITY OF CALIFORNIA HOSPITAL. J. L. Whitney, p. 1986.

SYPHILIS OF THE SPINE: ITS FREQUENCY AND THE VALUE OF ITS CHARACTERISTIC LESIONS AS A DIAGNOSTIC SIGN OF SYPHILIS. J. L. Whitney and W. I. Baldwin, p. 1989.

Syphilitic arthritis is quite common, the spine being most frequently involved. Of one hundred syphilitic patients examined, only twenty-six had perfectly normal spines, six others were classed as doubtful. All except four of the remaining sixty-eight had spinal abnormalities of a type considered to be more or less characteristic of syphilis by the authors.

Two types of arthritic lesions are recognized, the toxic and the infectious. The former is of the nature of arthritis deformans, with hypertrophic and villous lesions, less frequently atrophic changes, involving many joints, the spine being frequently affected and stiff. Of the infectious type, the gummatous form has been accurately described. Very little attention has been paid to the second form, except where it has occurred in the knees of congenital cases, which is a synovitis without destructive changes, and with which this paper is concerned.

An acute synovitis of the spine causes lessened motion from spasm. As the condition becomes chronic, permanent adhesions are frequently formed, producing limitation of motion or complete fixation, relieved only by forcible manipulation, as antisyphilitic treatment has no effect upon them. With stiffness, there is apt to be a deformity suggestive of early Pott's disease; either a slight prominence of the spine, a flattened area, or a shallow depression. The most characteristic single deformity is a prolongation of the dorsal curve into the dorso-lumbar region, or a flattening at this level. The deformity may not be noted until an area of fixation is shown by tests of mobility. Limitation of stiffness to a few of the vertebral joints, as a rule distinguishes it from arthritis deformans, though the entire spine may be involved.

Active synovitis occurs relatively early after infection, but the deformity and stiffness apparently remain throughout life, without any other evidence of syphilis. Pain is seldom a prominent symptom even in early cases or where destructive lesions are present. No appreciable bony changes are shown in either early or late stages.

Frequently accompanying this stiffness, is a hypotonicity of the ligaments and muscles of uninvolved portions of the spine, the sacro-iliac joints, and the hips. This condition enables many of these patients to touch the floor with fingers or hands, without bending the knees; a condition, however, which cannot be considered diagnostic when occurring alone; but when accompanied by a stiff spine or with areas of restricted mobility, it is regarded by the authors as "almost sure proof of syphilis."

None of the twenty-five non-syphilitic cases selected as controls exhibited either the localized stiffness or the hypotonicity. Unless there were other

positive evidences of syphilis, the Wassermann reaction decided whether or not the case was syphilitic. The authors do not agree with some other writers that the diagnosis of bone and joint syphilis must depend on the Wassermann reaction.

(*Ibidem*, Dec. 11, 1915, lxv, No. 24.)

THE SUGAR CONTENT OF THE BLOOD IN CERTAIN DISEASES OF THE SKIN: A PRELIMINARY REPORT. I. R. Pels, p. 2077.

Examination of specimens from fifty cases, by Epstein's modification of the Benedict-Lewis method, showed practically no increase above the normal, though the tendency was toward the higher percentage limit.

THE INTRASPINAL ARSENIC TREATMENT OF SYPHILIS. G. B. Hassan, p. 2078.

Following Schubert's method, Hassan treated cases of tabes, general paralysis, and cerebrospinal syphilis; injecting usually 0.003 gm. of neosalvarsan, frequently 0.006 gm., and sometimes 0.009 gm. "The most frequent reactions to the injections were shooting pains in the legs and sometimes in the upper extremities, pain in the back and between the shoulders, headache, nausea and vomiting, retention of urine, and slight elevation of temperature." The complications were usually of short duration.

No particular subjective improvement was noticed. The spinal fluids showed favorable biological changes.

Two case reports are appended.

NEW YORK MEDICAL JOURNAL.

(Feb. 26, 1916, ciii, No. 9.)

Abstracted by James F. Grattan, M.D.

SYPHILIS AND INTERNAL MEDICINE. L. F. Banker, p. 385.

This paper opens with a review of the improved methods of diagnosis in luetic conditions, beginning with Schaudinn's discovery of the Treponema pallidum in 1905 and mentioning Metchnikoff's and Roux's experimental studies in animals, Schereschewsky's, Laudsteiner's and Mucha's demonstrations of the living parasites, the Chinese ink method of Burri, Nitsche's colloidal silver method, and the silver method of Volpine and Levaditi; the demonstrations of the treponema in aortic aneurysms by Schmorl and J. H. Wright; in the brain by Noguchi and Moore; in tabetic lesions by Marinesco; in the organs and developing teeth in congenital cases and in the placentas of infected fœtuses; the Wassermann reaction with the perfection of its application and its value in symptomless cases and in the determination of cures, as proven by reinfections; the proof by experimental studies that the old method of excising the primary lesion is valueless because the general distribution has taken place before the sore appears; the discovery that immediate application of bichloride of mercury to the portal of entry can prevent the infection, if applied within a few hours. All these advances in the diagnostic armamentarium have been contributed within the last ten years. The older "belief" in a diagnosis has been replaced by certainty because of the perfection of these methods. The clinical value of the methods is well illustrated by the citation of seven very interesting cases of

doubtful significance, until cleared up by the application of the newer diagnostic procedures. Dr. Banker gives the following list of obscure conditions demanding a consideration of lues as a basis: 1. Long continued fever otherwise unexplained; 2. Obscure nervous cases, both functional and organic, with transient symptoms; 3. Chronic laryngitis, tracheal and bronchial stenosis, bronchiectasis and unexplained infiltration of, or masses in the lungs or pleuræ; 4. Aneurysms; 5. Aortic insufficiencies, especially in absence of other valvular lesions; 6. Heart block and other arrhythmias; 7. Arterial and venous thromboses; 8. Certain grave anæmias resembling the Addison-Biermer type; 9. Paroxysmal hæmaglobinurias; 10. Indolent nodules in the tongue or tonsils; 11. Enlargements of the liver or spleen; 12. Strictures of the rectum; 13. Atypical joint diseases, especially obscure diseases of the spine; 14. Thickenings or nodules in the bones, especially when accompanied by nocturnal pain; 15. Unusual forms of renal diseases; 16. Chronic orchitis, or nodules in the testes; 17. Repeated miscarriages; 18. Still-births; 19. In metabolic and internal secretion cases.

The author then relates two cases where syphilis could be ruled out by means of the newer methods and concludes by giving a second list of conditions which can occur without lues as a basis or independent of lues, though the latter be present: 1. Cerebral apoplexy; 2. High blood pressure cases; 3. Contracted kidneys; 4. Multiple sclerosis; 5. Certain suspicious lesions due to sporotrichosis or blastomycosis of the bones, lungs or subcutaneous tissue; 6. Psychoneurotic states accompanied by syphilophobia; 7. Graves' disease. His final warning is, "When in doubt, have a Wassermann test made; when not in doubt, still have a Wassermann test made."

UNSUSPECTED SYPHILIS IN NEUROLOGY. J. Collins, p. 389.

The syphilitic nervous diseases are divided into two classes, the assured and the suspected. Under the first head are included tabes, general paresis and cerebral and spinal endarteritis, because these diseases present symptoms that are characteristic and pathognomonic. Under the other head,—the suspected,—are included practically all other nervous symptoms or symptom complexes of indefinite and non-characteristic nature. The author gives a table in which 245 cases are distributed among 32 clinical headings and in all of which syphilis was later proven to exist, but in which it was unsuspected clinically when the cases first presented themselves. Many of these cases are gone over in detail and the effects of antisyphilitic treatment noted. The summary of this comprehensive paper is quoted in full: "Occurrence—syphilis of the nervous system displays itself not infrequently in the guise of practically every disease of that most vital part of the body.

Symptoms—The symptoms of syphilis of the nervous system are in many instances neither pathognomonic nor suggestive. They are often indefinite and inconclusive. Objective symptoms, particularly, are lacking. Multiplicity of symptoms is not the rule, it is the exception.

Diagnosis—The diagnosis cannot be made in the majority of instances from the consideration of the symptoms alone. Information obtained from study of the blood serum and cerebrospinal fluid, substantiated by repeated examination and corroborated by others working with different technique, is absolutely trustworthy and of more diagnostic value than the clinical evidence.

Prognosis—These disorders, apparently unrelated to syphilis, and usually unsuspected, are of good prognosis, unlike the syphilitic nervous diseases that have progressed to the production of pathognomonic objective symptoms.

Treatment—must be of the disease and the patient—for the former, salvarsan and mercury; for the latter, consideration and encouragement."

(*Ibidem*, Apr. 8, 1916, ciii, No. 15.)

SEROLOGY AND THE DIAGNOSIS OF SYPHILIS. M. L. Heidingsfeld, p. 673.

The writer gives all due credit to serology as a factor in the diagnosis and therapeutic control in syphilis, but insists upon the precedence of clinical data over laboratory findings, the latter to be considered as substantiating the former. He condemns the "doubtfully positive" reports, claiming that a test is either positive or negative. If positive, syphilis exists; if negative, it may or may not exist. The Wassermann reaction is valuable to check up the improvement during the early therapeusis, but he recommends the Hecht-Weinberg-Gradwohl test to detect the remaining positive traces, after the Wassermann has become negative. Two cases of tuberculide previously regarded as syphilitic, are cited. The first, diagnosed wrongly because of a "doubtfully positive" Wassermann report, while the mistake in the second case was due to misinterpretation of the history and lesions. The author calls attention to the many cases of mistaken reports and the trouble caused thereby, as sufficient reason for placing clinical evidence above serological findings, and points out the danger of "standing with both feet" upon the laboratory.

MEDICAL RECORD.

(Jan. 29, 1916, lxxxix, No. 5.)

Abstracted by James F. Grattan, M.D.

AN ENZYME THEORY OF CANCER ÆTIOLOGY. L. D. Bristol, p. 180.

This paper embodies a review of the conclusions reached by many of the better workers, past and present, in the field of cancer research. The recognized theories are discussed and their relations to each other and to the author's theory are shown. Precancerous agents are considered and tabulated as follows:

A. Non-infective.

1. Physical (a) Trauma (blow or incision), (b) Heat, (c) Cold, (d) Electricity, (e) Light rays (sunlight, X-rays, radium).
2. Chemical: (a) Drugs, (b) Chemical poisons, (c) Toxines, (d) Abnormal metabolic products, (e) Acids and alkalis.
3. Functional: (a) Over-activity, (b) Disuse.
4. Nutritional: Interference with blood-supply.
5. Referred: Injury at one point referred along a nerve, to a distant part, where it may have its effect.

B. Infective. Living parasitic agents: (a) Bacteria, (b) Protozoa, (c) Infusoria, (d) Flukes, (e) Cestodes, (f) Nefatodes, (g) Insects.

The author's theory is based on the chemistry of the cell and its processes of oxidation. He regards these processes as activated and controlled by the cellular enzymes. The pro-enzymes activate the oxidizing enzymes in the normal cell and the processes of oxidation are contained, within normal limits, by the inhibiting enzymes and the anti-enzymes. The activating enzymes are called peroxidases, the limiting enzymes catalases. By the activation by the one set and the inhibition by the other, balance is maintained in the oxidation processes of the normal cell and it is kept in a state of normal health to perform its function.

Any of the precancerous agents may disturb the normal balance of the oxidation processes in the cell. As a result, the cell is either killed or excessive oxidation goes on, because of the stimulation of the activating enzymes and the destruction of the inhibitors. The cell function is laid aside, the activity of the cell is spent in growth instead of function and the new-born cells inherit the excessive growth properties.

New tissue with excessive oxidation power forms, and a demand is made on the general oxygen supply of the body, so that general function, growth and repair of other organs are disturbed—a state of malnutrition (cachexia) results. This applies to malignant tumors. If the individual possesses immunity, the result of the excessive growth process is a benign tumor. The immunity is attributable to the presence, in the host, of anti-enzymes or inhibiting enzymes (catalases) that limit the general effects of the excessive oxidation processes, going on at the tumor site. The benign tumor, or the inflammatory reaction, is to be regarded as a step toward malignancy, further progress depending upon the presence or absence of anti-enzymes. The other characteristics depend upon the growth properties of the tumor. Conclusions: 1. Cancer is the result of hyper-oxidation (unlimited) in epithelial cells; 2. This is brought about by concentrated, accelerated and uninhibited action of intracellular oxidizing enzymes, the original disturbance having been brought about by one or more of the precancerous agents recognized in the table.

A SYPHILITIC ROSEOLA LIMITED TO THE SOLES. D. W. Montgomery, p. 192.

The author cites a case with a brown, dotted eruption, limited to the soles, without desquamation or subjective symptoms. The specific nature of the phenomenon was determined by the usual methods. Reports by other observers are quoted.

(*Ibidem*, Mar. 4, 1916, lxxxix, No. 10)

USE AND ABUSE OF THE RICE DIET. L. D. Bulkley, p. 407.

The originator of the use of the rice diet in skin conditions reiterates his experiences on his own person in controlling an annually recurring vesico-bullous eruption of the hands, by this simple dietary measure. He blames the poor results of other observers on their failure to follow the exact details of the diet. He relates an interesting self-inflicted experiment in his last attack of the vesico-bullous eruption on the hands. The first indication was a deep itching on the back and sides of the fingers of the right hand, followed by papulo-vesicles on the same hand and itching of the other, in 24 hours. The eruption was allowed to develop for three days because the writer's experience had shown him that it could readily be controlled by the rice diet. In forty-eight hours the itching and swelling ceased and the development of new lesions came to a halt. After five days of the strict diet, the attack ended and desquamation started. The rice diet was followed by a vegetarian diet, without sweets. The author repeats the directions of the diet as used by him: (1) The diet consists exclusively of rice, butter, bread and water, for a period determined by the improvement and the nature and severity of the case. (2) The rice is to be well boiled in water, but not to become soggy. (3) It is to be taken hot with plenty of butter and a little salt. No milk and sugar to be used. (4) It is to be eaten slowly with a fork, not with a spoon, and is to be thoroughly masticated. (5) The white bread used must be at least twenty-four hours old and must be well "fletcherized." (6) Water, hot or cold, is to be taken freely, but

not while food is in the mouth. One-half pint may be taken one hour before the morning and evening meals.

Bulkley believes that many skin eruptions are a manifestation of overtaxed kidneys, due to excessive protein intake. Rice is chosen because it contains least protein of all cereals. Milk must not be used because of its protein content. Where indicated, the diet must be supplemented by local measures, but the author has found these unnecessary in many cases.

RADIUM. A RECOGNITION OF ITS EFFICIENCY AND A PLEA FOR MORE THOROUGH INVESTIGATION. D. C. Moriarta, p. 410.

A definite amount of emanation, which means radio-activity, is always evolved from a given amount of radium. The emanation from a gram of radium, multiplied by thirty, would give a volume of gas about the size of a pin-head. The usual quantities employed are 50 to 500 milligrams. As these quantities usually produce very tangible effects, we can conceive of its wonderful force. In radium "decay" the particle of radium splits into alpha-rays and emanation. The emanation again gives alpha-rays and secondary deposit. The splitting of the secondary deposit gives the beta- and gamma-rays. If the radium is sealed, the splitting process gives general radiation. This is termed the "aging" process. It is only during such "aging" that radioactivity exists. If the radium is open, it may be used by inhalation or in solution in water and the secondary splitting up takes place in the body, just as in a sealed tube.

Alpha-rays are not rays but positively charged helium atoms. Beta-rays are also not rays, but a negatively charged stream of electrons. Gamma-rays are not particles but a vibration of ether, similar to ordinary light. They do not polarize, do not deflect a magnet nor are they deflected by a prism. The rays should be filtered to avoid irritation. Ordinary paper can be used as a filter for the alpha-rays. Beta-rays are divided into soft, medium and hard, according to their filterability. If space is used as a filter, alpha-rays are cut off by three cm. of air, beta-rays by about three times that distance, while gamma-rays can be traced by the electroscope at a distance of 100 meters or can penetrate a man at three meters. For the alpha-rays, paper, lead, rubber or mica are sufficient. Metals are used for the medium and hard beta-rays and the gamma-rays. Silver, aluminum, lead, brass, gold and platinum are used. One cm. of lead absorbs all beta-rays while five cm. are necessary for the gamma-rays. Without filtration, there are ninety alpha- to nine beta- and one gamma-ray. Under strong filtration a total of 600,000 rays are reduced to 5000 (gamma) rays (less than 1%). Certain irritating secondary rays, produced by filtration with a lead screen, can be obliterated by varying thicknesses of rubber tissue.

The density of the tissue is the next factor. The character of the rays, the filtration and the density of the tissue, are the three factors to be considered in radium application. "Cross-firing"—employing the rays on one spot from several directions, or burying in the tissue so that activity occurs in all directions from the tube as a centre, are mentioned as means of intensifying the action. The gamma-rays affect pathological cells in proportion to their youth, embryonic state, and degree of development. Young connective tissue, adjacent to the growth, multiplies vigorously. The control of the malignant state depends upon the stimulation of neighboring normal tissues, as well as upon the destruction of the morbid cells. Epitheliomata and growths of the oral mucosa are very resistant. Burying the radium tube in the tissue, or needle applicators, gives the best results because of the "cross-fire." Burns should be watched for and the tissue guarded when a burn is first detected.

The general effects of radium, when local benefit is obtained, are increased in the red and white blood cells and hæmoglobin, increased carbon dioxide, urea

and uric acid elimination, and increased urine output; and a diminution in the viscosity of the blood. Blood pressure is lowered.

The author believes that the benefits obtained by the use of the Saratoga Spring waters, long attributed to their general chemical combinations, is due to their radium content, because the synthetic products based on their chemical analyses have never given the same results as the natural waters. This is due to the absence of radium, which, he believes, the natural waters contain. In addition to application of the element, the use of the salts intravenously, and by mouth, in solution, is recommended. Twenty-five micrograms of radium chloride is suggested as an initial dose; after that, maintain the body content of radium by the use of activated waters, giving in all 10,000 to 100,000 mache units per day, in four doses. He claims that his results in cases treated are "too brilliant for publication."

A BROADER VIEW OF TABES DORSALIS. F. R. SHARKEY, p. 415.

The phenomena of tabes are due to affection of the autonomico-sympathetic system by the spirochætæ, as well as to the posterior root lesions. The autonomic and sympathetic systems are under the control of the ductless glands. Hence properly selected organo-therapy will control the symptoms referable to the autonomico-sympathetic system. The author argues that although tabes is the result of syphilitic infection, in most cases the signs of syphilis are dormant. Hence these cases should not be treated along antisyphilitic lines. On the contrary, he claims that dormant syphilis should be allowed to remain so, and tabetic cases are harmed by activating the syphilitic infection by arsenic and mercury, usually doing poorly when treated by these drugs. He also believes that luetic cases, vigorously treated in the primary stage, to abort the secondary stage, usually develop severe nervous symptoms, at an early date. The liability to involvement of the nervous system is less in cases with full-blown severe secondary phenomena, because the infection is attenuated. He believes that those cases in which tabes develops, have a disturbance in the glands of internal secretion; and as these control the normal function of the autonomic and sympathetic nervous systems, the vulnerability of the latter is increased by the secretory insufficiency.

(*Ibidem*, Mar. 11, 1916, lxxxix, No. 11.)

INTRAMUSCULAR INJECTIONS OF MERCURY SALICYLATE IN THE TREATMENT OF SYPHILIS. W. H. BEST, p. 473.

The author takes exception to the conclusion of Nelson and Anderson, that mercury salicylate injections, alone and unaided, do not possess any real curative value in syphilis. He reviews their contention that it produced a negative Wassermann in only a few cases, out of a series of 50. Nelson and Anderson gave 1½ grains, once a week, and later lengthened the interval to two weeks. Best claims that the dose is too small and the interval too fixed to include every case. He averages two to three grains and keeps the patient in a state of controllable salivation. Keeping the avenues of elimination open, using atropine for the ptyalism and attending to the mouth toilet are necessary procedures. He relates 10 cases where the Wassermann was beneficially affected by mercury salicylate and potassium iodide.

AMERICAN JOURNAL OF UROLOGY AND SEXOLOGY.

(January, 1916, xii, No. 1.)

Abstracted by Oscar L. Levin, M.D.

A RAPID AND SUCCESSFUL TREATMENT OF SYPHILIS. André Bernheim, p. 5.

This paper is a report of the technique followed, at the Chaptal Supplementary Hospital, to prevent hospitalization of syphilitic soldiers suffering from active lesions of the disease, and to insure their rapid return to the front. The treatment consists of a course of intensive mercurial medication and the most careful regulation of the general system.

Following admission to the hospital, the patient receives a thorough physical examination, the twenty-four hour urine is examined, the teeth and gums are cleaned and treated and he is instructed to brush his teeth, morning and evening, and after meals. The gums are painted daily with a 2% chromic acid solution and potassium chlorate tablets are used to prevent stomatitis. To hasten elimination of the mercury and increase the oxygen carrying elements of the blood, a glass of sulphur water is sipped slowly every morning. A quart of milk is drunk every day to insure good renal and hepatic function. Alkaline or sulphur baths are given every third day.

Intramuscular injections of a 1% solution of benzoate of mercury or biniodide of mercury are administered daily, in one-half grain doses, until twenty are given. Twice a day, the syphilitic receives one-sixtieth of a grain of arsenous acid or arsenate of soda, to hasten the disappearance of the lesions. In order to overcome the fatigue caused by the treatment, one-sixtieth of a grain of strychnine sulphate is added to the arsenic.

The various lesions which may be present receive appropriate local treatment.

SYPHILITIC REINFECTIONS; A STUDY OF THIRTY-ONE CASES. A. D. de Laviergne, p. 10.

The author concludes that a cured syphilitic may contract the disease a second time. To make a positive diagnosis of reinfection the following conditions must exist: (1) A history of exposure to infection; (2) An incubation period of two to four weeks; (3) A typical chancre and a corresponding adenopathy; (4) Secondaries appearing about six weeks following the development of the initial sclerosis. Scrupulous care should be taken not to confuse secondary and tertiary chancriform lesions with chancres or reinfection.

NEW YORK STATE JOURNAL OF MEDICINE.

(March, 1916, xvi, No. 3.)

Abstracted by Oscar L. Levin, M.D.

THE TREATMENT OF SCARLET FEVER WITH FRESH BLOOD FROM CONVALESCENT PATIENTS. Abraham Zinger, p. 112.

Fourteen patients suffering from severe, toxic scarlet fever were treated with fresh blood, obtained from individuals convalescent from two to six weeks. The blood was injected, directly or previously citrated, into the various muscles, in doses of four to eight ounces. In the uncomplicated cases there was an almost

immediate improvement in the symptoms. The temperature began to decline within two to four hours; the pulse became slower, stronger and steadier, cardiac symptoms and cyanosis improved; respirations became normal; the mentality improved and the rash faded rapidly. Local manifestations or secondary infections were not influenced by the treatment. Death occurred in four patients who were extremely toxic, delirious and practically moribund on admission.

It is suggested that intramuscular injections of fresh convalescent blood will be found of therapeutic value, not only in scarlet fever, but in other infectious diseases like erysipelas and pneumonia.

HEREDITARY SYPHILIS IN CHILDREN: LATER MANIFESTATIONS AFTER THE AGE OF ONE YEAR. L. E. LaFetra, p. 135.

SYPHILIS IN THE PARENTS AS A CAUSE OF FEEBLE-MINDEDNESS IN THE CHILDREN. Henry H. Goddard, p. 129.

As a result of a critical study of the literature, Goddard believes that it is impossible to prove that syphilis in the parents is a cause of feeble-mindedness in the children. In almost all the cases reported, other abnormalities were present which could have been the causative agents of the mental defects.

In a series of eighty-one feeble-minded children, the author obtained a positive Noguchi reaction in twenty. Five of these gave a family history of lues. In every one of the twenty positives, the feeble-mindedness was accounted for on some other basis than syphilis, which was at least as good as the hypothesis of syphilis, and in most cases, vastly more probable. The author concludes that feeble-mindedness in children is not caused by syphilis of the parents. Syphilis is too powerful a poison merely to maim the offspring; it kills.

HEREDITARY SYPHILIS—THE EARLY MANIFESTATIONS: FROM INTRA-UTERINE LIFE TO ONE YEAR OF AGE. Le Grand Kerr, p. 132.

MEDICAL TIMES.

(April, 1916, xliv, No. 4.)

Abstracted by Oscar L. Levin, M.D.

A PRELIMINARY REPORT OF THE RESULTS OF TREATMENT OF ONE HUNDRED AND FIVE CASES OF SYPHILIS. Edward H. Marsh, p. 105.

The author reports the results obtained on one service of the dermatological department of the Cornell Clinic. Eighty-seven of the syphilitics applying for treatment were given intravenous injections of salvarsan (0.2 gm. each) and intramuscular injections of mercury salicylate (0.1 gm. each). Two patients suffering with primary syphilis were cured clinically and showed negative Wassermann reactions, after five injections of salvarsan and ten of mercury. Thirty-five cases of early secondary syphilis yielded readily to more intensive treatment; clinical and laboratory cures being obtained, following the administration of ten salvarsan and thirty mercury injections. In old cases, the best results were obtained in those in which the infection was latent. Old cases with gummata and lesions of the central nervous system yielded to treatment with difficulty.

Eighteen patients suffering from mild forms of syphilis were treated with mercury alone. Following the administration of from ten to twenty intramuscular injections, nine showed negative Wassermann reactions.

EDINBURGH MEDICAL JOURNAL.

(March, 1916, xvi, No. 3.)

Abstracted by Oscar L. Levin, M.D.

REPORT ON THE RADIUM TREATMENT AT THE ROYAL INFIRMARY, EDINBURGH, DURING THE YEAR 1915. Dawson Turner, p. 204.

Rodent ulcers were treated by radium with primary doses of 1550 mg. hours, during a period of forty-eight hours, and subsequent doses 90 mg. hours, several months later. In nineteen cases the lesions disappeared with good cosmetic results and scarcely any contraction of the skin. Cures are to be expected when the cancer is uncomplicated and situated on the skin. Recurrences due to insufficient primary treatment are removed by a second application.

Papillomata, nævi and keloids were removed with no injury to the skin.

BOSTON MEDICAL AND SURGICAL JOURNAL.

(Apr. 13, 1916, clxxiv, No. 15.)

Abstracted by Oscar L. Levin, M.D.

THE RELATION OF SYPHILIS TO MENTAL DISEASES. Samuel T. Orton, p. 525.

Orton claims that syphilis causes 10% of all cases of insanity. The cases may be divided into three classes: 1, general paresis; 2, cerebrospinal syphilis; and 3, syphilitic endarteritis of the cerebral vessels. Although a positive Wassermann reaction was formerly obtained in over 95% of all cases of paresis, it remained for Moore and Noguchi to prove positively, that paresis was of syphilitic origin, by demonstrating the Treponema pallidum in the brains of paretics. Analysis of the admissions, for ten years, to one of the state hospitals in Massachusetts, showed 450, or 9.5% of over 4500 cases of insanity, diagnosed as general paresis. This figure corresponds fairly closely with the percentage found in all the state hospitals in New York, for one year.

Cerebrospinal syphilis is numerically of less importance. It affects localized areas of the meninges and the connective tissue surrounding the blood vessels.

Syphilitic endarteritis causes a partial or complete blocking of the blood vessels, resulting in partial or complete starvation of the involved parts of the brain.

Beside these three main types of syphilitic insanity, there are undoubtedly cases of feeble-mindedness and imbecility due to hereditary and acquired syphilis.

JOURNAL OF THE INDIANA STATE MEDICAL ASSOCIATION.

(Mar. 15, 1916, ix, No. 3.)

Abstracted by Oscar L. Levin, M.D.

THE TREATMENT OF CEREBROSPINAL SYPHILIS BY INTRASPINOUS INJECTIONS OF MERCURIALIZED AUTO-SERUM. G. W. McCaskey, p. 102.

The reasons for employing autogenous serum are: 1, The serum of a patient suffering from lues contains specific antibodies; 2, Exogenous serum might produce anaphylaxis; 3, Exogenous serum might possibly transmit pathogenic microörganisms.

After two years' experience with the intraspinous treatment of syphilis of the central nervous system, the author concludes that it is a valuable auxiliary to the usual methods.

THE JOURNAL OF CUTANEOUS DISEASES

Vol. XXXIV AUGUST, 1916 No. 8

ORIGINAL COMMUNICATIONS.

THE DERMATOLOGIST, THE PROPER TEACHER OF SYPHILIS.*†

By Joseph Zeisler, M.D., Chicago.

The wording of my address is not of my own choosing. I might have felt more like selecting, diplomatically, a less compromising title. But as it comes to me in the form of a mandate from the council of the American Dermatological Association, establishing the official attitude of this representative body, it behooves me to make my plea, to the best of my ability, as the spokesman of our organization, and I approach my task cheerfully and without any restraint, as I am fully and unhesitatingly in accord with the views implied in the title.

Why has it become necessary to discuss the question of who should teach the subject of syphilis in our medical schools? Has the derma-

* Read before the 40th Annual Meeting of the American Dermatological Association, Washington, D. C., May 8, 9, and 10, 1916.

† This article, together with papers by Drs. Post, Wile, Fordyce and Pollitzer, represent the symposium on syphilis delivered at the 40th Annual Meeting of the American Dermatological Association. Of the papers comprising the symposium those of Drs. Zeisler and Post are published in this issue. The remainder of the symposium, together with the discussion, will appear in the September issue.

tologist lost his ability or his right to appear in authoritative attitude towards it? Or has he lost his interest in it? Or has some other existing and recognized department of medicine developed more valid claims? Or has the time arrived when the subject of syphilis has assumed proportions so big and comprehensive as to justify its separation from all other established chairs, and its elevation to the dignity of a distinct and independent department of medicine with a correspondingly distinct and independent chair for its teaching? And granting, for the sake of argument, that this might be so, would such a radical departure be to the best interest of the student and the medical profession at large? Is the present or hitherto recognized or tolerated manner of teaching the subject entirely satisfactory and beyond the need of improvement, of modification? And finally, what should be the ideal, form, scope and extent of instruction?

All these questions are of paramount interest, and an unbiased answer to them should be forthcoming, not only from us as dermatologists, but after careful and thoughtful deliberation, from the responsible heads of our best medical schools.

The timeliness and acuteness of this discussion is evidenced by the positive stand taken already by one of the most prominent schools in this country in boldly separating the subject of syphilis from that of dermatology and assigning it to a newly created head.

That syphilis, during the last twelve years, by almost spectacular scientific advances has easily come to occupy the foreground of medical interest; that pathologic, experimental, biologic, therapeutic studies in relation to it have rushed into the columns of contemporary medical literature with torrential impetus, is, of course, a matter of record. In contrast to previous comparative stagnation, what a precipitate flow of epoch-making events! Like milestones, we distinguish: the successful inoculation of monkeys and other animals with syphilis, in 1903, by Metchnikoff and others; the discovery of the Spirochæte pallida, by Schaudinn and Hoffmann, in 1905; the serological diagnosis of lues by Wassermann, Neisser and Bruck, in 1906; the successful cultivation, in pure culture, of the spirochæte by Volpine and Fontana, in 1906, by Schereschewsky in 1909, later by Mühlens and Noguchi; the therapeutic experiments by Ehrlich, with their sensational climax—salvarsan, in 1910; the final establishment of the luetic nature of tabes and general paralysis through the demonstration of the culpable organism by Noguchi, in 1913.

The progress here outlined has had its far-reaching effect, not merely upon dermatology, but upon every single department of medicine. The

newly aroused and absorbing interest in the subject of syphilis was shared by general practitioner and specialist alike. But while we are far from overlooking the fact that much of the fundamental work referred to, was inaugurated by scientists outside of the department of dermatology, in fact outside of medicine in general, for Schaudinn was primarily a zoölogist, Metchnikoff a pure biologist, and Ehrlich chiefly a chemist, it is, nevertheless, but fair to admit that the overwhelming amount of clinical and laboratory work in confirmation and elaboration of that basic groundwork was done by dermato-syphilologists, as can be easily proven from the record of recent literature.

But it was unavoidable that the subject of syphilis, which was formerly considered a legitimate field of study and practice for the dermatologist, had now become, as it were, more accessible to the special workers in all other departments of medicine and to every general practitioner. No further need of the man specially trained in diagnosing the multiform and often doubtful and ambiguous manifestations of the disease, or in managing a case with judgment, experience, discrimination and technical skill. The matter had become so perfectly simple. Why worry whether an unfamiliar rash was a syphilitic roseola, or rather, a pityriasis rosea or toxic erythema? Whether a swelling on the leg was a gumma or an erythema induratum or nodosum? A tumor on the lip a chancre or an epithelioma? Who cared whether a chronic eruption was a psoriasis, a lichen planus or a papular syphilide? Why trouble whether an ulceration of the nose was of syphilitic, carcinomatous, or tuberculous nature? Or vegetations on the lip a pemphigus vegetans or condylomata lata? Even lepra or elephantiasis need not concern the self-satisfied, nonchalant practitioner. All these and hundreds of other diagnostic problems had become reduced to a simple, almost mathematical proposition. The laboratory, the reliable and infallible(!) Wassermann test, relieves him of all possible doubt and responsibility. And the treatment? Provided always, that the case is actually one of syphilis; again how simple! One or two "shots" of "606" and the work is accomplished.

But is the Wassermann test in reality all that is required for the diagnosis of a dubious case? With all due regard for its value as a confirmatory symptom, has not every one of us, time and again, known it to fail? How many tabetics give persistently a negative result! How often will different laboratories, supposedly trustworthy, report absolutely contradictory findings in the same patient! But this is not the place to enlarge upon this intricate matter.

And has salvarsan, with its substitutes, kept all the promises that

were held out for it when it first made its spectacular entry? The beautiful dream of the *sterilizatio magna*, like all dreams, did not last long. Soon enough, while fully appreciating its great merits, we learned to look upon it not as a sure curative agent, but as a most welcome, though by no means always indispensable, addition to our weapons against lues. The old and tried methods have not been entirely discarded, and he would indeed be a narrow practitioner who should be willing to ignore the accumulated therapeutic experiences of our teachers, who in their day—let us be fair—did not do so much worse than we can today. But here again I must avoid the temptation of going into detail. The fact remains that diagnosis and treatment of syphilis have not been simplified; they have become vastly more complicated. Instruction in them must be given by the man who has mastered the new accomplishments but has not forgotten the good old traditional treasures. These qualifications are found among the best dermatologists, rather than elsewhere. But the claims of the dermatologist upon the domain of syphilis are not only based on tradition. Everybody familiar with its literature knows that the foremost dermatologists of all times have been among the pathfinders, the teachers, the earnest workers in it. Have we forgotten Unna's and Auspitz's work on the primary lesion? Were Kaposi, Fournier, Leloir, Taylor, Hutchinson, Schwimmer, are Neisser, Hallopeau, Fordyce, and so many others less competent to teach syphilis because they were or are eminent dermatologists? Has their hold upon it loosened because representatives of other branches of medicine have lately crowded themselves forward? The genito-urinary surgeons (or are they now to be called urologists?) seem to encroach more and more upon our legitimate field. Upon what ground? Because the primary lesion of lues often occurs upon the outer genitalia! Theirs is a large and important field, requiring more than ordinary technical accomplishments, but it is distinctly a branch of surgery. Why they should consider themselves competent to decide fine points in differential diagnosis of cutaneous and mucous membrane lesions, a daily demand upon the syphilologist, is difficult to see. With equal right could the neurologist advance his claims, because tabes and general paralysis are the result of syphilis, or the ophthalmologist, because iritis is so often of specific origin, or the internist, because aortic aneurysm is now known as one of its consequences.

As to the establishment of an independent Department of Syphilis, I honestly believe there are serious objections. Specialization in medicine has continuously progressed and will undoubtedly continue to do so. Every practitioner has a right to arrange his practice to suit his inclina-

tion. If a physician will limit his work to diseases of the liver, or the pancreas, or cultivate only the surgery of the thyroid gland, or the stomach, or the rectum, we have no right to criticize his hobby. But should the medical schools follow suit and establish an unlimited number of independent departments? If syphilis is entitled to a distinct chair, why not tuberculosis, equally important and far-reaching in its effect upon the human economy? Why not diabetes, with its manifold medical, chemical, urologic, surgical and cutaneous aspects? Or cancer? Or leprosy?

I am not unmindful of the enormous growth of the subject of syphilis through the clarifying effect of modern research. But let me put the question of the proper teaching of syphilis in a nutshell: If any one of you were to write, today, a real comprehensive text book on syphilis, would you be willing or capable or bold enough to fill it with your own work from cover to cover? Would it not be wiser or more conscientious to entrust the chapter on specific eye affections to an ophthalmologist? Those of the nose and throat to the laryngo-rhinologist? The lesions of the nervous system to the neurologist? Those of the internal organs to the internist? And so forth. No doubt some of you have recently enlarged your former field. Some of you are experts in intraspinal injections. Some have given careful study to visceral lues. But does any one claim diagnostic and technical skill in all the different departments, including the eye, ear and nose and throat? Of course not!

And so it should be in our medical schools. Every department should retain its proper, limited, individual interest in the subject of syphilis. In fact no manner of regulation can ever change that. But the bulk of the teaching, the history, the general pathology, histology, serology, and the treatment of syphilis should remain with the chair of dermatology. Why with that and no other department? Because the inception of the disease is almost without exception upon the skin. The further phenomena in untreated cases are predominantly upon the outer integument, the mucous membranes, and in the superficial lymph glands. It is at this period that diagnosis and treatment are of paramount importance. If properly recognized and skilfully managed, it should be possible in many cases, practically to abort the disease and prevent the invasion of other organs; treatment begun at the right moment and persevered in, according to the best traditions, should reduce the affections of the eye, the nose and throat, the bones and the deeper organs, to an almost negligible quantity. It would be indeed an ideal state of affairs if by such timely treatment, syphilis should never develop beyond its cutaneous career.

And in the late, relapsing, inveterate cases we find again the outer integument as an important arena for the protean exhibitions of the disease. The pigmentary, serpiginous, ulcerative, nodular, gummatous, nail and tongue lesions have not been scared away by our modern diagnostic and therapeutic victories. The student needs here authoritative guidance, for there are diagnostic pitfalls in plenty.

The danger of duplication and overstepping in teaching the subject can easily be avoided by coöperation, coördination and tactful subordination. Unfortunately, coöperation is not overcultivated in our medical schools, where the teaching force rarely gets a chance to discuss such problems among themselves.

The present method of teaching syphilis is far from perfect. Before all there is not enough time given to it. But the greatest drawback is the lack of laboratory and hospital facilities. With a few notable exceptions there is in most hospitals in this country, where wards are open to medical students, not even a pretense of a special department for skin diseases and syphilis. Until there is a radical change in this respect, all our efforts, all our discussions and deliberations will remain academical. To the American student it has always been a revelation to find in the Hôpital St. Louis in Paris, in the General Hospital in Vienna, in Breslau and many other smaller university towns, hundreds of beds set aside for such cases. How we have been able to get along all these years without them, how we have given our students, with the aid of ambulatory material only, any kind of adequate instruction, is almost a mystery. Our immediate need, therefore, is, may I be permitted to say, preparedness. The next question, as to who should be in charge of the newly created armament can, to my mind, have but one answer. My "ceterum censeo" is: the Dermatologist, the proper Teacher of Syphilis.

CONGENITAL AND BONE SYPHILIS.*

By Abner Post, M.D., Boston.

When so comprehensive a subject is to be treated in the space of twenty minutes, it cannot be unwise to choose certain portions of the subject rather than attempt to cover the whole ground, and this title will be so modified as to read, "Certain features in the study of congenital syphilis." And this paper will concern itself only with such aspects or subdivisions as seem likely to prove of interest or arouse discussion. A few words in regard to Colles' law shall serve as an introduction.

Colles' law is so often misquoted that it is worth while to go back to Mr. Colles' original statement. It is as simple as the record of any naturalist of an observation of some natural phenomenon. He offers no explanation of the matter—he himself formulates no law. His observation is recorded in two different places and reads as follows:

"The following fact appears to me very deserving of notice: I have never seen or heard of a single instance in which a syphilitic infant (although its mouth be ulcerated), suckled by its own mother, had produced ulceration of her breasts; whereas very few instances have occurred where a syphilitic infant had not infected a strange hired wet nurse, and who had been previously in good health.

"It is a curious fact that I never witnessed nor ever heard of an instance in which a child deriving the infection of syphilis from its parents has caused an ulceration in the breast of its mother." (The New Sydenham Edition of Colles, p. 271.)

And again, in a little different language:

"One fact well deserving our attention is this: that a child born of a mother who is without any obvious venereal symptoms, and which, without being exposed to any infection subsequent to its birth, shows this disease when a few weeks old; this child will infect the most healthy nurse, whether she suckle it or merely handle and dress it; and yet this child is never known to infect its own mother, even though she suckle it while it has venereal ulcers of the lips and tongue." (New Sydenham Edition of Colles, p. 287.)

Naturally, other people sought an explanation and Mr. Colles has been unfortunate in his commentators. Apparently, Mr. Hutchinson was the first to speak of "Colles' law," and later the word "immunity" was used, but not in the sense in which it is now used. If we follow Mr. Colles accurately and formulate his observation into a law, it must be simply in some such form as this: "That a baby, born syphilitic, will not infect its own mother while it will infect a non-syphilitic wet nurse." It is a law based on observation and is not an explanation.

* Read before the 40th Annual Meeting of the American Dermatological Association, Washington, D. C., May 8, 9 and 10, 1916.

The pregnancies in a syphilitic family follow somewhat loosely a general course,—abortions, still-births, children dying shortly after birth, children that live as "hereditary" syphilitics, and later, if the births occur in a sufficiently long line, children that are healthy, apparently, at least. Two syphilitic families recently brought under my notice have younger sons who have passed the rigid examinations for enlistment in the regular army and navy.

An occasional exception to the usual sequence is worthy of note. The first-born of a syphilitic family occasionally survives,—syphilitic to be sure, and the often described sequence of still-births and early deaths begins with the second pregnancy. This first-born may be apparently healthy for many years, showing the first symptoms comparatively late.

These cases, so far as I can interpret them, are the cases in which a syphilitic father marries a healthy woman. The first child then is the offspring of a syphilitic father and a healthy mother, while the following children are the offsprings of two syphilitic parents. The first case of this sort that was brought to my attention was reported by me in 1898.

At the age of 22 years, when first seen by me, a young man had old interstitial keratitis and choroiditis. He was quite deaf. He died in the hospital from disease of the liver. The anatomical diagnosis at the autopsy was syphilis, atrophy of auditory nerves, gummata and diffuse syphilitic cirrhosis of the liver, gummata of abdominal walls, pancreas, lymphatic glands and bones of both lower extremities. His history was one continued story of syphilis from birth to death. The interesting part of his history, in this connection, is the fact that he was the first-born and was followed immediately by two miscarriages, a sister who died at one year of pneumonia, and one who died, at unrecorded age, of "congestion of the stomach." Five younger sisters and two brothers were then alive. In these living children, persistent headache and other symptoms were present which would call for serological investigation at the present day.

After the young man's death, the father voluntarily called upon the house physician, who had shown particular interest in the case, to tell him that he, the father, had had syphilis before his marriage and that he wanted to tell it in the hope that it might be of help. The mother had never shown any symptoms attributable to such disease according to her husband's story.

Similar cases have fallen under my observation in sufficient numbers to show that this was not an isolated case. Such cases will, I believe, always refer back to a father, syphilitic before marriage, and a healthy mother, and it is this supposed connection which has led me to introduce Colles' law and these cases of survival of the first-born, in this paper.

Cicatrices about the mouth are recognized as of frequent occurrence in hereditary syphilis. These are referred to as ulcerations in infancy. Some observations of late seem to justify the belief that they are occasionally due to intrauterine disease. When I have

made the observation that certain children must have had very sore mouths in infancy, the mother has occasionally disputed my statement, and careful examination of infants has occasionally shown cicatrices already existing, even in infancy. A photograph shows a baby's face with abundant ulcerations of the lips and about the mouth and on the cheeks. Marks, it may be, of ulcerations which were prenatal, possibly failures in development, similar to other defects, such as the failure of development of the nails, one example of which Dr. Wile published not very long ago.

One of the most constant symptoms of syphilitic infants is the difficult and noisy breathing known as "snuffles." It appears very early—sometimes it is present at birth. It varies from a troublesome sanguino-purulent discharge which excoriates the upper lip, crusts and obstructs the nostril, to a slight snuffling, noticed only at times. The obstruction to breathing interferes with nursing and sometimes makes it necessary to feed the child with a spoon. The baby smothers and chokes at night and sleeps poorly. It is known by all who have to do with syphilitic children and ought to be universally recognized; but while everybody knows about adenoids, not everybody recognizes syphilitic snuffles.

Adenoids. Few children with hereditary syphilis escape an operation for adenoids. The symptoms are the same, whether the breathing is obstructed by adenoids or by narrowed nasal passages, such as occur in hereditary syphilis. In syphilis, the relief is seldom obtained by operation and the operation is repeated a second and a third time. A newly consulted doctor is more apt to think that the preceding operation was imperfectly done than to look for any other explanation.

The upper jaw is known to lack proper development, so that the upper incisors fail to meet the lower, as was pointed out by Mr. Hutchinson in his observations on the deformity of the upper central incisors, known by his name. The very high arched palate is another example of a deformity in the same bones, and X-ray studies of the facial bones show that the nasal passages in syphilitic children are decidedly narrow, so that no amount of scraping away of soft tissue, adenoid or otherwise, can be expected to widen the passage.

The objection to operations on syphilitic snuffles, as for adenoids, is not alone that it is useless, but also that it exposes the physician to risk of inoculation. I have had the unpleasant duty of treating one enthusiastic operator for chancre of the finger. I have been told of another case, and even two cases are enough to warrant hesitation in doing an ill-advised and gratuitous operation.

Symmetrical synovitis of the knee joints was described, in 1885, as an

occasional result of hereditary syphilis. Within the past year it has occurred so often that it seems worthy of mention as a symptom which ought to be looked for. Synovitis of other joints, also symmetrical, occurs less frequently. Synovitis of both knees has occurred so frequently in connection with interstitial keratitis and Hutchinsonian teeth that such a triad seems of equal if not greater value than the famous triad of Hutchinson,—interstitial keratitis, deafness and notched incisors.

There is one phase of hereditary syphilis which demands our serious attention, and that is syphilis of the lung. I do not refer to the acute pneumonias of infancy, but to a chronic affection which simulates tuberculosis very closely, in its clinical history. A brief history of two cases will illustrate the class to which reference is made.

L. M., a girl of 18 years, has always been an invalid; is undersized, and suffers from interstitial keratitis, which obliged her to have an attendant when she first came to the clinic. She had a partial hemiplegia and some trouble with one hip joint which had been considered tuberculous, but it was not a destructive process. She had a cough and consolidation of one lung. She had spent time in the almshouse, in hospitals for tuberculosis and other hospitals; always considered tuberculous but tubercle bacilli were never found. She had a positive Wassermann. The entire left lung was consolidated, but the heart was not pushed out of place; on the contrary, it seemed to be drawn to the left. The right lung was practically free. The radiogram corresponded exactly to the picture presented by an acquired case, in which the diagnosis of syphilis had been practically established. She improved in every way under anti-syphilitic treatment, except that the lung condition changed hardly at all.

A boy of 10 years, Elias M., must be cited in this connection. He had four separate foci of consolidation—at each apex and at each base. He had been considered tuberculous, but he had not improved under treatment nor had he grown worse. A constant cough was his chief complaint. It was found that his sister had a positive Wassermann. The boy was then found to be Wassermann positive. There was a frightful infant mortality in the family. The boy was evidently a hereditary syphilitic and under treatment his pulmonary symptoms improved rapidly. The number of these cases is probably not very great, but it is appreciable.

The diagnostic signs of syphilis of the lung can hardly be absolutely formulated, but we may venture such a statement as the following:

When a case presents the rational signs of pulmonary tuberculosis, but the physical signs are unusual and no tubercle bacilli are found, a Wassermann test should be taken and certainly, if that is positive, a working diagnosis of syphilis may be made. If the Wassermann is negative, we may still consider the case worthy of careful study and perhaps of anti-syphilitic treatment. In the cases which I have cited a positive diagnosis of syphilis is warranted. These cases open up the widest field for research.

The coincidence of tuberculosis and syphilis in some of our patients presents occasional difficulties. That these two diseases may occur together is undoubted; that they are mistaken for each other is also true. They cause difficulty in the diagnosis of eye conditions, as they do in skin, bone and joint troubles. The family histories often mention tuberculosis in relatives of our patients and raise the doubt as to the possibility that the alleged tuberculosis was really syphilis.

The subject of the social relations of syphilitics is attracting sufficient attention to permit its mention. The study of these cases has brought to light many instances of dependence: on grandparents; on uncles and aunts, as, for instance, a syphilitic child is supported by the husband of the mother's sister; on step-parents, including second marriage after death or divorce; on the State, as state minor wards,—children deserted by their parents, children adopted in infancy who have later developed symptoms of syphilis, no evidence of which was discovered in babyhood. These adopted children have brought out the most unselfish devotion on the part of adopted parents, who not only find themselves burdened with an unhealthy child, but also with whatever discomfort may be attached to the supposed parenthood of such a child.

When one talks of the possibility of transmitting hereditary syphilis to the third and fourth generations, as is so loosely done, he admits the survival of the first generation of hereditary patients up to adult age, and the possibility of such transmission is the subject of much speculation. On the other hand, there is apparently a wide belief that hereditary syphilitics do not live to adult age, and there is a curious unwillingness to recognize syphilitic disease as hereditary in the adult. Such unwillingness to recognize adult hereditary syphilis is possibly one of the reasons why syphilitics are so often believed to be liars.

Hereditary syphilis of adult life appears under several conditions.

1. Cases which have been known to the physician from infancy, in which the heredity is known, and the disease watched from infancy to adult life.

2. Cases seen first as adults, but with their history recorded by the stigmata of syphilis in unmistakable manner.

3. Cases seen first as adults without relatives, with doubtful signs and the question of heredity not easily determined.

The more cases of the first and second classes that can be seen and studied, the easier will be the solution of the problems of the third class. These are cases which are often made to suffer from unjust suspicions, or are not recognized at all. From the first series of children we learn that hereditary syphilitics do grow up. That in adult life they show the

greatest variety in development and health, both physical and mental. Some justify all the serious things that can be said of syphilitics. Some are practically perfect. Medication seems to justify itself in certain cases, but it evidently is not the only element in shaping the adult life. Some of these cases carry with them their own diagnosis, as clearly read as can possibly be. Other children in the group present no sign of syphilis which would be recognized on very careful examination.

The second of our artificial divisions of these adult hereditary cases, consists of those in whom the recognition of syphilis and of its hereditary character is comparatively simple.

The case that did much to attract attention to this class came from one of the settlement houses. She is a scrub-woman, employed in part from charitable motives, as she can hardly be able to compare in working ability, with some of the robust women of her class. She was seen by the District Dispensary doctor, who told the authorities of the house that she was a syphilitic. They became alarmed and asked for information on the subject, particularly whether she was likely to infect others, and if anything could be done for her.

The case was that of Mary C., aged 33 years, a scrub-woman. She had marked opacities of the corneæ, extensive destruction of the soft palate, a nasal voice, and was quite deaf. There were Hutchinsonian teeth, extensive scarring on right lower leg, and the tibia was thickened. Her mother says she has been sick since she was six months old. She had been a patient at the Eye and Ear Infirmary, Boston City Hospital and Massachusetts General Hospital.

She had had an operation for abscess of the neck at six months of age. At present she has a discharge from the nose and noises in her head. She is an extreme example of hereditary syphilis. Hutchinsonian teeth, interstitial keratitis and deafness make the Hutchinsonian triad, which practically means heredity.

The question of danger to her surroundings is a remote one. She has, doubtless, spirochætæ somewhere in her body, but they are not so situated nor so numerous as to threaten her environment.

A second case is even more striking:

William B., aged 23 years (October, 1912). He suffered from interstitial keratitis and had been at the Eye and Ear Infirmary for 14 weeks—totally blind most of the time. He presents radiating scars at each corner of the mouth, most marked at the right. He has Hutchinsonian teeth and many scars on the lower legs, some of which are said to date from his tenth year. X-ray plates of the tibiæ show subperiosteal thickening, characteristic of syphilis. This young man has the signs of hereditary disease. There can be no doubt in diagnosis. His father was a drunkard, said to have died of consumption. His relatives are convinced that the son has acquired the disease and is lying to them, and all but an aunt have refused to help him. The stigma of the disease is visited upon him in a way more difficult to bear than the actual disease. Even when he tries to tell the truth, he is not credited.

Of the third class, the following is a good example:

Mrs. S. B., aged 20 years. Her parents died in England. She was sent to Canada with a sister. She knows nothing about the rest of her family.

Sept. 19, 1912. The woman is five months pregnant. She was picked up on the street, insensible, a few days ago and carried to the Relief Hospital, where they are said to have refused to keep her. Blood taken for a Wassermann test proved positive.

There was a superficial ulcer near the head of the tibia, syphilitic in character. The enamel of the upper middle incisors is very imperfect toward the cutting edge, making an arch which would make a Hutchinsonian sign if the thinner, imperfect cutting edge were broken away. She has one child who will be three years old in February. Her second child will be twelve months old in January. There is every reason to believe this woman to be a hereditary syphilitic.

The recognition of these cases is very necessary to the proper knowledge of the clinical history of syphilis.

Fig. 1. Rudimentary finger nails in hereditary syphilis.

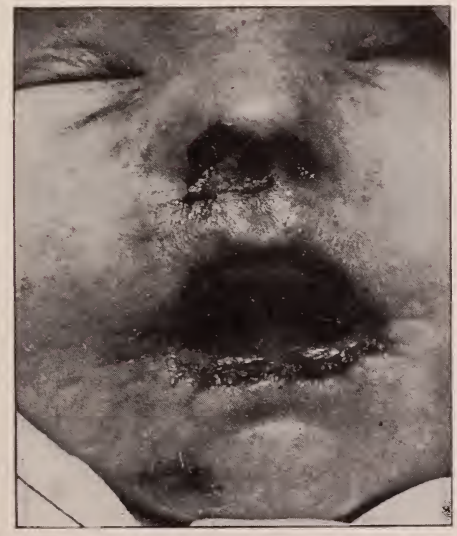

Fig. 2. Facial deformity in hereditary syphilis.

PASTES.

By Douglass W. Montgomery, M.D., San Francisco.

Pastes, like ointments, are mixtures of powders with fats, but with the notable difference that far more powder is present. They, therefore, differ widely from ointments both in their consistency and in their physical action.

As a general rule in a paste, the powder or powders is equal in amount to the fatty medium; the best known of them is the one called Lassar's paste:

℞	Acidi salicylici	1.00
	Amyli	12.00
	Zinci oxidi	12.50
	Vaselini	25.00

Lassar devised this with the idea that the eczemas were primarily infective diseases, which they are not. The discharges and the denuded surfaces, however, are extremely liable to infection and so contribute to the discomfort, to the intensity and to the prolongation of the eczema.

In the above combination the two powders, zinc oxide and starch, equal in weight the fatty medium, vaseline, and to this is added the antiseptic, salicylic acid, which, as we shall see, is a most astute device.

In this paste the large amount of powder, besides being light, gives the preparation the physical properties of porosity and absorbability proper to a powder, and the grease lends it consistency, so that when applied it adheres to the surface and acts protectively, and furthermore holds the active antiseptic, salicylic acid, to the surface better than a powder.

Applied on an oozing surface, therefore, the paste, because of its absorbability and porosity, takes up the discharges, and so favors drainage, and at the same time brings these discharges in contact with the salicylic acid distributed in the mass of the paste, and so prevents their fermentation, and their consequent erosive, irritative action on the diseased surface. Very frequently, when the discharges are abundant, a powder, such as boric acid or talc, or a mixture of them, may be dusted over the paste.

The paste may be removed each day, which may be done with benzine, or if this irritates, with olive oil. It is frequently inadvisable to be too thorough in this cleansing for fear of breaking down the delicate epithelium and doing more harm than good. In many cases a superficial removal of the dressing with a reapplication of the paste is more judicious.

Besides the oozing, wet eczemas, the superficial, irritable, patchy papular ones are often better controlled by pastes than by ointments. The stiff dressing affords protection, and also seems to hold the papillary layer as in a splint. The hot, erythematous eczemas also often do well under a paste or a powder, because neither of these preparations interferes with evaporation, which is so important in keeping the surface of the skin cool.

A distinction must here be made between eczemas and impetigo contagiosa, which is a streptococcic infection that causes a lesion on the skin resembling a burn. The exudation quickly forms a crust, under which the anaerobic bacteria thrive wonderfully well. The pastes and the powders aid in the formation of this crusting, and therefore act contrary to one of the chief indications for treatment.

In order to comprehend why a hot, erythematous eczema may behave better under a paste or a powder than under a salve, it is well to consider, in this respect, the action of salves.

Salves, when buttered on lint and applied, tend to heat the already hot skin of erythematous eczema by retaining the heat and by preventing the evaporation of sweat. An experiment by Schäffer shows to a certain extent what occurs: he filled a flask with water, and poured in a little oil so as to form a thin sheet over the free surface. For weeks such a flask was allowed to stand in the incubator without the least evaporation taking place[1]. This is similar in its action to the layer of olive oil, with which the Romans used to seal their wine jars, before the use of corks was known. Pastes, therefore, in contrast to salves, may be said to give the maximum of protection with the minimum of asphyxiation.

Ointments and oils, however, when rubbed into the skin, and wiped off, and the surface powdered with an indifferent powder, such as talc, do not act in this manner, as under such circumstances evaporation of both heat and moisture go on unhindered, and the action in the depth of the skin, proper to an ointment, is also attained. There are people, though, whose skin is sensitive to fats of whatever nature, and with these a powder, a lotion or a paste, must be employed. This irritating action of fats is so frequent that Schäffer cautions to be on the alert for it when an ointment does not act well.

In choosing powders with which to make paste, undoubtedly oxide of zinc and starch are the favorites in spite of the fact that starch, being vegetable, is quite susceptible to fermentation. It is interesting to note in books on dermatology how frequently starch is mentioned. It is employed so frequently, in fact, that during the present war, at least one German journal devoted to skin diseases, requested that starch, on

account of being an important food, should not be used in cutaneous troubles. It acts particularly blandly on the skin, and mitigates the rather harsh drying effect of oxide of zinc, whereas the oxide of zinc on its part prevents the starch becoming too gummy. Starch is employed in powders, lotions, pastes and as poultices.

If it is desired to make a softer, smoother paste the proportion of powder may be lowered as:

℞	Amyli	
	Zinci oxidi.....	āā 20.00
	Vaselini	60.00

All sorts of powders may be added as medicaments to such pastes, with the understanding that the proportion between powder and fatty medium is maintained. For instance, if sulphur is added the prescription would read:

℞	Sulphuris	20.00
	Zinci oxidi.....	
	Amyli, āā.....	15.00
	Vaselini	50.00

There is a paste, made of naftalan, that is particularly valuable in infantile eczema:

℞	Naftalan	50.00
	Zinci oxidi.....	
	Amyli, āā.....	25.00

Naftalan is a Russian coal tar product, a coal black mass of the consistency of vaseline, which makes a paste that adheres well to the skin. In fact, on renewing the application, which should be done at least once a day, it is necessary, as with the other pastes, to use benzine or olive oil as a cleanser.

Unfortunately, the present war has interfered with the supply of naftalan, but tumenol may be employed as a substitute. Tumenol is a mild, antipruritic tar preparation that, as Schäffer says, very rarely irritates. It may be used in acute eczema in one to three per cent. strength, in subacute eczema in ten per cent. strength.

℞	Tumenol	3.00
	Zinci oxidi.....	
	Amyli, āā.....	25.00
	Vaselini	50.00

Several years ago I ran across a modification of Lassar's paste by Jamieson, which consists in employing glycerine instead of vaseline as the oily base. The formula reads:

℞	Acid salicylici	1.00
	Amyli	12.50
	Zinci oxidi	12.50
	Glycerini	25.00

It makes a preparation of the consistency and color of thick white paint which spreads well, drifts into the skin almost like a powder, and holds its constituents tightly to the skin. It answers excellently in many superficial cutaneous inflammations, like poison oak. Not long since, an obese patient with a seborrhœic skin got a most tantalizing suppurative folliculitis of the lower limbs that was unusually refractory. After using many applications with no success, finally the above paste was ordered with the idea of drowning out the lesions. The relief was instantaneous, and the control was almost complete, as only a few pustules would appear from time to time. A given quantity of the preparation spreads over a larger surface than an ointment, and remains more permanently in place, and does not soil the clothing.

Boeck devised a combination that on the continent of Europe is called a paste, although in this country it is called a lotion. It consists of:

℞	Amyli	
	Talc āā	40.00
	Glycerini	20.00
	Gummi arabici	1.00
	Liq. plumbi subacetas	4.00
	Aquæ	200.00

It is what is commonly called a "shake mixture." It is easy of application, clean, and with the addition of ten per cent. of liquor carbonis detergens, is one of the best antipruritics I have ever employed. As a modification of this, Schäffer advises using equal parts of powder and fluid as:

℞	Amyli	
	Talc	
	Glycerini	
	Aquæ, āā	50.00

This approaches the above-mentioned modification of Lassar's paste with glycerine, as advised by Jamieson. It is, however, more fluid, less sticky and acts more like a lotion.

Because of the hygroscopic nature of glycerine, the preparations containing it make the skin damp and clammy, a sensation to which those having eczema are often particularly susceptible; they often shudder. In cold, damp weather, therefore, it may be inadvisable to spread them over a large surface. In warm weather their coolness is often an advan-

tage. In those who have an idiosyncrasy toward glycerine, and there are many such, these glycerine preparations cannot be employed.

None of the pastes may be used on situations covered by thick hair, as the scalp, the pubes or the axillæ, as they make a felted mass, difficult to remove. They also should not be employed on mucous membranes, such as on the lips, prepuce or anus.

When starch and glycerine are prescribed the result is a peculiarly smooth mixture. Boiling these two ingredients together, however, makes quite a different substance, a jelly called a glycerole. Many years ago I prescribed Lassar's paste made with a glycerine base. The result was a crumbly mass that would not spread, and that had no effect on the skin whatever. I found that the druggist had boiled the starch and the glycerine together, and on being admonished, said that under similar circumstances he would do so again unless otherwise ordered. In other words, he had been trained to make the glycerole of starch. To avoid misunderstandings, a note may be appended to the prescription, ordering this not to be done.

Gelatine Paste. Other forms of paste are made by the addition of gelatine. These make casts, which, however, are lighter, more pliable and easier of application than those of plaster. Under certain circumstances these glues are wonderfully effective, especially in eczemas and ulcers of the leg, and in pruriginous affections in other situations, where it is desired to exclude the air, and protect the part from the injury of scratching.

The recipe I employ runs:

℞	Gelatine	46.00
	Zinci oxidi	28.00
	Glycerini	12.00
	Aquæ	114.00
		200.00

The water should first be heated and the gelatine dissolved in it. Then add the glycerine and oxide of zinc and stir until cold. At room temperature it makes a solid mass.

The amount here, two hundred grams or over six ounces, is a convenient quantity to use on both legs. It should be dispensed in a deep jar that can be set in hot water to fluidify the contents just before applying. This fluid should be spread on the part with a spatula or wooden tongue depressor, and before it cools it should be covered with fleecy tufts of cotton that sink into the mass and make a felt. The hairs of the surface of the skin add also to this felting, and keep the application locked to the surface. It makes an excellent air-tight dressing. I

have seen itchy lichen-like eruptions, controllable in no other way, controlled absolutely for years with this simple dressing, which can be worn unchanged for two or three weeks.

In eczema or ulcer of the leg complicated with varicose veins, in order to get compression as well as protection, the glue is combined with a bandage. In fact, a weak point of the treatment is the breaking of the bandage at the ankle-joint, in a situation therefore basically important in the control of a sluggish circulation. As compression and support of the circulation from below upwards are of great importance in these cases, the bandaging should begin at the foot. The leg is well elevated and massaged toward the body to empty out the blood, and then washed off with alcohol or benzine. Still holding the extremity elevated, it is painted with the glue and bandaged with gauze, again painted and again bandaged until a cast of sufficient thickness is obtained. Here Schäffer[1] makes one of those practical recommendations that so often facilitates a procedure.

In ordinary bandaging it is necessary from time to time, to reverse the bandage so as to adapt it perfectly to the leg. A wet gauze bandage, however, reverses badly; it tends to twist and rope, and, furthermore, there is no object in reversing, as the bandage sinks into the glue, where it is held fixed in position. Instead, therefore, of reversing, the bandage may be cut off square and allowed to sink into the mass. One may then begin afresh with a new turn, and so on up the leg. If an ulcer is present that does not secrete too freely, a compress covered with a salve may be laid over it, and the whole included in the bandage, or a window may be made over the ulcer. In any case, even where secretions are present, maceration does not take place, as the glue is permeable by fluids.

A great objection to these preparations is the number of constituents they contain. They and their modifications are innumerable, and it would be impossible to memorize them. It is entirely practical, however, to learn the physical qualities of the constituents and to adapt them to the end that is to be gained. If this is done it gives an interest and an intelligence to the work that makes it a pleasure and not a toil.

[1] Schäffer, J. Therapie d. Haut u. venerischen Krankheiten, 1915, p. 17.

NÆVUS ANÆMICUS.

By John E. Lane, M.D., New Haven.

Nævus anæmicus was first described by Vörner, in 1906. He differentiated it from albinismus partialis, with which it had probably been confounded up to that time, and reported four cases. In September, 1914, Nanta and Lavau, of Audry's clinic, collected seventeen published cases and added one of their own, which was the first to be reported in France. None of the cases collected by them was from this country, and in my search for reported cases I was unable to find any in the English and American literature.

Case Report.

Mrs. D., aged 30 years, was referred to me in March, 1916, by Dr. Wilder Tileston of this city, for chronic paronychia of several months' duration. The nails of the fingers of the left hand were being shed and the new ones that were replacing them were apparently normal. The thumbnail of this hand had not fallen but showed marked transverse furrows. There was a mild, subsiding paronychia of the little finger of the right hand.

Aside from this, the history disclosed nothing abnormal. The patient had always been well. The routine physical examination, both by Dr. Tileston and by myself, also disclosed nothing abnormal, except a moderately enlarged thyroid, which had never given rise to any symptoms. The Wassermann reaction, made at the laboratory of the Connecticut State Board of Health, was negative.

In course of the examination some small white spots were noticed on the right cheek, concerning which the following statements were elicited: They were present at this time because the patient had chilled her cheeks by a walk in the cold air. They are plainly seen when the face is flushed by blushing, cold, heat or exertion, but at other times they are hardly perceptible. They have been present as long as the patient can remember, and her mother says that they have existed since birth.

There are six of these spots on the right cheek, the uppermost one about two and a half centimeters below the outer angle of the eye, the others grouped below it. They are all nearly circular in shape, but the borders are somewhat irregular. The largest is about one centimeter in diameter and the smallest about half as large. The vessels at the border of the largest spot are slightly teleangiectatic but otherwise the surrounding skin is normal. The skin of the spots themselves is normal except for the color. Hairs are present and of the same color as on other parts of the face. The pores are plainly visible and of the same size as those of the surrounding skin. Sensation is normal. Firm pressure with glass causes the spots to disappear, showing that there is no difference in the pigmentation. The patient was seen at a second visit, when the spots were less noticeable, and the application of hot water confirmed her statement that heat increased their prominence.

There is a striking similarity in the description of all of the reported cases of this affection. It is always discovered by the physician during

an examination for some other disease, as it is of so trifling importance that it does not bring the patient to a physician and does not lead him to mention it when he comes for something else. The spots occasionally occur singly, but usually are found in groups. The grouping frequently resembles that of the vesicles in herpes zoster. The spots appear anæmic, but in other respects are indistinguishable from normal skin. They are generally somewhat rounded and their borders are sharply outlined and somewhat irregular. The surrounding skin is usually normal but sometimes there are slight teleangiectases at the edges. The spots can easily be made more prominent by friction, by heat or cold, and by light cupping.

The ætiology and histological changes are uncertain. The affection is congenital, and there is never any history of disease or accident preceding it. The few histological examinations that have been made give varying findings. Vörner found the blood vessels smaller than in normal skin and the smaller arteries had the structure of capillaries. The sweat glands were smaller than normal and in the centre were apparently lacking. Otherwise the tissue was normal. From the structure of the vessels he concluded that the anæmia was caused by their inability to dilate. Fischer found no abnormality in the structure of the skin, and thought the affection rested on a functional basis, explaining it as a sluggish reaction of the skin vessels to dilatation in limited areas, and the opposite of cutis marmorata, in which the vessels are dilated and are sluggish to contraction. Stein thought that the actual number of blood vessels was diminished. Sprinzel calls nævus anæmicus, "the negative of the common nævus vasculosus" and thinks it is due to fœtal narrowing or obliteration of some of the vessels.

There is no difficulty in the diagnosis of nævus anæmicus if its characteristic points are borne in mind. The only other congenital affection with which it can be confused is albinismus partialis. It differs from this in the fact that there is no lack of pigmentation in the affected areas. The history always distinguishes it from the acquired conditions that resemble it. The examination also easily differentiates it in most cases. In scars, the skin is not normal. In leucoderma there is loss of pigment. In vitiligo and in leuco-melanoderma (syphilitic leucoderma), there is loss of pigment with hyperpigmentation of the surrounding skin. Glass pressure discloses these anomalies of pigmentation if they are not otherwise easily distinguishable. The rare condition, lues leukischæmia, described by Brauer and by Vörner, gives the same physical characteristics as nævus anæmicus,—white spots without pigment changes in the spots or surrounding skin. Vörner states that skin

changes of this type also undoubtedly appear, occasionally, in some cases of dermatitis and erythema. These are distinguished from nævus anæmicus by the fact that they are not congenital, but acquired; they are also usually attended by eruptions on other parts of the body; they usually change in size quite rapidly; they are not permanent, but disappear either spontaneously or with treatment. To these conditions, resembling nævus anæmicus, Vörner gives the name dermato-anæmia circumscripta acquisita, thus distinguishing them from nævus anæmicus, and from spots of depigmentation, congenital and acquired.

The attempt has been made to make the bibliography complete. Most of the references were given in Nanta and Lavau's article, but two or three of these have been corrected and one or two new ones added.

References.

Vörner, H. Ueber Nævus Anæmicus. *Arch. f. Dermat. u. Syph.*, 1906, lxxxii, p. 391.

Seeger. Ein Fall von Nævus Anæmicus. Thesis, Leipzig, 1908. (Not accessible.)

Fischer, W. Ueber Nævus Anæmicus. *Arch. f. Dermat. u. Syph.*, 1909, xcvi, p. 47.

Stein, R. Ueber Nævus Anæmicus. *Arch. f. Dermat. u. Syph.*, 1910, ci, p. 311.

Sprinzel. (Case shown before the Wiener dermatologische Gesellschaft, Sitzung vom November, 1910). *Wien. klin. Wchnschr.*, 1910, xxiii, p. 1891.

Brauer. Ueber ein seltenes syphilitisches Exanthem (Lues leukischämica.) *Arch. f. Dermat. u. Syph.*, 1911, cvi, p. 85.

Vörner, H. Zirkumskripte Dermato-anämien (Leukischämien). *Arch. f. Dermat. u. Syph.*, 1912, cxi, p. 149.

Bruner. Nævus Anæmicus. *Gazeta lekarska*, Warszawa, 1912, 2s., xxxii,, p. 363. (Not accessible.)

Nanta et Lavau. Sur L'angio-nævus anèmique. *Ann. d. dermat. et d. syph.*, Aug.-Sept., 1914, v, p. 472.

Bruner, E. Nævus Anæmicus. *Ikonogr. Dermat.*, 1914, vii, p. 277.

Vörner, H. Zur Kenntniss des Nævus Anæmicus. *Arch. f. Dermat. u. Syph.*, 1915, cxxi, p. 368.

CLINICAL REPORT.

ARGYRIA FROM AN UNUSUAL SOURCE.

By A. Davidson, M.D., Los Angeles.

P. D. contracted an acute gonorrhœa before he acquired the knowledge that he who treats himself has a fool for a physician, so he promptly began injections of argyrol in ten per cent. solution.

Three weeks after he began treatment, he noticed the back of his hands becoming "reddish" and thought they felt cold. In six weeks they attained their present bluish color. They feel cold to the touch and are distinctly leaden colored, especially over the knuckles. The whole body is of a muddy tint, the nose, cheeks, thighs and hands showing more markedly the bluish discoloration. There is no line on the gums, except on the two lower incisors, where there is a deposit of tartar. The hair is unchanged.

The coloration, etc., is similar to many others described, but there are three unusual features in this case. I have seen no record of argyria from urethral absorption. Argyrol being an albuminate of silver, it is supposed to be impossible of absorption. Three weeks is a short time in which to produce argyria by local application.

He used urethral injections three times a day, retaining the same for five minutes. During the period prior to his coming under observation, he used, so far as he can recollect, the following amounts: Argyrol, 4 oz., at 10 per cent., 2 oz., at 25 per cent., 2 oz., at 30 per cent. Protargol, 4 oz., at 10 per cent. Albargin, 4 oz., at 5 per cent.

There is probably no portion of the human body from which absorption is as rapid as from the urethral surface. One quarter grain cocaine, injected into the deep urethra, will frequently cause immediate alarming symptoms and occasionally collapse, and the rapidity with which so-called catheter fever will develop, all indicate that the urethra has unusual capabilities for absorption. It is possible that in this case there may have been some solution of continuity in the mucous membrane, that facilitated absorption.

Up to the time of the first appearance of the discoloration, he had used 800 grains of argyrol and 200 grains of protargol, a total equal to 400 grains of metalic silver, but as only a small portion of this amount could possibly be absorbed, the argyria must have been produced by a comparatively small amount of the metal.

My experience with argyrol has led me to consider it of no more value than vaseline or any other such lubricant; perhaps it has some potentialities for good as well as evil.

CORRESPONDENCE.

TREATMENT OF TINEA BARBÆ.

To the Editor:

The average physician realizes how rebellious to treatment is the nodular or lumpy form of trichophytosis barbæ. I refer especially to the individuals who present themselves for treatment after the usual patent and domestic remedies have been tried. This is accurately described and illustrated in Ormsby's "Diseases of the Skin," page 888. At this stage we are confronted by one or more boggy, fluctuating tumors in size from a hazelnut to a walnut, with pus or a gelatinous fluid exuding from several sinuses. These circumscribed lumps are in various stages of softening and usually are limited to the chin, one cheek or directly under the ramus of the jaw. The hairs are easily epilated and the roots are club-shaped, swollen, and many times larger in diameter than the other portion of the hair. In the last five or six years I have treated twenty or more cases, including a number of kerions in children. During this time I have had no failures and the average number of treatments by the method I have successfully adopted rarely exceeds three or four. Two cases of kerions, as described recently by MacKee and Remer in the *New York Medical Record* for August 7, 1915, which had been running a month each, were cured in two weeks with one treatment in the one case and two in the other.

Recognizing the utter futility of trying to force the usual parasiticidal remedy into the focal centre of a boggy pus-laden tumor the size perhaps of a filbert or larger, I began the injection of tincture of iodine into every portion of the infected area. Preceding the iodine the mass is filled with a solution of novocaine and in ten minutes the iodine treatment is begun. Every part of the diseased area is loaded with iodine until it trickles from every sinus. If the tumor is on the cheek I insert a finger into the patient's mouth to steady the tumor and it is then thoroughly filled with iodine. Often I use a second syringeful, employing the common glass-barreled, hypodermatic syringe with a steel needle until I am assured every part is well injected. With children it has been my practice to use a few whiffs of ether followed by novocaine, then the iodine. The reaction is moderately severe. The patient is ordered to return in four or five days, as soon as the immediate soreness disappears, and if any part of the fungus growth shows vitality another injection is given. No other treatment is given although it is policy to use the regular application of any of the usual ointments.

My experience in the treatment of this stubborn disease is limited, falling to my lot only in the course of a general practice. I do not offer this as a specific but I do insist that I have cured all my cases speedily and without worry and I offer it to the profession for what it is worth.

Very recently I treated another case of this affection. It was of four weeks' duration when he came to me and there were a number of sinuses. When I injected the iodine there seemed to be quite an excavation already formed. The first injection destroyed all semblance of the infection but quite a cavity resulted which is now about healed. This case got three injections—the third was really superfluous. I have never seen the treatment mentioned in any text-book or article.

Very truly yours,

W. M. Beck, M.D., Clarkfield, Minn.

SOCIETY TRANSACTIONS.

NEW YORK DERMATOLOGICAL SOCIETY.

Regular Meeting, Feb. 15, 1916.

HOWARD FOX, M.D., *President.*

PRURIGO NODULARIS. Presented by DR. WILLIAMS.

The speaker said that he had presented this case before the American Dermatological Association and that the history had already been published in the *Amer. Jour. Med. Sci.* (September, 1915). As the condition was very rare, he thought it might interest the members to see the patient again. The condition had remained about the same, but a few new lesions had appeared and a small mass had developed in the left side of the tongue. The general condition was unaltered, and the itching was the same. The only change in any of the spots was suppuration occurring in some of the lesions on the legs, and was probably due to scratching.

DISCUSSION.

DR. FORDYCE said the case was a most interesting one and was very similar to the case presented by Dr. Johnston, some years ago. The entire picture in this case, however, was more intense. He suggested a blood examination, with the possibility of leukæmia as an underlying condition.

DR. MACKEE said that the number, the distribution, and the characteristics of the individual lesions were like those of the case presented by Dr. Zeisler, in St. Louis, three years ago. That patient also was a woman. The lesions also resembled, to some extent, Dr. Trimble's case of possible localized prurigo nodularis. Theoretically, the X-ray should be of some service in these cases.

DR. HEIMANN said that the main interest in this case was the consideration of its ætiology. If it were actually a prurigo, and hence in the urticaria group, it would be an anaphylactic disease. Leukæmia and pseudo-leukæmia, and, finally, tuberculosis, would have to be considered, and only a study of the blood, tuberculin tests, and microscopic examination of the lesions could clear up these points.

DR. TRIMBLE said that his patient, who had been referred to, was a young woman, twenty-four years of age, with lesions of just this nature on the outer aspect of the right thigh. She had been under the care of several physicians, Dr. Jackson being one. She wandered from one place to another and finally came to his clinic. The lesions were larger than those of the case shown, and the whole area exhibited a distinctly bluish tendency. She had any number of different forms of treatment, among them, the X-ray. The X-ray treatment, which was given several years ago, caused a great number of teleangiectases; making it take on the appearance of a nævus. The lesions were all confined to

one location, the outside of the thigh. Carbon dioxide snow was tried on one lesion. It had been applied before, but apparently not sufficiently. Then he applied it to one of the lesions, and considerable necrosis resulted, forming an ulcer. Finally, each lesion was removed by excision. The patient was seen eighteen months later, and there had been no recurrence. The lesions were identical with those in Dr. Williams' case, but were localized to one small area. Excision, of course, was impossible in a generalized case.

Dr. Williams said that Dr. Trimble had spoken of one case occurring in a woman. Up to the present, all cases reported had been in women. His patient's blood had not been examined with any view to determining the leukæmic nature of the disease. Anaphylaxis had not been thought of, as typical urticarial lesions had developed from time to time, and on at least one occasion there had been an eruption of purpuric erythema. The patient had been badly constipated, had suffered from severe headaches, muscular pains after slight exertion, somnolence after meals, and other symptoms of intestinal toxæmia. These symptoms were all relieved by appropriate treatment, attention to diet, etc., but without effect on the nodules. Carbon dioxide snow had been used, but without benefit. Pilocarpine had been given to the point of toleration, without causing any improvement, and the same was true of arsenic, whether given by mouth or by intravenous injection. Weekly bleeding of 100 to 150 cc., followed by infusion of salt solution, had no apparent effect. The lesions on the tongue seemed to be unique in this case. So far as he was aware, none of the other cases reported had shown any lesions on the mucous membranes.

The patient to whom Dr. Trimble referred had a very chronic lichenification of the skin, and the tumors arose from the lichenified areas; and the whole process seemed to be due to pruritus and the resultant scratching. In prurigo nodularis, on the other hand, lichenification was slight or absent, and the tumors arose from apparently normal skin.

SYCOSIS VULGARIS ON UPPER LIP OF WOMAN. Presented by Dr. Trimble.

The patient was fifty-two years old and had hypertrichosis of the upper lip. In the centre of the lip was an area of pustular folliculitis, probably due, originally, to a nasal discharge. The hairs on the lip were unusually long and well developed. The lip lesion had existed for a year or more. Later, the eyelashes had become infected.

Discussion.

Dr. Heimann said that very frequently one saw a form of sycosis after epilalation by electrolysis.

A CASE OF ULERYTHEMA OPHRYOGENES, MARKEDLY IMPROVED BY KROMAYER LIGHT APPLICATIONS. Presented by Dr. Clark.

The patient, J. S., was twenty-three years of age. He had always been generally well and strong. Four years ago, he first noticed a redness of the eyebrows, and had noticed for some time that the skin in the region of the eyebrows and on the forehead seemed to flush more than usual, on excitement or exertion. The eyebrows had thinned very considerably at the central and inner ends and had practically all fallen out at the outer third. The skin of the forehead, near the eyebrows and where the eyebrows had fallen, presented a thinly granular or pitted appearance.

This patient had had many kinds of applications that had been suggested in the literature for this disease, including some very strong antiseptic ointments, which resulted in the production of considerable dermatitis and peeling, without, however, any apparent effect upon the disease.

Four months ago, the patient began to receive Kromayer light treatments, exposures being made at a distance of two and a half inches, through a two millimetre blue filter and sufficiently strong to produce a mild "sunburn." Directly after this had subsided with the peeling that usually followed, another exposure was given, and the patient has had practically weekly exposures, over a period of three months. The patient had had no exposures for several weeks, but still showed some pigmentation from the light exposures, and presented a very marked improvement in his condition. The skin in the region of the eyebrows had lost its granular, pitted appearance, more new and fine long hairs had come in throughout the region of the eyebrows and particularly in the outer third, and numerous healthy, fine hairs seemed to be growing.

The case was presented before the Society at its October meeting, and was brought back to show a distinct improvement under Kromayer light treatment.

Discussion.

Dr. Wise said he noted a considerable amount of new hair over the outer third of the eyebrows. As he had very carefully examined the condition of the patient during his previous presentation before the Society, he was enabled to compare the extent of his alopecia upon the second presentation, and felt certain that a new growth of hair had taken place.

Dr. Trimble also thought the case showed improvement, as Dr. Wise had just said. He had noticed that erythema was still present, and was under the impression that erythema was the primary condition. If so, it would seem that any treatment which would increase the erythema would aggravate the condition. A year ago he had a private patient, a girl of fourteen, who presented an almost identical picture. Two or three attempts were made at treatment, and finally she was given a watery solution of resorcin, ten or twelve per cent. This was used for a short time, and then the patient disappeared and was not seen again until a few weeks ago, when she presented quite a little improvement. She stated that she had continued the resorcin treatment for some time. The erythema was still present. The case was very like the one presented by Dr. Clark.

Dr. Heimann said that if a restoration of hair growth could be produced in ulerythema ophryogenes, it was of more than mere therapeutic significance. A great many writers considered this disease a form of lupus erythematosus, and both clinical and microscopical findings favored this view. Thus, if the observations in this case were correct, it would be indicated that an atrophying process could be arrested and normal conditions reëstablished. He said that this was the first instance of this kind he had seen in this country, although the condition was not uncommon in Europe.

Dr. Whitehouse agreed with Dr. MacKee that the case could not be considered as cured, nor did he think Dr. Clark claimed that it was cured, but simply that it was improved. There were certainly new hairs on the outer third of the eyebrows, fine hairs coming out of what were funnel-shaped follicular openings. In his own opinion, there was distinct improvement. He had seen cases before, treated by resorcin, etc., used up to a considerable strength, but it only succeeded in cleaning up the plugged follicles. He did not agree with Dr. Fordyce that it was a great deal of trouble for a little thing. It was a good deal of a misfortune for one to have the eyebrows fall out and the follicles atrophy, and the condition warranted careful consideration on that

account. The erythema of which Dr. Trimble had spoken did precede the fall of the hair, and still persisted. In the history which Dr. Clark gave, mention was made of the attacks of erythema preceding the loss of hair. It was a question what this erythematous phase would eventually produce.

DERMATITIS EXFOLIATIVA. Presented by Dr. Wise.

The patient was a man, thirty-four years of age, who had been referred by Dr. Pollitzer for intravenous quinine injections. The lesions began six months ago as an erythematous patch on one thigh; they gradually spread, and four months ago a similar patch appeared on the other thigh, and then the condition became generalized.

On examination, the patient presented a uniform, diffusely reddened, moderately infiltrated skin, bearing small, adherent scales. In some regions the skin was tense and adherent to the underlying tissues. There was considerable emaciation, and the patient complained of intolerable pruritus. Quinine injections (½ per cent. quinine sulphate in salt solution) relieved the itching and improved the condition to some extent.

Discussion.

Dr. Heimann thought it was a case of pityriasis rubra of Hebra, or an exfoliative dermatitis. The histological picture would further indicate that it belonged to the erythrodermias, and since the condition appeared to have improved after the administration of quinine, the diagnosis of Wilson's disease seemed justifiable.

LUPUS VULGARIS. Presented by Dr. Wise for Dr. Fordyce.

The patient was a man, thirty-nine years of age, with a well-marked and widely spread lupus vulgaris, covering half the right side of the face. The lesion first appeared when the patient was seven years old. The point of its initial appearance was indicated by a distinct depression where the original patch had evidently been excised, though some diseased tissue must have been left and from this the lesion had extended. The patient had been sent by Dr. Saxe to the Vanderbilt Clinic for consultation.

MOLLUSCUM CONTAGIOSUM. Presented by Dr. Trimble.

The patient was a young man who had been tattooed on his forearm, seven months ago. One month later, the disease manifested itself. Two friends who were similarly tattooed at the same time, were also infected in the same way. There were great numbers of typical lesions situated in the tattooed area.

Discussion.

Dr. Fordyce said it was singular to note that molluscum contagiosum seemed to have an epidemic character. One can go along for years without seeing a case and then see several in close succession. He told of one case that he had seen with numerous lesions, followed closely by several others, although he had not previously seen a case for several years.

CASE FOR DIAGNOSIS. MYCOSIS FUNGOIDES? Presented by Dr. Kingsbury.

The patient stated that about three years before, itching "blotches" appeared all over the body and remained for two or three months, new lesions appearing progressively. The papules were of an eczematous character and pruritus was marked. The condition had grown steadily worse. She had been treated, but without any benefit.

Discussion.

Dr. Trimble thought it was a case of mycosis fungoides, possibly just beyond the pre-mycotic stage.

Dr. Wise agreed with Dr. Trimble, as also did Drs. Whitehouse and Fordyce.

Dr. Heimann agreed with the previous speakers, that it was a case of mycosis fungoides, not only clinically but microscopically. The only other thing that suggested itself from the microscopical picture was that it was parapsoriasis. It lacked some of the features of premycosis, emphasized by Unna. The picture consisted prevailingly of lymphocytes and a few mast cells, but no vascular changes of any moment, or giant cells. Clinically, there seemed to be no doubt but that it was a case of premycosis.

Dr. Howard Fox agreed with the other speakers that it was clinically a case of mycosis fungoides. There was more objective evidence of itching than was usually seen in this disease.

DERMATITIS MEDICAMENTOSA. Presented by Dr. Kingsbury.

The speaker stated that the patient had only just come to the hospital and was presented as an example of dermatitis due to absorption of a drug from the skin. It was evidently a case of dermatitis medicamentosa,—probably from the application of belladonna plaster to his back. The eruption was distributed chiefly on the trunk and consisted of numerous macules and small papules, together with patches of erythema.

Discussion.

Dr. Fordyce regarded the case as a dermatitis venenata or medicamentosa, due to the application of a belladonna plaster. A few days before, at the City Hospital, he had seen a generalized scarlatiniform erythema involving the entire body as well as the mucous membranes of the throat, resulting from the application of tincture of iodine, over a limited area of the skin. In this case, the patient had an elevation of temperature which lasted for several days. The condition simulated a scarlatina.

Dr. MacKee was not convinced that it was a case of dermatitis medicamentosa. The patient had applied the belladonna plaster, and a little later the eruption appeared locally and later spread over the entire body. That would suggest the possibility of dermatitis venenata. The one condition was the result of an external irritation; the other was the effect of the drug after it had entered the system by absorption, injection, or ingestion.

Dr. Trimble, referring to Dr. MacKee's remarks, asked if Dr. Kingsbury had not presented the case as one of systemic absorption of the drug, locally applied.

Dr. Whitehouse said he did not wish to split hairs on nomenclature, but he agreed with Dr. MacKee that it was a dermatitis spread over the skin by an irritant drug, and not a general efflorescence from belladonna, as would appear from absorption from the plaster. So it impressed him.

Dr. Heimann said that as a matter of convenience, the distinction made by Drs. MacKee and Whitehouse was good, but that it was biologically unsound. Whether the portal of entry of toxines was the gastro-intestinal tract or the skin, made no difference, since in any case the disease was systemic. He said he had seen two other identical cases within the previous three days, all caused by the use of belladonna plasters. The eruption had begun at the point of application and the disease had rapidly become systemic. It was a frequent occurrence to find systemic reactions to the local use of quinine, as, for instance, in hair washes. Ingestion was not a prerequisite for systemic involvement. So far as he understood the question, it was one of allergy.

Dr. Wise said his understanding was that the man had applied the belladonna plaster and had absorbed the drug, and that a rash resulted from absorption. He had seen a case of iodine poisoning from the application of iodine-petrogen to an area of skin the size of a fifty-cent piece. The patient had a papular eruption which a physician diagnosed as smallpox, and a temperature of 104° F. The area over which the iodine had been applied was not more inflamed than the rest of the skin.

Dr. MacKee said that it did not strike him as an eruption due to a drug acting from within. In the case referred to by Dr. Wise, there was a typical iododermia, showing that the drug had been absorbed into the circulation and was affecting the skin just as though the stomach had been the portal of entry. If the iodine had caused an eruption through its local irritating properties, the dermatitis would have been eczematous in character. Belladonna, when affecting the skin from within, produced a sudden outbreak of generalized scarlatiniform erythema. In the case in question, there was a catarrhal dermatitis, beginning at the site of the plaster and spreading to other parts, just as one would see an occupational dermatitis and dermatitis from other causes, such as hair dyes, poison ivy, etc.

Dr. Heimann expressed the opinion that there was much in what Dr. MacKee had said, but that it rather supported his own contention. At the point at which the dermatitis occurred, there was a very good field for absorption through the broken skin, and this might be part of the very mechanism by which the whole anaphylactic reaction was produced.

Dr. Trimble said that he had been much interested in Dr. Heimann's first remarks about the case and wished to know if he considered the case analagous to the hair-dye eruptions spreading over half of the body. The port of entry did not make much difference, but he would like to know if Dr. Heimann considered that it belonged to that class of eruption and, if so, whether he considered it as the absorption of the poisonous product of the hair dye or as peripheral spreading of the inflammation.

Dr. Heimann replied: Probably both. There was absorption, or one would not see such febrile reactions, such as Kaposi recorded in acute dermatitis. The second possibility was an extension of the process from the site of application. Every one knew that when hair lotions were applied to the scalp a dermatitis may develop far beyond this site.

Dr. Howard Fox felt that there had been a good deal of hair splitting in the discussion. He thought it likely that the eruption was due to an external irritant. There was no history, however, of the characteristic belladonna symptoms, such as dilated pupils, dry mouth, and scarlatiniform rash.

Dr. Kingsbury agreed with the opinion expressed by Dr. Wise. It was peculiar how differently different persons viewed the same eruption. When he first saw the case during the day, his whole impression was that it was a case of dermatitis medicamentosa. It was a generalized eruption suggesting measles; then, going into the history, he found that the man had applied a

belladonna plaster. The irritation there, was not much greater than on the other parts of the body. The question of the hair lotion dermatitis was largely speculative. Both views had been advanced about its spreading. In some instances it was undoubtedly absorbed; in others, it was purely local extension.

Dr. Fordyce reported a very interesting case of dermatitis involving the face and neck, which followed the use of a hair dye. In addition to the skin manifestations, the patient suffered from vertigo and headaches, and had been sent to various health resorts to be cured of these symptoms. Dr. Gilman Thompson, who saw the case with him, had investigated the chemistry of the dye and found that the German Government had prohibited the sale of this particular product on account of its toxic properties.

Reports of Cases Previously Presented:

Dr. Whitehouse reported on a case which he had previously shown of what he then thought was hæmorrhagic erythema multiforme, but which was regarded by most of the members as a case of purpura. The young woman stated that she had had the lesions several months and that when they recurred, they always appeared on the same areas. He had just been informed that the patient had returned with some acute lesions on the identical pigmented areas that she had shown before, and that these were erythematous hæmorrhagic plaques, with some thickening. It seemed to be an anomalous type of purpura. An infiltrated erythema rising out of the same pigmented spots was peculiar in any case, and he hoped to be able to follow it further.

Dr. MacKee said that two or three months ago, there were two cases of possible lichen atrophicus shown at the same meeting. The exhibitors promised to make histological studies and report later. It would be interesting to know the result.

Dr. Trimble said that with the consent of Dr. Williams, he could report on one. The patient had been shown by Dr. Williams at a previous meeting. The patient was a young man with one or two lesions on one forearm and one lesion on the other. These lesions were the size of a split pea, had a narrow raised border, and were seemingly atrophied in the centre. The section had been very carefully studied, but it had not been possible to reach a diagnosis. It could be said, however, that it was not lichen planus. The specimen showed a good deal of blood pigment, very little infiltration, and apparently some atrophy. Dr. Heimann had been asked to look at the specimen, and in the main agreed as to the findings.

Dr. Heimann said that the collagen was swollen peripherally, atrophied in the centre, and that the skin glands were absent. Where the collagen was swollen, it had the appearance of that seen in the early stages of scleroderma. There was no marked infiltration, as in lichen, and the lesion strongly suggested morphœa.

CHICAGO DERMATOLOGICAL SOCIETY.

Regular Meeting, Dec. 21, 1915.

F. G. Harris, M.D., *President.*

VON RECKLINGHAUSEN'S DISEASE. Presented by Dr. Ormsby.

A young woman, aged thirty, a trained nurse, had had the disease for 22 years. The tumors were small, the largest about hazel-nut size, and nearly all were sessile. The peculiar bluish appearance and the ease with which they

could be pushed back into the skin were striking. Interspersed among the tumors were various sized areas of pigmentation. Many of the tumors presented the peculiar nipple-like appearance. The presence of the lesions on the face in this instance was a source of great concern to the patient.

A stained section from one of the tumors, made by Dr. Stillians, showed the typical histological picture presented in this disease.

Discussion.

Dr. Pusey remarked on the fact that a deficient mentality, which was supposed to be common in these cases was often lacking, and called attention to this patient, who was mentally bright, as illustrating this fact. He thought that some of the face lesions suggested those of adenoma sebaceum.

Dr. Foerster mentioned three instances in which he had seen adenoma sebaceum and von Recklinghausen's disease in the same patient.

Dr. Harris said that he believed that the histology of von Recklinghausen's disease was distinctive and different from that of the ordinary fibroma molluscum.

RAYNAUD'S DISEASE. Presented by Dr. Ormsby.

A male, aged 27, had had the disorder for three years. He complained of poor circulation in both hands and feet. For the past three years the toes of the left foot had been cyanotic and from time to time ulcers appeared, which gradually healed. He complained of quite severe pain within the toes. Season was stated to have had no effect on the condition.

On examination, the relics of ulcers were seen and all of the toes of the left foot and the fifth toe of the right foot were found cyanotic. The Wassermann reaction was negative; blood pressure, 124.

Discussion.

Dr. Baer said he believed that the case was one of circulatory disturbance followed by necrosis.

Dr. Foerster said that he would consider it Raynaud's disease; but would not pronounce a final diagnosis without more study.

LUPUS ERYTHEMATOSUS. Presented by Dr. Pardee.

An actor, thirty years of age, who had lupus erythematosus 9 years ago, had had a vesicular eruption on the face for several months. The eruption began on the nose and spread peripherally to the cheeks. Then new areas of erythema, with grouped vesico-pustules, appeared on the forehead, neck and ears. It had improved at times under treatment with antiseptic ointments, but always recurred. The eruption on the hands had been noticed only about three weeks. A vesicular eruption was grouped over the nose, the flush areas of the cheeks, the ears and the forehead. The lips were scaly and cracked. Both palms and soles were covered by deep vesicles, and on the backs of the fingers a raised, red area extended down to the first joint, with a marked paronychia.

DISCUSSION.

DR. PARDEE said that though he had considered the case one of impetigo added to lupus erythematosus, he now thought that it was all undoubtedly lupus erythematosus.

DR. PUSEY thought that it was not necessary to invoke a secondary infection to account for the lesions. It may be all lupus erythematosus, including the pustular dermatitis on the hands and the paronychia.

CASE FOR DIAGNOSIS. NODULES ON THE FACE OF A NEGRO. Presented by DR. SHAFFNER.

The patient was a young man with about twenty scattered lesions on the face and eyelids; they were spherical, translucent, glistening, some flat topped, almost gelatinous in consistency, and were present for about six months.

DISCUSSION.

DR. PUSEY considered the case to be one of keloids.

DR. HARRIS thought the tumors might be endotheliomata.

URTICARIA PIGMENTOSA. Presented by DR. STILLIANS.

A baby girl of 17 months had had the disease since she was three months old. The child was covered by soft, flat, round, slightly raised papules, chamois colored or darker, which reacted on irritation with the formation of wheals. No signs or history of itching. It was interesting to note that the mother gave a definite history of mild epidermolysis bullosa since her own childhood.

MULTIPLE PIGMENTED TUMORS OF THE SKIN. Presented by DR. SIMPSON.

A man of 28 years had a pigmented mole "clipped off" his back in 1905. It was the size of a hazel nut. Recurring five months later, it was again cut off, but a year later recurred again and grew to half walnut size. An excision beyond the apparent border of the tumor was then made, and the wound left to granulate, leaving the scar seen in the lower dorsal region, over 3 by 2 inches. In september, 1914, nine years after the original operation, the first of the present crop of tumors appeared on the neck, and since then they steadily increased in number and size, until he had about forty, from pea sized to the size of a hen's egg. The superficial ones were bluish black; the deeper ones showed bluish through the overlying skin.

DISCUSSION.

DR. PUSEY said he would consider them melano-sarcomata.

DR. ORMSBY said that he rather favored the view that these were nævo-carcinomata.

SCAPHOID NAILS, CURED. Presented by DR. HARRIS.

Three months before, the colored man, 38 years old, presented himself with typical scaphoid finger nails. The central depression was very well marked, and caused pain, seemingly due to pressure on the nail bed.

DISCUSSION.

DR. PUSEY congratulated Dr. Harris on his result and asked him to tell how he obtained it. He knew nothing that affected these nutritional disturbances of the nails as a rule.

DR. HARRIS replied that the treatment was a salicylic acid and oil of rusci ointment. To what other factors the improvement was due, he did not know.

ACTINOMYCOSIS OF THE NECK. Presented by DR. HARRIS.

The patient was a man, 34 years old; for 19 years he had a suppurative condition of the glands of the neck. He had had four operations and internal treatment. One month ago, when first seen, there was a discharging sinus along the anterior border of sterno-cleido-mastoid muscle at the level of the cricoid cartilage. The pus was thick and contained yellow granules, which were found to be actinomyces. X-ray treatment and potassium iodide produced a cure.

REACTION OF SKIN TO INJECTIONS OF AGAR. Presented by DR. STOKES.

This case was shown for the purpose of getting the opinion of the members on the resemblance of the lesion to a luetin reaction. The lesion consisted of a raised papulo-pustule with a central, slightly scaling crust, situated below the deltoid insertion on the right arm. This was the fifteenth day and the lesion was then undergoing involution. The patient was in the secondary stage of syphilis, with a positive Wassermann, and had been under vigorous treatment with mercury salicylate injections. Under similar conditions luetin had been known to produce positive reactions. The reaction in the present case was produced by 0.1 cc. of a 1% suspension of agar. The patient had not been receiving iodides. The speaker stated that in the course of experimental studies in intradermal sensitization, he had found reason to believe that the specificity of certain cutaneous tests, and especially of the luetin reaction, could be attacked. That is, they could hardly be regarded as purely antigen-amboceptor reactions in accordance with the older conceptions of the Friedberger school of immunologists. He had succeeded in producing fairly good clinical imitations of the luetin reaction with injections of sterile agar, and of skin emulsions in late syphilis, regardless of the use of potassium iodide. Such reactions apparently did not occur in normal persons, or in such dermatoses as psoriasis. The explanation advanced by the speaker for such phenomena was that of a local adsorption of anti-ferments by the injected substances. This adsorption of the protective agents in the skin or serum, uncovered proteolytic ferments at the site of injection, whose action then gave rise to autolysis with anaphylatoxine formation and inflammation. The speaker ventured the belief that such studies might throw considerable light upon the immunity mechanism and on the allergic phenomena of late syphilis, and stated that he was conducting experiments along these lines, and that some of the results were in process of publication.

ECTHYMA. Presented by DR. PUSEY.

The patient was a man of 55 years, with ulcerative lesions over the body and limbs for the past 10 months. He had had diabetes since 1907, and his right leg was amputated in 1914, because of diabetic gangræne. A doubtful history of syphilitic infection 20 years ago was given, the patient appeared in poor health and presented multiple, angry looking ulcers, from the size of a split pea to that of a nickle, surrounded by slight induration and covered by bloody

crusts. Scars of previous lesions showed hyperpigmentation. Scratch marks were present. The Wassermann was positive. The urine was heavy with sugar.

Discussion.

Dr. Ormsby said that some of the lesions appeared to be factitious, though most of them could hardly be placed in that category. The case did not present the usual characteristics of dermatitis factitia. He was in doubt as to the proper placing of the disorder.

Dr. Foerster noticed that all the lesions could be easily reached by the patient. The fact that the man had diabetes should not be forgotten.

Dr. Heidingsfeld thought it a late, secondary, ulcerating, papular syphiloderm.

Dr. Harris said he considered it a case of dermatitis nodularis necrotica; that he had had a case some time ago, a young man apparently in robust health, who developed nodules that became gangrænous in the centre, leaving slowly healing scars.

Dr. Pusey considered it to be a case of gangrænous ecthyma in a cachectic, diabetic patient.

MANHATTAN DERMATOLOGICAL SOCIETY.

Regular Meeting, Jan. 14, 1916.

George M. MacKee, M.D., *Chairman.*

ERYTHEMA MULTIFORME PERSTANS. Presented by Drs. MacKee and Wise.

The patient, a female adult, had been shown before the Society in March of the previous year, as a rather unusual type of erythema multiforme. This eruption, instead of running its usual course, had been persistent, so that the speakers had changed their diagnosis, tentatively, to one of erythema multiforme perstans. The interesting feature, the speaker said, was not so much the persistence of the lesions which could be seen on the patient's face and upper extremities, as the formation of verrucous growths, which appeared over the sites of the original lesions. They showed quite plainly on the face and arms. A biopsy had been taken and the slides were presented for examination. They exhibited chiefly a very marked dilatation of the blood vessels, additional new blood vessels and considerable round cell infiltration in the corium; Dr. Wise said there was a possibility of this being a tuberculous lesion. The case was presented as an erythema multiforme perstans, with superimposed lesions of a verrucous nature. Some of the lesions had cleared up at one time under autogenous vaccines, but those on the face had remained for over a year.

Discussion.

Dr. Oulmann said that the microscopical picture of the section of this case reminded him of pictures of angiokeratoma. The only difference was that he did not find the stasis of blood and plasma in the widened vessels and lymph spaces, while the acanthosis as well as the keratosis were present and the cutis was in a state of inflammation. Also he believed that one or two lesions on the fingers could be regarded as angiokeratoma. He thought this case a combination of erythema multiforme and angiokeratoma.

Dr. Satenstein said he had studied some of the sections of this case when previously presented and found in them all the markings of erythema mutiforme.

CIRCINATE SYPHILIS. Presented by Drs. MacKee and Wise.

The patient was a colored female adult, twenty-nine years of age and married. She presented an eruption on the neck and parts of the face, which required very little description, the case being so characteristic, but the patient was shown because of the rather unusual, marked circinate arrangement. The speaker said the lesions began to clear up under the very first treatment, so that they were not nearly so distinct as when first seen. The duration of the eruption had been since the previous October.

KELOIDS. Presented by Dr. Oulmann.

The patient, a female adult, had received a severe burn from fire, eighteen months before. The lower part of both arms and the frontal neck and lower chin were one mass of keloids. As she could not raise the head, a plastic operation was performed and a flap from the upper arm was taken, and healed with splendid result. But the margin consisted of lines of keloid; where the flap was taken from, keloids also developed. The case was shown to demonstrate the predisposition for keloids, as the case was treated aseptically and antiseptically.

TUBERCULIDE. Presented by Dr. Parounagian.

The patient was a female, twenty-eight years of age, married and born in Russia. The family history was negative; she was apparently in good health. Her skin affection began about eight years previously, on the dorsal surfaces of the fingers. The lesions were symmetrical, extending up to her elbows and a few lesions on the extensor surfaces of both knees. There were a number of recent lesions and a great many older ones, dark-purplish in color, with necrotic centres. The case was a typical example of the disease.

Discussion.

Dr. Satenstein asked Dr. Oulmann what his results had been with the use of tuberculin. How many cases had he treated and how many von Pirquet reactions had been made by him, the speaker asked.

Dr. Oulmann answered that he lately did not have any cases of tuberculide. Of those cases mentioned in a former statement, he used the von Pirquet test as treatment only, five to six times, to get the result, while in others he used it up to eighteen times. In one case of mixed Bazin's disease and tuberculide, he used the Park, Davis and Co. tuberculin tablets, with excellent results.

LUPUS ERYTHEMATOUS. Presented by Dr. Weiss.

The patient was a female adult, who showed extensive lupus erythematosus lesions of the face and head. The speaker said that the disease was very rarely observed to be of such great extent on the head. The patient showed depressed, atrophic spots all over the scalp, with an absolute alopecia. The duration of the disease had been three years.

Discussion.

Dr. Oulmann said that the condition of the scalp was not exactly like that of lupus erythematosus in that locality. There they found a loss of hair, which was circumscribed, a red scaly skin with more or less central atrophy. Here

they found an almost entire loss of hair with very little atrophy, and the skin was thinned and showed numerous little blood-vessels. While he did not doubt the skin lesions being due to lupus erythematosus, he did not accept the scalp condition as lupus erythematosus alone.

Dr. Parounagian recognized the patient, whom he had treated some months previously at the Gouverneur Clinic. He stated that the condition had progressed since. The scalp condition he did not recall as the patient wore a tight wig at that time. She was very recalcitrant and did not attend regularly.

Dr. Weiss said that to him there was no doubt of the diagnosis of lupus erythematosus on the face, but on the scalp he took into consideration folliculitis decalvans; but there was here scar formation, atrophy and depression, while the peripheral portions carried no follicular elevations, as would be seen in that disease. The speaker said he had stated that there was no follicular atrophy, and thought that the two diseases may coexist.

PURPURA? Presented by Drs. MacKee and Wise.

The patient, J. M., was a male adult, twenty-two years of age, born in the United States; his family history was negative. He had been exhibited by Dr. Whitehouse at the Academy of Medicine, one year previously. Seven years before he was shown before the Society, the patient went camping in summer and when he returned home he found an eruption of "blood spots," limited to the upper extremities and axillæ. This eruption was preceded by no illness of any kind. The physical examination was negative and the patient appeared to be entirely well. He presented an eruption of purpura in the retrogressive stage, some of the lesions being pigmented spots and others true extravasations of blood, limited entirely to the upper extremities. The speaker said it was remarkable that lesions had been coming out during seven years and that they were limited to the upper and were absent on the lower extremities. The ætiology was obscure. The patient also presented an acne of the face.

Discussion.

Dr. Wallhauser said he was inclined to regard this case as one of parapsoriasis lichenoides, presenting an unusual feature in the hæmorrhagic lesions.

Dr. Satenstein said that the lesions in this case were transitory, which was not the history of parapsoriasis.

Dr. Oulmann said that if Drs. MacKee and Wise stated that the man had at certain times attacks of purpura, as the speaker's description showed, that was enough reason for believing that to be a fact. The patient had, besides, especially on the upper arms, some psoriasis-like lesions and small, striated atrophic patches on his skin. Some cases of psoriasis and parapsoriasis, he said, would be very hard to diagnose without further study.

Dr. Wise said that two things had to be taken into consideration,—first, that when Dr. Whitehouse presented this case it had been a true purpura and secondly, that at the clinic, when seen by the speaker, he also had a true purpura. The speaker had studied the literature on the subject of parapsoriasis and he had noted that purpura was not a feature of parapsoriasis. There may be an increase in the blood vessels, but no hæmorrhage took place in the skin. The speaker freely admitted, however, that the case looked like parapsoriasis of the guttate variety. He intended to remove a piece of skin for microscopic study.

ECZEMA ERYTHEMATOSUM. Presented by Dr. Weiss.

The patient was a male adult, who showed eczema erythematosum of the face, of several years' duration. The face was discolored and there were multiple melanotic warts on the eyelids and bronzed coloring of the skin, which gave an indication of adrenalin insufficiency, and he was put on small doses of suprarenalin. There was some puffiness of the face before treatment, with a subsidence of the condition afterwards. The skin of the face commenced to peel and the patient felt better. He had been observed for symptoms of Addison's disease, the speaker stated, as such blemishes were very often found in adrenal insufficiency.

Discussion.

Dr. Oulmann said that the pigmentation was seen not only in the face but also on the lower arms. This condition was seen in quite a number of people who were exposed much to air and light, probably due to influence of ultraviolet rays. Whether the pigmentation was brought on in people with abnormality in the secretion of their adrenal glands or in those with liver trouble, he was not able to state, but it was interesting to watch the effect of the treatment.

Dr. Weiss said he believed that sooner or later, dermatologists would have to get acquainted with the influence the ductless glands exert on the skin. The old French and English schools always held, without knowing anything about ductless glands and their deficiencies, that most skin diseases were due to some internal disorder, which caused the external manifestations. The Vienna school, under Hebra, ridiculed that as impossible. It was a well-known fact that the adrenals caused a great deal of trouble when they were deficient. Besides causing hypernephroma and Addison's disease, as the extremes of their affections, there were minor grades of their deficiency, not well observed yet and having great influence on the system and also on the skin. The patient presented simply an erythematous eczema of the face. The speaker would not say that adrenalin deficiency alone caused the eczema, but that by administering suprarenalin, the patient did get better.

Besides his pseudo-bronze color in the face, the speaker stated that this patient showed the regular adrenal hair distribution, with a tuft of hair over the sacrum and a tuft of hair in the nape of the neck. Those cases who had this distribution always had slight adrenal deficiency and some trouble with the glycogen secretion of the liver. By offering these casual remarks, which, the speaker said, were very incomplete, he only wanted to draw attention to the pathology and ætiology of the ductless glands and their correlation to the skin.

MINNESOTA DERMATOLOGICAL SOCIETY.

Regular Meeting, April 11th, 1916, held at St. Paul, Minn.

Burnside Foster, M.D., *President.*

MYCOSIS FUNGOIDES. Presented by Dr. Foster.

F. G., male, aged forty-five years. About eighteen months ago, he first noticed an eruption on the back of the legs near the ankles, which soon began to itch exceedingly and gradually spread to the upper part of both legs and thighs. A few months later, the same eruption appeared on the arms and wrists. The eruption was general on the extremities, with here and there a

patch on the body. The eruption was salmon-colored, slightly scaly in places, with a few indurated and very scaly spots on both buttocks. There was intense itching. The patient complained of chilliness.

GRANULOMA PYOGENICUM. Presented by Dr. Butler.

The patient was a male adult with a tumor-like mass, the size of a silver dollar, located on the chin.

Discussion.

Dr. Irvine stated that as the patient had had potassium iodide, the negative blastomyces examination would not absolutely rule out blastomycosis.

Dr. Olson agreed with the diagnosis of granuloma pyogenicum, and stated that about one year ago he had seen a granuloma pyogenicum exactly similar to this one, but located on the back of the neck.

SCLERODERMA. Presented by Dr. Butler.

The patient was a male adult with large patches of scleroderma on the neck.

PHLEBITIS LUETICA. Presented by Dr. Olson.

Male, aged thirty-five years. This patient had had a practically untreated syphilis for ten years. Infection was acquired in the Philippines. During the past year he had had "dropsy" of the right leg, the latter having been at times twice the size of the left leg. The right leg below the knee was markedly œdematous. The right long saphenous vein, near the groin, was thickened for a distance of five or six inches, so that it felt like a piece of rubber tubing. The Wassermann reaction was four plus. The patient showed marked improvement following five mercury salicylate injections.

Discussion.

Dr. Armstrong cited a similar case that he had seen, which involved the saphenous vein, in which the vein felt like a piano wire, and could be traced the entire length of the leg. This occurred in a patient with early secondary lues.

LICHEN SCLEROSUS ET ATROPHICUS. Presented by Dr. Sweitzer.

Miss U., aged twenty-one years. This patient had had the disease for three and one half years. The lesion consisted of a white, slightly elevated and infiltrated round area, on the nape of the neck. It was smooth and had no scales, but the surface showed an accentuation of the normal folds of the skin. Considerable itching was present. The lesion was fairly round and about two inches in diameter.

TABES AND LARGE SERPIGINOUS SYPHILIDE. Presented by Dr. Armstrong.

The patient, a male adult, had had very little treatment for syphilis. He showed typical tabes and a palm-sized serpiginous syphilide on the back. The patient was presented because of the rarity of skin lesions of syphilis in tabetics.

MYCOSIS FUNGOIDES. Report of Case by Dr. Thomas.

Numerous photographs and microscopic slides were shown from this patient, a male adult, who had large erythrodermia-like patches and some proliferating and ulcerating lesions on the abdomen. The slides were characteristic of mycosis fungoides.

SYPHILIS. MARITAL REINFECTION. Report of Case by Dr. Wright.

This patient acquired syphilis last fall, at which time he infected his wife. He had thorough salvarsan treatment last fall and winter. This spring he presented a typical primary lesion containing numerous spirochætæ of syphilis. Other exposure than with his wife was denied by the patient.

DISCUSSION OF AMERICAN, CANADIAN AND FRENCH SALVARSANS.

Dr. Wright stated that he had given fifty to sixty injections of diarsenol and had had no trouble when the diarsenol was given well diluted. In one patient, following the injection of a more concentrated solution, there had occurred marked shock.

Dr. Butler stated that he had given many injections of the French novo-arsenobenzol, with satisfactory results, although he preferred the German neosalvarsan.

Dr. Thomas said that at the Mayo Clinic he had given one hundred injections of diarsenol. More irritation in the arm, and greater systemic reaction resulted from the concentrated solutions, so that he advised the use of well-diluted solutions.

Dr. Freeman thought that the therapeutic efficiency of arsenobenzol was equal to that of neosalvarsan. He had given about fifty injections of arsenobenzol. One lot of the arsenobenzol gave rather cloudy solutions, but no ill effects resulted from the injections. He stated that he had found diarsenol more toxic than arsenobenzol. In one patient, after giving part of a dose of diarsenol, alarming symptoms,—spasm of the muscles, unconsciousness, weak pulse, vomiting, etc., followed. This patient recovered and was all right the next day.

Dr. Irvine had given more than twenty-five injections of arsenobenzol. Vomiting in one case, and some shock, rapid pulse, etc., in another occurred, although the reaction in neither patient was severe.

Dr. Foster suggested that some of the reactions might come from the salt solution or water, and Dr. Thomas stated that at the Mayo Clinic slight disturbances had followed the intravenous injection of salt solution alone.

The consensus of opinion was that the German salvarsan was the least toxic of the salvarsans, and that the American salvarsan or aresnobenzol ranked next. The majority favored giving arsenobenzol in large amounts of water—180 to 240 cc.

REVIEW

OF

DERMATOLOGY AND SYPHILIS.

Under the direction of

FRED WISE, M.D., New York,

Assisted by

CLARENCE A. BAER, M.D., Milwaukee.
WILLIAM H. BAUGHMAN, M.D., New York.
PAUL E. BECHET, M.D., New York.
J. S. EISENSTAEDT, M.D., Chicago.
CHARLES GOOSMANN, M.D., Cincinnati.
JAMES F. GRATTAN, M.D., New York.
ROBERT C. JAMIESON, M.D., Detroit.
FREDERICK T. LAU, M.D., New York.
M. F. LAUTMAN, M.D., Hot Springs.
OSCAR L. LEVIN, M.D., New York.
M. L. RAVITCH, M.D., Louisville.
ISADORE ROSEN, M.D., New York.
MAX SCHEER, M.D., New York.
PHILIP F. SHAFFNER, M.D., Chicago.
A. W. STILLIANS, M.D., Chicago.
JOHN H. STOKES, M.D., Chicago.
HARVEY P. TOWLE, M.D., Boston.
VICENTE PARDO, M.D., Havana, Cuba.

DERMATOLOGISCHE WOCHENSCHRIFT.

(Feb. 19, 1916, lxii, No. 7.)

Abstracted by MAX SCHEER, M.D.

THE WASSERMANN REACTION IN THE PRIMARY LESION OF SYPHILIS. H. HECHT, p. 145.

In the author's opinion the results of Bendig's investigations (*Dermat. Wchnschr.*, 1915, 1) do not in the least diminish the value of the Wassermann reaction. In primary lues the Wassermann reaction is the more apt to be positive, the longer the duration of the infection. A positive Wassermann reaction is very rare before three weeks after the infection. A positive Wassermann reaction, even in the absence of other manifestations, speaks for syphilis; the exceptions are well known and should always be kept in view.

(*Ibidem*, Mar. 11, 1916, lxii, No. 10.)

THE NATURE OF ECZEMA. SAMBERGER, p. 217.

Eczema differs from other superficial inflammatory skin affections clinically and (according to Unna) histologically. Brocq calls eczema an inflammation of the skin of "*special d'aspect.*" In eczema, according to Unna, the epithelial cells are compressed, but not necrobiotic and the vesicles are intracellular (spongiosis). In previous papers in this *Journal*, the author discussed the nature of inflammatory and lymphatic reactions. He believes that the clinical appearances of eczema can be explained by assuming a combination of inflammatory and lymphatic reactions, as the pathological basis. Usually the inflammatory reaction predominates; when the lymphatic reaction is in excess, lesions may result similar to those described by Neisser as urticarial eczema and by Martinotti as acute exudative œdema of the skin.

LUPUS CARCINOMA AND ROENTGEN RAYS. G. STÜMPKE, p. 226.

The first case was that of a man, 68 years old, with lupus vulgaris of 25 years' duration, on the right side of the neck. In the middle of this lesion was a cutaneous horn, two cm. long. The lupus lesions were treated first with pyrogallic acid salve and later with a sharp curette; the cutaneous horn, with three erythema doses of a moderately hard ray, given in the course of eight weeks. The therapeutic results were good. Three months after the X-ray treatment, a nodule appeared over the site where the cutaneous horn had been. A biopsy showed this nodule to be a squamous celled carcinoma. Its development on the area that was rayed suggested that the X-ray was the causative factor.

The second case was in a man, 58 years old, with lupus vulgaris of 25 years' duration, in the popliteal space. The lesions were curetted and the patient remained well for three and a quarter years. He then noticed a small nodule in the scar, for which a physician had given him 30 X-ray treatments—unmeasured and probably with a soft tube—over a period of five months. During the treatment the tumor grew rapidly. Biopsy showed a squamous celled carcinoma.

These were the only cases of lupus vulgaris that had received X-ray treatments. In 150 other cases under the author's observation, in which other methods were employed, he never saw a carcinoma arise. Lupus vulgaris should be treated surgically. Only inoperable cases should be rayed; the dose should be measured; a hard tube used, and the ray filtered.

ANNALES DES MALADIES VÉNÉRIENNES.

(April, 1915, x, No. 4.)

Abstracted by PAUL E. BECHET, M.D.

VIRULENT HEREDITARY SYPHILIS OCCURRING TWENTY YEARS AFTER SYPHILIZATION OF THE MOTHER. GAUCHER, BIZARD, BALZER AND DELCAMP, p. 193.

The authors report a case of hereditary syphilis manifesting itself forty days after birth by fissures at the angle of the mouth, mucous patches on the lower

lip, moist papules on the scrotum, and a vesiculo-bullous eruption on the right foot. The mother had had a syphilitic infection twenty years previously, and had been entirely free from specific symptoms for many years. The father was absolutely free from syphilis.

(*Ibidem*, May, 1915, x, No. 5.)

GUMMA OF THE TONGUE IN A HEREDITARY SYPHILITIC, NINE YEARS OF AGE, PRESENTING WIDELY SEPARATED MEDIAN SUPERIOR INCISORS. GAUCHER, BIZARD AND BALZER, p. 257.

Report of a case.

(*Ibidem*, June, 1915, x, No. 6.)

CHANCRE OF THE PREPUCE WITH PHIMOSIS. GAUCHER, BIZARD AND BRALEZ, p. 321.

The authors report seven cases of this type of chancre, which is usually situated on the entire circumference of the free cutaneous border of the prepuce, assuming a crown-like appearance. To the touch the induration is disc-like. The lesion is of a bright red color, bleeds easily, and causes a marked phimosis.

(*Ibidem*, August, 1915, x, No. 8.)

CHANCROIDAL BUBOES WITHOUT A PRIMARY LESION. GOUGEROT, p. 449.

Gougerot reports several cases of chancroidal adenitis in which the presence of the streptobacillus of Ducréy was demonstrated, without a chancroid being present. It is possible for Ducréy's bacillus to pass through the mucous membrane without leaving a visible trace of its passage, and cause infection of the inguinal glands.

CHRONIC CHANCROIDAL BUBOES. GOUGEROT, p. 459.

The author discusses the various varieties of chronic chancroidal buboes, but brings out nothing essentially new.

(*Ibidem*, September, 1915, x, No. 9.)

DEATH FROM INJECTIONS OF GRAY OIL. GAUCHER, p. 513.

Gaucher mentions the fact of his having previously published statistics of twelve deaths following the injection of gray oil. He reports a case of a man, aged 50, who began treatment immediately after the appearance of the chancre. He first received ten injections of biniodide of mercury, which were well tolerated. The treatment was then changed, the patient receiving ten injections of gray oil, administered once weekly, each dose amounting to five centigrammes of mercury. The total dosage was fifty centigrammes. A very grave stomatitis supervened, the whole floor of the mouth was denuded and greatly infiltrated. The jaws were tightly locked, the breath exceedingly fœtid. Diarrhœa was absent. The pulse, while good, was intermittent. Death occurred in two days. In conclusion, Gaucher condemns the administration of gray oil.

(*Ibidem*, October, 1915, x, No. 10.)

THE ZOSTERIFORM SYPHILIDES. GAUCHER, BIZARD AND BRALEZ, p. 557.

Under this heading the authors report their observations in 26 cases of papulo-squamous syphilides, which, instead of being irregularly scattered over the body, are grouped over the course of certain nerves, markedly simulating zoster. The similarity was only one of distribution and locality, however, as the lesions were not vesiculo-bullous.

RUSSKI JOORNAL KOJNIKH E VENERICHESKIKH BOLEZNEI.

(Jan., Feb., Mar., 1915, xxix, Nos. 1 to 3.

Abstracted by M. L. RAVITCH, M.D.

MULTIPLE IDIOPATHIC HÆMORRHAGIC SARCOMA OF THE SKIN (KAPOSI). GROIGORYEV, p. 3.

Kaposi, in 1872, classified this disease as a separate nosological entity, describing it as brown, bluish or purple spots on the feet, hands and face, due to hæmorrhages in the skin; these spots afterward develop into flat or raised nodules, varying in size from a shot to a cherry: this is usually preceded by œdema and pruritis. In a later stage these nodules may enlarge or swell as if fluid were accumulated in them; they are painless, as a rule, though Schwimmer reported some very painful ones. Besides these nodules or tumors, a diffused elephantiasis was observed in some cases, as has been described by Pick, or infiltrations alone may appear, as in Kracht's case.

There are many deviations from the description of Kaposi. For example, Prof. Tanturri, in 1887, observed in one case (out of his seven cases) that nodules appeared in the region of the knee and also below the ribs. Dr. Fokin exhibited, in 1897, before the 12th International Congress in Moscow, a case of sarcoma Kaposi in which only the clavicular region and palm of the left hand were affected.

The mucous membranes are also sometimes affected; Radaeli, Halle, Kaposi and Seziak mention such cases. In 1869, Kaposi reported that he observed manifestations of the disease in the internal organs at autopsy, in several of his cases, and De-Amicis, Hallopeau, Semenov, Pini, Mariani, Sternberg and others claim that the disease is not uncommon in the internal organs. Scholtz, Bernhardt, Halle and Zumbusch found that the caseous structures were sometimes involved. While the majority of the observers deny involvement of the lymphatic glands, Tanturri, Deballa, Schwimmer and Sellei claim to have observed cases in which some lymphatic glands were affected. Satrapa, Semenev, and Tiptzer believe that the appearance of headaches, neuralgia and paræsthesia and an increase in the reflexes show that the disease affects the nervous system. It is peculiar that women rarely suffer from this disease, according to many observers. As to blood changes in multiple hæmorrhagic sarcoma (Kaposi), the majority of the observers could find nothing of significance. In the later stages of the disease, after cachexia has set in, there is the expected decrease in hæmoglobin and low number of erythrocytes, and also an increase

in the leucocytes. Urinalysis does not show any change in the urine in this disease.

The ætiology of the disease is rather obscure, and those who have observed cases of it, advance different theories. The infectious theory has as many adherents as does that which attributes the disease to systemic disturbances.

Geographic distribution does play an important part. Statistics show that the disease is more prevalent in Poland, Austria-Hungary and Italy, but a racial susceptibility to this disease has not been established.

The results of treatment have been very unsatisfactory, though X-ray and Finsen light treatment have proved very beneficial in some cases.

The author cites several interesting cases and gives the minute anatomy of his pathological findings; the latter, however, are no more definite than those described by Fordyce, Wende and others.

THE TREATMENT OF BURNS. Beck, p. 27.

Bogrov describes Beck's treatment of burns in the children's clinic in Budapest. After all of the blisters have been opened, the patient is immersed in a bath, for 5 to 30 minutes, at a temperature of about 90° F. Afterwards the burns are covered with warm bandages soaked in a solution of 1-4,000 of potassium permanganate, the bandages being changed every half hour. If possible, a bath of very mild potassium permanganate solutions are given for 30 to 40 minutes twice a day. To maintain the heart action, hypodermic injections of digitalis or camphorated oil are administered. The children are fed milk in small portions. Later, ointments of 8% of amido-azo-toluol and 5% bromide of zinc are applied for the purpose of hastening epithelial proliferation, and prolonged baths without permanganate of potassium are given. Every fourth or fifth day borated vaseline is applied to prevent irritation of the skin. Excessive granulation is checked by the silver nitrate stick. Massage is advised when cicatrization sets in. In case of keloid formation, carbon dioxide snow is advocated; sometimes injections of fibrolysin are of benefit.

THREE INTERESTING CASES OF PARAKERATOSIS AND ITS PHYSICO-THERAPY. Maki, p. 35.

Mescherski cites Maki's three interesting cases of parakeratosis. Two of those cases were in two brothers; the other in a girl, 18 years old. Different methods of treatment were used, and, as a result, it was decided that applications of carbon dioxide snow were the most effective. The author claims that the X-ray, light from a quartz lamp, and radium and mesothorium radiations were also found of considerable value.

TREATMENT OF SYPHILIS BY INJECTIONS OF STRONG SOLUTIONS OF BICHLORIDE OF MERCURY. Kakushkin, p. 53.

The treatment of syphilis with injections of strong mercury bichloride solutions was introduced by Oeatreicher in 1889; he used 4, 6, 8 and 10% solutions. In 1892, Ludaziewicz used $HgCl_2$ solutions, starting the patient with 1 cc. of a 3% solution, increased later to 1 cc. of a 5% solution. He believed that the slight reaction and absence of intoxication and bad secondary effects spoke in favor of these injections. Miller, in Lassar's clinic, used an 8% solution, injecting only ½ cc. Pellagati, Piasacki, Immerwohl and Malberle used it with success, but Jessner met with very bad reactions. Zelenev preferred mercury suspended in liquid petrolatum. Prochorov injected very large doses of

mercury biniodide in what he called his dynamic method; *i.e.*, he measured his doses according to the weight of the patient: 1 cc. of a 10% solution to each 10 kilo weight of the patient. However, he had severe reactions. Nario and Burdjalov employed the same method.

The 47 cases treated by the author were divided into 3 groups; one group was treated with injections of strong bichloride of mercury solutions, one by mercury and arsenic, and one by arsenic alone. The author comes to the conclusion that injections of strong bichloride of mercury solution have no advantage over other methods of treatment.

BRITISH JOURNAL OF DERMATOLOGY.

Jan. to Mar., 1916, xxviii, Nos. 1 to 3.

Abstracted by I. Rosen, M.D.

SECONDARY LICHENOID TRICHOPHYTIDES IN ASSOCIATION WITH KERION CELSI (LICHEN SPINULOSUS TRICHOPHYTICUS). C. Rasch, p. 9.

(Translated from the Danish by W. Jenkins Oliver.)

Rasch reports two cases, one a boy, thirteen years of age, and the other a girl, twelve years old; both of them were admitted to the University's Dermatological Clinic at the Rigshospital in Copenhagen, with a large kerion of the scalp. About seven to eight weeks after the appearance of the lesion on the scalp, an eruption consisting of densely placed miliary papules, occurring chiefly in groups, made its appearance on the chest, arms and legs. The papules were white, pink, or the color of the skin, very hard and almost "horny" to the touch. On many of them was a small bristle or spine, a few millimeters in length, which could be removed by traction, leaving a small cavity in the skin. Microscopical examination failed to reveal any fungus.

The kerion, treated with fomentations, healed in about six weeks, but the lesions on the body continued to spread, so that the whole trunk was eventually covered by the eruption.

The author considers these two cases typical examples of "lichenoid trichophytide," first described by Jadassohn, in 1911, during the discussion on Bloch's discourse on ringworm, at the Swiss Medical Congress, in October, 1911. Jadassohn at that time made the following remarks: "With kerion celsi, especially about the time of healing, he had often seen, either in groups or diffusely spread, an eruption which consisted of small pale follicular nodules, sometimes very numerous, at other times in lesser numbers, which after some time disappeared. They most closely resembled lichen scrofulosorum, but did not react to tuberculin injections and were also histologically different from this disease. Occasionally they showed small horny spikes or spines, and the condition might then be said to correspond to the picture of lichen spinulosus."

Histologically, there is a follicular or perifollicular inflammatory condition. The follicle is more or less dilated, being filled with a mixture of round and epithelial cells. In the spinous form there is considerable parakeratosis in the wall of the follicle, and the horny layers in connection with it are pushed out of the follicle by the pressure inside, so giving rise to the development of a bristle or spine.

The condition with which it may most readily be confounded is lichen scrofulosorum. This can be ruled out by the history of the case, the lesions being more grouped and of a darker color, and the distribution is more limited.

With regard to the differential diagnosis from lichen spinulosus, the author is of the opinion that some of the cases previously described under this name are probably identical with the "lichen trichophytides."

TWO CASES OF HERPES ZOSTER ASSOCIATED WITH A GENERALIZED ERUPTION OF VARICELLA-LIKE SPOTS: ONE OF THE CASES FOLLOWED BY OCULO-MOTOR PARESIS, MYDRIASIS AND FRONTAL ANÆSTHESIA. F. PARKES WEBER, p. 13.

Weber reports two cases, one a man, 59 years of age, who was suffering from chronic lymphatic leukæmia, with considerable enlargement of the cervical, axillary and inguinal lymphatic glands, and enlargement of the spleen and liver. The glandular enlargement began about six years ago.

The patient received arsacetin (dose not given) on Nov. 6, 1915, and two weeks later, an eruption typical of herpes zoster made its appearance on the right shoulder; this was accompanied with a great deal of pain. About five days later a generalized but scanty eruption of varicella-like spots occurred.

The second patient was a widow, 60 years of age, who during the latter part of August and beginning of September, suffered from an attack of neuralgia of the left side of the head in the occipital region, and in the area of distribution of the first branch of the fifth cranial nerve. About the middle of September, an eruption of typical herpes zoster appeared on the forehead, covering practically the entire left side, involving the left upper eyelid, and left side of the nose. Considerable œdema accompanied this eruption. About the end of the week following this eruption, a generalized varicella-like eruption appeared, covering the entire trunk and extremities.

About six weeks after the appearance of the herpes zoster, the patient complained of diplopia, and this on examination was found to be due to paresis of the left rectus superior muscle. The eyeball was considerably injected throughout the illness, lachrymation was marked, and a muco-purulent discharge from the conjunctiva existed.

Improvement was very slow, and not until four and a half months from the beginning of the illness was the patient considered cured.

SPECIFIC HYPERSENSITIVENESS, OR ALLERGY IN RELATION TO CERTAIN ERUPTIONS OF MICROBIC ORIGIN. H. G. ADAMSON, p. 27.

The view that tuberculides are virtually "phenomena of Koch" induced by autoinoculation by virile tubercle bacilli, in a subject hypersensitized by previous infection, is one of great interest. The same idea may be applied to the secondary eruptions of syphilis and possibly to certain other skin affections of microbic origin.

"Tuberculides," in contrast to the other tuberculous affections of the skin, show no tendency to local spread, as, for instance, the lesions of lupus vulgaris, and they eventually arrive at a spontaneous cure. This has been explained by the theory that tuberculides are due to tuberculo-toxines, or perhaps to dead or attenuated bacilli, which have not the power to multiply locally, and thus to cause persistent or spreading lesions.

In support of his theory, intradermic injections of tuberculin or bacillary emulsion, in tuberculous subjects, produces lesions of erythema induratum and

lichen scrofulosorum. These eruptions can occur only in persons who have been previously infected by the tubercle bacillus, and whose system is consequently hypersensitive.

In syphilis, the chancre represents the local result of the initial infection. By this infection the subject becomes hypersensitized or allergic towards the micro-organisms of syphilis, and thus protected from a second infection. The secondary eruptions may be looked upon as "cuti-reactions" or as "phenomena of Koch," a result of the arrival of spirochætæ in the skin of the now highly allergic subject.

The tuberculides and the secondary syphilides are not the only eruptions whose characters of symmetrical generalized distribution, and of advance towards spontaneous cure, may be accounted for upon the hypothesis of Koch phenomena in allergic subjects, for we find the same phenomena in the eruption of measles, enteric fever, varicella and smallpox.

FOUR CASES OF SCLERODERMIA ASSOCIATED WITH DISEASE OF THE THYROID GLAND. J. H. Sequeira, p. 31.

Sequeira reports in detail four cases of sclerodermia (all of them in females), associated with disease of the thyroid gland.

In discussing the pathogenesis of sclerodermia, the author states that this affection occurs in connection with such a variety of conditions that it is difficult to believe that many of the casual relationships which have been suggested can be accepted.

While it is true that a certain proportion of the cases are associated with affections of the thyroid gland, nevertheless there is nothing to warrant the conclusion that alterations in the activity of the gland or of its secretion are actually causative of sclerodermia. The very fact that sclerodermia has been known to occur in thyroid hypertrophy and thyroid atrophy, makes one cautious, and in the author's fourth case, in which the sclerodermia developed in a myxœdematous patient under thyroid treatment, seems sufficient to cast doubt upon the view that sclerodermia develops as a result of deficient or excessive thyroid secretion.

JOURNAL OF EXPERIMENTAL MEDICINE.

(January, 1916, xxiii, No. 1.)

Abstracted by R. C. Jamieson, M.D.

A PATHOLOGICAL STUDY OF SYPHILITIC AORTITIS AND ITS SEROLOGY. J. H. Larkin and I. J. Levy, p. 25.

The authors found that the luetic aortitis in the gross specimen presented a typical picture, the lesion being usually in the ascending and transverse parts. There is a diffuse dilatation, or an aneurysmal pouch, and the surface shows a number of elevated, white scars. There is a perivascular round cell infiltration of the adventitia. The early cases show the histological changes, the gross changes not being so apparent. They consider an aortic insufficiency, uncomplicated by other lesions, to be always luetic except in cases of infectious endocarditis, and think that it is doubtful if the spirochætæ pallidæ can be demonstrated.

In the serology they prefer to use the guinea-pig heart antigen and explain the discrepancy in the Wassermann reaction findings in heart cases, by the fact that the different types of lesions are not sufficiently differentiated by clinicians, pure aortic insufficiency giving approximately 100% positives. With few exceptions, the Wassermann reaction remained positive after treatment.

(*Ibidem*, March, 1916, xxiii, No. 3.)

STUDIES ON TREPONEMA PALLIDUM AND SYPHILIS. II. SPIROCHÆTICIDAL ANTIBODIES AGAINST TREPONEMA PALLIDUM. M. McBurney, p. 329.

Using cultural spirochætæ pallidæ the authors found that rabbits and sheep, immunized with these cultures, possessed a serum having spirochæticidal properties, the normal serum, however, also possessing a certain degree of such action, the result of the immunization evidently being to increase the normal antibodies. The spirochæticidal properties are destroyed at 56° C. The addition of small amounts of fresh normal serum will reactivate this action of the immune serum.

III. THE INDIVIDUAL FLUCTUATION IN VIRULENCE AND COMPARATIVE VIRULENCE OF TREPONEMA PALLIDUM STRAINS PASSED THROUGH RABBITS. H. Zinsser, J. G. Hopkins, and M. McBurney, p. 329.

Fourteen strains were used passing through inoculations from two to twenty-one generations. They found no constant change in the virulence of the different strains by passing through successive rabbits, nor did the different strains vary, though the original material had been obtained from various types of lesions—condylomata, chancres, mucous patches and the nervous system.

The speed of incubation was, with slight differences, the same for all strains, the nature of the lesion resulting from inoculation of any individual strain depending upon the material used, the technique employed for injection and the size of rabbit used. The testicular development of the rabbits used accounted for some of the variation in the results obtained.

IV. THE DIFFERENCES IN BEHAVIOLC 1 IMMUNE SERUM BETWEER CULTIVATED NON-VIRULENT TREPONEMA PALLIDUM AND VIRULENT TREPONEMA PALLIDUM FROM LESIONS. H. Zinsser, J. G. Hopkins, and M. McBurney.

It was found that antibodies could be produced in the process of immunizing animals to *cultivated* treponema pallidum, which antibodies had agglutinative and spirochæticidal powers upon the cultivated organisms. It was also discovered that these antibodies possessed no action upon the virulent organisms obtained directly from the lesions. The article gives a detailed report of the experiments to determine agglutination and treponemicidal action.

ANNALES DE L'INSTITUT PASTEUR.

(January, 1916, xxx, No. 1.)
Abstracted by R. C. Jamieson, M.D.

CERTAIN ALTERATIONS IN BIOLOGICAL PROPERTIES OF SPIROCHÆTÆ THROUGH ARTIFICIAL CULTIVATION. Hideyo Noguchi, p. 1.

Experimental work has proved that an odor-producing treponema is not the organism of syphilis. The different varieties of treponema obtained in pure culture are the pallidum, pertenue, macrodentium, microdentium, mucosum, calligyrum and refringens. The staining properties and morphology of these varieties in culture have remained practically unchanged during several years, but the virulence of the pallidum was lost after about four months; the microdentium became almost odorless in two years; the mucosum also lost its mucin-producing properties.

AMERICAN JOURNAL OF THE MEDICAL SCIENCES.

(March, 1916, cli, No. 3.)
Abstracted by R. C. Jamieson, M.D.

SYPHILITIC BURSITIS, WITH REPORT OF A CASE. R. W. Scott, p. 386.

This article is a report of a case in which the prepatellar bursæ on both sides were involved in a gummatous process. Pathological examination showed a gumma, and the Wassermann was positive.

This case can be added to those few already reported.

ARSENOBENZOL.

Resolution by the Council of the American Dermatological Association.

Whereas, the importation of Salvarsan has been stopped by the war in Europe and the loss of this valuable remedy would have entailed serious consequences to the life and health of the affiicted, and indirectly to the health of the community; and,

Whereas, Drs. Schamberg, Raiziss and Kolmer, after an extended research, have produced in Arsenobenzol a substance equivalent to, if not identical with, Salvarsan and have placed it at the disposal of the profession;

Now, Therefore, Be It Resolved, that this Association record its appreciation of the valuable service rendered to the profession and to humanity through the successful efforts of these gentlemen.

SALVARSAN.

For the benefit of our readers we announce (see advertising pages) that a large supply of salvarsan has been received in this country from Germany. Dr. Schamberg, who has done so much to offset the harm occasioned by the absence of salvarsan, will not supply more arsenobenzol unless the supply of the German product again fails.

NEWS ITEMS.

Dermatological Appointments to the German Hospital:

Dr. Sigmund Pollitzer has been appointed Honorary Physician;
Dr. Howard Fox, Visiting Dermatologist, and
Dr. H. R. A. Graeser, Assistant Visiting Dermatologist. H. F.

THE JOURNAL OF CUTANEOUS DISEASES

Vol. XXXIV SEPTEMBER, 1916 No. 9

ORIGINAL COMMUNICATIONS.

THE PRINCIPLES OF THE TREATMENT OF SYPHILIS.*†

By S. Pollitzer, M.D., New York.

I shall not commit the indiscretion of presenting before this body of expert syphilologists a detailed account of the treatment of syphilis. I propose rather to discuss the reasons for our therapeutic measures, the underlying principles of treatment, and give only a brief exposition of the methods I have found most useful in my practice.

For four hundred years we have been treating syphilis without a definite conception of the aims of our treatment. Mercury, discovered through a happy accident, has been employed in a purely empirical way, and though it has given us results in syphilis comparable only to the effects of quinine in malaria, we have wasted a great deal of time and energy through our failure to formulate a therapeutic theory in correlation with the pathology of the disease. Progress depends not alone on observation and experiment, but on orderly observation and experiment; and the vague and haphazard use of a remedy is less likely to lead to clear ideas than experience based even on a false theory. In

* Read before the 40th Annual Meeting of the American Dermatological Association, Washington, May 8-10, 1916.

† Continuation of the Symposium on Syphilis which began in the August issue. Dr. Fordyce's article was not received in time to be published with this Symposium. It will appear in the October issue.

other words, a "working hypothesis," even if it be proven wrong, is more advantageous than no theory at all. The recent advances in our knowledge of the pathology and therapy of syphilis, especially the introduction of salvarsan, the product of a definite chemo-therapeutic theory, enable us to lay down certain theoretical principles of treatment which, even though they ultimately prove wrong, may serve to crystallize and clarify our knowledge.

The aim of the treatment of syphilis is the sterilization of the body with reference to the spirochæte.

The way in which mercury cures syphilis is not known. The disappearance of spirochætæ from the surface of a chancre within a week or ten days after an intravenous injection of calomel or other insoluble salt of mercury, indicates a definite effect of the drug on the parasite, but this effect is only moderate in degree, and it is quite probable that mercury serves only to create conditions unfavorable to the life of the organism, without acting as a direct spirochæticide. Salvarsan, on the other hand, seems to destroy spirochætæ in the tissues with the promptness and direct action of a chemical antiseptic. It is probable that there is a direct chemical union of the drug or some of its radicals with the constituent substance of the spirochæte; a union which inhibits and destroys the vital functions of the germ in accordance with the side-chain theory on which Ehrlich planned his great research.

Six years of observation with this remedy enables us to conclude that in the early stages of the disease, salvarsan in reality serves to destroy all the spirochætæ in the body; the *therapia magna sterilisans* is an accomplished fact. I have records of twenty-eight cases of syphilis treated by salvarsan within the first three months after infection, in every one of which the patient has remained asymptomatic and Wassermann-negative for three years or more. In more than half of these cases the spinal fluid has been examined and provocative injections of salvarsan have been given, with negative results. These patients are cured.

But in patients that come under treatment six months or longer after infection, it is only rarely that a single course of salvarsan serves to bring about a cure. In the later stages of the disease prolonged treatment, often extending over a number of years, is necessary to sterilize the patient. What explanations may be offered for this difference in the results achieved in the early and the late stages of the infection? The remedy is the same, its mode of application the same, the spirochæte is still the spirochæte,—but the remedy fails to combine with the infecting organism and destroy its activity. Why?

If the union of salvarsan and spirochæte results in the death of the latter, and the introduction of the drug into the circulation of the patient in a given case is not followed by the cure of his disease, we must conclude either that the salvarsan has failed to come in contact with the spirochæte or that the latter has undergone some change which enables it to resist the action of the drug.

The first hypothesis is the one generally accepted. After the first great generalization of the invading organisms throughout the system, many spirochætæ make their way to regions that lie outside the great circulatory highways of their host, and in the "dark corners" and "dead angles," of the system, slumber secure from the effects of the drug which, rushing through the vascular paths of the body and rapidly excreted, fails to reach them. From these hiding-places minor swarms of germs are liberated into the circulation from time to time and, locating in new regions, produce, under favorable circumstances, fresh lesions of the tertiary period or lead a *quasi* saprophytic existence in the circulating blood, till they are destroyed by the natural defensive agencies of their host.

Much may be said in favor of this hypothesis. It is a fact that spirochætæ are found from time to time in the circulating blood of the late-syphilitic. It is a fact that there are in the body tissues of such low vegetative quality that they require and receive only a feeble supply of the fluids derived from the blood, such, for instance, as cartilage, ligaments, etc. Spirochætæ located in such tissues might readily escape sufficient salvarsan-laden lymph to survive. But on the other hand, spirochætæ in the tissues always produce distinctive evidence of their presence in the form of histologically characteristic lesions, and the less vascular connective tissue structures referred to, are but rarely the seat of syphilomata. One may well ask where are the "dead angles" required by the hypotheses?

The other hypothesis, that the spirochæte has undergone a change which renders it resistant to salvarsan, rests equally on grounds that lack scientific proof. The biology of the spirochæte is but little known. Even its place in the biological system is uncertain. We are in doubt as to whether it should be grouped with the vegetable or the animal parasites, with the bacteria or the protozoa. In either case, however, we may assume the existence of some resistant form of the organism, a spore formation if the organism be vegetable, a so-called encysted stage if it be animal. Several observers have described forms which strongly suggest spore-like structures; and if, on the other hand, the spirochæte

is a protozoön, then the assumption of an encysted stage, or "dauer Form," is a biological necessity; it is a necessary part of the life history of all protozoa.

The clinical history of syphilis seems to me to speak very strongly in favor of some resistant forms of the spirochætæ, which, deposited in the tissues after the first great flooding of the system, lie dormant until they are roused to activity by some accidental cause such as a trauma. Facts with which we are all familiar, such as the development of a gumma at the site of a blow twenty years or more after the last clinical symptoms of syphilis have disappeared, the occurrence of lesions of *syphilis hereditaria tarda* in the patient who has never, in the first twenty or thirty years of his life, shown a single lesion of syphilis,—such clinical facts speak strongly, in my opinion, for the existence of a resistant form of the spirochæte which may rest without change and without provoking any reaction on the part of the tissues of their host, for an indefinite period. From such foci of spores or encysted forms of spirochætæ, adult organisms may make their way, from time to time, into the circulation and in turn give rise to new lesions. But so long as the organisms remain in an encysted or spore stage, salvarsan, which kills the developed spirochæte, is of no avail.

These theoretical considerations are of importance in any attempt to base our treatment on scientific grounds. We must consider, on the one hand, the possibility of having to deal with organisms that lie in remote or hidden portions of the body, and on the other hand, the possibility of resistant or encysted forms of the parasite. In the absence of definite knowledge, both these possibilities must be dealt with.

For more than a quarter of a century clinicians have recognized the chronic intermittent method of treating syphilis as the best. No one offered an explanation of the fact, but it was recognized on the basis of clinical experience that the continuous exhibition of mercury, over a period of two or three years, failed to cure as many cases of syphilis as the employment of the same drug with periodic intervals of rest for an equal time. Knowledge acquired since this empirical conclusion was reached, knowledge derived from the younger science of bacteriology affords, it seems to me, an explanation of this clinical observation. In the sterilization of our culture media we adopt the rapid method of sterilization in the autoclave, whenever the nature of the medium permits the use of the high temperatures necessary to destroy bacteria and spores. But when we are dealing with a medium like gelatine or blood serum, which would be destroyed by the high temperature of the auto-

clave, we adopt the method of fractional sterilization. The culture medium is exposed to a moderate temperature, sufficient to kill adult forms but not spores, for a short period, on each of a succession of days. In the intervals between exposures some of the spores in the medium develop into adult organisms in which form they are killed by the next exposure; and so on until they are all killed and the medium sterilized. I think an analogy to this method of fractional sterilization of culture media may be made with the recognized method of sterilization of the body, by the fractional or intermittent method of employing mercury.

This, then, is the first principle of treatment of syphilis,—*the principle of fractional sterilization.* It applies alike to our treatment with mercury and salvarsan; only in the case of the latter, the rapid, direct action of the drug on the spirochæte demands only short periods of treatment.

I am aware that in the prolonged treatment of a chronic infectious disease like syphilis, whether by the continuous or by the interrupted method, there is the theoretical possibility of producing a strain of organisms that is especially resistant to the drugs employed. It was this consideration that Ehrlich had in mind when he set out to find a spirochæte-poison that would act so intensely as to destroy all the germs at a single dose, while not injuring the tissues of their host. But there is no good clinical ground for assuming the existence of a mercury-fast strain of spirochætæ, at least not in the sense of a complete resistance to the large doses that may be employed. Moreover, we must remember that mercury, so far as we know, does not act directly on the spirochæte; hence, the likelihood of developing mercury-resistant organisms is not very great. As for salvarsan, that drug certainly has been shown, *in vitro*, capable of developing a strain of salvarsan-fast organisms. Noguchi has recently found that while salvarsan kills spirochætæ in a dilution of 1 : 7,500, it is possible by the use of sublethal dilutions, gradually to accustom a given strain of spirochætæ to salvarsan doses several times their normal lethal dose. In practice this would be a serious drawback in our salvarsan therapy, were it not for the fact that in the relatively large doses in which we ordinarily administer that drug, all the spirochætæ reached by it are promptly killed. It is only such organisms as lie outside the limits of the active blood and lymph stream, or the hypothetical resting forms, that escape the fatal union with salvarsan; and such organisms, untouched by the drug, will not acquire the traits of salvarsan-fast bodies.

This leads us naturally to the conclusion that the dosage of salvarsan should be large; the largest possible consistent with the safety of the

patient. It is the practice of some physicians to begin their salvarsan treatment with very small doses, gradually increasing the dosage at weekly intervals. I know of one distinguished dermatologist whose plan of treatment consists in the administration of a series of intravenous injections of salvarsan, beginning with one decigram, increasing the dose to two decigrams the next week, and so on by small increments, until he attains his maximum dose of six decigrams in the sixth week. It seems to me that this is an ideal method to pursue, if our object is to cultivate a strain of salvarsan-fast spirochætæ. It defeats the very purpose of salvarsan therapy; it contravenes the underlying principle of the *therapia magna sterilisans.* The correct principles of treatment demand the flooding of the infected host with as much salvarsan as he will tolerate,—and we may rejoice if he will tolerate a sufficient concentration of the drug to destroy all his spirochætæ at once. Fortunately, the *dosis tolerata* for this drug lies so far above the *dosis curativa* that we should be able to sterilize our patients at a single dose—as we can in the earliest stages of the infection—were it not for the considerations already referred to,—spore or encysted forms on the one hand, and remote and unattainable localization of the organisms on the other.

To meet the indications for therapy created by the possibility of spore or encysted forms, we have the method of fractional sterilization already referred to. A short course of full doses of salvarsan should be given and repeated after an interval of two or three months' rest from treatment. This period of two or three months' rest is based on the clinical observation of the time that usually intervenes between the conclusion of a course of treatment in the active stages of the disease. as during the first year or two,—a course of treatment sufficient to remove lesions and produce a negative Wassermann reaction,—and the relapse of the negative Wassermann reaction to a positive, or the recurrence of lesions. The Wassermann reaction is often negative two months after the conclusion of the treatment, and positive after another three or four weeks. Now, we know from the time of the first appearance of the positive Wassermann reaction after infection, that it requires about three weeks of spirochætal activity to cause the development of a sufficient quantity of Wassermann-bodies in the blood to yield a positive reaction. The case that relapses into a positive Wassermann reaction three months after the cessation of treatment, was therefore beginning to be actively spirochætal at least three weeks earlier. It is at this time, when spirochætæ are just beginning again to multiply, and before they have had an opportunity to pass into fresh outlying portions of the tissues, or develop a new crop of resistant forms, that our treat-

ment is most effective. *We should not wait for the recurrence of a positive Wassermann reaction.* The intervals of rest from treatment in the first year or two should be about two months. In the later stages of the disease the Wassermann relapses occur at longer intervals and the intervals between courses of treatment may be extended to three months. Whatever the merits of the theoretical consideration here developed, I wish to emphasize the fact that the results of clinical experience show that these methods and these intervals are the most advantageous.

How shall we meet the indication derived from the possibility of having to deal with spirochætæ that lie in remote regions of the system, feebly supplied with blood and lymph? It is obvious that no portion of the body is wholly beyond the reach of the nutritive juices. No living tissue could long survive the complete failure of opportunities for the renewal and exchange of the elements of nutrition. When, therefore, we speak of regions lying beyond the reach of the circulating juices, we must be understood as using the phrase only in a relative sense. The circulation in an articular cartilage or a ligament is very much less active than that in the kidneys, for instance; but there is of course a circulation even in these tissues. The hypothesis we are considering implies, however, that so small a quantity of the circulative fluids pass through these tissues that not enough salvarsan is conveyed to them to destroy the spirochætæ they may harbor, in the short time that the drug remains in the system, after an intravenous injection. It must be obvious, however, that if we could maintain a sufficient concentration of salvarsan in the blood for a considerable period, no portion of the system, not even the least vascular, could escape contact with the salvarsan-laden fluids in which it is bathed.

From this statement of an obvious fact I would deduce the second principle of salvarsan therapy: *Salvarsan should be administered in sufficient doses, repeated at such intervals that the blood is kept charged with the drug for several days, continuously.* The elimination of salvarsan from the system takes place very rapidly. It begins almost immediately aften an intravenous injection; the drug may be detected in the urine within an hour or less, and at the end of twenty-four hours probably nine-tenths of the amount injected has been excreted. The full effect of salvarsan is exerted therefore only for a very brief period, a few hours at most; and any organisms in the system that are not killed within this short time, necessarily will survive the small proportion of salvarsan retained during the succeeding hours or days. If, therefore, we wish to maintain an adequate concentration of salvarsan in the blood for a longer period, the injection of the drug must be re-

peated at intervals which should be measured by hours rather than by days or weeks. The theoretical considerations here advanced require that injections of salvarsan should be made at least three times in twenty-four hours.

The practical application of this principle presents obstacles which make it extremely difficult of execution. It can be done only in a hospital. It is the method employed by Scholtz of Breslau, who administers salvarsan to his patients at eight in the morning, two the same afternoon, and again the following morning. Scholtz, however, employs doses which, in my opinion, are too small to meet the indications I have set. Most of our patients are treated ambulatorily and a stay even of a couple of days in the hospital offers serious objections. There is, however, no great difficulty in making our salvarsan injections daily, and this is the plan I have of late employed, giving three full doses of salvarsan on three successive days. By this method cases that have in the past remained Wassermann-positive in spite of repeated courses of salvarsan and mercury at weekly intervals, have responded with a negative result.

To descend from general considerations to a few details of treatment, I wish first of all to emphasize the fact that our knowledge of the best methods of employing salvarsan is still unsettled, is still in a state of flux. It required more than three centuries of mercury to arrive at our present excellent methods of employing that drug. With the current methods of correlation of scientific work, and the enormous number of scientific observers all over the world, we need not fear that we will have to wait for a definite knowledge of the most advantageous mode of employing salvarsan till the close of the twenty-third century; but it will certainly require the experience of a couple of generations of syphilographers to attain this result. I crave your permission to present in brief outline what, in my judgment, is the best method of treating syphilis, as based on my experience up to the present time.

When the patient comes under observation with a suspicious sore, the diagnosis is based on the demonstration of spirochætæ on its surface. Treatment is begun as soon as the diagnosis is established. To wait for the appearance of a corroborative eruption is inexcusable negligence. We do not wait for a patient with an infected wound to develop septicæmia before treating him; we should not wait for a spirochætal septicæmia to develop in a patient with a chancre. If the Wassermann reaction is negative when the diagnosis is first made, so much the better. Our chance of curing the patient by a single energetic course of treatment diminishes with the lapse of time after infection, and after three

months, or after the appearance of the secondary rash, I do not rely on abortive treatment. Within that period the treatment consists in excision of the chancre when its localization permits that procedure, and otherwise of vigorous calomel inunctions twice a day, for a week; and the administration of an intravenous injection of a full dose of salvarsan on each of three successive days. The dose of salvarsan is proportioned to the weight of the patient, approximately one decigram of salvarsan to each twenty-five to thirty pounds of body weight, so that the man of one hundred and twenty pounds receives 0.4 or 0.45, the man of one hundred and fifty to one hundred and sixty pounds, 0.6, the man of two hundred pounds, 0.8. Of course, I am referring to robust men in good physical condition. For women the dose in general is 0.1 less than for men of equal weight. I sometimes make the dose on the third day a little less than that employed on the first two days, to allow for the small amount of salvarsan left in the blood from the previous injections; for instance 0.5, 0.5, 0.4. I do not give a preliminary injection of mercury. It may serve to prevent reactions, it is true, but in theory, at least, it may interfere with the action of salvarsan, by creating conditions unfavorable for the spirochæte, thus hastening the development of resistant forms. The urine should be examined before each injection. The salvarsan is dissolved in freshly distilled sterile water, without the addition of any saline, in the proportion of one decigram of salvarsan to 20 cc. of water. This solution is more nearly isotonic than the solution in two or three times that amount of water, as originally recommended, and in the smaller volume of fluid employed is less likely to produce disturbances in the blood. Moreover, there is a considerable saving of time in having only 100 cc. of fluid to inject as against 200 cc. or 300 cc. for each case; a matter of importance where we are treating many patients at once, as in our clinic practice. I frequently employ a solution of one decigram to fifteen cc. of water. Following this course of salvarsan I give an intramuscular injection of the salicylate of mercury, of two to two and a half grains (0.13-0.16) in a $33^1/_3$ per cent. suspension, in olive oil, once a week for eight weeks. The first dose of course should be smaller. I do not regard this mercurial course as essential and have several times omitted it; but it does no harm and is possibly of value. We shall know in fifty years. This is the only treatment the patient receives if he has come under treatment promptly after the appearance of his chancre and before the development of a strongly positive Wassermann reaction.

If the patient is not seen till his Wassermann reaction is strongly positive, or until a roseola has appeared, the same course of treatment

is pursued, but I do not feel so confident of having cured him with a single course. A large proportion of my early cases, in which treatment was begun immediately after the appearance of the roseola, have received this single course of mercury and salvarsan alone, and are cured; but in general I prefer not to run the risk of assuming a cure that may not have been accomplished. The intelligent patient is taken into my confidence, the *pros* and *cons* explained to him, and while some elect to continue the treatment, others are willing to share the responsibility of awaiting developments. In any case the Wassermann reaction is carefully watched and on the first indication of a positive reaction, treatment is resumed and thereafter carried out as in the case of the patient who begins his treatment well after the appearance of a secondary eruption. Treatment by three daily injections of salvarsan, is followed by eight injections of salicylate of mercury; a rest from treatment for two months; a repetition of the course of salvarsan and mercury *whether the Wassermann reaction is positive or negative;* and a third course after another two months' pause, so that the patient has received three courses of this combined treatment within a year. I consider it safe to suspend treatment after this period if the Wassermann reaction has remained negative throughout the year.

The patient who first comes under treatment a year or more after his infection, is treated in the same way, but in only a small proportion of the cases are we able to bring about a cure with a few courses of treatment. The cases vary greatly. I have seen a single course of treatment render a patient permanently negative who for the first eight years of his disease had received nothing but pills. On the other hand, we are all acquainted with those obstinate cases that remain Wassermann-positive after years of energetic treatment. These resistant cases have given rise to the idea of a class of persistently Wassermann-positive syphilitics who can never be cured. Within the last two years I have seen so many of these resistant cases become negative and remain negative that I am of the opinion that every case of syphilis, save only those with paresis or tabes, is curable.

A word as to the possibility of the persistent retention in the system of Wassermann-bodies after the cure of the disease,— an idea that has been advanced to explain some of the asymptomatic persistent Wassermann-positive cases. On theoretical grounds the retention of these substances for any considerable period after the removal of the agents which provoke their presence is extremely unlikely; the patient who is free from spirochætæ soon becomes permanently Wassermann-negative; but it is possible that there is an analogy in this respect between the

Wassermann-bodies in syphilis and the agglutinins in typhoid, which give a persistent Widal reaction long after, sometimes many years after, typhoid bacilli have left the system. In one of my resistant Wassermann-positive cases, long and faithfully treated, where the patient was obliged to undertake a voyage and interrupt active treatment, I prescribed an interval course of small doses of iodides and mercury by mouth, and found, on the patient's return, a negative Wassermann-reaction which has remained negative during the two years that have since elapsed. I have tried this treatment in a number of similar cases without success in most of them; but the three cases in which a permanently negative Wassermann reaction followed this eliminative treatment, suggest the advisability of testing the method in other cases.

The prognosis of syphilis, as to the curability of the disease, may, in my opinion, be stated to depend on the result of a spinal puncture. If the examination of the spinal fluid establishes the presence of tabes or paresis, the case is hopeless as to cure, though much may be done to relieve symptoms in tabes and prolong life in paresis. But if the central nervous system be free the patient can be cured by persistent treatment. It need not be emphasized that even though there be an ætiological cure, the damage done before the patient is rendered spirochæte-sterile may be irreparable and of such a nature as to lead to his death: damage done to the heart and aorta before treatment is effective—the secondary changes wrought by the spirochætæ in these important organs—may prove fatal after the spirochætæ have all been destroyed. Just so there are cases of tabes, that have become permanently Wassermann-negative in the blood and spinal fluid, free, therefore, from spirochætæ, in which, however, the degenerative processes in the posterior columns, initiated by the spirochætæ, progress. But though no organ of the body is so frequently the seat of spirochætal invasion as the heart and aorta, the damage done to these organs is slow in developing and treatment but rarely fails to bring about a clinical and ætological cure, if secondary changes are not too far advanced.

As to the reactions that sometimes follow an intravenous injection of salvarsan, in five and a half years' experience with that remedy, I have seen only two cases that developed really alarming symptoms. In both these, there was an immediate flushing and œdema of the face, and an extreme fall in blood pressure with subsequent weak and rapid heart action, lasting for twenty-four hours. One of the patients was pulseless and comatose. In both these cases the patients, contrary to my instructions, and without my knowledge, had eaten a hearty meal shortly before the injection was given. The injection should be given on an empty

stomach. I have learned to have at hand a hypodermic syringe and a solution of adrenalin, which I administer to the patient upon the first signs of flushing of the face. The explanation of these occasional nitritoid symptoms, as Milian calls them, is still lacking; but we are fortunate in possessing a remedy which controls them so perfectly and which will probably prevent those rare fatal cases of œdema of the brain, of which I have never seen an example. As to the minor reactions, such as vomiting, diarrhœa, etc., some patients get them after each injection, but they occur in only a small percentage of the cases. I do not know how to prevent them nor what causes them. They do not depend upon any special toxicity of the drug because I have seen one patient profoundly affected by an injection of a portion of the same solution which three others received without any disturbance. The arsenical dermatoses which sometimes, though very rarely, follow treatment with salvarsan, while not grave, may make the energetic employment of salvarsan impossible, and prove thus a serious hindrance to an effectual treatment.

To summarize my plan of treatment: specific therapy should be instituted at the earliest possible moment after a positive diagnosis is made. Three injections of salvarsan should be administered in large doses, at intervals of twenty-four hours, and followed by a course of eight weekly injections of salicylate of mercury. If the treatment was begun before the appearance of the roseola, there is a strong presumption of cure and the case may remain under observation without further treatment. When the treatment is begun after the appearance of a rash, the first course of salvarsan and mercury is repeated after a pause of two months, and again after another similar interval. After three courses within the first year, if the Wassermann reaction has remained negative, further treatment may await the reappearance of a positive Wassermann reaction. In cases which come under treatment a year or more after infection, treatment should be continued till the Wassermann reaction becomes negative, and thereafter two more courses of treatment should be administered, even though the Wassermann reaction remain negative. After a year or more of constantly negative Wassermann reaction without treatment, the cure should be tested by a provocative injection of salvarsan * and by an examination of the spinal fluid.

Fifty-one East 60th Street.

* I employ the provocative salvarsan test in deference to current opinions. I am, however, not entirely convinced of its value and am now engaged in a study of the question.

SOME OBSERVATIONS ON THE TRANSMISSION OF SYPHILIS; WITH PARTICULAR REFERENCE TO A PATERNAL SOURCE OF INFECTION.*

By Udo J. Wile, M.D., Ann Arbor.

The criticism may well be made that any contribution relating to so-called syphilitc inheritance is purely speculative. It must be admitted at the same time that much of our knowledge, or at least much of our belief, and of certain current beliefs which I shall hope to contradict, are based upon pure speculation. It is, indeed, only speculation and deduction from clinical facts and scientific data that can possibly lead to fruitful investigation.

Turning first to the question of the recurrence of syphilides, there are two main theories which stand out. The first, held by syphilographers of earlier times, that late lesions, particularly those of the skin and mucous membranes,—the so-called tertiary manifestations of the disease,—are due to an early implantation of the organism and its subsequent lighting up *in loco*. In other words, that a spirochæte infection of the blood stream exists but at a single time, the time of the dissemination of the organism just preceding the so-called secondary period. This view is the one most in favor to-day. The second belief, which held favor up to a decade ago, and which has since fallen into more or less disbelief, is that from time to time the blood stream becomes infected from old sources of early implantation, and that gummous lesions, when they do occur, do so as a result, not of lighting up *in loco,* but of a recurrent blood stream infection.

I believe that recent researches of visceral syphilis have a direct bearing on this question. I believe, moreover, that the evidence is fast piling up which shall establish beyond a peradventure that in a latent syphilitic the blood stream is from time to time recharged with spirochætæ and that their elimination into the blood stream and dissemination to distant foci results in gummous lesions, rather than from a lighting up, *in loco,* of older implantations.

* Read before the 40th Annual Meeting of the American Dermatological Association, Washington, May 8-10, 1916.

A study of splenic syphilis and of syphilis of lymphatic structure in general bears directly upon this subject. Credit for first calling attention to acute splenic hypertrophy in secondary syphilis belongs to A. Weil. This author publishes observations on three cases of secondary syphilis in which he was able to percuss enlargement in two and palpate enlargement in the third. In 1895, Columbini stated that enlargement of the spleen was a uniform finding in all cases of fresh syphilis, coincident with the appearance of the exanthem. The fact that these authors' results were based on percussion, vitiates these figures when one considers the great difficulty in percussing splenic enlargement. Bruhns, in 1899, investigated 60 cases of recent syphilis and was able to palpate enlargement in but six. Wewer, Haslund and Nolte, who have also discussed this subject, express the conviction that splenic tumor in early syphilis is a rare finding. Avanzini found enlargement in 8 out of 30 cases. Schuchter, in about the same number. In a recent publication, based on the examination of 100 cases of early syphilis, Elliott and I established the fact that the spleen was the first viscus to be manifestly enlarged in early syphilis. Of our 100 cases, 36 were found to have definitely palpable splenic tumors. We were able to establish the fact, moreover, that but a certain proportion of these cases returned to normal. A fair number of cases, notwithstanding vigorous treatment, left as a residue, a firm, hard spleen, not unlike that seen in chronic malaria. In two cases at least, such involvement has persisted for three years *post infectionem*. The possibilities that this study suggests, together with the striking fact that in the largest number of cases of latent syphilis, which have received no treatment or inefficient treatment, the general adenitis stands out as the one remaining clinical feature, is that the lymphatic structures may and probably do serve as reservoirs for the spirochæte, from which sources, under conditions of lowered resistance or by reactivation of the organism itself, the blood stream is from time to time recharged. That such an hypothesis is not at least without some basis, is evidenced by the fact that in one case of chronic splenic tumor, I was able by direct puncture of the spleen, to demonstrate living active organisms. Analogy with other infections, moreover, lends weight to this view; thus, malaria of the chronic type exists in the spleen and bone marrow in a distinctly resting condition for many years. Under appropriate physical conditions, or under the influence of trauma, or of lowered resistance, or perhaps in the reactivation of the parasitic protoplasm itself, in malaria there occur from time to time exacerbations in the blood stream. The same thing occurs with other infectious diseases in which the host becomes a chronic car-

rier. That such a condition and such a reinfection of the blood stream may and probably does occur in syphilis, is suggested, moreover, by the observation which I have had the opportunity of making in the hospitalization, over a period of time, of cases of latent syphilis. What, besides reinfection of the blood stream could give rise to the occasional fever, imperceptible by the patient, but clinically demonstrable, which so frequently occurs in latent syphilis? Further clinical evidence that such occurs is shown in the fact that the blood of old syphilitics is definitely infectious, certainly not in all cases; but under given conditions, experimental and accidental chancres have occurred from contact with the blood of patients, syphilitic five, ten and even more years. In the face of this evidence, do we not have to give up definitely the idea that the blood stream is infected in syphilis but a single time? Must we not regard the interstitial tissues of the body, particularly the lymphatic and perivascular structures, as sites of predilection for the resting place of organisms and as the distributing foci of reinfection into the blood stream?

The analogy of encapsulation of foci and the absorption or injury of such encapsulation leading to redissemination is found in tuberculosis.

If one argue for the dissemination of the organism at a single time, how explain such cases of single gummous lesions remaining solitary for a time and then followed at distant parts of the body by lesions of a like nature? Such a condition probably occurs by a redistribution in the blood stream, of the organism. That it might occur by the reactivation of local foci from a circulating toxine from the initial gumma, may perhaps be argued by some. For myself, I regard the first explanation as much more acceptable. We have at present definite knowledge concerning spirochæte dissemination. We have but very vague knowledge concerning spirochæte toxine. The all too frequent accidental chancres in surgeons, when operating on old syphilitics, can only be explained by assuming the presence of spirochætæ in the blood stream of such patients at the time of operation.

The second part of my presentation deals with a more speculative and perhaps more hazardous theory. I refer to the subject of inheritance, using the word in its strictest sense. It is noteworthy that Fallopius, Paracelsus and Fernillius recognized the possible inheritance of syphilis as early as the sixteenth century. Ambrose Paré distinguished clearly the infection of healthy wet nurses by syphilitic children. Hunter, however, was responsible for many years of disbelief in the inheritance of syphilitic infection, since he taught that the chancre only

was infectious and disbelieved in the transmissibility to the second generation. Indeed, it was not until the end of the 18th and well into the 19th century, with tht establishment of Colle's law, that the transmission of syphilis to the new-born was accepted as an established fact. The earliest teachings following this, accepted inheritance through the mother and through the father as two distinct possibilities. Strictly speaking, there can be no inherited syphilis unless the unfertilized ovum or the spermatozoön itself is infected with some form of the invading organism. In other words, true hereditary transmission must assume a conceptional infection. Are we justified, upon the pathological, clinical and experimental evidence, in assuming that any such condition occurs? That there is evident post-conceptional maternal infection is accepted by all. Such transmission, as I shall attempt to show later, is, I believe, at least for the largest number of cases, an infection at the time of birth or during the passage of a healthy child through an infected birth canal.

Recent teachings, stimulated by serological examinations of apparently healthy mothers bearing syphilitic children, have led to the belief that all infection is maternal. In other words, that no child is syphilitic unless it gets its syphilis from the mother. For myself, on the basis of the study of the literature and from personal observation, I believe that paternal inheritance must be accepted in the future as an established fact.

Let us consider the pathology of the organs of generation themselves, for it is in the ovary and the testes, rather than in the blood stream, that one must look for the possibility of intracellular involvement leading to conceptional infection.

Our knowledge concerning ovarian syphilis is extremely meagre. Many of the various texts deny the possibility of such involvement. That clinically ovarian syphilis is a rare condition cannot be gainsaid. Is there any possibility, realizing the hæmatogenous nature of syphilis, that the ovary can possibly escape infection, whether it be clinically involved or not? Recent investigations have shown that in old cases of latent syphilis the intestinal submucosa is loaded with spirochætæ. Notwithstanding this fact, intestinal syphilis as a clinical entity is and always has been a rare condition.

The ovary must receive its quota of infecting organisms, together with other structures of the body. That unquestionably there is some form of clinical ovarian syphilis I have convinced myself by observation on a fairly large series of cases of syphilis in all stages. The frequent occurrence of delayed menstrual function in early syphilis, particularly

as it occurs in young women, and definite abdominal pain referable to the ovaries, are frequently met with, and suggest early ovarian infection. In any case of early syphilis, in the absence of a previous history of menstrual irregularity, the occurrence of irregularities, such as amenorrhœa, dysmenorrhœa and delayed or precipitate menstruation, coincident with the exanthem of syphilis, must be regarded as evidence in favor of ovarian involvement. And such manifestations, indeed, occur frequently. The normal histology of the ovary furnishes a suggestive explanation for the non-recognition of syphilitic processes in its structure. The most common sequel of syphilis in a viscus is fibrosis. Fibrosis is in the ovary a normal finding, not only in the senile ovary, but as the result of the expulsion from the Graafian follicles of each ovum. A normal process is constantly going on in the ovary which, except for the inflammatory change, leads to the same end-results as syphilitic fibrosis. As I shall attempt to show later, fibrosis likewise is the most frequent ultimate change in testicular syphilitic involvement. The possibility that the ovarian secretion may exert some protective influence which inhibits the action of infecting organisms, is a factor which cannot be lightly regarded. But such a protective action would not protect the periovarian connective tissue, nor would it of necessity prevent involvement of the interstitial tissue of the ovary. Yet it must be admitted that up to the present the spirochætæ have not been demonstrated in the ovarian parenchyma. If this be so, it is probable that the syphilitic product of conception is only infrequently the result of preconceptional invasion of the female germ cell. The frequent cases of infected children from syphilitic mothers and healthy fathers would then have to find their explanation in an exchange of the fœtal and maternal blood stream, or by infection at the time of birth. Under the trauma incident to birth, a latent syphilitic mother may infect her healthy child with an acquired syphilis.

Turning now to the placenta as the alleged source of fœtal infection, it may be stated that the infection of the fœtus from the mother in this way is accepted as the most frequent mode of maternal transmission. The placenta is frequently involved with typical syphilitic changes. The spirochætæ are easily demonstrable in the chorionic villi. Can we accept this, however, as evidence that the fœtus is thus infected from the mother through the placenta? I believe there is better evidence in favor of placental infection from the fœtus than from the mother, Syphilitic changes in the placenta, when they are present, occur exclusively in the fœtal portion of this organ; that is, they are represented by vascular and degenerative changes in the chorionic villi. Decidual

or maternal placentic syphilis is practically unknown. If it be assumed that the mother infect her product through the placenta, there is no satisfactory explanation for those cases in which the fœtus is syphilitic and the placenta entirely normal—a not infrequent finding.

The possibility that the placenta is syphilized through the fœtus, offers, moreover, an explanation for the constant serological infection in the mother, in the absence of clinical syphilis. It is an accepted fact that there is an interchange of immune substances between the maternal and fœtal circulation. A Wassermann-positve mother, therefore, may receive her complement-binding substance by filtration of these substances through the placenta, from her infected product of conception.

Turning to the possibility of paternal transmission, we are face to face with two great, striking factors. First, that the syphilitic father conveys to the mother of his syphilitic child an undeniable syphilis. Second, that the testis is, above all other viscera, the site of election for spirochæte infection. Not only is this so in acquired and congenital syphilis, but our experimental studies have shown us that in our laboratory animals the testicle is above all other viscera the easiest site of inoculation and for growth of spirochætæ. Rabbits injected intravenously with pure cultures of spirochætæ not infrequently develop the initial lesions in the testis.

Clinically, syphilitic orchitis manifests itself in three distinct forms. In the earlier stages of the infection, clinical epididymitis is recognized, and through it the spermatic fluid itself may, of course, be the carrier of the infection. Infection carried to the mother in this way, and from her to the product of conception, could not in the strictest sense be called hereditary.

More important are those changes which occur in the testicle, which lead to extensive fibrosis. I refer to gummous orchitis and diffuse sclerosing orchitis. Both of these conditions are recognized as frequent clinical entities. I will not go into the clinical picture of these conditions nor discuss their pathology minutely, except to say that both lead to testicular atrophy and extensive testicular fibrosis. Warthin is authority for the statement that he can identify syphilis in an old syphilitic from an examination of the testis alone. A surprisingly large number of cases in which clinical orchitis is entirely lacking, show definite changes referable to syphilis. If this be so, and recognizing that gummous orchitis is comparatively rare, one must assume that in the human host, as well as in the laboratory animal, the testicle is a site of election for the growth and cultivation of the organism of syphilis, unassociated for the most part with clinical findings. Is it not much

more suggestive, therefore, and should one not look for the transmission to the unfertilized ovum, of some form of the spirochæte carried over, not by the seminal fluid, but by the product of the diseased seminiferous tubule? The actual proof of spirochætæ within the body of the spermatozoön has not been demonstrated. If infection is intraspermatozoal, it must be by the presence within the male germ cell of the spirochæte in a stage of its development which has not shown itself by modern microscopic methods. As bearing directly upon the likelihood of such resting stages existing, I beg to cite you some recent work which I have done. During the past year I have, in six out of nine cases, produced experimental syphilis in the rabbit testis, or perhaps I had better say, I have demonstrated living spirochætæ in the rabbit testis as early as three days following an intratesticular injection of spinal fluid from general paresis and acute cerebrospinal syphilis, in which the most careful examination of the fluid before injection failed to show any evidence of spirochætæ. More than suggestive in this connection was the subsequent history of these rabbits. The spirochætæ remained demonstrable for a week or ten days and then suddenly disappeared. In two cases there was a reappearance, followed again by disappearance, and now, after four months, there is total disappearance of the organism in all cases. May not this be explained upon the basis that in the spinal fluid a resting stage existed? The transplantation to a more favorable soil, such as the testicular parenchyma, enabled the organism to develop in its normal cycle, and its subsequent disappearance is a readjustment of the new soil to the resting stage. That this is not entirely speculative is evidenced by the analogy which exists in the case of the bacillus of anthrax, which disappears as such in cultures, lapsing into a spore stage, in which stage it is capable of reinfecting animals, even after years. On the basis of our clinical, pathological, and experimental evidence, is it not more rational to accept true paternal inheritance, that is, infection of the ovum through the spermatozoa, rather than to assume that inheritance is always maternal? As we frequently observe, the man with a syphilis of ten years' duration who contracts marriage, may be the father of both healthy and syphilitic children. His infected children then are the result of the union of a diseased spermatozoön with the ovum, and the healthy children result from the union with the ovum of an uninfected spermatozoön. Surely such a latent individual does not infect his consort, at least not frequently, through open syphilitic sores. The infection in such cases must also be seminal. It will be remembered, in this connection, that the experiments of Uhlenhuth and Mulzer, Finger and

Landsteiner, and others, have shown that the seminal fluid may be infective to laboratory animals. That this is open to criticism is evident from the fact that the seminal fluid itself is complex and contains prostatic juice, as well as material from the seminal vesicles.

True paternal inheritance with coincident maternal infection can, I think, be rationally explained by assuming that both mother and ovum are infected the same way.

The interdependence of maternal and fœtal circulation would seem to preclude the possibility of maternal infection from an infected fœtus, although this point is not a settled one in the opinion of embryologists.

Notwithstanding the fact that there is an interchange of nutrient and effete products between the maternal and fœtal circulations, clinical evidence bears out that bacterial infection through the placenta is rare. Fœtal blood is not ordinarily infected in sepsis in the mother. This is true not only in the ordinary infections, but for such infections as typhoid, malaria and all septicæmias. By analogy, then, it may be assumed with probability that spirochætæ rarely pass through the maternal and fœtal blood unless there be a break in the placental circulation. Such a break may occur at the time of birth. It is perfectly evident that maternal transmission by infection of the ovum and through interchange of maternal and fœtal blood in some way must occur, for how else could one explain the infection of a child born of a syphilitic mother and healthy father? Where syphilitic children are born of old syphilitic mothers and healthy fathers, the product of conception is usually carried to term as a healthy fœtus and develops the manifestations of syphilis a few weeks after birth. Such cases are infected not *in utero*, necessarily, but they may occur at the time of birth, infection taking place through a rip in the placenta at this time, or as the child passes through an infected birth canal.

My observations have led me to believe that a paternal inheritance, as I have outlined it, usually results in expulsion of the fœtus before birth in the first pregnancies and stigmatized children, if such are born alive, in the later pregnancies. Maternal infection, therefore, would not be hereditary, but would be an acquired form of syphilis, except when the syphilis is recent in the mother. For those cases in which maternal infection results in expulsion of the fœtus, one would have to presume the unfertilized ovum to be the seat of the resting or active stage of the spirochæte, as may occur with the male germ cell. That such is infrequent is established by the pathology of ovarian syphilis. Paternal infection, therefore, would be for the most of the cases, the commonest mode of transmission.

With regard to placental transmission, the weight of evidence is more in favor of a fœtal infection of the placenta than of infection of the placenta by the mother. The complement-binding substances passing through readily from the fœtus to the mother, suggest an explanation for the uniformly positive tests in the mother and the otherwise inexplainable phenomenon that most of such mothers go through life Wassermann-positive, without ever having clinical syphilis.

Discussion of the Symposium on Syphilis.

Dr. Schamberg said there had been so much of surpassing excellence presented by the various essayists and so many valuable suggestions made, that it would be impossible to even allude to most of them. He would like to advert to just one or two things said among the many. He believed with Dr. Wile, from close observation of some cases he had the opportunity of studying for some years, that infection was not exclusively transmitted by the mother to offspring. He was not satisfied at all, from an intimate knowledge of these patients, that paternal transmission was impossible. In regard to congenital syphilis, he wished to state that children born in apparent health, and not only that, but with negative Wassermann reactions, might at the end of three, four, five years or later, develop positive reactions. He believed the great technical weakness of the Wassermann reaction was, that we have never had a sufficiently delicate reagent to determine minute amounts of antibody in the blood. Many negatives are in reality not negative. We might compare the various antigens with different chemical substances for the determination of sugar in the urine. If we had a sufficiently delicate test we would not have those intervals of negative reactions, in uncured cases, but more or less permanent positive reactions, varying in degree.

In regard to the plea made in Dr. Pollitzer's paper, the speaker would say that he was convinced that his line of treatment would cure a very much larger percentage of cases than were now being cured, but on the other hand, he was likewise convinced that in the hands of the ordinary practitioner such treatment would kill a larger number of patients than were now killed. Such vigorous treatment, he thought, should be undertaken only by skilled men, who knew full well the character of the remedies they were employing. There were a large number of patients with damaged organs, who could not be given such large doses of salvarsan and mercury without dire consequences.

Dr. Heimann complimented Dr. Wile on the ingenious way in which he had arrived at his conclusions. He thought that the latter were heretical, however, and based upon two fundamental misconceptions, namely, inexact views on heredity, and unfounded hypotheses concerning the invasion of the ovum and spermatozoön by the spirochæte. Dr. Wile stated that he employed the word "heredity" in the strict sense. The mechanism of heredity as understood by the embryologists was the transmission of congenital variations through the chromosomes. Should it actually have been proved that the influence of spirochætæ on the spermatic chromosomes could so alter the latter as actually to enable them to transmit syphilis—for this is what heredity in the strict sense would mean—Dr. Wile would have succeeded in proving the heredity of acquired characteristics or more, a view countenanced by no authorities, as a perusal of the works of Darwin, Romanes, Hertwig and others would have shown. In other words, such a theory would have failed because it proved too much.

Concerning the question of ovarian infection, although probably very rare, Bab had once demonstrated a spirochæte in an ovum. Very little could be deduced from an isolated instance. The theory of paternal transmission raised the important question of the way in which the spirochæte was conveyed, by the spermatozoön, and if it was so conveyed, how it penetrated the ovum. Was it coupled to the spermatozoön, and if it was so conveyed, how it penetrated the ovum. Was it coupled with the spermatozoön as a tender to a locomotive, was it in the spermatozoön as a passenger, or did it take a course strictly parallel to that of the spermatozoön? The first and second were impossible because the treponema was longer than the head of the spermatozoön; the third possibility was inconceivable, because it would imply too delicate an adjustment of the travelling time of the micro-organism to that of the spermatozoön, and the synchronous union of both with the ovum,—a series of circumstances requiring too much delicacy of adjustment to be generally operative in the production of the disease. It might be argued that resting forms existed in the spermatozoön and that these began to flourish after fecundation. By analogy, as in malaria, we knew that intracellular forms of protozoa destroy the cells they have invaded, and it would be probable that a spermatozoön, the host of encysted protozoa, would not be viable. Hence, no fecundation could occur, and if it were shown that spermatozoa could actually convey spirochætæ in any stage of development, this in itself would almost positively exclude any chance of a paternal transmission of syphilis.

It was conceivable that syphilis in the father might so disturb the growth impulses of the spermatozoa as to engender monstrosities, but not syphilitics.

It were far more reasonable and simple to adhere to the accepted views of congenital syphilis, namely, that the infection took place maternally, the first site being the placenta which then assumed the rôle of a primary lesion. This hypothesis would account for all of the vagaries of congenital syphilis. Why, for example, should a congenitally luetic child be born apparently normal and after the lapse of years show its first evidence of syphilis, if it had been paternally infected? How, indeed, could such a fœtus have developed at all? We knew that the earlier in intra-uterine life the infection, the less was the chance of the fœtus being born alive. On the other hand, placental infection would have been possible at any period of fœtal existence, and all of the views of congenital syphilis would thus have been explicable, and its analogy to the acquired form comprehensible. The speaker regretted that the period allotted for discussion was too brief to develop the same theme adequately, for with sufficient time he thought that Dr. Wile's astonishing conclusions could have been shown to have been untenable in the light of calm analysis.

Dr. Pollitzer said that he regarded that portion of Dr. Wile's address, which dealt with his researches on splenic syphilis and his successful inoculations with cerebrospinal fluid as constituting a valuable contribution to syphilology. In regard to Dr. Wile's views on "hereditary" syphilis, he said it required a certain amount of courage to argue in favor of paternal conceptional syphilis. This doctrine was in vogue from the middle of the sixteenth century till almost the present time. But a couple of generations ago it began to be questioned and Matzenauer's clear analysis of all the available data made it evident that paternal conceptional syphilis rested on very doubtful foundations. The final blow was given to the elaborate structure based on inadequate observation and impossible theory—including Colles' and Profeta's laws—by the evidence derived from a study of the Wassermann reactions in the presumably healthy mothers of syphilitic children and the demonstration of spirochætæ on the maternal side of the placenta, in these cases. The notion that a spirochæte might be conveyed to the ovum in the head of a spermatozoid or might travel alongside of the

spermatozoid and enter the ovum simultaneously and thus infect the fœtus, needs only to be stated to be rejected as unthinkable. A spirochæte is not an entirely harmless animal and it seems self-evident that a spirochæte-bearing spermatozoid would be incapable of performing its normal function and that an ovum into which a spirochæte had penetrated would be incapable of developing into a fœtus. It has been definitely established, by experimental observations on invertebrates and the lower vertebræ, that the slightest disturbance of a single blastomere in the ovum results in a failure of development. We do not require a theory of paternal conceptional syphilis to explain all the observed facts of hereditary syphilis. The mothers of these infants are themselves Wassermann-positive; a large number of them, if observed for a sufficient period, develop lesions of syphilis.

The well-known anomalies encountered in the course of familial syphilis, first a number of dead or syphilitic children, then one child healthy, another syphilitic and so on, even one of twins healthy and the other syphilitic—were readily explained if we bore in mind the fact that a syphilitic woman's blood is actively spirochætal only in the first year or two of her infection and that later the spirochætæ occur in the blood only in small numbers and at intervals. During the first year or two, therefore, the fœtus is seen to become infected early in its development, as soon as the placental circulation is established—and will perish. When the infection of the fœtus takes place later in its development, the child may be born alive and syphilitic. But when pregnancy occurs at a time when only a few spirochætæ are present in the blood and at rare intervals, it is purely a matter of accident, whether or not the spirochætæ make their way through the placental vessels and reach the fœtus, or whether they are deposited elsewhere in the mother's tissues or destroyed in her blood. With double ovum pregnancies, therefore, one placenta may be the landing place of a few spirochætæ and that fœtus become syphilitic, the other placenta may escape and hence the other fœtus remain free. But when a fœtus is infected in the later stages of the mother's syphilis, the spirochætæ reaching the fœtus, find there the same conditions of relative immunity,—anergy, as Neisser has called it—that exists in the mother,—because the fœtal tissues and blood are those of the mother, and the fœtus infected at this stage may harbor spirochætæ without developing florid syphilis and show no sign of the disease, except a positive Wassermann reaction, till after the lapse of many years, just as any tertiary syphilitic may go for years without a symptom. We may thus explain the cases of syphilis hereditaria which have always seemed so mysterious.

That the infant may be infected at birth is, of course, well known. These cases are quite different from the cases of intra-uterine infection and do not differ from any other cases of acquired syphilis. Inspection should always disclose the presence of a chancre on the infant, a week or two after birth and the roseola will appear as in an acquired syphilis, six or eight weeks later. Whether the infant derive its infection from an active lesion, usually a chancre in the parturient canal of the mother, or by inoculation through the skin or mucosa from the mother's spirochætæ-bearing blood, does not affect the case. But in any case, parturitional syphilis is a rare event. As to paternal conceptional syphilis conveyed to the ovum by some ultra-microscopic or granular form of the spirochæte enclosed in a spermatozoid, no one could either affirm or deny the possibility of such an occurrence. Personally, the speaker said, the notion of a resting stage, an encysted or a spore stage, of the spirochæte, was one which appealed to him very strongly. He had for a number of years past argued in favor of the necessary existence of some such stage of the spirochæte on clinical and biological grounds, and no one would be more pleased than he to see this view definitely established. But to assume the existence of these

hypothetical forms and to add the further hypothesis that they may be present in a spermatozoid without affecting its physiological function, and that they may be conveyed to the ovum, and the ovum with these hypothetical spirochætal granules go through the complicated changes incidental to fecundation and development without disturbance, was not only adding one hypothesis to another of less probability, but seemed to the speaker to be wholly unnecessary for a rational understanding of the problems of hereditary syphilis.

Dr. Pusey said there was one collateral point which Dr. Wile had made, which he thought should be criticized. Dr. Wile had spoken of the frequent inoculation of syphilis from syphilitic blood. The speaker would like to know the basis for Dr. Wile's statement upon this point. As far as the speaker knew, there was not in the literature an authentic case of inoculation of syphilis from uncontaminated blood. Furthermore, animal experiments in inoculating syphilis with blood from syphilitic patients had proven very difficult, and where successful inoculations with blood had been made, such large quantities of blood had been required (a cubic centimeter or more) that it had shown that the danger to the operator in surgical operations of inoculation of syphilis by blood alone, might practically be considered as nil.

He had been very much interested in the methods of treatment which Dr. Pollitzer had outlined. He wondered, however, if in the cases which were not gotten early enough to make quick abortion of syphilis practicable, Dr. Pollitzer was escaping neuro-recurrences, and the other early occurrences which were the chief objections to the early use of salvarsan, when it fell short of aborting the disease.

Dr. Goldenberg said the views expressed by Dr. Wile were so iconoclastic that naturally most of the criticism will apply to his statements. He agreed with Dr. Pusey in his remarks about infection through blood. In the experience of the speaker, cases of infections on the fingers of physicians originated from handling patients with symptoms of active syphilis (mucous patches). The second point of Dr. Wile's statements with which the speaker disagreed, were his ideas of infection through the ovary, based upon irregularity of menstruation and pain of the ovary upon pressure, in affected women. The former may be caused by any infection, the latter depended greatly upon personal equation and was found so often that it could hardly be of such diagnostic value to base upon it an entirely new idea.

Apropos to Dr. Pollitzer's remark, the speaker referred to a classical case, which had been presented before one of the meetings in New York this winter, where one of a pair of twins showed symptoms of syphilis with a positive Wassermann, while the other one was healthy and had a negative blood reaction. He failed to understand how Dr. Wile's or Dr. Pollitzer's theories could explain this condition.

Dr. Fordyce asked Dr. Pusey for further information regarding the statement he had made, as to the more frequent occurrence of recidives three or four months after infection, in cases treated with salvarsan. He would like to know whether these cases were treated by salvarsan alone or by the combined method of treatment. In the past three or four years, the speaker said, in cases which had been treated by the combined method, he had seen no recidives whatever, but in cases of early syphilis treated by salvarsan alone, such recidives were apt to be met with.

The speaker said that if Dr. Pusey would study the chart which he had presented, giving the spinal fluid findings in cases of early syphilis, he would find that optic neuritis was present in cases that had received no treatment whatever. This applied not only to optic neuritis but to affections of the auditory nerves and paralysis of the eye muscles. He firmly believed that the de-

velopment of recidives depended upon the manner in which the treatment was carried out.

Dr. Post asked the members present to please notice that there had not been one single theory, not one speculation, but simply clinical observation, in his paper. He would beg them not to let their theoretical speculations make them forget the value of simple clinical observation. Even now too little of the clinical course of syphilis was known and there was room for careful clinical study.

Dr. Wile said he was glad his paper had brought out such fruitful discussion. In regard to Dr. Heimann's criticism, with reference to the use of the term hereditary, the speaker stated he might better have said paternal transmission. He felt that everybody realized that he used the term hereditary, not in the strict biological sense, but as we were accustomed to use it. As a matter of fact he had not gone into this without consulting authority. He had consulted an eminent embryologist and several biologists, who informed him that the introduction of foreign substances into the male or female germ cells did not prevent conception from occurring. The introduction of tubercle bacilli, for example, into the hen's egg did not prevent that egg from hatching out a chicken, even though the chick were feeble. One could not assume that the presence of a microörganism of necessity meant that that cell was not capable of fecundating and developing in a modified way.

With regard to the maternal transmission of syphilis, the speaker thought the whole question hinged on the transmission of syphilis through the placenta. It was just as speculative to assume the placenta to be the chancre of fœtal syphilis, as Dr. Heimann suggested, as it was to assume that the fœtus was syphilitic and transmitted spirochætæ to the placenta. The speaker was not offering any proof, but thought this a question which ought to be seriously considered.

To the question as to the appearance of syphilis in children who were born healthy and then developed syphilis, the speaker found an explanation in the fact that the chancres in these cases were seldom looked for. Children who were born healthy and developed infection six or seven weeks later, had an acquired form of the disease.

With regard to Dr. Pusey's question, the speaker felt that in reality the surgeons did not fear syphilis half enough. In the past four years he had seen three cases of infection in operators, in which it would appear the blood stream had conveyed the infection.

Dr. Fordyce said, in reply to Dr. Zeisler's question, as to the best time to begin the general treatment of syphilis, that salvarsan had such a rapidly destructive action on the spirochætæ that the development of antibodies in the patient's blood, due to the long contact between the organisms and hosts, did not take place. Under these conditions foci of spirochætæ were at times not reached by the drugs and developed with more rapidity and caused the so-called neuro-recidives and mono-recidives. It was for this reason that mercury was now combined with salvarsan so that we obtained the benefit of both agents in bringing about the destruction of the organisms of the disease.

As a result of his experience covering a period of about four years in the intensive and combined use of these remedies, he had not seen a single mono-recidive or neuro-recidive. Regarding Dr. Zeisler's statement that the old-fashioned method of treatment cured many cases, the speaker said that this statement was undoubtedly true but this treatment had not been subjected to the serological tests as at present employed. The fact that our asylums and institutions were now filled with incurable paretics and our hospitals with many thousands of patients suffering with aortitis and visceral manifestations of

syphilis, was the best reply to the statement that the older method of treatment was sufficient. He, furthermore, stated that if the possibilities of syphilis were more generally recognized by the practitioner and more careful examinations of patients made in the early stages of the disease, including examination of the spinal fluid, many incurable affections of the nervous system could be entirely prevented.

Dr. Pollitzer said, in regard to the neuro-recidives to which Dr. Fordyce and Dr. Zeisler had referred, that he had not seen a case of this kind within the past couple of years. He had seen quite a number of optic and auditory manifestations in the early days of salvarsan, but since he had been giving adequate doses of salvarsan, he had not seen any. There had been neuro-recidives after salvarsan because not enough of it was given. He would go even a little farther than Dr. Fordyce in the matter and say that even while he agreed as to the advisability of mercurial treatment, he did not think the recidives were caused by an absence of mercury, but by insufficient salvarsan.

In regard to the case of twin births in New York, in which one child was syphilitic and the other not, the speaker was very glad to hear of that case, for he had not heard of it before. The explanation of the occurrence of hereditary syphilis which he had given seemed to him to fit these cases perfectly. A syphilitic woman in the later stages of syphilis only occasionally had some spirochætæ in her blood. Whether they entered the placental vessels and reached the fœtus or were retained in the maternal arteries or tissues, was purely a matter of chance. Where one fœtus became infected it was not necessary at all that the other should be, any more than it was necessary to have a gumma on the right hemisphere of the brain because there was one on the left side.

MENINGOCOCCUS MENINGITIS WITH UNUSUAL PURPURIC MANIFESTATIONS; DEMONSTRATION OF THE DIPLOCOCCUS IN THE SKIN.*

By Charles T. Sharpe, M.D., New York.

Resident Physician, Queensboro Hospital, Jamaica, L. I. Clinical Assistant, Department of Dermatology, Vanderbilt Clinic, Columbia University.

Four cases of cerebrospinal meningitis were reported in this city for the week ending March 18th. One of these cases, under the designation of measles and purpura, found its way into the Willard Parker Hospital at midnight of March 13th. Needless to say, the admitting physician did not accept it as a case of measles and it was promptly isolated, as it presented very unusual objective symptoms.

The patient was a little Hebrew girl, three and a half years old, well developed and well nourished. The history obtained stated that the child had been ill six days with measles and the rash disappeared on March 11th.

Case Report.

Physical Examination. The child is apathetic, eyes closed, moves head from side to side, and has a marked tremor which is more or less constant. She can be roused sufficiently to take a drink but appears in a subconscious state and has a dry, troublesome cough.

The most notable feature is the wide-spread purpura with a remarkable vermilion border in the larger lesions. In size, the purpuric areas vary from small petechiæ to suffusions four to four and a half inches in diameter. One area involves the left ear, left cheek, the nose, upper and lower lips, the chin, the right cheek to an extent of about two inches from the right angle of the mouth and spreads up to the forehead, over the glabella. On the forehead are petechiæ. Both eyes show subconjunctical hæmorrhage and the lids are also involved. Over the scalp there is little sign of hæmorrhage but there are two areas one to one and a half inches by one-half inch on the back of the neck, within the hair line.

The mouth shows petechiæ on the buccal mucous membrane, hard palate and tongue. The gums over the central upper and lower incisors and adjacent areas are black, but there is no free bleeding.

Over the trunk and extremities the same gradations in the purpuric areas exist, as noted above. The left arm is involved to a much greater extent than the right and the discoloration extends from the shoulder to the wrist. There are small hæmorrhages in the palms. The suffusions are more marked on the right leg than the left and involve the knee and ankle. Both buttocks are

* This article will appear simultaneously in the *Archives of Pediatrics.*

involved to a considerable extent. The vulva is not involved and the mucous membrane here is normal in color.

Examination of the heart, lungs and abdominal organs reveals nothing abnormal. The stools are normal in consistency and color. The urine is clear, amber, acid, specific gravity, 1008. There is a moderate amount of albumin and there are hyaline casts with a few white blood cells.

Nervous System. The eyes are normal on inspection and react to light. The patella tendon and triceps reactions are reduced. Other reflexes are negative. There is but little response to stimuli, either in testing reflexes or sensation. There is more or less tremor when disturbed.

Blood Examination. The blood was examined by Dr. Hess and his report is as follows: Capillary resistance was greatly diminished and the application of the bandage increased the purpuric areas on the arm. Bleeding time prolonged. Platelets, 216,000. Leucocytes, 34,000. Coagulation time, fourteen minutes (slightly above normal). Plasma, slightly hæmolysed.

Later in the day, moderate rigidity of the neck was noted and Kernig's and Brudzniski's tests were possibly present. A lumbar puncture was done and 15 cc. of a slightly turbid fluid withdrawn. There was no evident increase in pressure. The fluid was sent to the Meningitis Department of the Research Laboratory for examination. Two other punctures were done on succeeding days. The reports on these fluids showed from 95% to 98% polymorphonuclear leucocytes, moderate increase in cells. The first two samples were not distinctly purulent. The bacteriological examinations showed an increasing amount of extra cellular gram negative diplococci, and the cultures gave pure growths of meningococcus. The reaction was neutral. Albumin was present in increasing amounts at each examination, and the globulin increased from two plus to three and four plus. It should be noted that the Fehling's reaction gave a reduction in all three samples, but in decreasing amounts.

Blood Cultures. A blood culture was done on the 14th and on the next day a gram negative diplococcus was found. Glucose acetic agar tubes and plates were successfully inoculated. These were given to the Research Laboratory for absolute identification of the suspected meningococcus, and the cultural reactions were found to be characteristic.

Later Physical Examination. On the 15th, a physical examination showed a few scattered, moist, crepitant râles at the left base, posteriorly. The right ear was normal, the left showed some congestion of Shrapnell's membrane; short process and handle of malleus, distinct; membrana tensa, normal. The patient was still in a semi-conscious condition. The left leg and arm were rigid. The respirations were very rapid at times and then returned to normal or subnormal. The skin over the purpuric area on the back of the scalp broke down and there was some slight bleeding. One black, tarry stool was recorded.

Treatment. Two intraspinous and two subcutaneous injections of anti-meningitis serum were given.

At 10:25 A.M., March 16th, the child died and immediately thereafter three sections of skin, one quarter of an inch in diameter, were removed from the vermilion border of the purpuric lesions and hardened in 70% alcohol.

Autopsy. An autopsy was done by Dr. Alexander Fraser, of Bellevue Hospital Medical College, who reports as follows:

"Name, N. S. Age, three and one-half years.

Anatomical Diagnosis. Nervous System: Acute cerebrospinal meningitis.

Vascular System: Moderate granular degeneration of heart; degeneration and in many places necrosis of terminal vessel walls, with early thrombosis.

Respiratory System: Acute exudative bronchiolitis; hypostatic congestion of lungs, with small foci of exudative pneumonia.

SPLEEN: Acute congestion.

LIVER: Congestion, œdema and moderate granular degeneration.

KIDNEYS: Acute granular degeneration.

EXTERNAL INSPECTION. White, female, age, 3½ years. Body fairly well developed and fairly well nourished. Slight rigor mortis. Eyes, aural, nasal and buccal cavities apparently negative. Skin shows large ecchymotic patches involving greater part of face, left arm, buttocks, right knee and ankle. Smaller subcutaneous hæmorrhages are sprinkled thickly over whole body.

INTERNAL INSPECTION. HEAD: Skull and dura negative. The arachnoid is for the most part smooth and transparent. In the subarachnoid space are small "hazy" to "milky" areas around the vessels, especially over the superior surfaces of the parietal lobes and the posterior surface of medulla and cervical cord. On the superior surface of the central lobule of the cerebellum is a very thick whitish spot, about the size of a pea. The base of the brain and cranial nerves are apparently negative. The pial vessels are markedly congested. The lateral ventricles are free from fluid; ependyma negative; cortex of brain and basal ganglia apparently negative.

THORAX, HEART: Myocardium pale, "cooked" looking and friable; otherwise negative.

LUNGS: Both lower lobes markedly congested and possibly hæmorrhagic. Sections do not sink deeply in water. Both upper lobes emphysematous. Pleural cavities dry; few adhesions in posterior lower portion of right side.

ABDOMEN. PERITONEAL CAVITY: No fluid. Serosa smooth and glistening. One ecchymotic spot about the size of a dime, on intestinal wall.

LIVER: Size normal. Surface mottled, dark purple and pale brown. Parenchyma granular and friable.

SPLEEN: Slightly enlarged and dark purple in color. Cut surface of deep red color, peppered with numerous white dots (splenic nodules). Parenchyma firm in consistency.

KIDNEYS: Both are swollen and grayish in color. On section, the parenchyma bulges and the edges become everted. Capsule strips easily. Cortex is swollen and grayish; markings obscured.

OTHER ORGANS: Negative.

MICROSCOPIC EXAMINATION. MENINGES: Sections from the area in cerebellum noted above, show the subarachnoid space and pia infiltrated with a moderate number of polymorphonuclear leucocytes, large endothelial leucocytes and plasma cells, with a few lymphocytes and red cells. The endothelial leucocytes and plasma cells are particularly abundant around the blood vessels, large numbers of them being closely packed in the perivascular lymph spaces. They frequently contain, in their cytoplasm, several polynuclear leucocytes and sometimes lymphocytes and red cells. Occasionally, a vessel is seen distended with a mass of closely packed polymorphonuclear leucocytes, giving the appearance of a leucocytic embolus. Many of the vessel walls show various degrees of necrosis of the endothelial and sometimes of the deeper layers. Serum is present but no fibrin can be detected. The vessels of the chorioid plexus show perivascular infiltration of similar cells. One of the larger vessels contains a large mass of red cells enmeshed in distinct fibrin threads. The epithelial covering of the plexus is for the most part well preserved, but occasional groups of cells stain poorly. The underlying cortex is unchanged.

LUNGS: Sections from the lower lobes show diffuse congestion with a few small foci of cellular exudate, similar to that present in the meninges. In these foci the bronchioles are filled and their walls infiltrated with similar cells.

HEART, KIDNEYS AND LIVER: Show granular degeneration."

Histopathology of the Skin Sections.

Epidermis. Stratum corneum: Groups of red blood cells are seen between the meshes of the cells and upon the outermost layer. In one area there is an accumulation of cells and fibrin; keratinized cells between the stratum corneum and stratum lucidum.

Stratum lucidum: Normal.

Stratum granulosum: Normal in thickness, with some œdema within the cells and occasionally vacuolization of the cells.

Stratum malpighii: Here there is marked œdema and vacuolization with a fine granular infiltration, or degeneration occupying the vacuolated cells and the interstices. Some mitotic figures are noted.

Stratum germinativum: Same as above. The pigmentation in areas examined is normal.

Corium. Pars papillaris: The most notable feature is, again, the œdema, with a dilatation of the blood vessels and some cellular infiltration and hæmatin crystals.

Pars reticularis: Here the collagenous bundles are still more widely separated, and the cellular infiltration is more marked. In the lower strata and in the trabeculæ extending into the areolar tissue, red blood cells, polymorphonuclear leucocytes, fibrin, and endothelial cells are to be seen in abundance. Vessels are to be seen in longitudinal section and cut across. They are widely dilated. Some are blocked with endothelial cells, leucocytes and fibrin, while many of the capillaries are seen filled with red blood cells in many layers. One vessel in the hypoderm shows, in many successive sections, absence of the elastic fibres in about one quarter of the circumference, with separation of the coats, and opposite this there is an area of the areolar tissue, filled with red blood cells, leucocytes and fibrin; evidently therefore a rupture of the vessel wall has occurred; an interpretation borne out by the evidence elsewhere of early thrombosis. The endothelial cells, free in the sections, show degenerative changes.

The bacteriological study of the sections is much more interesting. It is established that the meningococcus has been found in the secretions of the nose, the eyes, the bronchi in pneumonia, in the pus of complicating joint affections, the urine, subcutaneous abscesses and in the blood. In the last, it has been demonstrated in smears by Simon on two occasions, and once by Skilton.

Dr. Koplik states, on page 502 of Osler's Modern Medicine, first edition, "Although there may be abscesses in the skin and purulent infiltration, as yet the intracellular diplococcus has not been found in the skin lesions. In the herpes, both on the face and trunk, no diplococcus has been isolated from the fluid, but there is purulent infiltration and increase of the fixed cells of the tissues." Again, on page 513, he states, "Subcutaneous abscesses have been mentioned in various epidemics. In some of these subcutaneous abscesses, the diplococcus has been found."

A great many authorities have been consulted and, so far as can be found, the meningococcus has not been demonstrated in skin sections, although in cases with cutaneous hæmorrhages it would be reasonable to expect to find it. With the Gram stain it was rather difficult to

satisfy oneself that it could be located, but with the Pappenhein-Saathoff stain, the difficulty was at once removed and the meningococcus was observed and demonstrated to several bacteriologists and pathologists. In these sections it is to be found both intra- and extracellularly within the capillaries as well as free in the tissues.

Conclusions.

In conclusion, I would like to draw your attention again to the almost complete absence of clinical evidence of cerebrospinal involvement and the striking cutaneous picture, substantiated by the macroscopic findings of the pathologist and the dermatological report. It would seem that when the spinal symptoms are marked, the cutaneous symptoms may be negative and vice versa.

That this interrelationship holds, I have long been convinced. In the infectious diseases, both during the early and late periods of the illness, I have noted repeatedly marked cerebral symptoms as evidenced by stupor, low, muttering delirium, and slight retraction, possibly œdema of the brain, relieved by a profuse cutaneous eruption.

In one case, observed in 1906, a boy of about nine years, had, after an attack of measles, compression of several weeks' standing, evidenced by melancholia, with at times a cry like that heard in tuberculous meningitis. He was entirely relieved following the most pronounced attack of *urticaria* that I have ever seen. Incidentally, this boy's teacher told me that before his illness he was a good mathematician and a poor reader while afterwards he was a good reader and a poor mathematician.

In another case, a man ill with scarlet fever, erysipelas, and associated cerebral symptoms, became normal and made a splendid recovery after an outbreak of urticaria.

This has been observed so frequently that I have come to regard an outbreak of a cutaneous eruption as a very favorable prognostic omen.

I wish to thank Dr. Haynes, on whose service this case occurred, for the opportunity of presenting it; the Dermatological Department of the Vanderbilt Clinic for the preparation of the skin sections; Dr. Park, for the coöperation of the Research Laboratory, and Dr. J. A. Hall for the use of his photographs of the patient.

Microphotographs showing the meningococcus were exhibited before the Section on Pediatrics, New York Academy of Medicine, April 26, 1916.

SPECIAL ARTICLE.

HISTOPATHOLOGY.

(*Continued from July number, page 540.*)

By Walter J. Heimann, M.D., New York.

(From the Departments of Dermatology and Pathology, Cornell Medical School.)

Chapter VI.

The Lichens—Lichen Acuminatus and the False Lichens.

The position of this group of the lichens in the family of dermatoses, and such historic facts as are germane, have been outlined in the preceding chapter. It was also stated that lichen acuminatus is scarcely a true lichen. Histopathologically, it belongs among the follicular hyperkeratoses, associated with a chronic perifollicular inflammatory deposit of lymphatic cells. Thus, on the one hand, it possesses some similarity to that form of lichen planus which happens to include the pilosebaceous and sweat duct outlets, and on the other hand to lichen (keratosis) pilaris and spinulosus, which are primarily true hyperkeratoses of the follicles, and to folliculitis rubra (Wilson). Lichen pilaris is regarded by many as an ichthyosis, the impulse to which, though congenital, gains expression only later in life. This subject will receive further consideration among the hyperkeratoses (Chapters XV and XVI), in connection with the questions of inborn and acquired keratoplasia.

Lichen Acuminatus. There are few dermatologists to-day who doubt that lichen ruber acuminatus and pityriasis rubra pilaris are one and the same disease. Why it was that in Hebra's original series so many cases terminated fatally; why it is that now so few cases seem to do so, is one of the mysterious passages in the story of dermatology. The last attempt at an explanation was made by Rothe,[1] who points out that many chronic infectious skin diseases with a low mortality, notably syphilis and tuberculosis, occasionally present isolated instances of extreme severity. By analogy, he argued that lichen acuminatus might

be due to an infection usually mild, but at times malignant. Accepting or rejecting such a syllogism for what it is worth, we cannot fail to heed the logic of Riecke,[2] who recalls that psoriasis, pemphigus, eczema, in fact all dermatoses when universal, may be severe and even fatal, and he asserts that lichen acuminatus is no exception. This is at least reasonable, if not final, and serves to dissipate any illusions that pityriasis rubra pilaris and lichen acuminatus are different because the former is invariably mild and the latter potentially fatal. Neither on clinical nor prognostic grounds are the two diseases separable, and the same holds true of their microscopic anatomy.

Considering to what an extent the lichens were the cock-pit of militant dermatology, the opinions on their morbid anatomy are indeed astonishingly harmonious. This has been illustrated in connection with lichen planus, and will again be observed in the ensuing review of acuminate lichen. Of course there are the usual lapses into casuistry concerning the starting-point of the process, whether epidermal or dermal, whether primarily or secondarily in the follicular or surface epithelium,—in fact, concerning all points which we have no means of deciding and which it would be immaterial to decide. The objective facts are clear, and regarding them the bulk of writers are in accord. The annals of this malady are most completely inscribed in Riecke's[2] classic, and to abstract his paragraphs on the histology of lichen acuminatus will prove the most concise manner of outlining its salient features. Only the names of writers whose views are of most importance will be quoted, and the titles of their contributions may be found in Riecke's extensive bibliography. Hence, the list of references in the present chapter will be correspondingly brief.

A follicular hyperkeratosis is noted by all authors. This is continuous with a ten or twenty-fold increase in the thickness of the extrafollicular stratum corneum. The spaces among the layers of the horny cells are few, so that the redundant cuticle is dense, and at times folded upon itself at acute angles, forming pointed elevations in no correlation whatever to the pilosebaceous or poral apertures. (Fig. 1.) An occasional nucleated cell may be observed in the cuticle, but marked parakeratosis is never seen. Lewin notes a few granules in such cells, strongly suggesting those found in the stratum granulosum. The hyperkeratosis of the follicles is dense and a plug of horny tissue is formed which completely fills the follicle and projects above it. (Figs. 2 and 6.) Those layers of the plug nearest the wall are continuous with the layers of the extrafollicular corneous tissue, and when the plug is transected in a horizontal plane, it is found to be composed of concentric circles of keratinized cells arranged in an onion-like fashion. Both the hair follicles and sweat pores contain these structures (Fig. 2) (Besnier, Joseph, Unna), and they may be observed independent of either (Jarisch), their origin being subject to papillary proliferation as follows: If several papillæ grow aloft they form a cup, the walls of which are moulded

of a ring of digital processes. In its hollow the hyperkeratosis forms a plug in a manner quite analogous to the process in the follicles (Fig. 3). Boeck mentions the reduplication of plugs. This phenomenon depends upon the breaking down of contiguous follicles and the resulting compact juxtaposition of their preformed contents. The hairs are atrophied or absent. In the former event they are dystrophic, wrinkled, or otherwise deformed, and broken off at their points of emergence. The stratum lucidum is seen at times, but opinions are at distinct variance regarding the stratum granulosum. Neumann and von Düring note its absence; Robinson, Taylor, and Jacquet say it is normal; Galewsky states that it is increased, Mourek finds it increased in the papule and wanting elsewhere, while Unna and Liddell say that it is present throughout and never more than two or three layers thick. The rete pegs are lengthened and thickened (acanthosis) but, as Jacquet, Robinson and Jarisch point out, about the follicles containing plugs this is not the case (Figs. 2 and 6). Here the rete is thin and ribbon-like, all evidences of scalloping being absent. The columnar layer is normal. Joseph says it is lost over the lacunæ. Unna maintains that no lacunæ are found in pityriasis rubra pilaris, but that they are present in lichen ruber acuminatus, and he counts this as a point of distinction between the two diseases.

The papillary body conforms in outline to that of the epidermis and is the site of an infiltration which consists of the lymphatic type of round cell and a few plasma cells. Unna notes the presence of many mast cells, Jacobs of but a few, and Palm finds some eosinophiles. The infiltration differs in density in various lesions, and where it is sparse it may be discerned as being perivascular (Fig. 6). The collagen fibres and elastic tissue are unchanged. A certain degree of collagenous œdema has been noted, the spindle cells are increased numerically and interspersed among the cells composing the infiltration. The subpapillary vessels are encased in a slight perivascular sheath of cells. The sebaceous glands are normal or atrophied while the arrectores pilorum are prevailingly hypertrophied. Riecke's own description departs from this composite picture in no essential detail. Unna's[4] findings correspond in the main to the foregoing, but he emphasizes, more than Riecke, the intercellular œdema in the rete and the presence of wandering cells in the epidermis, particularly near affected follicles. He quotes Elsenberg's observation of a dense infiltration between the arrectores and the hair follicles. Ehrmann and Fick[5] observe coil gland cysts and thickening of the hair muscles. Joseph[6] finds giant cells in the infiltration, a fact corroborated by no one else. Rothe[1] emphasizes the presence of lacunæ and quotes Galewsky in corroboration. Darier,[7] in all essential points, is in accord with Riecke.

There is little to be added to the gleanings from the literature already recorded. Pityriasis rubra pilaris, or lichen acuminatus, is a subacute or chronic folliculitis or perifolliculitis, accompanied by profound epidermal and more or less marked dermal changes. The hair follicles and outlets of the sweat ducts (Fig. 2) are involved as well as the surface epidermis. Hyperkeratosis (Figs. 1 to 3 and 6) is the dominant feature of the process. In the follicles and pores it leads to the formation of a funnel or wedge-shaped plug, composed of concentric layers of completely keratinized cells (Figs. 2 and 6), and on the surface it produces a compact scale from twenty to thirty rows of cells

deep (Fig. 6). At times the scale bends upon itself, forming acute angles which clinically appear acuminate (Fig. 1), and resemble the follicular or poral plugs, but histologically, of course, are extrafollicular and extraporal. Further than this, when groups of papillæ proliferate, the hollow thus formed also becomes the site of a hyperkeratotic plug (Fig. 3). Thus there are four types of plugs,—follicular, poral, angular and verrucoid. A destruction or deformity of the hair (Fig. 2) is caused by the follicular hyperkeratosis. The stratum granulosum tends to be increased to a thickness of from three to five rows, but the extreme limit is by no means so great as in lichen planus. There is moderate acanthosis with lengthening and broadening of the pegs, save about the affected follicles, where the rete is stretched and thin (Fig. 6), consisting of four to five rows of cells. Intercellular œdema and a few mitoses are present. The germinative layer is usually intact and a few wandering cells invade the epidermis. Lacunæ are formed at times, it is true, but by no means as constantly as in lichen planus.

The papillary body is shaped in conformity with the outline of the rete pegs. It is the site of an infiltration (Fig. 6) by no means constant, either as to shape or density. The components are round cells of the lymphocyte class. There are very few plasma and mast cells and some spindle cells. The number of the mast cells, as will be seen in the discussion of urticaria, depends largely upon the degree of œdema present. The latter is rarely extreme in degree and is evidenced by slight separation, but no necrosis, of the collagenous fibres, slight vascular dilatation with swelling of the wall endothelia, and an increase in the perithelial cells, as well as some enlargement of the lymphatics (Fig. 6). There is no disturbance of the elastica. Occasionally an infiltration is also present in the follicle walls, and between these and the arrector muscles. Below the papillary area there is a very trifling indeterminate cell deposit, consisting of the same elements as are found higher up. The blood and lymph vessels are slightly increased in size and moderately surrounded by inflammatory cells. The arrectores pilorum are apparently somewhat hypertrophied, or at least very distinct (Fig. 6) but not increased in number.

Mechanical influences produce a series of changes in addition to the inflammatory ones just described. These are due to the plugs, which act as follicular obstructions. In the hair follicles they often extend down to, or beyond, the sebaceous duct and occlude it, gradually producing atrophy of the gland. Their presence in the sweat pores tends to the

formation of retention cysts, either in the ducts or coils. It appears contradictory that the same influence should lead to atrophy of one type of gland and to hypertrophy of another, and an explanation of this is difficult to find. These two organs, however, have vastly different functions. Over-activity of the sebaceous structures is rare except in such areas as are subject to seborrhœa, in which exaggerated function is primary and follicular hyperkeratosis secondary. In pityriasis rubra pilaris, the hyperkeratosis is primary and atrophy occurs, which is caused by suspended function. With the sweat mechanism, matters stand differently. Perspiration occurs at all ages except early infancy, and in all areas, its balance being nicely adjusted to the elimination of water by the lungs and kidneys; nor has the fluid of the sweat apparatus great propulsive force, so that it remains in lakes, causing moderate cystic dilatations either in the ducts or coils. These reach no great proportion, for the functioning glands in the normal areas of the body maintain the balance of elimination, preventing marked overstrain of the affected structure.

The microscopic characteristics of lichen acuminatus thus are:

1. Hyperkeratosis of the extrafollicular and follicular epithelium.
2. Hyperkeratotic plugs:
   - A. Follicular:
     - (*a*) Hair follicles.
     - (*b*) Sweat pores.
   - B. Extrafollicular:
     - (*a*) Caused by folding of stratum corneum at acute angles.
     - (*b*) Caused by hyperkeratosis in the cup produced by rings of proliferated papillæ.
3. More or less increase in the thickness of the granular layer.
4. Acanthosis of the rete and pegs not about the follicles.
5. Thinning of the rete and absence of pegs about the follicles.
6. Occasional presence of lacunæ below the epiderm.
7. An infiltration, mainly perifollicular, consisting chiefly of round cells (lymphatic type).
8. Hypertrophy of the hair muscles.
9. Mechanical changes:
   - (*a*) Dystrophy of the hairs.
   - (*b*) Atrophy of the sebaceous glands.
   - (*c*) Cysts in the sweat ducts or coils.

The conditions from which lichen acuminatus or pityriasis rubra pilaris must be differentiated are lichen planus, keratosis follicularis

seu pilaris (keratosis pilaris alba and rubra), lichen spinulosus, red, atrophying follicular keratosis of the face (Wilson's folliculitis rubra, and probably Taenzer's ulerythema ophryogenes), lichenification, lichen scrofulosorum, lichen nitidus, lichen syphiliticus and psorospermosis. Since many of these diseases have not yet been described here, it would be fruitless to make comparisons at present. In general it may be stated that the presence of giant and plasma cells in lichen scrofulosorum, nitidus and syphiliticus, as well as spirochætæ in the last, serve to separate these maladies from lichen acuminatus. The presence of the round bodies and other features identifies Dárier's disease. Keratosis pilaris, lichen spinulosus and Wilson's red facial folliculitis will be discussed later on, in this chapter. The microscopic separation of lichen acuminatus from lichen planus, because of their clinical and historic association, as well as because of certain overlapping anatomic attributes, is somewhat trying and delicate. A reference to the preceding chapter will be of service, but for the sake of clearness, the main points will be set forth in parallel columns.

Lichen Acuminatus.	Lichen Planus.
1. Marked, but less dense hyperkeratosis.	1. Marked, but less dense hyperkeratosis.
2. Plug formation characteristic.	2. No plug formation.
3. No dells.	3. Dells.
4. Slight increase in stratum granulosum.	4. Marked increase in stratum granulosum.
5. Slight acanthosis of rete and pegs, except about follicles.	5. Acanthosis with tendency for the pegs to be absorbed by infiltration below.
6. Lacunæ inconstant.	6. Lacunæ practically constant.
7. Infiltration in papillary body;	7. Infiltration in papillary body; when perifollicular, only incidentally so.
8. Hypertrophy of arrectores.	8. Arrectores normal.
9. Atrophy of sebaceous glands.	9. Sebaceous glands unaffected.
10. Process constantly follicular, perifollicular and periporal.	10. When so distributed, only incidental, and in other areas typical papules are discernible.

Keratosis Pilaris. Keratosis pilaris, renamed by Unna keratosis suprafollicularis, and variously known as keratosis pilaris alba or rubra, lichen pilaris simplex (Bazin), cacotrophia follicularum (Tilbury Fox), ichthyosis anserina scrofulosorum and xerodermia pilaris, is a pure follicular hyperkeratosis. It has been widely considered an ichthyosis, a view practically overthrown by Unna, Veyrières[8] and Jacquet; and by Brocq it has been associated with Wilson's folliculitis rubra and Taenzer's ulerythema ophryogenes, because it leaves superficial atro-

phies. The very sparse literature is harmonious, both as to the clinical and anatomical features of the disturbance. Unna[4] emphasizes the very significant fact that a plug is found at the top of, but not in, the hair follicle, preventing the eruption of the hair, which accordingly becomes rolled up in the infundibulum and thus holds the follicle walls apart (Fig. 4). The hairs are not of the papillary variety. A tonic spasm and hypertrophy of the arrectores is found and the muscles kink, cutting off the lower part of the follicles and forming horn cysts. No inflammation is present, despite the assertions of Brocq and Crocker to the contrary. Giovannini[9] in the main agrees with Unna, but notes atrophy of the outer root sheath, arrectores and sebaceous glands, as well as the fact that the plugs are not necessarily suprafollicular, but may attain to the bottom of the follicle. Ehrmann and Fick[5] absolutely corroborate Unna, stating that if any inflammation is found, it is secondary, the plugs acting as a foreign body, and that it is only in the congestive stage, since the capillaries (Fig. 7) are dilated, but no infiltration is present. Mibelli[10] says that ichthyosis may include the follicles, but that keratosis pilaris is no ichthyosis since it affects only the follicles. He finds a simple hyperkeratosis and changes corresponding to those recorded by Unna. Veyrières,[8] and Jacquet, whose unpublished article he quotes, find, in addition to the enumerated features, a normal extrafollicular epiderm, atrophy of the follicular epithelium, destruction of the follicular germinative layer, hypertrophic and displaced muscles, a deep plug and atrophy of the hair.

Keratosis pilaris is purely a follicular hyperkeratosis without primary inflammation. In the hair follicle, and entirely restricted to this structure, a hyperkeratotic plug is formed, not unlike that seen in lichen acuminatus (Fig. 4). Its usual site is at the upper portion of the follicle, but it may reach the infundibulum. The hair below is distorted and crowded down into a coil (Fig. 4). It is unusual to find the hair attached to a papilla. The wall of the follicle is stretched and thin. No signs of inflammation are found in the papillary body and corium, save occasionally a slight degree of vascular dilatation (Fig. 7). Such congestion accounts for the color of keratosis pilaris rubra. The arrectores are hypertrophied, the sebaceous glands atrophied, and sometimes cysts are found containing keratin and formed by the kinking off of hair follicles by the muscles, or produced by some other and yet unexplained mechanism. There is nothing to account for the alleged atrophy associated with the process. The positive diagnostic points are:

1. A hyperkeratotic plug restricted to the hair follicle and usually found only in its upper part.
2. Distortion of the hair.
3. Hypertrophy of the arrectores.
4. Horn cysts.
5. Atrophy of the sebaceous glands.
6. Absence of inflammation.

The only conditions with which keratosis pilaris could possibly be confused are ichthyosis involving the follicles, ulerythema ophryogenes and lichen spinulosus. All of the other conditions, such as lichen acuminatus, nitidus, scrofulosorum, Darier's disease, etc., have microscopic features which at once rule out keratosis pilaris. Ichthyosis may be excluded by the restriction of the process in keratosis follicularis to the hair follicles, and by the presence of extrafollicular morbid changes in ichthyosis. Ulerythema ophryogenes is characterized by evidences of atrophy, and this condition, as well as lichen spinulosus, will be dealt with below.

Ulerythema Ophryogenes. In Unna's work on histopathology is found the only complete description of the microscopic anatomy of this disease, the postulation of which, as a clinical entity, must be accorded to Taenzer. Unna himself, Brocq, Kaposi, and in fact all authorities include it among the follicular hyperkeratoses. Brocq has indicated that keratosis pilaris also leads to atrophy, and thus disputes the justifiability of setting up ulerythema ophryogenes as an independent clinical process. Unna,[4] on the other hand, endeavoring to establish a narrower conception of lichen pilaris, asserts that the presence of atrophy excludes lichen pilaris and indicates ulerythema. There is thus actually no real difference between the attitudes of Unna and Brocq, save that the one champions a restricted conception of the one disease, the other of the other. I have never seen a section of ulerythema ophryogenes, but from Unna's description, which is here appended, I fail to see any great histologic difference between the two conditions in dispute. Unna recognizes three phases of the malady,—erythematous, horny papular and atrophic, each of which he pictures in detail.

The Erythema: The stratum corneum is hyperkeratotic at the opening of the follicles, the stratum granulosum is normal, a suprafollicular plug is found in the hair follicles, the hair is spirally crowded down, and horny cysts are found in the corium. Here, too, are seen vascular dilatation near the follicles, no definite infiltration, and a few mast cells. Just about the follicles the collagen and elastica are disturbed, the former being rarefied, the latter broken up.

The Horny Papule: The changes here are an exaggeration of those found above. More marked follicular hyperkeratosis is present, the vessels are no longer dilated, but a slight round cell infiltration is seen about the follicles and the collagen is sclerotic, while the elastic fibres are more broken up.

The Atrophy: The follicle is now atrophied and devoid of hair, the plug is gone, the walls are thin and the vessels are sparse and collapsed. A complete sclerosis of the perifollicular collagen has taken place.

Lichen Spinulosus. As a clinical entity, lichen spinulosus is none too clearly defined. Microscopically it suggests keratosis pilaris in all respects but one, as will be noted later, which constitutes a point of resemblance to lichen acuminatus. Brocq, in his article on lichens, in the third volume of the Pratique Dermatologique, says: "Lichen spinulosus of certain authors may belong in the group of acne cornea or lichen scrofulosorum; perhaps it is actually an independent disease." That lichen spinulosus is related to acne cornea, if not actually identical, cannot be doubted; the possibility of its being a separate disease may be granted. It is obviously, however, unrelated to lichen scrofulosorum, and Brocq's error in this respect is due to deductions from purely clinical data, without reference to histological facts. The main reason for quoting Brocq at all is to illustrate the uncertainty expressed in his closing assumption,—an attitude of mind which must inevitably appeal strongly to the logical. Clinically, lichen spinulosus differs from keratosis pilaris, first in extensiveness, and second in the presence of a filiform spine (Fig. 5), which projects a millimeter, or a trifle more, above the level of the papule. If we are to continue to create new disease concepts on the length or shortness of follicular plugs and similar superficialities, without reference to the meaning of underlying processes, the reduplication of dermatoses will become enormous. Two centuries more of such thinking, and dermatology will be in a hopeless tangle, a condition it occasionally appears to verge on now, after scarcely a hundred years of independent existence.

Lichen spinulosus is evidently identical with Hardy's acné cornée, Hallopeau's acné cornée en plaques, Audry's kératose pilaire engainante, Tenneson's acne kératotica, Baudoin's and Du Castel's kératose folliculaire villeuse, Salinier's keratosis spinulosa and Unna's keratosis follicularis spinulosa. The works of Adamson, Crocker, Hallopeau and recently Salinier, Coppolino and Vignolo-Lutati and others, are practically unanimous in their histological remarks.

Vignolo-Lutati[11] mentions a local hyperkeratosis causing a long plug to form above and one-third way into the hair follicle. A few nucleated cells are found in the plug, suggesting parakeratosis. Below, a coiled up lanugo hair is found. The epithelium forming the wall of the follicle is acanthotic, while the sebaceous glands are wasted, the arrector muscles rudimentary and the coils cystic. Some spines are formed by a folding on itself of the hyper- and occasionally parakeratotic corneal stratum, as in lichen acuminatus. This is the point mentioned in which the two diseases are similar. A slight round-celled infiltration is observed. Beck[12] notes the presence of plugs in the sweat ducts, fragmentation of the elastica in the papillary body, sweat and horn cysts and a somewhat pronounced hyperkeratosis. Otherwise he agrees with Vignolo-Lutati. Adamson and Lewendowsky, as quoted by Beck, emphasize the horny plugs. The former notes no inflammation; the latter does. Coppolino[13] agrees with the features already mentioned and adds one more, namely, the absence of hair in the follicles in lichen spinulosus, which distinguishes it from keratosis follicularis. It is thus obvious that the differences among keratosis pilaris, ulerythema ophryogenes and lichen spinulosus are subjective rather than objective, and that not one of the conditions is in any way, shape or manner a lichen.

References.

[1] Rothe. Ueber einen Fall von Lichen ruber acuminatus acutus. *Arch. f. Dermat. u. Syph.*, ciii, p. 265.

[2] Riecke. Lichen acuminatus. Mraçek's Handb., Vienna, 1905, ii, p. 521.

[3] Galewsky. Discussion, Third Congress, Deutsch. Dermat. Gesell., 1891.

[4] Unna. Histopath. d. Haut. Berlin, 1894, pp. 293, 297 and 1104.

[5] Ehrmann and Fick. Kompend. d. Histopath. d. Haut. Vienna, 1907, p. 30.

[6] Joseph. Hautkrankheiten. Leipzig, 1898, p. 89.

[7] Darier. Précis de dermat. Paris, 1909, p. 379.

[8] Veyrières. Keratosis pilaris. Prat. Dermat., 1901, ii, p. 958.

[9] Giovannini. Zur Histologie der Keratosis pilaris. *Arch. f. Dermat. u. Syph.*, lxiii, p. 163.

[10] Mibelli. Zur Ætiologie, und dies Varietation der Keratosen *Monatschr. f. prakt. Dermat.*, xxiv.

[11] Vignolo-Lutati. Studium der Keratosis spinulosa. *Monatschr. f. prakt. Dermat.*, lii, No. 12, p. 611.

[12] Beck. Ueber Keratosis spinulosa. *Dermat. Wchnschr.*, lv, No. 48, p. 1461.

[13] Coppolino. Keratosis follicularis spinulosa. *Arch. f. Dermat. u. Syph.*, cxvi, p. 840.

Description of Illustrations.

Fig. 1. Lichen acuminatus. Diagram showing extrafollicular cones.

a. Cones formed by knuckling of redundant hyperkeratotic corneous layer.

b. Hyperkeratotic corneous layer.

c. Slightly thickened granular layer.

d. Slightly acanthotic pegs.

e. Normal hair and follicle.

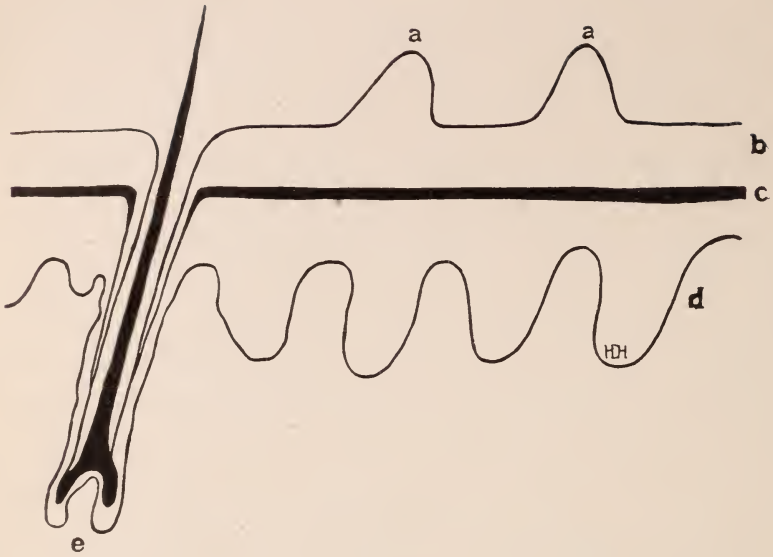

FIG. 1.

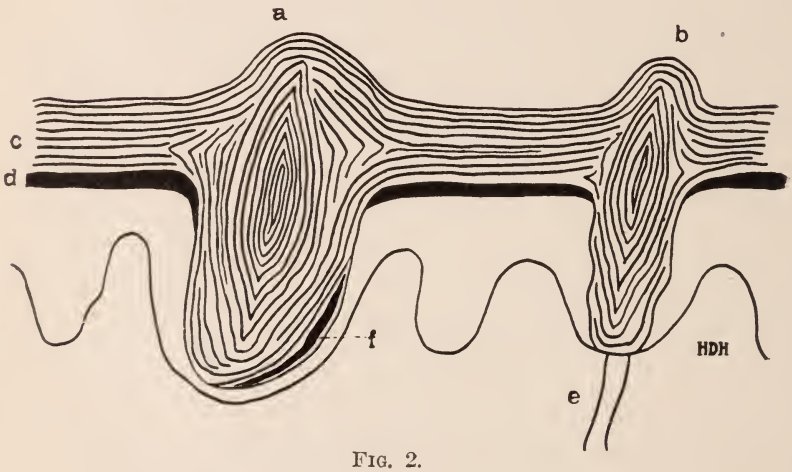

FIG. 2.

FIG. 2. Lichen acuminatus. Diagram showing follicular and poral plugs.
a. Follicular plug with concentric arrangement of corneous cells, continuous with surface hyperkeratosis.
b. Poral plug.
c. Hyperkeratotic corneous layer.
d. Slightly thickened granular layer.
e. Sweat duct.
f. Atrophied hair.

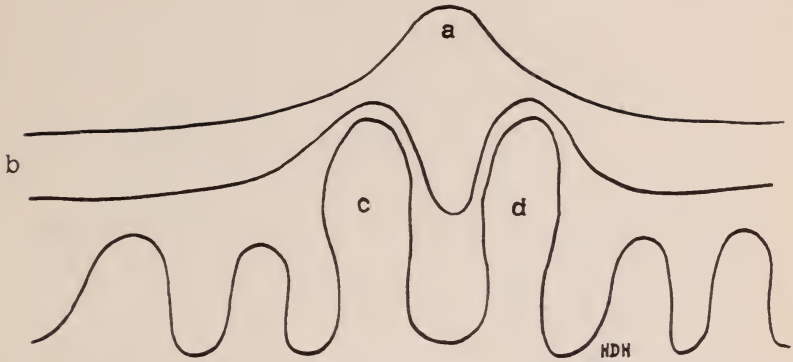

FIG. 3.

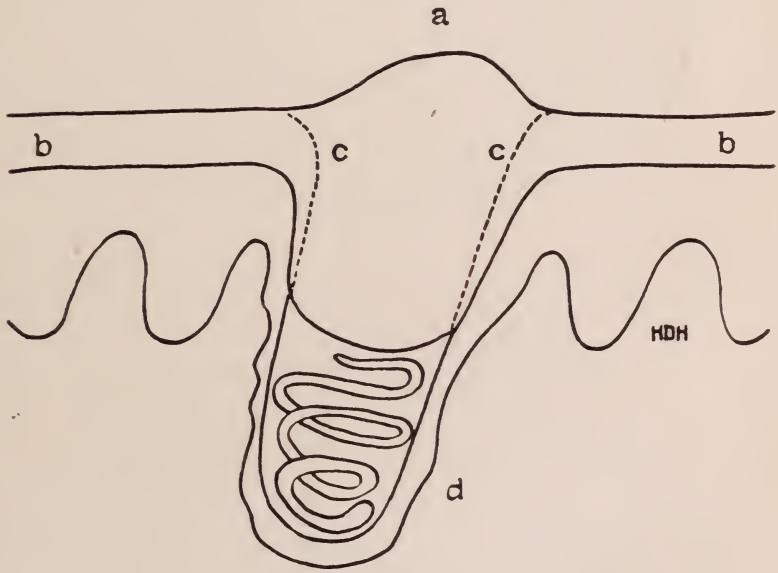

FIG. 4.

FIG. 3. Lichen acuminatus. Diagram showing extrafollicular plug formation due to papillary proliferation.
a. Plug.
b. Hyperkeratotic corneous layer.
c. d. Proliferated papillæ.

FIG. 4. Keratosis pilaris. Diagram showing plug in upper part of follicle, and coil of hair in infundibulum.
a. Plug.
b. Moderate hyperkeratosis.
c. Dotted lines showing contour of follicle. (Usually there is no hyperkeratosis outside of the follicle.)
d. Curled atrophic hair holding follicle walls apart.
Note the absence of pegs about the affected follicle.

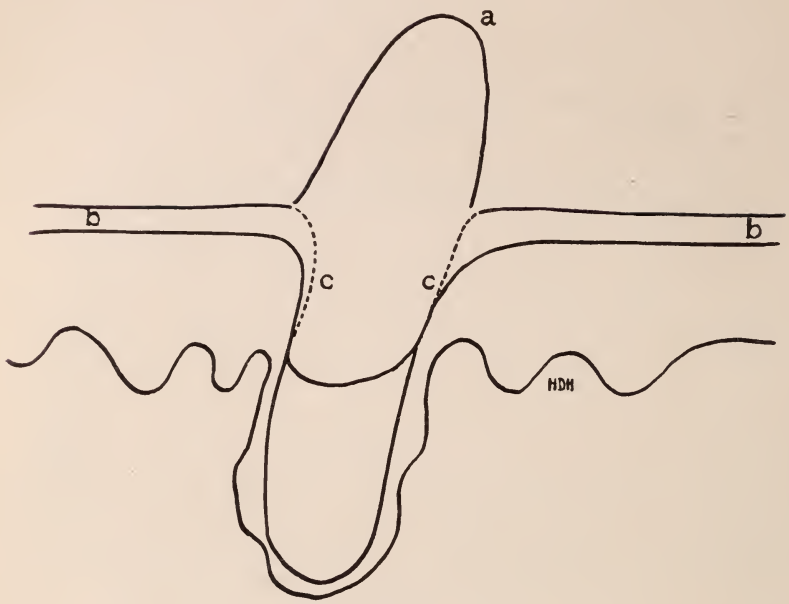

FIG. 5.

FIG. 5. Lichen spinulosus. Diagram showing filiform plug.
a. Elongated plug situated high in the follicle and projecting far above the surface.
b. Normal stratum corneum.
c. Dotted lines showing normal contour of the follicle.

FIG. 6. Lichen acuminatus. Drawing. Zeiss, Oc. 4, Obj. DD.
Note the large follicular plug, the stretching of the follicular wall obliterating the pegs, the acanthosis and hyperkeratosis in the epiderm to the left of the follicle, the dense infiltration to the right, the slight infiltration to the left, the perivascular infiltration, the general but slight vascular dilatation, and the distinct muscle bands below and to the right of the follicle.

FIG. 7. Keratosis pilaris. Drawing. Zeiss, Oc. 4, Obj. DD.
Note the superficiality of the plug, the absence of extrafollicular hyperkeratosis, the stretching of the follicular epithelium, the absence of infiltration, the marked vascular dilatation (red type of keratosis pilaris).

(*To be continued.*)

Plate LIV.—To Illustrate Article on Histopathology, by Walter J. Heimann, M.D.

Fig. 6.

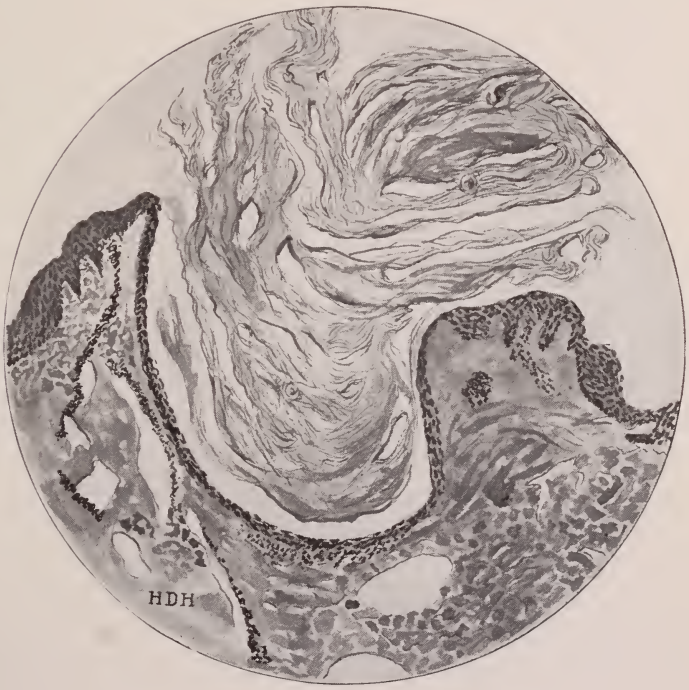

Fig. 7.

SOCIETY TRANSACTIONS.

MANHATTAN DERMATOLOGICAL SOCIETY.

Regular Meeting, Feb. 11, 1916.

George M. MacKee, M.D., *Chairman.*

CASE FOR DIAGNOSIS. Presented by Drs. MacKee and Wise.

The patient was a colored child, six months of age, who came to the Vanderbilt Clinic, Dr. Fordyce's service, three days previously. The child showed small, pitted scars of an eruption on the buttocks, thighs, scalp and face, more marked on the buttocks than elsewhere. A Wassermann test was taken in the mother, the child being too puny for vein puncture. The speakers presented the case with a tentative diagnosis of papulo-necrotic tuberculide. They were not certain whether the condition was one of lues or tuberculide. The result of the blood test in the mother was not yet made known.

Discussion.

Dr. Kingsbury said that he thought there was considerable justification in putting the question mark after a diagnosis of syphilis in this case. He did not think that the character of the scars or the localization of the condition looked like any known type of syphilitic lesion, liable to occur in an infant of that age. Syphilis could be excluded from the clinical appearance, the speaker said, and he thought it was probably scarring from an infection of the skin.

Dr. MacKee said that perhaps some of the gentlemen present would recall a small white boy, four or five years of age, who had a syphilitic and tuberculous dactylitis. He had grouped, pustular lesions that left similar pitted scars. This patient was followed up for a number of years and the lesions occurred in groups, and had not in any way been influenced by treatment. He thought that case was probably one of tuberculide and the case shown before the society resembled it to a certain extent, the pitted scars and the distribution being the same.

Dr. Satenstein said as this child was only six months old, he could not accept the eruption to be any form of tuberculide, having such uniform scarring, without some active lesions. The history of tuberculide did not run such a short course. The speaker said that the patient was underfed and he agreed with Dr. Kingsbury that it was simply scarring due to infection of the skin.

NÆVUS LYMPHANGIETODES(?). Presented by Drs. MacKee and Wise.

The patient, F. G., was a boy, eleven years of age, who had come to Dr. Fordyce's Clinic a few days previously, with a lesion on the right foot, involving

the large, first, second and third toes. The lesion consisted of an infiltration and œdema, giving the impression of a pseudo-elephantiasis of the toes. A diagnosis, tentatively, had been made of tuberculosis, without, however, any very definite characteristics of lupus or tuberculosis verrucosa cutis, in the clinical appearance of the lesion. The duration of the trouble had been ten years. The patient had exacerbations and attacks of inflammation with œdema, which subsided under wet dressings, leaving a moderate thickening of the toes, without any improvement in the lesion itself.

CASE FOR DIAGNOSIS. Presented by Dr. Bechet.

The patient, a male adult, from the service of Dr. Kingsbury, at the Skin and Cancer Hospital, had had for about seven months, a peculiar bluish-gray discoloration, about an inch in diameter, and situated on the shaft of the penis. Two other lesions, much smaller in extent, were observed on the scrotum. Outside of the discoloration, the affected areas seemed perfectly normal. Previous to the appearance of the stains, the patient had noticed some redness and considerable itching, upon which he had used a patented salve. The discoloration appeared with the subsidence of the inflammation. Since then he had had periodic attacks of itching with considerable redness around the discolored areas, which themselves underwent no change; these attacks came on every four or five weeks. There had never been vesicular formation or herpes progenitalis. The patient stated that the rest of the body had always been entirely free. A few weeks after presentation, in a good light, several flat but typical lichen planus lesions were observed on the glans penis. The areas of discoloration were then probably the site of a resolving lichen planus, yet no objective change in the skin, outside of the peculiar discoloration, could not be observed.

Discussion.

Dr. Satenstein said that if the patient had not been so persistent about his statements, he would be inclined to call the condition nævus pigmentosus.

CIRCINATE SEBORRHŒIC ECZEMA. Presented by Dr. Howard Fox.

The patient was a German woman, twenty-eight years of age, who presented an eruption on the face and neck, of two months' duration. It consisted of greasy, slightly scaly, nail-sized patches on the forehead, chin and cheek, and circinate, dull red patches on both sides of the neck, suggesting an erythema multiforme.

PEMPHIGUS. Presented by Dr. Wallhauser.

The patient was a male, aged twenty-eight years. The first indication of illness was noticed in January, 1915, when he experienced a sharp pain in his throat, accompanied by coughing, and expectorated a slight amount of blood. On examination, the uvula was found to be greatly swollen, and several "blisters" were observed on the soft palate. He consulted his family physician, and after several applications had been made to his throat, he was pronounced cured. About one week later he had a similar attack, which was followed by recurrences, until the entire membrane of the mouth had become involved. Nine months following the onset, the skin lesions appeared as typical bullæ of pemphigus; first on the upper extremities, then gradually involving the face, chest, back, abdomen and lower extremities, new crops appearing daily.

The patient's general health had suffered greatly, he having lost about twenty pounds; there had been a slight elevation of temperature, and the blood showed a secondary anæmia; the Wassermann and urine tests were negative.

After trying many routine remedies, including arsenic, without result, rapid improvement followed the administration of mild doses of bichloride of mercury and iodide of potash, together with baths of bichloride of mercury, 1 to 4000.

When presented, the patient had been on this plan of treatment about six weeks, during which time the skin lesions had entirely disappeared, leaving pigmented areas. The mouth still showed a few lesions, but his general health had improved to such an extent as to warrant a favorable prognosis.

Discussion.

Dr. Gottheil said that in some cases there did not seem to be any practical way of differentiating a severe bullous erythema from pemphigus. The presence or absence of constitutional symptoms, the involvement of the mucosæ, and the result, seemed to be the only way of reaching a conclusion. During the past year he had seen a few cases illustrating the difficulty. One, for instance, occurred in an elderly but vigorous man, whose whole body was covered with a true pemphigoid eruption which had come on slowly; in the course of several weeks: there were absolutely no other lesions; but the mucosæ were free, the general health was uninvolved, the patient had had a similar attack some years previously, and he made a good recovery. Another was in an elderly lady with a bad heart (myocarditis), and a gradually spreading bullous eruption which could only be diagnosed as pemphigus; the mucosæ were badly affected and the general health became progressively and badly impaired. Yet from time to time, true erythema and iris lesions appeared among the abundant and large bullæ. Yet it turned out to be a case of true pemphigus, with the usual result. The whole question of the diagnosis and consequently of the prognosis of these generalized bullous eruptions was very confused.

Dr. Ochs, in answer to Dr. Wallhauser, said that he recalled two such cases with a difference in the time of the appearance of the lesions of the mouth and skin. One case was in a woman, about fifty years of age, who came to the speaker for some mucous membrane lesions of the mouth. Bullous lesions had existed there for about two years, and the diagnosis varied. A laryngologist suggested the diagnosis of pemphigus. It took fully eight months before any cutaneous lesions developed and it proved to be a very severe case of pemphigus. The woman lived for about one year thereafter. The second was a private case, in which the lesions in the mouth had existed for fully one and one half years before any cutaneous manifestations came out, and also proved a severe pemphigus. The speaker stated that in many of these cases a long time elapsed before the skin would be affected, though the mucous membranes had been involved for a long while. All persistent and relapsing bullous eruptions of the mouth and fauces should be carefully watched, as these were the earlier forms of pemphigoid eruptions, and such cases became very severe ones and died soon after the cutaneous lesions appeared.

Dr. Kingsbury said he agreed with the remarks in general and especially with those of Dr. Gottheil. He thought the appearance of the man and the lesions of the skin suggested a strong possibility of erythema multiforme bullosum, rather than pemphigus.

Dr. Wise agreed with the diagnosis of benign pemphigus and believed that there existed a distinct dividing line between benign pemphigus and malignant pemphigus.

Dr. Senear (by invitation) said that in regard to the discussion of the mouth lesions, they had had a case under observation of recurrent erythema multiforme. It was one of very severe type and in all attacks there had been marked lesions of the mucous membranes with hæmorrhage from the mouth and blood in the stools. He came to the hospital before the last attack and stated that he had had lesions in the mouth several months previous to the appearance of the skin lesions. There was never any pigmentation following the attacks as was present in this case.

Dr. Mount said he thought that Dr. Wallhauser had not brought out one point in his statement. These bullous lesions appeared upon seemingly normal skin, with no erythema at all, and that, the speaker said, was one of the points in the diagnosis of pemphigus.

Dr. Bechet said that he had seen bullæ arising on apparently normal skin in erythema multiforme bullosum, and did not think that this point alone would be of value in the differentiation between the diseases.

Dr. Ochs asked the members of the Society whether they recalled the case of an Italian child, which he had presented in 1905. The patient, a child of three years, came to the Lebanon Hospital Clinic, having had repeated attacks, not only in the mouth, but lesions appeared over her entire body. Each attack was distinct in itself. The skin and mucosæ became normal, and in a short time another attack of vesicles and bullæ would appear and the patient was shown during one of these bad attacks; a diagnosis of benign pemphigus had been accepted by the Society. The patient died when five years of age, of pneumonia.

EPITHELIOMA OF THE MOUTH. Presented by Dr. Weiss.

The patient was a male adult, who had come from the German Polyclinic Hospital. He complained of pain in the tongue. An ulceration was confined to the under surface of the tongue, involving also the floor of the mouth. The history, so far as the patient knew, was that for the past five weeks he had experienced pain on talking and swallowing, and on eating. For a number of years he had had a sharp tooth on one side of the mouth. The patient showed a scar on the neck where, fifteen years previously, he had been operated on for swollen glands. The diagnosis had been made of epithelioma of the mouth, involving the buccal surface and the tongue.

EPITHELIOMA OF THE PENIS. Presented by Drs. Howard Fox and Ochs.

The patient, R. F., was a colored man, thirty-three years of age, born in the United States, a horse trainer by occupation. About fourteen months ago he had had a sore, according to his description, on the inner surface of the foreskin. This was removed, he said, by operation. He was told that he had contracted syphilis and was given treatment by mouth. About a month after the operation, the lesion for which he was presented appeared and had steadily progressed. During the past year he had not received any anti-syphilitic treatment, having suffered during this time from an attack of typhoid fever. He presented a fungating, papillomatous, ulcerating mass, the size of a horse chestnut and arising from the posterior half of the glans penis, the anterior half being intact. The mass was red, hard, tender and bled easily upon slight traumatism. He suffered from severe pain which prevented him from sleeping. There were two slightly enlarged and hard inguinal glands upon the left side. The Wassermann reaction was three plus.*

* (An examination made subsequently by Dr. Heimann, showed the presence of a basal cell epithelioma.)

DISCUSSION.

DR. WISE said that although he had no doubts as to the correctness of the diagnosis, he had an impression that the case might very well have been an epithelioma, engrafted upon a gumma, and that very stringent antiluetic treatment might have a tendency to diminish the size of the tumor. A tumor of that size in malignancy, with an absence of enlarged glands in the groin, was sufficient evidence to warrant the physician in going slowly, so far as amputation was concerned. All cases of epithelioma of the penis, of this size, the speaker said, usually were accompanied by glands in the groin, palpable and easily found, in his experience. These glands might appear on incision, but from the fact that they were not palpable there was a justification for strong antiluetic treatment before radical operation was undertaken.

DR. GOTTHEIL said complete ablation of the external genitals seemed to be the thing to advise when carcinoma of the penis was probable, as in this case; of course microscopic confirmation was needed. If the patient was not very old, as in this case, amputation of the penis alone was inadvisable. The late Dr. Carl Beck had done this in a case of his, years ago, ablating the penis at its root in a vigorous individual, not much over forty years of age, and the resultant discomfort and unhappiness had been very marked.

DR. HOWARD FOX thought the case was clinically an epithelioma. If this were confirmed by a biopsy, he thought that an operation should be performed at once. He did not see why time should be lost in giving the patient antisyphilitic treatment, if it were proved that an epithelioma was present. The speaker had previously shown a case of squamous cell epithelioma of the penis, before the dermatological section of the Academy. The patient was a man, sixty years of age, and the operation consisted of removal of the entire penis, scrotum and inguinal glands. There had been no recurrence at the end of three years.

XANTHOMA TUBEROSUM ET PLANUM ET LINEARIS. Presented by DR. ROSEN.

This patient was a female, sixty-six years of age, born in Russia, and came to the Mount Sinai Hospital Dispensary, service of Dr. Goldenberg, about seven months ago, complaining of intense itching of the entire body; this she said had existed for about one year.

On examination, the most pronounced symptom was an intense jaundice, the skin and conjunctivæ being deeply pigmented (yellow). At this time there were no evidences of any xanthomatous infiltrations in the skin. The patient continued to consult the speaker for the itching; after a few weeks she called his attention to small nodules on the elbows and body. New lesions made their appearance as time went on, so much so, that the folds in the palms were so thickly studded with these infiltrations, that great difficulty was experienced in closing the hands. The neck, chest, back, abdomen and lower extremities were also affected.

On examination, it was seen that the patient was poorly nourished; the skin and conjunctivæ were deeply pigmented with a lemon yellow color; the face presented numerous xanthomatous tumors varying in size from the head of a pin, to that of a small bean (these were located mostly on the upper lid and chin). The neck was covered with numerous small, linear, xanthomatous infiltrations, most marked in the folds. The chest showed numerous infiltrations, varying in size from a small pea to a hazel nut. The abdomen, back, thighs and lower extremities were similarly affected. The palmar folds were studded

with these xanthomatous infiltrations. The elbows were also affected with numerous tumors of variable size and shape.

CASE FOR DIAGNOSIS. Presented by Dr. Rosen.

Anna G., female, twenty-six years of age, born in Austria, married, came to the Mount Sinai Hospital Dispensary, service of Dr. Goldenberg, about the middle of January, 1916, for a lesion on the lip, that had existed about eight months and was constantly growing larger. It began as a small, red blotch; the lip became swollen as the area had increased in size.

On inspection, one first noticed a swelling of the outer portion of the upper lip (left side). The color of the affected area was chamois yellow, the surface was studded with horny plugs that stood out very prominently from the markedly hypertrophied follicular openings. No evidence of scaling was present, nor could one see any atrophic areas.

On palpation the lip was soft and œdematous; the surface was rough as a result of projections of the horny plugs.

A small piece of tissue was removed for microscopical study. The result of the pathological findings had not been reported upon as yet.

Discussion.

Dr. Wise said that it was true that there were follicular plugs, nutmeg-grater-like in appearance, but there was very little inflammatory reaction, very little redness, very little tendency to flattening or depression of the lesion; but on the contrary there was considerable œdema, which might have been caused partly by the biopsy, but œdema was present before the biopsy. Œdema was usually not a symptom of a patch of lupus erythematosus, and the speaker said that it was quite possible that the lesion, if kept under observation, might eventually turn out to be something else. The microscopic slide was not entirely decisive.

Dr. G. H. Fox said that in this case he would make a diagnosis of lupus erythematosus of unusual location. He said that he would like to see what the condition looked like after treatment had been stopped for a while, and that if it were decided that this was a case of lupus erythematosus, he would suggest treatment by radium. In severe cases of lupus erythematosus the speaker still believed in the use of the curette, which left a smooth scar; but in the incipient or mild cases, especially around the lips and nose, where one did not care to leave a scar, he had had very good results from the application of radium.

Dr. Howard Fox agreed with Dr. Wise that the lesions did not present the ordinary clinical picture of lupus erythematosus, being elevated and button-like in appearance. He called attention to a similar case shown previously before the Society as a case for diagnosis, a single lesion being present on the upper lip, near the nose. Even with the aid of a histological examination, made by Dr. Johnston, it was not possible to make a positive diagnosis, though lupus erythematosus was one of the possibilities suggested. Later Dr. Fox and Dr. MacKee were surprised to see this patient at the recent A. M. A. meeting in San Francisco. The patient, who was presented by Dr. Culver, then showed numerous typical lesions of lupus erythematosus, scattered over the face.

Dr. Parounagian said he did not know of any objection to the use of the solid carbon dioxide snow in these cases, and that very good results had been obtained by its use.

Dr. MacKee said he did not agree with Dr. Wise and those who spoke against the appearance of lupus erythematosus, clinically. He said he recollected the

case Dr. Fox spoke of very well and it was exactly like this case, with just a slight verrucous element and a follicular keratosis. The speaker remembered the case and it had been treated with the X-ray for quite a period. In the present case he would make a clinical diagnosis of possible lupus erythematosus. Dr. MacKee agreed absolutely with Dr. G. H. Fox in regard to radium and said that the X-ray was practically useless in these cases. If the beta X-rays could be obtained these lesions might be benefited, but as this could not be done, the X-ray did not seem to prove very efficacious. Simpson, of Chicago, the speaker said, had treated a number of cases with radium with very good results. Dr. MacKee was inclined to doubt the efficacy of the method until he tried it and said that in the discoid type radium was exceedingly efficacious.

Dr. Snyder (by invitation) said that to him the condition looked like lupus erythematosus. The microscopical slide showed involvement of the follicles and marked infiltration, with small lymphocytes. There was nothing pointing to erythema multiforme.

ACRODERMATITIS CHRONICA ATROPHICANS. Presented by Dr. Rosen.

Mary B., from the service of Dr. Goldenberg at the Mount Sinai Hospital Dispensary, was thirty-three years of age, born in Austria, married, the mother of two healthy children and had had no miscarriages. As a child she remembered having had measles and varicella; otherwise she had been healthy.

The condition presented began about two years ago, with an itching of the right forearm. She did not pay much attention to this at first, but after a month or so, she noticed a reddened condition of the forearm and peculiar sensations of heat and cold. This continued for months; after about seven or eight months, the lower extremities began to itch, and the same alterations of temperature were noted.

Present Condition. The patient was a well-nourished white woman of medium height and weight. Her general health was not impaired. Heart and lungs were normal, abdominal organs normal, reflexes normal. Wassermann test negative, von Pirquet test negative.

Description of Lesions. The entire right forearm, from the elbow to the wrist, was of a purplish hue (the color was not unlike that of pellagra), the skin was atrophied, and to the palpating fingers gave the impression as if one were touching the head of a drum. The circumference of this forearm was much smaller than that of the opposite side.

Both lower extremities were affected; the dorsal surface of both feet showed a similar involvement as that of the upper extremity, with one exception, and that was, the color was not as deep a purplish hue (salmon red). The gluteal and lumbo-sacral regions were also involved, and in running one's hand carefully along the back, from the inter-scapular space downwards toward the sacrum distinct infiltrations were felt.

Discussion.

Dr. Bechet said that he had presented this case two years previously before the Academy of Medicine, and was interested to observe that the disease had made very little progress in that time. It had apparently remained stationary.

Dr. Wise said that in the stage of the case, as presented, the name acrodermatitis was a misnomer, for there had been no atrophy as yet, and all the lesions were in the pre-atrophic stage. A biopsy from any part of the lesion, the speaker said, would show subepidermal infiltration, but no atrophy. The only area showing a suggestion of atrophy was the so-called anetodermia of the

knees, where the skin appeared wrinkled, but this was only suggestive. The speaker said that later the skin would become atrophic in all the affected regions, as the disease progressed.

KERION OF THE WRIST. Presented by Dr. Howard Fox.

The patient was a man, thirty-one years of age, a driver by occupation. About three weeks ago he had noticed a dry spot on the radial border of the left wrist, which enlarged and within ten days had attained the size presented. Ten days ago, according to the patient's statement, there were numerous pustules, each one pierced by a hair. He presented a semi-solid, reddish, somewhat tender, elevated, flattened lesion, the size of a half dollar, upon which were a few follicular pustules. Microscopical examination showed the presence of ringworm.

PITYRIASIS ROSEA. Presented by Dr. Bechet.

This case, a male adult, was shown because of the extraordinary amount of infiltration and scaling present. A number of the lesions were papular in character. Several of them were distinctly circular, with centres of absolutely normal skin. Others had fawn-colored centres; they therefore strongly resembled seborrhœic dermatitis, or tinea circinata. The disease had been present for one week. On the night of presentation, the lesions had markedly changed and had then assumed the typical appearance of pityriasis rosea. A few of the lesions, however, still showed marked infiltration.

IDIOPATHIC HÆMORRHAGIC SARCOMA, KAPOSI. Presented by Drs. MacKee and Wise.

The patient, J. F., was a male adult, forty-two years of age, born in Russia, from Dr. Fordyce's Clinic. The lesions began five years previously and were present on the legs, feet, hands and forearms, and showed the familiar picture of idiopathic hæmorrhagic sarcoma of Kaposi. The patient had been under X-ray treatment at the Vanderbilt Clinic for some time and the lesions which were treated had retrogressed considerably, but none of them had as yet faded entirely.

Discussion.

Dr. Remer (by invitation) said they had treated one or two cases of Kaposi's disease by the X-ray and that they had improved under the treatment. In the man presented, the lesion on the left arm, which was fully as marked as any of the most prominent lesions, after two or three X-ray treatments, had become almost flat.

Dr. Wise said he had another case of Kaposi's' sarcoma under observation, where a large plaque had disappeared and had remained away for eight months, under the influence of one erythema dose of the X-ray.

MULTIPLE GUMMATA. Presented by Dr. Bechet.

An adult male, aged thirty-five, presented himself in the service of Dr. Kingsbury, at the Skin and Cancer Hospital, with a number of indolent lesions, which had been present for four months. On the flexor surface of the left forearm were three rounded, brownish-red, fluctuating lesions, showing some resemblance to sporotrichosis. On the trunk were three or four typical gummata.

All of the lesions were apparently in the same stage of evolution. The Wassermann reaction was four-plus.

ERYTHEMA MULTIFORME PERSTANS. Presented by Drs. MacKee and Wise.

The patient, H. I., was a male adult, thirty-two years of age, from Dr. Fordyce's service at the Vanderbilt Clinic. He presented the remnants of lesions, showing pigmented spots, one on the left shoulder and two in the inter-gluteal space. He had occasionally had eruptions of erythema multiforme of the ordinary variety, which had persisted for three or four months. Two pigmented spots which the patient presented, near the sacral region, resembled ecchymoses, and were the result of a previous erythema multiforme eruption; they had been of nine months' duration. The patient presented several erythematous and partly pigmented lesions which had persisted for a year, without appreciable change in their appearance.

MANHATTAN DERMATOLOGICAL SOCIETY.

Regular Meeting, Mar. 10, 1916.

George M. MacKee, M.D., *Chairman.*

EPITHELIOMA. Presented by Dr. Bechet.

The patient was a woman, fifty years of age. The lesion had been present for six years. It was located in the right infraclavicular region and was very extensive, being several inches in diameter. Its growth had been slow but steady, but there had been no increase in size since the previous year. The lesion presented markedly circumscribed, rolled-up borders, several areas of cicatricial tissue about its central portion and several islands of exuberant, unhealthy granulations, bathed in pus and covered with rupia-like scales.

Discussion.

Dr. MacKee said that this case seemed to be an epithelioma of the serpiginous type, very superficial and spreading, with scar formation.

URTICARIA PIGMENTOSA. Presented by Dr. Bechet.

This infant was six months of age and had had the eruption for two months previously. The mother stated that the lesions first began as reddened papules and wheals, which, during involution, became pigmented. A considerable number of wheal-like papules of a dark red color, with interspersed, deeply pigmented lesions, were scattered irregularly over the body.

HERPES ZOSTER FEMORALIS. Presented by Dr. Parounagian.

The patient was a child, four and one-half years of age, who showed an eruption of herpes zoster of uncommon location. The lesion was situated on the anterior surface of the thigh, extending downward below the knee, corresponding to the area supplied by the internal cutaneous branch of the anterior

crural nerve. As this was the first case the speaker had seen about this location in so young a patient, he considered it of interest to present him.

ANGIOMA. Presented by Drs. Gottheil and Ochs.

The patient, Helen G., fifteen months of age, showed a large angioma about two inches in diameter, on the anterior surface of the chest, which had received two treatments with the solid carbon dioxide. She was presented to show the results obtained by the freezing treatment.

ANGIOMA. Presented by Drs. Gottheil and Ochs.

The patient, John O., nineteen months of age, showed an angioma, involving the entire lobe of the left ear and extending on to the cheek. He had had two treatments with the solid carbon dioxide snow, of forty seconds each in duration, and was showing marked improvement.

Discussion.

Dr. Ochs said he was sorry he had not shown these cases before the application of the treatment. Both lesions had flattened down considerably and were approximately one-half of their original height. These cases were shown to emphasize the extent and size of the angiomata, and were to be presented again in the fall, after thorough treatment.

Dr. Gottheil said that improvement was not quite the word applicable to these cases, for although the tumors were about half their original size, they were still covered with scar tissue. He said that if this were contracted more there would be a desirable result.

Dr. Pisko said that a good result was invariably obtained on the chest, over the ribs, with one treatment, no matter how large the lesion. He said that such a good result could not be obtained, however, on the face, even over the zygomatic process, where there was plenty of bone underneath.

Dr. Oulmann said that he had seen a number of these smaller angiomatous tumors in children, which he had left entirely alone and they had disappeared. The speaker said that, in the case of children, he believed one should postpone the treatment, to see whether spontaneous involution would occur.

Dr. MacKee said that this question about the treatment of angiomata had been brought up before the Society, two or three years previously. In the remarks made at that time, it had been stated that cases of cavernous angioma were very uncommon in adults. The speaker had seen only one case in an adult, which had persisted throughout life. He said there had been a number of cases in children at Dr. Fordyce's clinic, in which there was a spontaneous involution, beginning in the centre and spreading peripherally. The treatment which they were now using with considerable success, was radium. They liked it in these cases, not because it produced better end results, but because very little reaction and very little pain occurred. The results in the cavernous type of angioma with radium were really remarkable. On the other hand, the speaker had found the so-called port-wine mark to be very rebellious.

Dr. Ochs said that, in regard to radium, he had seen a case in a child, where the reaction was very marked after less than one-half hour's exposure of ten milligrams of radium. The speaker wished to call attention to the different methods of applying the solid carbon dioxide snow in his two cases. In a case like the one on the ear, one could make a fairly firm pressure of about one to one-and-one-half minutes in length, without obtaining very much reaction. On the

chest, however, the pressure must be slight and the duration very short, of about twenty to twenty-five seconds. The reasons were obvious, because the irritation caused by clothing, pressing against the chest, would produce a breaking down and subsequent bleeding. This must be prevented, in the use of the solid carbon dioxide. In both cases the tumor was now at least one-half of its original thickness; each case had received two applications, the one on the chest lasting twenty seconds and the one on the ear being one minute. The speaker hoped to show both cases in the fall.

SECONDARY SYPHILIS. Presented by Drs. Gottheil and Ochs.

The patient was a small girl. The interesting feature about this case, the speaker said, was that at the age of nine years, this child should have an acquired infection of syphilis. The site of the infection was undiscovered and there was no lesion in the throat or on the body. There was nothing to be seen but some small condylomata on the vulva. Dr. Ochs did not know where the child could have gotten the infection, which was manifested by a very recent eruption of the maculo-papular type, over the chest, back, arms and face.

Discussion.

Dr. Satenstein asked if it were possible that this was a direct inoculation into the blood. If such were a fact, then an initial sclerosis would not develop; the patient would be stating the truth when saying that she had had no primary sore.

Dr. Gottheil said that before the present eruption came out, the child had an infection of two fingers, which lasted only a few days. There was a little pus in the lesions, which were pricked and then disappeared. There was no case of syphilis in the family, the speaker said. It seemed that some of these cases must get their inoculation in the gastro-intestinal tract, pharynx and œsophagus.

Dr. MacKee said that hidden chancres were not uncommon. In Dr. Fordyce's clinic, a few years ago, a man presented himself with a generalized macular syphilide but there was no sign nor history of a primary lesion. It was noticed that the patient was almost deaf in one ear and the patient stated that a Eustachian catheter had been passed eight or ten weeks before the advent of the cutaneous eruption and that the deafness had gotten much worse, a few weeks after the use of the catheter. An examination by a rhinologist revealed the presence of a Eustachian chancre, the lesion being located just inside the nasal termination of the tube.

Chancres of the male urethra, the anus and of the throat were frequently overlooked. Then, finally, if the inoculation were sufficiently deep, it were possible that systemic syphilis might follow, without the development of a chancre. In line with this was the possibility of paternal syphilis and the infection of the mother through the fœtus.

The speaker said that a possible source of error in cases where there was no history nor evidence of an initial sclerosis was in assuming that every eruption possessing the clinical characteristics of an early syphilide, necessarily occurred a short time after inoculation. The speaker had presented a little boy to the Society several years ago—a boy with congenital syphilis, and yet at the age of eight, there were mucous patches on the roof of the mouth and on the tonsils —at least they possessed the clinical appearance of lesions that usually occurred only in the first few months of the disease. It should also be remembered that a generalized macular or papular eruption might occur in the second year of syphilis or even later, in exceptional cases.

Dr. Davis (by invitation) said he would like to ask Dr. MacKee whether in his male patient the deafness came on after the initial or after the secondary lesion.

Dr. MacKee replied that the man had had some deafness before he had syphilis. It was to relieve this condition that the Eustachian catheter was passed.

PURPURA. Presented by Drs. MacKee and Wise.

The patient was a young woman, twenty-six years of age, from Dr. Fordyce's clinic. She showed a diffuse purpura on the thighs and gave a history of bleeding very easily, as when a tooth was extracted, but apparently the disease was not typical of hæmophilia. The history was not really definite enough to justify calling her case one of hæmophilia. She presented numerous purpuric spots in her mouth, on her lips and on both upper and lower limbs. This purpura first came out after six injections of horse serum, and, according to her history, it had never appeared before that. The speaker said Dr. Satenstein had been kind enough to call his attention to an article on pseudo-hæmophilia and Dr. Wise thought his case to be one of that kind, showing Sicard's syndrome. Her menstrual periods had been prolonged to ten days. The purpura improved after she had received calcium chloride for a period, in one-and-one-half grain doses, every hour. The speaker presented the patient for further therapeutic suggestions.

Discussion.

Dr. Gottheil said he would like to ask why this case was called a pseudo-hæmophilia.

Dr. MacKee said that for one thing, hæmophilia did not occur very often in the female, in fact, it was not supposed to occur at all in that sex. The symptoms were not those of clean-cut hæmophilia, for if this case were such, the woman could not very well continue to live, for she would have bled to death during a menstrual period.

Dr. Abrahams asked Dr. MacKee what made him think that hæmophilia did not occur in women. He said he had seen quite a number of female hæmophilia patients, who had lived a long time and had lost a good deal of blood during menstruation. The speaker did not see why these cases were called "pseudo," because they occurred in the female. He said he had seen two patients who eventually died; one lived until eighteen years of age and the other up to twenty-four years of age.

Dr. Wise said he would call attention to those cases, which they saw rather frequently in women and men, who got ecchymoses very easily, and to the article to which Dr. Satenstein had referred him, dealing chiefly with that type of cases.

Dr. Abrahams said one of the very best forms of treatment in purpura hæmorrhagica was the injection of emetin. He had recently seen a few patients who had responded splendidly to emetin injections, which were given in doses of one ampule, containing one-and-one-half grains, every two or three hours, for two or three days in succession.

Dr. Wise said he would like to emphasize the fact that this patient had immediately improved after the administration of one-and-one-half grains of calcium chloride, every hour.

UNILATERAL PIGMENTATION. Presented by Drs. Howard Fox and Ochs.

The patient, Kate K., forty-five years of age, married, was the mother of seven living and four dead children. She had never had any skin disease. Three months previously, she noticed some small, brown "specks" appearing on the forearm and also on the left knee, over the knee cap. These quickly grew in size, so that when presented, there was a fairly sharply outlined, reticulated and pigmented lesion on the left forearm, about ten by two and one-half inches in size. The color was brownish-red with some light red spots and others dark red. There was no hyperæmia or elevation. Pressure did not remove the spots. The surrounding skin was normal, as was the skin within the reticulated area. On the knee over the patella was a dark, pigmented area, the size of a bean, and radiating from this, fan-shaped, over the lower part of the thigh, there was a similar reticulation as on the arm, but not so extensive. There was marked enæsthesia here, but none on the forearm. There was no itching or burning.

Discussion.

Dr. Satenstein said that the nearest approach to the picture presented in this case, was the so-called syphilitic cutis marmorata as described by Ehrmann, in 1907 and 1912, under the heading of livedo racemosa, representing the clinical picture of syphilitic changes in skin vessels.

Dr. Pisko said he would make a diagnosis of morphœa.

Dr. Satenstein said that early syphilitic lesions were as a rule more or less general, but later lesions rarely so; in this case the lesions were limited. In some of the cases reported by Ehrmann in 1912, the lesions were also limited to the extremities, and in one case had appeared many years after infection.

ADENOMA SEBACEUM. Presented by Dr. Bechet.

The patient, a young female adult of apparent normal mentality, presented for examination a considerable number of typical lesions. They were particularly numerous on the sides of the nose and the central portion of the chin. They had been present for seven years, and had greatly increased during the year previous to presentation.

Discussion.

Dr. Parounagian remarked that the interesting feature in this case was, that the patient seemed to be quite intelligent, as most of the text-books stated that patients with adenoma sebaceum were, as a rule, feeble minded.

Dr. Bechet said that it might be of interest to add that he had presented a case of this disease at the Academy of Medicine, two or three years previously. The patient's mentality was also absolutely normal and she had none of the stigmata usually associated with the disease.

CASE FOR DIAGNOSIS. MORPHŒA (?) Presented by Drs. Gottheil and Ochs.

The patient, M. V., fifty years of age and married, was the mother of four living children and one dead child. The baby had died when three months old, of summer complaint. She had always been well. One year previously she sustained an injury to the bridge of the nose, being struck with a ring. Only a bruise resulted and no blood showed. The wound healed with a scar, pin-

point in size. From this an atrophic lesion developed, which slowly grew in size. Three months ago the patient developed grippe and since that time the lesion grew more rapidly. Over the bridge of the nose there was a perfectly flat, atrophic, white, almost circular spot, about one-half inch in diameter. There was no thickening palpable to the touch, but the skin appeared thinned. The borders were sharply defined and erythematous, showing an increased amount of capillaries.

Discussion.

Dr. Pisko said that superficial epithelioma was the diagnosis which he considered most probable.

Dr. Satenstein said that the erythematous border as usually seen with morphœa, was not present in this case. The upper margin of the lesion seemed to be slightly infiltrated and teleangiectasis was more marked in this area. The speaker would be inclined to call this a morphœa-like-epithelioma, as described by Fordyce, in 1908.

Dr. Bechet said that he thought he had observed a marked teleangiectasia. The lesion was waxy and board-like, there was an apparent absence of a raised border, and he would be more inclined to consider it a morphœa than an epithelioma.

Dr. Wise said although it was a fact that teleangiectasis held good for both epithelioma and morphœa, he agreed with Dr. Satenstein in the diagnosis of epithelioma.

Dr. MacKee said he agreed with a diagnosis of morphœa-like epithelioma, as described by Hartzel.

Dr. Ochs said he was undecided whether to classify this case in the category of morphœa-like epithelioma or simply as a morphœa, though he stated that along the edges there was an increased blood supply and teleangiectasis. He was, however, inclined to the diagnosis of morphœa, with trauma as the causal factor.

LEUKONYCHIA TOTALIS. Presented by Drs. MacKee and Wise.

The patient was a female, thirty-four years of age, from Dr. Fordyce's clinic. She presented lesions of the nails, which were typical examples of leukonychia. The finger nails of both hands showed transverse, white striations, occupying the entire nail surfaces. She had had the trouble since early childhood.

MORPHŒA AND ACRODERMATITIS. Presented by Dr. Bechet.

The patient a woman, aged sixty-one years, had had an acrodermatitis of five years' standing, involving both lower legs; the typical thinning of the skin, prominence of the surface veins, and interspersed brownish discoloration, were all present. On the upper third of the right breast was a sharply circumscribed, indurated, board-like patch, about one-and-one-half inches in diameter. It had a waxy appearance, and was surrounded by a teleangiectatic halo. Two or three atrophic spots were present on the back. She stated that the morphœa patch had first appeared as a white stripe, which had gradually widened.

Discussion.

Dr. Ochs said he had treated this case some three years ago at the Lebanon Hospital and at that time the patient had the morphœa patch. All the other lesions seen had been almost identical, were not progressing and had been in a

very quiescent stage. He made the diagnosis of acrodermatitis atrophicans at that time.

Dr. Wise said the lesions on the leg were typical of acrodermatitis chronica atrophicans. The clinical differentiation between the aspect on the leg and scleroderma was, that in scleroderma the veins did not shine through the skin, as they did in this disease.

Dr. Oulmann said he believed that scleroderma and acrodermatitis belong to one group and that the lesion on the chest was simply a circumscribed lesion, which showed the same process.

MYCOSIS FUNGOIDES. Presented by Dr. Kingsbury.

The patient was a female adult, who had had a general pruriginous eruption for the past three years. The condition remained unrelieved by the usual antipruritic remedies. The speaker showed the case as one of mycosis fungoides in the premycotic stage.

Discussion.

Dr. Gottheil said they had had such a case in the City Hospital, in the premycotic stage. They did not know what to do with the case. Dr. Abrahams saw the case too and suggested putting the man on Coley's toxines, after which every lesion disappeared. They did not recognize the man at a meeting of the Eastern Medical Society and all the lesions had disappeared under the injections of Coley's mixed toxines. They saw the man at autopsy and found tumors in the liver, intestines and kidneys, which were histologically like the skin tumors.

Dr. Wise said that without doubt the lesions would heal up under the X-ray, but that they would recur after a while. The skin would become normal clinically, but the patient would have to be kept under observation and treatment.

Dr. Satenstein said in the literature it was stated that the histological characters of recurrent lesions after radio-therapy, were more like those met in sarcoma than in the pure inflammations. Death ensued quicker after X-ray therapy than would otherwise have been the case; that the rays seemed to stimulate the malignant tendencies of the cells present in mycosis fungoides.

Dr. MacKee said that in condemning or praising the X-ray treatment of mycosis fungoides, it should be remembered that the clinical course of the disease was likely to be capricious. In some instances where no X-ray had been administered, the affection would cause very little disturbance for years and then would become suddenly worse and cause death. If the X-ray were administered to such a case, late in its evolution, it might produce only temporary relief. The remission would be followed by an exacerbation and the X-ray would receive the blame. Contrarily, there were cases that ran a comparatively benign course and in such instances the X-ray probably received too much credit. Large doses of X-ray, applied over extensive surfaces, might readily be productive of bad results in mycosis, especially when the treatment began, and the speaker did not doubt that many of the reported bad results were correctly attributed to the X-ray, or rather to the manner in which it was employed—in other words, faulty technique. It should be remembered, too, that after a while, regardless of the technique employed, the disease failed to yield to the influence of the X-ray, often became rapidly worse and resulted in the death of the patient. The X-ray should not be blamed in such instances, for without the X-ray the lives of many of these patients would be shortened by several or even many years. The technique employed by Dr. Remer at Dr. Fordyce's clinic, was to apply small doses to small areas, at first. The doses were gradually increased

and the surfaces enlarged. Finally, if necessary, areas as extensive as half of the back received a massive dose— H 1, B 9–10, at skin distance. The patients who finally died did so in spite of, and not due to, the X-ray. The speaker had one case under observation in which tumors had been developing over a period of ten years. As soon as a lesion appeared it was given a suberythema dose at one sitting and it promptly disappeared. At times, eight or ten tumors would develop in one month. At other times the patient might be free of lesions for several months. Both Dr. Fordyce and Dr. Howard Fox had observed and treated the patient. The speaker did not think the benign course of the disease was due entirely to the X-ray, but he did think that the patient would have been very uncomfortable for years and probably would have died years ago if he had not received X-ray treatment.

DERMATITIS HERPETIFORMIS WITH LYMPHATIC LEUKÆMIA. Presented by Dr. Parounagian.

The patient was a female, fifty-three years of age, born in Austria. The duration of her skin affection was two years and of the lymphatic enlargements about fifteen months. Several months ago, she was presented at the Academy of Medicine, with typical lesions of Duhring's disease,—grouped papules, with pigmented areas, excessive itching and recurrent attacks. Dr. Heimann, who had the patient under observation at the German Hospital, stated that he had studied the case microscopically and the result of the examination revealed a leukæmic skin lesion. The patient improved under routine treatment for Duhring's disease, i. e., iron and arsenic internally, and locally, sulphur, 10 per cent., phenol, 3 per cent., in ungt. zinci oxidum, alternating with calamine lotion, with phenol and menthol. For a time she was comparatively free from skin manifestations, until several weeks ago, when she developed a gangrænous zoster in the pectoral region, and the skin manifestations reappeared. At the time of the last presentation, a number of pea-sized, hard nodules were present on the face and on the body, which were not present at the time she was presented before the Academy meeting.

Discussion.

Dr. Wise said that this patient presented granulomata of the face and it was a very interesting question as to whether she did not have a coincidence of Duhring's disease with leukæmia.

Dr. Oulmann said that Dr. Heimann had diagnosed the sections as leukæmia of the skin and that the combination with Duhring's disease was mentioned before by others.

Dr. Pisko said that the lesions were probably due to the leukæmia, as Dr. Heimann had stated at the Academy meeting.

Dr. Parounagian said that when he showed this patient several months previously, she had a typical eruption of Duhring's disease. She gave a history of these recurrent attacks, with pigmented areas; the itching was intense, the lesions would partly disappear and then exacerbations would take place. The speaker said he began to treat the patient with arsenic internally and ten per cent. silver nitrate in a zinc oxide base, locally. This treatment allayed the itching, the lesions disappeared and after they cleared up, the patient remained away. Several weeks previously he saw her with a very severe attack of zoster of the gangrænous type and had not seen her since. He saw the nodules on the face for the first time that evening and would be very glad to watch the patient and report further on the case.

LEPRA. Presented by Dr. Gottheil.

The patient was a male adult, born in Italy, who had appeared at the Lebanon Hospital Dispensary the week previously, with an eruption of leprosy. The eye department had referred the patient to the speaker. Most of the lesions were on the arms and thighs. There were no lesions on the trunk.

TUBERCULOSIS CUTIS ORIFICIALIS. Presented by Dr. Bechet.

The patient, a male adult, had had a lesion on the inner left cheek, of three months' duration. It was an indolent ulcer with sharply defined, undermined edges, its floor was covered with indolent granulations, bathed in a watery pus. He had had a chronic cough for one and a half months previously. Tubercle bacilli were found in the sputum and a physical examination revealed tuberculous foci in the lungs. The Wassermann reaction was three plus. In spite of the result of the Wassermann, the speaker thought the lesion was tuberculous and presented it as such.

Discussion.

Dr. Parounagian said, in view of the positive Wassermann and tuberculin tests, he would suggest a thorough therapeutic test, before deciding on the diagnosis of tuberculosis.

Dr. Kingsbury said he believed the case was one of tuberculosis, but agreed with Dr. Parounagian that it should have a therapeutic test.

Dr. Pisko agreed with the diagnosis of tuberculosis.

Dr. Abrahams said he would suggest a thorough antisyphilitic treatment. There were cases on record of syphilitic lesions where mercury was employed, in which it also cured the tuberculous lesions. The speaker had treated one such case of tuberculosis cutis in a syphilitic, fifteen or sixteen years previously, which had appeared in the Montefiore Home. Some mixed antisyphilitic treatment was employed and the patient improved quite nicely, both lesions being cured.

Dr. Bechet said this case was interesting because of the positive tuberculous and syphilitic findings. The lesion was certainly a tuberculous one and the speaker thought that at times one was inclined to dwell too much on the Wassermann test and too little on the clinical manifestations. Because this man had a three plus Wassermann reaction it did not necessarily mean that the lesion was syphilitic, but of course it did mean that he had had an antedating syphilis.

LUPUS VULGARIS. Presented by Dr. Bechet.

The patient, a male, aged sixty-four years, stated that the disease began when he was sixty years of age, and that it had been present only four years. He had tuberculous glands of the neck when a boy. The lesion involved the greater part of the left cheek and contained many "apple-jelly" nodules. The case was presented because of the unusually late occurrence of the lesion.

ERYTHEMA MULTIFORME IRIS. Presented by Dr. Weiss.

The patient was a male adult and had had rheumatic fever with a high temperature, last November. About three weeks previous to his presentation, an eruption had broken out, which proved to be erythema multiforme iris, occupying both thighs, buttocks and both sides of the trunk and arms. Twenty minutes

after receiving one-tenth grain pituitrin he had felt pains in the left arm on the site of a peculiarly pronounced patch of erythematous lesions. This happened after every dose, until the treatment was stopped. The pituitary extract was given him empirically, as the patient exhibited a certain degree of acromegaly.

Discussion.

Dr. Parounagian said this case reminded him of a case of pityriasis rosea, existing on the lower extremities only, but that upon further examination, his case also showed some beginning lesions on the body. The speaker said there was a possibility of this case being pityriasis rosea, as the condition appeared too scaly for erythema multiforme.

Dr. Satenstein said he thought this a case of pityriasis rosea, hæmorrhagic in character.

Dr. Gilmour thought this case to be one of pityriasis rosea.

Dr. Pisko considered the case to be one of erythema multiforme.

Dr. Oulmann favored the diagnosis of pityriasis rosea.

Dr. MacKee said that the case looked very much like pityriasis rosea to him. There was a crinkling in the centre of the lesions, which also, however, might occur in erythema multiforme. The limited location was in favor of erythema multiforme, although cases of pityriasis rosea also occurred in fairly limited regions.

Dr. Weiss said he did not think this case could be one of pityriasis rosea and the eruption was not one which he made out to be of that type. In pityriasis rosea the lesions were salmon colored, had slightly furfuraceous markings and, the speaker said, would never be of such a deep brown color with a tendency to circular papulation, with depressed centres and rather purplish hue, as in erythema multiforme. He still thought the diagnosis of erythema multiforme the right one.

MULTIPLE GUMMATA. Presented by Dr. Parounagian.

The patient was a male adult, thirty-six years of age, born in Spain and a fireman by occupation. He had had an initial lesion about eight years previously. He had received some treatment by mouth, two years ago, and was treated with salvarsan at the Moravian Hospital. He came to the Gouverneur Clinic about eight weeks previous to his presentation, where treatment was begun with intramuscular injections of mercury, in doses of one to two grains. He showed lesions of multiple gummata. While under treatment, he continued to develop new lesions. These were present on the scalp, face and over the body. There was a gumma on the penis also. The speaker had brought this patient before the Society because of a remark made at the last meeting, that they could do just as much with mercury as with salvarsan and this case certainly disproved that statement to his mind.

Discussion.

Dr. Wise said that in this case he thought large doses of potassium iodide should be kept up persistently.

Dr. Gottheil said that they had forgotten to treat syphilis with large doses of potassium iodide, and by large doses he meant one hundred grains of that drug.

Dr. Pisko said that in a case like this, where intramuscular injections of salicylate of mercury were given while new lesions appeared, the injections

should be stopped for an indefinite time. It was much better to do nothing and just allow the patient to recuperate. The speaker said the patient's condition should be toned up and that he should be sent to the country.

Dr. Ochs said in this case he would act as Dr. Pisko had suggested, stop the mercury, give the patient a change of air, put him on small doses of arsenic and tonics and by this treatment the patient would get well.

ANTHRAX SPECIMENS. Presented by Dr. Wallhauser.

The specimens shown had been removed from two cases of anthrax, treated at the Newark City Hospital.

Treatment consisted of complete removal of the nodular, necrotic, vesicular area, down to the underlying fascia, using a paquelin cautery; phenol was then injected into the surrounding subcutaneous tissue, the amount being limited to 15 minims, distributed to include all the outlying œdematous area; anthrax serum had also been administered intravenously, for several days. Both patients recovered with remarkable rapidity.

NEW YORK ACADEMY OF MEDICINE.
SECTION ON DERMATOLOGY.

Regular Meeting, April 4, 1916.

Charles M. Williams, M.D., *Chairman.*

RHINOSCLEROMA. Presented by Dr. Chargin.

L. K. was 26 years old, a tailor, and married. The family history was negative. The patient was a native of Southwestern Russia (Bessarabia) and had been three years in the United States. The onset was not definite, but the disease began at least three years ago, first appearing upon the inner aspect of the alæ nasi, and later involving the anterior portion of the nasal cavity on both sides. The cavities were markedly stenosed, especially the left, and there was constant discharge, with crust formation. The rest of the respiratory tract was apparently uninvolved. The nasal examination showed nodular and diffuse infiltration with scars and teleangiectasis.

ADENOMA SEBACEUM. Presented by Drs. MacKee and Wise.

L. T., aged 19, female, single; was from Dr. Fordyce's service. The lesions were of ten years' duration and occupied the cheeks and bulb of the nose. They consisted of pinpoint- to pinhead-sized, closely aggregated small papules, with similar-sized angiomata. The left lesion was treated by Dr. MacKee with radium four days before presentation, and had resulted in a moderate erythema.

ICHTHYOSIS HYSTRIX. Presented by Dr. Howard Fox.

This case had been previously shown before the March meeting of the New York Dermatological Society. See Transactions.

DISCUSSION.

DR. POLLITZER said that this case did not suggest one of ichthyosis hystrix, but rather one of linear nævus. He added that the term ichthyosis hystrix was used loosely to indicate sometimes a severe ichthyosis and sometimes a linear nævus. The case presented was certainly not one of ichthyosis, though the term ichthyosiforme might be added as descriptive of some portions of the linear nævus.

DR. ROSEN agreed that the case was not one of ichthyosis hystrix, nor was it an example of erythrodermia ichthyosiforme, which was suggested. He preferred the designation of generalized nævus.

DR. TRIMBLE agreed with Dr. Fox's diagnosis as presented on the history card,—ichthyosis hystrix. He said this same subject had been discussed before, at several meetings of the Section, and he thought the difference of opinion was merely of academic nature. Some men preferred to call cases like the one under discussion nævi, while others preferred the designation ichthyosis hystrix. It made no material difference which name was used; but that he personally preferred to call such cases ichthyosis hystrix. This had been the custom in the past, and was justified for several reasons, the main ones of which were, that the lesions were always bilateral and the so-called nævus cells were not found. The name commonly in use for such cases as the first one shown by Dr. Fox was nævus unius lateris, showing the condition to be unilateral. When cases presented themselves with lesions generalized, bilateral and at times symmetrical, he preferred to classify them with ichthyosis until better proof could be offered that they were nævi. The speaker added that the differentiation between the two conditions under consideration resolved itself into one of nomenclature, and that this patient seemed to him to have a nævus.

DR. HEIMANN said that he thought the confusion exhibited in connection with this discussion depended upon an inexact and too restricted use of terms. In general it was imagined that only that lesion was a nævus in which nævus cells were present. In the first place, the nature and significance of nævus cells were not understood. According to Darier,—and this view seemed the logical one,—all disturbances of the skin, present at birth, or developing later in life from embryonal predisposing causes, were to be classed as nævi. Thus would be included ichthyosis, von Recklinghausen's disease, Pringle's disease, xeroderma pigmentosum, etc., none of which were found to contain nævus cells. In other words, a nævus was any non-inflammatory congenital disturbance of any element, or combination of elements, in the skin.

NÆVUS VERRUCOSUS LINEARIS. Presented by DRS. MACKEE and WISE.

J. L., female, aged 23, single, was from Dr. Fordyce's service. The lesions were on the bend of the right elbow, both surfaces of the right knee, midline of abdomen, and right side of abdomen. Lesions were also present on the dorsum of the right foot, and a few in the right axilla. The lesions were treated in Boston, with radium, five years ago. X-ray was applied to the lesion of the right cubital space, with only temporary benefit.

CASE FOR DIAGNOSIS (BROMIDE ERUPTION?). Presented by DR. A. S. CLARK.

Previously presented before the New York Dermatological Society. See transactions.

In addition, the following cases were presented:

ELEPHANTIASIS. Presented by Dr. Howard Fox.

This case was shown previously before the March meeting of the New York Dermatological Society.

LICHEN PLANUS. Presented by Dr. Parounagian.

KERATOSIS PALMARIS ET PLANTARIS. Presented by Dr. Parounagian.

PHILADELPHIA DERMATOLOGICAL SOCIETY.

Henry K. Gaskill, M.D., *Secretary.*

Regular Meeting, Feb. 21, 1916.

Frank Crozer Knowles, M.D., *Chairman.*

LUPUS ERYTHEMATOSUS. Presented by Dr. Hartzell.

Male, white, aged 46. The chest, as far down as the fourth rib, particularly over the clavicles, was involved but much more on the left side than on the right. The eruption was almost one solid plaque, with several small areas of marked intensity and the entire surface more or less covered with a gray scale. The eruption started only last July (1915) and had extended very rapidly, particularly in the last three weeks. The outline was extremely irregular, extending up into the scalp where there were a few scattered, individual lesions. The patient's health had remained particularly good and he complained of no subjective symptoms.

CONGENITAL SYPHILIS. Presented by Dr. Walker.

Female, white, aged 11. This patient had been brought to the Episcopal Hospital in October, 1915, for a lesion in the submaxillary region, extending from the middle of the jaw down and out, for an inch and a half, where it turned upwards and became much wider and thicker over the submaxillary bone. There was marked induration and scarring, though the speaker said that feature was infinitely better than when first seen by him, and she had been under very energetic antiluetic treatment. Wassermann 4 plus. The lesion made its appearance last June (1915) and had been treated for carbuncle with flaxseed poultices, followed by curettage and other external applications.

CASE FOR DIAGNOSIS. Presented by Dr. Hirschler.

Female, white, aged 39. On the under side of the right leg was an orange sized area, irregular in outline, which consisted mostly of pigmentation, though there were several elevated lesions which had the appearance of being vesicles; but instead of being filled with clear serum, contained blood. These lesions sometimes attained the size of a dime and had occurred periodically, for the last three years. The patient usually knew when they were going to break out, on account of a peculiar sensation, though there was none after they had made their appearance. The lesions occurred approximately every six weeks. They

formed within a few days, broke down and discharged the blood, after which a scab formed and healed over, leaving only pigmentation.

CHANCRE OF TONGUE. Presented by Dr. Davis.

Female, white, aged 18. On the right side of the tongue there was an indurated lesion, about the size of a dime, which had been painted by the druggist with silver nitrate and alum. This lesion made its appearance about six weeks ago and while there was considerable glandular involvement and a 2 plus Wassermann, there was no eruption discernible on the body. The only lesions which were suggestive of syphilis other than the chancre, were a few moist papules on the upper lip. No history of any infection in this case was obtainable.

CASE FOR DIAGNOSIS. Presented by Dr. Davis.

Male, white, aged 48; Italian by birth. While the patient had always been troubled with excessive sweating, it was only approximately three years ago that the skin began to peel off in large plaques. On the left leg there was an eruption which usually preceded the exfoliation and resembled the skin of a pineapple, only of a gray-white color. The scales overlapped each other and were considerably elevated above the surrounding skin. This crust had evidently been due to some exudative process which had dried, become heaped up and, in a few weeks, will drop off, leaving a smooth, mildly inflammatory area beneath.

MOLLUSCUM CONTAGIOSUM. Presented by Dr. Hartzell.

Male, white, aged 12. Under the boy's left arm were a few lesions typical of the molluscum contagiosum type, except that a certain percentage of them were pedunculated. In all, there were approximately twenty lesions, most of them on the posterior axillary fold. The lesions had been there since August, 1915, and new lesions had been developing very slowly. There were none whatever on the exposed parts of the body nor did any other member of the family have any. The speaker remarked that this reminded him of the epidemic of this disease which he had seen a few years ago, in a certain college, where the peculiarity of the eruption lay in that all the lesions on the four or five hundred men who were seen, were on the trunk. In that instance, the infection undoubtedly took place in the swimming pool.

CASE FOR DIAGNOSIS. Presented by Dr. Davis.

Male, white, aged 60. The patient had a few scattered lesions on the body, two on the back; one on the leg and four around the neck, though there were several deep scars where previous lesions may have been. When the patient was first seen, a tentative diagnosis of blastomycosis was made, but the laboratory findings excluded this, giving the diagnosis as a staphylococcic infection. The lesions were all sharply marginated, most of them approximately the size of a dime, and while it was remarked that the diagnosis of syphilis could not be excluded, yet the lesions had shown considerable improvement under local applications.

REVIEW

OF

DERMATOLOGY AND SYPHILIS.

Under the direction of

FRED WISE, M.D., New York,

Assisted by

CLARENCE A. BAER, M.D., Milwaukee.
WILLIAM H. BAUGHMAN, M.D., New York.
PAUL E. BECHET, M.D., New York.
J. S. EISENSTAEDT, M.D., Chicago.
CHARLES GOOSMANN, M.D., Cincinnati.
JAMES F. GRATTAN, M.D., New York.
ROBERT C. JAMIESON, M.D., Detroit.
FREDERICK T. LAU, M.D., New York.
M. F. LAUTMAN, M.D., Hot Springs.
OSCAR L. LEVIN, M.D., New York.
M. L. RAVITCH, M.D., Louisville.
ISADORE ROSEN, M.D., New York.
MAX SCHEER, M.D., New York.
PHILIP F. SHAFFNER, M.D., Chicago.
A. W. STILLIANS, M.D., Chicago.
JOHN H. STOKES, M.D., Chicago.
HARVEY P. TOWLE, M.D., Boston.
VICENTE PARDO, M.D., Havana, Cuba.

JOURNAL OF TROPICAL MEDICINE AND HYGIENE.

(Nov. 15, 1915, xviii, No. 22.)

Abstracted by R. C. JAMIESON, M.D.

INOCULATION OF SMALLPOX AS A PROPHYLACTIC MEASURE, AS PRACTISED BY THE NATIVES AT DJEN IN NIGERIA. H. A. FOY, p. 255.

Inoculation is made on the forearm, taking lymph from a case of discrete smallpox in a young person on the ninth day of the disease. A half-inch incision is made with a razor and some of the pus inoculated by means of a

straw. A grain of maize is then placed in the mouth of the inoculated person followed by a drop of honey on the tongue, and also on the site of the inoculation. The latter procedures are for the purpose of producing a discrete smallpox in which the lesions will have contents clear as honey.

Eighty per cent. of those inoculated developed a local reaction, while 43% developed smallpox (53% of those developing local reaction). The incubation period of the disease so acquired was shortened and the majority had mild attacks.

(*Ibidem*, Jan. 15, 1916, xix, No. 2.)

NOTES ON PELLAGRA. W. M. McDonald, p. 17.

McDonald reviews the maize, protozoal, water and protein theories, and states his reasons for belief in the theory that pellagra is due to lack of certain elements in the dietary of pellagrins, associated with poverty. He believes that poverty is a great ætiological factor in the production of pellagra, as the poorer classes are unable to provide a varied diet, and further states that he believes that "pellagra only occurs among those persons who by reason of poverty or confinement in an institution, or eccentricity of taste or constitution, such as dyspepsia, are debarred from exercising a natural selection in regard to articles of diet."

BULLETIN OF THE JOHNS HOPKINS HOSPITAL.

(December, 1915, xxvi, No. 298.)

Abstracted by R. C. Jamieson, M.D.

A FURTHER STUDY OF THE DIAGNOSTIC VALUE OF THE COLLOIDAL GOLD REACTION, TOGETHER WITH A METHOD FOR THE PREPARATION OF THE REAGENT. S. R. Miller, N. D. Brush, J. S. Hammers, and L. D. Felton, p. 391.

This is a lengthy article, taking up and discussing in detail the technique used for preparing the various reagents, the results of the reaction and the routine employed in all cases.

As a result of their work they have found that a normal spinal fluid produced no change in the colloidal gold solution, and that the reactions obtained in tabes and cerebrospinal syphilis, while not characteristic in themselves, were valuable as confirmatory diagnostic evidence. Paresis gave a nearly uniform reaction type; congenital lues did not give generally a characteristic reaction.

Their final conclusions are as follows: "The colloidal gold reaction does not in any sense replace other cerebrospinal fluid tests of known value. In certain instances it seems to possess a sensitiveness and specificity shared by none of the others. Its sources of error are few and are easily recognized; its results are for the most part clear cut and decisive; its performance requires a minimal amount of spinal fluid and a technique of extreme simplicity."

JOURNAL OF THE AMERICAN MEDICAL ASSOCIATION.

(Jan. 1, 1916, lxvi, No. 1.)

Abstracted by Wm. H. Baughman, M.D.

OCCUPATIONAL INJURIES DUE TO RADIUM: REPORT OF CASES. T. Ordway, p. 1.

The cases reported are of persons engaged in the handling of radium for therapeutic or other purposes. The onset was either acute or chronic. The most prominent sensory disturbances were blunting of the sensibility of the finger-tips, tenderness on pressure, hyperæsthesia, increased sensitiveness to heat, paræsthesia, unnatural feeling of finger-tips, and difficulty in delicate manipulation. These symptoms were pronounced, persistent, and out of proportion to objective manifestations. The surfaces of the fingers were smooth and shining, with flattening and obliteration of the ridges; the epidermis was thickened, dry and parchment-like, wrinkled, cracked, scaling; persistent pitting followed pressure; the nails were extremely brittle and stood away from the fingers, because of a marked tendency to an upgrowth of tissue beneath the nails. A determination of the "sensory threshold" was made, which showed that the radiated fingers were much less insensitive than the normal ones. A table is given, showing the changes in the blood of each case.

HYPERTRICHOSIS, VARIATIONS IN FEMALE SECONDARY SEXUAL CHARACTERISTICS, AND INTERNAL SECRETIONS. G. R. McAuliff, p. 15.

From a consideration of many theories and results of investigations, the author concludes that the basis of marked variations in sex characteristics "must be some profound and complex disturbance of the antagonistic and synergistic pluriglandular equilibrium."

INTRAMUSCULAR INJECTIONS OF WHOLE BLOOD IN THE TREATMENT OF PURPURA HÆMORRHAGICA. H. W. Emsheimer, p. 20.

The case was that of a young boy suffering with purpura hæmorrhagica and marked hæmaturia. Seventeen days after the condition first appeared, and when none of the many usual remedies had proved of benefit, 20 cc. of blood from a relative were injected intramuscularly, into the buttock, by means of a syringe coated with sterile petrolatum. The blood was injected immediately after being withdrawn and before any clotting had taken place. No undesirable effects were noted. Twelve hours after the injection, the urine was much lighter in color; four hours later, it was clear, a few red cells being found microscopically. Later in the day, it became somewhat smoky, but the following day it became clear again and remained so. The purpuric lesions rapidly disappeared; a few new ones occasionally appeared. Six weeks after the injection, all evidences of the condition had disappeared.

PROTEOLYTIC FERMENTS OF THE BLOOD SERUM IN TABES DORSALIS AND GENERAL PARESIS. F. H. Falls, p. 22.

Following the Abderhalden technique closely and using human placental tissue as substrate, Falls' investigations apparently indicate that, in both tabes dor-

salis and general paresis, the ferment activity of the blood is increased, the reactions in cases of tabes being relatively weaker than in cases of general paresis. The reactions in certain of the cases of general paresis were as strong as in some of the cases of pregnancy tested.

(*Ibidem*, Jan. 8, 1916, lxvi, No. 2.

THE INCIDENCE OF SYPHILIS AMONG JUVENILE DELINQUENTS: ITS RELATION TO MENTAL STATUS. T. H. HAINES, p. 102.

THE ANATOMIC DISTRIBUTION OF CUTANEOUS NEOPLASMS. F. T. VANBEUREN, JR., p. 111.

Approximately two-thirds of the epitheliomas were from the neck and head; all of those from the lip and nearly all from the hand were of the squamous-cell type, eleven of the thirteen from the nose were of the basal-cell type; neither type predominated among those from the forehead, scalp and cheek.

The sarcomas were quite evenly distributed, the melanosarcomas being most frequently located on the lower extremities. Pigmented moles, removed possibly for cosmetic reasons, were generally from the head and neck. Fibromas and angiomas showed an apparent preference for the head, neck and upper extremities. Seventy-five per cent. of the papillomas were from the unclothed surfaces of the body.

(*Ibidem*, Jan. 15, 1916, lxvi, No. 3.)

CREEPING ERUPTION (LARVA MIGRANS) OF THE SKIN, PARTICULARLY IN REGARD TO ITS HISTOLOGIC FEATURES, INCLUDING THE DEMONSTRATION OF THE BURROW AND THE LARVA IN THE EPIDERMIS. F. C. KNOWLES, p. 172.

A case of this rare parasitic infection was carefully investigated by Knowles. Tissue containing three distinct burrows was excised and cut serially, various stains were employed to bring out the different features. The burrow, unlike those of the Acarus scabeii, were located in the lower part of the horny layer at its junction with the rete, and also in the upper portion of the rete Malpighii. The parasites were demonstrated in sections of each of the burrows, this being the first recorded instance in which this has been done, though the parasite had been discovered by other investigators.

TRICHOKYPTOMANIA. R. L. SUTTON, p. 185.

An interesting case, classed as one of the neurodermatoses, which occurred in a girl of nervous temperament, aged 18 years. Irregular patches of baldness, involving the eye-brows and eye-lashes, and parietal and postauricular regions, were noted; the hair shafts, in these places, were short and stiff, the distal extremities of many being jagged or split; others were broken squarely across as if they had been cut. The hair, in other localities, showed no parasitic or trophic disorder. The patient finally demonstrated that by twisting one or two hairs into the form of a small figure 8, and then sweeping them across the sharp edge of the finger-nail, they could be broken off short without epilating them. Psychotherapy produced an appreciable progress toward recovery.

(*Ibidem*, Jan. 22, 1916, lxvi, No. 4.)

ANAPHYLACTIC FOOD REACTIONS IN DERMATOLOGY: PRELIMINARY REPORT. A. STRICKLER AND J. M. GOLDBERG, p. 249.

DRAINAGE OF CEREBROSPINAL FLUID AS A FACTOR IN THE TREATMENT OF NERVOUS SYPHILIS. S. F. GILPIN AND T. B. EARLY, p. 260.

If the theory is held that substances circulating in the blood do not pass by osmosis into the cerebrospinal fluid, because the pressure of the cerebrospinal fluid equals that of the blood in the venous sinuses and capillaries, why then should not substances osmose through, if the blood is saturated with them and the cerebrospinal fluid is simultaneosuly reduced? Working with this theory in mind, the authors placed three patients, suffering respectively with early paresis, taboparesis and tabes dorsalis, under treatment with inunctions of mercury. From 20 to 40 cc. of spinal fluid were drained off from each patient, once a week if possible, one patient being drained fourteen times. Clinically, marked improvement was noted in the mental and the physical conditions, with lessening of the ataxic symptoms, but there was no improvement in either the knee-jerk or the pupillary reactions. From the laboratory standpoint, an improvement was also shown in that the number of cells in the cerebrospinal fluid was reduced. The globulin, in all cases, remained positive. The Wassermann reaction in the patient with taboparesis remained positive; in the patient with tabes dorsalis, it became negative. The article is presented as a preliminary report only.

PURPURA HÆMORRHAGICA (MORBUS MACULOSUS WERLHOFII): REPORT OF A FATAL CASE OF UNKNOWN ORIGIN. P. M. KELLOGG, p. 271.

BOSTON MEDICAL AND SURGICAL JOURNAL.

(Apr. 20, 1916, clxxiv, No. 16.)

Abstracted by OSCAR L. LEVIN, M.D.

PELLAGRA: A REVIEW OF THE SUBJECT, WITH REPORT OF A CASE. CHARLES A. HOWLAND, p. 563.

(*Ibidem*, Apr. 27, 1916, No. 17.)

CEREBRAL SYPHILIS: A METHOD OF TREATMENT BY PROLONGED INTRASPINAL INJECTION OF SERUM UNDER HIGH PRESSURE. JAMES B. AYER, p. 614.

Moderate amounts of fluids injected intraspinally under normal pressure reach no higher than the medulla. Cerebral lesions are, therefore, less influenced by intraspinal treatment than are diseases of the cord. To insure the intro-

duction of drugs into the perivascular spaces and tissue of the brain, the author suggests the intraspinal injection of large amounts of fluid under high pressure, for a long period of time.

Three patients were injected intraspinally with 20 to 30 cc. of full strength diarsenolized serum, followed by 70 to 160 cc. of normal saline solution. The spinal fluid pressure (150 mm. to 190 mm.) gradually increased (450 mm. to 550 mm.) as the solutions were slowly injected (40 to 105 minutes). In two of the patients, diluted serum was obtained by puncture of the subarachnoid space over the frontal lobes, after the injections.

NEW YORK STATE MEDICAL JOURNAL.

(Apr., 1916, xvi, No. 4.)

Abstracted by Oscar L. Levin, M.D.

THE TREATMENT OF SYPHILIS IN THE SECONDARY STAGE. Sigmund Pollitzer, p. 181.

Patients suffering from secondary lues are subjected to energetic treatment, consisting of courses of frequently repeated injections of salvarsan and mercury salicylate. The remains of the chancre is excised, if its site permits its removal.

In the early cases a preliminary intramuscular injection of mercury is followed, in two days, by an intravenous injection of 0.4 gm. of salvarsan, and after two more days, by 0.5 gm. of salvarsan. The salvarsan injections are then administered at intervals of three or four days, until five have been given. Subsequently the patient receives ten weekly mercury injections, in doses of two to three grains. Several patients thus treated have remained under observation for more than three years and show clinical and laboratory cures.

Syphilitics in the later stage of this period receive a course of five weekly salvarsan and ten weekly mercury injections, followed by courses of three weekly salvarsan and eight weekly mercury injections, at intervals of two to three months, for a period of two years. Wassermann tests are made systematically, but the plan of treatment is completed whether the reaction is negative or positive.

Salvarsan should be administered promptly in cases with acoustic or optic nerve affections, and repeated immediately if the lesions develop after a first injection of salvarsan. In syphilitic involvement of the vocal cords a course of mercury should precede the administration of salvarsan, to prevent a Herxheimer reaction and a possible œedema of the glottis. Small doses of salvarsan should be used when visceral lesions exist. A course of mercury should precede the salvarsan when the liver is enlarged, and it is safer to omit the salvarsan when icterus is present. Small doses of salvarsan may be given when there is a trace of albumin and a few casts in the urine. In the presence of meningeal symptoms it is advisable to give a small hypodermatic dose of adrenalin, ten minutes before the salvarsan.

THE HEART IN SYPHILIS. Harlow Brooks, p. 185.

The heart is involved early in the disease. The myocardium in the neighbor-

hood of the coronary terminals is most frequently affected and the occurrence of dyspnœa, cyanosis, vague precordial pains and occasional marked retrosternal tenderness in the secondary stage suggest syphilitic myocarditis. The diagnosis of syphilitic heart disease after the secondary stage, is made by finding signs and symptoms of heart disease associated with stigmata of lues in other parts of the body and a positive Wassermann reaction.

The treatment of syphilis of the heart consists in the administration of combined courses of mercury and salvarsan. Iodides assist in the removal of deposits and the restoration of normal function. Clinical cures may be expected in early cases by employing specific treatment alone. In advanced cases, however, it may be necessary to use cardiac drugs subsequent to the specific medication.

PELLAGRA. G. Kirby Collier, p. 195.

Description of the disease. Report of a case.

JOURNAL OF LABORATORY AND CLINICAL MEDICINE.

(Apr. 1916, i, No. 7.)

Abstracted by Oscar L. Levin, M.D.

THE TREATMENT OF SYPHILIS OF THE CENTRAL NERVOUS SYSTEM. Henry G. Pamment, p. 498.

The author concludes that patients with syphilis of the central nervous system should be given the benefit of intradural therapy. He believes that mercurialized serum is a good substitute for salvarsanized serum.

PROCEEDINGS OF THE ROYAL SOCIETY OF MEDICINE. DERMATOLOGICAL SECTION.

(February, 1916, ix, No. 4.)

Abstracted by Frederick T. Lau, M.D.

THREE CASES OF SYPHILIS TREATED BY "INTRAMINE" (DI-ORTHO-AMINO-THIO-BENZINE). J. E. R. McDonagh and H. Spence, p. 51.

The authors present three cases of syphilis which have been treated with a non-metallic compound which contains no arsenic. After an exhaustive biochemical investigation, they conclude that intramine should be prescribed first in recurrent and late syphilis, and a metallic compound afterwards, while in early syphilis, a metallic compound should precede the intramine. They have also found that if intramine is prescribed before a metallic compound in early syphilis, it may occasionally result in a Herxheimer reaction. The authors hope to show, in the future, cases that have been treated with metallic compounds which contain no arsenic. They have already prepared some strongly

adsorbed compounds of aluminium and iron, which they think will replace the arsenical compounds altogether. This is a very interesting symposium, and should be read in detail by those interested in the treatment of syphilis.

The cases presented were:

Case 1. Patient, aged 70 years, contracted syphilis in 1866. Eighteen months ago, he had two intravenous salvarsans, followed by three courses of mercurial injections and iodides, which produced no improvement in his condition. At the beginning of the present treatment, the patient presented an ulcer, the size of a dime, on the dorsum of the tongue, with two fissures running laterally from it. Behind the ulcer was a wart about the size of a small cherry. The movements of the tongue were restricted, and the patient suffered considerable pain and discomfort.

On November 6th, 1915, the patient was given 1 gm. of intramine, intramuscularly. On the third day after the administration of the intramine, the tongue began to improve, and two weeks later the ulcer had closed, the fissures had disappeared and the wart was considerably smaller. Two months after the injection, the tongue had become soft and mobile, the wart had nearly disappeared, and the patient suffered no pain or discomfort.

Case 2. Patient, aged 42 years, contracted syphilis in 1898, and had intermittent treatment during the following four years. Upon admission, the upper lip and central half of the beard region were dull red and inflamed, were now scarred, and in places ulcerated; some bullous lesions were found on the right thigh, and a chronic laryngitis rendered him exceedingly hoarse.

On December 22nd, he was given 0.4 gm. galyl, and on December 24th, 1.5 gm. intramine, intramuscularly. Six days later, a considerable improvement in the condition of the face and also of the thigh was apparent, the redness of the face being distinctly lessened and the ulcerated lesions smaller and closed. On the eighth day all lesions were closed with the exception of a nummular area on the central part of the upper lip, which, on January 20th, had been healed a week. He has had two further injections of galyl, each 0.4 gm., on January 4th, and January 11th, respectively.

Case 3. Patient, aged 28 years, presented a clinical picture of congenital lues. He furnished a history of exposure in the latter part of August, 1915, followed, in four or five weeks, by a "white pimple," which he scratched, the ulceration then spreading around the sulcus to the extent of one-quarter the circumference of the penis. The penile lesion was diagnosed as a recurrent syphilide.

On November 30th, 0.35 gm. galyl was given, and on December 2nd, 2 gms. of intramine. Two days later, the patient developed acute lobar pneumonia, the crisis occurring on the third day of the disease. Meanwhile the lesion in the sulcus had greatly improved and upon discharge from the hospital (December 29th) had practically closed.

CASE OF VERY EXTENSIVE TINEA CIRCINATA OF TROPICAL ORIGIN. E. G. G. Little, p. 55.

The patient is a soldier who has spent some time in West Africa. He has had gonorrhœa but not syphilis, and the Wassermann test is negative. The eruption, which began in the groin last September, has spread, and at the time of this report the greater part of the body, except the hair and nails, is involved. The fungus has been identified in scales taken from several parts of the body. An unsuccessful attempt has been made to grow the same on a Sabouraud medium. The author suggests the Epidermophyton inguinale as a possible organism.

CASE OF CHRONIC ULCERATION IN A BOY. (Shown at the October Meeting.) E. G. G. LITTLE, p. 56.

This is a further report in detail, showing remarkable results with vaccine therapy. Autogenous vaccine, made from organisms from the lesions, as well as those found in blood cultures, has been used in conjunction with local treatment.

NOTE ON A CASE SHOWN FOR DIAGNOSIS. (Indian Medical Student with an Eruption Suggested by Several Members to be Tuberculous.) E. G. G. LITTLE, p. 61.

The largest tumor, removed from the forehead, has been divided into two parts, and one part used for inoculation into a guinea pig and the other part submitted to Dr. Spilsbury for report. The guinea pig has shown no symptoms of inflammation at the site of inoculation, and has now been killed and an autopsy made, five weeks after inoculation. Dr. Colebrook reports that there were no signs of tuberculous infection. As the disease, if tuberculous, was clinically of the nature of acute lupus, failure to infect the guinea pig was, as far as it went, a negative finding for the diagnosis of tubercle. Dr. Spilsbury reports, with reference to the section of the tumor, that it is quite unlike tuberculous tissue, and that he conceived the possibility of leprosy; but sections stained for bacilli did not reveal the presence of any organism. The diagnosis at present offered is simply that of a granuloma of unknown causation.

SO-CALLED IDIOPATHIC MULTIPLE PIGMENT SARCOMA OF KAPOSI (ACRO-SARCOMA MULTIPLEX CUTANEUM TELEANGIECTODES OF UNNA). F. PARKES WEBER, p. 62.

This patient, a Galician Jew, was shown before the Dermatological Society of London, on February 8th, 1905. At that time, he was aged 46 years, and presented the typical bluish nodules in the skin of the right foot, the left lower extremity, the hands and the penis. In some of these parts there were small sessile or pedunculated outgrowths. There was also considerable chronic œdema of the left foot and ankle. The illness was at that time of about three years' duration, and the prognosis seemed to be not altogether unfavorable.

The patient was for a time treated with arsenic, and for a time externally with lead lotion, but for the last four years, he has had no treatment at all. He is now aged 59 years, and looks well and active. There is moderate œdema of both legs. The left lower extremity is still the more affected of the two. There are brown-red and purple patches on the feet and (much less) on the legs. On the feet and legs there are a few small, dark-colored, hard cutaneous nodules, and there are a few on the thighs and glans penis, and one or two minute, bluish nodules on the hands. There are now not any of the small pedunculated tumors. There is no evidence of any visceral disease, and the urine is free from albumin and sugar.

CASE OF TERTIARY SYPHILIDE. G. WARD, p. 63.

The patient, a male, aged 37 years, had a primary sore sixteen years ago, and the present rash appeared at or about the same time. It has never caused any trouble or interfered with his work. It has been treated on different occasions as a syphilide, but without improvement. The eruption has never given rise to irritation, and is markedly better in winter and worse in summer. There has

been no itching at any time. There is no eosinophilia. The general health is not affected, and there is no history of any change in the type of the disease.

The lesions are most typical on the back (several illustrations), and consist of papules with scaly tops at the periphery and pigmented patches, more centrally. These papules are, in some cases, surmounted by flat, yellow vesicles, which dry quickly, leaving scales. Fluid from small bullæ shows only degenerated leucocytes and staphylococci. Scales show many clusters of yeast-like organisms, but no mycelium.

This case is shown to elicit answers to the questions: (1) What is the diagnosis? (2) Is this man fit for general military service?

Remarks by the president confirmed the diagnosis and suggested intravenous galyl and intramuscular mercury, at intervals. He also expressed his belief in the man's fitness for labor.

CASE FOR DIAGNOSIS. S. E. Dore, p. 65.

The patient is a male, aged 40 years, who has just come from a military hospital in France. The affection began six weeks ago, on the right hand, with an eruption of papulo-vesicles, which subsequently became bullous, and the dorsal surface is now covered with bullæ and excoriations. A week ago the left hand and elbows and knees became affected in a similar manner, the lesions becoming bullous, and three days later the eruption began to appear in the form of erythematous patches on the feet. The author believes the case to be a streptococcic impetigo, but that some characteristic patches on the feet suggest erythema multiforme.

In the discussion, Streptococcus and Staphylococcus albus infections were suggested, also septic pemphigus.

SCLERODERMIA WITH GRAVES' DISEASE. J. H. Sequeira, p. 66.

This case is shown as a contrast to the myxœdematous patient exhibited at the last meeting, in whom sclerodermia developed while taking thyroid extract.

The patient, a female, aged 22 years, shows a typical Graves' disease with areas of sclerodermia across the left clavicle, over the right side, in the middle of the sternum, two oval patches on the back and a few small areas over both trochanters.

Dr. Travers Smith reported a whole family with these two conditions.

Dr. F. Parkes Weber remarked that the occasional association of sclerodermia and Graves' disease suggests that there can be only an indirect connection between myxœdema and sclerodermia.

Dr. A. Eddowes suggested that this case illustrates the frequency of sclerodermia beginning over the left clavicle.

NEW YORK MEDICAL JOURNAL.

(Apr. 29, 1916, ciii, No. 18.)

Abstracted by James F. Grattan, M.D.

SYPHILIS IN EPILEPSY. W. T. Shanahan, J. F. Munson and A. L. Shaw, p. 820.

The authors believe that syphilis as a cause of epilepsy has been much overrated. From the study of a large number of epileptics at the Craig Colony, they find that the percentage occurrence of syphilis as determined by the Wassermann blood test, is about two per cent.—practically the same as in the general community. They maintain that an epileptic with syphilis is not necessarily a syphilitic epileptic, and that the condition called syphilitic epilepsy is not a clinical entity, since syphilis can be regarded only as one of the many agencies producing the disorder.

(*Ibidem*, May 6, 1916, ciii, No. 19.)

THE TREATMENT OF CARDIAC SYPHILIS. J. M. Anders, p. 865.

The root and ascending arch of the aorta is a site of predilection for the spirochæte. Longcope believes that the infection occurs during the second stage, but the symptoms referable to the lesions do not occur, as a rule, until the tertiary stage, the average period being sixteen to seventeen years. In a few cases the symptoms developed several months after the infection. The most important cardiac lesion is involvement of the myocardium, which is dependent upon periarteritis of the coronary vessels. The spirochæte was demonstrated in these lesions by Warthin and confirmed by Wright. Longcope has determined, by autopsies and the Wassermann reaction, that 75% of aortic insufficiency cases are due to syphilitic aortitis. As curative treatment cannot be successful when the lesion with its symptoms has been established, vigorous medication, with a view to prophylaxis, is the logical and necessary course in the early stages. The author makes a vigorous appeal to the profession to adopt this as the only means of preventing the invasion of the myocardium by the organism. Salvarsan, a powerful weapon in the early stages of the disease, is very dangerous when the myocardial lesions have developed. The author believes that the sudden deaths following the use of salvarsan or neosalvarsan are due to the presence of myocardial lesions. In a clinical study of 288 cases of secondary syphilis by Gassman, 85% showed disturbances of rate and rhythm of the pulse, while 40% had murmurs, usually accompanied with dilatation. In reference to this type, the writer suggests treatment with mercury salicylate, by deep injection, pushed to tolerance, to be followed by salvarsan intramuscularly. After a few days the mercury is to be resumed. In the less active cases the protiodide, by mouth, may be used. The combined treatment is much more effective than either drug used alone. The only reliable method of determining efficiency of treatment is the establishment and maintenance of a negative Wassermann reaction. A negative Wassermann may mean the presence of too few spirochætæ, to produce antibodies. Therefore it may be desirable, in some cases, to continue the use of mercury for one year, to be sure of eradication. Unusual tolerance to mercury may necessitate further use of salvarsan, to render the Wassermann negative. The cases seen in the tertiary stages are usually the old cases of aortic regurgitation with decompensation. Complete rest, digitalis and hygienic measures are to be used as in non-syphilitic cases. The effect of these measures is usually unsatisfactory. Salvarsan is used if mercury by inunction and deep injection does not yield a negative Wassermann. The intramuscular method is effective and safe, while the intravenous method is extremely hazardous and may cause sudden death. Neosalvarsan causes less pain and fewer general after-effects than salvarsan. If mercury, followed by one of the arsenic preparations, fails to render the Wassermann negative, a follow-up course of mercury should be used. After the active symptoms have been checked, the iodides should be used, preferably potassium, beginning with

a five-grain dose and working up to ten or fifteen grains, according to tolerance, three times a day, with or without the second course of mercury. The ultimate prognosis in these cardiac cases of the tertiary stage is unfavorable, but many show a decrease in distressing symptoms, and their lives may be prolonged, in a state of comparative comfort, as a result of the treatment suggested.

(*Ibidem*, May 27, 1916, ciii, No. 22.)

ADDISON'S DISEASE OF SYPHILITIC ORIGIN. P. M. SCHAFFNER AND T. HOWARD, p. 1026.

This paper describes a case with general pigmentation, low blood pressure (98-80) and a positive blood Wassermann. There is also a suspicion of pulmonary tuberculosis, but bacilli have not been found. Antisyphilitic treatment, consisting of four salvarsan injections and thirty injections of mercury salicylate, resulted in fading of the pigmentation and an increase in blood pressure to 138-95. After these symptoms of adrenal insufficiency had disappeared, the patient was given one to three grains of desiccated adrenal gland, three times a day. At the time of writing, all signs of Addison's disease had practically disappeared.

MEDICAL RECORD.

(May 6, 1916, lxxxix, No. 19.)

Abstracted by JAMES F. GRATTAN, M.D.

THE CAUSATION AND TREATMENT OF PELLAGRA. H. E. BOND, p. 816.

The author advances the theory that pellagra is caused by (1), gastro-intestinal intoxication; (2), actinic rays of the sun. He shows the anatomic relations of the sympathetic and central nervous symptoms, and suggests that the toxines eventually affect the central nervous system through the sympathetic system. The chromophile system is affected. The chromophilic cells of the nervous system lose their staining properties and the pigment is dislocated. Similar alterations take place in the cells of the semilunar ganglia of the sympathetic, as well as in the posterior root ganglia. McNeil is quoted as showing chemical and bacteriological changes in the fæces. Indol and skatol are present in abnormal amounts, give a marked aromatic odor and there is an increase in the numbers and varieties of the bacteria.

The actinic rays of the sun are potent as an irritant to the dermal lesions and increase their severity.

For treatment, intestinal disinfection by the use of calomel, beta-naphthol, acetozone and salol is recommended. Locally, an ointment of beta-naphthol, balsam of Peru and zinc ointment is used. When the bullæ have burst, tar, salicylic acid, ammoniated mercury and zinc ointment are applied to the raw surfaces. For diet, a well balanced diet containing ripe bananas and papaws, is best. To prevent aggravation of the lesions, the patient must be kept out of the sun's rays.

OBITUARY.

ALBERT NEISSER, M.D.

SCIENCE disowns nationalism, and the loss of Albert Neisser is the world's even more than his country's. In an epoch in which many lives of promise are severed by an untimely garnerer, there is something of consolation in beholding Death stand by until the twilight of stalwart old age shall have enveloped a life rich in accomplishment. This mellow end has been Neisser's and now he, with Ehrlich and Metchnikoff, is a memory we may revere as he had been a living power we all admired.

Dermatology to him was medicine, and medicine to him had that far-flung horizon which it is for the vision of but few to encompass. His achievements were of the kind which elucidated, clarified and laid foundations upon which posterity would be able to rear a solid edifice. The labor of his early days led to the discovery of the gonococcus, and this swept away the doctrine of the trinitarians, as Ducrey's discovery, ten years later, proved. His riper age was devoted to exploring the great field of syphilis. Here he ranked with Hunter, Wassermann, Fournier, Schaudinn and Ehrlich. He was the last of the Olympians. His share in the studies of complement fixation as applied to syphilis was scarcely less than Wassermann's. It was to his efforts, even more than to those of Metchnikoff and Roux, that the susceptibility of primates to syphilis was proved,—a fact, the importance of which to the scientific study of the disease, is beyond present estimation. The monograph upon his investigations in the East Indies, the ingenuity and resourcefulness of the former, have a magnitude which is truly overwhelming.

His lesser labors alone would have won him undying distinction. There is no phase of dermatology upon which he failed to turn the rays of a luminous mind. His atlas attests to his clinical prowess, and he was one of the great cutaneous histopathologists. Adequately to tell his story would be in a large measure to recount that of dermatology during the last four decades. Such was his power that in quality he established Breslau as a more serious dermatological center than Vienna, and the august Teuton traditions passed from Austria to Germany, there to remain until today. It was not a part of his genius to compile as Kaposi did, but to elucidate. He was not only a visualist but a critic and thinker. His dermatology did not end in the retina. It merely began there.

In Breslau, he gathered about him, as years went by, a great circle of ardent pupils, of whom many have gone forth into other parts, quickened by their master's inspiration. Thus Neisser's school has flourished vigorously. His most notable apostle, perhaps, is Jadassohn, and Jadassohn through his scientific bonds with Darier, has been the personal means of bringing the influence of Breslau into France. Originally the great medium of expression of this coterie was the *Archiv für Dermatologie und Syphilis.* As this periodical developed in excellence, it increased in power and geographical scope, so that when the present war broke out, it had become the important dermatological journal of all of Europe east of the Rhine to the Urals, and south to the Mediterranean. It was Neisser's influence more than that of any one other man which made this possible. Scientifically he was a force rather than an individual.

W. J. H.

BOOK REVIEWS.

CANCER OF THE SKIN. HENRY H. HAZEN, M.D., Washington, D. C. Cancer Series Pamphlet, No. IV. Issued by the Council on Health and Public Instruction of the American Medical Association.

The author covers the subject in a remarkably clear and concise manner, no easy task for the medical man when writing for "lay" readers.

His appeal to the public not to patronize the "quacks" and his criticisms of the lay press for their cancer advertisements are bitter reminders to us of those cases that come too late to be saved.

Dr. Hazen points out that 90% of all early skin cancers can be cured, and if the patients but consulted the proper authorities at the slightest evidence of any abnormality of the skin, the incidence and the ravages of the disease could be reduced to a minimum.

He advocates surgery, Roentgen-ray and radium as the best means of treatment, giving the indications for their use, mentioning in regard to the last, that the vast majority of skin cancers have not been permanently cured by its use.

E. W. A.

TREASURY DEPARTMENT. UNITED STATES PUBLIC HEALTH SERVICE. HYGIENIC LABORATORY BULLETIN. No. 103, February, 1916.

CHEMICAL CHANGES IN THE CENTRAL NERVOUS SYSTEM IN PELLAGRA. BY MATHILDA L. KOCH AND CARL VOEGTLIN.

This "Arbeit" merits the highest praise as an example of a clear, direct and thorough piece of work.

Additional scientific evidence is furnished that pellagra is a dietary disease. Monkeys fed by the authors on a restricted vegetable diet, developed lesions in the central nervous system, practically identical with those that occur in the nervous system of human pellagrins.

They recall the fact that the spinal cord shows most of the pathological changes, as evidenced by a degeneration of its columns, principally the lateral, and they find, by their investigations, that the most striking chemical changes occur in this part of the central nervous system.

Of the various chemical constituents, the lipoids and proteins show a loss, while the extractives and the water show an increase in their contents.

E. W. A.

THE JOURNAL OF
CUTANEOUS DISEASES

Vol. XXXIV OCTOBER, 1916 No. 10

ORIGINAL COMMUNICATIONS.

SYPHILIS OF THE NERVOUS SYSTEM.*†

By John A. Fordyce, M.D., New York.

Professor of Dermatology and Syphilology, College of Physicians and Surgeons, Columbia University, New York.

The number of patients who show involvement of the spinal fluid in the secondary period of syphilis bears a certain relation to the total percentage of cases with lues of the nervous system. In a series of cases of secondary syphilis examined in my hospital service two years ago, less than 20% revealed abnormalities in the spinal fluid. Recently another series of 63 cases were punctured; 10 showed very slight changes as to lymphocytosis and globulin content, coming well within the borderline cases, while 15 exhibited a definite increase in cells and globulin, with a positive Wassermann reaction in 7. Thus 25% of the cases gave evidence of a definite pathological condition of the cerebrospinal axis, while 16% showed trifling abnormalities. The significance of the latter we are not prepared at this time to state, but it may be assumed that they are only transient and part of the systemic affection.

* Read before the 40th Annual Meeting of the American Dermatological Association, Washington, May 8-10, 1916.

† Published simultaneously in the *Medical Record* for Sept. 30, 1916.

The standard used was a cell count over 5, a globulin content demonstrated by the Pandy test, a positive Wassermann reaction in amounts to 2.0 cc. of fluid and the color changes elicited by the Lange test. Statistics in the literature, treating of abnormal fluids in the secondary stage of lues, are variously quoted at from 10 to 90%. In criticism of this disparity, it is possible that too much significance has been attached to minor changes, as increased pressure, increase of a few cells or a trace of globulin. My belief is that only such individuals who show very conspicuous changes as evidenced by a definite cell count, globulin and positive Wassermann, are candidates for one or the other of the different clinical types of cerebrospinal syphilis, and that in a large majority of patients the spirochætæ must be destroyed spontaneously or by therapeutic agents administered in the ordinary way. It is said that from 9 to 25% of all syphilitics develop disease of the nervous system. These figures have little value at present as they were compiled before the era of laboratory diagnosis, and must be revised on the basis of more exact data. With our modern aids to diagnosis we are in a position not only to differentiate the specific from the non-specific types of disease, but also to make the diagnosis of syphilis in many cases that would otherwise go unrecognized.

Our greatest hope in the cure of syphilis of the nervous system lies in the adequate handling of the infection in its early inception. In other words, it must be prophylactic. Failing this, too great stress cannot be laid upon the early recognition of signs or symptoms which point to involvement of the cerebrospinal axis. The syphilographer and dermatologist, by contact with cases of secondary syphilis, are in a position to discover the earliest clinical signs of involvement, such as irregularity of the pupils and irresponsiveness to light, exaggeration of the knee jerks, headache, auditory and ocular defects, or oculo-motor paralyses. These are all positive indications for lumbar puncture. If dermatologists and genito-urinary surgeons were familiar with the earlier manifestations of nerve involvement, they would uncover many cases of nervous syphilis against which a therapeutic attack could be made and the patient rendered secure from future degenerative changes.

The treatment in the early active stage must be intensive and systematic and should consist of a combination of salvarsan and mercury, for we have learned that salvarsan alone is apt to be followed by neuro-recurrences. It has also been shown that in patients inadequately treated, a pleocytosis, marked increase of globulin and a strongly positive Wassermann reaction, may be present without evincing any sub-

jective discomfort, the condition remaining latent for years, until symptoms of tabes or paresis make their appearance. When these cases are clinically developed, irreparable damage has already been done to the nerve tissue. It is, therefore, incumbent upon the syphilographer to treat the fresh infection energetically, and wherever practicable to examine the spinal fluid at the completion of the treatment or, in the absence of physical signs, after a provocative injection of salvarsan, which should be given one year after the Wassermann reaction has been continuously negative.

In the treatment of luetic affections of the nervous system, it is important to properly instruct patients that the procedure is a long drawn out one, and unless they are willing to place themselves under the care of a physician for one or two years, it is hardly worth while to undertake it. It is true that the progress of certain types can be arrested by intravenous therapy alone, combined with mercury and potassium iodide. I have had under observation for the past five years, cases of cerebrospinal syphilis of the basilar meningo-vascular type where salvarsan was administered only intravenously and the fluid findings have become negative, the symptoms have disappeared and there has been no relapse. In a few cases of tabes and optic atrophy the condition has been brought to a standstill, and even shown marked improvement. This method, however, is inadequate for the great majority of sufferers, for I have repeatedly seen patients who have had 10 to 15 intravenous injections of salvarsan with the prolonged use of mercury and potassium iodide, with little or no change in the fluid findings or clinical symptoms. After a course of subdural injections both symptoms and serological findings greatly improved.

In outlining the course to be pursued I have found the best procedure to be the following:

In patients with a negative blood and a positive fluid a provocative injection of salvarsan should be administered and the Wassermann reaction taken at stated intervals. If it remains negative, subarachnoid treatments may be begun at once. When both blood and fluid are positive two or more injections of mercury should precede the intravenous administration of salvarsan, and after two or three doses of the latter, the intraspinal injections instituted, supplemented by the intravenous. In paresis my usual practice is to begin the intraspinal injections after the first intravenous treatment. The intervals between doses, and this applies to both routes of introduction, are regulated by the reaction produced in the patient. Where subdural injections are well borne, they may be given in series of four to six, one to two weeks apart, with a rest

period of four to six weeks, and then another course. Frequently tabetics are met with, in whom intraspinal medication cannot be repeated oftener than once a month.

Since the introduction of the intraspinal method, in 1912, by Swift and Ellis, we have treated in my private work and at the Vanderbilt Clinic. 110 cases of tabes, 13 of taboparesis, 12 of optic atrophy, 25 of paresis. and 20 cases of other types of cerebrospinal syphilis. At first the original method of Swift and Ellis, namely, the use of auto-salvarsanized serum, was adhered to; for the past two years, the modification of Ogilvie, with the direct addition of salvarsan to the blood serum. In the earlier work it soon became apparent that salvarsan in quantities of one, two or three milligrams often acted as an irritant and caused traumatic irritation of the lower cord, which manifested itself in bladder paralysis, numbness of the gluteal region and extremities, with an increase in the ataxic state. Some patients bore these large amounts of the drug without apparent injury, and even marked improvement in their symptoms, but we felt that the risk was too great to justify their continuance. The method, however, seemed a logical one, and if a therapeutic quantity of the drug could be used which would accomplish the desired result short of an irritating effect, it was well worth a thorough trial. The reasons for employing this technique instead of the auto-salvarsanized serum recommended by Swift and Ellis were, first, that a definite quantity of salvarsan can be introduced and the dose more easily controlled; second, the addition of a definite amount of the drug with a smaller quantity of serum, and third, the possibility of preparing several doses with the blood serum removed from a single patient. The last is of decided advantage in treating a large number of hospital patients. Then, too, the intraspinal injections often have to be repeated more frequently than the intravenous injection, and in cases with a negative serum there is no indication for the latter. Experience has shown that the blood serum removed indifferently from patients acts equally as well as the autogenous serum. The most important step in the technique, besides absolute asepsis, is the use of a salvarsan solution which is nearly neutral. The blood is removed from an arm vein and is centrifugalized, the serum pipetted off and then centrifugalized again to insure complete removal of any red cells. To 8 to 10 cc. of this serum, 1/20 to 1/2 mg. of salvarsan, according to indications, is added. This mixture is incubated at 37° C. for 40 minutes and inactivated at 56° C. for one half hour.

As to dosage, patients with general paresis tolerate larger doses than

those suffering from tabes or other forms of cerebrospinal syphilis. For tabetics the initial dose should be 1/20 to 1/10 milligram, depending on the bladder involvement and the amount of pain present. The quantity is gradually increased; in some patients never exceeding the dosage of 1/10 milligram; in others, 1/5 or 1/3 milligram may be injected without producing much discomfort. The intervals depend upon the reaction and vary from ten days to a month. In paretics the primary dose may be 1/4 milligram, running up to 1/2 milligram and repeated at intervals of a week to ten days, to two or three weeks. In patients in whom the cord is not involved, weekly injections of 1/4 milligram have not produced any iritative symptoms. There is apparently no limit to the number of injections that can be given. An activation of the lesions after the first injection is not a contraindication to the use of the drug but calls for care.

The reactions incident to the treatment of nervous syphilis fall under two headings: (a) Those dependent upon the intravenous injection and (b) those occurring after intraspinal medication. The majority of patients, providing small initial doses are given, preceded by two or three injections of mercury, are able to take the intravenous treatment without bad effects. Cases are met with, from time to time, however, who from the first do not support it well even in small doses. They become actively ill an hour or two after treatment, with chill and vomiting, and complain of malaise for the next day or two. A woman with paresis and a man with tabes under observation had this type of reaction each time they were treated. A reaction of an anaphylactoid nature, characterized by flushing of the face, rapid breathing with cardiac or thoracic oppression, is also seen in a certain number of patients. More rarely severe reactions are encountered with alarming symptoms as chill, fever, headache and mental excitability, succeeded by coma. Several years ago I noted such a reaction in a patient with cerebrospinal syphilis. In two or three days he entirely recovered and subsequent treatment was well tolerated. Another patient, who had a hemiplegia several years before and who at the time under discussion was being treated for choroiditis and atrophy of the retina, became unconscious three days after an intravenous injection of 0.35 gm. of salvarsan. He regained consciousness after several hours but was disoriented, mentally confused and unable to speak. The next day he was normal. As part of the intravenous treatment, an intensification of the lancinating pains, girdle sensation or bladder symptoms is not uncommonly met with in tabes, if a large dose is administered. With the exceptions noted, reactions can usually be obviated by keeping well within the *dosis tolerata*

for that particular patient, if necessary making the intervals a little shorter in order to get the desired effect.

The reactions following subdural injections form two groups. First: those incidental to puncture, and second, those due to the medicated serum itself. In the first class belongs chiefly the headache which sometimes develops twenty-four to forty-eight hours after the treatment, coming on shortly after the patient gets up. It is very annoying, lasts several days, and is only relieved by the recumbent position. Usually it can be avoided by rest in bed for forty-eight hours after treatment, but occasional cases suffer in spite of this precaution. Rarely vomiting, as an isolated symptom, comes on two or three hours after treatment and lasts until the next day.

Of the second group, by far most of the discomforts occur in tabetics, and usually manifest themselves as exacerbations of their lancinating pains, gastric or rectal crises. They appear within a few hours, last for a day or so, and are often severe enough to require the administration of opiates. These paroxysms are then followed by longer intervals of freedom from pain. It is well to bear this type of reaction in mind and to give very small doses for the first few treatments, as its severity is often proportional to the size of the dose. Since we have been using 1/10 to 1/8 or even as low as 1/20 milligram, patients have complained of less inconvenience. Alcoholics and morphine habitués tolerate both intravenous and intraspinal treatment very poorly as a rule. Among the severer types of reaction, bulbar symptoms sometimes make their appearance, that is, shock with marked laryngeal crises, irregular respiration and partial loss of consciousness. In a paretic this train of symptoms developed each time after the first three injections, becoming less intense and then ceasing altogether,. He is now treated with amounts of 1/5 to 1/4 milligram without any discomfort. It is interesting to note that his first intravenous treatment was followed by mental confusion. In another case, a woman with general paresis, aphasia and mental confusion lasting several hours, developed two days after the fourth intraspinal treatment of 1/10 milligram. There was no paralysis. In yet another case a fatal hæmorrhage ensued within twenty-four hours after the introduction of 1/4 milligram. The patient was a man, aged 47, markedly alcoholic.

From the foregoing it will be seen that while in the larger percentage of cases there is little risk attending either intravenous or intraspinal treatment in disease of the nervous system, it is not altogether a harmless procedure, and it cannot be emphasized either too strongly or too frequently, that every precaution be carefully carried out in regard to

preparation, size of dose and sufficient rest in bed after treatment. Whether in the subdural injections the untoward effects mentioned are due to the irritating action of the arsenic, or to a change in pressure acting on the diseased vascular walls, cannot be positively asserted.

The results of the treatment may be grouped according to their effect on the biological findings and the clinical status of the patient. Cure, amelioration or failure are dependent upon the extent and type of the morbid process, *i.e.,* whether an active meningeal inflammation is present or degeneration of the essential nerve structures. While the same physical signs may be produced by both processes, their prognosis is quite different. Where the symptoms are due to an active inflammation with strongly positive fluid, the outlook is very encouraging. Where, however, the underlying process is one of degeneration with atrophy and sclerosis, with negative or weakly positive fluid findings, the prognosis is not so hopeful.

Of the laboratory findings the pleocytosis is most susceptible to therapy and usually disappears after a few injections; in many cases with intravenous treatment alone. The Wassermann reaction and the globulin content are more refractory, the latter persisting even after the Wassermann reaction has become negative. The influence of treatment on the Wassermann reaction in the fluid depends upon the type of the affection met with. In cerebrospinal syphilis it is more quickly affected by the combined treatment than in tabes or paresis. In some cases, 13 injections intravenously and 1 injection intraspinally brought about a reversal. In others, 16 intravenously and 15 intraspinally were required. Treatment should be continued for a time in spite of a negative reaction, as I have seen it become positive again after several months where it had been intermitted with the first negative findings. In tabes, with the reaction positive with 0.2 cc. or less of fluid, it is usually very slow to disappear, but gradually grows weaker under prolonged treatment. Its persistence is suggestive of tabo-paresis. This can be confirmed by the colloidal gold test. In tabo-paresis and paresis the reaction is most resistant; in some cases fixed. In the greater number of cases I have under observation it has been influenced only in the higher dilutions remaining ++++ with 0.4 or 0.6 cc., even where 30 to 40 or more intraspinal injections have been given. In a few cases the reaction has become completely negative to 2.0 cc., the globulin has been reduced to a trace and the colloidal gold test has been changed from a paretic to a luetic curve. These in my experience are exceptions. In one case, where the serological findings have become practically negative, the patient has steadily deteriorated clinically. The gold sol re-

action usually runs parallel with the other findings and changes from a luetic curve to normal in cerebrospinal syphilis and tabes, and from a paretic curve to a luetic curve, rarely normal, in general paresis and tabo-paresis.

The clinical achievements may be summarized as follows: In active progressive tabes the lancinating pains are ameliorated or disappear entirely. The gastric and rectal crises are usually controlled, or regress, and the ataxia is markedly decreased, and in some cases has disappeared. Disturbances of sensation partially or completely clear up. Sphincter control and sexual power have improved or returned to normal. The patients feel better, put on weight, and are able to resume their occupation. I have noted no return of absent reflexes. The following cases are illustrations of the therapeutic results obtained.

1. Tabes; man, aged 40. Syphilis 8 years ago. For one year severe pains in legs, girdle sensation and marked ataxia; absent reflexes. Argyll-Robertson pupils. Blood ++++; cerebrospinal fluid, Mar. 11, 1913: cells 70, globulin ++++, Wassermann ++++ to 0.4 cc. Treatment, 12 intravenous; 10 intraspinal injections. Patient could not take mercury and was unrelieved by intravenous treatment. Under subdural therapy, leg and girdle pains disappeared. He is able to walk without assistance, has gained considerably in weight and for two years has been back at his work. Serological findings have remained negative.

2. Tabes; man, aged 32. Syphilis 14 years ago. Tabetic symptoms, four years. Loss of coördination; most pronounced ataxia; lancinating pains, rectal and vesical control impaired. Blood ++++. Fluid, Feb. 10, 1912; cells 34, globulin ++; Wassermann ++++ to 0.2 cc. Treatment, 15 salvarsan injections intravenously; inunctions and injections of a soluble mercurial salt. Result: Freedom from pain; sphincter control regained; sexual power improved; most marked change in ataxia which is now scarcely perceptible and patient is able to walk several miles a day.

3. Tabes and optic atrophy; woman, aged 32. Syphilis probably 15 years ago. For four years, severe headaches; manual incoördination and slowly progressing numbness. For two years, girdle sensation and ataxia. Reflexes absent; marked Romberg; gait very ataxic, patient almost unable to walk. Eight months before treatment, vision of left eye became impaired and then failed entirely. Right eye showed irregular pupil, sluggish to light and accommodation; fundus slightly pale, vision 40/20. Blood Wassermann, ++++, spinal fluid: cells, 67, globulin ±, Wassermann ++++ to 0.4 cc. Treatment: 19 salvarsans, intravenously; 16 mercuries; her last salvarsan injection was given July 24, 1914, and the last mercury, Jan. 5, 1915. The latter drug she did not tolerate well. In March, 1915, she gave birth to a child. She was seen again on April 27, 1916; a most remarkable improvement in her gait had taken place; only a very slight ataxia remained. The condition of her right eye has remained stationary. Her general health is very much better and she has gained 12 pounds in weight.

4. Tabes; man, aged 41. Syphilis 19 years ago. For two years has had rectal crises. Knee jerks normal; station good; bladder slow; sexual power weak; pupils unequal and sluggish to light. Blood Wassermann ++++. Spinal fluid: 150 cells, globulin ++, Wassermann ++++ to 0.4 cc.; Lange:

luetic curve. He has had 11 intravenous and 9 intraspinal injections of salvarsan in dosage of 1/10 to 1/5 milligram and two courses of mercurial injections. Excepting a trace of globulin, his serological findings are negative; his blood remains ++++. The crises, which were intensified by the first few intraspinal injections, have cleared up entirely.

5. Incipient tabes; man, aged 43. Syphilis 20 years ago. Was first seen January, 1911, at which time he exhibited the symptoms of incipient tabes. Two years before, he had had double vision. His serum was ++++. His fluid examination on November 21, 1912, showed 14 cells, positive globulin, negative Wassermann. Serum negative. Treatment: 10 intravenous injections of salvarsan and several courses of mercurial treatment. Clinically the pains, which had been a pronounced symptom, have entirely disappeared. The patient was again punctured, April 27, 1916, and showed a normal spinal fluid and a negative blood.

The results in optic atrophy depend upon whether the nerve substance is primarily affected or whether there is an extension from the meninges. In primary optic atrophy the essential tissue is attacked either by gummata or Huebner's arteritis (Nonne). It is, however, more often affected secondarily, and the vast majority of cases show positive findings in the fluid, with symptoms of tabes. In the former, treatment at first appears to be effective in arresting the process, but some cases slowly progress in spite of the apparent improvement. In the secondary form, energetic treatment is especially indicated and gives a more encouraging prognosis.

6. Optic atrophy; woman, aged 48. Syphilis six years. One year after infection, double vision and strabismus. When seen in October, 1912, vision of right eye was 20/50; left, fingers at 4 inches. Cerebrospinal fluid: cells 24, globulin +. Wassermann ++++ with 1.0 cc. She has had 23 intravenous injections of salvarsan, one intraspinal, several courses of mercurial injections, inunctions and mixed treatment. Under treatment her headaches ceased, vision in right eye was 20/20 and in left, fingers at 2½ feet. August 21, 1914, the report on her eyes was as follows: vision of the right, 20/20, of the left, fingers at 5 feet. The condition has remained stationary and at the present writing the fields of vision are normal in the right eye and somewhat improved in the left. The paleness of the left disc is apparently about as before.

7. Optic atrophy; man, aged 35. Syphilis denied. June, 1911, blurring of left eye; pupils irregular, sluggish to light and accommodation; both discs pale, left markedly so. Vision of left, 50/20, right, 40/20. Spinal fluid, October 6, 1912, cells 15, globulin +. Wassermann —; serum ++++. Treatment: 17 salvarsan injections intravenously, several courses of mercury and mixed treatment. February 16, 1915, ophthalmologist's report read as follows: Accommodation has increased in both eyes; vision has improved; the irides react to the stimulus of light but they are a little sluggish. Optic disc improved somewhat in color and fields of vision improved.

8. Optic atrophy; man, aged 50. Syphilis denied. Gonorrhœa, 25 years ago. In June, 1914, complained of pains in legs and double vision. Disturbance in walking; slight headache. Impairment of vision of right eye, 20/70. Blood ++++. Spinal fluid: 0 cells, globulin +. Wassermann ++++ to 0.8 cc.; Lange: luetic curve. Treatment: 3 intravenous, 12 intraspinal injections of

salvarsan, besides mercury. The patient feels better in every respect, his mind is clearer, he has no pain and no fatigue after exercise. The vision in his right eye is now 20/30. Spinal fluid, Dec. 1, 1915; cells 2, globulin +, Wassermann ++ with 1.0 cc.

Summarizing the cases of paresis, all showed the typical biological findings namely, a positive serum, an increase of cells varying from 18 to 290, strongly positive globulin content and a positive Wassermann in dilutions of 0.2 cc. or less. The colloidal gold test gave a typical paretic curve, that is, complete decolorization in the first four to eight tubes. The number of intraspinal injections administered varied from 6 to 41, alternating with intravenous injections of salvarsan.

In the following abstracts are cited the average type of case met with, and from these can be gauged the hope to be held out for amelioration of the condition:

10. Paresis; man, aged 38. Syphilis in 1902. No symptoms until 1912, when he complained of headaches. No treatment. In April, 1914, mental symptoms, with marked excitability and grandiose ideas developed and he was placed in an institution. On February 20, 1915, he came under my care. His serum was ++++; spinal fluid; cells 290, globulin ++++, Wassermann ++++ to 0.05 cc.; gold reaction, paretic curve. Since that time he has had 23 intravenous and 25 intraspinal injections of salvarsan, inunctions and intramuscular injections of mercury. In June, 1915, a marked improvement in his mental condition had taken place, he was able to leave the sanatorium and the treatment was then carried out on the ambulatory plan. In August, 1915, he seemed normal mentally and went back to work. His fluid became normal as to cells, globulin remained strongly positive and Wassermann positive to 0.4 cc.; the Lange showed a luetic instead of the paretic curve. His remission lasted until July, 1916; when he became careless about his work in the office, destroyed letters and exhibited kleptomaniac tendencies.

11. Paresis; man, aged 50. No history. Mental symptoms began the early part of 1912. May 8, 1914, serum ++++; spinal fluid; cells 48, globulin ++, Wassermann ++++ to 0.2 cc.; gold test, positive. He has had 15 intravenous and 24 intraspinal injections of salvarsan. Clinically, he has not returned to his former mental condition but is able to remain with his family, takes part in their social affairs, goes to the theatre, etc. In other words, for the past two years he has led a comfortable vegetative existence and excepting an increased irritability now and then has had no mental outbreaks. His fluid is normal only as to cells.

12. Paresis; man, aged 45. Primary lesion in 1905, for which he had three years' treatment. In 1914 he developed continuous headaches, was unable to attend to business, became very nervous, disconnected and rambling in his talk. May 13, 1914, blood ++++, spinal fluid: cells 30, globulin ++++, Wassermann ++++ to 0.05 cc.; gold sol, paretic curve. He received 12 intravenous injections and 20 intraspinal injections from ¼ to 1 milligram. The first few injections were followed by short periods of improvement, during which his mental condition cleared up somewhat but never returned to normal. The later treatments produced no change whatever and in April, 1915, he developed attacks of weakness, became progressively feebler until the latter part of June, when he died. Serologically there was only a reduction in the cell count.

13. Paresis; physician, aged 38. Chancre, 1904. No treatment. In July, 1914, change in personality. Wassermann at that time, ++++; grandiose ideas, filthy habits, forgetful. Spinal fluid: August 23, 1914, cells 180, globulin ++++, Wassermann ++++ to 0.05 cc., colloidal gold reaction, positive. Had 30 intravenous injections of salvarsan, several courses of mercurial injections and 41 intraspinal injections, from ¼ to ½ milligram. His mental improvement was quite marked after the second intraspinal injection and progressive improvement was noted until the latter part of March, 1915, when he had a severe headache; became talkative and excitable, with grandiose ideas and delusions; some disturbance of speech; memory very poor. Under continued treatment, this phase passed over. He went about his ordinary affairs, attended lectures and clinics and had a remarkable insight into his condition. Excepting a tendency to become easily excited and quarrelsome, with two attacks of transient aphasia, his remission lasted nearly a year. On February 22 of this year he had an attack of aphasia which did not clear up, and two days later, a hemiplegia. He died on the 26th. A post-mortem was not obtained.

In estimating the results obtained in the treatment of paresis, the benefit to be looked for, it seems to me, depends on the duration and the anatomical involvement. In the type with the preponderant changes in the meningo-vascular structures, with a high cell count, a rather sudden onset and marked mental disturbance, good results can be obtained and the process perhaps kept stationary. Where the parenchymatous tissue is chiefly involved, with atrophy or sclerosis, attended by a low lymphocytosis, and an insidious onset, the degenerative changes have probably advanced too far, and at most only temporary improvement can be expected, with almost certain relapse. No one can tell when paresis begins, and by the time it is clinically manifest the damage is irretrievable. Cases that respond to treatment and those where therapy yields but indifferent or no results, give the same gold reaction with decolorization in the paretic zone. We have, therefore, in this test, not a means of distinguishing possible different types, but a method of separating true paresis from forms of meningo-vasculitis which simulate it. While a promise of cure cannot be held out in cases which are clinically developed, the treatment is of value in inducing remissions, making the patients socially possible and amenable to home care, and in a few cases restoring them, partially at least, to economic efficiency. If the diagnosis of paresis can be established through the colloidal gold reaction, when the affection is in its incipiency, we may be justified, perhaps, in speaking of a cure.

Conclusions.

In order to develop a successful plan of treatment in syphilis of the central nervous system it is necessary to have a clear idea of how infection takes place. In the secondary period of the disease, about 25% show marked changes, while a lesser number reveal slight abnormalities in the spinal fluid. We conclude, therefore that a certain percentage of such cases are cured spontaneously or during the general treatment of the disease. It is impossible to estimate the number of syphilitics who later develop manifestations on the part of the nervous system, but it is probably larger than the statistics show. A careful examination of affected individuals would probably reveal a larger number with abortive or rudimentary tabes or paresis or involvement of the fluid without objective signs.

All patients at the end of the first year of their infection should be punctured whether or not they have manifestations or positive signs of the disease. If the fluid remains negative to all of the tests, they can be assured with a reasonable amount of certainty that they are not menaced by the possibility of a later development. Furthermore, a positive colloidal gold test with a persistent positive Wassermann, in the high dilutions, points to an impending paresis, whether or not the patient shows mental impairment. In other words, years before the stigmata of degeneration appear, the pathological process is at work in the central nervous system. When the clinical symptoms of paresis develop, like memory, speech, hand-writing defects, etc., the disease has already existed for years. This statement also applies to tabes. The results obtained in the treatment of tabes would seem to confirm the hypothesis that this affection is primarily an inflammatory process involving the meninges, rather than a degenerative process, for if the latter assumption were correct we could not hope to derive benefit from the treatment.

CHART I. SPINAL FLUID FINDINGS IN EARLY SECONDARY SYPHILIS.

CASE	DATE I	DATE II	SYMPTOMS	SERUM WASS.	CEREBROSPINAL FLUID. CELLS	GLOB.	WASS.	LANGE	REMARKS
M. B.	1/1916	3/15/16	Sluggish pupils	++++	6	±	—	Luetic curve.	Very marked maculo-pap. rash.
J. B.	10/15/15	10/1915	Dizziness; exag. reflexes.	++++	27	—	—	" "	
D. B.	10/1915	1/1916	Dilated fixed pupil.	++++	7	+	—	" "	Grouped papulo-squam. rash.
M. B.	11/1915	11/15/15	None	++++	2	+	—	Negative.	
P. M.	10/1915	2/1916	"	++++	6	—	—	"	
J. F.	9/10/15	1/15/16	Pupils sluggish.	++++	11	—	—	"	Papulo-pustular rash.
S. G.	12/1915	1/1916	Iritis.	++++	1	—	—	"	
E. G.	12/1915	4/6/16	Right disc hazy.	++++	6	—	—	"	
M. M.	12/1915	1/1916	Impaired hearing.	++++	12	—	—	"	
G. M.	1/1916	2/1916	Irreg. fixed pupils.	++++	31	+	—	Luetic curve.	Generalized papular rash.
C. N.	1/1916	3/1916	None.	++++	4	—	—	Negative.	3 Chancres.
J. P.	3/1916	4/10/16	"	++++	5	—	—	"	
H. R.	12/3/15	1/1916	Iritis.	++++	2	—	—	"	
T. R.	?	9/15/15	Headache; exag. knee jerks; fixed pupils; convulsions.	++++	34	++	4+ 0.2	Paretic curve.	Mucous patches; H rash 9/15/15.
J. V.	12/1915	1/29/16	Reflexes exag. Choroiditis, Papilo-edema left disc.	++++	260	+++	4+ 0.4	Luetic curve.	
J. D.	12/1915	2/1916	Fundi congested; right disc hazy.	++++	0	—	—	" "	
J. W.	12/1915	1/1916	Pains temporal region.	++++	0	—	—	Negative.	
M. R.	1/1916	3/15/16	Headaches; reflexes sluggish.	++++	3	—	—	"	
E. M.	6/1915	8/1915	None.	++	1	±	—	"	
A. L.	10/1915	1/1916	Beginning papillitis; exag. reflexes.	++++	2	—	—	"	
A. R.	9/1915	?	Tinnitus; dizziness; right disc obliterated; left cloudy.	++++	9	++++	4+ 0.8	Luetic curve.	Symmetrical, ulcerating lesions arms 2 mos. duration. Malignant precocious syphilis.

CHART II. SEROLOGICAL RESULTS IN TREATMENT OF SYPHILIS OF NERVOUS SYSTEM.

		Before Treatment.					Amount of Treatment			After Treatment			
		Blood	Cerebrospinal Fluid							Blood	Cerebrospinal Fluid		
Case	Diagnosis	Wass.	Cells	Glob.	Wass.		Salv. I. V.	Salv. I. S.	Hg. Injts.	Wass.	Cells	Glob.	Wass.
W. G.	Tabes	4+	34	2+	4+	0.2	19	1	17	+	3	+	Neg.
T. C.	"	Neg.	9	4+	2+	1.0	11	6	12	Neg.	3	Neg.	"
I. G.	"	4+	160	4+	4+	0.4	6	5	12	"	0	+	"
S. G.	"	4+	73	4+	4+	0.4	5	6	8	"	0	Neg.	"
L. F.	"	4+	128	4+	4+	0.2	10	7	12	4+	0	+	"
J. H.	"	4+	150	4+	4+	0.4	11	9	20	4+	0	±	"
W. R.	"	Neg.	81	4+	4+	0.4	5	7	0	Neg.	0	±	"
E. M.	"	"	12	2+	+	1.0	12	0	22	"	6	Neg.	"
G. R.	"	4+	70	4+	4+	0.4	12	11	12	"	0	"	"
L. C.	Optic Atrophy	Neg.	60	4+	4+	0.2	5	6	0	"	0	+	"
S. G.	" "	"	35	4+	4+	0.6	3	4	0	2+	4	2+	"
H. R.	Cerebrospinal Syphilis	4+	46	4+	4+	0.6	12	0	40	Neg.	0	Neg.	"
H. H.	"	4+	235	4+	4+	0.6	13	1	20	4+	8	++	"
E. R.	"	4+	90	4+	4+	0.1	7	7	8	4+	0	+	"
M. G.	"	4+	96	4+	4+	0.4	4	11	0	4+	0	Neg.	"
L. T.	"	4+	51	3+	4+	0.2	9	10	26	2+	3	+	"

CHART III. SEROLOGICAL RESULTS IN PARESIS BEFORE AND AFTER TREATMENT.

	Before Treatment						Treatment			After Treatment					
		Cerebrospinal Fluid				Blood					Cerebrospinal Fluid				Blood
Case	Date	Cells	Glob.	Wass.	Lange	Wass.	Salv. I. V.	Salv. I. S.	Hg. Injts.	Date	Cells	Glob.	Wass.	Lange	Wass.
H. H.	12/12/13	26	+	4+ 0.6	5555554100	++++	30	34	7	1/12/16	2	++++	4+ 0.4	5555555430	±
E. R.	8/23/14	180	++++	4+ 0.05	5544443200	++++	31	41	38	2/16/16	6	++	4+ 0.2	5555542000	+++
E. N.	11/11/14	16	++++	4+ 0.2	5555543100	++++	14	23	0	4/5/16	13	+	4+ 0.4	5555430000	++++
H. M.	5/11/14	30	++++	4+ 0.05	5555543100	++++	12	20	0	6/1/15	8	++++	4+ 0.4	5555543100	++++
G. J.	3/29/15	75	++++	4+ 0.4	5555543200	++++	10	15	29	4/21/16	12	++	4+ 0.4	5555553000	Negative
W. A.	2/20/15	290	++++	4+ 0.05	5555542100	++++	23	25	22	4/26/16	7	++++	4+ 0.4	2223332000	++++
W. R.	6/28/15	100	++++	4+ 0.05	5555542000	++++	7	5	10	4/29/16	2	++	4+ 0.4	5555432000	++++
L. F.	11/27/15	75	++++	4+ 0.1	5555555543	++++	5	18	0	4/19/16	10	++++	4+ 0.1	5555555400	++++
H. W.	5/19/15	3	++++	4+ 0.1	5544442100	++++	11	20	11	12/22/15	0	±	2+ 1.0	1134330000	Negative
F. P.	10/5/15	60	++++	4+ 0.2	5555555200	++++	10	16	2	3/29/16	6	++++	4+ 0.2	5555554300	++++
B. A.	12/18/15	45	+++	4+ 0.1	5555542000	++++	6	9	16	4/19/16	7	++	4+ 0.4	5555430000	++++
W. L.	3/24/16	110	++	4+ 0.1	5555554400	++++	4	3	6	4/12/16	24	++++	4+ 0.1	5555554400	++++
M. H.	3/9/16	35	+++	4+ 0.6	5555543000	++++	4	4	3	4/19/16	10	+++	4+ 0.4	5555543000	++++
F. H.	1/22/16	40	+++	4+ 0.2	5555555520	++++	4	4	0	4/29/16	11	++++	4+ 0.1	5555555300	++++
T. R.	2/11/16	34	++	4+ 0.2	5555542200	++++	13	0	50	4/26/16	3	++	4+ 0.6	5555530000	++++

A UNIQUE CASE OF ATROPHY OF THE FATTY LAYER OF THE SKIN, PRECEDED BY THE INGESTION OF THE FAT BY LARGE PHAGOCYTIC CELLS—MACROPHAGES.*‡

By T. C. Gilchrist, M.D., and L. W. Ketron, M.D., Baltimore.

(From the Dermatological Department of the Johns Hopkins University.)

Case Report.

The patient was a young girl, aged 8 years, who came of a good family. There was nothing of importance in the family history. She was a seven-months child but there were no complications at birth.

The disease began in April, 1915, six months previous to examination, at which time the mother noticed a spot on the calf of the right leg. This was soon followed by lesions on the other leg and later on the thighs. The mother described them as "lumps under the skin which appeared to the naked eye as dimples." During this period of development of the disease the patient's health was not very good. She would have feverish attacks and loss of appetite at various times. There were no definite subjective symptoms. Various medical treatments were tried but without any favorable results on the course of the disease.

Present Examination. The patient was a rather underdeveloped, moderately nourished child, weighing 37 pounds. She was bright, rather serious minded and the expression on her face was that of a much older child.

The cutaneous changes were present only on the lower extremities, extending from the inguinal region to the ankles. (Figs. 1 and 2). The anterior and outer surfaces of the thighs were comparatively free, the condition being limited to the inner and posterior aspects. The greater portion of the legs was involved, except over the knees and directly over the anterior tibial surfaces. The most striking thing which was seen on general inspection was the distorted contour of the legs, visible even with the stockings on, due to areas which were apparently sunken below the normal level of the skin.

Thighs. The smallest lesion which could be seen was a pea-sized, irregular or round, bluish tinted, slightly depressed macule which was not sharply defined but faded out gradually into the surrounding tissue. From these were formed larger, sunken, morphœa-like patches which were round, irregular or band-like and reached the size of 10.14 cms.

The depth of the atrophy varied from that which was scarcely perceptible in the smaller lesions, to about 2 mm. in the larger ones. The skin over the atrophic areas looked entirely normal except for a dusky bluish color which became more pronounced as the lesions increased in size. The edges were not

* Published simultaneously in the *Johns Hopkins Hospital Bulletin*, October, 1916.

‡ Read before the 40th Annual Meeting of the American Dermatological Association, Washington, D.C., May 8-10, 1916.

raised above the normal level of the skin and arose from the atrophic centre gradually or rather abruptly. There was no redness or scaling of the lesions.

If one palpated the affected area, a new condition was found which was not manifest to the naked eye. This consisted of hard, sclerotic, freely movable, irregular or branching masses or strands which varied in size from those which were barely palpable to the size of a man's finger. These masses lay in the subcutaneous tissue and ran beneath the smaller atrophic macules and the apparently normal skin. They did not invade the tissues beneath the larger patches where the atrophy was complete but, in some cases, were continuous with the edges of these patches. These subcutaneous strands extended for the most part down the inner sides of the thighs. The skin over the larger atrophic patches had a normal elastic feel. It was not hardened, was freely movable and could be picked up between the fingers in the same manner as the normal skin over portions of the body where there is little or no fatty layer. The skin over the smaller macules could not be picked up in this manner but was bound down, in many cases, to one of the deep infiltrations, giving a feel similar to that of a scirrhus cancer of the breast. The edges of the large lesions were soft and passed abruptly into the normal skin or, in some cases, could be felt to be continuous with the subcutaneous infiltrations. At the edge of one of the atrophic patches two or three finger-nail sized, flat lumps could be felt which had a cartilaginous hardness.

Legs. On the legs the atrophic process had involved the greater portion of the posterior and lateral aspects. Here were seen palm-sized, atrophic areas which spread with a smooth or serpiginous border. These had become confluent with other patches, leaving here and there islands or tongues of normal looking tissue which had a hard or œdematous feel. The lesions on the legs differed from those on the thighs in that they had indurated, pinkish-yellow or reddish edges which were covered by a few thin, white scales.

The skin over these lesions was elastic and was not bound down. It had a dusky-bluish color and beneath it the veins were distinctly visible. On the legs the subcutaneous infiltrations were not so distinct because most all of the normal looking tissue in this region had a hard, œdematous or, in some cases, almost sclerodermatous feel. There was some œdema with pitting at the lower border of the atrophy about the ankles. A slight elevation of temperature over the reddish edges of the lesions of the legs was perceptible.

Histological Examination.

Two pieces of tissue were excised for histological study and stained with the usual stains.

Preparation 1. This tissue represented the smallest nodule which could be detected on the patient's thigh by deep palpation. Its existence gave no visible signs on the surface of the skin. It was hard to the touch and appeared to lie beneath the cutis.

The changes in the section were confined entirely to the fatty layer. The epidermis and the corium were unaffected. In the upper half of the fatty layer a small cellular nodule was seen, which was divided into lobules by the connective tissue strands which pass down perpendicularly from the lower portion of the cutis (Fig. 3). This cellular infiltration, towards its centre, had replaced most of the fatty tissue, but

as one approached the periphery, the fat spaces became more numerous and the infiltration gradually ended with prolongations, or isolated groups of cells which lay between the strands of the fat framework.

Fig. 1. A.

The new growth, towards the centre, consisted of a cellular connective tissue within which numbers of plasma cells were scattered diffusely or lay in groups (Fig. 5). Towards the periphery, where numbers of fat spaces still remained, the infiltration was made up of fibroblasts, large

endothelioid cells, small round cells, and scattered here and there, rather thickly in some areas, plasma cells and a few polymorphonuclear

Fig. 1. B.

leucocytes (Fig. 7). Besides these there were other numerous and striking cells which were markedly conspicuous because of their arrangement and abundant protoplasm. These lay mostly in the fat

spaces, in some cases filling them; in others lining them with gland-like regularity (Figs. 8 and 9).

They were found mostly in the depths of the infiltration but in the earliest stages of their formation, isolated groups lying near blood vessels were occasionally seen at the extreme edge of the infiltration (Fig. 4). The nuclei of most of these cells were large, oval, irregular or round with a heavily staining chromatin network (Figs. 8 and 9). Some

Fig. 2.

of them, however, were small with a picnotic appearance, while others were larger with a more faintly staining chromatin network. Mitotic figures were occasionally seen. The cells usually contained 1 to 3 nuclei, but large giant cells were found with fifty or more nuclei (Fig. 6). The protoplasm was frequently two or three times the width of the nuclei, stained faintly with eosin and polychrome methylene blue

and appeared as a fine foam-like network (Fig. 9). The contour of the cells varied with their location. When they completely filled the fat spaces, they were irregular or had a mosaic-like arrangement. If they surrounded the fat space they were usually rectangular in shape, resembling the flattened cuboidal epithelium of a glandular structure (Figs. 8 and 9). In rare instances the fat spaces were surrounded by cells which did not have this foam-like protoplasm and resembled cells of a leucocytic type (Fig. 4b).

In the comparatively normal fatty tissue surrounding the infiltration, one saw here and there small dilated blood vessels containing a number of polymorphonuclear leucocytes. Some of the vessels showed a proliferation of their endothelial lining and of the connective tissue surrounding them. Lying between the strands of the non-infiltrated fatty framework, small groups of epithelioid or fibroblastic cells or plasma cells were occasionally seen.

Preparation 2. This piece of tissue was excised from one of the large patches on the leg, extending from the atrophic centre through the elevated pinkish edge (Fig. 7). Here the changes were seen principally in the subcutaneous tissue. There was a slight scaling of the horny layer of the epidermis and a mild infiltration about the blood vessels in the cutis of the left half of the section. In the left third of the section (A), which corresponds to the elevated edge of the lesion, the same infiltration was found in the fatty layer which has been described in Preparation 1 (Figs. 7D and 8). If one followed the section towards the right, the fatty tissue was seen to give way rather abruptly to a dense sclerotic tissue (B) within which were found, in nests or more or less diffusely scattered, large fibroblastic cells, large and small round cells and plasma cells (Figs. 5 and 11). Newly forming and thickened blood vessels, showing endothelial proliferation, were seen. One small inclusion of fatty tissue was found in which were seen the large cells described above (Fig. 10). Further towards the right, corresponding to the atrophic centre of the lesion, the sclerotic tissue became less prominent and very few changes were noted except the entire disappearance of the fatty layer (Fig. 7C).

A polychrome methylene blue stain of both preparations showed no unusual increase of the mast cells. No change in the elastic tissue of the cutis was noted.

In order to study the fatty tissue of these preparations, some of the fresh tissue was stained with Soudan III. The fat spaces were seen to be filled with large, red stained fat globules. The large, single or multinucleated cells already described, which surrounded or replaced a fat

globule, were filled with reddish staining granules. These granules were also occasionally found in the cells lying in the infiltration considerably removed from the fat.

The resemblance of these large cells to xanthoma cells and the fact that the granules which they contained were shown by the Soudan III stain to be of a lipoid nature, led also to investigations to determine the presence of cholesterin. Dr. Shipley, of the Anatomical Department, kindly tested some of the fresh tissue with the polariscope, but no doubly refractive substances were found.

General Observations While the Patient was in the Hospital. The patient was admitted to the Johns Hopkins Hospital, Children's Department, on October 28th, 1915, about seven months after the beginning of the disease, and remained there during a period of about two months. Dr. Howland and other members of the Hospital Staff examined the patient, but nothing definitely pathological could be found, with the exception of the skin lesions. Dr. C. M. Byrnes, who referred the case to one of us, found no abnormalities in the nervous system. There were no muscular disturbances, and the glands of internal secretion were normal as far as could be determined.

The Wassermann and von Pirquet reactions were negative. The urine was negative for albumin, sugar and casts.

Dr. Shohle kindly made a determination of the cholesterin of the patient's blood but there was no increase above the normal limits. (He examined at the same time the blood of a patient who showed numerous xanthoma lesions on the buttocks and elbows and found a considerable increase in the cholesterin content.)

The temperature of the patient, which was 101 degrees, F., on entrance to the hospital, was subject to slight elevations at various times, but with no regularity. The white blood cell count was 15,600 and the increase was in the polymorphonuclear element.

From the time of admission, the patient was about the ward and on the outside daily, except during the two attacks described below. She had a very good appetite and only complained, at various times, of indefinite pains in the legs. No internal medication was tried except potassium iodide, which was given for only a few days and without benefit.

On the 9th of December, about six weeks after admittance to the hospital, she had an acute attack of toxic erythema with macules and papules scattered over the body. This followed a period of constipation and lasted three days. On December 17th she had a second attack of a toxic rash associated with a rise in temperature and a swelling of the

joints. During this time the white blood cell count was 26,000; a differential count showed: polymorphonuclears, 86 per cent., polynuclear eosinophiles 1.6 per cent., small lymphocytes 8 per cent., large lymphocytes 1.2 per cent., transitionals 3.2 per cent. Hæmoglobin (Sahli) 70 per cent. This attack lasted also about three days, at the end of which time she was able to be up and about the ward.

On the 21st of December the patient was taken home with no definite change in the skin condition. She had gained two pounds in weight.

General Discussion. The clinical course of the disease, while the patient was in the hospital, gave very little assistance as to the nature of the condition except that the slight irregular rises in temperature, associated with the high leucocytic count, were suggestive of some chronic inflammatory process with suspicious exacerbations. The attacks of toxic erythema, we feel, might have had some connection with the course of the disease.

The histological findings show that the lesions in their development and evolution follow a definite course which leads to the ultimate loss of the fatty layer without other permanent changes in the skin. The disease begins with the formation in the fatty layer of small nodules or strands which are not perceptible to the naked eye, but are found only by deep palpation. These small nodules are made up of cells of a chronic inflammatory nature. The inflammatory process spreads only in the fatty layer, the fat itself being taken up in the cytoplasm of large phagocytic cells which are very striking in appearance. After the fat is removed the infiltration gives way to a fibrous tissue, the contraction of which leads to the formation of the small atrophic macules visible on the skin, and which are bound down to the underlying masses. Later, as the lesions increase in size, this fibrous tissue is itself absorbed, leaving a soft elastic skin which, due to the loss of the fatty layer, has sunken down directly on to the muscular fascia. Since the edges of some of the lesions showed no induration, the sunken areas rising directly into the normal feeling skin, the process must be subject to self arrest. The fact that the areas affected return to a practically normal state except that the fatty layer is entirely lost, is strong presumptive evidence that the aim of the pathological process is the removal of the fatty layer. This assumption is best supported if we further assume that the fat itself, through some chemical change, has been converted into a substance, still of a fatty nature, but which acts as a foreign body in the tissues.

The other possibility is to assume that the condition is an infective process and that the invading organism has a special affinity for the

fatty layer, changing the fat into some substance which acts as a foreign body. The difficulty here is that, if bacterial in origin, one would not expect the process to be so narrowly confined to the fatty layer and, also, would not look for such complete restitution of the areas affected, after removal of the fat.

As to the nature of these phagocytic cells, they no doubt belong to the group which is classed as "macrophages." This term, which was introduced by Metchnikoff, was at first rather indefinite in its application, but lately, especially as the result of the work of Evans with the acid azo dyes, it is now applied to a definite and important group of cells. (Evans, "The Macrophages of Mammals," *The American Journal of Physiology,* 1915, xxxvi.) When animals, which are normal or have been experimentally infected, are injected intravenously with these azo dyes, *e.g.,* trypan blue, the dye is stored in various portions of the body in the cytoplasm of certain large mononuclear cells, which have the power of taking up finely particulate matter. To this class of cells belong the Kupffer cells of the liver which, in malaria, are filled with pigment and the cells of the bronchial lymph glands which, in anthracosis, contain pigment particles (coal dust). Other cells of endothelial origin, according to Evans, which have the power of taking up foreign bodies and which are found in the spleen, bone marrow and the serous cavities, belong to this special group, as do also the clasmatocytes of the skin and the foreign body giant cells. It has been shown by Evans, Winternitz and Bowman (*Jour. Exper. Med.,* 1914, xix), that the epithelioid cells and the giant cells of the miliary tubercle are pure colonies of these cells called macrophages.

The similarity of the macrophages occurring in our case, to xanthoma cells, is striking. Anitschow (*Archiv f. Dermat. u. Syph.,* 1914, cxx) has shown, in the experimental production of xanthoma by introducing foreign bodies into the skin of animals fed on cholesterin, that large macrophages are first called forth by the introduction of the foreign bodies, and these are later transformed into the typical xanthoma cells, because they take up the extravasated cholesterin which is present in excess in the blood. In xanthoma the foreign material is in the blood as a cholesterol-fatty-acid-ester, while in our case the foreign material is probably formed *in situ,* from the normal fat.

In conclusion, we may say that in the condition which we have described there is a gradual progressive change in the fat of the subcutaneous tissue of the skin, due to some unknown cause. This metamorphosed fat now acts as a foreign body in the tissues and calls forth a foreign body inflammatory reaction. Macrophages, derived from the

resting tissue cells, the endothelium of the capillaries and probably from the connective tissue cells, now appear and phagocytose this changed fat, which they probably liberate in some soluble, inert form which can be excreted through the blood and lymph channels. After the fat has disappeared, this inflammatory reaction, its function accomplished, is replaced by a fibrous tissue, which itself gradually disappears, leaving the skin practically normal with the exception of the absence of the fatty layer.

NOTE. We had the privilege of seeing the patient again in May, 1916, six months after our first observations. The changes observed were very interesting and corroborated and made stronger our previous convictions as to the nature of the pathological process. Two or three new depressions had appeared on the outside of the thighs and those on the inner sides had increased in size. The atrophic process had practically covered the whole of the legs, which now did not present the irregular contour observed at first, but looked and felt almost normal except for their extreme thinness due to the absence of the fatty tissue. The induration, redness and œdema had disappeared, and the scar following the excision of our Preparation 2, which was taken through the reddish, scaly, indurated edge of one of the large patches on the leg, was now surrounded by normal feeling, elastic skin. The mother said that the patient had had another attack of a toxic rash and at times still complained of pain in her ankles, but otherwise had been in very good health. There seemed, at this time, to be no interference with her muscular activity.

We wish to express our thanks to Mr. A. G. Martin, artist and photographer to the Phipps Psychiatric Clinic, for his attention and care in making our photographs.

EXPLANATION OF PLATES.

FIG. 1. Photograph A—front view. B—back view.

FIG. 2. Photograph of a painting of the inner portion of the thigh and leg, kindly made for us by Prof. Max Broedel.

FIG. 3. This represents the smallest lesion which could be palpated on the patient's thigh. The cellular infiltration is seen lying in the fatty layer (B) beneath a normal cutis. (A) is magnified in Fig. 4. (C) is magnified in Fig. 5. (D) practically normal fat.

FIG. 4. (Magnified portion (A) in Fig. 3.) At (a) is seen one of the earliest changes in the growth of the lesion seen in Fig. 3. Here is a small group of macrophages lying by the side of a blood vessel which is surrounded by normal-looking fatty tissue. At (b) is seen a fat globule surrounded by cells of a leucocytic type.

FIG. 5. Shows the large number of plasma cells which were found towards the centre of the infiltration shown in Fig. 3. (Magnified portion (c) in Fig. 3.)

FIG. 6. This section shows the large giant cells which are formed by the confluence of the macrophages.

Fig. 7. This section was taken through the edge of one of the large atrophic patches on the patient's leg. (A) represents the normal looking, although slightly reddened, skin and shows the infiltration (d) in the fatty layer which is of the same character as that which is seen in Fig. 3. (B) shows replacements of the infiltration in the fatty layer by sclerotic tissue. (C) represents the atrophic area in which the skin is practically normal except for the absence of the fatty layer. ((d) is magnified in Fig. 8, (e) in Fig. 10 and (f) in Fig. 11.)

Fig. 8. (Magnified portion (d) in Fig. 7.) Here is seen the arrangement of the large macrophage cells which fill the fat spaces or surround them with gland-like regularity.

Fig. 9. High magnification of the macrophages showing their foam-like protoplasm. In the lower right-hand corner they are seen surrounding a fat space. Immediately to the left of this they have completely filled the fat space..

Fig. 10. (Enlargement of Fig. 7 at (e)). Shows a small inclusion of fatty tissue surrounded by a richly cellular connective tissue. A degeneration of the tissue surrounding the artery is to be seen. Transition changes present from (A) to (B).

Fig. 11. Sclerotic tissue which replaces the fatty layer representing a later stage than that shown in Fig. 5. (Magnified portion (F) in Fig. 7.)

Discussion.

Dr. Goldenberg said he would like to ask Dr. Gilchrist if in this particular case there had been any primary changes in the muscle. It had been the speaker's good fortune lately to observe a case which in the end stage resembled this case, but differed from it in the microscopical findings. His case was one of dermatitoneuromyositis chronica atrophicans, a disease which had been described from Professor Herscheimer's clinic, in the *Archiv fuer Dermatologie*, in 1911. Clinically it resembled that case very much. The child had fever, tachycardia, the pulse was 120, the patient had a large spleen and absent patellar reflexes. The end stage showed a similar sclerodermic atrophy, but the case was different from the one presented, in the location of the lesions, which were localized on the upper and lower extremities and on the face and chest. In dermatitoneuromyositis there was primarily an inflammation of the muscle, and secondarily a dermatitis ending in atrophy. The speaker said that in Dr. Gilchrist''s patient he did not see, in the photograph of the specimen, any muscle tissue and that he would like to know if the excision had been deep enough. In his case there was a marked pain in the affected muscles, mainly on pressure, so that the case upon admission was considered a trichinosis, which was, however, disproved by microscopical examination.

The speaker said this might also be an abnormal and unusual end stage of dermatitoneuromyositis chronica atrophicans.

Dr. Hazen said he knew little about the fatty degeneration of this case. He had seen a case on the back of the leg, in which the fat had gravitated downward and liquefied. The speaker said that probably the fatty degeneration was something of which they knew very little at the present time, but if all cases were watched more closely we might make some interesting discoveries later on.

Dr. Hartzell asked whether the normal tissues had been replaced by fat or whether the tissues had undergone fatty degeneration.

Dr. Ravogli congratulated Dr. Gilchrist for giving such a deep study of this important case. There was no doubt of the atrophy of the fatty substance, but the disposition of the atrophic spots was in stripes and it could correspond to the nervous ramifications underneath. In these cases of atrophy he believed

Plate LV.—To Illustrate Article on Atrophy of the Fatty Layer of the Skin, by T. C. Gilchrist, M.D., and L. W. Ketron, M.D.

Fig. 3.

Plate LVI.—To Illustrate Article on Atrophy of the Fatty Layer of the Skin, by T. C. Gilchrist, M.D., and L. W. Ketron, M.D.

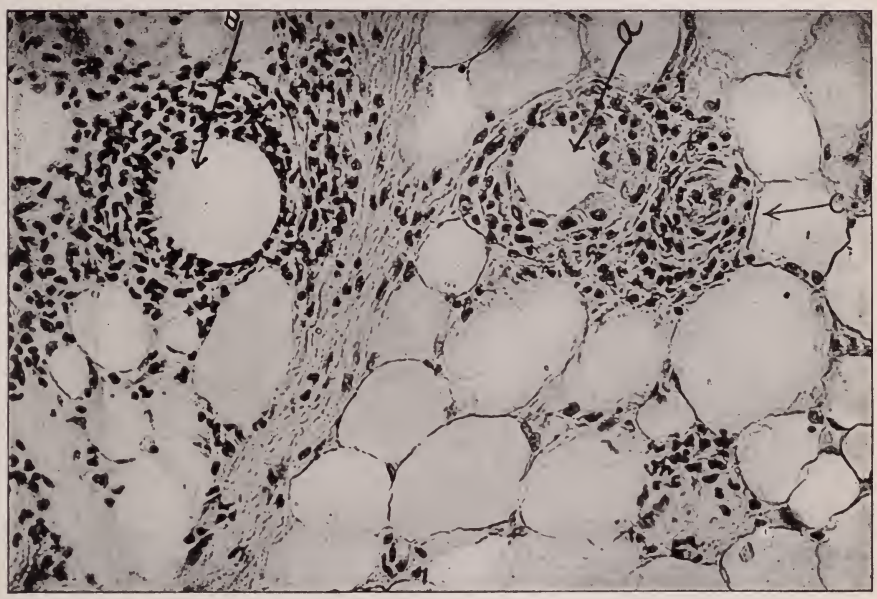

Fig. 4.

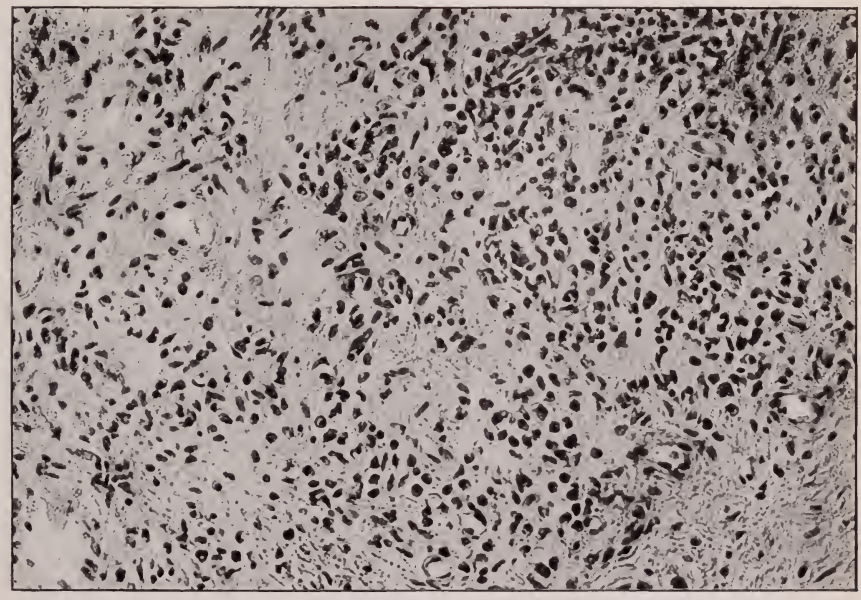

Fig. 5.

Plate LVII.—To Illustrate Article on Atrophy of the Fatty Layer of the Skin, by T. C. Gilchrist, M.D., and L. W. Ketron, M.D.

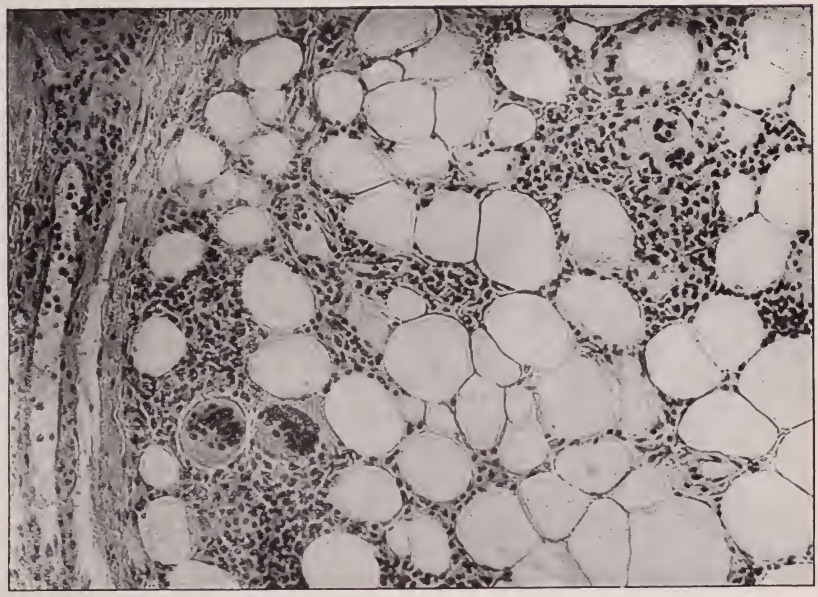

Fig. 6.

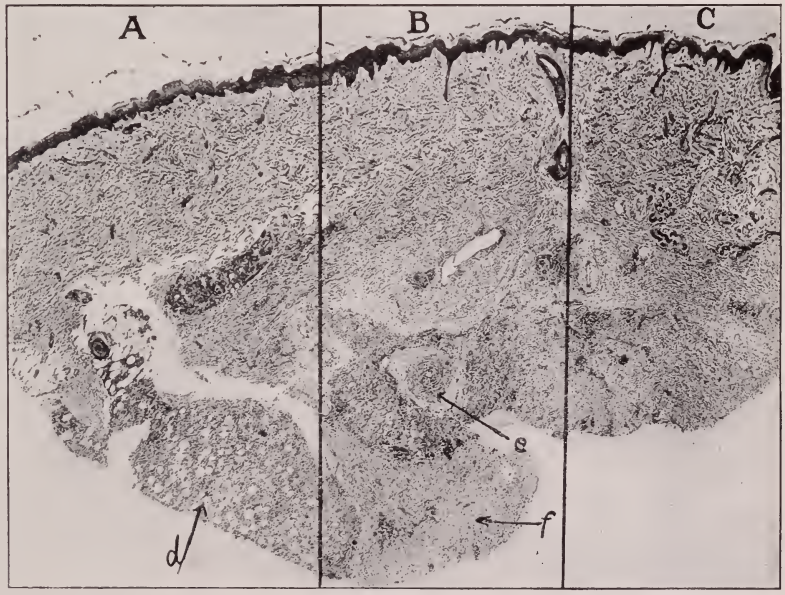

Fig. 7.

Plate LVIII.—To Illustrate Article on Atrophy of the Fatty Layer of the Skin, by T. C. Gilchrist, M.D., and L. W. Ketron, M.D.

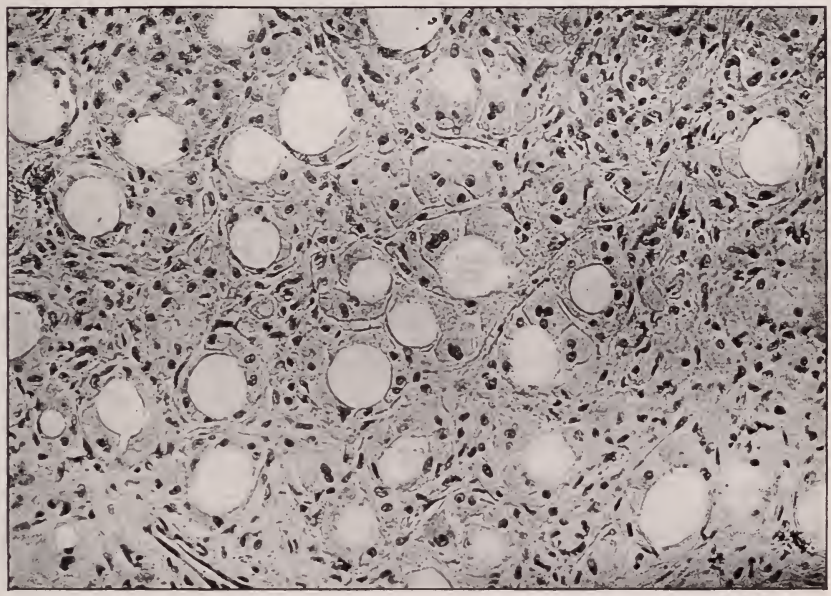

Fig. 8.

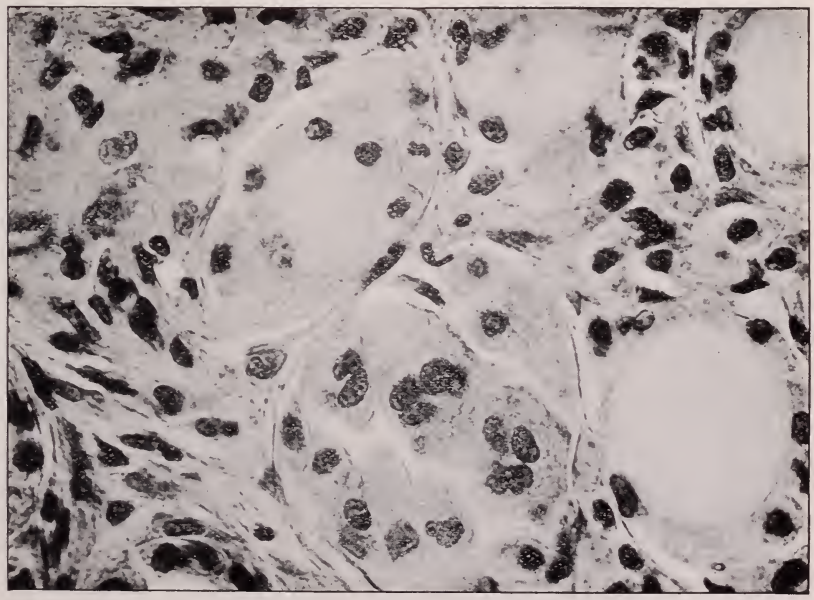

Fig. 9.

Plate LIX.—To Illustrate Article on Atrophy of the Fatty Layer of the Skin, by T. C. Gilchrist, M.D., and L. W. Ketron, M.D.

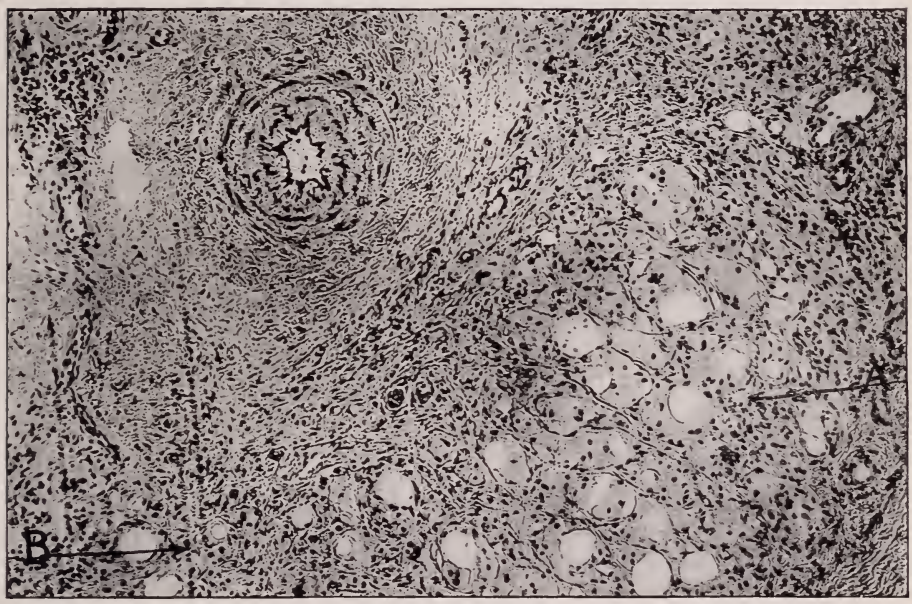

Fig. 10.

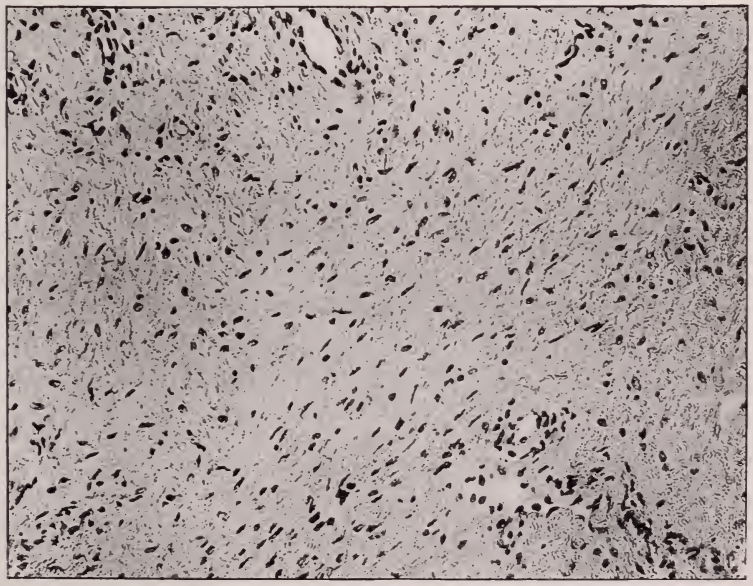

Fig. 11.

that the vasomotor nerves, which provided for the nutrition of the tissues, were affected, and as a result atrophic spots followed. It was possible that this condition had to be referred, pathologically, to a perverted condition of the internal secretions of the glands. The balance of these secretions was disturbed, and probably formed a kind of infection, a peculiar diathesic condition of the system, to act upon the vasomotor centre, which, affecting the trophic nerves, had produced degeneration of the connective tissues and of the fatty tissues. In this case the thyroid gland seemed not in good condition, as it was slightly enlarged, tachycardia was present, and the symptoms of an altered condition of the internal secretions were apparent.

THE EXUDATIVE DIATHESIS, AND A STUDY OF ACETONE BODIES IN THE BLOOD OF NINE CASES.

By Martin F. Engman, M.D., and Richard S. Weiss, M.D., St. Louis.

Part I.

(From the Department of Dermatology, Washington University Medical School.)

In 1905 Czerny presented his first paper on the exudative diathesis, crystallizing the experience and observations of years, and making what appears to be a logical separation of this congenital and hereditary anomaly from the mass of diatheses variously termed scrofula, lymphatism, arthritism, status lymphaticus, etc. Three more papers by him rapidly followed, and other investigators turned their attention to this subject. American dermatological literature practically ignores it, therefore we thought a comprehensive review would not be amiss.

Summary of the Literature.

According to Czerny, exudative diathesis may be defined as a congenital anomaly in the chemistry of the organism, characterized by an imperfect fat metabolism. It is surely congenital and hereditary; evidence may almost always be found in the parent, brothers and sisters. The affected children are usually large and apparently robust, but they may be small and delicate. The large ones show a great fatty development with slight musculature. There are two distinct nutritional types; one in which the weight curve remains subnormal in spite of a plentiful supply of milk and in the absence of gastrointestinal symptoms, the other showing a rapid gain in weight even with a scanty milk supply. In both there seems to be a disturbance of fat metabolism.

All of the symptoms of the exudative diathesis are evanescent. This is a characteristic feature. These children often show loss of appetite, foul breath, coated tongue and fever. The fever is ephemeral. The subjective symptoms are more or less pronounced, depending on the state of the nervous system (*q.v.*). Usually, the intestinal functions are normal. The condition is evidently not due to gastric disturbance for which it is so often treated. Absorption of toxines from tonsil or adenoid crypts or nasal infection may be a factor.

The natural immunity of these children to the infectious diseases is enormously decreased. They contract the acute exanthemata with ease. Tuberculosis—pulmonary, glandular and skin—is very readily acquired.

Symptoms in Detail.

Weight: The first pathological sign is failure of prompt equalization of the birth weight after the physiological loss, with sufficient nourishment and in the absence of gastrointestinal symptoms. These children do not regain the birth weight until the third or fourth week, instead of the eighth or tenth day, as in normal children. Symptoms of the exudative diathesis appear with the beginning of the gain in weight.

Gastrointestinal Tract: The only symptom of the alimentary tract mentioned by Czerny, is the geographical tongue. It is said to occur quite frequently and even in the very young infants.

Langstein, in 1908, called attention to diarrhœa due to the exudative diathesis *per se*. In the mild cases he notes mucous stools and in the severe cases purulent stools. In none of his cases were there any bacterial findings. Goeppert reported similar findings, but Sehlbach disputes this, and states that these children do not suffer from purulent stools more often than healthy children. Czerny believes that the intestinal mucous membrane can certainly play a part in the exudative diathesis, sometimes in severe form.

Dental caries has been mentioned by Schütz, who asserts that it occurs quite frequently in these children.

Circulatory System: None of the writers has mentioned any circulatory symptoms as characteristic of the exudative diathesis. The vasomotor disturbances belong more to the nervous phenomena and will be described later.

Respiratory Tract: These symptoms are very important. Czerny states that practically all exudative children show respiratory tract symptoms. The nasal, pharyngeal and laryngeal mucous membranes show simple hyperæmia, which is evanescent and is a vasomotor phe-

nomenon due to the excitable nervous system. Repeated attacks lead to actual inflammation. Following this, one observes adenoids and hypertrophied tonsils, with infection of the adenoid and tonsil crypts and subsequent absorption of toxic products; then follows lymph-adenopathy. The so-called asthma of children occurs in these cases, and according to Czerny, it is nothing more or less than a diffuse bronchitis, the asthmatic symptoms being caused by the unstable nervous system. The combination of asthma and eczema should always lead to a suspicion of the exudative diathesis.

All of the respiratory symptoms are said to be secondary to irritation, as from dust, for instance. This is shown by the comparative freedom from attacks in rural districts.

Genito-Urinary: Czerny mentions vulvitis and balanitis as an occasional symptom. Finkelstein states that this has not been proven, and should be looked upon as an accidental complication.

Lymphatic System: Irritation of the upper respiratory tract causes hypertrophy of the tonsils. It is said that this may occur without infection, but it is more marked in children suffering from repeated infections. Tonsillectomy does not remove the tendency to infection. Infection arises in the mucous membrane and not in the tonsils.

The adenopathy is always caused by the repeated infections. It is not a part of the exudative diathesis itself.

The following glands are usually involved:

(1) Glands posterior to the sterno-mastoid muscle, draining the adjoining scalp. They enlarge with eczema and scratch wounds of that region. A much more important region drained by this group is the naso-pharynx, and infection of this region can be diagnosed with certainty from the enlargement of the post-cervical glands, when the scalp is clean.

(2) Glands under the angle of the jaw, draining the tonsil region, become enlarged with tonsillitis and pharyngitis.

(3) Submental glands, draining the mucous membrane of the lips, tongue and floor of the mouth.

(4) Glands on either side of the larynx, extending down to the opening of the thorax, and becoming enlarged with pseudo-croup, acute and chronic laryngitis, etc.

The submaxillary and submental glands are commonly infected with tuberculosis, the post-cervical and laryngeal glands, rarely.

The enlargement of the glands always persists long after the primary infection has disappeared. In severe infections not only the regional, but also the distant glands are affected. This, however, is also secon-

dary. The tonsils, intestinal follicles and spleen may hypertrophy without infection. The highest grade of tonsillar hypertrophy may be found, without swelling of the lymph glands.

Nervous System: Almost always the family history of exudative children will demonstrate evidence of neuro- or psychopathy. The children themselves are of a neurotic disposition, and all their symptoms are subjectively increased. Itching is sometimes extreme. Slight obstruction of the air passages may be magnified, even to asthmatic attacks. Flushing of the skin and hyperæmia of the mucous membranes occurs with the slightest provocation. There is often a tendency to profuse perspiration.

Eye Symptoms: Occasionally blepharitis and phlyctenular conjunctivitis are observed.

Skin Symptoms: Seborrhœa capitis often occurs, even early in infancy. It is distributed particularly over the large fontanelle and sagittal suture, and is characterized by large greasy scales and underlying hyperæmic skin. The long continuance of this condition leads to eczema.

A pityriasic condition of the skin of the face, usually limited to a patch in front of the ears, is often seen.

Intertrigo occurs very readily, not alone on the diaper region but also in the folds of the neck, back of the ears, axillæ, front of the elbows, popliteal spaces, and in the folds of the groin and abdomen.

Eczema is one of the most formidable symptoms. It arises in the above mentioned symptoms, most frequently from seborrhœa. This type of eczema is a very familiar condition, and a description is unnecessary.

Prurigo is fairly common. It occurs sometimes in the first months, usually in the second six months. Its duration and intensity seemingly depend on the diet. In children who are not allowed to become excessively fat, it may disappear in the second to third year, in others it may last even to the eighth year. Itching varies in the different cases, depending on the stability of the nervous system. It may lead to sleep disturbance, scratching, furunculosis and eczema. Prurigo in the exudative children is evanescent, like the other conditions allied with it.

Skin Reaction: In cases of exudative diathesis, the skin is said to react to stimuli which do not affect the normal skin. Working on this basis, Rachmilewitsch discovered a skin reaction which he claims is found only in these children. He found that chemical or mechanical irritation alone does not produce a different reaction in exudative and normal children, while chemical and mechanical irritation together produce a characteristic reaction in exudative children. This was demonstrated

when a paste made of Coleman's mustard and water was applied to the scarified skin, as the following reaction was observed:

One-half hour after the application, a prominent hyperæmic wheal appeared. Serum exuded from the scarifications. At the end of about two hours, the serum began to dry up, and one hour later a small yellow crust appeared. The wheal remained at the height of its intensity for two to four hours. On the second day, the wheal was paler and not so prominent, and it remained so in the very fat children for from fourteen to eighteen days.

This, Rachmilewitsch says, is a positive reaction, as he found it in all exudative children, whether suffering from few or many symptoms.

On normal children a negative reaction was observed, which consisted of only the erythema of the normal mustard effect. Exudative children, who had been symptomless for months, still gave a positive reaction.

This reaction was tried on twenty new-born babies; four gave a positive reaction and all four had a high body weight. (Nothing was learned from the family history of these cases.) These observations on the new-born coincide with Czerny's statement that the diathesis is congenital.

Blood: Rosenstern states that all cases of eczema do not show eosinophilia; but those cases which occur as a manifestation of the exudative diathesis, show a constant eosinophilia. In other words, the occurrence of eosinophilia in cases of eczema shows that the eczema is a part of a constitutional diathesis and is a secondary affair.

Helmholz finds an almost constant eosinophilia in exudative children, particularly in those with eczema. In eczema of the scrofulous type he finds no eosinophilia. He also states that exudative children have an increased opsonic index to a hæmolytic staphylococcus. Lymphatic and scrofulous types have a low opsonic index to the same staphylococcus.

Aschenheim, in a very conclusive research, comes to the following conclusions:

(1) Eosinophilia occurs more often with acute eczema than with any other manifestation of the exudative diathesis.

(2) This eosinophilia disappears with the recession of the skin disease.

(3) Eosinophilia is not to be regarded as a trustworthy (or pathognomonic) symptom of the exudative diathesis, in spite of the fact that, (a) it is quite frequently found in the different manifestations of this constitutional anomaly, and (b) that it tends to disappear with the disappearance of the skin symptoms.

(4) It does not appear that there is a family tendency to eosinophilia in families where cases of exudative diathesis occur.

(5) Healthy people, who have never had a symptom of the exudative diathesis, may be found with eosinophilia.*

Benfey agrees with Aschenheim, but states that more research must be done on the blood of a very large number of infants. If some of these show eosinophilia and later on develop symptoms of the exudative diathesis, then eosinophilia may be regarded as an essential symptom.

Putzig made a very careful investigation of this much disputed question. He found that the normal eosinophile count averaged 1.8% on healthy infants from one week to one year of age. The highest count was 3.2%.

Children normal at the time of the blood count, and later showing exudative symptoms, gave an average eosinophile count of 4.08%. The highest count was 7.89%.

Children with frank symptoms of the exudative diathesis showed a constant eosinophilia, particularly when they had eczema.

His conclusions are as follows:

(1) The normal eosinophile count in healthy infants is from 2 to 4%.

(2) Apparently normal children, who later showed exudative symptoms, have a higher than normal eosinophile count before the exudative symptoms appear.

(3) Children with frank exudative diathesis show a constant eosinophilia.

(4) Eosinophilia is a symptom of the exudative diathesis.

(5) It is quite probable that the exudative diathesis is an anaphylactic phenomenon.

Treatment: The treatment is essentially dietetic. Up to the eighteenth month the infant should be given the smallest possible quantity of milk on which it will thrive without getting fat. The general appearance of the child and not the weight should regulate the feeding. If corpulence cannot be prevented in this way, substitute for part of the milk, carbohydrates, soups and vegetable extracts. After fifteen to eighteen months of age, milk should be reduced to a minimum and the baby given the diet of older children.

The condition is unfavorably influenced by over-feeding, either quantitatively or qualitatively. After the second year a vegetable diet is advisable. It should be supplemented by small amounts of milk and meat. Unlimited water may be given. Contraindicated are: eggs, cream, but-

* This was demonstrated on several members of A.'s family.

ter, sweet desserts and cooked fruits. Not more than one-fourth to one-half litre of milk should be given daily.

With this way of feeding, infections are fewer and milder; prurigo may promptly clear up; naso-pharyngeal infections disappear; hypertrophied tonsils diminish in size. Erythema, seborrhœa and eczema do not yield so readily. The appropriate local treatment must be carefully used.

The psychical condition of the child must be watched. He should not be coddled and made a chronic invalid. He must be encouraged to mingle with other children.

Weaning of exudative children is difficult. It is characterized by loss of weight, irritability, diminished motor functions, etc. It is wrong to give to fat infants the same large amounts of food after weaning that they have received on the breast. In this case the exudative symptoms become severe; bad infections, tetany, cardiac failure, etc., or great loss of weight and severe nutritional disturbances are observed. Children who gain weight slowly the first year, later surpass the very fat infants in weight, motility and immunity.

Artificial feeding is usually not promising. Even with a slow, regular gain in weight, the severe cases remain at a disadvantage; infections run a malign course; nutritional disturbances are often fatal.

The severe cases of the exudative diathesis present very unfortunate results even on breast feeding. The weight may remain low for months, not only on account of the defective fat metabolism, but also on account of the repeated infections. In these cases symptoms of the respiratory tract are prominent. They are doubly harmful; the child takes less food and the infection lowers the tolerance for the food ingested. These cases must be continued on the breast. Artificial feeding is often fatal. Fatalities may occur on breast feeding but certainly with less frequency. In children not gaining on the breast, fatalities are rare. They are more common in those breast babies who gain rapidly.

Conclusions to be drawn from the literature:

(1) Exudative diathesis should be recognized as a clinical entity.

(2) It is hereditary and congenital and whole families may show evidences of it.

(3) The main symptoms are respiratory and dermal (parts exposed to trauma).

(4) Eosinophilia is very frequently found.

(5) The treatment is essentially protective and dietetic.

Bibliography.

[1] Czerny. Die exudative Diathese. *Jahrb. f. Kinderh.*, 1905, lxi, p. 199.

[2] Czerny. Zur Kenntnis der exudativen Diathese. *Monatschr. f. Kinderh.*, 1905, iv, p. 1.

[3] Czerny. Zur Kenntnis der exudativen Diathese. *Monatschr. f. Kinderh.*, 1907, vi, p. 1.

[4] Czerny. Zur Kenntnis der exudativen Diathese. *Monatschr. f. Kinderh.*, 1908, vii, p. 1.

[5] Hussey. Die exudative Diathese. *Cor. Bl. f. Schweiz. Aerzte, Basel.*, 1905, xxxv.

[6] Hymanson. Remarks on the Exudative Diathesis. *Arch. Pediatrics*, 1907, xxiv, p. 927.

[7] Duckworth. Address on Diatheses. *Lond. Lancet*, 1908, i, p. 699, and *Bull. med. Paris*, 1908, xxii, p. 163.

[8] Grulee. Exudative Diathesis. *Ill. Med. Journ.*, 1908, xiii, p. 658.

[9] Rosenstern. Exudative Diathese und Eosinophilie. *Jahrb. f. Kinderh.*, 1909, lxix, p. 631.

[10] Gerstenberger. Exudative Diathesis and Case Demonstrations. *Cleveland Med. Journ*, 1909, viii, p. 458.

[11] Schütz. Beiträge zur exudativen Diathese. *Deutsch. med. Wchnschr.*, 1910, xxxvi, p. 271.

[12] Sittler. Die Erscheinungsformen der exudativen Diathese und ihre diatetische Behandlung. *Kinder Arzt*, 1910, xxi, p. 241 and p. 265.

[13] Sittler. Die Therapie des Lymphatisch-skrofulosen Symptomkomplexes. (Exudative Diathese.) *Therap. d. ärztl. Praxis*, 1910, x, p. 292.

[14] Von Planta. Die exudative Diathese und das hochalpine Gebirgsklima. *Cor. Bl. f. Schweiz. Aerzte*, 1911, xli, p. 499.

[15] Pfaundler. Ueber kombinierte Krankheitsbereitschaften oder Diathesen im Kindesalter. *Therap. d. Gegenw.*, 1911, lii, p. 289 and p. 361.

[16] Schmidt. Ueber Diathesen, Dyskrasien und Konstitutionen, *Wien, klin. Wchnschr.*, 1911, xxiv, p. 1659.

[17] Duckworth. The Morbid Diatheses, etc. *Practitioner*, Lond., 1912, lxxxviii, p. 1.

[18] Pfaundler. Ueber Wesen und Behandlung der Diathesen im Kindesalter. *Verhandl. d. deutsch. Kong. f. inn. Med.*, 1911, xxviii, pp. 36, 85.

[19] His und Pfaundler. Ueber Wesen und Behandlung der Diathesen. *Deutsche Aerzte-Ztg.*, 1912, pp. 36, 52, 68, 86.

[20] Pfaundler. Kindliche Krankheitsanlagen (Diathesen) und Wahrscheinlichkeitsrechnung. *Ztschr. f. Kinderh.*, 1912, iv, p. 175.

[21] Von Planta. Die kindlichen Diathesen und das alpine Hochgebirge. *Deutsch. med. Wchnschr.*, 1912, xxxviii, p. 1096.

[22] Aschenheim. Eosinophilie und exudative Diathese. *Monatschr. f. Kinderh.*, 1912, xi, p. 269.

[23] Benfey. Eosinophilie und exudative Diathese. *Monatsch. f. Kinderh.*, 1912, xi, p. 241.

[24] Rachmilewitsch. Hautreactionen von Kindern mit exudativen Diathese. *Jahrb. f. Kinderh.*, 1913, n.f. lxxvii, p. 176.

[25] Savini. Le type constitutionnel sympathique ou vasomoteur. *Progress med.*, Par., 1913, xxi, 3 s., p. 82.

[26] Galup. Le lymphatismé, diathese d'anaphylaxie, immunité, etc. *Presse med.*, Par., 1913, xxi, p. 313.

[27] Siegert. Die lymphatische Disposition, exudative Diathese im Säughlingsalter. *Münch. med. Wchnschr.*, 1913, lx., p. 1407.

[28] Aschenheim. Eosinophilie und exudative Diathese. *Verhandl. d. Versamml. d. Gesellsch. f. Kinderh.—deutsch. Naturf. und Aerzte,* 1913, xxix, p. 170.
[29] Krasnogorsky. Exudative Diathese und Vagotonie. *Monatschr. f. Kinderh.,* 1913, xii, p. 129.
[30] Jacobi. Diatheses. *Amer. Med.,* 1913, c. s. xix, n. s. viii, No. 10, p. 643.
[31] Langstein. Erscheinungen von seiten des Magendarmkanales bei der exudativen Diathese. *Münch. med. Wchnschr.,* 1908, No. 15, p. 823.
[32] Helmholz. Eosinophilie Blutkoerperchen und opsonischer Index bei der exudativen Diathese. *Jahrb. f. Kinderh.,* 1909, lxix, p. 153.
[33] Simpson. Infantile Eczema. *Jour. Amer. Med. Assn.,* 1912, lxiii, p. 995.
[34] Putzig. Das Vorkommen und die klinische Bedeutung der eosinophilen Zellen im Säuglingsalter, besonders bei der exudativen Diathese.
[35] Finkelstein. Lehrbuch der Säuglingskrankheiten. 1912, ii, p. 543. H. Kornfeld.
[36] More and Kolb. Schicksal von Ekzemkindern. *Monatschr. f. Kinderh.,* ix, No. 8, p. 428.
[37] Czerny. Exudative Diathese, Skrofulose u. Tuberculose. *Jahrb. f. Kinderh.,* lxx, No. 5, p. 529.

Literature Not Available.

[1] Stoerk. Beitrag zur Klinik des Lymphatismus. *Mitt. d. Gesellsch. f. inn. Med. und Kinderh. in Wien.,* 1911 x. p. 28.
[2] Pfaundler. Zur Lehre von den kindlichen Diathesen oder Krankheits-bereitschaften. *Jahresk. f. ärztl. Fortbild.,* 1911, vi, pp. 3, 22.
[3] Ventura. La diatesi essudative. *Riv. di. clin. pediat.,* 1909, vii, p. 473.
[4] Velasco Blanco. Diathesis exudativa. *Gac. med. d. Sud. de Espana.,* 1912, xxx, pp. 31, 53.
[5] Svarc. Eksudativna diateza. *Lijee. vijesnik. u. Zagrebu.,* 1912, xxxiv, p. 86.
[6] Kovacs. Exudative Diathesis. *Gyogyaszat,* Budapest, 1912, lii, p. 150.
[7] Sittler. Die exudative-lymphatische Diathese. Würzb., 1913, O. Kabitzsch.

(To be continued)

LICHEN PLANUS ACCOMPANIED BY BLEB FORMATION.

By Douglass W. Montgomery, M.D., San Francisco.

Lichen planus is an eminently papular disease, the papules of which have a characteristic shape and color, and rarely undergo any more advanced pathological change, as into vesicles or blebs. Rasch is the only author with whom I am acquainted, who finds vesicular attacks frequent in this disease. In a paper read before the Scandinavian Society for Dermatology, he stated that he found vesicles in one quarter of his cases in Copenhagen.[1] The occurrence of this phenomenon gives rise to very little additional trouble, nor does it portend a grave state of affairs, as was at one time thought. It is, however, interesting because of its rarity, because of the mistakes it may occasion in diagnosis, and because of the pathological substratum upon which, in some instances, it seems to depend.

Case Report.

Through the kindness of Dr. F. R. Orella, I was called, July 23rd, 1914, to see a Spaniard, 87 years of age, suffering from typical lichen planus of the body and limbs, with a heavy white patch of the same eruption in the right cheek pouch. He had a dry, deep red, coated tongue, he was constipated, and there was much gas in the bowels, with an evenly distributed hypertympany over the whole abdomen. At times he suffered from headache, but his general health was good, and he was thin and spare, as comported with his age. He had a dark complexion, and temperamentally was alert, active and nervous.

Means were instituted to clean out his alimentary tract, and a coal tar lead application was ordered for his skin. Under this he improved.

On August 15th, 1914, I was again called to see the patient, during Dr. Orella's absence, and found that although the upper limbs and upper part of the trunk had cleared, a typical eruption was present on the thighs and on the lower part of the trunk. On the patient's legs, together with typical lichen planus papules, there were a great number of blebs. They varied greatly in size, from a half a hen's egg to a small blister. These lesions seemed to arise as blebs from the skin, with very little inflammatory reaction, and could not be made out to develop from preëxisting papules. The contents were serous; some were purple, others, the majority, were citron-yellow. The blisters appeared at irregular intervals, some were fresh, others had evidently been present some time, while others had dried down. There was very little itchiness. The soles were not affected.

Inquiry elicited a rather interesting state of affairs in an alimentary way. When his bowels were loose, he passed the fæces in bed, so for convenience' sake the nurse kept him constipated. On the other hand, with the idea of building him up, he was fed several times a day, and

principally on soft, easily fermentable food. For instance, he was given mush in the morning, a dish he was not used to, and like many elderly people he gulped down his food, and the nourishment he was given was the kind that could be gulped. The consequent intestinal fermentation accounted for the severity of the eruption. Under regulation of the bowels and more reasonable feeding, the lichen subsided.

Dr. Orella told me that the blebs were followed by depigmentation and that subsequently the skin resumed its normal color. Kaposi first drew attention to this peculiarity that he said was characteristic of the lichen bleb.[2] Indeed, Bettmann saw the papules followed by hyperchromia and the blebs by depigmentation in the same patient.[3]

It is strange that clinical vesiculation is not frequent, because histological vesiculation is almost constantly present in the lichen papule.

The first phenomenon noticed in the spot, when a lichen papule is about to develop, is a small, round celled infiltration about the small blood vessels in the corium, that goes on to a dense, small, round celled infiltration in the upper part of the corium and in the papillary layer. This infiltration is distinguished by its density, and by its sharply defined level base. Just above the papillary layer there is cleavage of the epithelium, away from the papillary layer, or this cleavage may occur just above the first layer of epithelial cells, leaving the latter still attached to the papillæ. This space is filled with fibrin, some small round cells and a few epithelial cells, showing plainly that it is not an artefact, but a true histological vesicle. Clinically the presence of this structure would never be guessed, as the lichen papule is remarkable for its solid, substantial, papular appearance. It is likely, however, that in those rare cases in which vesicles and bullæ appear, they sometimes take their inception from this histological vesicle or cleavage. That they do not always do so, however, seems clear from a case reported by Klingmüller, in which the initial eruption was an outbreak of blebs alone, that at first was supposed to be pemphigus, and which cleared up under arsenic given internally.[4]

THE LOCATION OF THE BULLOUS ERUPTION IN LICHEN PLANUS.

In the present instance the bullæ occurred only on the legs. Engman observed them only on the extremities,[5] and in a case described by Buschke, they occurred only on the palms.[6]

DIAGNOSIS.

In lichen planus the occurrence of blebs may be due to the reaction caused by arsenic, which is so often administered in treatment. Clin-

icians have frequently observed that many lichen patients bear arsenic remarkably well, and also that finally, just before involution of the lichen eruption begins, an inflammatory redness of the skin may appear and even bullæ arise. Jadassohn looks upon these symptoms as indicating a specific action of arsenic in this disease.[7] In the present instance no arsenic was administered, so that that cause of error can be excluded. When, however, during the course of a lichen planus eruption, which is under treatment with arsenic, bullæ appear, the wisest attitude is to cease giving the drug, and await the course of events.

As we have seen in Klingmüller's case, lichen planus may be mistaken for pemphigus. Hallopeau and Weill have also reported a case in which bullous outbreaks during several months completely masked the usual eruption.[8] As in pemphigus so in lichen, the mouth symptoms may not alone be present, but may be very severe, as in a case reported by Cattle.[9] In every case of pemphigus, therefore, the mouth should be searched for the curious reteform lesions of lichen and for papules, and the skin should be carefully gone over for the characteristic papules.

At a meeting of the Philadelphia Dermatological Association, May 8th, 1911, Davis reported a bullous eruption, possibly erythema multiforme, that followed a generalized lichen planus eruption.[10]

As a further illustration of the liability of ascribing a bullous eruption to lichen, that does not properly belong to it, Hutchins reported a vesiculo-bullous outbreak of an infective nature, that supervened in lichen planus. This infective eruption cleared up promptly on administering an injection of 15,000,000 staphylococci that had been grown from the bullæ.[11] Whether the disappearance was due to the vaccine or was spontaneous is, of course, undecided; its very transitory nature, however, was unlike lichen.

In the light of the above facts, therefore, when a bullous eruption appears in the course of a lichen planus, we first think of an arsenical reaction, then of some adventitious disease, such as erythema multiforme, as in Davis' case, or of a bullous impetigo as in Hutchins' case, or of the coincidence of lichen planus and pemphigus, which would be very rare indeed, as between a disease which is not common, lichen planus, and a disease which is very rare,—pemphigus.

In considering of what nature a purely bullous disease may be, we must not now come to the conclusion that it is a pemphigus, even though it affects the mouth, as pemphigus often does. According to Klingmüller's experience we must think of the possibility of its being lichen planus—a disease that also often affects the mouth.

My case, related above, is what one might call a normal instance of

bullous development in lichen planus; subsequently a patient came to the office with a small vesicular type, a description of which I have never seen.

A woman, 50 years of age, the wife of a physician, consulted me Sept. 28, 1915, on account of an eruption that had been troubling her for a year. She showed me small red spots on the forearms and in other situations, upon each of which a vesicle would develop. These the patient would open, and the lesion would settle down to a light red, scaly point of pinhead size or slightly larger. If scratched, or if the patient became very warm, these would itch, and she had formed quite a habit of opening them, as if to relieve a discomfort.

While noting the above details and wondering what could be the nature of the trouble, my eye lit on some characteristic lichen papules. A further search showed many such papules on the legs, one on the chest and a group on the abdomen. There was also a group of papules in the left cheek pouch that showed the characteristic lacework appearance so frequently met with in this situation. Her tongue was normal.

Under treatment and regulation of her diet, which was faulty in regard to an overload of milk fat and fructose, she improved in all respects in about equal measure; that is to say, the papules, the vesicles and the mouth lesions. To my mind all these symptoms were expressions of one disease, lichen planus.

The only observation I can find paralleling this is made by Petges,[12] who reported a case in which an acute generalized lichen planus was accompanied by some miliary lenticular bullæ about the malleoli.

REFERENCES.

[1] Abst. in *Ann. d. Dermat. et d. Syph.*, 1910, p. 411. Bang, who abstracted the above, remarked of Rasch's article that the results were quite different from those generally recognized.

[2] Quoted by Dr. F. Tamm. Ueber das Auftreten von Blasen bei Lichen ruber planus. *Dermat. Ztschr.*, 1915, p. 402.

[3] BETTMANN. Lichen ruber pemphigoides. *Dermat. Ztschr.*, 1901. Quoted by F. Tamm, *loc. cit.*, p. 403.

[4] KLINGMÜLLER, VICTOR. Ueber Lichen ruber verrucosus vegetans. *Arch. f. Dermat. u. Syph.*, May, 1912, p. 523.

[5] ENGMAN, M. F. A Case of Bullous Lichen Planus. *Jour. Cutan. Dis.*, 1904.

[6] BUSCHKE. *Arch. f. Dermat. u. Syph.*, 1903, p. 279. Quoted by Dr. F. Tamm, Ueber das Auftreten v. Blasen bei Lichen ruber planus. *Dermat. Ztschr.*, 1915. p. 402.

[7] Dermatologie von J. Darier. 1913. p. 94.

[8] HALLOPEAU ET WEILL. Sur un nouveau cas de lichen de Wilson pemphigoïde. *Ann. d. dermat. et d. syphil.*, 1906, p. 377.

[9] *Brit. Med. Jour.*, June 13, 1914, p. 1292.

[10] Report in *Arch. f. Dermat. u. Syph.*, Dec., 1912, p. 302.

[11] HUTCHINS, M. B. *Jour. Cutan. Dis.*, Oct., 1912.

[12] PETGES. *Jour. d. med. de Bordeaux*, 1912, No. 14; Abst. in *Arch. f. Dermat. u. Syph.*, Dec., 1912, p. 373.

DIFFERENTIAL BLOOD COUNTS IN PARASITIC SKIN DISEASES AND THEIR POSSIBLE SIGNIFICANCE.

By Albert Strickler, M.D., Philadelphia.

Assistant Dermatologist, Philadelphia General and Samaritan Hospitals; Instructor in Dermatology, Philadelphia Polyclinic and College for Graduates in Medicine.

This study was undertaken with the hope of throwing some light on the clinical blood picture of ringworm of the scalp, and also as far as possible to interpret the blood findings of favus and pediculosis of the body. A survey of the studies in hæmatology, in as far as they have a bearing on the studies of skin affections, discloses the fact that effort has been directed towards a study of a few cases of a large number of diseases of the skin, rather than limiting one's self to the interpretation of a large number of blood counts of one or several affections of the skin.

As example of this, one may quote the article of Herbert French (Guy's Hospital Reports, 1904, p. 81), in which there is recorded a study of the blood of 90 patients suffering from various diseases of the skin. Coming to more recent works we have the publication of Engman and Davis, of St. Louis, published in The Journal for February, 1915, in which the authors present an excellent report of blood counts in a wide variety of dermatoses, but unfortunately but a few cases of each disease are represented.

It was in 1912, in the February issue of The Journal, that Dr. Jay F. Schamberg and the author reported a study of the differential blood count of 47 cases of scabies, with special reference to eosinophilia. In this paper it was stated that 38 out of the total number of cases studied, or over 80%, showed 5% or more of eosinophiles. The maximum count was 19%, but there were also cases exhibiting 14%, 12% and 10%. The average eosinophilia in the entire series was 7%. The cases exhibiting no increase of eosinophiles were, for the most part, patients with scant eruptions and in one or two, the diagnosis was doubtful. In discussing this paper, before the Philadelphia Pathological Society, Dr. J. A. Kolmer reported that he had examined 18 cases of scabies, in which the average eosinophile count was 5.9%.

In our study of ringworm of the scalp, the predominating feature in the blood picture was a large increase in the vast number of instances of the small lymphocytes. In reckoning the increase, a standard of comparison was adopted, and the standard we preferred was the one adopted by Cabot, in his work, "Clinical Examination of the Blood," which is as follows:—

(a)	Small lymphocytes	20 to 30%
(b)	Large lymphocytes	4 to 8%
(c)	Polymorphonuclear neutrophiles	62 to 70%
(d)	Eosinophiles	½ to 4%
(e)	Mast cells	¼ to .9%

In addition, a word must be said about the division of the lymphocytes into small and large.

About five years ago, when the author did a great deal of work in the blood picture in tuberculosis, we were often struck with the circumstance that there were a great many cells which were on the boundary line between the large type and the small type, and which one observer would place in one category and another observer in a different classification. We feel that some emphasis must be placed on this observation.

In our study of the blood picture of ringworm of the scalp, we divided our cases into two groups: those cases that were treated with the aid of vaccines and those which were treated only by local measures. In this study the slides were stained with the eosin and hæmotoxylin method; which we find easy and reliable. In the vast majority of instances, 200 cells were counted.

A review of the literature bearing on the differential blood picture in ringworm of the scalp, discloses the following facts:

TABLE I.

CASE NO.	AGE.	TINEA TONSURANS.	OTHER ILLNESS.	SMALL LYMPHO-CYTES.	LARGE LYMPHO-CYTES.	POLYMORPHO-NUCLEARS.	COARSELY GRANULAR EOSINO-PHILES.
1	11	Patch in front of ear; present some weeks	None	30	10.4	59	0.6
2	6	Patch covering one-third of head. Duration, fortnight	"	28	8.8	62	1.2
3	7	Patches covering one-fourth of scalp. Duration, five weeks	"	49	6.7	43	1.3
4	5	Several patches; present two months	"	39	5.3	54	1.7
5	10	Several patches. Duration, six weeks	"	36	6.2	56	1.8
6	7	Extensive. Duration, two months	"	32	18.1	48	1.9
7	11	Extensive. Duration, five weeks	"	38	10.6	48	3.4
8	5	Several large patches. Duration, two months	"	40	11.5	45	3.5
9	7	Extensive. Duration, six weeks	"	30	5.5	60	4.5

In this table, taken from the article by Herbert French, the average percentage of small lymphocytes was 36.

TABLE II.—BLOOD PICTURE OF PATIENTS WITH RINGWORM WHO HAVE HAD VACCINE TREATMENT.

	NAME.	DIAGNOSIS.	DURATION.	EXTENT.	TREATMENT.	BLOOD PICTURE.	
1.	C. D.	Ringworm of scalp	7 mos.	Two small patches	Vaccine	Poly. 62.5 Eosin. 1.	Lympho. 36.5.
2.	E. W.	" " "	3 yrs.	General	"	Poly. 47.5 Mono. 2.	Lympho. 49.5. Eosin. 1.
3.	D. C.	" " "	1 yr.	"	"	Poly. 54. Mono. 1.5 Trans. .5	Lympho. 40. Eosin. 4.
4.	H. B.	" " "	9 mos.	"	"	Poly. 56.5 Mono. 1.	Lympho. 41. Eosin. 1.5
5.	S. S.	" " "	—	"	"	Poly. 54.5 Mono. 3.	Lympho. 42. Eosin. .5
6.	M. C.	" " "	1 yr.	"	"	Poly. 57.5 Mono. 4.	Lympho. 42. Eosin. 5
7.	A. O.	" " "	4 mos.	"	"	Poly. 68. Mono. 1. Trans. 1.	Lympho. 25. Eosin. .5
8.	A. G.	" " "	—	Several patches	" "	Poly. 60. Mono. 1. Trans. 3.	Lympho. 31. Eosin. 5.
9.	E. S.	" " "	—	General	"	Poly. 40. Mono. 2. Trans. 2.	Lympho. 24. Eosin. 1.
10.	H. L.	" " "	1 yr.	"	"	Poly. 49. Mono. 2.	Lympho. 49.
11.	E. G.	" " "	3 yrs.	"	"	Poly. 49.	Lympho. 51.
12.	H. H.	" " "	1 yr.	"	"	Poly. 67. Mono. 3.	Lympho. 30.
13.	E. T.	" " "	—	—	"	Poly. 56. Mono. 2.	Lympho. 41. Eosin. 1.
14.	J. W.	" " "	1 yr.	General	"	Poly. 43. Mono. 6.	Lympho. 50. Eosin. 1.
15.	R. L.	" " "	—	—	"	Poly. 62. Eosin. 4.	Lympho. 34.
16.	B. G.	" " "	—	—	"	Poly. 64. Mono. 8.	Lympho. 26. Eosin. 2.
17.	E. W.	" " "	—	Small patches	" "	Poly. 43. Mono. 4. Trans. 1.	Lympho. 49. Eosin. 3.
18.	A.	" " "	—	—	"	Poly. 44. Mono. 1.	Lympho. 44. Trans. 1.
19.	A.B.	Tinea kerion	1 yr.	General	"	Poly. 60.	Lympho. 40.
20.	A.	Ringworm of scalp	—	—	"	Poly. 51. Mono. 2.	Lympho. 46. Eosin. 1.
21.	T. D.	" " "	—	—	"	Poly. 55. Mono. 2.	Lympho. 42. Trans. 1.
22.	J. J.	" " "	Several months	—	"	Poly. 62. Mono. 5.	Lympho. 31. Eosin. 2.
23.	H. M.	" " "	—	—	"	Poly. 59. Mono. 3.	Lympho. 34. Eosin. 4.
24.	T. S.	" " "	—	—	"	Poly. 48. Mono. 3.	Lympho. 47. Eosin. 2.
25.	M. J.	" " "	1 yr.	General	"	Poly. 54. Mono. 2.	Lympho. 37. Eosin. 7.
26.	T. J.	" " "	1 yr.	"	"	Poly. 55. Mono. 6.	Lympho. 36. Eosin. 3.
27.	H. D.	" " "	1 mon.	—	"	Poly. 60.	Lympho. 40.

There were 27 cases treated with ringworm vaccine. The average percentage of small lymphocytes in this series was 38.8%. The highest individual count was 51%. In this series only four cases did not show an increase of small lymphocytes.

TABLE III.—BLOOD PICTURE OF PATIENTS WITH RINGWORM WHO HAVE HAD LOCAL TREATMENT.

	NAME.	DIAGNOSIS.	DURATION.	EXTENT.	TREATMENT.	BLOOD PICTURE.	
1.	R. L.	Ringworm of scalp	—	—	Local	Poly. 62. Eosin. 4.	Lympho. 34.
2.	B. G.	" " "	—	—	"	Poly. 64. Mono. 8.	Lympho. 26. Eosin. 2.
3.	E. W.	" " "	—	Small patches	"	Poly. 43. Mono. 4. Trans. 1.	Lympho. 49. Eosin. 3.
4.	A.	" " "	—	—	"	Poly. 44. Mono. 1.	Lympho. 44. Trans. 1.
5.	A. B.	Tinea kerion	1 yr.	General	"	Poly. 60.	Lympho. 40.
6.	A.	Ringworm of scalp	—	—	"	Poly. 51. Mono. 2.	Lympho. 46. Eosin. 1.
7.	T. D.	" " "	—	—	"	Poly. 55. Mono. 2.	Lympho. 42. Trans. 1.
8.	J. J.	" " "	Several mos.	—	"	Poly. 62. Mono. 5.	Lympho. 31. Eosin. 2.
9.	H. M.	" " "	—	—	"	Poly. 59. Mono. 3.	Lympho. 34. Eosin. 44.
10.	T. S.	" " "	—	—	"	Poly. 48. Mono. 3.	Lympho. 47. Eosin. 2.
11.	M. J.	" " "	1 yr.	General	"	Poly. 54. Mono. 2.	Lympho. 37. Eosin. 7.
12.	T. J.	" " "	1 yr.	"	"	Poly. 55.	Lympho. 36.
13.	H. D.	" " "	1 mon.	—	"	Poly. 60.	Lympho. 40.
14.		" " "	—	—	—	Poly. 36. Mono. 7.	Lympho. 52. Eosin. 5.
15.		" " "	—	—	—	Poly. 52. Mono. 3.	Lympho. 45.
16.		" " "	—	—	—	Poly. 63. Mono. 2.	Lympho. 30. Eosin. 5.
17.		" " "	—	—	—	Poly. 60. Mono. 3.	Lympho. 37.
18.		" " "	—	—	—	Poly. 53. Mono. 6.	Lympho. 40. Eosin. 1.
19.		" " "	—	—	—	Poly. 65. Mono. 2. Trans. 1.	Lympho. 29. Eosin. 3.
20.		" " "	—	—	—	Poly. 59. Mono. 5.	Lympho. 34. Eosin. 2.
21.		" " "	—	—	—	Poly. 69. Mono. 1.	Lympho. 30.
22.		" " "	—	—	—	Poly. 62. Mono. 5.	Lympho. 33.
23.		" " "	—	—	—	Poly. 45. Mono. 3.	Lympho. 52.

From this series of 23 patients, all of whom received only local applications to their ringworm patches of the scalp, it can be shown that the average percentage of small lymphocytes was 37.2%. The highest individual count was 52%. Out of this series, 6 patients, or 26%, showed no increase in the small lymphocytes, while the remaining cases showed a count varying from 32 to 52%.

TABLE IV.—BLOOD PICTURE IN PEDICULOSIS CORPORIS.

NAME.	DIAGNOSIS.	BLOOD PICTURE.			
1. F. H.	Pediculosis corporis	Poly. 82.	Lympho. 18.		
2. J. B.	" "	Poly. 70.	Lympho. 27.	Mono. 3.	
3. G. A.	" "	Poly. 69.	Lympho. 23.	Mono. 3.	
		Eosin. 3.	Trans. 2.		
4. C. F.	" "	Poly. 57.	Lympho. 35.	Mono. 3.	
		Eosin. 5.			
5. V. H.	" "	Poly. 69.	Lympho. 23.	Mono. 5.	
		Eosin. 3.			
6. M. S.	" "	Poly. 57.	Lympho. 34.	Mono. 7.	
		Eosin. 2.			
7. B. S.	" "	Poly. 69.	Lympho. 29.	Mono. 2.	
8. S. H.	" "	Poly. 64.	Lympho. 24.	Mono. 9.	
		Eosin. 3.			
9. M. J.	" "	Poly. 65.	Lympho. 30.	Mono. 3.	
		Eosin. 2.			
10. R. C.	" "	Poly. 72.	Lympho. 19.	Mono. 4.	
		Eosin. 5.			
11. B. H.	" "	Poly. 75.	Lympho. 18.	Mono. 3.	
		Eosin. 4.	Trans. 1.		
12. J. R.	" "	Poly. 77.	Lympho. 23.		
13. F. S.	" "	Poly. 72.	Lympho. 25.	Mono. 3.	
14. G. S.	" "	Poly. 85.	Lympho. 12.	Mono. 3.	

We studied 14 cases of pediculosis corporis. Their blood picture shows some very few slight and inconstant variations from the normal. In three cases of this series there was a very slight eosinophilia. A close study of the table shows that the blood counts approach closely the normal blood picture.

There were four cases of favus in our series with the following blood picture.

TABLE V.

Case 1.	Poly. 66%	Lympho. 34%		
Case 2.	Poly. 64%	Lympho. 35%	Trans. 1%.	
Case 3.	Poly. 54%	Lympho. 29%	Mono. 6%	Eosin. 11%
Case 4.	Poly. 45%	Lympho. 52%	Mono. 3%	

In this series, three out of the four cases showed an increase of lymphocytes. The number of cases is, however, too few to permit of any definite conclusions, but these cases, added to those that may be collected in the future, may make it possible to establish a definite blood picture for this disease.

Conclusions.

1. From a study of our own work and a résumé of the literature, we may conclude that in ringworm of the scalp there is an increase in the blood, of the small lymphocytes.

2. That the average count for 60 cases was 37.4% of lymphocytes.

3. That in our series representing 50 cases, 20% did not show any increase in the small lymphocytes.

4. That there is a slightly greater increase in the small lymphocytes in those patients treated by vaccines, than in those patients receiving local treatment only. This difference is, however, small.

5. That this increase in the small lymphocytes may be of some value in the differential diagnosis between ringworm of the scalp and other affections.

6. That pediculosis of the body, unlike scabies and grain itch, does not show any change in the blood picture from that seen in the average normal patient.

7. That in the four cases of favus studied, there seems to be an increase of small lymphocytes, but the cases are too few to permit of any conclusions.

We wish to express out indebtedness to Dr. Trimble and Dr. Finch of the New York Skin and Cancer Hospital and to Dr. Pisko for supplying some of the slides which have made this work possible, and as always, we wish to thank our chief, Dr. Jay F. Schamberg, for his encouragement and support of our efforts.

SOCIETY TRANSACTIONS.

NEW YORK DERMATOLOGICAL SOCIETY.

Regular Meeting, March 29, 1916.

HOWARD FOX, M.D., *President.*

WHITE-SPOT DISEASE. Presented by DR. HEIMANN.

The patient was a young woman, 22 years of age, who was presented last year before the American Dermatological Association as a case of white-spot disease. The speaker said that he was not so sure of the diagnosis, and was considering the possibility of its being a lichen sclerosus, and would be glad to have an expression of opinion by the members. Last spring the microscopic aspect of the case was that of morphœa. She came under treatment for a seborrhœal type of eczema, and not for the spots on her back. There were no subjective symptoms. She had recently been treated with the Kromayer lamp.

DISCUSSION.

DR. SHERWELL referred to two cases he had seen, which did not, however, resemble the case shown. Dr. Johnston, in one (the most marked) had made a biopsy and presented the report. In that case there were several lesions on the neck, larger than a dollar, characterized by nothing save a dead whiteness; no elevation and seemingly no atrophy; no violaceous border or teleangiectases, so common in morphœa. As far as the speaker's memory served, however, they resembled, clinically and pathologically, that disease. They were treated, and under local treatment of a stimulant and resorptive nature, slowly disappeared.

DR. WISE said that a histological examination and careful study were required to differentiate between white-spot disease and lichen sclerosus. It was admitted that in the later stages of white-spot disease and lichen sclerosus even a microscopic differentiation was impossible.

DR. HEIMANN said that when the case was presented before the American Dermatological Association, some of the lesions had the violaceous ring. There were no papules in the margin at that time, suggestive of lichen, but that during the past summer the patient had developed some hyperkeratotic patches. Microscopically, the case corresponded in every point with the case in the article referred to by Dr. Sherwell, which was evidently scleroderma.

CASE FOR DIAGNOSIS (PERSISTENT ERYTHEMATOUS PATCHES OF TRUNK.) Presented by DR. HOWARD FOX.

The patient, Mrs. H., was a business woman, 48 years of age, born in the United States. The eruption first appeared about three years ago, and had persisted without much change to the time of presentation. It consisted of two

irregular shaped patches upon the left side of the trunk, the larger patch measuring about eight inches in the longest diameter, and the smaller one, about three inches. The smaller patch had appeared about four months ago. The anterior border of the patches was fairly sharply circumscribed, the posterior and upper and lower borders fading gradually into the normal skin. The lesions were pale red, smooth, non-elevated, and upon pressure became lighter in color. Scattered over the larger areas were about a dozen pinhead sized, reddish, elevated, somewhat shiny, smooth, semi-solid elevations. There were no objective evidence of scratching, though the patient stated that at times there was severe itching, and that the appearance of the red patches had been preceded by peculiar subjective symptoms. The patient was well-nourished, but more or less nervous from her occupation as the president of a large manufacturing concern.

DISCUSSION.

Dr. Wise said that he could not make a definite diagnosis, but did not believe the eruption to be angioma serpiginosum, as had been suggested by some. It suggested a possible beginning scleroderma, en band or en plaque.

Dr. Trimble said it was a most interesting case, and he was quite at loss for a diagnosis. He wished, however, to make a suggestion. The case might possibly be one of angioma serpiginosum. He had seen several cases of that affection, and some of them bore some resemblance to this case. The others did not. He was aware that the redness disappeared on pressure, and there were none of the so-called red-pepper grains common in typical cases of angioma serpiginosum. Another possibility was lymphangioma. Several seemingly soft, raised lesions suggested the possibility of lymph vessels, rather deeply seated. While examining the case, these two conditions had occurred to him; the raised lesions made him think of a possible lymphangioma, while the whole general condition made him think of angioma serpiginosum.

Dr. Sherwell said that it had occurred to him at first glance to be a self-inflicted condition, though the woman did not look like an hysteric person. Probably that was not the cause, but *possibly* it was.

Dr. Kingsbury said that the suggestion made by Dr. Fox had occurred to him also, especially on account of the interest which the woman showed in the case, but later he had ruled that out. He agreed with Dr. Wise that it should not be regarded as an angioma serpiginosum. The case would bear careful watching; possibly it might later develop some malignant change.

Dr. Howard Fox said that the possibility of an artificial eruption had not occurred to him. The patient was a busy woman, engaged in conducting a large manufacturing concern, and did not appear to be the type of person to go from one physician to another in search of sympathy. In fact, she had not applied directly for treatment, not considering the eruption of much importance. The possibility of a premycotic eruption had occurred to him at her first visit.

PARAFFINOMA. Presented by Dr. Howard Fox.

The patient, Mrs. D., was a woman, about 40 years of age, born in the United States, an authoress by profession. About two years ago it was suggested to the patient that her appearance might be improved by having a little paraffine injected in her cheeks. She accordingly consulted a physician, and submitted to injections of some liquid substance (presumably paraffine) at both angles of the mouth. She was satisfied with the result of this procedure until about six months later, when she noticed a swelling over the left malar prominence.

A few weeks later she again consulted the physician, who she claims, made some incisions inside the cheeks and upper lip, which had also become swollen. There was considerable hæmorrhage at the time, but no improvement followed this operation. A few days later the physician, she stated, again injected some fluid which he said would dissolve the paraffine. The swelling then subsided, until about three months ago, when it again appeared, and she consulted a "specialist," who treated her face for an hour with some hot mud applications. On the following day the entire face became severely swollen, and had remained in this condition up to the time of presentation. On examination, she presented a swollen. lumpy condition of the cheeks, lips and submaxillary region. There were five more or less distinct, hard, somewhat tender, subcutaneous swellings over the malar prominences, at the angles of the mouth, and at the angle of the right jaw. The largest mass was about an inch and a half long, by an inch wide. The skin covering the masses was dusky red, as a rule not movable over the tissue beneath. Some of the masses were movable, others incorporated with the underlying tissues. The upper lip was almost immobile. The swelling had also extended into the cavity of the mouth, interfering somewhat with eating and slightly with speech. The patient was well-nourished, and according to her statement, had a rather nervous disposition.

DISCUSSION.

Dr. Philip W. Huntington (by invitation) said that it would appear that the swelling was in the infiltrated tissue surrounding the paraffine injection, and he did not think that anything could be done to relieve the patient.

Dr. Kingsbury thought it was a very good case to leave alone. Incising the tumors, he thought, would be little short of malpractice.

Dr. Sherwell said he had seen several similar cases, and had never known anything to be of benefit. Extreme heat, to smooth it down, had been suggested, and it had been tried, but he had seen no good resulting. He then cited a case in which a woman of wealth had tried to have some wrinkles removed from her face by paraffine injection, the treatment resulting in a dreadful deformity. There was no way of expressing the paraffine, or cutting open the tissues and getting rid of the material by expression, etc.

Dr. Wise said that the only case of the kind that he had seen was at the Post-Graduate Hospital, about six years ago. The patient developed a sarcoma at the site of injection and died shortly after.

Dr. Nilson (by invitation) said that he had seen the patient some months ago, before she came to Dr. Fox's service at the Polyclinic Hospital, and there was very little inflammation at that time. Since then, there had developed a considerable amount of productive inflammation, without infection. The mucous membrane of the mouth was much congested. He was inclined to agree with Dr. George Henry Fox's suggestion, to increase the local circulation by hydrotherapeutic measures.

Dr. Howard Fox said that the consensus of opinion seemed to be that the condition should be left alone. The patient had consulted several surgeons of high standing, who had expressed this opinion. In regard to the possible benefit from hot applications, he said that the trouble seemed to have started almost immediately after the hot mud treatment. He thought that further applicaions of heat might make the condition worse by the production of sloughing. He had seen a case, in a young woman, where the masses of paraffine had sloughed out at different points and had given the appearance of a scrofuloderma.

CONGENITAL HYPERTRICHOSIS OF SACRAL REGION. Presented by Dr. Howard Fox.

The patient, J. G., was an Italian boy, 11 years of age. Upon the sacral region there was a congenital growth of straight, black hair, about eight inches long, arising from apparently normal, non-pigmented skin, and falling below like an apron. The growth arose from a triangular area with the apex in the gluteal fold and the base above. The sides of this triangle measured about four and a half inches, and the base six and a half inches. The boy's mentality was somewhat deficient.

LUPUS PERNIO. Presented by Dr. Clark.

Dr. Clark said that probably some of the members had seen this patient before. It was a typical example of lupus pernio, and was one of those cases which had invariably been benefited by the injection of tuberculin. The young man had not reported for over a year, but presented an outbreak on the hands, when shown before the Society. He showed the superficial, punched-out scars on the ears and hands, from former lesions. He complained of a stinging, burning, hot sensation in the hands, which were stiff and uncomfortable. The lesions were about the same as when shown before, excepting that they had not yet reached the stage of central necrosis; but the backs of the hands and the fingers displayed the typical infiltrated areas. He returned for treatment, asking for more tuberculin. The patient lived under the best possible circumstances, being out-of-doors a great deal, and going to the seashore in summer. He had taken cod liver oil and various tonics, but nothing helped him in these attacks, excepting the tuberculin, to which he responded immediately. Four years before this condition developed, he had tuberculous glands of the neck, and the eruption followed some six months later.

ICHTHYOSIS HYSTRIX. Presented by Dr. Howard Fox.

The patient, Walter S., was a boy, 10 years of age, born in New York State. He was the only member of his family to present any abnormality of the skin. He had never attended school, and was mentally backward. He presented a very extensive symmetrical eruption of the trunk and extremities, consisting of marked papillary and verrucous elevations. Some of the lesions formed solid, irregular patches, while others displayed a more or less linear tendency. At least four-fifths of the body surface was involved, most of the face and some areas of the buttocks and backs of the arms and legs being spared. The lesions were especially thick in the axillary and inguinal regions. Between the diseased areas the skin was apparently normal, and did not present the appearance of ichthyosis simplex. The color was a dirty mixture of gray and yellow. The palms and soles were diffusely thickened. Small areas had been treated by carbon dioxid snow and by radium, marked benefit following both of these methods of treatment.

DISCUSSION.

Dr. Winfield asked if Dr. Fox was going to continue to use radium on the case.

Dr. Fox replied that it seemed to be the only thing that seemed to do any good so far, and he intended to try it.

Dr. Wise said they had been treating a similar case at the Vanderbilt Clinic with the X-ray, using a very carefully measured dosage, but much to his surprise the treatment had no curative effect on the condition.

ELEPHANTIASIS. Presented by Dr. Howard Fox.

The patient, Max N., was a man, 31 years of age, born in Germany, a sign-painter by trade. He came to America eleven years ago, having previously lived in Germany and Russian Poland. He had never visited the tropics. There was no family history of tuberculosis. His parents died of unknown diseases. Two brothers and three sisters were living and healthy. He had suffered from some of the usual diseases of childhood. At seven years of age he had been kicked in the left femoral region by a young playmate. On the following day, there was a swelling, the size of an egg, and on the fourth day it was opened by a physician and some fluid was evacuated. The lesion then promptly healed. About six years later, some papillomatous lesions appeared on the knee and dorsal surface of the left foot. They remained unchanged for four years, and were then treated by excision and skin grafting. About six years after this operation the "edges of the skin grafts began to open up," and two and a half years ago, the left foot and leg, as high as the knee, began to become enlarged and to assume the appearance of elephantiasis. About this time he suffered from attacks of redness of the skin of the thighs, and chills and fever. These attacks appeared at first at weekly intervals, and later every second or third day. They were entirely relieved by taking medicine. The patient was recently treated at the Washington University Hospital, in St. Louis, where he was given tuberculin injections, without benefit.

On examination, the left foot and leg presented an elephantiasic enlargement, the left leg measuring 16, 11¼, and 11½ inches at the calf, ankle and dorsum of the foot, respectively, as opposed to 13, 8 and 9¾ inches on the normal leg. Upon the dorsal surface of the toes especially, and also upon the sole and instep, were numerous reddish, papillomatous elevations, the largest being a half inch in width. They gave rise to some discharge with a disagreeable odor. On the dorsum of the left foot and inner aspect of the knee were areas that had formerly been skin grafted. On both sides of the knee were elevated, partially ulcerated, painless lesions, suggesting the appearance of tuberculosis. There were also several rounded, deeply depressed old scars upon the leg. The general health appeared to be good. The Wassermann test was negative, von Pirquet positive. A radiogram of the leg showed no change in the bones.

DISCUSSION.

Dr. Sherwell said that presumably the lymphatics had been disturbed, so that there was no recurrent flow of the lymphatic fluid. That was his idea of the causation of the elephantiasis in lepra Arabicum.

ECZEMA SEBORRHŒICUM, WITH SOME LESIONS RESEMBLING PREMYCOTIC GRANULOMA FUNGOIDES. Presented by Dr. Trimble.

The patient was a man, aged 41, born in the United States. He presented an extensive seborrhœic eczema of the scalp and numerous lesions on body. The lesions on the back were scaly, infiltrated and varied in size from a silver dime to a quarter. They were brownish red in color and itched intensely. The case was shown on account of the lesions on the back resembling premycotic granuloma fungoides.

DISCUSSION.

Drs. Wise, Schwartz, Winfield and Sherwell thought that one should consider the possibility of a premycotic condition, rather than a seborrhœic eczema.

Dr. George H. Fox said that the case showed various phases of ordinary eczema, and he doubted if it would ever develop into mycosis fungoides.

Dr. Clark was inclined to favor the diagnosis of seborrhœic eczema.

Dr. Trimble said he was glad to find that practically every one agreed with him. He himself regarded it as a suspicious case.

CICATRICES OF BODY AND SCALP FROM TUBERCULOSIS. Presented by Dr. Trimble.

The patient was a man, aged 50, born in Russia. He was apparently in good health up to eleven years ago. The first lesion was noticed on the scalp. From the history given it seemed that the lesions which later made their appearance were "cold abscesses," as the patient's body showed great numbers of scars, varying in, size, shape and depth. He had been in Riverside Hospital for lung trouble, and was also a patient at the Mount Sinai Hospital. The only active lesions were on the scalp. In this location, there were two fungoid, granulating lesions, about the size of hazel nuts, having the character of pyogenic granuloma.

LICHEN ACUMINATUS. Presented by Dr. Heimann.

The patient had been presented at the January meeting as a case of lichen ruber acuminatus, and some of the members at that time thought it lichen spinulosus. The speaker said that he still adhered to his former opinion. Microscopic study favored the diagnosis of lichen acuminatus.

DISCUSSION.

Dr. Wise said he had not seen enough cases to judge, but that those he observed were usually in children, and presented more widespread, closely aggregated papules, forming patches which became scaly and lichenified. He could not say whether or not this case would prove to be lichen ruber acuminatus, but was inclined to think it was rather a lichen spinulosus. He called attention to a picture in Dr. Piffard's book, which, to a certain extent, resembled this case.

Dr. Trimble said that when he last saw the case he was inclined to consider the condition similar to that described as lichen spinulosus. He did not think that it was lichen ruber acuminatus, for one or two reasons. Of course, it was still in the early stage, and it was difficult to say what might develop later. One did not often see lichen ruber acuminatus in its very early stage, and it may begin in the manner shown in this patient and develop patches later. The lesions in this case were so discrete and scattered, and each one presented the little projecting spine so distinctly, that in his opinion the case was one of lichen spinulosus. The fact that there were no patches and no furfuraceous scaling, made him think it was not lichen ruber acuminatus.

Dr. Clark also thought it was not lichen ruber acuminatus. Some of the lesions on the back and phalanges suggested it, but the whole picture was very different. There did not seem to be much thickening or keratotic condition of the palms, and the patches were discrete. He was inclined to agree with the diagnosis of lichen spinulosus.

Dr. G. H. Fox objected to the term "lichen ruber acuminatus," inasmuch as there was no lichen ruber which was not acuminate. It was true, he said, that Kaposi, under the erroneous belief that lichen ruber and lichen planus were clinical forms of one disease, used the terms lichen ruber acuminatus and lichen ruber planus; but at the present time few, if any, believed that these

diseases had any relation to each other except in name. He added that it seemed strange to think that Hebra, with his large experience, never saw or certainly never described lichen planus until Wilson wrote about it. It seemed equally strange that Wilson, who gave a most accurate description of lichen planus, said nothing about lichen ruber, the disease described by Hebra. Many years after Hebra described lichen ruber, Besnier called the disease "pityriasis rubra pilaris," a long and unnecessary name which had, unfortunately, been accepted by many dermatologists.

The speaker said that Dr. Heimann's case looked at first glance like the papular form of lichen ruber, but the lesions were pale and presented horny plugs, instead of soft, red, scale-tipped papules. He thought lichen spinulosus was a good name to apply to the eruption, and felt sure that it would never develop the squamous and rugous surface often seen in chronic lichen ruber.

Dr. Sherwell did not consider it a case of lichen ruber, as the lesions were so flattened down and improved in so short a time, by treatment. As Dr. Fox had said, these cases were seldom seen early, and they lasted a long time. They did not cause much itching or subjective symptoms, as a rule. He did not feel that he was prepared to make a diagnosis, but it did not seem like a typical case of lichen ruber acuminatus, such as those he had seen.

Dr. Heimann agreed with Dr. Fox's remarks on nomenclature. The only true lichen that he knew was lichen planus. In the present case there were lesions on the skin which might be those of either lichen spinulosus or acuminatus, and there were also other lesions in the mouth. It was a problem how to interpret their association. When Kaposi identified the pityriasis rubra pilaris and the lichen acuminatus, and also established the identity between Wilson's lichen planus and the so-called lichen ruber planus, he said there were mixed forms of the latter, with lesions which might resemble either disease, associated with lesions on the buccal mucosa. How to bring all the features of this case into correlation was the question to be settled.

So far as the microscopic anatomy was concerned, the lesions certainly did not suggested lichen spinulosus as much as lichen acuminatus. The plug in lichen acuminatus was in the follicles, as mentioned in all the classical descriptions. In lichen spinulosus the plug was in the upper part of the follicle and extended a millimetre above it, corresponding to keratosis suprafollicularis or keratosis pilaris.

He said that he could not imagine lichen spinulosus in the mucosa, and that the buccal involvement in this case excluded that diagnosis. He thought that lichen acuminatus must begin with uncharacteristic lesions which were small, and that this was such a case. The disease could not begin suddenly with full grown lesions, and on account of the general manifestation in this case, he was inclined to place it in the lichen group, in the broad sense of the word, which included lichen acuminatus.

BULLOUS AND HÆMORRHAGIC ERUPTION BENEATH THE NAILS. Presented by Dr. Howard Fox.

The patient, P. T., was a man, 31 years of age, born in Russian Poland, a farmer by occupation. Five weeks ago he took a position as dishwasher in a restaurant. On the second day, while engaged in his new work, he noticed that the terminal phalanges of the third and fourth fingers of the left hand became swollen and painful, to such an extent that he felt obliged to stop work. On the third day, according to his statement, some clear fluid exuded from beneath the nails. The swelling then subsided and the nail became black. For a week there was no further change, except that the nails gradually became whitish

in color. At the end of this time, all of the other nails, except that of the little finger of the left hand, presented similar changes to those above described.

On examination, all of the nails save that of the little finger of the left hand, showed marked changes. The majority of them were more or less loosened and raised from the nail-beds, in some cases as far back as the matrix. Beneath them could be seen a small amount of blackish, friable material. The nail plates were opaque, of a bluish-gray color, and without lustre. They presented no ridges or pits, and were not brittle. There was no paronychia. The toe nails were not affected. On the skin adjoining one of the nails, a flaccid bulla, a half inch in length, was present. There was no other affection of the skin, either in the neighborhood of the nails or elsewhere on the body.

DISCUSSION.

Dr. George H. Fox said he thought that the use of a strong, hot solution of carbonate of soda might affect the nail-bed without producing much dermatitis of the skin around the nails. The man might have had some tendency to nail disease, acting as a predisposing cause, and the dishwashing may have been merely the exciting cause.

Dr. Sherwell thought it was an exaggerated occupational dermatosis, such as was sometimes seen on washerwomen's hands, until they are taught to clean the matrix thoroughly.

Dr. Wise thought it out of the question that any irritant would produce such a condition of the nails without affecting also the skin of the fingers.

Dr. Kingsbury remarked that the medico-legal aspects of the case seemed to be of rather more interest than the medical features.

Dr. H. Fox said that if the case ever came before the courts there would be a magnificent battle of experts. Ordinarily, he would be inclined to agree with what Dr. Wise had said. He could hardly conceive of an external irritant causing the condition, excepting for the history of the trouble coming on immediately after the occupation. The man had been a farmer, performed this unusual service, and the condition developed immediately after.

PARONYCHIA AFTER OPERATION. Presented by Dr. Howard Fox.

The patient, L. K., was a woman, 31 years of age, born in Germany, a domestic by occupation. She was presented to show the result of an operation for paronychia, described by Drs. Seff and Berkowitz (*Jour. Amer. Med. Assn.*, 1915, lxv, p. 234.) The condition first appeared a year and a half ago, and altogether five fingers had been affected. In the case of two fingers, a permanent cure had followed the use of X-ray; three other fingers, however, being unaffected by the treatment. Temporary benefit had resulted from chrysarobin ointment, and no improvement at all from silver nitrate applications. Three of the nails had been operated upon—the left thumb and middle and index finger-nails of the right hand. The thumb-nail had been operated upon seven months ago, and five months later, a new nail had grown, and all traces of paronychia had disappeared. In the case of the other two nails, the operation had been performed more recently, and the new nails were half grown, the paronychia having also entirely disappeared. The new nails were all entirely normal in appearance. The operation, performed under cocaine, consisted of retraction of the swollen, posterior nail wall, elevation of the root of the nail from the matrix, and snipping off portions of the proximal end of the nail.

DISCUSSION.

Dr. Sherwell thought it would be better to put the patient under a general anæsthesia, and treat all the fingers at one time, rather than let the patient suffer considerably and often with local anæsthesia.

RETRACTOR FOR NAIL OPERATIONS. Presented by Dr. Howard Fox.

Dr. Howard Fox presented a retractor which had been made for him and which he had found of great assistance in performing the operation for paronychia, above described. The instrument was a three-pronged retractor, three-sixteenths of an inch in width, the handle being about five inches in length.

NEW YORK DERMATOLOGICAL SOCIETY.

Regular Meeting, Apr. 25, 1916.

Howard Fox, M.D., *President.*

ACNE WITH UNUSUAL SCARRING. Presented by Dr. Trimble.

The patient was a woman, thirty years of age, whose skin was smooth and clear up to three months ago. At that time, while having her face massaged, practically every sebaceous gland in her face became inflamed and infected, and was followed by disseminate scarring. The case was shown on account of the peculiar scarring, resembling that of so-called acnitis, and also because of the unusual ætiology.

CASE FOR DIAGNOSIS. Presented by Dr. Howard Fox.

The patient, B. E., was a girl, nine years of age, born in the United States. Two years ago, a dime-sized patch appeared over the right clavicle and lasted one year. It then disappeared for several weeks; then reappeared and with it were several new patches, all tending to coalesce. The patient presented one patch of three months' duration, upon the right clavicular region, and on the abdomen and thighs were a dozen more superficial, reddish, dry, scaly patches, showing no evidence of scratching. A possibility of parapsoriasis was thought of, from the lack of itching and the failure, according to the patient's statement, to respond to treatment.

Discussion.

Dr. Trimble said that if he had not known the history of the case he would, offhand, have made a diagnosis of pityriasis rosea. He had never heard of a pityriasis rosea lasting for several years, though he had seen it persist for six months, or perhaps longer. Clinically, the case presented the appearance of that eruption.

Dr. Potter said that he had seen the patient some months ago and at that time she had no lesions excepting the one on the neck, which he took to be a seborrhœic dermatitis. He saw her three or four times, and the condition remained about the same. The condition was very different upon presentation. The lesions on the body resembled pityriasis rosea. It seemed probable that

there might have been two conditions.—pityriasis rosea and seborrhœic eczema.

Dr. Robinson thought it was a case of seborrhœic eczema, but that it would be difficult to differentiate one condition from the other without studying the case for some time.

Dr. Winfield said that he had seen the patient about a year ago when there was one patch over the clavicle, of seborrhœic eczema.

Drs. MacKee and Heimann agreed with the diagnosis of seborrhœic eczema.

Dr. G. H. Fox said that he had seen pityriasis rosea last for more than a year in several cases. The French writers reported cases lasting four or five years, so it must be recognized that there is such a thing as chronic pityriasis rosea. This case, however, did not appear to him to be one of that disease.

URTICARIA PIGMENTOSA. Presented by Dr. Clark for Dr. Whitehouse.

E. J., female, born in the United States, aged fifteen years, and younger sister, thirteen years of age, were presented.

The speaker stated that he had not before seen the younger sister, but as the older girl had stated that her sister had similar lesions, he had requested that she also come before the Society. Both girls were in good general health and looked well. The older girl gave a history of having had jaundice twelve years ago (at the age of three), and she dated the appearance of the lesions from that period. She gave a history of having had several attacks of hives, but said that the eruption which she exhibited did not itch.

She presented numerous yellowish-brown, pigmented macules on her trunk and neck, like freckles, but generally larger. There was a tendency to a circular outline with sharp margins. The lesions were not scaly nor indurated and did not disappear under pressure. The patient exhibited a dermographism, and the lesions could be more plainly brought out by rubbing them.

URTICARIA PIGMENTOSA. Presented by Dr. Clark.

This patient was a boy, ten years of age, of German extraction. He was well nourished. The trouble began in the winter, four years ago, with redness of the skin and itching. The itching disappeared when the warm weather came on, but dark stains remained over the body. Each winter since the original outbreak the boy had had more or less irritability and redness, the stains persisting all summer. When presented, the patient showed dermographism on the trunk and legs, together with yellowish-brown pigmented spots that did not entirely disappear on pressure. There was no scaling, no induration, no itching of lesions, which were circular in outline and considerably larger than freckles. The lesions were made more pronounced by rubbing them.

Discussion.

The diagnosis of all three cases was accepted without dissent.

Dr. Heimann said that one point of interest in the two sisters was that some of the lesions suggested nævi.

PSORIASIS. Presented by Dr. Whitehouse.

The patient presented a case of acute guttate psoriasis, the condition being unusually pronounced for two months' duration. There were lesions on the scalp with patches so close together and scales so heaped-up that it looked like favus. The palms and soles were free of lesions.

CASE FOR DIAGNOSIS. Presented by Dr. Trimble.

The patient was a girl, 16 years of age, who was shown for the white spots on her forearms and which did not seem to be those of ordinary leucoderma. The patient stated that last summer she had had a number of warts on her hands for which a druggist gave her "some acid." This caused blisters, and after the inflammation subsided there remained scars on her hands where the warts had been. She said that gradually she noticed a few white spots on her forearms, which were increasing in number, but never preceded by warts.

Discussion.

Dr. Potter thought that possibly the girl had herself caused the lesions.

Dr. MacKee agreed with Dr. Potter that the lesions might be traumatic and self-inflicted.

Dr. Howard Fox thought that dermatitis factitia was not improbable, on account of the marked symmetry of the lesions.

Dr. Trimble said that he had considered the possibility of dermatitis factitia, but wished to learn what the other members thought. A point against that diagnosis was the fact that the lesions on the upper part of the forearm showed no infiltration,—merely loss of pigment. The patient claimed that she had had no warts excepting those on her hands. It brought to mind another case shown last year,—a boy, 12 years of age, with a similar condition, and at that time no definite diagnosis was made in his case.

CASE FOR DIAGNOSIS. Presented by Dr. Howard Fox.

The patient, J. N., was a man, 35 years of age, born in the United States, a farmer by occupation. There was no family or personal history of syphilis. The eruption had begun about fifteen years before, becoming worse during the past three or four years. It was confined to the face and ears, and neck. The patient was practically never free from the eruption, one or more lesions always being present. He stated that some of the lesions began as itchy spots, after which a small "sore" would appear and become crusted. Others began as "pimples" or hard white pin-head lumps. The duration of each individual lesion was about a month. All of them eventually became crusted and were mostly followed by more or less scarring. When presented, there were two superficial, crusted, pea-sized spots on the nose and two upon the chin. Upon the cheeks, nose and ears, and more especially on the sides of the neck, were pea-sized, whitish scars, neither raised above nor depressed below the surface of the skin. Some of them were so superficial that they were recognized only upon close observation. A few scars were seen upon the right side of the forehead, but none was noted in the scalp. The patient's general health appeared to be good.

Discussion.

Dr. Whitehouse thought the condition was produced by continual picking, and that it was a case for the neurologist rather than the dermatologist. He himself had had a patient who kept picking his face for years, and wore a pair of tweezers and scissors down, in his attempts to remove what he thought were ingrowing hairs. The patient presented complained of a peculiar sensation of the skin, and said that he had tried to get rid of it by picking it out. Such a dermatitis could be kept up by continual picking, as a result of a nervous condition. As the lesions did not seem to correspond to any type of skin disease, it seemed to the speaker to be a neurosis of the type mentioned.

Dr. Winfield said he had not thought of that diagnosis until Dr. Whitehouse spoke of it, but what had been said brought to mind a somewhat similar case which he had seen recently, where the patient, a girl, had almost identical lesions. She had a prickling sensation of the skin, and would keep at it with her fingernails until she produced a condition like a necrotic acne. It seemed clearly a traumatic condition.

Dr. Johnston agreed with the other speakers that the lesions were traumatic and not the result of any sort of acne.

Dr. MacKee also agreed with the other speakers. He had had two or three such cases of neurotic dermatitis.

Dr. Wise agreed with Dr. Whitehouse and said that the basis of the trouble seemed to be a neurotic disturbance—perhaps corresponding to trichotillomania.

MILIARY PAPULAR SYPHILIDE. Presented by Dr. Howard Fox.

Previously presented before the Manhattan Dermatological Society (see Transactions.)

CASE FOR DIAGNOSIS. Presented by Dr. Clark.

T. M., male, 34 years of age, born in Galicia. Six months ago the patient began to have "pimples" on his legs; later, they appeared on his face and arms. The papules gradually increased in size, some of them becoming as large as a two-cent piece. They were sharply circumscribed, symmetrically located, distinctly raised and indurated, rather flat on top, with some tendency to crusting.

The patient had been presented before the Dermatological Section of the Academy of Medicine with a tentative diagnosis of bromide eruption in which none of the members concurred. He was presented in the hope of obtaining further enlightenment as to diagnosis. Dr. Heimann had made a section of one of the papules, but had not as yet reported his findings.

Discussion.

Dr. Johnston said that he could not state positively that it was a staphylococcic pyodermia, but that the assumption was possible. It was not a prurigo nodularis, in his opinion.

Dr. Winfield was inclined to agree with Dr. Johnston, that the lesions were those of a low grade staphylococcic granuloma.

Dr. MacKee agreed with the other speakers. He thought that the man had irritated the condition by scratching. It seemed to be a staphylococcic pyodermia.

Dr. Heimann said that microscopically the case showed the picture of a chronic infection. It certainly did not belong to any prurigo group.

Dr. Wise considered it to be a follicular pyodermia.

Dr. G. H. Fox recalled a case of prurigo nodularis seen at Chicago and reported by Dr. Zeisler, other cases reported by Dr. Williams and others, and one case that he himself had shown at a former meeting of the Society. It seemed certain that all of these cases were of the same nature, and he would call the case one of prurigo nodularis.

Dr. Trimble did not think it was a staphylococcic condition. There were no outlying pustules, small abscesses, or crusts to indicate this. He had made an unofficial suggestion that it might possibly be prurigo nodularis; this suggestion was based on the deep bluish color of the lesions, the location, and the fact that they itched intensely. He knew that Dr. Johnston's statement was correct,—

that according to our present knowledge lesions of prurigo nodularis persisted and were not removed by treatment; neither did they heal spontaneously. We had not, however, seen enough cases of this rare condition to know all about it, and we might in the future see cases in which some of the lesions would heal spontaneously.

Dr. Whitehouse said that he could not get over the idea that it was an infectious granulomatous process. He agreed with Dr. Johnston that there might be some internal dyscrasia at the bottom of the condition. The patient had furuncles from time to time. He could not reconcile this condition with the prurigo nodularis type of disease.

Dr. Potter agreed with the diagnosis of pyogenic granuloma, as suggested by Dr. Johnston.

Dr. Clark said he was very glad to have this discussion of the case. He had watched the patient for three months and the lesions had changed considerably. Three months ago the nodular type was more pronounced than upon presentation. He had observed three or four furuncles during that time, but none of them had run into such a nodular granuloma as had been suggested by some of the members. He was inclined to accept the diagnosis of pyogenic granuloma.

ACRODERMATITIS CHRONICA ATROPHICANS. Presented by Dr. Heimann.

The patient was sixty-five years of age, and presented a combination of psoriasis, scleroderma and acrodermatitis atrophicans. The case was a duplicate of one presented by the speaker at the American Dermatological Association, in 1915. He had often noticed, as in these cases, the association of scleroderma and acrodermatitis.

Discussion.

Dr. Wise agreed with the diagnosis of acrodermatitis atrophicans. He did not think that the scaly lesions were those of psoriasis, but rather an adventitious eczema occurring on devitalized skin. The scleroderma of the legs was the usual concomitant of the acrodermatitis atrophicans.

Drs. Whitehouse, Potter and Robinson said that there was one distinct process—sclero-acro-dermatitis atrophicans.

Dr. Johnston said that the process was all one, and suggested that that one was syphilis.

Dr. Heimann said he did not know whether or not it was syphilis. He had done a dozen Wassermann tests in cases of scleroderma and had not yet found one positive. If he had, he would have regarded it as a coincidence.

ACRODERMATITIS CHRONICA ATROPHICANS. Presented by Dr. Howard Fox.

The patient, M. L., was a woman, 54 years of age, born in Sweden, a cook by occupation. The family history was negative. She had noticed enlarged veins for many years. The atrophic condition, she stated, had been present about three years and the scleroderma about one year. She was a well-nourished and apparently healthy woman, who presented a typical picture of diffuse atrophy of the greater part of the lower extremities, from the anterior superior spine to the toes. The atrophy was most marked upon the buttocks and knees. Upon the lower legs and dorsal surfaces of the feet was more or less scleroderma. There was a slight amount of atrophy over the elbows. There were no subjective symptoms.

EPITHELIOMA OF LOWER LIP. Presented by Dr. Howard Fox.

The patient, J. E., was a man, 50 years of age, born in Sweden, a boatman by occupation. At the age of nine years, he had been kicked in the mouth by a cow, his teeth broken and lower lip split open. After healing, according to his statement, a lump, the size of a small hazelnut, was left in the lip. This could be felt, he said, as a hard lump to the right of the centre of the lower lip and was not visible. He had never experienced any pain or other subjective symptoms. Two months ago, the entire lower lip began to swell, and one week later the ulceration presented appeared, which had remained about the same up to date. The general swelling of the lip had increased. He had noticed the enlargement of the submaxillary glands during the past two weeks. Examination showed a general swelling of the entire lower lip. An ulceration was present a little to the right of the centre of the lower lip, situated partly upon the vermilion border, but mostly on the mucous membrane. The ulceration was elevated, the edges rolled and, together with the entire mass, decidedly hard. The base was clear, reddish, and not covered with crusts. The discharge was slight and there was no bleeding. There were two enlarged submaxillary glands on the right, the larger one being the size of a cherry and not only palpable, but visible. Both of these glands were decidedly hard. The general health was excellent. The Wassermann reaction was negative. There were no signs or symptoms of syphilis.

Discussion.

Dr. Wise agreed with the diagnosis of epithelioma but thought that tuberculous ulcer could not be entirely excluded.

Dr. Clark said that the edge was too hard for a tuberculous ulcer. The condition was very typical of epithelioma.

Dr. Potter told of a case in the King's County Hospital. The patient was a man, 25 years of age, with a lesion on the lip similar to this one. His Wassermann was negative, but as the condition was thought to be of too short duration to produce a Wassermann reaction, an examination was made for spirochætæ and the pathologist reported them present. The patient was given salvarsan, with no improvement of the lesion. He was held under observation, and finally it was decided that the lesion was epithelioma—after a good deal of time had been lost. Section of the tissue after removal of the lesion proved the case to be an epithelioma.

Dr. Winfield said that the rapidity of the process was against the diagnosis of tuberculosis.

Dr. Howard Fox said that the idea of tuberculosis had not occurred to him at all, on account of the rapid development of the lesion. Before the Wassermann was found to be negative, the differential diagnosis between epithelioma and chancre seemed somewhat difficult on account of the rapid growth of the lesion on the lip and the rapid enlargement of the glands.

CASE FOR DIAGNOSIS (Tumor formation with hyperpigmentation over malar prominences). Presented by Dr. Sherwell.

Mr. E. N., 50 years of age, was a Swede. There was no history of specific trouble. He came under observation first, on Jan. 3, 1912, for a dermatitis medicamentosa, especially on the face, appearing after the use of strong lotion.

On January 3rd of the present year, he again presented himself with lesions

on his face. He stated that they appeared in September, 1915, after he had been exposed to the sun; after a few hours of irritation they appeared over the malar prominences. Then followed a gradual increase in the pigmentation. At first a lotion containing hydrarg. bichloride, etc., was applied in view of its possible resorbent action; that not acting well, or at least, not promptly, it was supplemented with an unguent of hydrarg. ammoniat. and salicylic acid, since which there had been some improvement in the lesions, but not much.

The case was presented for diagnosis and suggestions as to treatment.

Discussion.

Dr. Trimble thought that it was a case of sarcoid. It was not always possible to make a diagnosis of such a rare condition upon one superficial examination, but the location, the livid color, and the nodulation of the lesions seemed to indicate that disease.

Dr. Clark thought it was lupus erythematosus. Distinct teleangiectatic lesions were scaly, and that seemed to be a satisfactory diagnosis, in his opinion.

Dr. Whitehouse was inclined to the diagnosis of lupus erythematosus, superficial in type. By putting the skin on the stretch, some patches showed a circinate, almost discoid character of outline. Inside the ear was a distinctly circumscribed patch. There was no atrophy, but it was certain to have that later. The symmetry, the scaliness, the circinate outline, and the discoid patches all favored the diagnosis of lupus erythematosus.

Dr. Winfield also thought it was lupus erythematosus.

Dr. MacKee thought it was lupus erythematosus on account of the thickened horny layer and the presence of lesions in the ear. There was a certain amount of œdema present that was often seen in early cases of lupus erythematosus.

Dr. Heimann thought it was the involuting stage of the sarcoid of Boeck. It presented the mixture of plum color and brown, as well as the teleangiectasis seen in that disease. He could not see anything in favor of lupus erythematosus outside of the fact that the two conditions had a certain similarity; but there was no central atrophy, as in lupus erythematosus.

Dr. Trimble recalled a case shown by Dr. G. H. Fox, a number of years ago, an account of which was published later. It was a more extensive case than this, but the lesions were very much alike.

Dr. Howard Fox thought that the lesions of the back resembled sarcoid, and suggested treatment by carbon dioxide snow, a method that had given good results in one of his cases.

Dr. Sherwell thanked the members for the evident interest manifested. He himself had been unable to establish a diagnosis. The fact that the lesions had developed very quickly and definitely after exposure to heat, baffled him. He had thought of erythematous lupus, but the tumefied character did not seem to coincide with that diagnosis, nor the fact that it had improved somewhat under treatment. He had seen no cases of Boeck's sarcoid. He asked if any of the members could make suggestions as to treatment.

Dr. Clark said that if the lesion was a sarcoid it would respond very well to X-ray or radium treatment; while if it were lupus erythematosus it would also be very decidedly influenced by radium exposure. In the cases where they had had trouble in healing with the Kromayer light, when they were given a primary X-ray or radium treatment, they finally cleared up the lesions under the Kromayer lamp.

Dr. Heimann said that ninety per cent. of the cases of sarcoid healed spontaneously.

Dr. Trimble said that the other ten per cent. would probably disappear under arsenic injections.

HERPES ZOSTER FOLLOWING OSTEOPATHIC MANIPULATION OF THE SPINE. Reported by Dr. Howard Fox.

The patient was a physician, about forty years of age, who had suffered from time to time from periodical attacks of pylorospasm. Radiograms made on two occasions had shown the findings of pylorospasm, but not of any organic lesion of the stomach. As an experiment, an examination of the spine had been suggested by an osteopathic physician. Regarding his case the patient stated as follows: "I agreed to an examination by three osteopaths, each to make his examination and report his findings entirely independent of the others. While these reports varied slightly in their wording and in the description of the findings, they were practically unanimous in their diagnosis of a so-called lesion in the region of the ninth dorsal vertebra. When asked to interpret the symptoms of a lesion in this region, they all, absolutely without my having expressed my opinion, located the symptoms as in the gall-bladder region, the region of the pylorus, or the pancreas. On the strength of this rather unanimous opinion as to the most important thing, I agreed to allow one of the men to attempt to reduce this so-called lesion. An attempt to do this by extreme flexure and a twisting by local pressure of the thumbs, in the region of the ninth and tenth dorsal vertebræ, resulted in the sensation of slipping or grinding in that region. Two days later I had another treatment, this time limited practically to deep local massage. About three days later, a small papule appeared on the back, directly opposite the point where the treatment had been applied and on the same side. The next day this increased, and the following day there was a well marked, typical herpes zoster, limited to the region of the ninth and tenth dorsal vertebræ on the left side. A few days later it appeared on the surface of the anterior end of the rib. The eruption lasted altogether about a month."

The patient was seen on the fifth day of the eruption, when he presented a typical picture of herpes zoster. The case is recorded inasmuch as a traumatism in the region of the posterior roots or ganglia of the ninth and tenth dorsal nerves was followed, in three days, by a typical herpes zoster occupying the region supplied by these nerves.

Dr. Howard Fox reported on the histological examination of a case of a woman with persistent erythematous patches, previously shown at the last meeting, for diagnosis. Dr. Heimann, who made the examination, reported: "Nothing that I have ever seen is recalled to me by the picture here shown. It is possible to rule out psoriasis, seborrhœa, parapsoriasis, scaling eczema and the ordinary exfoliative erythrodermias. It is not an inflammatory granuloma, such as syphilis, tuberculosis or lepra. The things that suggest themselves are premycosis, pernicious lymphodermia, leucæmia and perhaps a beginning sarcoma, although I cannot see enough of any one of these conditions in the slide to be positive. Neither does it seem like a sarcoid. We know very little, however, about the early stages of sarcoma and perhaps that is what it will finally turn out to be. It is certainly not on the basis of a nævus."

CASE PREVIOUSLY SHOWN BY DR. HOWARD FOX.

Dr. Heimann said that the first section taken from the negro baby was studied through the almost impenetrable gloom of an institutional microscope and looked like a lichen planus, but when examined under a better lens, he found giant cells. It was then seen to resemble syphilis or lichen scrofulosorum. There were not enough vascular changes to state positively whether or not it was syphilis, but the diagnosis lay between the two conditions mentioned, and Dr. Fox's further tests showed it to be unquestionably syphilis.

REVIEW

OF

DERMATOLOGY AND SYPHILIS.

Under the direction of

FRED WISE, M.D., New York,

Assisted by

CLARENCE A. BAER, M.D., Milwaukee.
WILLIAM H. BAUGHMAN, M.D., New York.
PAUL E. BECHET, M.D., New York.
J. S. EISENSTAEDT, M.D., Chicago.
CHARLES GOOSMANN, M.D., Cincinnati.
JAMES F. GRATTAN, M.D., New York.
ROBERT C. JAMIESON, M.D., Detroit.
FREDERICK T. LAU, M.D., New York.
M. F. LAUTMAN, M.D., Hot Springs.
OSCAR L. LEVIN, M.D., New York.
M. L. RAVITCH, M.D., Louisville.
ISADORE ROSEN, M.D., New York.
MAX SCHEER, M.D., New York.
PHILIP F. SHAFFNER, M.D., Chicago.
A. W. STILLIANS, M.D., Chicago.
JOHN H. STOKES, M.D., Chicago.
HARVEY P. TOWLE, M.D., Boston.
VICENTE PARDO, M.D., Havana, Cuba.

ARCHIV FUR DERMATOLOGIE UND SYPHILIS.

(April, 1915, cxxi, No. 2.)

Abstracted by JOHN H. STOKES, M.D.

TWO CASES OF NEURODERMITIS NODULOSA. J. FABRY, p. 241.

Fabry describes two cases of what he had earlier discussed as urticaria papulosa perstans (*Arch. f. Dermat. u. Syph.*, 1895), but which he now regards as nodular forms of the general group of neurodermites described by Brocq. The primary lesion of the condition is a pruritic nodule, about 0.5 cm. in diameter, hard, and from a pink to a grayish-brown in color. Diffuse patches of typical neurodermitis were present. (There seems to have been no effort to compare the cases with those of prurigo nodularis reported in this country, to which they would seem to bear more than a superficial resemblance. —Reviewer.)

CONTRIBUTION TO THE QUESTION OF THE BASAL CELL TUMORS OF THE SKIN. J. KYRLE, p. 246.

This is an elaborate discussion and critical examination of the opinions of Krompecher, Boermann, Ricker and Schwalbe and others, on the histogenesis of so-called basal celled malignant growths in the skin. Kyrle describes his own

findings in a piece of tissue excised from a lesion of lupus vulgaris of the nose, in which a coincidental malignant degeneration of the epithelium was observed. Kyrle seems to adopt a compromise view, expressed substantially in the statement that the basal cells of the epidermis have two potential functions or developmental tendencies. When functioning as an epithelial cell, the basal cell gives rise to the horn cell as the sequel of a keratinization cycle. In another capacity it may function as a source of post-fœtal sebaceous gland formation. According as the one tendency or the other is uppermost when malignant degeneration occurs, the picture produced is that of the squamous celled epithelioma, or that of the basal cell epithelioma.

THE BLOOD PICTURE IN ACUTE AND CHRONIC FORMS OF LUPUS ERYTHEMATOSUS. SPIETHOFF, p. 269.

Spiethoff's conclusions are as follows: In the chronic forms of lupus erythematosus, the basophilic and eosinophilic count is unchanged, the large mononuclears and transitionals are occasionally increased, both relatively and actually. The neutrophilic count is occasionally relatively, and practically always absolutely, diminished. There is a relative increase of lymphocytes, often also an absolute increase. There is a general tendency to leucopenia in the total white count. In the acute febrile form of lupus erythematosus, uncomplicated, the basophiles and eosinophiles were practically absent, with the same relative increase in lymphocytes as in the chronic form. Other features of the picture resemble the chronic form. Complications caused the blood picture to assume the characteristics appropriate to the complicating disease. While the blood picture is not specific, there is a certain resemblance to that of tuberculosis.

NODULAR CONDITION OF THE HELIX OF THE EAR. M. WINKLER, p. 278.

The author has seen eight cases of a soft nodular growth, the size of a pea, on the external ear, usually on the helix. The nodule in some cases was surrounded with a crust. Jadassohn's histopathological study showed a chronic inflammatory process, with degenerative changes in the cartilage, which caused it possibly to act as a foreign body. One case in which the lesion was excised, developed a recurrence, while other cases were cured by this procedure. Winkler designates the condition "chondrodermatitis nodularis chronica helica."

A CASE OF ANGIOKERATOMA CORPORIS DIFFUSUM. G. STUMPKE, p. 291.

A case of angiokeratoma with lesions on the ankle. There were also lesions on the scrotum, and on the abdomen and back. No evidences of associated tuberculosis were found.

TWO NOTABLE CASES OF SYPHILIS, WITH REFERENCE TO EXTRAGENITAL INFECTION, AND ITS PROGNOSIS. J. AND E. KOTTMAIER, p. 296.

The authors emphasize what they believe to be the unfavorable prognosis and malignant course of syphilis, when inoculation occurs more or less directly into the blood stream, without the usual lymphatic resistance to the spirochæte. In one of the cases, a rather rapidly fatal syphilis followed an extragenital pri-

mary lesion on the nasal mucosa, in a debilitated patient, without the development of a secondary eruption, but with an early onset of tertiary lesions. In the second case, an especially severe infection followed a primary lesion on the tongue.

NEURODERMITIS VERRUCOSA. C. Kreibich, p. 307.

A case report of an exaggerated lichenification in the scrotal region, almost verrucous in character, presenting histologically an acanthosis upon a non-specific inflammatory base, with a marked accumulation of eosinophiles in the tissue. There were nodular lesions present, exhibiting marked hyperpigmentation, and vitiligo-like patches.

KERATOHYALINE. C. Kreibich, p. 313.

The author investigated the origin of keratohyaline by studies of the cellular structure in the epidermis of acuminate condylomata. He reached the conclusion that keratohyaline is of nuclear origin. Chemically, the substance seems to be a fluid mixture of chromatin and nucleolin, whose tinctorial reactions may be influenced both by peculiarities in the protoplasm of the cell, and by the composition of the nucleolin itself.

RUSSKI JOORNAL KOJNIKH E VENERICHESKIKH BOLEZNEI.

(April, May, June, 1915, xxix, Nos. 4, 5, 6.)

Abstracted by M. L. Ravitch, M.D.

IDIOPATHIC HÆMORRHAGIC MULTIPLE SARCOMA OF THE SKIN. Grigoriev, p. 137. (*Continued*).

While no new pathological findings of importance have been discovered by Grigoriev in the many cases described and reviewed by him, the author has continued his laborious research in the histopathology of this disease, which is quite common in Russia, although extremely rare in this country. From his examination of many specimens, Grigoriev reports that the chief histological changes are in the corium only; here the collagen does not stain normally, but is degenerated; still deeper and extending into the subcutaneous tissue, there is a dense connective tissue with large numbers of newly formed blood vessels and lymph spaces, while blood extravasations and deposition of blood pigments are common; frequently there is a proliferation of the endothelial cells of some of the blood vessels. The histological picture of the disease, as he reports it, is materially the same as given by American dermatologists.

In his conclusion, the author says that notwithstanding numerous investigations, the interpretation of the histological findings of this disease has not yet been made and is still an open question.

VACCINE THERAPY IN ACNE VULGARIS AND FURUNCULOSIS. MANUGARIANZ, p. 151.

Bogrov quotes Manugarianz's results in regard to heterogeneous polyvalent vaccine applied in twenty cases, six of acne and fourteen of furunculosis. While his cases are too few in number to be of value by themselves, yet since his conclusions coincide with those of other investigators, he takes the opportunity to quote them. They are as follows: (1) vaccine therapy in acne vulgaris and furunculosis is both non-injurious and valuable; (2) vaccine therapy of staphylomycosis deserves a larger application; (3) the weakness of vaccine therapy is the lack of an established standard; (4) the question of recurrences is as yet an open one.

DESTRUCTION OF VERMIN AMONG THE MASSES AND MILITIA. ZAUCILOV, p. 153.

It is well established that various forms of parasites, found often on underwear, clothes, bed clothes and on the human skin, are easily transferred from sick people to healthy ones, thereby spreading certain infections. This is particularly evident among the poorer classes and in the army.

For the destruction of parasites on underwear or clothes, steam, hot air and sulphurous gas are the most powerful, the last being especially convenient for private residences and institutions. For cleansing the human skin of parasites, the Russian bath, tub bath and showers are effective, and therefore it is the duty of the government of the city or state to establish many bath houses where the mass of the people and the soldiers may avail themselves of these baths. While the armies are in movement and bathing facilities insufficient, inunctions with different preparations of tar and solutions of lysol are advocated.

DIFFERENT CHEMICAL MEANS FOR THE DESTRUCTION OF BODY LICE. RAPCHEVSKI, p. 154.

Rapchevski's method for the destruction of body lice has been accepted by the Russian military-sanitary committee. For the destruction of lice and nits on the underwear and clothing, hot air of high temperature is employed. As a chemical application, a soap composed of 65 parts of naphthol and 35 parts of cresol is employed. This soap is dissolved in water and the underwear and clothes immersed in it. This method has been found a very useful one.

EMPLOYMENT OF STERILIZED VASELINE INSTEAD OF BECK'S BISMUTH PASTE. DOMBROVSKI, p. 155.

Dombrovski quotes Troitski's method of treating fistulas and sinuses with injections of sterilized vaseline instead of Beck's paste. After washing out the cavity with an antiseptic solution until there is not a sign of pus left, the sterilized vaseline is injected. His results with it were far superior to his results from Beck's paste, and moreover there was no danger of bismuth poisoning as has been observed with Beck's paste.

GRANULOMA MALIGNUM. BERTELS, p. 163.

Bogrov, in quoting Bertels' article, omits the history of this disease. Bertels claims that Sternberg's lymphogranuloma should be called granuloma malignum, separating it from Hodgkin's disease, which he calls lymphoma malignum.

The author has observed nine cases of granuloma malignum, and in the lymphatic glands from either bioscopy or autopsy, in all nine cases, he found Sternberg's giant cells. He does not commit himself to either side in the controversy as to the tuberculous ætiology of this disease; the author himself does not go deeply into the histology of the tissue changes nor the changes in the blood.

A RARE CASE OF ACUTE GENERAL URTICARIA. Sodachev, p. 164.

Sodachev quotes Bogrov's case of acute general urticaria, not only of the skin but also of the mucous membrane. The eruption was intense and well defined. The patient had intense pain in the lumbar region and urticarial fever, his temperature going up to 102° F. The disease lasted two weeks, the patient recovering completely.

CASE OF A DERMOID CYST, AT FIRST MISTAKEN FOR A SWELLING DUE TO THE INJECTION OF PARAFFIN. Kholevo, p. 166.

Troitski describes Kholevo's case of a dermoid cyst that was mistaken for a tumor, supposed to be due to the injection of paraffin. The case occurred in a young recruit and was located in the region of the chest. The swelling was in the shape of a hemisphere the size of a tangerine. The tumor was quite hard and mobile; the skin over it was normal and also mobile. The tumor was excised and examined. Kholevo recognized it as a dermoid, though the name of a "traumaide" could be applied, since the swelling was of traumatic origin.

ULCUS MOLLE ANI IN A BOY. Pospielov, p. 169.

Pospielov describes this rare case on account of its unusual location. Before describing this case he mentions also the case of Rosenquist, of ulcus durum circa anum. A young man, out of work, approached two well dressed men and asked them for help. They promised to help him secure work if he would go with them to a saloon. After drinking some beer, which must have been drugged, he fell into a stupor from which he awoke to find himself lying in a wagon. He had some pain in the rectum and vomited a great deal. He applied to a local hospital for treatment. After two weeks he developed a hard chancre of the rectum, which yielded to specific treatment.

The second case was that of a 14 year old boy. The boy was well developed and strong, but complained of pain before a bowel movement. He also gave a history of sadism. Having been compelled to leave home, he went to a cheap lodging house and shared his cot with a tramp. Upon examination of his rectum a few days afterwards at a hospital, a soft chancre was found by the hospital physician.

NEW YORK STATE JOURNAL OF MEDICINE.

(May, 1916, xvi, No. 5.)

Abstracted by Oscar L. Levin, M.D.

SYPHILIS AS AN ÆTIOLOGICAL FACTOR IN EPILEPSY. William T. Shanahan, p. 239.

Wassermann tests performed on the blood serum of 886 epileptics at the Craig Colony, revealed only 22 (2.48 per cent.) positive reactions. In several of the positive cases it was possible to demonstrate the causative relationship between syphilis and epilepsy. The histories of nine such cases are described. As a result of these findings, it is concluded that syphilis may cause epilepsy, but plays a less active rôle than has heretofore been thought.

SYPHILIS OF THE STOMACH. Raymond B. Morris, p. 245.

Report of a case illustrating the difficulty of differential diagnosis between cancer of the stomach and syphilis of the stomach, with tumor formation. A gumma of the stomach may produce the same signs and symptoms as a malignant process of the stomach. Syphilis and cancer may coexist, and a positive Wassermann reaction, combined with a luetic history, does not prove that a stomach tumor is luetic. Even an exploratory laparotomy may not settle the diagnosis, as the gross pathology in both conditions is often similar. Thickening and induration of the stomach wall suggest lues. The therapeutic test is of value if the patient is observed long enough to be sure that the improvement from antisyphilitic therapy is permanent.

The case reported is that of a man, 32 years of age, who had complained of gastric disturbances for two and a half years. An exploratory operation revealed a large, inoperable growth at the pylorus. The remainder of the stomach and the lower part of the œsophagus were thickened and indurated. A history of lues was later obtained from the patient and the Wassermann proved double plus. Improvement followed antisyphilitic treatment for a while. Exitus occurred five months after the operation. At autopsy, an enormously enlarged liver, filled with hundreds of metastatic nodules, was found. The gastric tumor was smaller than at exploratory operation. It is not unlikely that the cancer developed as a result of the chronic irritation from luetic invasion of the liver.

THERAPEUTIC GAZETTE.

(May 15, 1916, xxxii, No. 5.)

Abstracted by Oscar L. Levin, M.D.

THE PREVALENCE OF SYPHILIS. Edward B. Vedder, p. 308.

The paper is based upon the Wassermann findings in the blood serum of 1019 newly accepted army recruits and 621 cadets at West Point. None of these men exhibited any clinical evidence of lues. Positive Wassermann reactions were obtained in 16.77 per cent. of the recruits and in 5.46 per cent. of the cadets. The recruits had passed two physical examinations and represented only 17 per cent. of the applicants. Of those rejected, 2.3% showed evidence of syphilis. It, therefore, appears conservative to estimate that about 20 per cent. of the adult male population of the class from which the army is recruited are infected with syphilis. West Point cadets are physically superior to the students of other colleges, have passed severe physical examinations, are under the strictest military discipline and seldom leave the reservation. Under these circumstances, it is fair to assume a prevalence of 5% among college students.

The Wassermann test was positive in 36 per cent. of the negroes and 55 per cent. of the Porto Ricans. Lues is possibly the greatest single factor in the production of disability and the high mortality among these people.

The author believes that syphilis is a greater menace to the public health than any other single infectious disease, not even excepting tuberculosis.

THE TREATMENT OF NÆVUS FLAMMEUS (PORT-WINE MARK) AND ALLIED CONDITIONS BY FILTERED ULTRA-VIOLET RAYS, EMPLOYING THE COMPRESSION METHOD OF APPLICATION. REPORT OF TEN CASES WITH TWO ILLUSTRATIONS. WILLIAM L. CLARK, p. 312.

The author concludes that port-wine nævi, teleangiectases, rosacea and other superficial vascular cutaneous lesions respond to treatment with powerful ultra-violet rays. Nævi which fade upon pressure and contain no thickened connective tissue, are most amenable. The treatment also improves scars caused by caustics and enlarged features due to vascular engorgement. Young children and blondes respond more rapidly than adults and brunettes. The healthy skin is more susceptible than abnormal skin, and must be protected during applications of the rays.

VIRGINIA MEDICAL SEMI-MONTHLY.

(May 26, 1916, xxi, No. 4.)

Abstracted by OSCAR L. LEVIN, M.D.

THE MASSIVE DOSE METHOD OF ROENTGEN THERAPY. A. L. GRAY, p. 82.

BOSTON MEDICAL AND SURGICAL JOURNAL.

(May 25, 1916, clxxiv, No. 21.)

Abstracted by OSCAR L. LEVIN, M.D.

THE PROBLEM OF RINGWORM IN CHILDREN. E. L. OLIVER, p. 751.

NEW YORK MEDICAL JOURNAL.

(June 3, 1916, ciii, No. 23.)

Abstracted by JAMES F. GRATTAN, M.D.

PRESENILE GANGRÆNE; THROMBOANGEITIS OBLITERANS. C. GOODMAN AND E. P. BERNSTEIN, p. 1073.

A review of the world's literature on this condition shows that it is most prevalent in Russia, Austria, Japan, Bulgaria and Turkey. In these same countries, epidemic typhus fever is also prevalent. The number of cases of presenile gangræne in any one of these countries at any one time seems directly proportionate to the number of typhus cases in the period preceding. The authors believe that the idea prevalent here that the disease is peculiar to the Jewish race is a misconception derived from the fact that most of our immigrants from the typhus countries are Jews. In the countries mentioned above, the disease is just as frequent in occurrence in the non-Semitic inhabitants.

Cigarette smoking as a factor in the production of presenile gangræne is regarded now as questionable.

Syphilis as a cause may be disregarded.

Two of the assistants of Kuettnev, of Breslau, who served in the Bulgarian campaign, reported unusual frequency of gangræne among Bulgarian soldiers. Typhus has always been a frequent visitor of Bulgarian camps. Zinsser, on his return from a recent visit to Servia, reports a considerable number of cases of gangræne of the extremities following the Servian epidemic. Gangræne, as a direct complication of typhus, has been described. Saltikow and Buergev have suggested the infectious origin of thromboangeitis obliterans. The theory that a disturbed metabolism may be the cause, has had no substantiation by fact, to date.

Working upon the theory that latent typhus microörganisms may be an ætiological factor, serological examinations were made upon 21 cases, controlled by 102 patients with other diseases. Eighteen negative and 3 positive reactions were obtained. The agglutination and complement fixation tests of Olitsky were used. Agglutination showed in one case up to one in 200, and in the other two, up to one in 400. As it has been shown that the serological reactions may be lost in typhus cases in as short a time as five months, the significance of the finding of positive reactions in only three out of the twenty-one cases may not be as slight as the numbers would seem to indicate. The authors consider the results as significant and warranting further investigations.

PELLAGRA—A CLINICAL REPORT ON THE STATE OF NEW YORK. J. M. Winfield, p. 1076.

The author refers to a record by MacKee of seven imported cases reported by physicians in New York State. In 1911, Coccini and Wende each reported an indigenous case. MacKee also reported an indigenous case observed by himself, and Wise and Lautman reported two indigenous cases. A summary of these reports totals twelve cases within the limits of New York State. The series of eight cases reviewed by the author contains two cases not included in MacKee's report. Seven of the eight cases were females. Five were inmates of State hospitals for the insane. One had been in the asylum two years before symptoms of pellagra were noted. The time of the other four varied from two months to a year. Two of the total number were patients in a general hospital and the other was seen in the private practice of Dr. Robbins of Hornell, N. Y. This last case had had suggestive signs for two years preceding the appearance of the unquestionable picture. Two of the eight had enlarged thyroids, two had arrested pulmonary lesions ond one had died of pneumonia and pulmonary gangræne. The history of diet and living habits was unsatisfactory in the insane cases. One of the others gave a history of a diet of beans, oleomargarine and tea biscuits for years. Two gave a history of subsistence on bread and tea for some time. The eight cases cover a period of six years in the state reports.

(*Ibidem*, June 10, 1916, ciii, No. 24.)

AN APPARATUS FOR INTRAVENOUS SALVARSAN INJECTION. W. R. KAUFMAN, p. 1127.

The author uses an ordinary Luer syringe which has, as a novel factor, a side inlet or nipple, emerging from its barrel about one-quarter inch from the needle end. An ordinary five-eighths inch Luer needle is attached at the usual place, and the side inlet is connected by eighteen inches of soft rubber tubing to an ordinary gravity apparatus. With the plunger "driven home," the needle is inserted into the vein. The plunger is withdrawn to a point above the side inlet and the salvarsan solution, previously made to fill the circuit by aspirations, flows into the vein. The flow can be shut off by making the plunger pass the inlet. The syringe acts as a handle for the needle, and neither blood nor salvarsan are spilled at any time during the procedure.

(*Ibidem*, June 24, 1916, ciii, No. 26.)

THE VALUE OF AUTOSERUM INJECTIONS IN SKIN DISEASES. W. S. GOTTHEIL, p. 1209.

The conclusions of the author contain his opinion of the value of autoserum injections in clear, concise form, and are repeated verbatim:

"1. In psoriasis the autoserum treatment, while not in itself curative of the disease, is an important factor in the treatment. It cuts down the time required for the troublesome local treatment from weeks to days, and enables us to promise to clear the skin in from two to five days in even the worst and most obstinate cases. It postpones relapses for a long time, possibly indefinitely. In most cases it so influences the type of the disease that the relapsing lesions are few and insignificant, and are readily amenable to mild local treatment.

"2. In chronic urticaria, neurodermatitis, pruritis senilis, and other obstinate itchy dermatoses, it is worthy of trial. In some cases its action is effective and brilliant.

"3. It is of some value in bad pustular acne; but in furunculosis, folliculitis, and other pus infections, I have not found it useful.

"4. In chronic eczema the same may be said as of acne; the injections are sometimes apparently effective, and at others fail entirely.

"5. In pemphigus, lepra, and obstinate lichen planus it is ineffective.

"6. In syphilis it is useless."

Dr. Gottheil quotes H. Fox, G. H. Fox, MacKee, Fordyce, Winfield and Schwartz as believers in the efficacy of autoserum injections in psoriasis at least. Kingsbury, Trimble and Williams are skeptical, while Willock, after an experience in ten cases, declares the treatment valueless in psoriasis. The quotations indicate that none of the experimenters are quite as optimistic as Gottheil regarding the results in psoriasis. The author gives four to six injections at three-day intervals before beginning local treatment in the marked and persistent cases of psoriasis.

TRACHEOBRONCHIAL SYPHILIS. H. ARROWSMITH, p. 1211.

The author deplores the scarcity and inadequacy of the literature on this subject and ascribes this deficiency to the apathy of internists in their observations on inexplicable cases of dyspnœa and their reluctance to give over such

cases to the bronchoscopists. He cites Connor's paper in the *American Journal of Medical Sciences* of July, 1903, as the only comprehensive and valuable reference material upon this important subject. With the exception of Vierling's review of forty-six cases in 1878, nothing worthy of mention has appeared in the literature before or since Connor's classical review of the subject.

Connor's paper grouped these cases into four classes:

1. Gummatous swellings, circumscribed or diffuse.
2. Ulcers, single or multiple.
3. Endotracheal (bronchial) connective tissue, new growth, (a) distinct scars, (b) diffuse thickening.
4. Fibrous peritracheitis or tracheobronchitis.

Of the first class there are twenty cases.

Of the second class, fifty-one.

Of the third class, forty-seven of group (a) and thirteen of group (b).

Of the fourth class, eight cases.

Arrowsmith records two cases that came under his own observation. The first, a most interesting one, coming under the fourth class, peritracheobronchitis, determined by endoscopy and improved by antiluetic treatment, finally died but no autopsy was obtained. The second was one of the first class, a sessile gummatous swelling, which is improving under antiluetic treatment.

(*Ibidem*, July 1, 1916, civ, No. 1.)

CONGENITAL SYPHILIS. J. P. Jones, p. 11.

This is a report of a case of congenital syphilis with an extensive pathological summary. The patient, a girl of eighteen, bedridden for five years following flexion-contractures of both knee-joints and elbow-joints, had suffered subsequent pathological fractures of the right leg and the left thigh. Bowing of the long bones occurred so that the weight of the hands or feet was sufficient to bend the bones. Suppurative lachrymal dachryocystitis occurred and absorption of the bridge of the nose. X-ray demonstrated that absorption of the lower ends of both tibiæ had occurred. Typical syphilitic dactylitis existed. Liver and spleen were enlarged. The teeth were loose, and suppurative paronychiæ existed around the toe-nails.

In spite of the hopeless and helpless condition of the patient, antiluetic treatment, consisting of 0.4 gm. of neosalvarsan every month, for the first two doses, increased to every two weeks for two months, were given, followed by mercury salicylate, one grain, by deep injection, every two weeks. After six or seven months of treatment the patient showed a complete change from a limpid pathological specimen to a self-helpful convalescent, able to sew, embroider and write. Refractures are being done upon the angulated bones and further anatomical improvements are looked forward to.

(*Ibidem*, July 8, 1916, civ, No. 2.)

RADIUM. E. Tousey, p. 56.

The introduction to this paper is a review of the physical peculiarities and properties of radium. The beneficial therapeutic effects are illustrated by several cases, the author forming one of the series. He describes the destruction of X-ray keratoses on his own hands in a short time. The other cases are, a contracture of the fingers following a cellulitis of the hand, an epithelioma of

the lip in a patient of eighty-two and a poor operative risk, and a vernal catarrh of the eyelids, not amenable to the ordinary treatment with caustics. Tousey also mentions good results in arterial and rheumatic cases from the use of the radium-charged atmosphere of the emanatorium and from radium-charged waters, taken internally.

SYPHILITIC AORTIC DISEASE. G. W. McCaskey, p. 60.

This is a case report with polygraphic tracing which the author interprets as representing an asynchronism in the contracture of the ventricles. His conclusion is based upon a bifurcation of the R wave in his tracing. He holds that the R wave represents an electrical event due to a relative negativity of the base of the heart, at the moment preceding ventricular contraction, *i.e.*, it is a record of the electrical phenomenon which precedes and is responsible for the ventricular contraction. A positive Wassermann, a doubtful luetin test, an aortic lesion with a Corrigan pulse, mark this case, in the opinion of the author, as one of syphilitic infection of the myocardium and aortic orifice. The steady improvement under antisyphilitic treatment seems to substantiate this view.

SYNCOPE IMMEDIATELY AFTER THE ADMINISTRATION OF DIARSENOL. S. H. Likes and H. Schoenrich, p. 64.

The authors call attention to syncope in three cases, immediately after the injection of this substitute for salvarsan. The three cases cited occurred in an experience consisting of some fifty or sixty injections. In the third of the accidents, the contrast in the effect of salvarsan and diarsenol upon the same individual was evident. He had had twelve injections of 0.6 gm. each of salvarsan, without any unusual reaction. The first dose of the new preparation caused marked syncope and vasomotor collapse in two minutes. The authors believe that the preparation in general is good and its effects similar to those of salvarsan. They ascribe the accidents to variability in the quantity and quality of diarsenol, in the occasional ampoule, due to careless measurement and chemical construction. They will attempt to avoid future similar accidents by using smaller doses.

MEDICAL RECORD.

(May 6, 1916, lxxxix, No. 19.)

Abstracted by James F. Grattan, M.D.

A URINARY TEST FOR SYPHILIS AND ITS COMPARISON WITH THE WASSERMANN REACTION. C. D. Gray, p. 821.

The author reviews a series of cases tested, part of which series was controlled by the Wassermann blood test. The urinary test is performed as follows: The urine must be a fresh specimen to rule out decomposition products, must be acid and must have a specific gravity over 1.016. Sugar reactions must be negative, as the presence of sugar renders the reaction positive, even in the absence of syphilis. Recent use of beer or stronger alcoholic beverages interferes with the result, as does polyuria from the use of diuretics or excessive water intake, to allay prolonged thirst. With the above factors ruled out, we may proceed with the following reagents: (*a*) 1 gram of resublimed iodine

in chloroform or carbon tetrachloride; (*b*) 10% phosphoric acid. Take 6 cc. of urine, add 1 cc. of the first solution and shake thoroughly for two minutes; the tube is set aside. The chloroform settles to the bottom, and assumes either a pearly white color (negative reaction), or becomes pink or purple, which is probably a positive reaction. One cc. of the second solution is added and the tube is again shaken. If the chloroform is cleared, the test is to be considered negative.

Two tables are given—the first containing 200 cases, in which positive reactions were obtained in 52 cases which were known to be syphilitic. Five of these cases were in the primary stage. Five cases of glycosuria, 5 cases of polyuria of nervous origin, and 10 cases of polyuria due to diuretics, also gave positive reactions. In the second table, 35 cases of suspicious or definite nature are reviewed. All of these cases were controlled by the Wassermann blood test. The latter was positive in 24 of the cases, while the urine test was positive in 32. All cases were justly suspicious. In no case in which the Wassermann was positive, was the urine test negative.

THE INTRAVENOUS ADMINISTRATION OF MERCURY IN SYPHILIS. T. Shaw, p. 823.

The need of a cheap drug and the scarcity of the European arsenic preparations led the author to experiment with the mercury salts. The bichloride was found to be the most efficient. Solvents that were compatible with the blood presented a problem. At first, sodium chloride was added to prevent laking of the blood by distilled water, but a chemical change was found to occur, probably the breaking up of $HgCl_2$ into HCl and HgCl, resulting in a rise in temperature, cramps, bloody stools, urinary suppression and albuminuria. After experiments with the different salts and solvents, the simple solution of $HgCl_2$ in distilled water, in the proportion of 1 gram to the ounce, was found to be most satisfactory. The dosage used was 1/12 to 1/6 of a grain, every 5 to 7 days. Improvement was noted in 16 cases, with a rapid, marked improvement in 50% of this number.

(*Ibidem*, June 3, 1916, lxxxix, No. 23.)

THE EPIFASCIAL METHOD OF INJECTING MERCURY AND SALVARSAN DERIVATIVES. A. Wolbarst, p. 999.

Wolbarst believes that the intramuscular method of giving salvarsan and its derivatives is much more effective than the intravenous method, the great disadvantage of the former method being the great amount of pain experienced after the injection. He mentions Ehrlich and Wechselmann as concurring in this belief. Wechselmann, in an attempt to effect a compromise between the diminished effectiveness of the intravenous method and the painful after-effects of the intramuscular method, devised a third, the epifascial method. Wolbarst observed that about 50 per cent. of Wechselmann's patients suffered little or no pain after the administration of large doses of neosalvarsan, epifascially. Owing to the high price of the arsenic preparations, Wolbarst's experience, since observing Wechselmann's technique, has been limited to fifteen injections of neosalvarsan, but he has given over 200 injections of the mercury salts by the new method. He has recorded that 20 per cent. have been absolutely painless, 60 per cent. more or less painful for twenty-four hours or less, while the remaining 20 per cent. have suffered more or less severe pain for periods varying from one day to two weeks. The particular preparation used does not seem to control the amount and duration of the pain. The per-

sonal equation seems to have considerable effect upon the interpretation of the pain. In some the pain is directly at the site of injection, in others it is about two inches below (gravitation), and in others it may be referred along a nerve trunk (the sciatic).

Technique. The needle is plunged into the gluteal muscle and manipulated until it feels to be free and not limited in its motions by muscle fibres. To test the correctness of this sensation, sterile water, saline or a local anæsthetic is injected and the syringe removed. If the tip of the needle is epifascial, the fluid will return steadily, drop by drop. If in the muscle, there will be no reflux. The needle is plunged in at right angles to the side of the buttock. A needle 1½ inches long is desirable. If in the test for location of the needle tip, 10 or 15 minims of 2% novocain or alypin is used, the injection of the therapeutic agent will be practically painless. It is best to use separate syringes for the anæsthetic test fluid and for the injection of the drug.

(*Ibidem*, June 24, 1916, lxxxix, No. 24.)

WHAT IS THE POSITION TO-DAY AS TO THE VALUE OF BLOOD AND CEREBROSPINAL FLUIDS IN THE DIAGNOSIS OF SYPHILIS OF THE NERVOUS SYSTEM? E. D. Fisher, p. 1127.

The variability of laboratory tests in syphilis of the nervous system, the findings of positive blood Wassermann with negative fluid Wassermann, and vice versa, in cases which are clinically unmistakable as cerebrospinal lues, leads us to stand firmer upon our clinical knowledge than upon laboratory tests, using the latter as confirmatory of the ætiology and as a guide to the method and extent of our treatment. True cerebrospinal syphilis, the author holds, follows soon after the primary lesion, is acute in its course, involving the blood vessels and meninges, while meta- or para-syphilitic affections are late in occurrence and insidious in onset. In the latter conditions the parenchyma of brain and cord are involved, as well as the meninges. In the matter of therapeutics, Fisher regards the serological tests a great help but insists upon the presence of clinical manifestations. In the absence of the latter and in the face of positive tests, he advises against antiluetic treatment.

(*Ibidem*, July 1, 1916, xc, No. 1.)

THE PRESENT CONCEPTION OF CONGENITAL SYPHILIS AND ITS MODERN DIAGNOSIS. A Rostenberg, p. 14.

The germinative theory of transmission of syphilis to the offspring, based upon Colles' law, that an apparently healthy mother could give birth to a luetic child and at the same time acquire an immunity, has been disproven since the perfection of the serological tests. These same tests have substantiated the theory contained in Matzenauer's "Vererbung der Syphilis," published in 1903, in which he maintained that it was the mother alone, carrying the infection in her placenta, who transmitted the disease to the fœtus. The intervillous spaces were later found to contain spirochætæ in practically all cases examined by various observers. This finding was a fatal blow to the older theory and to Colles' law. The fact, as we now know it to be, is that the mother's immunity was established long before the child's birth, due to infection of herself. The spirochætæ are poured into the fœtus from the maternal side of the placenta, and the extensive dissemination of the infection in congenital syphilis seems to substantiate this theory. The toxæmia corresponds to the severe toxæmia of the second stage of the acquired type, and there is

no stage corresponding to the primary stage of the acquired type. If both parents have lues in an active form, the fœtus can scarcely escape,—usually it does not develop, a miscarriage results. If the parents are under treatment, the fœtus may develop but will show the luetic stigmata soon after birth. If the mother acquires syphilis after conception, the child may be born and live without luetic stigmata, but if a Wassermann is done, it will usually show a positive reaction. Finger and Landsteiner, and Bab, have succeeded in infecting monkeys with the sperma of a syphilitic man. This may explain the secondary manifestations in a pregnant woman and the stigmata in the child, if miscarriage does not intervene, when the mother has never had an initial lesion. This is an exception to Matzenauer's theory. According to Fournier, the mother, in these cases, is infected by the fœtus. Maternal syphilis persists much longer than paternal, as far as infectivity of the offspring is concerned. A woman infected twenty years previously, may bear syphilitic children to a perfectly healthy second husband.

The diagnostic features of a still-born luetic are, macerated, peeling skin, enlarged thymus containing multiple abscesses, white hepatization of the lungs, enlargement of liver, spleen, pancreas and kidneys, due to interstitial fibrosis and gummata. Spirochætæ are present in abundance in all organs. At the ends of the long bones there is a zone of ossification between epiphyses and diaphyses. Islets of cartilage are found in the bone and islets of bone in the cartilages. The placenta is larger and more solid than normal, and is more friable, resembling sausage meat. Gummata and vascular changes in the villi are present. The decidua shows gummatous endometritis. The umbilical cord is thickened and there is thickening of the vessel walls. Spirochætæ are found throughout the placental and cord structures. An infant, luetic at birth, is rarely born alive. Most infants born alive appear healthy, but show stigmata from the first to twelfth week. Desquamation of the palms and soles or syphilitic pemphigus may appear in a day or two. The child begins to waste away when the stigmata appear and assumes the appearance of a little old man. Pemphigus and copper-colored spots are the usual skin lesions. Condylomata about the anus are frequent. "Snuffles" is very characteristic. The Wassermann reaction is present in all mothers of syphilitic children, showing signs as above, but the test is unreliable in the infants, due to an inability of the weakling to form antibodies. Fifty per cent. of all syphilitic fœtuses are born dead, and seventy-five per cent. of those born alive die within the first year.

(*Ibidem*, July 8, 1916, xc, No. 2.)

RADIUM EFFICIENCY IN NON-MALIGNANT SURGICAL CONDITIONS. R. Abbe, p. 47.

Vernal catarrh, a recurrent inflammatory reaction in the lids, intractable to ordinary treatments, yields readily to fifteen minutes' application of strong radium held under the lid and moved about from side to side. A lead pencil with a groove on the side for the radium, the lead being encased in a celluloid holder, is used. Ten cases have been treated. One has remained cured ten years. The applications are repeated every four to eight weeks.

Lymphoid tumor tissue, or hæmolymphangiomata, disappear under radium, though other forms of treatment do not yield good results.

Skin warts and papillomata on the mucous surfaces disappear under radium action. A cure lasting five years was obtained in a singer with papillomata of the larynx.

Leucoplakia of the tongue can be cured by radium. Painful irritation often follows, but this reaction is essential to cure.

Abraded ulcers of the lips, practically continuous, or at least frequently intermittent, because subject to irritation of food, drinks and the tongue, are curable by radium. The chronic painful crack of the lip will heal under radium treatment.

Keloids, defying surgery, yield to radium. The applications must produce irritation to be effective.

Uterine fibroids diminish remarkably when treated by a uterine applicator, and hæmorrhage of the submucous nodules stops after the first or second treatment, even when manifested to a marked degree.

MEDICAL PRESS AND CIRCULAR.

(June 28, 1916.)

Abstracted by Oscar L. Levin, M.D.

A NEW AND SIMPLE TEST FOR SYPHILIS. J. E. R. McDonagh.

From 5 to 20 cc. of blood is taken and allowed to clot. The serum is drawn off. Cloudy or blood-tinged serum does not affect the result. Two cc. of glacial acetic acid are placed in a dry and clean test tube and 0.5 cc. of the serum is added. The combination is shaken. Four dry, clean test tubes are placed on a rack. One cc. of glacial acetic acid is placed in each, and they are labelled A, B, C and D. Into A are placed 2 drops of the acid serum, into B 4 drops, into C 6 drops and into D 8 drops. A finely-drawn pipette is used to make the drops as small as possible. The tubes are shaken. Then 0.2 cc. of lanthanum sulphate (thorium sulphate or nitrate may be substituted) are added and the tubes again shaken. Positive and negative controls are used. In the positive control a precipitate is first seen in D and then in C, B and A. In a half hour or more, the precipitate will have fallen in all four tubes, leaving a clear solution above. In the negative control the precipitate forms slowly and does not leave a clear supernatant fluid.

Positive results were obtained in practically every justly suspicious case in a series of 200. All were controlled by the Wassermann reaction, which was negative in 37 cases with definite histories.

The test depends upon the fact that syphilitic sera contain more lipoid proteins in the form of emulsoids than do normal sera. These emulsoids are converted into a gelatin by freeing them from their salts, by the addition of glacial acetic acid. The author calls the test the "Gel" test.

BOOK REVIEW.

DISEASES OF THE SKIN. By Henry H. Hazen, A.B., M.D., Professor of Dermatology in the Medical Department of Georgetown University; Professor of Dermatology in the Medical Department of Howard University; Sometime Assistant in Dermatology in the Johns Hopkins University; Member of the American Dermatological Association. Two hundred and thirty-three illustrations, including four color plates. *C. V. Mosby Company*, St. Louis, 1915. (539 pages.)

As time goes on, the writing of a new text book on dermatology and syphilology, in this day of many excellent works of the kind, becomes a more and more arduous and time-consuming task. To write a text book which displays any great amount of originality is to-day a well nigh impossible feat. Nevertheless, Hazen has succeeded, in this work, in at least presenting us with a book which contains much of original thought in the depiction of cutaneous diseases, in the interpretation of the histological changes which characterize them, in his methods of treatment, etc.

The book is intended especially for undergraduate students. In his arrangement of the various classes of diseases, Hazen carries out a scheme of classification which will appeal strongly, also, to instructors of dermatology. The first seven chapters deal with the usual introductory subjects of anatomy, physiology, ætiology, symptomatology, etc., the last of the seven chapters being devoted to hygiene. The next ten chapters are headed with titles beginning with the words, "Diseases due to" with the exception of Chapter VIII, which deals with congenital affections. In these chapters, the author groups the diseases, as far as is permissible, with an eye to ætiological factors, under captions such as: Diseases due to local irritation; to local bacterial infection; to animal parasites; to systemic infection with spirochætes, under which he includes syphilis, gangosa and frambœsia; to diseases of the blood vessels and lymphatics; to nerve changes, etc., etc. The succeeding chapters are arranged with a view toward the correlation of the morphological characters of cutaneous eruptions, under such titles as exfoliating erythrodermias, follicular keratoses, etc. Separate chapters are given to pellagra, cancer, benign and malignant tumors of epithelial and non-epithelial origin, nail and hair diseases, anomalies of sweat secretion, etc. Such a method of classification, or rather, of arbitrary arrangement, seems to be more easily grasped by the undergraduate student, in beginning the study of dermatology, than is the older method of Hebra. During the past semester, the reviewer has found the book especially valuable as a personal guide in his quiz classes, in so far as a short perusal of a certain group of diseases enabled him to pick out "leading questions," with a minimum waste of time and energy.

One of the outstanding features of the book is the well deserved respect paid to the histopathology of the commoner affections, a subject with which Hazen has a most intimate acquaintance; this does not, however, imply that his knowledge of the rarer histopathological alterations in the field of dermatology is not equally intimate.

Exceptionally well presented are the chapters on eczema, syphilis and cutaneous cancer. Especial attention is directed towards the occurrence of skin diseases in the negro, from which race the author draws a considerable propor-

tion of his text material in the various clinics which he attends. This will appeal more especially to those who appreciate the difficulties of diagnosis of cutaneous affections in colored people.

The book is profusely illustrated, more especially with the commoner dermatoses, and contains numerous reproductions of original histopathological plates. The vast majority of the latter are beyond criticism, but the reviewer hopes to see better reproductions of some, as those of lichen planus and molluscum contagiosum, in the forthcoming editions of the book.

The temptation to point out typographical errors is great, but is hardly within the province of the reviewer. He will, therefore, desist from calling attention to more than two errors of this kind: radiochro*n*ometer should give place to radiochromometer; and corpus *luetin* should be discarded for corpus luteum.

References to literature are quite up to date and appear in the form of numerous footnotes, which greatly enhance the value of a book of this kind, in the hands of the advanced dermatologist and the practitioner.

To those whose work includes the teaching of dermatology and syphilology, the book will prove to be a valuable asset. F. W.

THE ABSTRACT DEPARTMENT.

Because of the European War we are not receiving many of the foreign journals. We will make the Abstract Department as complete and as interesting as possible. At the termination of the war, we will endeavor to briefly abstract every article of dermatological interest in all the important medical journals.

DEATHS.

Dr. H. C. Baum, Syracuse, N. Y.
Dr. B. Wolff, Atlanta, Ga.

THE JOURNAL OF
CUTANEOUS DISEASES

Vol. XXXIV NOVEMBER, 1916 No. 11

ORIGINAL COMMUNICATIONS.

ACRODERMATITIS HIEMALIS.*

By M. B. Hartzell, M.D., LL.D., Philadelphia.

Professor of Dermatology in the University of Pennsylvania.

In a paper entitled, "A Clinical Study of Some Winter and Summer Recurring Eruptions," Crocker, in 1900, reported three cases of a cutaneous affection characterized by an eruption which was situated exclusively upon the hands, particularly about the knuckles and sides of the fingers, occurring in the winter only, to which he gave the name *acrodermatitis pustulosa hiemalis.* The eruption began as small, firm, red papules which, after enlarging somewhat, became pustules, upon which crusts formed and after a time fell off, leaving small scars. Not all of the lesions, however, underwent this transformation, but some of them remained papules, which after a time disappeared without scarring. If punctured soon after they appeared, a watery fluid escaped from them. The disease had lasted in one case six years, in another ten years, and in a third two years. One of the patients had a tuberculous family history and had herself suffered from "scrofulous

* Read before the 40th Annual Meeting of the American Dermatological Association, Washington, D. C., May 13 to 15, 1916.

caseating glands." The number of lesions was usually quite small; they came out in crops and ran a course of about a fortnight, but their duration was greatly prolonged in cold weather, some of them lasting three months. Crocker was inclined to regard the affection as a variant of the *folliclis* of Barthélèmy.

Although Crocker was the first to call attention to the malady in a formal way, a few cases of it had been previously described. Cavafy, some years before, had reported one as an unusual affection of the hands, which he exhibited at a meeting of the London Dermatological Society. It was characterized by an abundant eruption of small, firm, flat papules with an occasional vesicle in the centre, a few pustules and numerous vesicles in the palms. It had recurred for three successive winters and lasted until the coming of summer, and was unaccompanied by any subjective symptoms worthy of notice. Cavafy was inclined to regard the case as an aberrant form of erythema multiforme, but Jonathan Hutchinson, who saw the case, stated that he had seen a number of similar ones, and thought it an example of what he had called "chilblain lupus." Crocker referred to this case in his treatise, and regarded it as an example of the affection which he had described later. In 1898, Allen, a late member of this Association, presented a case of what he called "necrotizing chilblains," before the New York Dermatological Society, in which small red nodules appeared upon the hands and feet in winter, or occasionally after washing in cold water; the papules underwent central necrosis and were followed by scars. Since the publication of Crocker's paper, Eddowes has reported a case which he thought belonged in the same category, and Ormsby, in his recent work on diseases of the skin, refers to one which he presented at a meeting of the Chicago Dermatological Society.

A small group of cases resembling in many, but not in all respects, the affection described by Crocker, has come under the author's observation, three of them in the past winter. The first case, which was seen so long ago as 1898, was much the most characteristic of the group, was longest under observation, and will, therefore, be described with some detail.

Case Reports.

Case 1. B., 29 years old, a car-driver by occupation, and therefore much exposed to the vicissitudes of the weather, consulted me in the latter part of October, 1898, for an affection of the hands, from which he had suffered for the previous nine winters. The attack was just beginning, and he had a single papulo-vesicle upon the dorsal surface of the right index finger, which itched severely. No new lesions appeared until the middle of November, when several dark-red, slightly elevated, flat, painful papules appeared on the backs of the

fingers of both hands, and the third phalanx of the left index finger became red, painful and swollen; both hands were markedly cyanotic, as if cold, although the outside temperature was 48° F. Three weeks later, there was a new crop of shot-sized, hard papules, limited as before, to the fingers. After another period of quiescence of about three weeks, another outbreak occurred, consisting of a considerable number of dull-red, pea-sized, erythematous, slightly elevated lesions, on some of which vesicles developed. All were painful, and one of them over the knuckle, when pressed or rubbed, gave out a curious faint creaking sound like new leather when it is rubbed. This was the most severe attack observed during the winter; in February but a single papule was seen upon each hand, and early in March the disease seemed to have come to an end, at least for the season. The eruption was always a strictly papular or papulo-vesicular one—there were never any pustules, and no scarring followed, differing in these particulars from the cases of other authors. Although no eruption was observed on any other part than the fingers, the patient stated that in other years, he occasionally had lesions on his ears, like those upon his hands.

This case remained for some years unique in the author's experience, but as already observed, three new ones were seen during the winter just past, which presented the same symptoms, although in a much less marked degree.

Case 2. Miss W., 28 years old, a saleswoman in a department store, and therefore but little exposed to the weather, consulted me, about the middle of last December, for an eruption confined to the fingers and toes, which consisted of a few quite small, dull-red, ill-defined patches and a limited number of discrete vesicles, accompanied by severe itching and burning, which caused the patient great distress. It had lasted five or six weeks, having begun about the first of November; and this was the second winter of its occurrence.

Case 3. Miss A., a school-teacher, 27 years old, was seen December 15 of last year, suffering from an eruption which she had had for three successive winters, confined to the fingers. As in the preceding case, the dorsal surface of the fingers was the seat of a few dull-red patches which itched and burned, and the patient stated these had begun with the appearance of vesicles. She was quite certain that there had never been any sign of eruption in the summer months.

Case 4. On December 26th, 1915, Miss M., 29 years old, was brought to me for advice concerning an eruption consisting of a few dark-red, non-elevated spots on the palmar surface of the fingers of both hands and a small number of similar but somewhat larger patches, at the roots of the nails of several of the fingers, some of which were covered with a scanty, fine, loose scale; there was also a history of there having been a few scattered vesicles at times. The eruption had lasted three months, having begun in the early autumn, and was similar to one which she had had the previous winter, and which lasted until the appearance of spring. The small patches on the backs of the fingers suggested, in some respects, a very superficial erythematous lupus, but the vesicles which accompanied them in the beginning, and their complete disappearance in the summer, made such a diagnosis improbable.

Through the courtesy of Dr. Knowles I am able to add to the foregoing cases brief notes of one which he exhibited at a recent meeting of the Philadelphia Dermatological Society. A young woman, 26 years old, a domestic, presented a few discrete, sluggish, dark-red, pea-sized papules, some of them with pustular tops, situated upon the fingers. These dried up into crusts, which

after a time fell off, leaving depressed scars. They came out, a few at a time, during cold weather and ceased to appear with the coming of warm weather. The patient's general health was somewhat below normal, but she presented no evidence of tuberculosis: her hands were dusky-red (chilblain circulation). The lesions were quite like the papules of the papulo-necrotic tuberculide, but were strictly limited to the fingers, and appeared only in the winter, this being the second season in which they had appeared.

To recapitulate very briefly the most characteristic features of this small series of cases, the eruption was made up of a limited number of small, flat, dull-red papules, a lesser number of small, erythematous patches, and with the exception of Knowles' case, a few discrete vesicles, strictly limited to the fingers in the majority of cases, but occurring in one case upon the toes, and in one upon the ears, coming out in small crops, at intervals of two or three weeks, in the autumn and winter only, and accompanied by severe itching and burning. All the cases occurred in young adults who were apparently in normal health, although the first case exhibited a marked cyanosis of the hands in cool weather. Although these cases differed from the majority of those reported by other observers in the absence of pustulation and scarring, I have no doubt that they belong in the same category. These, with the cases previously reported by other authors, seem to represent a distinct morbid entity, and for that reason deserve to be separated from other cutaneous affections. On the one hand they seem to be closely related to chilblain, and on the other to the papulo-necrotic tuberculide. Some of the cases described by Crocker and those of Allen and Knowles certainly bear a close resemblance to the latter affection in the character of the lesions, but differ from it in the course which they pursued, in their marked seasonal incidence and in the limitation of the eruption to the hands.

For the purpose of learning something definite about the temperature conditions of the seasons in which the disease began and declined, in the cases here reported, the records of the Weather Bureau were examined, with somewhat unexpected results. It was found that the mean temperatures for October and November, 1915, in Philadelphia, the months in which the eruption began to appear in three of the cases, were 56.3° F. and 44.9° F., respectively, while the temperatures for March and April of the same year, the months in which it had declined or disappeared, were 40° F. and 50.8° F., respectively; an examination of the mean minimum temperatures gave practically the same result. From these figures it is at once apparent that the temperatures were higher in the months in which it began than in those in which it was declining

or had disappeared; and that, therefore, it is likely that some other seasonal influence besides comparatively low temperature is concerned in its production.

A word or two as to the treatment: All the patients complained much of itching and burning, and a number of local remedies were tried, but none of them afforded much relief except ichthyol; and this in every instance produced more or less improvement in the symptoms. A twenty-five to thirty per cent. solution in water was painted on the affected parts in the evening, allowed to remain all night and washed off the next morning with hot water, the patient's occupation in most cases precluding its use during the day.

Discussion.

Dr. Pusey said he would like to ask Dr. Hartzell for the exciting factor of the condition, if it had not been cold.

Dr. Ormsby stated that a case similar to these reported by Dr. Hartzell had come under his observation. In this particular case he had never seen any vesicles, but regarded the case as an example of acrodermatitis hiemalis. In this case there were bluish nodules and small pustules, the latter having horny plugs in their centres. An interesting point in this case was the fact that there were large glands in the neck, which were later removed, and following their removal, the disorder largely disappeared. During the time the patient was under observation, previous to the operative procedure, ichthyol, applied locally, appeared to be of service. The speaker stated that this disease was somewhat different from the papulo-necrotic tuberculides, but there appeared to be some points of resemblance.

Dr. Wise said he would suggest that if the lesions were not due to exposure to cold, they may have been due to the sudden onset of cold weather—a sudden variation in temperature.

Dr. Ravogli said he had seen at times vesicular eruptions on the hands and fingers, rather stubborn, he had thought, to be due to perspiration as a form of hydrosadenitis and the season could have some ætiological relation. In other cases this condition seemed to be due to herpes tonsurans. He had used Wilkinson's ointment, which had given favorable results.

Dr. Knowles said he had found ichthyol to work best in a case like this, which he had under observation.

Dr. Goldenberg said he was very much obliged to Dr. Hartzell for having called attention to this diagnosis, for he had labeled two cases wrongly as frost bites, which he was fully convinced belonged to that type. In his two cases the very peculiar feature had been the seasonal influence which prevailed. The speaker nearly had a fight with one patient who had said the eruption did not appear in very cold weather, but disappeared when it got colder. The two cases which he had labeled wrongly, belonged to this type. In regard to the suggestions made in the treatment of these cases, he had only treated them this winter, it being rather an experiment, with lactate calcium, internally. In frost bites this drug worked very well and should be used for a long time in the early fall, in order to prevent a recurrence of the eruption.

Dr. Brayton thought that the title was fitting and expressed a definite pathological entity. He had two cases under observation which very closely followed the symptomatology detailed by the essayist. Regarding it as possible strepto-

coccic infection, he had used selected stock vaccine, to no avail. Each of these cases had lasted from early boyhood to mature life. One was an office helper, doing inside work without notable exposure; the other was a railroad conductor suffering incidental exposures. In each of the cases the disease began late in October or early November, and became markedly better in the pleasant days of late spring. The speaker had regarded the disease as a persistent papular and vesicular eczema.

Dr. Wallhauser said that he would like to add a case of three or four years' duration, which corresponded very well with Dr. Hartzell's description. The treatment which had succeeded in arresting this case, consisted of having the patient immerse the hands, first in hot and then in cold water, alternating every few minutes for half an hour; this was followed by an ordinary dusting powder.

Dr. Hartzell said, in reply to Dr. Pusey's question, that he was unable to say what the cause of the affection was, but he felt quite sure that cold was not the only factor in its production. In his hasty summary he had omitted to say that in Crocker's cases, as well as in those of others, scarring followed the eruption; in other respects his cases resembled those reported by other observers.

In reply to Dr. Wise's suggestion, that it might have been due to sudden cold, he would say that his first case began when the outside temperature was as high as 48° Fahrenheit. In reply to Dr. Ravogli's suggestion, that it might be a form of herpes tonsurans, he might remind him that we knew of no ringworm fungus which grew in winter only. In answer to Dr. Wallhauser, he might remind him that in the case reported by Dr. Allen, bathing in cold water brought out the eruption.

AN UNUSUAL VARIETY OF VITILIGO (LEUCODERMA ACQUISITUM CENTRIFUGUM).

By Richard L. Sutton, M.D., Kansas City, Mo.

Our knowledge of the ætiology and pathology of vitiligo has advanced but little, if at all, since Hebra's[1] day, and the statement of that eminent authority that in the greater number of cases we must fall back on the suggestion of a disturbance of innervation, a bad cloak for one's ignorance, as a cause for the condition, holds good now as it did then.

A limited number of instances have been observed following local injuries, and Hebra has pointed out that the first white spot may occur close to a previously existing pigmentary nævus. Shepherd[2] has seen one case where the disease apparently commenced from the pressure of a collar stud, and another from the spots left after burning warts. Lecat[3] once saw the malady develop in a negro after a burn, and Alibert[4] quotes Hamilton regarding a similar occurrence in a negro, following a surgical operation. Recently I had opportunity to study a striking example of the disease which developed following syphilitic lesions of the nodular type. The subject was a coal-black negro, and the skin underlying the whitened areas was unaltered, except for the pigmentary changes. The source of epidermal pigment is not definitely known. The views of various investigators have recently been admirably summarized by Meirowsky[5]; Kolliker[6] and Caspary[7] conclude that all branched cells of the epidermis are connective tissue cells; Ehrmann[8] holds that the pigmented epidermal cells develop from mast cells, and have nothing to do with connective tissue cells, leucocytes, or epithelial cells; Riehl,[9] Abby,[10] Meyerson,[11] and Rabl [12] believe that pigmented cells are, in part at least, emigrant leucocytes; Schwalbe,[13] Unna,[14] and Kromayer[15] consider the branched pigment bodies as acellular structures, which, according to Kromayer, Jarisch,[16] Post,[17] and Grund,[18] develop from ordinary epithelial cells.

The results of Hellmick's[19] researches also indicate that the coloring matter is a direct product of the epidermal cells, and not a hæmatogenetic substance which has been conveyed to the epidermis by chromataphores. Hellmick concludes that the epidermis has in itself the power of forming pigment, and that the nuclear substance is probably the mother substance of this pigment. More recently, Hooker,[20] of Yale, has demonstrated the development of stellate pigment cells in plasma cultures of frog epidermis. On studying Harrison plasma cultures of

the epidermis of 3 to 4 mm. embryos of *Rana pipiens,* the elaboration of pigment was observed in some of the epidermal cells, at first appearing as a mass of brown granules in the immediate vicinity of the nucleus, the pigment gradually spread throughout the entire cell. The ratio of pigment-forming cells to those which formed none was about 3 to 1. After the elaboration of a considerable amount of pigment, these cells either actively or passively migrated to a position below the non pigment-bearing cells. In this position several assumed a stellate form by sending out pseudopodia. Indirectly, Hellmick's conclusions are also supported by the investigations of Spiegler,[21] who has shown that none of the high chemical products of the coloring matter of hæmoglobin can be obtained from the pigment of the hair, so that the origin of hair pigment from hæmatin seems impossible.

Judging from the variable results of therapy in different cases of vitiligo, it would appear, theoretically at least, that in some instances the nuclear changes are of such a character as to preclude further regeneration of pigment, while in others it is possible, under certain conditions, to bring about a return of the coloring matter. Anatomically, it is generally conceded that the lesions of leucoderma present none other than pigmentary changes. The atrophy of the terminal nerves noted by Leloir,[22] in 1881, has not been confirmed by modern investigation.

Recently I have encountered two cases of vitiligo which presented some unusual features, both clinically and histologically.

Case Reports.

The first patient was a housewife, aged 22, referred to me by Dr. T. J. Beattie, of Kansas City, in October, 1915. The personal and family histories were negative. There was a single rounded lesion, located on the right cheek. The spot measured a little more than 2 cm. in diameter, and had been present three months. There was no history of trauma. Exactly in the centre of the patch was a minute, rounded, slightly elevated, brownish maculo-papule which somewhat resembled a small, pigmentary nævus, but which the patient said had been present only since the onset of the attack. The hyperpigmented areola commonly found in vitiligo was absent. The lesion had developed slowly, and has never given rise to subjective symptoms of any kind. The patient was somewhat sensitive regarding the blemish, and objected to having it photographed. Permission to perform a biopsy also was refused. A 1% solution of mercuric chloride in alcohol and water was prescribed, to be applied frequently to both the central portion and the margin of the patch, in order to lessen the disfigurement. Shortly afterward the young woman removed to Southern California, and I had no further opportunity to study the case.

The second patient was a schoolgirl, aged 16, referred to me by Dr. W. F. Fairbanks, of Kansas City, Kansas, in 1915. The disorder had first become apparent three years before, but the earliest patch, which was located on the

right side of the forehead, had gradually regained its normal color, and at the time of consultation was scarcely discernible. A second small patch in the left clavicular region also was very faintly defined. Two other lesions, in the right and left scapular regions respectively, had changed but little, however, since attaining their present size, and stood out sharply as snowy, oval plaques with normally pigmented borders. The centre of each spot was marked by the presence of a small, roundish, brown maculo-papule. The patient's mother said that the lesions had begun as minute, brownish points, which were usually, but not invariably, sufficiently elevated to be perceptible to touch. There was no history of trauma, or of preëxisting nævi. The family history was negative. A careful physical examination of the patient revealed nothing abnormal. There was no reaction to tuberculin, and both the Wassermann and luetin tests gave negative results.

Only one small piece of tissue could be secured for laboratory study. This was excised by means of a cutaneous punch from the centre of the patch in the right scapular region. At the time the biopsy was performed, the mother promised me more material later, and for this reason only the simpler staining methods were employed in the preparation of the specimen obtained. Unfortunately, the little patient proved more refractory than the parent, however, and up to the present, permission to perform a second biopsy has been refused. The material was fixed in formalin, and sectioned in a freezing microtome. For staining purposes, hæmatoxylin-eosin, Unna-Pappenheim's methylene blue, and Weigert's preparation were used.

Histopathology. The stratum corneum was slightly thickened and parakeratotic. The prickle layer was increased in depth and the basal cells exhibited signs of active proliferation. The epidermis contained large amounts of pigment. The papillæ were hypertrophied and somewhat swollen. The intrapapillary blood vessels were greatly increased in size, and there was more or less perivascular infiltration, mainly small round cell in character, throughout the upper regions of the derma. The lymphatic channels also were greatly dilated. The most striking change, however, was the presence, throughout the corium, and especially in the areas underlying the inflammatory zone, of masses of tissue of endothelial origin, which stained deeply with the basic dyes. The perivascular regions were richest in this newly deposited material, but few localities in the subpapillary region were entirely exempt. No pigment was found in the derma. The skin glands were apparently unaffected. The elastic fibres, particularly those in the papillary region, were shorter, and straighter, and stained less deeply than those in normal tissue.

The second case here described has now been under observation for more than one year, and during that time the appearance of the lesions has changed but little, if at all, despite the frequent employment of various chemical and actinic irritants, calculated to hasten the formation of pigment.

References.

[1] Hebra. Diseases of the Skin, Sydenham Trans., London, 1874, iii, p. 180.
[2] Shepherd. Morrow's System, N. Y., 1895, iii, p. 459.
[3] Lecat. Cited by Hebra, *loc. cit.*
[4] Alibert. Cited by Hebra, *loc. cit.*
[5] Meirowsky. *Monatsh. f. prakt. Dermat.*, xlii, p. 151. *Idem, ibid.*, xliii, p. 391. *Idem*, Ueber den Ursprung des melanotischen Pigments der Haut und des Auges, Leipzig, 1908.
[6] Kolliker. *Ztschr. f. wissenschaftl. Zoölogie*, 1883, xlv, p. 174.
[7] Caspary. Verhand. auf dem X internat. med. Kongress, Berlin, iv. *Idem*, Verhand. d. Deutsch. dermat. Gesellsch., Berlin, 1906. *Idem*, Mraçek's Handbuch, ii, p. 571.
[8] Ehrmann. Bibl. Medica, D. II, Heft 6, Cassel, 1896. *Idem, Arch. f. Dermat. u. Syph.*, 1892, p. 397. *Brit. Jour. Dermat.*, 1890, p. 280.
[9] Riehl. *Viertjahrsh. f. Dermat. u. Syph.*, 1884, p. 83.
[10] Abby. Cited by Meirowsky, *loc. cit.*
[11] Meyerson. *Arch. path. Anat.*, 1889, cxviii, p. 197.
[12] Rabl. Erg. f. Anat. u. Entwicklungsgesch., vi, p. 493, Zt. nach Grund.
[13] Schwalbe. *Wien. klin. Wchnschr.*, 1892, v, p. 13.
[14] Unna. Histopathology. *Idem, Monatsh. f. prakt. Dermat.*, 1895, xxi, p. 1.
[15] Kromayer. *Dermat. Ztschr.*, 1897, iv, p. 335.
[16] Jarisch. Verhand. dem X internat. med. Kongress, Berlin, Bd. 4.
[17] Post. Ueber normale und path. Pigmentierung der Oberhautgewebe, J. D., Konigsberg, 1893.
[18] Grund. Beitrag. z. path. Anat. u. Allg. Path., 7 Supplement.
[19] Hellmick. *Monatsh. f. prakt. Dermat.*, xliv, p. 184 (good abstract in *Brit. Jour. Dermat.*, 1908, p. 169).
[20] Hooker. Anat. Record, 1914, viii, p. 103.

Fig. 1.

Leucoderma Acquisitum Centrifugum. Showing character and location of lesions on the dorsal surface of the trunk.

Plate LX.—To Illustrate Article on Leucoderma Acquisitum Centrifugum, by Richard L. Sutton, M.D.

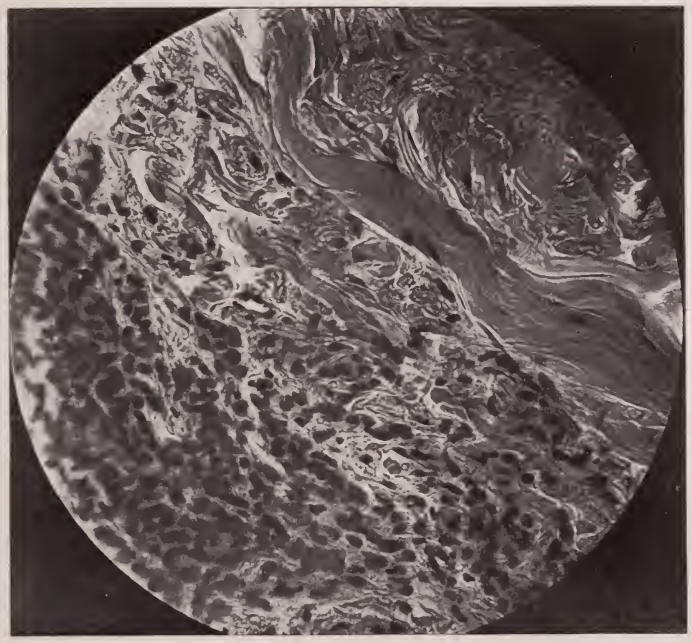

Fig. 3.
(Moderate magnification). Showing endothelial cells in the derma.

Fig. 2.
(Low magnification.) Showing character and distribution of endothelial cells in the derma.

A HITHERTO UNDESCRIBED SUPERFICIAL ATROPHY OF THE MUCOUS MEMBRANES OF THE TONGUE AND MOUTH.

By H. H. Hazen, M.D., Washington.

Professor of Dermatology, Medical Department of Georgetown University; Professor of Dermatology, Medical Department of Howard University.

On February 18, 1914, a patient came to me because of a "spot" upon her tongue. The family history was unimportant. The past history revealed the fact that she had been a trained nurse, but that she had been compelled to abandon her vocation because of symptoms of hyperthyroidism and that for the past five years she had been acting as a companion. She was now thirty-four years of age. There was no history of any gastro-intestinal trouble. She had never used tobacco in any form. A number of teeth had been lost because of pyorrhœa.

The patient stated that the present trouble had started about three months previously, with a small, superficial white patch, that had been discovered accidentally, inasmuch as it had given rise to no subjective disturbances.

Examination revealed a tall, slender brunette, with a slightly enlarged and soft thyroid. There was slight tremor of the extended fingers and the pulse rate was eighty-five. The eyeballs protruded slightly, and there was no wrinkling of the forehead when she looked up. The upper lids lagged a bit about following the eyeballs down. Both Wassermann and luetin reactions were negative.

Upon the dorsal surface of the tongue, opposite the second molar, and about one and one-half centimeters from the left lateral edge, was a roughly oval, sharply circumscribed patch, of which the long axis was parallel with that of the tongue. This patch was ten millimeters long by four in width. The color was a glistening white, so that it closely resembled a scar. There were absolutely no papillæ present. To the palpating finger there was no sense of deep induration, but simply one of a surface atrophy. The upper molar teeth had been removed some time previously and had been replaced by a rubber plate, that apparently fitted very well. At that time I was inclined to consider the condition a scar, although the patient denied any injury to her tongue.

She was seen at monthly intervals, and early in June of the same year it was noted that the original lesion was unchanged, but that just anterior to it, a new patch had developed. This measured six by five

millimeters. The patient was then referred to Dr. Joseph C. Bloodgood, of Baltimore. He told me that he had seen seven similar cases, but that in all of them there was either the history of the use of tobacco or snuff, or of an almost complete anacidity of the stomach.

The patient then left Washington for the summer, and when she returned in the fall, the condition was the same, but in November the anterior of the two patches began to grow slightly, and on January 9,

Showing area of atrophy on left side of dorsum of tongue.

1915, it was noted that the two had coalesced, forming one patch that was twenty-two by ten millimeters in diameter. The photograph was taken at this time. It is to be especially observed that at no time was there the slightest evidence of inflammation. Sensation in the patch was slightly dulled, but in no other way abnormal. Four months later there was no change in the lesion, or in the patient's general condition. Unfortunately it was impossible to secure a biopsy. No treatment of any kind was attempted beyond the use of a simple mouth wash, and the scrupulous care of the teeth and gums.

On December 3, 1915, Dr. Philip Roy, of Washington, referred to me a patient, because of a patch upon the inner surface of her cheek. She was thirty-eight years of age and unmarried and lived in a small country town. Both family and past history were unimportant, except that she suffered from chronic constipation. She stated that the lesion had been

present for about a year, and that it had not changed in any way during this time. Both the Wassermann and luetin reactions were negative.

Examination showed that the gums were in excellent condition. The second lower molar on the left side was missing, and on the buccal mucous membrane, exactly opposite this gap, was an atrophic white area, a little over a centimeter in length, and exactly corresponding in size and shape to the space between the teeth. The edges of this patch, where they were in contact with the teeth present, were distinctly elevated and thickened. There were no subjective symptoms.

A thorough search of the literature at the Surgeon-General's library reveals no mention of an analogous condition. The books dealing with diseases of the tongue and mouth do not mention anything similar. The smooth tongue described by Butler and Spencer [1] as resulting from a superficial glossitis, is certainly not the same condition, nor is the smooth atrophy of the base of the tongue [2] due to syphilis. Wagner's [3] case of superficial atrophy of the tongue is entirely different. Brocq and Pautrier [4] have recently described a median glossitis of the dorsal surface of the tongue, which, however, was always more or less inflammatory and usually showed a considerable papillary condition of the surface.

BIBLIOGRAPHY.

[1] BUTLER AND SPENCER. Diseases of the Tongue, London, 1900, p. 140.
[2] MILNE. *Journ. Amer. Med. Assn.*, 1911, lvii, p. 1040.
[3] WAGNER. Trans. Amer. Laryng. Assn., 1908, xxx, p. 174.
[4] BROCQ AND PAUTRIER. *Ann. d. dermat. et d. syph.*, 1914, v, p. 1.

THE EXUDATIVE DIATHESIS, AND A STUDY OF ACETONE BODIES IN THE BLOOD OF NINE CASES.

By Martin F. Engman, M.D., and Richard S. Weiss, M.D., St. Louis.

Part II.

(From the Department of Dermatology, Washington University Medical School.)

In reviewing the literature on the exudative diathesis, one is impressed with the fact that from the large group of infantile eczemas a perfectly distinct group has been isolated.

The opinion of those who have written on the subject seems to be that it is a disturbance of metabolism, the Czerny school maintaining that it is a disturbance of fat metabolism, and the Finkelstein school that it is a disturbance of salt metabolism. We were of the opinion that if it were a disturbance of fat metabolism, an increase of the acetone bodies of the blood might be expected, provided the disturbance be concerned with the faulty oxidations of fatty acids in the body. As a means of getting some information on this point, we decided to determine these substances in the blood of a number of typical cases of the condition, and we record our results herewith. The method used was that of Shaffer and Marriott,[1] worked out in the Biological Chemistry Laboratories of the Washington University Medical School. We are greatly indebted to them for teaching one of us (Weiss) the technique of the method and for the use of their laboratories.

For purpose of comparison we quote some of Marriott's[2] figures, obtained from both normal and pathological individuals (Table I). From this table we note that the blood of six normal children was examined. The acetone plus diacetic acid varied from 0.5 mgm. to 0.8 mgm. per 100 gm. blood. The betaoxybutyric acid varied from 1.4 mgm. to 4.4 mgm. per 100 gm. blood.

From the results of all of his cases, both children and adults, Marriott concludes that the blood of normal human subjects contains less than 1.5 mgm. of diacetic acid and less than 4 mgm. of betaoxybutyric acid per 100 gm.

We have examined the blood of nine frank cases of the exudative diathesis. In all of them the blood was withdrawn approximately two hours after eating. No attempt was made to estimate the amount of fat in the meal just preceding the blood withdrawn. All of the cases had

some external manifestation of the exudative diathesis at the time (Table II).

Analyzing the results we find that the acetone plus diacetic acid varied from 0.9 mgm. to 4.7 mgm., as compared to Marriott's figures in normal children, of 0.5 mgm. to 0.8 mgm. The betaoxybutyric acid varied from 1.8 mgm. to 6.6 mgm., as compared to Marriott's figures in normal children, of 1.4 mgm. to 4.4 mgm.

TABLE I.*

	Acetone plus diacetic acid	Betaoxybutyric acid
Normal child	0.7	2.6
" " æt. 5	0.6	4.4
" " " 7	0.8	4.4
" " " 8	0.5	1.4
" " " 10	0.6	2.8
" " " 10	0.5	2.8
" adult	0.0	0.0
" "	0.0	0.0
" "	0.0	0.0
" "	0.7	2.1
" "	0.0	2.1

SOME ACIDOSIS FIGURES.

Child in coma	23.4	24.8
" after operation	11.2	24.8
" æt. 2. Syphilis, pyelitis	13.3	15.8
Light diabetic	3.0	7.1
" "	11.9	13.1
Severe "	28.2	37.4
" "	28.0	45.2
Same diabetic, month later	28.0	49.5

The above results are all expressed in terms of acetone, *i.e.*, milligrams of acetone per 100 grams blood.

TABLE II.

	Acetone plus diacetic acid	Betaoxybutyric acid
Case 1	2.5	3.4
Case 2	3.0	5.7
Case 3	3.4	6.6
Case 4	1.5	2.7
Case 5	2.3	4.2
Case 6	4.7	4.3
Case 7	2.6	3.3
Case 8	.9	1.8
Case 9	3.4	2.9

The above results are all expressed in terms of acetone, *i.e.*, milligrams of acetone per 100 grams blood.

* Marriott, *loc. cit.*

These differences, if expressed in percentages, are at first sight quite large; but in no case, as was to be expected, were any such figures found as shown by Marriott in his table of pathological cases. From our findings one might be tempted to say that there is a relatively large increase in the acetone bodies in the blood of exudative children. Such a conclusion, however, cannot be substantiated because there have been published, as yet, too few figures for normal cases. Also it is perhaps to be expected that an increased amount of acetone bodies would be found when the blood is drawn at the height of digestion, as was done in our cases. This, too, is theory as, so far as we know, no consecutive calculations have been done to determine the variation in the acetone content of the blood during various periods of digestion. We wish to emphasize that no conclusions can be drawn from this experimental work, alone. But taking our results, together with clinical evidence, we are able to provisionally dispose of certain contentions and theories in regard to this group of cases and so arrange our ideas into a good working basis for future study and experimentation. The most important point from our experimental work is, that we have been able to show that the acetone bodies are apparently not higher than the few results of Marriott indicate for normal children and that, assuming that Marriott's results represent the true normal values, we believe that there is no acetone body acidosis connected with the exudative diathesis.

The main clinical facts on which we base our conception of the exudative diathesis are, then, the following. (This evidence is drawn from our own cases and the cases reported in the literature.)

There are cases which have improved on a salt-low diet when given good hygienic care and quiet, unirritating surroundings.

Certain cases have improved under the same conditions on a fat-low diet.

Certain cases under the same conditions have improved on ordinary careful diet suitable to their age.

Certain cases have improved when the skin was merely protected from harmful external influences.

Therefore we are unable to convince ourselves that the condition is due to a metabolic disturbance, and attempt to explain it in an entirely different way.

In 1904, Leslie Roberts,[3] in a paper on Cutaneous Reactions, gave the following conception of eczema, which is particularly appropriate in this connection.

"Eczema is not an entity; it is a cutaneous reaction attended by increased transudation of lymph, richer in proteids than the normal

lymph, and which attempts to escape from the tissues by exfoliation of the epidermis. Whenever the equilibrium between the surface tension of the skin and the capillaries is constrained (and by surface tension Roberts means the total effect of all exterior influences on the skin), the natural reaction is eczematization of the skin. Hereditary influences, dietetic disturbances, auto-intoxication, nervous or moral disturbances,—none of these are competent to produce any skin disease unless they succeed in shifting the balance of equilibrium between the several parts which make up the epiderm and the metaderm."

The improvement which one observes on a salt-low diet, and which is also so evident on a fat-low diet is apparently due to the fact that the great majority of cases so treated are put under the best hygienic conditions (usually hospital care) and are therefore placed under those circumstances which tend to restore that equilibrium which Roberts mentions.

So their condition improves and they leave the hospital or the care of their physician and return to their old surroundings. In a few weeks or months they return with their former symptoms, perhaps just as bad as they ever were.

It may be true that the exudative diathesis is due to a dietetic or metabolic disturbance, but our clinical experience and our survey of the subject have not been sufficient to convince us of this.

In our opinion, then, the exudative diathesis may be explained as follows:

There are certain individuals and certain families who have skins and mucous membranes in whom the ordinary conditions and surroundings of life are sufficient to disturb the delicate balance of equilibrium, this equilibrium being probably dependent upon capillary permeability, *i.e.*, these cases react abnormally and repeatedly to all sorts of trauma because the capillaries in the skin and mucous membranes are congenitally irritable and therefore permeable.

We desire to thank Dr. Veeder and Dr. Jeans, of the Pediatric Department, for the use of some of their material.

REFERENCES.

[1] SHAFFER AND MARRIOTT. Determination of Oxybutyric Acid.

[2] MARRIOTT. Nephelometric Determination of Acetone. *Journ. Biolog. Chem.*, Nov., 1913, xvi, No. 2; Blood in Acidosis, Aug., 1914, xviii, No. 3.

[3] ROBERTS, LESLIE. On the Non-parasitic Cutaneous Reactions. *Brit. Med. Jour.*, 1904, ii, p. 996. (For a complete understanding of the words "surface tension of the skin and capillaries," the reader is referred to this paper.)

(*Concluded*)

THE IMPORTANCE OF VISCERAL SYMPTOMS IN DERMATOSES OF THE EXUDATIVE ERYTHEMA TYPE.*

By Burnside Foster, M.D., St. Paul.

While the association of the various skin lesions of the exudative erythema type with visceral symptoms was first, so far as I have been able to ascertain, remarked upon by a dermatologist (Willan) in the early part of the 19th century, the modern text books on dermatology pay but slight attention to the subject. While it is probably true that these cases are usually first seen by the internist or the surgeon, on account of the symptoms which relate to the internal organs, it is of great importance for the dermatologist to be able to correctly interpret cases of this type; and I am quite sure, from my own experience, that if we go carefully into the history of our cases, especially of urticaria and purpura, we will find that visceral symptoms, more or less severe, have at some time been present in a much larger proportion of them than is generally known. The dermatoses which are at times complicated by visceral symptoms, are the various forms of erythema, particularly erythema mutiforme and erythema nodosum, urticaria and angioneurotic œdema, purpura and, more rarely, pemphigus. Osler has gone into this subject more thoroughly than any other writer, and my attention was first called to it by one of his earlier writings, more than 20 years ago. Since that time I have been on the lookout for these cases and have made quite a large number of personal observations concerning them.

The visceral lesions are quite various and are either due to exudation on mucous membranes, as of the stomach or intestines, of a similar nature to the exudations on the skin, or they may be inflammatory and perhaps embolic in character and produce inflammation of the endocardium, the pericardium, the pleura, the peritoneum, the lining membranes of the joints or the membranes of the brain. Hemorrhage into the brain has been described by a number of observers of these cases. The intestinal lesions are of especial importance to the surgeon because in these days, when appendicitis is writ large upon the diagnosis chart of every case of recurrent, right sided belly-ache, it is well to remember

* Read before the 40th Annual Meeting of the American Dermatological Association, Washington, D. C., May 13 to 15, 1916.

that if a purpuric or urticarial eruption is present, or has been noticed at some previous attack, the appendix may not be the offender, and an operation for its removal may be a very serious matter. I have personally seen two cases in which the presence of purpuric spots and a history of frequently occurring urticaria, associated with abdominal pains, enabled me to persuade the surgeons who were about to operate to make further study of the cases, with the result that the operations were avoided. Doubtless many an innocent appendix has been removed on account of similar symptoms. A unique case is described by Jacobson (*Medical Record,* Feb. 7, 1903) in which a hæmorrhagic appendicitis was found to exist, and a few days after removal of the appendix, which was found to present numerous areas of hæmorrhage into its substance, there appeared a purpuric eruption on the legs and abdomen, together with abundant hæmorrhages from the nose and lungs. The patient recovered. Of course in this case the operation was justified by the findings. The intestinal symptoms in these cases are colicky pains, lasting but a few minutes at a time, and recurring several times daily, vomiting, perhaps blood stained, and the passage of blood in the stools. The fact that the pain is not localized, but rather radiating to various parts of the abdomen, that the abdomen is not apt to be very painful on pressure, and that fever is absent, should put the surgeon on his guard. The pain may be so severe that the patient will writhe in agony and a few minutes later it will be entirely gone.

An interesting case was a woman, 35 years of age, whom I saw, first, in 1899. She had had, for many years, recurrent urticaria, and her mother and one sister had had the same disease. When I saw her for the first time, her lips and cheeks were enormously swollen and there were numerous large wheals on her body, which were intensely irritable, and there were also a few purpuric spots on her legs and abdomen. She complained of excruciating pain in her abdomen, which was soft and not sensitive to pressure, and she had vomited several times and could retain no food. For three days the attacks of pain continued, coming on several times daily and lasting, perhaps, ten minutes. Between the pains she was comfortable. There was no blood in the vomitus or in the stools. The urticaria lasted for several weeks after the pains left her. During the next few years, I saw her in perhaps half a dozen similar attacks of urticaria, in each of which she had some abdominal distress, but none so severe as the first one. Since 1906, I have not seen or heard from her, as she has moved from Minnesota. An interesting feature of this case was the presence of large amounts of albumin in the urine during the attacks and for a few days following them, but none in the normal intervals.

Another very similar observation was in a travelling salesman, 28 years of age. Since boyhood he had suffered from recurring attacks of urticaria, several times a year. There was frequently, but not always, some abdominal pain during the attacks, which always began with vomiting. On several occasions

he had vomited blood and once had passed blood during an attack of diarrhœa. He had never had any purpuric spots on the body, the only skin lesions having been the urticaria, which had been often of the angioneurotic type. When I first saw him, there were enormous wheals on various parts of his body, particularly the arms and legs, which were much swollen. The lips were swollen and also the tongue, so that he articulated with difficulty. He complained bitterly of abdominal pains, particularly in the lower part of the belly, but there was no localized tenderness or swelling. Treatment seemed to be of no help to him, and for nearly two weeks his condition remained about the same. The pain then ceased quite abruptly, but the urticaria remained for another week and gradually disappeared. This was in September, 1900, and since that time I have seen him about twice a year in similar attacks, but none so severe. He has several times had severe abdominal pain, coming on suddenly and lasting for a few days without any manifestations on the skin. Osler mentions a number of instances in which the abdominal crises have been without skin symptoms.

A quite different type, but evidently belonging to this group of cases, was the following: F. G., 12 years of age. From infancy, she had been a bleeder and came of a family of bleeders. Nose bleeds, so severe that plugging had been demanded many times, had been of frequent occurrence. On one occasion, about a year before I saw her, she had bled profusely for many hours after pulling out a tooth. In March, 1906, she had a severe attack of articular rheumatism, affecting many joints, and was suffering from this when I first saw her on account of a quite general purpura, which affected the arms, legs, chest and abdomen. Coincident with the purpura was a profuse epistaxis and vomiting of blood and bloody diarrhœa. She also suffered from severe colicky pains, the urine was bloody and loaded with albumin. The hæmorrhages lasted for about a week and new crops of purpura came out nearly every day. The rheumatic fever lasted for about six weeks and finally disappeared, and the child has remained well ever since. The abdominal pain was so severe in this child that operation was seriously contemplated, but fortunately was postponed, and finally was seen not to be necessary.

In the *Boston Medical and Surgical Journal* of July 9th, 1914, Morrison reports three cases of the same types as those above outlined, and in summing them up, he states that he believes them to be infectious in origin and that the infection is that of rheumatism. It is true that many of these cases present joint symptoms and other manifestations which resemble true rheumatic arthritis, but in many of them there are no joint symptoms at all, and it seems to me more likely that we have to deal with a special, as yet unidentified form of infection which produces various symptoms in different individuals, and in which the symptoms vary in the same individual in different attacks. One of the most striking features of the disease is its tendency to recur at varying intervals, sometimes during the entire life of the individual.

It is not unlikely that the experimental work of Rosenow, so beautifully demonstrated to us at a recent meeting of this Association, might

throw some light on these cases. In Osler's most recent communication on this subject (*British Medical Journal,* March 7th, 1914) he comments on the variable character of the exudate in the lesions of the skin and mucous membranes, at one time serum alone, then blood and serum together and again blood alone, and expresses the view that the actual exudate is conditioned by the epithelial cells of the capillary wall, damaged by a circulating poison. He expresses the view that "Before long the anaphylactic key will unlock the mystery of these cases."

Numerous writers of recent years have discussed this subject, but they have usually been surgeons or internists, and I have seen very little concerning it in dermatological literature.

The fact that many of these cases are first seen by the dermatologist, and that a careful study of such cases would undoubtedly bring to light additional observations, is my excuse for presenting this brief paper before this Association.

SOCIETY TRANSACTIONS.

NEW YORK ACADEMY OF MEDICINE, SECTION ON DERMATOLOGY.

Regular Meeting May 2, 1916.

CHARLES M. WILLIAMS, M.D., *Chairman.*

LICHEN PLANUS ATROPHICUS. Presented by DR. ROBINSON.

Previously presented before the New York Dermatological Association.

DISCUSSION.

DR. MACKEE had seen the case before and remembered having seen lichen planus lesions (Wilson) at that time. On this presentation these formerly papular lesions of lichen planus had become flattened and atrophic. Dr. Robinson had made histologic studies which revealed a structure like that of scleroderma. The speaker mentioned a case presented by Fordyce, years ago, which histologically showed a sclerosis above and an infiltration below, in the corium. Even histologically it was difficult to tell the difference between lichen sclerosus and scleroderma.

PREMYCOTIC STAGE OF MYCOSIS FUNGOIDES(?). Presented by DR. LAPOWSKI.

The patient was a man, 56 years old. A year ago an erythematous patch had appeared on both buttocks. Six months later, patches appeared on the flexor surfaces of the forearms, which gradually had spread to the abdomen, thighs, neck and shoulders. These lesions were symmetrical, or of a slight hæmorrhagic character, œdematous, slightly infiltrated and sharply defined. On pressure the redness disappeared, leaving a dark brown stain. Untreated patches oozed slightly, became crusted and fissured.

DISCUSSION.

DR. POLLITZER considered the case presented by Dr. Kingsbury to be a typical example of mycosis fungoides in the erythematous stage. As to Dr. Lapowski's case, he saw nothing to warrant the diagnosis of mycosis fungoides. He regarded it as an eczema.

Drs. MacKee, Wise, Clark, Trimble, Oulmann and Rosen agreed with Dr. Pollitzer.

Dr. Lapowski gave a number of reasons for the supposition that his case did not represent a type of eczema, one of them being the extremely persistent patches which it presented. The fact that there was symmetry and oozing was not unfavorable to the diagnosis of premycosis. If this case had been eczema, even mild treatment should have improved the condition.

WHITE-SPOT DISEASE. Presented by Dr. Trimble.

Previously presented before the April meeting of the New York Dermatological Society.

DISCUSSION.

Dr. MacKee agreed with Dr. Trimble's tentative diagnosis of dermatitis factitia. The application of acid might have caused depigmentation without causing actual scarring.

CASE FOR DIAGNOSIS. Presented by Dr. Lapowski.

This case had been presented before the Section in February, 1908, with the diagnosis of Paget's disease; a diagnosis which had been disputed by many members who had considered it was gumma. The patient, K. L., 54 years old, gave no history of syphilitic infection. On Mar. 3, 1908, after two injections of calomel and the administration of potassium iodide, the lesions healed. The patient had not been seen for eight months prior to his reappearance at the clinic, Jan. 18, 1916, with the following lesions. On the left breast was seen a half dollar sized patch with a red border which was not infiltrated. The centre of the patch was occupied by a raised, slightly fluctuating bulla, the skin covering which was soft and thin. On opening the latter, the floor was found covered with a gelatinous adherent bloody mass. This could not be removed. Here and there hypertrophied granulations could be seen. The whole patch was sharply defined. At the site of the old lesions there were white, soft scars without pigmented borders. The Wassermann reaction was negative. The patient had received two calomel injections in January, 1916, and about 50 grams of potassium iodide three months ago. The lesions, under this treatment, did not disappear. Only after local applications of nitrate of silver did healing begin, leaving dried crusts.

DISCUSSION.

Dr. Trimble stated that he remembered the case and had made the diagnosis of syphilis. He favored the diagnosis of another outbreak of lues. Against Paget's disease was the fact that it was not near the nipple.

Dr. Pollitzer saw no signs of Paget's disease, either eight years ago or on presentation. He thought that the case was one of syphilis and that the lesion which Dr. Lapowski described as a necrotic gumma was actually one of that character. There were no points about the lesion to justify the diagnosis of Paget's disease, in his opinion.

Dr. Lapowski called attention to the fact that eight years ago, the patient had had a bulla, with a gelatinous mass underneath. He stated also, that nitrate of silver caused a partial disappearance of the lesion of Paget's disease, even though it were not permanent.

LEPRA. Presented by Dr. Rothwell.

The patient was a man, 35 years old, single, and born in Greece. At the age of 32 years he had gone to New Mexico, where he had worked in coal mines. The first indication of the trouble had been five months ago, when nodulation of the face and hands had appeared. On the face, neck, and upper and lower extremities were papules of various sizes, from a pin-head to nearly three fourths of an inch in diameter, soft, and the color of normal skin or darker. On the arms, hands, and legs were firm, hard nodules. Smears showed Hansen's bacillus.

TUBERCULOSIS CUTIS VERRUCOSA. Presented by Dr. Rothwell.

The patient was a colored girl, aged 18 years. The infection probably had begun inside the nose, and four years ago made its appearance in the form of a small papule, on the cutaneous surface. It had steadily progressed. The upper lip and side of the nose were infiltrated, verrucous and ulcerated in places. The picture was that of tuberculous verrucosa cutis.

PRIMARY EPITHELIOMA. Presented by Dr. Chargin.

The patient was a man, 55 years of age. For the past six years he had been troubled with what appeared to have been a simple ulcer at the site of the lesion presented. During the past six months the involved area had taken on greater activity and had produced the ulcer, which was situated upon the lateral aspects of the third and fourth toes of the right foot. The entire ulcer was indurated, the border rolled. The base showed uneven granulations with a scant discharge. He had been under observation about four weeks, during which time the extent of the ulcer had apparently not increased. The biopsy showed prickle celled epithelioma.

DISCUSSION.

Dr. Pollitzer said that besides the unusual localization of the disease, the question of treatment came up for discussion. The lesion might respond to X-ray or radium, but it did not seem to be accessible to these agents. The best therapy was either amputation, cauterization or curettage.

Dr. Trimble suggested palliative treatment, with amputation of two toes.

CICATRICES OF BODY AND SCALP FROM TUBERCULOSIS. Presented by Dr. Rothwell.

The patient was a man, 50 years of age, born in Russia. He was in apparently good health up to eleven years ago. The first lesion was noticed on the scalp. From the history given, it seemed that the lesions that later made their appearances were "cold abscesses," as the patient's body showed a great number of scars, varying in size, shape and depth. He had been in the Riverside Hospital for lung trouble, and also had been a patient in the Mount Sinai Hospital. On presentation, the only active lesions were on the scalp, consisting of two fungoid, granulating lesions about the size of hazel nuts, having the character of pyogenic granulomata.

PSORIASIS LICHENOIDES. Presented by Dr. Lapowski.

The patient was five years old. Six weeks ago he became affected with an eruption on the palms and soles, which spread gradually to the scalp, face,

trunk, buttocks, thighs, legs and forearms. On the palms and soles the skin was red, dry, scaly and covered with millet-sized, scaly papules. Other regions were covered with disseminated papules, some of which were psoriatic, some lichenoid in type, and arranged in groups or patches.

DISCUSSION.

DR. POLLITZER had seen several cases of this type, supposed to have followed scarlet fever. He did not think that the case presented could be called "lichenoid" psoriasis. The speaker considered the case to be one of plain psoriasis of a superficial type.

DR. KINGSBURY had had the case under observation ten days ago. Many cases of this type might be preceded by an erythematous eruption. The involvement of the palms was of interest.

LYMPHANGIOMA CIRCUMSCRIPTUM. Presented by DR. CLARK.

The patient was a girl, aged 10 years, whose mother first noticed the lesion on the child's neck in infancy. The lesion had persisted, having very gradually enlarged by the addition of outlying spots. Scattered over an area of the size of a silver dollar, were several pea sized, or smaller, vesicles, containing an opalescent, yellowish fluid. Some of the vesicles were hæmorrhagic and blood red. A radium exposure with 20 milligrams, on a flat applicator, filtered through 1/50 of a millimeter of platinum foil, had been made.

DISCUSSION.

DR. POLLITZER considered the case to be typical of the disease as diagnosed. The contents of the vesicles were lymph. As the vesicles were divided into compartments, it was easy to see that only little lymph could be expressed. He thought that radium would cure the case without difficulty.

ICHTHYOSIS HYSTRIX. Presented by DR. TRIMBLE.

Previously presented before the New York Dermatological Society.

DISCUSSION.

DR. MACKEE agreed with the diagnosis of ichthyosis hystrix. He saw no necessity of separating the disease from ichthyosis, and calling it a nævus. The same applied to the so-called hyperkeratotic nævi. All the cases might be placed under the head of ichthyosis.

DR. POLLITZER said he was opposed to the use of the term ichthyosis as applied to a circumscribed nævus, no matter what its shape or extent might be. In this case, he said there were features which militated against the diagnosis of ichthyosis and referred particularly to the pronounced character of the lesions in the flexures. He was inclined to group the case as belonging to ichthyosiform nævi, but for the fact that the trunk and back were affected by the diffuse scaling.

DR. TRIMBLE did not believe that either name, ichthyosis or nævus, should be used exclusively.

BOOK REVIEW

DISEASES OF THE SKIN AND THE ERUPTIVE FEVERS. By Jay Frank Schamberg, A.B., M.D., Professor of Dermatology and Infectious Eruptive Diseases in the Philadelphia Polyclinic and College for Graduates in Medicine; Dermatologist to the Philadelphia General Hospital, the Jewish Hospital, and Samaritan Hospital; Fellow of the College of Physicians of Philadelphia; Member of the American Dermatological Association. Fully Illustrated. Third Edition, Thoroughly Revised. Philadelphia and London: *W. B. Saunders Company.* 1915.

This very handy text book of 585 pages has been considerably amplified in its third edition and brought thoroughly up to modern standards and usages in the field of dermatology and the exanthemata. The first four hundred and twenty-four pages are devoted to skin diseases proper, and syphilis, with introductory chapters on anatomy, physiology and symptomatology, and closing chapters on actinotherapy, radiotherapy, opsonotherapy and refrigeration. In the discussion of syphilis, the latest serological discoveries are briefly but understandingly presented to the student. The descriptions of the various dermatoses are concise, yet at the same time sufficiently comprehensive for the third and fourth year medical students' purposes.

The reviewer looks forward to a fourth edition in which certain dermatoses will be given more space than is accorded them in the present book; among these may be mentioned granuloma annulare, the different forms of sarcoid, the cutaneous leukæmides, the erythrodermias exclusive of the parakeratoses, and a few others, which, of course, can be dealt with only very briefly in a treatise of this kind.

The half-tone cuts are almost without exception admirable examples of the art of photography in this field, nearly all of them being the result of Dr. Schamberg's own work.

The division dealing with the acute eruptive fevers gives to the work its great value as a guide to the student and practitioner of medicine. In reading over this section one is struck by the question why the average text book on dermatology does not devote a great many more pages than it does, to the exanthemata. The answer probably lies in the circumstance that few men in America are fortunate enough to be able to present the subject with the skill and erudition of Schamberg, whose knowledge of the subject is vast. Chapters on the mild type of small-pox and on Rocky Mountain fever are included in this division. The photographic reproductions, here also, are remarkable for their excellence and unquestionably are a great help to the reader in studying diagnosis.

The book is well bound, printed in large type and is worthy of the highest commendation as a comprehensive text book. F. W.

THE JOURNAL OF
CUTANEOUS DISEASES

Vol. XXXIV DECEMBER, 1916 No. 12

ORIGINAL COMMUNICATIONS.

KERATOSIS BLENNORRHAGICA: WITH REPORT OF A CASE.*

By Marcus Haase, M.D., Memphis.

This very interesting dermatosis associated with gonorrhœal arthritis was first described by Vidal[1] in 1893, and since that time about thirty cases have been reported; two in America, three from England and one from Australasia, and the others from the Continent.

To Simpson[2] is due the credit of reporting the first American case (1912) at which time he called attention to the fact that no mention of the disease was made in any American text book on dermatology.

The excuse offered for reporting this case is the opportunity afforded for observation of an acute exacerbation of the eruption.

Case Report.

History. F. R., age 28, has had four attacks of gonorrhœa; the first attack at the age of 16, second at 18, third, and most severe, at 22, which lasted eighteen months. During this attack he had epididymitis, which confined him to bed for three weeks. The last attack began on September 22d, 1914; one week later the left knee became enlarged and painful. Two weeks after the beginning of the arthritis he entered Bellevue Hospital, New York, and was transferred from there to the City Hospital on Blackwell's Island, where he remained one week; he left there and went to Camden, N. J., where he entered Cooper Hospital. While in the hospital on Blackwell's Island, an eruption appeared, described as "small blood spots, the size of a pinhead, situated about the navel." At the time he entered Cooper Hospital he had active gonorrhœa and arthritis in the left knee. While in the hospital the right knee and both ankles became swollen and painful; an eruption appeared on the left knee after

* Read before the 40th annual meeting of the American Dermatological Association, Washington, D. C., May 13 to 15, 1916.

Fig. 1.

Fig. 2.

Fig. 3.

it had been "baked" which looked like "water blisters" and was thought to be due to the baking. In a few days this eruption was covered with crusts; it later spread over the body, except the face. At this time the eruption covered the soles of the feet and all the lesions were capped with yellowish crusts. The discharge from the urethra ceased about one month after entering the hospital. While in the hospital, five or six of the toe-nails and three of the finger-nails were exfoliated; the joint pains gradually improved and the eruption disappeared, except from the soles. He left the hospital on January 11th, able to walk with the aid of crutches, which he continued to use until April 1st, at which time the crusts from the feet had exfoliated, and the joints, except the left knee, which was still stiff, were freely movable and painless.

He was comfortable and able to work from April, 1915, to the last week in August, when both knees became swollen and painful, and a few days later an eruption appeared about the genitals, which were red and scaly. He was at this time working in Pittsburgh, and left there and went to Hot Springs, Arkansas, where he remained about six weeks. While in Hot Springs the eruption became general. There the prostate gland was massaged and the discharge from the urethra reappeared. He denies any active gonorrhœa or any sexual intercourse since September, 1914. The condition grew worse while in Hot Springs; he came to Memphis and entered the City Hospital, under my care, on October 29th, with the following condition:

The patient is not markedly anæmic, although he says he has lost considerable weight since July. The right knee and both ankles are swollen and painful, and there is a generalized eruption over the body. The entire scalp is covered with a thick yellowish crust, matted in the hair, in places three-eighths of an inch thick. On the face, in the axillae and about the genitals and anus, there is an erythemato-squamous condition, deep red in color and covered with thick, greasy scales; not unlike an exaggerated seborrhœic dermatitis. Over the chest (Figs. 1 and 2) and buttock (Fig. 3) are circinate lesions, pink in the centre, and the border composed of closely aggregated small red papules, covered with soft yellow crusts. Over the abdomen there are large flat lesions, many of which have coalesced about the umbilicus. The individual lesions vary in size, and all have a thick crust, surmounting a deep red base. On the legs (Fig. 4) and forearms are round, yellow, translucent, horny lesions, with little or no inflammatory border, varying in size from a small pea to one and one-half inches in diameter. The smaller ones are conical in shape; the others, which

Fig. 4.

are more numerous, have a depression in the centre, while a few have a flat raised ring at the outer border within which is a depressed ring, and finally a sharply defined central elevation.

The forcible removal of these cup-shaped crusts reveal soft, succulent, velvety protuberances, some of which are pointed, while the larger ones have a depression in the centre, and in this depression is a foul smelling, putty-like substance. The soles of the feet (Fig. 5) have lesions of various size, the smallest is about the size of a pea, the largest a slightly elevated, plate-like thickening of the epidermis of brownish-yellow color. If the crust from any lesions was removed it would form again in a few days, but if allowed to remain, would fall off, leaving a smooth pink surface. While unable to walk or even stand because of the joint pains and lesions on the feet, he was fairly comfortable when at rest.

An examination of his blood, at this time, showed little or no abnormality; the urine was negative, except for the presence of a small quantity of pus. The discharge from the urethra had ceased before he entered the hospital, but the massaged prostate revealed a number of intra- and extracellular, gram-negative diplococci.

For a period of over two months after entering the hospital, except for an extension of the lesions on the abdomen and chest, no new lesions appeared.

Fig. 5.

Fig. 6.

Fig. 7.

Fig. 8.

Those on the abdomen (Fig. 2) extended at the periphery and assumed the circinate character of those on the buttock and chest. All other lesions, except those on the feet, very slowly cleared up; the crusts exfoliated, leaving a smooth pigmented surface; the pigmentation being most marked on the legs.

On January 5th, he complained of increased pain in the affected joints, and in his left elbow, which had heretofore been free from pain. A slight rise in temperature was noted on the evening of this day; it had been slightly subnormal previous to this time. Gradually, other joints became involved and by February 1st, he was absolutely helpless; unable to move any of the extremities or raise his head from the pillow. The pain became so severe that it was necessary to keep him constantly under an opiate.

On January 11th, a small, soft papule was noted on the forearm; five days later other lesions appeared, most marked on the forearm and chest; they began as very small, pinhead size, bright red, soft papules, with no inflammatory areola. They gradually increased in size and were covered with a thick, waxy-yellow, adherent crust, resembling at this time little drops of beeswax; vesicles appeared on the apex of a few of these lesions before the crusts formed.

On January 15th, a flat, flaccid bulla, about the size of a finger-nail, appeared on the left knee, and a few days later, similar lesions appeared on both knees and elbows. These lesions increased rapidly in size and in crust formation, the crusts being dirty grayish in color and not unlike oyster shells (Fig. 6). The scalp and face became involved; on the latter an erythemato-squamous condition appeared, the scales being soft and greasy, except on the forehead, where small, horny protuberances formed (Fig. 7). Those on the former began as scaly papules, which enlarged to the size of a chestnut. The nails, both on fingers and toes, were raised from their bed by thick, waxy-yellowish masses, and flat superficial pustules formed at the base of some; the nails subsequently exfoliating. The shape and contour of the toes became entirely obliterated and they looked like masses of dirty yellow crusts. On the outer border of the feet various sized horns formed. On the soles there was an extension of the condition, remaining from the former exacerbation (Fig. 8), and on the right heel numerous new lesions appeared, which coalesced to form a large, thick, yellow crust, covering the entire heel. The entire palmar surface of the right

hand was covered with a thick horny plate, and in the left palm a conical lesion formed, an inch in height and a similar smaller one, grew on the outer border of the little finger.

At this time his condition was most lamentable. The temperature ran a course of low grade sepsis, the pain was intense, his mental condition exceedingly poor, and during the week of March 5th, he was frequently disorientated.

While at the present time he is still confined to bed and unable to feed or care for himself, and requiring opiates to relieve pain, he is slowly improving and the lesions are gradually disappearing.

Pathology. Three biopsies were made for histological examination. One, a quite new lesion, showed a thick, friable, horny, layer, the cells of which still retain flattened nuclei; between the cells numerous leucocytes are seen; the epithelial plugs are very much elongated; there is an absence of keratohyaline granules and no eleidin globules can be demonstrated except about the hair follicles and mouth of the sweat ducts. The prickles are still intact, although there is a marked inter- and intracellular œdema with leucocytic infiltration (Figs. 9 and 10).

The epidermis above the papillæ is thinned to two or three rows of cells and in some instances is entirely absent. The papillæ are decidedly œdematous, the capillaries are distended and there is a slight infiltration of leucocytes. In the subpapillary layer there is a localized infiltration, composed of leucocytes and lymphoid cells with few plasma cells. This infiltration is also marked about the blood vessels, which are distended.

The pathology of the second and older lesion differed from that of the first in that it contained many variously sized microscopical vesicles, within the prickle cell layer. A large vesicle (Fig. 11) was covered by two or three rows of œdematous cells; the cellular content being made up of a number of leucocytes, some epithelial nuclei and few cells which had lost their prickles.

The section from the third biopsy, which was taken from an old lesion, the horny cap previously having been forcibly removed, showed a dense hypertrophy of the epidermis with œdema and an infiltration of leucocytes. The papillary layer of the corium was almost entirely obliterated, and there was a diffuse infiltration in the subpapillary layer, composed of cells similar to those found in other sections, except for a relative increase in the number of plasma cells (Fig. 12).

Small pieces of tissue from skin lesions and epitrochlear glands, which were enlarged, were inoculated into various media; some of the same material was used to inoculate rabbits' testicles, skin and peritoneum; defibrinated blood was injected intravenously into rabbits. Blood cultures were made on various media. Smears and cultures were made from pustules and serum by cupping succulent lesions, all of which were negative.

Repeated examinations of sections from the skin and epitrochlear glands failed to reveal any organisms resembling gonococci. The or-

ganism was not demonstrated anywhere except in material expressed from the prostate gland. The complement fixation test for gonorrhœa was positive; the Wassermann test to exclude syphilis was made in three different laboratories and all of them were negative.

Arning and Meyer[3] and especially Sabotka[4] are of the opinion that a vesicle is the initial stage of all lesions; this cannot be confirmed after a careful observation of this case, during an acute exacerbation.

Chauffard and Feissinger[5] made experiments in an endeavor to produce cutaneous lesions; they claim to have succeeded by abrading the skin and inoculating on this prepared surface, serum obtained from beneath the crust of an old lesion. In the case here reported, any abrasion of the skin would determine the location of a new lesion; this was especially true during the height of the eruption; instances of which were demonstrated by the appearance of small, yellow, waxy-capped lesions appearing on the chest, following minute burns from cigarette sparks, and along the upper arm, after hypodermic injections.

The pathological findings in this case and a careful analysis of those of Chauffard,[5] Bearman,[6] Sequeira,[7] Simpson,[2] Arning and Meyer,[3] and Sabotka,[4] who have studied the condition histologically, show no very marked differences, but all apparently agree that the condition is not a true keratosis, but a parakeratosis.

References.

[1] Vidal. *Ann. d. dermat. et d. syph.* 1893, p. 3.
[2] Simpson. *Jour. Amer. Med. Assn.*, Aug. 24, 1912, p. 607.
[3] Arning and Meyer. *Arch. f. Dermat. u. Syph.*, cviii, 1911, p. 3.
[4] Sabotka. *Dermat. Wchnschr.*, Feb. 15, 1913, p. 181; and Feb. 22, 1913, p. 218.
[5] Chauffard and Feissinger. *Bull d. l. soc. fr. d. dermat. et d. syph.*, May, 1909, p. 162.
[6] Bearman. *Arch. f. Dermat. u. Syph.*, 1904, lxix, p. 363.
[7] Sequeira. Proc. Royal Soc. Med., London, iii, Part 1, p. 77.

Discussion.

Dr. Corlett said he would like to know if the centre of the lesions in this case had been denuded. The speaker said the reason he asked this was because this interesting case suggested to him some sixteen cases of a moist, pie-crust eruption, which he had seen, of pemphigus foliaceus. The photographs bore a slight resemblance to these cases. The speaker stated he had seen the sixteen cases mentioned, in Cleveland. The cases he spoke of, with the exception of two, had been fatal, and he wondered if the disease in Dr. Haase's case might not be of the same nature.

Dr. Zeisler said that the case presented by Dr. Haase was certainly extraordinary on account of the extensive area involved. Keratodermia blennorrhagica was by no means common, and in the speaker's fairly long experience,

in seeing and handling skin diseases, he had seen only one single unmistakable case of keratodermia blennorrhagica, in which, however, only the palms and soles were affected. The chief interest in these cases was the pathogenesis, the modus operandi. We knew that gonorrhœal discharge was capable of producing proliferating conditions like condylomata accuminata, which were the direct result of the irritating action of the secretion. But the production of horny lesions, far away from the source of the discharge, was difficult to explain. It suggested the similarity to arsenical keratosis and the thought was but natural that some remedy used in the treatment of gonorrhœa might be responsible for it.

Dr. Wise asked that he might be permitted to call the attention of the last speaker to the fact that Hodara, of Constantinople, found the gonococci in the vesicles themselves, in a case which he reported several years ago, in the *Dermatologische Wochenschrift*.

Dr. Pollitzer said these cases were rarely seen, but they were probably more common than the reports would indicate. At the St. Georgi Hospital in Hamburg, where there was a large service for gonorrhœics, Dr. Arning could almost at any time demonstrate gonorrhœal dermatoses in his wards. The speaker was strongly inclined to agree with the pathogenesis as presented by Dr. Haase and thought that the dermatosis was toxic, notwithstanding the occasional presence of a gonococcus in some of the lesions. Dr. Haase had examined a large number of lesions and had failed to demonstrate the gonococcus. The speaker said that the evidence against direct gonococcal infection of the skin was pretty strong, and that these lesions were due to gonorrhœal infection elsewhere in the system, and it was extremely likely, he fancied, that the eruption was due to the absorption of some chemical products produced by the gonococcus. In other words, the speaker said, he thought the eruption a toxic dermatosis of gonorrhœal origin.

Dr. Haase said he had very little to add. In answer to Dr. Corlett's question he would say that in this case the lesions had never been denuded, but were scaly or covered with a thick crust. Only when the crusts were forcibly removed, would there be any bleeding whatever. He had watched the lesions very closely during the acute exacerbation, and most careful observation had shown no vesicles at the beginning. Some lesions were capped with small vesicles after the eruption had existed for a short while.

The speaker said he did not think that keratosis was a good name, because this disease was not a true keratosis. If there could possibly be a typical histological manifestation of parakeratosis, aside from psoriasis, the speaker thought this disease would unquestionably go under that head. If he might be allowed the privilege he would suggest that parakeratosis, instead of keratosis blennorrhagica, be hereafter the title of this condition.

CALAMINE LINIMENT.

By William Allen Pusey, M.D., Chicago.

The usefulness of lotions containing inert powders in suspension, such as calamine lotion, is familiar to all dermatologists. These lotions when dabbed on the skin have a temporary cooling effect, partly due to the powders and partly to the abstraction of heat by the water in them. When applied in the form of wet dressings these same effects are increased. The objection to such lotions, and to most wet dressings in irritable dermatoses, is the drying effect which they produce. Largely for the purpose of overcoming this effect, liniments of similar composition have a limited use among dermatologists. The employment of liniments, however, in dermatology is not very extensive, chiefly for the reason that those which we use are rather inelegant and inefficient preparations. As a rule, water is added to them for its cooling effect, and when this is done, lime water is ordinarily used in order to get the benefit of the emulsifying action, which comes from the formation of calcium soap in such mixtures. The commonest liniment of this sort is a liniment made with calamine and oxide of zinc, each about 1 ounce, olive oil 4 ounces, and lime water to make a pint. This is a useful mixture, but it is a crude preparation and it has the disadvantage that the powder in it will not stay in suspension, but must be vigorously shaken up before application. Sometimes a dram or one-half a dram, of lanoline is added to this mixture to make it more creamy, but it still remains a poor mixture of water and fats.

In order to overcome the drying effect of a simple calamine lotion, several years ago I devised a liniment whose formula is practically that of the common calamine lotion with the addition of olive oil and enough tragacanth to make a permanent emulsion. The essential feature of this liniment is that by utilizing the emulsifying action of tragacanth a permanent emulsion is produced which maintains an even mixture of all the ingredients. The formula for this liniment is as follows:

Powdered tragacanth		ʒ 1
Phenol and glycerine, mixed,	aa.	m. 10
Zinc oxide and calamine,	aa.	℥ 1
Olive oil		℥ 4
Water, q. s.		O. 1
Oil of bergamot		gtt. 20-50

The few drops of phenol keep the liniment sweet indefinitely. The formula above gives a thick emulsion, about like very thick cream or a cod liver oil emulsion. If a thinner emulsion is desired an equally permanent one about the consistence of ordinary cream can be made by using ½ dram of tragacanth, instead of a dram, to the pint.

In order to get a satisfactory emulsion, a definite technique should be followed in its preparation. A wide mouth bottle should be used; one large enough to allow a free shaking of the quantity of emulsion to be made—for example: a quart bottle in making a pint of emulsion. The bottle should be clean and dry. The phenol and glycerine and oil of bergamot are first added to the olive oil. The entire quantity of oil is then put in the bottle, the bottle corked, and the oil shaken up in the bottle in order to be sure that the entire inner surface of the bottle and cork becomes covered with a film of oil. The tragacanth, which should be in a fine powder (I use Merck's powdered tragacanth) is then added little by little to the oil, and the mixture is thoroughly shaken until a yellowish opaque mixture is formed. If this is properly done, the tragacanth becomes evenly mixed through the oil. This is essential in order to get a good emulsion. Then about 4 ounces of water are added and the mixture vigorously shaken. This will produce a yellowish creamy emulsion. The calamine and zinc oxide are mixed dry, and then stirred up with the remaining 8 ounces of water in a separate container. The easiest way to do this is to take a wide mouth bottle, put in the zinc oxide, calamine and water, and shake it. This mixture of the powders and water is then added, an ounce or two at a time, until the quantity is brought up to a pint. After each addition of the suspension the emulsion is vigorously shaken.

Like all verbal descriptions of manipulations requiring several steps, the explanation of this technique makes it seem complicated. As a matter of fact, it is very simple; a pint of the mixture can readily be made in five minutes by one who is used to doing it. This technique is a common one used by pharmacists for making emulsions.

The product is a smooth, pink emulsion, which, if well made, remains permanent indefinitely, with practically no separation of the oil or powders. It makes an exceedingly presentable pinkish creamy preparation, and it is a very agreeable soothing oily application. An extensive use of this liniment for several years by me and a few of my colleagues has made us regard it highly. Indeed, it is on the insistence of some of my friends that I publish it. I have found it not only a good substitute for the old calamine lotion, but a liniment that may be substituted for ointments with convenience and good effect. It can be well used

in the form of wet dressings. When smeared on the surface it leaves a coat of powder like that from a calamine lotion, but one which is slightly oily. Like other liniments, it is more easily applied over a large surface than an ointment. On the other hand, it does not furnish as much protection as an ointment.

Most of the common dermatological remedies can be incorporated in it: resorcin, salicylic acid, sulphur, ichthyol, corrosive sublimate, etc. Alcohol, of course, cannot be added to any tragacanth mixture. Ichthyol may be added to it in any proportion. By the addition of a few drops of ichthyol, 10 to 30 or 40 to the pint, the mixture can be made the color of almost any skin. Precipitated sulphur mixes easily in the emulsion, and I have found this mixture an exceedingly agreeable one in dermatitis herpetiformis. A mixture which patients find very grateful for extensive itching dermatoses, such as generalized eczema, lichen simplex chronicus, and dermatitis herpetiformis, is:

Camphor-phenol	M. xx to xxx
Camphor-chloral	ʒ ss to ʒ i
Calamine liniment	O.i

THE RELATIONS OF DIETS TO SEBORRHŒA.

By Douglass W. Montgomery, M.D., San Francisco.

This article is intended to show how a class of foods may effect a very prevalent condition of the skin called seborrhœa.

Definition of Seborrhœa. Seborrhœa is a chronic morbid condition of the skin characterized by:

(1) An accentuation of the openings of the pilosebaceous follicles;

(2) A dirty grayish or tawny yellow discoloration, and often greasiness of the skin;

(3) A slight thickening of the integument.

The anatomical lesions of the status seborrhœicus are:

(1) A slight diffuse hypertrophy of the corneous layer;

(2) An alteration of an unknown nature in the amount of fat in the epithelium; and

(3) A hyperkeratosis of the pilosebaceous follicles.[1]

The skin is an enormous fat organ. It rests upon a thick fatty cushion; there are extensive fat deposits intermingled with the fibres of the true skin; there are innnumerable fat or sebaceous glands and sweat glands that also secrete fat, imbedded in the skin, and pouring out their secretions on its surface, and the epidermal horny covering is itself quite fatty. Clinically, in seborrhœa, it looks as if the entire fat of this large organ undergoes a change.

Normally the skin is covered with a smooth, beautifully translucent, yellow, horny layer, through which the subjacent red blood of the papillary layer shines, giving a soft pink color that we designate complexion. The cells composing this layer are renewed from below upwards. These cells are at first succulent and juicy, composing the quick. They later become condensed and horny, and finally, as they ascend, they loosen from one another until on the surface they are cast off as an imperceptible dandruff. A proper cornification of the epithelial cells, a function intimately associated with fat metabolism, is essential if these cell changes are to be carried out properly. In seborrhœa the skin is thick and heavy looking. The cornification processes are interfered with, so that the skin becomes dull in tint instead of rosy, and because the upper layers do not fluff off normally, the cutaneous surface becomes rough and fatty. The functions of the fat glands are also interfered with. Their orifices become enlarged, and the glands either pour out an abundant liquid fat that makes the surface of the skin oily, or they secrete an abnormally solid fat that rests in the gland orifices as

comedones. The function of the sweat glands is also altered. They either do not secrete enough sweat, rendering the skin dry, or they pour out, either locally or generally, too much sweat, causing local or general hyperidrosis. The hair, and frequently the nails, suffer with the other structures of the horny envelope of the skin, of which they are modifications. The lighter grades of these changes in the skin are so frequently met with in the white races, and in civilized life, that by some they are looked upon as being normal. Instead of designating the condition seborrhœa, which in its literal sense means an unusual flow of glandular fat, Darier proposes to call it kerosis, which would be the better term, as the changes in the horny layer of the skin are always existent, while, as has been before mentioned, an excess of fluid fat, secreted by the fat and sweat glands, is not by any means always present. On the contrary, the skin may be abnormally dry and harsh, and the fat of the sebaceous glands may be abnormally hard and dry. However that may be, the name kerosis has not yet made a way for itself, and the name seborrhœa is generally accepted.

Relationship Between Food and the Skin. Where any organ is preponderatingly engaged in the storage or secretion of any class of foods, it is natural to suspect that abuses in the intake of those foods may account for some of the aberrations of that organ. As we have seen, the skin is eminently a fat organ, and therefore a consideration of the fat-producing foods might readily furnish an explanation of some of its diseased conditions, and particularly of seborrhœa, in which, as we have seen, the cutaneous fat is especially affected. The fat-producing foods are:

(1) Fats, of which there are a great number, and

(2) Starches, of which there are also a great number, and in which are also included the sugars, which are soluble starches.

These foods constitute the carbon, hydrogen, oxygen, the CHO foods, or the ternary or three-element foods, in contradistinction to the carbon, hydrogen, oxygen, nitrogen foods, or the quaternary or four-element, CHON, foods. They are, therefore:

The CHO starches;

The CHO sugars; and

The CHO fats.

Clinically, therefore, the sugars, the starches and the fats are closely connected, and their relative rate of diffusibility, their rate of absorption from the alimentary canal and also their relative susceptibility to fermentation, are all of great importance in the questions now under

consideration. These propositions will become clearer as the individual members of the groups are taken up.

STARCHES. The solid, insoluble carbohydrate, starch, forms our main article of diet, and the machinery and chemical arrangements for comminuting it, liquefying it, and finally turning it into sugar, are most elaborate and time-consuming, so that it takes five hours or longer for a starch meal to be fully turned into dextrose and absorbed.[2] The physiological importance of this slowness in the conversion of starch into dextrose rests partly on the fact that in a slow chemical reaction, such as the conversion of starch into sugar, the reaction takes place in some particles, that are particularly favorably situated, much more quickly than in other particles that are less favorably situated. It, therefore, transpires that in a well-proportioned meal, dextrose, derived partly from sugar and partly from starch, is absorbed from a large extent of bowel, and is delivered to the liver in small manageable quantities throughout a considerable length of time.

All the starches are by no means alike, but we lack any chemical segregation of them. Even the molecular weight of the starch molecule is not known. It is, however, known, that it is some polymerization of the sugar molecule. It is also known from gross physical properties that the starch, for instance, of potato differs greatly from the starch of the cereals, and greatly to the advantage of the latter. I personally think that potato should be as carefully restricted as sugar in any case in which the patient seems to be suffering from an overabundance of easily convertible carbohydrate.

SUGARS. There are many sugars, each with its own rate of diffusibility. Of especial interest in this regard is lactose, as it is the sole sugar furnished the infant mammal. It is very slowly diffusible, and in the process of digestion is split into two sugars, glucose and galactose, each with a different rate of absorption. These properties secure a slow, enduring delivery of sugar to the liver during a reasonable time between feedings, and prevent an overcrowding immediately after a meal, which would be followed by an equally sudden penury.

Lactose has yet another property, which is likely of importance here. Sugars are antiputrefactive, and the best of them in this respect is lactose, then follow glycose, mannit, and finally galactose.[3]

Therefore Nature, confronted with the necessity of furnishing the infant a sugar instead of a starch, because a starch cannot be delivered from the mammary gland, gives one as slowly diffusible and as antiputrefactive as possible, showing how much weight, in this particular instance, she lays both on slowness of absorption and on antisepsis.

The fruit sugars constitute another group of carbohydrates, partaken of in the natural state, together with the cellulose, the fruit acids and the mucus of the fruit. These are usually well borne, especially when eaten with starch, to which they lend a most attractive flavor. Individuals are variously sensitive to them, however, and they are the occasion of many an interesting idiosyncrasy, frequently accompanied by a cutaneous manifestation, some of which may be ascribed to the products of fermentation of the fruit in the alimentary canal and others to the direct effects of the fructoses and the fruit acids. Some of the disagreeable phenomena observed following fruit may be anaphylactic, but from my experience they must be very rare. The fruit sugars are frequently powerfully sebeogogic.

Saccharose. The principal members of this group are beet sugar and cane sugar. They are both highly artificial products, as in the effort to get a marketable article of beautiful appearance all the mucus, cellulose, non-crystallizable sugars and pigments are carefully separated from the one crystallizable white sugar. They are disaccharids, very soluble, and are quickly absorbed after hydrolytic change in the gut, and being so nearly homogeneous, they tend to be absorbed in a limited time, in a limited section of the intestinal tube.

As having a direct bearing on this question, London and Polowzowa have carried out some interesting experiments on the relative absorbability of saccharose and glucose. According to these observers, saccharose was entirely resorbed before the contents of the bowel reached the cæcum, whereas under the same circumstances, more than 21% of glucose reached the cæcum before being resorbed.[4] This result is quite contrary to what I would have expected. All the starches and all the sugars have, in the process of digestion, to be turned into glucose, and one, therefore, would naturally suppose that glucose would be more easily transferred from the alimentary tract to the blood than any other sugar. That saccharose is more easily transferred quite accords, however, with its highly sebeogogic character.

There is yet another important circumstance in the absorption of sugar. Sugar, like water, when prevented from entering the circulation by way of the portal vein and the liver, goes by way of the lymphatic and the thoracic duct.[5] This short-circuited sugar is probably not so elaborately digested as that that goes through the liver, and might readily be much more irritating and sebeogogic. In this respect it is interesting that many patients having seborrhœic eczema have a more or less demonstrable enlargement of the liver, possibly due to fatty in-

filtration or to an excess of stored glycogen, that might form an obstruction to the passage of glucose through the liver and so force the abovementioned short circuiting.

Saccharose is also sebeogogic because of inducing sluggishness of the alimentary tract. Cane sugar, for instance, when present in large quantities in the intestinal canal, may delay the discharge of the stomach contents. This is due to the fact that sugar, with its tendency to retain water for its own solution, delays or prolongs the absorption of other substances from the bowels.[6] The strongly sebeogogic action of sugar is, therefore, to be accounted for by its rapid rate of absorption, its constipating effect, favoring intestinal fermentation, and its tendency, shared with the other sugars, to enter the circulation by way of the thoracic duct when the liver is blocked and so to miss the more perfect elaboration of hepatic digestion.

Fats. The fats of our food and of our body are chiefly triglycerides containing palmitic acid with sixteen carbon atoms, and stearic and oleic acid having each eighteen. In certain fats there are small quantities of other acids; for instance, butter, which possibly contains butyric acid, with only three carbon atoms, and capron, capril, and caprinic acid with five, seven and nine carbon atoms respectively. All these fats have different melting points and different rates of absorption.

When the fat of an animal is ingested in its natural combination with meat, it is enclosed in a membrane, which has first to be digested off in order to set the fat free. Fat is slow to leave the stomach and after entering the intestine has to be emulsified. All these processes take time, and this delay, as in the case of starches, tends to secure an even prolonged delivery of the fat to the chyle duct and thence to the blood.

Milk. Milk is practically a fat emulsion, and the richer it is in fat the more it is prized as an article of pleasure and luxury. As the fat globules have no surrounding membrane and as they exist in a state of very fine division, two important digestive processes are shortened and the fat is delivered very speedily to the blood. Cream, as being more concentratedly fatty, is worse than milk in this respect.

Butter is a peculiarly attractive fat. It is solid at ordinary temperatures; it is pleasant to the eye and delightful to the taste. In our households it occupies a position so apart that the laity do not regard it either as a fat or as a component of milk. A man will take coffee with abundant cream and sugar, a cereal breakfast food made into a rich pudding by the addition of sugar and cream, fruit swimming in cream, hot rolls spread thickly with butter, and beefsteak with potatoes, over

which he pours lovingly the melted butter of the gravy. After such a meal he naturally feels "logy" and disinclined to stir, and therefore takes in very little oxygen to burn this easily absorbable fat and carbohydrate. That the blood is overloaded with fat after such a fatty meal is capable of physical demonstration. Under such circumstances what little oxidation does take place is done at the expense of the carbohydrate, and the fat is either fermented in the alimentary canal, giving rise to highly irritating acids, or it is absorbed and shunted into the skin repositories, such as the panniculus adiposus, or excreted through the cutaneous fat glands where it often forms, in badly ventilated situations, as in the groins, a greasy coating. That these superfluous fats are laid down in the fat depositories and excreted by the fat glands as the very fats ingested, has been abundantly proven by experiment. It, therefore, transpires that in eating an excess of milk fat, the sebaceous glands secrete fats that are peculiarly liable and peculiarly exposed to bacterial attack, instead of secreting, as they normally should, a fatty substance largely composed of cholesterol esters, which are peculiarly resistant to bacterial attack.

Ernest H. Sterling has drawn attention to the fact that the fatty secretion of the sebaceous glands in man and in the higher animals, consists almost entirely of cholesterol esters. These are so little liable to fermentation that they can even pass through the alimentary canal without change.[7] When, therefore, the easily fermentable milk fats enter the sebaceous glands they naturally render these people susceptible to acne, furuncle and carbuncle.

It is also not unlikely that the milk fats are all the more easily secreted by the sebaceous glands, because they originate in a gland, the mammary gland, that is a modified sebaceous gland. Although milk fat is a decided sebeogogue, it is not so powerful in this respect as sugar, and not nearly so powerful as that modification of sugar that is called ethyl alcohol.

Alcohol and the Products of Bacterial Fermentation. Ethyl alcohol is a vasodilator poison and a powerful sebeogogue. It, therefore, flushes the skin and makes it greasy. Furthermore, almost all the products of bacterial fermentation are vasodilator poisons,[8] and therefore it comes about that intestinal intoxication and its principal favoring circumstance, constipation, is frequently accompanied by cutaneous flushings and erythema, that in their turn, by bringing an undue quantity of nourishment to the skin, give rise to the phenomena of seborrhœa. It, therefore, naturally follows that an overloading of the alimentary

canal with easily fermentable fats, such as milk fats, both by inducing, through sluggishness, constipation, and also by their essential ease of fermentation, give rise to products of fermentation, that, like alcohol, flush the skin, and particularly the face, and also act as powerful sebeogogues.

As being derived directly from starch and sugar, alcohol, in so far as it is a food, probably acts like sugar, and in so far as it is very rapidly absorbed, probably acts like a very rapidly absorbable, rapidly diffusible sugar, and everything said in regard to these two qualities, in considering the sugars, likely applies to alcohol. Alcohol is rapidly absorbed even from the stomach,[9] which is not a readily absorbing organ.

This rapid diffusion and rapid absorbability of alcohol may be due to the smallness of its molecule. The molecule of alcohol weighs $24+6+16=46$, whereas that of glucose weighs $72+10+80=162$. It is needless to mention the fats in this connection, they weigh so much more. On the other hand, it must be said that, as far as alcohols are concerned, and according to the present doctrine, the heavier their molecular weight the more poisonous they are.[10]

Alcohol, probably, in still another way causes seborrhœa. As it is more readily oxidized than either fat or starch or sugar, it saves these from oxidation.[11] It would appear that in alcohol two of the hydrogens are very loosely hitched to the molecule, and an oxygen atom from the air, if the temperature is slightly elevated and platinum is present as a catalyser, may march in and pick them out.[12] The fat ingested is, therefore, not burnt, but shunted into the fat repositories and the starch and sugar are also turned into fat and also shunted. This increase of fat would tend to increase seborrhœa.

Alcohol may also exert its poisonous influence and directly lower the oxidizing power of the tissues and therefore increase the fat deposits and seborrhœa.

Oxypenury. Oxygen is the most important of the chemical elements. It constitutes one-half the ponderable earth with its enveloping atmosphere and it is absolutely essential to the maintenance of life. It is by much the most important food we consume. We can go for days without ordinary food, we can go for a less time without water, but half a minute without air causes distress. In order to get an abundant vivifying amount of oxygen down into the tissues, exercise and blood of good oxygen carrying quality are necessary. Through insufficient exercise and a consequent insufficient supply of oxygen all the great oxidizing activities of the body are slowed down. The conversion of fats

and carbohydrates into CO_2 gas and water is, therefore, diminished, and the output of CO_2 gas is lowered. In this way the accumulation of waste products, CO_2 gas, and a watery, soggy condition of the tissues and of the skin, results. Therefore anæmia, a paucity of hæmoglobin, the oxygen-carrying material in the blood, is an important factor in causing seborrhœa. It is because of this that the treatment of anæmia is often so important in the amelioration of seborrhœa.

THE FREQUENCY OF SEBORRHŒA. Mention has already been made of the frequency of seborrhœa. It so often happens that the abuse of the sebeogogic foods is very general. Milk fat, both as cream and as butter, is very attractive to a great number of people and the abuse of sugar and alcohol is very general. Besides this, there is the prevalence of intestinal intoxication and gastro-enteritis, and anæmia. It may be said that the modern civilized man always has a gastro-intestinal catarrh and from his sedentary habits and occupations he frequently suffers from a penury of oxygen. And because of his penury of oxygen he tends to select the easily split, easily fermentable carbohydrates and the easily absorbable fats, and these are the very foods that favor seborrhœa.

The phenomena of senility of the skin are also largely seborrhœic—the older the man grows, the greater the tendency to fatty change in all the tissues, the cutaneous structures included.

It is needless to insist on an appreciation of the importance of this fatty condition of the skin in the treatment of seborrhœa, the status seborrhœicus and the incident inflammatory conditions called seborrhœides, that constitute so many of the affections the skin specialist is called upon to manage.

REFERENCES.

[1] DARIER, J. Dermatologie, 1909, p. 182.
[2] HOWELL, WM. H. Physiology, 1913, p. 788.
[3] SIMNITAKE. *Zeitschr. f. phys. Chemie*, xxxix, s. iii. Quoted by COMBE, A. L., L'Autointox. intestinale. Second Edition, p. 388.
[4] THOMSEN, E. Ueber die Einwirkung des Zuckers auf die Verdauung, *Zeitschr. f. physiol. Chemie*, 1913, lxxxiv, p. 435. Editorial, *Jour. Amer. Med. Assn.*, Aug. 2, 1913, p. 351.
[5] ALBERTONI, PIETRO. Ueber das Verhalten u. Wirkung des Zuckers im Organismus, *Ergebn. d. Physiol.*, 1914, p. 442.
[6] ALBERTONI, PIETRO. *Loc. cit.*, p. 439.
[7] STERLING'S Physiology, 1912, p. 62.
[8] DARIER, J. All the bacterial toxines, with the exception of pyocyanin and mallein, act as vasodilators. Dermatologie, 1909, p. 9.
[9] HOWELL, W. H. Physiology, 1913, p. 771. Gottlieb and Meyer think alcohol goes through the cement substance between the stomach cells.
[10] VON BUNGE, G. Organische Chemie, 1913, p. 35.
[11] HOWELL, W. H. *Loc. cit.*, p. 900.
[12] VON BUNGE, G. *Loc. cit.*, p. 9.

A CASE OF DARIER'S DISEASE IN ITS EARLY STAGES.*

By Max Scheer, M.D., New York.

(From the Department of Dermatology and Syphilology, College of Physicians and Surgeons, Columbia University.)

The object of this paper is to record the findings in a case of Darier's disease of short duration. If the patient's statement is to be given full credence, the age of her eruption is probably shorter than any that I have been able to find recorded in the literature—namely, one month. It must be admitted, however, that the appearance of the eruption gave the impression of having been present for a longer period.

Case Report.

The patient, Mrs. E. E., visited the Vanderbilt Clinic on June 25, 1915. She was 41 years old, was born in Germany and had been in this country eight and one-half years. Her occupation was housework. She was twice married, eleven years ago and five years ago. Her first husband was killed in an explosion. She had had two miscarriages, one at two months, ten years ago, and one at four months, in December, 1914. There were no children. Her family history is negative. Her habits are good. Menstruation is irregular, but there are no other pelvic disturbances. She has had several attacks of bronchitis in the past few years; she has also occasional slight pain in the left breast and in the left hypochondrium, and complains of occasional flushing and cardiac palpitation. Her appetite has been good, though not excessive. She complains of dryness of the mouth, excessive thirst, and has frequency of urination. In addition, she has had severe itching in the pubic region and the vulva, which was most marked at night under the warmth of the bed clothes; the act of urination seemed to aggravate the itching. Sugar is said to have been found in the urine. This symptom complex, pointing to the existence of diabetes, has been present for the past two years. She sleeps poorly.

Present Condition. The patient is a stout and well-nourished woman. Physical examination of the lungs is negative. There is a soft systolic murmur at the apex, transmitted to the mid-axilla and best heard when the patient lies down. Otherwise the general physical examination is negative.

Skin. The patient first noticed the present eruption in the latter part of May, 1915. She describes the eruption which then appeared as small "warts," in the groins. These warty lesions formed patches on the thighs, each of which occupied an area about the size of a man's palm. Those in the cubital spaces were roughly oval in shape and about one by two inches in dimension. The warty lesions have not increased in size since first observed. There was no itching in the bends of the elbows, but there had been severe itching in the groins.

Examination. In the bends of both elbows, covering an area about two inches long by one inch broad, at the widest part, are numerous closely set, warty-

* Read before the Clinical Society of the Department of Dermatology, Vanderbilt Clinic, April 20, 1916.

looking papules; a few are isolated, while the great majority are closely aggregated. They are pinhead sized and larger. They are elevated, beadlike in appearance, and are arranged parallel to the folds of the skin in the bend of the elbow. The color of the individual lesions is a faint yellowish-brown, but the affected area, as a whole, presents a grayish color with a faint violet tinge, like that of lichen planus. The papules are not angular and do not show the

Fig. 1.
Lesions in cubital space. Here there are numerous, linear lesions possessing a verrucous appearance.

Fig. 2.
Patch in femoral region, consisting of coalesced, shiny, flat-topped, polygonal papules, having a marked resemblance to lichen planus.

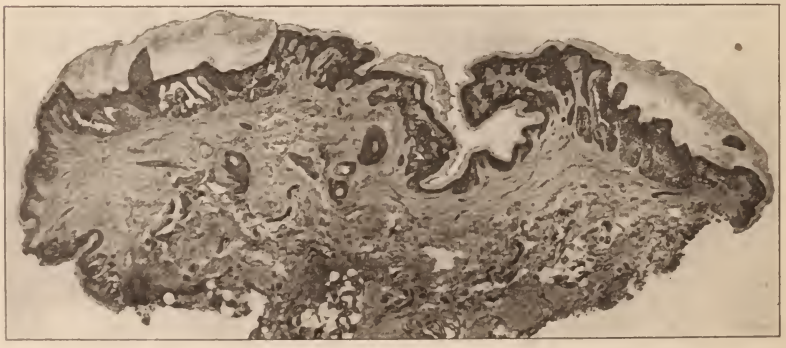

Fig. 3.
Zeiss-Planar 30 mm. Shows entire lesion. Hyperkeratosis, acanthosis and dyskeratosis

characteristic fine, adherent, white lines commonly seen in lichen planus. The lesions are more numerous and more elevated in the left cubital space than in the right. The patches resulting from the coalescence of these warty growths feel rough, like a nutmeg-grater, and are dry. In addition to this type of lesion the patches also present—especially when the skin is put under tension—a series of slightly raised linear excrescences, apparently composed of coalescing warty formations, and running transversely across the bend of the elbow. There has never been any moisture in them, and no unusual odor has ever manifested itself.

On the inner and upper aspect of each thigh, beginning at the genito-crural folds and extending from here downward for about two inches, is a roughly triangular-shaped area, showing lesions similar to those in the cubital spaces and running parallel to the folds of the skin in the groin. The lesions are more numerous in the left groin than in the right.

In the femoral regions the individual lesions are larger than those in the cubital spaces. They are in part isolated and in part confluent, and vary in size from a pinhead to a split pea; a few have an involuted centre which is slightly depressed. The color of the individual lesions is grayish; that of the patch is gray with a lilac tinge, strongly suggestive of lichen planus. They are warty in appearance, and in spite of their location are dry, nutmeg-grater like and present no secretion. Certain portions of the patch, especially at its periphery, present flattened, shiny, rhomboidal papules which are closely set and simulate areas of lichenification of the skin. The skin of and around the vulva is reddened (diabetic erythema) but there are no warty lesions elsewhere.

The rest of the cutaneous surface, including the scalp and nails, was entirely free of lesions.

When first seen, this picture did not suggest the diagnosis of Darier's disease. We seriously considered the possibility of lichen planus, multiple warts, and lichen chronicus circumscriptus. It was not until Prof. Fordyce examined the case that the likelihood of its being one of psorospermosis follicularis was suggested.

A biopsy was made from one of the lesions on the thigh. The tissue was fixed in alcohol, embedded in paraffin and stained in the usual fashion.

The sections showed the characteristic changes commonly found in Darier's disease. There was marked dyskeratosis of the epidermis and an enormous hyperkeratosis. The horny layer appeared as a thick solid plate, firmly adherent to the subjacent layer of the epidermis. While in the main the horny layer was completely keratinized, there were a few areas where the nuclei were retained (parakeratosis). There were no mitoses.

The granular layer for the most part was markedly increased in thickness and keratohyaline granules were found, even in the lowermost portions of the rete.

The stratum mucosum showed a decided hyperplasia as well as a destructive process which resulted in a loosening and separation of individual cells and the formation of cystic spaces and clefts, some of

which were free, while others were filled with detached cells and debris.

The basal layer in places had lost its contour and in some areas had entirely disappeared.

Nearly all the transitional stages leading to the formation of the peculiar bodies—"corps ronds"—which are characteristic of the affection, could be made out. A cell would lose its prickles, become swollen, the nucleus would shrink or become fragmented and the remaining cell body appear as a hyaline mass with a condensed, double contoured, refracticle margin or border. The bodies were found both in the rete and in the horny layer. While there was considerable œdema and tearing apart of the cells, the increased thickness of the Malpighian layer was due mainly to hyperplasia. There were no mitoses.

The rete pegs presented a great irregularity in shape; some were elongated, dipping deep down into the corium, others were short and blunt. In some areas they coalesced, presenting a wavy line.

In the pars papillaris of the corium there was some dilatation of the superficial blood vessels, the endothelium was rather prominent and there was a slight infiltration of lymphocytes. There was considerable œdema of the papillary body, the individual bundles of connective tissue being widely separated and to some extent degenerated and granular.

The elastic fibres, while not reduced in quantity, showed a fragmentation.

Only one follicle was seen and this was normal.

The lumina of the coil glands appeared to be choked with cells, some of which were detached and showed fatty degeneration. No sebaceous glands were encountered. The subcutaneous fat was normal.

In spite of the presumably short existence of the disease here described, it is of interest to note that the pathological changes are practically identical with those so frequently described in cases of long standing. Presumably, therefore, the disease begins with the characteristic changes peculiar to keratosis follicularis from its early stages or from its very incipiency.

Treatment. Ths patient was referred to the X-ray department for treatment. She received one unit of X-ray in four divided doses, with the result that a marked flattening of the patches in the cubital spaces became evident after an interval of three weeks. Up to date the patches on the thighs have not received treatment.

I am indebted to Prof. Fordyce for his kindness in permitting me the privilege of reporting this case and for the use of the laboratory. For the photographs and microphotographs I extend my thanks to Dr. MacKee.

SOCIETY TRANSACTIONS.

MANHATTAN DERMATOLOGICAL SOCIETY.

Regular Meeting, April 14th, 1916.

GEORGE M. MACKEE, M.D., *Chairman.*

CASE FOR DIAGNOSIS. Presented by DRS. MACKEE AND WISE.

The patient, a female adult, came from Dr. Fordyce's clinic, was married, and her history was negative, as regarded syphilitic disease. The history was also negative regarding the lesion for which she was being presented. She showed on her palate a tumor, raised about one-quarter inch, cone-shaped, with a large pinhead sized ulceration in the centre, which was slightly depressed and the base of the tumor sloping gradually off into the normal mucosa of the hard palate. The tumor had been of two years' duration and was hard to the touch. The result of the Wassermann test was not yet known on account of this being the patient's first visit to the clinic. The speaker said that the diagnosis rested between a benign periosteal or osteal growth of the palate, and lues.

DISCUSSION.

DR. SATENSTEIN said that he would like to suggest periosteal sarcoma in this case.

DR. WALLHAUSER said that the papule-like protrusion over the hard induration was probably caused by a minute sinus leading from the bone, and suggested the diagnosis of periostitis.

EPITHELIOMA OF THE TONGUE. Presented by DRS. MACKEE AND WISE.

The patient was a female adult, married, from Dr. Fordyce's clinic. She presented a lesion on the side of the tongue near the anterior fauces, which, she said, had had its beginning ten years previously, but which had become active and aggressive only within the last two years. It was indurated, sharply defined at the side of the tongue, about the size of a ten-cent piece, with raised, pearly edges. The patient had a distinctly sharp tooth opposite this lesion. The speaker said she was presented before the Society to show the rather unusual condition of epithelioma of the tongue in the female.

LUPUS ERYTHEMATOSUS. Presented by Drs. MacKee and Satenstein.

The patient was a male adult, who had been infected six months previously with syphilis and had gone to the Cornell Clinic for treatment. At that time the patient had a four plus Wassermann reaction. He was then sent to the City Hospital for treatment. There he received two injections of salvarsan and a number of injections of mercury, and the lesions responded to therapy, very slowly. He left the hospital in February, and on February 17th came to the Vanderbilt Clinic, where a Wassermann reaction, taken at that time, was found to be one plus. The eruption which, when shown, was present on his face, had come on about four months previously. The eruption on the extremities came on at about the same time. Since he had been first seen at the Vanderbilt Clinic he had received eight salvarsan injections and about twenty-five to thirty mercury injections, but clinically the lesions did not change. The lesions of the face became broader and more extensive. In spite of the fact that there was a positive Wassermann and a straightforward history of syphilis, a biopsy was made in order to find out why the lesions did not clear up. The speaker said the tissue changes of lupus erythematosus had been found. In examining the patient very carefully on the afternoon previous to his presentation, he showed similar lesions on the forearm, with minute atrophy. A slide was presented which showed the microscopical picture.

DISCUSSION.

Dr. MacKee said he thought the case deserved a little study. The lesion on the forehead was of a dull-red color, slightly infiltrated, slightly œdematous, and it had been present for several months, without any clinical alteration. The lesions on the arm, at a distance, possessed the general appearance of psoriasis, but on close inspection they were seen to be composed of confluent follicular papules. There were one or two very early lesions present, where the minute clinical features were not marked by a diffuse scaliness. In the young lesions the scaliness was limited to the follicular orifices, and the lesions consisted of a group of inflamed follicles containing horny plugs and a perifollicular erythema. The histology was not that of psoriasis nor eczema. It was more suggestive of lupus erythematosus than seborrhœa.

FIBROMA CUTIS? Presented by Dr. Weiss.

The patient was a female adult, who showed a rather rare skin lesion. For the past three years she had had very small tumor infiltrations in the skin of the back, arms, chest and face, of split-pea size. They were elastic to the touch and compressible. A number of the lesions, especially those sunk or infiltrated into the skin, were wrinkled on the surface. The speaker presented the case as one of non-pedunculated fibromata cutis.

DISCUSSION.

Dr. Mount said he thought this case one of macular atrophy.

Dr. Parounagian said that the lesions in this case corresponded to a case he had presented before the Academy of Medicine, one or two years previously. His patient, however, had no lesions on the upper extremities; they were mostly over the sternum and back. The newer and more recent lesions began like those of lupus erythematosus, which became atrophic and whitish. The case had been seen by Dr. Bulkley, at which time a diagnosis was made of myoma, but the lesion had been presented as one of macular atrophy.

Dr. MacKee suggested the early stage of macular atrophy. The case resembled one presented by Gottheil several years ago, where the large papules showed, under the microscope, only a swelling of the collagen with dilated vessels and lymph spaces. There was no infiltration. The papules later disappeared, leaving atrophic, depigmented macules.

Dr. Weiss said that these lesions had impressed him as small, compressible nodules, some a little above and others in the skin, showing fibromatous growth. In reference to the diagnosis of atrophy, he would have to wait, he said, until the condition came to that stage, before he would change his diagnosis.

PARAKERATOSIS VARIEGATA. Presented by Dr. Wallhauser.

The patient was a female adult, and was presented as a case of parakeratosis variegata, as described by Unna, Santi and Pollitzer.

The eruption had been present about five years and had remained practically unchanged. It was composed of a purplish-red, slightly elevated eruption, presenting a mottled or retiform configuration on the upper extremities, while on the lower extremities it appeared in numerous wavy lines. It was distinctly lichenoid in character, the peculiar figures and wavy lines being developed by coalescence of flattened, shiny papules, which were also distributed between the figures.

DISCUSSION.

Dr. Howard Fox said the patient looked like one of his, in which the diagnosis of angioma serpiginosum had eventually been made. The case in question had been reported by Dr. Wise in his article upon that subject. Dr. Fox did not think that the case corresponded to any type of parapsoriasis.

Dr. Wise said that the skin of the arms in this case to a great extent resembled angioma serpiginosum, with the one exception that in the condition presented by this case one did not see the pin-point sized lesions found in angioma serpiginosum. The blood vessels were also smaller and had a tendency to form rings about one-eighth inch in diameter, not seen in this case. The speaker said he admitted there was a superficial resemblance to angioma serpiginosum, but the striate infiltrations on the lower extremities were never a feature of that disease. As regarded the diagnosis of Dr. Wallhauser, never having seen a case of true parakeratosis variegata, the speaker said he was unable to verify his diagnosis, but from what he had read of Pollitzer's description, there were no such angiomatous and deeply infiltrated lesions present in that dermatosis.

Dr. Wise expressed the opinion that the case presented lesions which, to his mind, were unique, and hoped that a biopsy would be obtained.

Dr. MacKee agreed with Dr. Fox that very possibly the case could be included in the infective angioma group. Concerning the clinical infiltration, it should be remembered that Wise's case of angioma serpiginosum showed, histologically, a marked and diffuse infiltration. The speaker did not feel that the linear, infiltrated lesions should definitely rule out infective angioma. They might be concomitants of the disease or they might be coincidental. There was some tendency toward the formation of circinate lesions and there was a furfuraceous scaling, as in Wise's case.

Dr. Wallhauser said, regarding the possible diagnosis of angioma serpiginosum, he felt it should be excluded on the ground that that condition presented a progressive eruption, while the case under consideration had remained practically unchanged during a period of five years.

Dr. Wise said, with reference to Dr. Wallhauser's question, that out of 27

cases of so-called angioma serpiginosum, practically every one had a different course, superficial appearance, symptomatology, etc. In only a few was there a true appearance of progression by means of peripheral extension.

PARAPSORIASIS IN PATCHES. Presented by Dr. Wallhauser.

The patient was a male, 25 years of age, presenting a mixed eruption of five years' duration. On the chest and back it consisted of variously-sized erythematous plaques, measuring from one to several inches; the color varied from a light to a deep purplish red; the surface was roughened and slightly scaly; on the upper and lower extremities, the eruption consisted of pea- to dime-sized, disseminated lesions, which were slightly raised and covered with silvery-white scales. There was a mild pruritus and a decided hyperæsthesia in the patchy areas.

The resemblance to the early stage of mycosis fungoides on the abdomen and back, and psoriasis on the extremities, was a marked feature.

MACULAR ATROPHY. Presented by Dr. Ochs.

The patient, a girl, had been shown previously, at which time the diagnosis of macular atrophy had not been accepted by the Society. She was again presented in conjunction with her brother, who showed a similar condition. The duration of the boy's lesions had been indefinite and nothing could be told about them. The girl showed an alopecia areata, to which he had called attention at the last presentation. She had been under treatment with the Kromayer light, and the lesions were extending and increasing in size, having been of four years' duration. The speaker said it seemed peculiar to have the same condition in brother and sister, and as there was an apparent crinkling of the skin, hs again presented it and maintained the diagnosis of atrophia cutis maculosa.

DISCUSSION.

Dr. Oulmann said, in regard to macular atrophy, he thought the condition showed simply atrophy of the pigment and not atrophy of the skin. Those cases usually started with a reddish, inflamed halo around a leukodermic spot. This halo either became pigmented afterwards or disappeared entirely. He said he had observed a number of these cases for years and years, in which lesions appeared, reached a certain size, and progressed no further.

MILIARY PAPULAR SYPHILIDE. Presented by Drs. Howard Fox and Ochs.

The patient, A. J., was a colored woman, 20 years of age, born in the West Indies, a domestic by occupation. The eruption had first appeared about three months ago, and had attained its maximum development in about two weeks. She presented a profuse papular eruption that was generalized and symmetrical. It was most profuse upon the neck, arms, shoulders, sacral region and upper portions of the thighs. Some of the lesions, especially upon the chest, simulated closely the papules of lichen planus. Other lesions were acuminate and scaly. There was a mild angina and a moderate enlargement of the posterior cervical glands. The Wassermann reaction, performed subsequently to the presentation of the patient, was strongly positive.

DISCUSSION.

Dr. Oulmann said he thought there was lichen planus present, beside syphilis

in this case. There were some scratch marks on the elbows, with longitudinal striæ, which led him to believe that the two diseases coexisted.

Dr. Weiss said he believed this case was one of lichen planus in a syphilitic individual.

Dr. Wise said he thought this a condition of syphilis without lichen planus.

Dr. Ochs said when he had first seen this case, about nine weeks previously, she came in with what was apparently a lichen planus of the body; there were no lesions on the face. The face and neck had been entirely clear. He did not see the patient again, until five or six weeks later, and still maintained the diagnosis of lichen planus. When the woman came in, on the day of presentation, the condition caused both Dr. Fox and the speaker to change their diagnosis. The speaker said they could not reconcile a condition like this with an absence of lichen planus lesions on the forearms and elsewhere, and lichen planus lesions on the face; and in examining her most carefully, they thought it was a papular syphiloderm.

LICHEN PLANUS SIMULATING PITYRIASIS ROSEA. Presented by Dr. Weiss.

The patient was a male adult, who, when the speaker saw him for the first time, exhibited all the signs of pityriasis rosea. When the case came a second time, he found that he presented papules around each pityriasic lesion, resembling Hebra's classical description of lichen planus in plaques, presenting the appearance of a brooch surrounded by little stones. Later on, the lichen planus papules came out in abundance.

LUPUS VULGARIS. Presented by Dr. Ochs.

The patient, E. J. S., was a male, 28 years of age, well developed and strongly built. On the entire right, as well as partly on the left side of the nose, was a sharply defined, reddened and scaly lesion with fairly sharp edges; at the right nasal orifice there was ulceration with scabbing. The lesion was not elevated, but highly erythematous, with a few apple-jelly nodules, especially along the lower margin of the lesion. There was a slightly inflammatory lesion on the inner canthus of the right eye. Just back of the right tonsil was a sharply punched-out ulceration. Repeated Wassermann tests had been negative. The duration of the disease on the nose had been five years, in the throat two years and at the canthus one week. The patient had had tuberculin treatment with no result. The case was presented as one of lupus vulgaris with ulceration.

NÆVUS UNILATERALIS. Presented by Drs. Howard Fox and Pisko.

The patient, G. D., was an Italian, 17 years of age. Upon the right supraclavicular region there was a group of pinhead sized, brownish, pigmented spots, that had been present for the past four years. The patient had come to the clinic on account of another disease of the skin.

LUPUS ERYTHEMATOSUS WITH PSORIASIS. Presented by Drs. Gottheil and Ochs.

The patient, Mrs. A. M., aged 43 years, had never been pregnant, and up to one year previously, had been free of any cutaneous lesions. At that time, a red spot appeared on the right cheek, which rapidly spread, extending over the nose and then to the other cheek, presenting a characteristic butterfly appear-

ance. Six months before, she noticed some scaly patches appearing on the left elbow and on the right knee. Upon examination there were found patches of well-marked, scaly psoriasis of the elbow and knee, also patches of psoriasis on the scalp. On the left ear were a few slightly scaly, small, reddened lesions.

DISCUSSION.

Dr. Parounagian said he thought the whole condition one of psoriasis.

Dr. Bechet said that the eruption on the ear was very suggestive of lupus erythematosus. The lesions on the nose and cheeks were more characteristic of psoriasis than lupus erythematosus. It would require further observation to definitely determine whether the whole process was due to either or both of the diseases.

Dr. Ochs said that, as regarded the lesions on the ear, they exhibited a similar character to those on the face, and that both the face and the ear lesions were lupus erythematosus, while those on the knees and elbows were psoriatic, in his opinion.

ERYTHEMA IRIS AND MULTIFORME. Presented by Drs. MacKee and Wise.

The patient, a child, 5 years of age, from Dr. Fordyce's clinic, was presented as an unusually persistent erythema multiforme and iris. The erythema multiforme began about seven months previously, and since that time there had been no period in which the skin was entirely free of lesions, but there were a number of spots which had persisted for three or four weeks, but no longer. Individual spots had disappeared, but the patient had had erythema multiforme without cessation during the last seven months. The lesions were of a violaceous color, due to the subcutaneous hæmorrhages which took place in them. There were slight vesicular and bullous lesions on the lips. The ætiology was obscure.

DISCUSSION.

Dr. Ochs said he wanted to call attention to a case of erythema multiforme in a child, whose condition started shortly after the use of vaccine. He had intended to present the patient that evening, but could not, on account of the bad weather. The case would apparently get well and then relapse again, and the disease had started after vaccination.

Dr. Bechet said that he had had under observation, some years previously, a case of Henoch's purpura. The lesions in his case greatly resembled those of the boy under discussion. He suggested the possibility of a similar diagnosis in the case presented.

Dr. Wise said that Dr. Bechet's suggestion of purpura should be given serious consideration. He had shown a case, not long ago, before the New York Dermatological Society, in which the question of erythema multiforme and purpura were discussed, as in this case. This may be a case in which the erythema multiforme had as a symptom, an effusion of blood into the tissues, in the end stages. The speaker said this disease began not as a purpura, but as an erythema multiforme which resulted in a purpura, so that the question arose as to whether there were types which were transitions between the two.

EPITHELIOMA OF THE PALATE. Presented by Dr. Oulmann.

The patient was a male, 59 years of age. He presented an epithelioma of the soft palate, extending to the right gum, which had been from eight to ten weeks' duration. The diagnosis had been corroborated by biopsy.

PSORIASIS IN A FULL BLOODED NEGRO. Presented by Dr. Howard Fox.

The patient, D. T. T., was a full blooded negro, 50 years of age, born in the United States, a cook by occupation. He presented typical, thickened patches of psoriasis on the backs of both elbows and other, less marked patches, on the scalp and trunk. The case would be reported later, with photographs and result of biopsy.

DISSEMINATE LUPUS VULGARIS. Drs. MacKee and Wise.

The patient, a male, 20 years of age and single, had been referred to the speaker by Dr. Kimball of this city. The Wassermann reaction had been negative and there was no specific history. He presented a series of lesions on the face and one of the series consisted of the disseminate type of lupus vulgaris, which diagnosis had been confirmed by microscopic examination. There were present the so-called acne agminata of the text books, together with small nodules, showing superficial inflammation and others, similar to small sebaceous cysts, chiefly over the neck and shoulders. The speaker said they were not so sure of the significance of those lesions, but thought they represented a type of tuberculide. The subcutaneous lesions were being presented for consideration as to the question of their being a nodular tuberculide. The von Pirquet test had been positive.

HYPERKERATOSIS SUBUNGUALIS. Presented by Dr. Weiss.

The patient was a male adult, who presented lesions of a bluish-purple color on both hands, especially noteworthy at the tips of the fingers. The subungual layer of all the nails, with the exception of one ring finger, was involved. The patient had varicose veins, a left-sided varicocele and an eczematous seborrhœic patch on the glans penis. A network of varicose veins was arched alongside the false ribs, and over the chest, abundant varicose veins extended, giving the appearance of a *caput medusæ*. The hair growth on the pubes and axillæ was scarce, and in the face it resembled the Chinese type of hairs. There was no hair growth on the back or legs. The speaker said he had made quite an extensive examination of the case, and the general appearance showed it to be one of the pluriglandular type, where primarily the suprarenals, and then the hypophysis were involved. Symptoms of the latter condition were the undeveloped teeth, small chin, tapering fingers and high maxillary arch. The vasomotor reaction in the case showed an erythematous streak on scratching with a blunt instrument, soon disappearing and leaving a white streak in its wake.

The speaker said he did not bring this patient before the Society because of the hyperkeratosis, but because the man exhibited a certain syndrome of endocrine inefficiency, to which dermatologists were not giving very much attention as yet, but which would be noted more in the very near future. This case showed an angio-neurosis of the skin, the face was flushed purple, dilated veins extended over the chest; there was a venous circle around the false ribs and a varicocele on the left side. To those giving attention to the glandular syndromes in dermatology this meant an inadequacy of the adrenal content in the blood. As the adrenalin was attracted by the hæmoglobin as an oxydizer, the lack of oxygen which was present in these cases gave the skin a purplish appearance, through venous stasis. The appearance of the varicocele on the left side was due to the same adrenal inadequacy. All these patients had a varicocele, especially on the left side, because the venous supply here did not

empty itself into the vena cava first, but into the vena venalis and then into the vena cava, while on the right side it emptied directly into the vena cava. The glandular syndrome in these cases was that of an adrenal insufficiency. This patient also possibly had a beginning hypernephroma.

Dr. Howard Fox presented photographs of a case of lupus erythematosus of the upper lip and one of xanthoma of the palm, in connection with cases shown at the previous meeting. He also showed a photograph of an extensive pityriasis rosea with numerous lesions upon the face.

PHILADELPHIA DERMATOLOGICAL SOCIETY.

Rgular Meetings, April 17th and May 15th, 1916.

Frank Crozer Knowles, M.D., *Chairman.*

PEMPHIGUS VEGETANS. Presented by Dr. Hartzell.

Female, colored, aged 59. She had been a patient in the Philadelphia General Hospital for over three weeks. She said that the eruptions had existed two months, but they were probably of longer duration. In the axillæ and groins were numerous large bullæ, in some cases with a typical vegetating mass, superimposed. There was a scattered eruption all over the body and marked itching.

EPITHELIOMA. Presented by Dr. Pfahler.

Male, white, aged 48, with a small pea-sized lesion in the inner canthus of the right eye. This was of two years' duration; by the formation of fibrous tissue, there was considerable ectropion; also marked induration, the lesion being covered with a yellowish crust. The Wassermann was negative; this, however, had no bearing on the diagnosis as the growth was typically epitheliomatous.

EXTRAGENITAL CHANCRE. Presented by Dr. Schamberg.

Female, white, aged 22. This patient had had an initial lesion on the upper lip which was typical in every respect, accompanied by considerable adenopathy. There was no history as to the mode of infection. She had been given 0.4 gram of arsenobenzol, the product of the Polyclinic Hospital Laboratory, and the lesion had healed in one week, leaving no scar.

LUPUS ERYTHEMATOSUS. Presented by Dr. Clark.

This patient had had a very extensive eruption of lupus erythematosus covering a large part of the face, across the nose, and which had existed for several years. She had been treated by the violet rays and desiccation method with very good results, leaving only a very small amount of scarring.

The speaker also showed photographs of other cases which had been treated by the same methods, very successfully.

LUPUS VULGARIS. Presented by Dr. Schamberg.

Male, white, aged 45. Prior to the treatment undertaken by the speaker, the entire lower jaw was covered with deep nodules, of soft consistency and yellowish brown color; there were areas of atrophy and heavy crusting in places. This had been of thirteen years' duration and the picture was typically that of lupus vulgaris. The patient had been treated with six per cent. pyrogallic acid ointment and there was considerable improvement, though the disease was far from cured.

X-RAY TREATMENT FOR HYPERTRICHOSIS. Presented by Dr. Pfahler.

Ten cases of young women were shown, all of whom had had extensive growths of hair on the face and had been treated by the X-ray by the speaker, with very good results on the whole. In some, after a period of several months, there had been no return of the hair and there was no atrophy or scarring of the skin. In some of the others there had been a slight return.

OCCUPATIONAL DERMATITIS. Presented by Dr. Davis.

Male, white, aged 28, who had a more or less generalized erythematous dermatitis, in places distinctly squamous, accompanied with intense itching. The patient had been working in one of the powder rooms at the Du Pont Powder Works and was constantly exposed to the fumes of ether which he necessarily inhaled; the dermatitis was evidently the result of the systemic poisoning. He had had this condition for fourteen weeks, during all of which time he had been engaged in his regular occupation.

ECZEMA WITH MARKED FOLLICULAR INVOLVEMENT. Presented by Dr. Stelwagon.

H. D.; male, white, aged 14. The eruption made its appearance about one year ago as a small spot on the forehead, soon becoming erythematous in character, papulo-squamous and accompanied by considerable itching. In a few days it began to spread peripherally and within a comparatively short time, the entire body was involved. At the time of presentation, the only parts free were the palms and buttocks and occasional areas on the extensor surfaces of the arms and legs. There was considerable thickening, particularly on the face, neck and lower legs. Combined with the squamous condition was a marked follicular involvement, this being more intense over the trunk, flexors of arms and legs. The body was covered with excoriations, as the itching was intense. There was considerable glandular involvement, particularly in the groin. The patient's health was and had been especially good; no marked nervous manifestations were present though he complained bitterly of loss of sleep from the intense itching at night. Examination of the urine showed nothing abnormal. There was no loss of weight and the only point of interest in the history was of his having had, as an infant, an eczema of the face and body which disappeared when he was about two years old.

The speaker said that when he saw this patient the first time, which was the morning of the day of presentation, there were a few wheal-like elevations on the chest which had disappeared and he felt that the patient should be carefully watched as this might develop into a mycosis fungoides at a later date. The patient had been in a hospital in a neighboring city where the diagnosis of prurigo ferox had been made, in spite of the fact that the preponderance of the

lesions was on the flexor surfaces rather than on the extensors; that there was a moderate amount of glandular involvement; that there was no increase in pigmentation and that the patient was native born. He had been subjected to all the food reaction tests, with no results. Blood tests were normal with the exception of a high color index.

The members of the Society were of accord that this was not a case of prurigo and were very much interested in it, on account of the marked follicular involvement.

CASE FOR DIAGNOSIS. Presented by Dr. Davis.

E. S., female, white, aged four. Last June, a small "pimple" appeared on the right cheek just below the malar eminence. This grew steadily until now it reached to about the size of a marrowfat pea, nodular, very firm to the touch and of a reddish-brown color. This color could be almost entirely expressed under glass pressure, the only part remaining being the little pinkish halo which surrounded the lesion.

Discussion.

Dr. Schamberg said that a sarcoid must be considered but it would be impossible to make the diagnosis without the aid of a biopsy.

Dr. Stelwagon was inclined to look upon it as a keloid or a hypertrophic scar and said if such be the case, excision for therapeutic purposes or for biopsy would not be indicated, as the resulting scar might be larger than the existing condition.

Dr. Hartzell did not agree with the suggestion of its being a keloid on account of the distinct halo which surrounded it, but suggested the possibility of a lupus vulgaris in spite of there being no small, yellow-brown nodules, simply this one single papule.

Dr. Stelwagon suggested in the line of treatment, that as the child was so young, the parents wait until the expiration of a few years before treating the lesion, unless it continue to grow, in which case he considered carbon dioxid snow of the greatest value.

CASE FOR DIAGNOSIS. Presented by Dr. Davis.

Female, white, aged 54. About two years ago, the patient experienced a sense of irritation on the upper lip, just below the right nostril, and rubbed it very vigorously with her veil. The more she rubbed, the more irritation was produced, and finally a rough, irregular papule appeared, which continued to grow until there was an elevated plaque, about the size of a dime, on the upper lip, distinctly nodular; and on the septum of the right nostril was a papule the size of a small pea, pedunculated, and had been and was discharging a small amount of purulent material. The patient was given potassium iodide and there had been considerable improvement in the two weeks since she was first seen, though the speaker was still inclined to look upon this as a tuberculous condition, in spite of the age of the patient at which it began. No Wassermann test had been taken as yet.

ERYTHEMATOUS LUPUS. Presented by Dr. Knowles.

Female, white, aged 7. Italian by birth. Four months ago, there appeared on the arms, forearms and face, a papular eruption which had continued in

those situations but had changed in character until there were on the backs of each hand and forearm, about six or eight pea- to dime-sized lesions, covered with a grayish-white scale, crater-like, the edges of some being distinctly elevated above the surrounding skin, with a central umbilication or depression. Interspersed were small papules, rather shiny in appearance and accompanied by intense itching. Around the mouth and eyes were groups of papules covered with a brownish scale.

Discussion.

Dr. Schamberg was inclined to look upon it as a lichen planus annularis.

Dr. Hartzell said if this were a case of lichen planus, it was the most unusual manifestation of it that he had ever seen, and while he was willing to admit the possibility of it, he felt that the whole subject of lichen planus with its different manifestations was anything but clear, and that it was not right to include such a great diversity of types under the one general classification; he thought it corresponded more to the necrotic or lichenoid type, agreeing fully with all the other members of the Society that it was a most remarkable type of any form of lichen planus.

Dr. Stelwagon was inclined to agree with the speaker in the diagnosis of erythematous lupus, but was not willing to discard altogether the diagnosis of lichen planus.

ERYTHEMA OF IRIS TYPE. Presented by Dr. Hartzell.

Female, mulatto, aged 28. On each wrist was a perfectly round lesion, about the size of a silver half-dollar; very much darker than her light mulatto tint, lightly elevated and surrounded by a markedly inflammatory halo, about a quarter of an inch wide. Over the right scapula was another, smaller lesion, which was oval in shape. Completely surrounding the mouth was a zone of dark pigmentation about half an inch wide and which, in turn, was surrounded by a pinkish halo. There was only a slight burning sensation and the lesions had existed four days. She gave the history of having had one attack three years ago; another last October, of an exactly similar nature. On her arms and back were about ten pigmented spots which were the remains of previous lesions. They were extremely tender to the touch and accompanied by considerable itching. If this patient were white, probably the iris form of erythema multiforme would be much more noticeable.

LUPUS ERYTHEMATOSUS. Presented by Dr. J. Strousse.

Female, white, aged 36. On the cheek, across the nose and on the forehead, was a lupus erythematosus of distinctly florid type. The edges were rather sharply defined; there was no induration and very little scaling except where treatment had been applied. It appeared seven weeks ago; (the patient said, two days after having taken ten drops of Fowler's solution, t.i.d.).

Discussion.

Dr. Hartzell said that he had seen this type appear very suddenly in the course of a few hours, and disappear just as quickly and believed that it was an entirely different type from the classical lupus erythematosus.

TUBERCULOSIS VERRUCOSA CUTIS. Presented by Dr. Davis.

Boy, aged 12. On the right side of the nose, covering the entire cartilaginous portion to the tip, was a warty, granular, raspberry-like lesion, which appeared ten months ago. It was covered with a thick gray sanguineous crust which the speaker had tried ineffectually to remove. The patient's family was so indifferent or ignorant that his instructions to apply the medicament in such a manner that the crust could be removed and the underlying conditions seen, had not been carried out.

Discussion.

Dr. A. Strauss remarked that this was very similar to the case he had presented at the February meeting, and which had done remarkably well under X-ray application and pyrogallic ointment.

CASE FOR DIAGNOSIS. Presented by Dr. Schamberg.

Female, dark mulatto, aged 18. On face and chest, mostly anteriorly, and under the arms, were numerous lesions, flat, irregular in outline, varying from the size of a small French pea to a marrowfat pea, distinctly pink in color and entirely denuded of epithelium. Scattered between this type of lesions were numerous dark papules and there could be seen an occasional vesicle. All the larger lesions which looked so raw had previously been vesicular in character. Here and there was some attempt at grouping. There was a slight erosion on the left tonsil but this was not considered to be syphilitic in character. The diagnosis was suggested of dermatitis herpetiformis, but it was not a typical case.

TREATMENT OF INOPERABLE SARCOMA. Presented by Dr. Pfahler.

Male, white, aged 11. This patient had sarcoma of the right side of the face, which was considered by the surgeons as inoperable. He had had a three months' X-ray treatment before seeing the speaker, and with no result. An X-ray plate, taken January, 1916, showed a complete involvement of the inferior maxillary bone on that side. He had been given two weeks' treatment with the Coolidge tube, using a 5 millimeter aluminum screen. An X-ray plate, taken April, 1916, showed a complete regeneration of the bone and there was absolutely no effect on the skin from the X-ray exposures.

Dr. Pfahler also showed several cases and plates of epithelioma which had been wonderfully improved under X-ray treatment.

Henry K. Gaskill,
Secretary.

REVIEW

OF

DERMATOLOGY AND SYPHILIS.

Under the direction of

FRED WISE, M.D., New York,

Assisted by

CLARENCE A. BAER, M.D., Milwaukee.
WILLIAM H. BAUGHMAN, M.D., New York.
PAUL E. BECHET, M.D., New York.
J. S. EISENSTAEDT, M.D., Chicago.
CHARLES GOOSMANN, M.D., Cincinnati.
JAMES F. GRATTAN, M.D., New York.
ROBERT C. JAMIESON, M.D., Detroit.
FREDERICK T. LAU, M.D., New York.
M. F. LAUTMAN, M.D., Hot Springs.
OSCAR L. LEVIN, M.D., New York.
M. L. RAVITCH, M.D., Louisville.
ISADORE ROSEN, M.D., New York.
MAX SCHEER, M.D., New York.
PHILIP F. SHAFFNER, M.D., Chicago.
A. W. STILLIANS, M.D., Chicago.
JOHN H. STOKES, M.D., Chicago.
HARVEY P. TOWLE, M.D., Boston.
VICENTE PARDO, M.D., Havana, Cuba.

FORTSCHRITTE AUF DEM GEBIETE DER ROENTGENSTRAHLEN.

(Jan. 25, 1915, xxii, No. 5.)

Abstracted by CHARLES GOOSMANN, M.D.

THE HISTOGENESIS OF ROENTGEN AND TAR CARCINOMAS. H. RIBBERT, p. 473.

Ribbert describes and illustrates the histologic findings of several newly studied cases of epithelioma due, respectively, to Roentgen rays and to tar irritation. These studies tend to confirm his previously published theory that the primary and important change is in the connective tissue, and not in the epithelium. The elastic and collagen fibres disappear, and a cellular infiltration of the connective tissue occurs, all of which lessens the resistance to the downgrowth of epithelium. The changes are similar whether the epithelioma is due to tar, Roentgen ray exposures, or any other cause.

INSTRUMENTARIUM FOR THE APPLICATION OF HIGHLY ACTIVE RADIUM AND MESOTHORIUM PREPARATIONS. P. WICHMANN, p. 479.

The flat surface applicators heretofore have been made by incorporating the radioactive salt in a varnish with which the applicator is coated. This does not

exclude the air, and therefore permits variations of the emanation content, causing variations in radioactivity, with the consequent uncertainties of dosage. The susceptibility to injury of the unprotected surface is another drawback to these varnish applicators.

Wichmann describes and illustrates his methods of mounting, which were first published in 1912. Each applicator is hermetically sealed with 1/10 mm. of silver, and the mounting may be square, circular or oval.

ABSORPTION MEASUREMENTS WITH THE FURSTENAU INTENSIMETER. IMMELMANN AND J. SCHUTZE, p. 533.

The intensimeter utilizes the principle that selenium acquires increased electrical conductivity when exposed to light or Roentgen rays. This permits its utilization in measuring the intensity of the latter, for a unit time, and then calculating the total time needed for a given Roentgen treatment (the production and quality of rays being assumed to remain constant). The unit of dose is arbitrary, as in all other methods, and is designated 1 F. Twelve F. units are equal to one H. unit (of Holzknecht), or to two X units of the Kienböck scale. With hard filtered rays, however, this proportion changes, one H. unit being equivalent to 5 X (Kienböck) or 30 F. (intensimeter) units. This is explained by the authors as being due to the less rapid coloring of the Sabouraud pastille when exposed to hard Roentgen rays.

(*Ibidem*, Mar. 18, 1915, xxii, No. 6.)

MEASURING THE PENETRATION OF ROENTGEN RAYS. ROBT. KIENBÖCK, p. 567.

INCREASED RADIO-SENSITIVENESS OF THE HAIR FOLLICLES IN PSORIASIS. ROBT. KIENBÖCK, p. 591.

Increased sensitiveness of the skin to Roentgen rays may be due to internal disease, such as exophthalmic goitre, or it may accompany cutaneous disorders, and particularly psoriasis. In the latter case, the hypersensitiveness is not limited to the area of efflorescence, but affects the entire integument. A case is reported in which the entire scalp was given 2¼ H. units of Roentgen treatment filtered through one mm. of aluminum, for the relief of an itching psoriatic eruption. In less than three weeks, the hair began to fall out, and progressed to an almost complete baldness, that lasted for a period of two months. This patient had, several months previously, received mild Roentgen treatment, with soft (unfiltered) rays, with no untoward results, and Kienböck believes the use of hard rays in the last exposure caused the undesirable effect on the hair follicles.

THE REALIZATION OF RADIOMETER VALUES. ROBT. KIENBÖCK, p. 593.

The most widely used radiometers are the Sabouraud-Noiré (in the original or with Holzknecht's scale) and the quantimeter of Kienböck. They should be used together, Kienböck believes, the former to measure the progress of radiation, the latter to register the total surface and deep dose. With medium soft rays, the erythema dose is equivalent to 5 units on the Holzknecht scale or 10 X measured on the quantimeter.

However, when working with very hard rays, filtered through 3 or 4 mm. of aluminum, the erythema dose registers 10-15 H. on Holzknecht's scale, and

40-60 X on Kienböck's. It is, therefore, inaccurate to try to measure dosage in terms of X units on a Holzknecht scale, and vice versa.

DOSE MEASUREMENT IN ROENTGENTHERAPY. H. E. SCHMIDT, p. 594.

The radiometer of Sabouraud and Noiré should be read by daylight (not sunlight). It would be convenient to substitute an artificial light, if a satisfactory one could be found. Kruger has recommended a lamp (osram lamp) with blue glass filter, as made by the firm of Pohl, in Kiel, but Schmidt warns against its use, as his experience with the lamp showed very unreliable readings of the pastilles.

SOME REMARKS ON KIENBÖCK'S ARTICLE ON PAGE 593. H. E. SCHMIDT, p. 637.

Schmidt criticizes Kienböck's quantimeter, and believes it much inferior to the Sabouraud and Noiré pastilles for measuring X-ray dosage.

(*Ibidem*, Oct. 12, 1915, xxiii, No. 3.)

PROCEEDINGS OF THE SPECIAL COMMISSION FOR DOSIMETER COMPARISONS (GERMAN ROENTGEN SOCIETY.)

The subsequent 7 articles, comprising 80 pages of technical discussion, are submitted by the commission.

MEASURING HETEROGENEOUS RAYS. TH. CHRISTEN, p. 214.

It is well known that X-rays occur in different wave lengths, somewhat analogous to the visible spectrum. This heterogeneity is greatly emphasized by Dessauer, but Christen believes that it is not such a serious drawback in treatment as filtration, though 3 mm. of aluminum is sufficient to render the rays practically homogeneous. Christen confirms this by an analysis of one of Dessauer's own tables.

He suggests a method for measuring and recording the degree of heterogeneity of any Roentgen rays by the use of his penetrometer.

RECORDING THE ABSORPTION OF ROENTGEN RAYS BY A NEW GRAPHIC METHOD. CARL WEISSENBERG, p. 229.

INSTRUMENTAL DETERMINATION OF THE ERYTHEMA DOSE. HEINRICH WACHTEL, p. 248.

TECHNICAL ROENTGEN RAY MEASUREMENTS. G. HOLZKNECHT AND C. WEISSEBERG, p. 257.

Roentgen ray measurements are of two kinds, qualitative and quantitative. The best instrument for measuring quality or penetration is the one devised by Christen. The Benoist penetrometer is less accurate, and different examples, even from the same manufacturer, may vary one or two degrees from each other. The various instruments devised for quantitative measurements are also discussed.

ROENTGEN RAY MEASUREMENTS WITH THE SELENIUM CELL. RICHARD GRANN, p. 267.

This is a technical discussion of the photo-electric phenomena involved.

THE PRACTICAL USE OF THE SELENIUM CELL AND THE AVOIDANCE OF SOME OF ITS ERRORS. ROBERT MAYER, p. 283.

The author discusses the method of using Furstenau's intensimeter, and considers it sufficiently accurate for practical purposes, as well as time-saving.

MEASURING ROENTGEN RAYS WITH THE CALOMEL PRECIPITATION REACTION, AND PHOTO-CHEMICAL METHODS IN GENERAL. RICHARD GRANN, p. 289.

ANNALES DES MALADIES VÉNÉRIENNES.

(November, 1915, x, No. 11.)

Abstracted by PAUL E. BECHET.

CHANCRELLOUS ULCERATION OF THE PENIS IN AN OLD SYPHILITIC TREATED WITH NEOSALVARSAN. POSSIBLE CONFUSION WITH A REINFECTION. GASTINEL, p. 641.

The author reports a case of syphilis infected about two years previously, who had received ten injections of neosalvarsan, three intravenous injections of cyanide of mercury and three injections of gray oil. Eight months later, after a marked encephalitis, eight injections of gray oil were administered; one and a half years later an ulceration occurred on the site of the former chancre, the patient having had coitus with an unknown woman three weeks previously. The lesion disappeared completely after twelve injections of biniodide of mercury. There were no other signs of a new infection. The author believes that the lesion was a recurrent chancrellous ulceration (chancre redux) and not a new infection.

RECURRENT SPECIFIC ACCIDENTS AFTER "606." BRALEZ, p. 644.

Bralez reports two cases of syphilis, one of which presented a papulo-squamous syphilide on the penis and scrotum, three months after eight intravenous injections of salvarsan; the patient had also received forty-five injections of the soluble mercurial salts. The lesions disappeared after nine injections of benzoate of mercury, of two centigrammes each. The other case occurred in a woman, aged 23, whose infection had begun four years previously. She had received five injections of salvarsan, once weekly. One year later a facial paralysis developed, which disappeared entirely after forty injections of salvarsan, intermittently administered. After remaining ten months without treatment, she

complained of constant headache, osteocopic pains an the arms and legs, and tinnitus aurium. All of the symptoms, with the exception of the tinnitus, disappeared after fifteen injections of benzoate of mercury.

(*Ibidem*, December, 1915, x. No. 12.)

SYPHILITIC NEURASTHENIA AND ITS RESULTS. GAUCHER, p. 706.

Gaucher, in discussing the subject, states that neurasthenia is frequent among syphilitics. He does not believe that syphilis alone can cause the disease, but that there must also exist a hereditary nervous inefficiency. He considers the latter a predisposing cause, and syphilis the determining factor. Specific treatment has little or no effect on the neurasthenia, which must be treated by the usual means employed in this disease.

INTRAVENOUS INJECTIONS OF BENZOATE OF MERCURY IN SYPHILIS. BIZARD AND KLEIN, p. 711.

Bizard and Klein used the following formula:
Benzoate of mercury, 1 gr.
Sodium chloride, 2 gr. 50.
Distilled water, q.s. ad 100 gr.
The dosage varied from one centigramme to four cubic centimeters. The injections in each case averaged twelve in number, and the authors' observations were based on fifteen cases. A temperature of 38°2 and 38°5 C. occurred in two cases. Endophlebitis occurred in three instances. Two-thirds of the cases had a mild stomatitis. Two developed a severe diarrhœa. One had a mercurial rash. In three cases the Wassermann reaction became negative after the tenth injection; in the twelve other cases it was not modified by the treatment. The authors believe that the benzoate is inferior to the cyanide of mercury for intravenous use. They recommend the intravenous administration of mercury only when intensive treatment is required, and believe the best results are obtained by the alternate use of cyanide of mercury intravenously and benzoate of mercury intracutaneously.

A FEW ATYPICAL CHANCRES. BIZARD AND BRALEZ, p. 720.

ANNALES DE DERMATOLOGIE ET DE SYPHILIGRAPHIE.

(July, 1915, No. 10.)

Abstracted by PAUL E. BECHET, M.D.

DIMINISHED RESISTANCE OF THE SKIN. L. BROCQ, p. 529.

Brocq states that diminished cutaneous resistance may be general, and quotes epidermolysis bullosa congenitalis as an example. It may also be local, as evidenced by the various trade exanthems. A feebleness of resistance may be brought on by a series of repeated local irritations; it is in this way that

inflammation frequently results from the continued use of epispastic salves, cosmetic preparations, etc. Diminished resistance may involve all or one or more of the cutaneous layers. Even the same irritant may produce the various changes; as an example he mentions the various alterations produced by sunlight, some of them pathological, such as xeroderma pigmentosum and hydroa vacciniforme; again only the pigmentary layer may be affected, as in freckling. Diminished cutaneous resistance may be congenital or acquired, permanent or transitory. Influences of internal origin, such as renal insufficiency, gastro-intestinal fermentation, hypofunction of the ductless glands, etc., may lower cutaneous resistance.

THE LENGTH OF THE PERIOD OF INCUBATION IN SYPHILIS FROM A MEDICO-LEGAL STANDPOINT. THIBERGE, p. 54.

Thiberge finds, after a review of the literature, that the average period is 25 to 30 days, but that the extreme limit varies considerably; limits of 60 days, and in one case 90 days, having been reported.

BRITISH JOURNAL OF DERMATOLOGY.

(April to June, 1916, xxviii, Nos. 4 to 6.)

Abstracted by I. ROSEN, M.D.

ON SPRAYS AND SPRAYING IN THE TREATMENT OF CERTAIN SURFACE AFFECTIONS OF THE SKIN. W. ALLAN JAMIESON, p. 104.

Jamieson recommends the hand spray in the treatment of the various forms of seborrhœa of the scalp. He has used the following lotion in the ordinary hand atomizer, with very good results: Euresol, 2 drachms; spiritus formicarum, 1 ounce; spiritus rosmarini, ½ ounce, olei ricini, ½ ounce; spiritus vini rectificati, to 8 ounces.

A CASE OF SYRINGOMA. S. NORMAN PAUL AND H. G. ADAMSON, p. 106.

This case is of interest on account of its unusual character. It would be impossible to predict its histological structure from the macroscopical appearance of the lesions.

The patient under consideration is a man, 46 years of age, who has about 25 smooth, firm, raised growths, situated between the sternum and the nipple on the left side. The growths are sessile, firmly attached to the skin and move with it. Some of the smaller tumors coalesce to form one large plaque. The largest ones measure 2.5 cm. across and are raised 1.5 cm. Some of them have been present 25 years. The color varies from a dark blue to that of a pinkish blue, and some of the larger growths appear to be cystic, with dilated blood vessels ramifying the surface.

The authors classify the benign forms of adenomata and adenoid epitheliomata, as follows:

1. Adenoma sebaceum: which usually occurs on the cheeks and sides of the nose and forehead, consisting of small rounded tumors of sebaceous gland tissue.

2. Epithelioma adenoides cysticum of Brooke: these are usually multiple, the choice of location being the forehead, temples, eyes and nose, but they may occur upon the scalp and chest. The structure of these growths is that of embryonic pilosebaceous follicles, so that they have been described by some authors as tricho-epitheliomata. Histologically, they closely resemble rodent ulcer, and it is very probable that rodent ulcer is also a tricho-epithelioma or embryonic pilosebaceous tumor, but made up of cells less stable than those of epithelioma adenoides of Brooke, with a greater tendency to break down and ulcerate.

3. Endotheliomata of the scalp, of Spiegler and Mulert are also pilosebaceous tumors or tricho-epitheliomata.

4. Jarisch's so called "hæmangioendothelioma," has also the structure of basal cell epithelioma of the embryonic pilosebaceous or tricho-epithelioma type.

5. Another important type, probably of embryonic sweat gland origin, is Kaposi's "lymphangioma tuberosum multiplex," later described by Jacquet and Darier as "hydradenome eruptif," and by Török as syringo-cystadenoma, and now generally known by the name given to it by Unna, of syringoma or syringadenoma.

6. Many authors have reported single sweat gland tumors, sudoriparous adenoma or syringoma.

7. There have been described linear nævus made up of sweat glands, or of sebaceous glands.

The authors' case may be placed among the sweat gland tumors of group 6. The massing of the growths in one area is suggestive of a segmental or linear nævus.

DIPHTHERITIC WHITLOW. J. D. Rolleston, p. 110.

Rolleston reports a case of a boy, 5 years of age, who was admitted to the hospital with a severe faucial diphtheria. He received large doses of antitoxin immediately, and in a few days the throat began to improve. About a month after the onset of the disease, the patient developed a transient right hemiplegia and aphasia, and at the same time there developed bullæ on the terminal phalynx of the left index, middle and ring fingers. Local applications of antiseptic solutions, such as 2% iodine solution, fomentations, compresses of sodium citrate and sodium chloride, and iodoform failed to heal the lesions. There was a profuse discharge from the granulations that had formed, and in one or two places there was a distinct slough. The patient complained of very little pain; there was no rise in temperature and no constitutional disturbance.

No membrane was present at any time, and the lesions looked like a severe whitlow.

It was not until one and one half months after the involvement of the fingers that the diagnosis of diphtheria was suspected. Cultures were taken and numerous groups of diphtheria bacilli were found. The patient received antitoxin, and within one week the lesions had healed.

The author emphasizes the fact that many cases of obstinate whitlow occurring in hospital residents and nurses are probably diphtheritic in origin.

A NEW TEST FOR SYPHILIS (THE EMULSOID-GELATION, OR THE "GEL" TEST). J. E. R. McDonagh, p. 114.

The author claims that the "gel" tests give more accurate results than the

Wassermann test. The change observed in the "gel" test is the conversion of the emulsoid particles, which form the internal phase of the serum, into the "gel" particles.

Its advantages are as follows: First, serum withdrawn in the early stages of the disease gives a different reading to one in the late stages. Secondly, the influence of treatment upon the solid particles or the protective substances in the serum can be better gauged. Thirdly, paradoxical results are not obtained, results which are too often met with in the non-specific complement-fixation test, especially with sera from patients who have recently been treated. Fourthly, a positive reaction is never obtained with a normal serum, provided it has not been kept too long, and negative reactions are not given by the "gel" tests, when the results should have been positive.

The test had been given a thorough trial in 200 cases, and the Wassermann test had been done in the same patients. Out of these 200 cases, one gave a strongly positive and two a slight positive Wassermann reaction, although the patients had never had syphilis, so far as one was able to tell. By the "gel" test these sera were normal. Thirty-seven of the 200 cases gave a negative Wassermann reaction, when the test should have been positive. By the "gel" tests all these sera were positive.

The author describes the tests in detail in his article, and refers the reader to his book, "LINKS IN A CHAIN OF RESEARCH ON SYPHILIS." Printed by Harrison and Sons, London.

A CASE OF FOURNIER'S SECONDARY SYPHILITIC ANALGESIA. C. Rasch, p. 119.

(Translated from the Danish by W. Jenkins Oliver.)

A girl, 21 years of age, was admitted into the department for skin diseases at the Rigshospital, with the following history. In October, 1914, she had some ulcerations on the forehead which were diagnosed as syphilitic and treated with 39 inunctions of mercury. In March, 1915, an ulcer appeared in the throat, for which she received 30 inunctions of mercury. In the middle of July of the same year, new ulcerations appeared on the forehead; at the same time she suffered from headaches, considerable loss of hair, loss of weight and loss of appetite.

The patient was very pale and thin. On the frontal border of the hairy scalp was a sharply defined, flat ulcer, about the size of a twenty-five cent piece. On the chin there were four small ulcers of the same character. To the right of the vertebral column, immediately above the vertebral border of the spine of the scapula, was another ulceration of the same nature. No bone affection could be observed. No enlargement of the glands. The left tonsil showed a sharply defined ulceration about the size of a hazel nut. The Wassermann reaction was positive.

Owing to the patient's poor condition, she was given a tonic consisting of potassium iodide, with iron. The ulcers healed in about three weeks, and the patient gained a few pounds in weight.

A spinal puncture, on Sept. 9, showed no pathological changes. Examination by the ophthalmologist and otologist revealed nothing pathological.

On Sept. 30, the patient was tested for sensations over "Fournier's areas"; a pronounced analgesia was demonstrated on the dorsal surfaces of both hands and on the mammæ, accompanied by some anæsthesia. The pupils were equal and reacted to light. Nothing abnormal was elicited in any of the cranial

nerves. There was hypæsthesia and hypalgesia of the glove type, with the upper limit about the middle of the forearms; no alteration in the sense of localization or of passive position; hypæsthesia and hypalgesia over both mammæ, thighs and upper part of the legs on their anterior aspects. The patellar reflexes were entirely absent. The Achilles tendon reflexes were exaggerated.

The absence of patellar reflexes definitely points to an affection of the nervous system, and, together with the altered sensation in the lower limbs, suggests an affection of the cord rather of the nature of some slight vascular disturbance, than a meningitis. The altered sensation in the upper limbs is probably functional in origin, while the hypæsthesia of the mammæ might be due to either cause.

ARCHIVES OF INTERNAL MEDICINE.

(July, 1916, xviii, No. 1.)

Abstracted by R. C. Jamieson, M.D.

THE HEREDITARY FACTOR IN PELLAGRA. C. B. Davenport, p. 4.

The hypothesis is taken that "pellagra is the reaction of the individual to the poisons elaborated in the body, probably by a parasitic organism," and "is, in all probability, a specific infectious disease, communicable from person to person." The inflammations of the skin and mucous membranes are, as would be expected, more severe in those with lowered resistance, either acquired or inherited; so also is the disease more readily spread among those mentally deficient, on account of their inability to protect themselves properly against infection and improve their sanitary surroundings.

The author believes that there is an hereditary influence in pellagra, noting that whites are affected two and one-half times as frequently as negroes, although sanitary surroundings were similar. Investigations showed that many families had five or more cases of pellagra, and the article goes on to elaborate those cases where heredity and contact would be responsible for the appearance of the disease. He accounts for the immunity of some members of a family with several pellagrins by variations in resistance on the part of the individual as well as by variations in the virulence of the infection.

From his investigations the author concludes that pellagra is not a directly inheritable disease, but that it does depend upon inherited traits. He thinks it is probably communicable, 40 to 50% of the children of susceptible parents being susceptible to the disease.

A STUDY OF THE HEREDITY OF PELLAGRA IN SPARTANBURG COUNTY, SOUTH CAROLINA. Elizabeth B. Muncey, p. 31.

The histories of about six hundred pellagrins were studied, the families being grouped according to the umber of those affected in each family, both pellagra and "pellagra sine pellagra" being recognized. It was found from this study that heredity does not play any direct part in the transmission of the

disease, but, however, there may be an hereditary predisposition in families that have had gastro-intestinal disturbances for several generations, these disturbances being relatively high among pellagrous families. The exciting factor would seem to be contact or life in those sections where the disease is endemic.

The article is accompanied by many diagrams.

A CRITICAL CONSIDERATION OF SYSTEMIC BLASTOMYCOSIS. H. W. Wade and George S. Bel, p. 103.

The authors state that blastomycosis is not easily recognized, as most of the localized cutaneous cases do not develop into systemic infections, and systemic infections are generally mistaken for tuberculosis on account of lung involvement. This condition is now recognized as having a wide distribution, and in all probability more cases would be reported if the disease were recognized. Many different species of the organism are, however, capable of causing similar lesions.

They give a detailed discussion of the morphological and cultural characteristics of the organism and state that in the systemic infection, the atrium is usually the lung, due to inhaling repeatedly the fungi, especially where there is already some pathological condition present. It is rare to have a systemic infection follow a cutaneous lesion. The onset is commonly a severe cold with cough and expectoration, the course of the disease later becoming subacute or chronic, with little toxicity, the five organs most frequently involved being the lungs, skin, bone, spleen and kidneys. Other organs may be involved, but not frequently.

Microscopically the organisms may be either within or without the giant cells and may vary greatly in numbers.

Nothing new was discovered relative to the treatment of the disease, although they consider vaccine therapy offers a field for experimentation. They give a detailed report of their five cases.

(*Ibidem*, August, 1916, xviii, No. 2.)

DIETARY DEFICIENCY AS THE ÆTIOLOGICAL FACTOR IN PELLAGRA. Capt. E. B. Vedder, p. 137.

Vedder has reviewed the work of the Thompson Pellagra Commission at Spartanburg County, South Carolina, entirely from a dietary point of view, with the idea of finding a defect in vitamins in the diet such as exists in scurvy and beriberi.

While the dietary could contain sufficient calories to sustain life, it might lack certain vitamins which would be essential for the prevention of pellagra, thus differentiating malnutrition from a deficiency diet, each individual requiring a different amount of vitamins.

He draws comparisons between beriberi and pellagra in similar gastro-intestinal and nervous symptoms, and frequency, in inmates of institutions. Pellagra may be self limited during a deficiency diet or may continue even though a patient be put on a seemingly correct diet, but this may be due to the fact that we are ignorant of the vitamins necessary, or the patient might not be able to assimilate them.

He thinks that the tendency to recur in the spring is more in favor of a dietary ætiology than an infection, as beriberi acts in the same manner, while no known infection does.

To account for the cases in which contact has occurred, he believes that some of those people (43.5%) belonged to the same families and had the same diet, yet at the same time large numbers of people came in contact with pellagrins without developing the disease.

The most densely populated centres usually contained the poorest elements, who would live on a poor diet and would consequently develop the disease independently of any contact. Infection also presupposes conveyance of the organism from house to house, and this has been neither proved nor disproved, except that physicians, nurses and attendants in institutions rarely contract the disease.

Although the Commission failed to find any special food as the cause of pellagra, Vedder thinks that diet can still be responsible as being deficient in quantity and in vitamins present. In the diet of a great many of the mill-hand class there was a lack of variety and a great preponderance of certain articles of food, such as an exclusive use of wheat flour with cornmeal, salt meats and canned goods. He thinks the deficiency theory should be thoroughly studied in future work.

THE INCIDENCE OF PELLAGRA IN SPARTANBURG COUNTY, SOUTH CAROLINA, AND THE RELATION OF THE INITIAL ATTACK TO RACE, SEX AND AGE. J. F. Siler, P. E. Garrison, and W. J. MacNeal, p. 173.

According to the records accumulated by the Pellagra Commission, the disease has been increasing more or less rapidly since 1907, with a death rate in the year of initial attack of 15.8, although the proportion of negroes attacked has been slowly rising.

Children had a low death rate in the initial attack, the disease being rare under one year, but fairly common from two to twelve. From twelve to sixteen there is considerable freedom from pellagra, but later on it increases rapidly up to twenty and then diminishes in women but rises in men.

In cases of infantile pellagra they always found a previous residence close to a pellagrin but they believe that a nursing pellagrin does not communicate the disease through her milk.

The highest rate per 10,000 was for white females, 231; second were white males, 103; then colored females, 81; with 25 colored males; the age of greatest incidence being 30 to 34 in females, 55 to 64 in males.

(*Ibidem*, September, 1916, xviii, No. 3.)

THE TREATMENT OF SYPHILIS OF THE CENTRAL NERVOUS SYSTEM. J. C. Walker and D. A. Haller, p. 376.

Walker and Haller review analytically their treatment and results in 48 cases of tabes dorsalis, 6 cases of general paralysis of the insane, 16 cases of cerebrospinal syphilis and 5 cases of syphilitic meningitis.

They employed three methods: first, intravenous salvarsan alone; second, intravenous salvarsan and intraspinal salvarsanized serum; third, intraspinal salvarsanized serum alone. All patients were treated at first with intravenous salvarsan alone, but if no improvement occurred, the intraspinal salvarsanized serum was administered later. Only those with a negative blood Wassermann and a positive spinal fluid Wassermann were treated intraspinally only, the Swift-Ellis method being followed throughout, with the exception that larger

intravenous doses were given, the blood withdrawn one-half hour afterward and 20 to 25 cc. of whole serum used for injection. A moderate reaction for a few hours gave more improvement than a slight or no reaction, and was much more to be desired.

They found that long-standing infections resist salvarsan, although some cases with central nervous involvement improve remarkably after three to six intravenous injections alone. Other cases that did not improve under that treatment are benefited by one intraspinal injection. The most improvement in this class of cases was noted in those with recent infections.

In those cases, however, in which both the intravenous and intraspinal methods were used, improvement occurred in all cases; pain, headache, ataxia, dizziness, etc., were lessened; the Wassermann reaction became less positive and the cell count decreased.

Twenty cases were treated with intraspinal salvarsanized serum alone, the improvement in symptoms in all cases being marked, the Wassermann, however, being only slowly changed from positive to negative. The cell count diminished gradually, except in a few cases with a high cell count.

One case of general paralysis of the insane with a positive blood Wassermann was given two normal syphilitic serum treatments without changing the cell count, but later the cell count diminished one-half after one intraspinal treatment with salvarsanized serum.

They consider this treatment of great value, either alone or combined with intravenous salvarsan.

THE SUBSEQUENT HISTORY OF PELLAGRINS IN SPARTANBURG COUNTY, SOUTH CAROLINA, WHO SURVIVED THE INITIAL ATTACK. J. F. Siler, P. E. Garrison, and W. J. MacNeal, p. 340.

This paper is a further report of the Robert M. Thompson Pellagra Commission and deals with 1053 recurrent attacks of pellagra with 130 deaths in the year of recurrence, or 12.3%.

The prognosis in recurrent cases of pellagra seems to become more favorable each year for recovery from the attack, but each succeeding attack tends to increase the probability of a recurrence the following year, the disease becoming less malignant in the later years. A year without recurrence is very favorable both with regard to subsequent recurrence and to severity in case of later appearance, recurrences taking place even after several years' freedom from the disease. They consider it impossible to say when a case has completely recovered, stating that it is most probably arrested or inactive, as in the latent state of tuberculosis and syphilis.

JOURNAL OF EXPERIMENTAL MEDICINE.

(August, 1916, xxiv, No. 2.)

Abstracted by R. C. Jamieson, M.D.

THE TREATMENT OF LEPROSY WITH CYANOCUPROL. R. Takano, p. 207.

The author's work was done with six cases of leprosy at the I-hai-yen lepro-

sorium in Tokyo, the drug being a combination of potassium cyanide and copper, which is specially treated chemically before being introduced into the body. This compound was originally used and prepared by G. Koga, and used in his work with tuberculosis.

The similarity of organisms in tuberculosis and leprosy led the author to use cyanocuprol in the latter disease, in doses of 16 to 20 mg. every two weeks; 20 to 24 mg. may be given every week without ill effect. Injection is made very slowly in the femoral vein in the usual manner; after several injections such symptoms may occur, as congestion in the head, deep breathing, fast pulse, etc., but they rapidly pass off.

The six cases all received similar treatment with seeming benefit in all. Further reports will appear later.

BULLETIN OF THE JOHNS HOPKINS HOSPITAL.

(August, 1916, xxvii, No. 306.)

Abstracted by R. C. Jamieson, M.D.

A TREATMENT FOR PRURITUS ANI. H. B. Stone, p. 242.

Stone used alcohol in his experiments, finding that too deep injections would produce a paralysis of the sphincter and incontinence, while if injected *into* the skin, ulceration would follow. He overcame this by inserting the needle through the skin and injecting the alcohol *under* the skin.

Relief from itching is immediate and will last at least several months—just how long is not known. The skin becomes more normal in appearance. Local anæsthesia is usually employed before the alcohol is injected—novocain or quinine and urea hydrochlorid, 1%, to 95% alcohol being used and injected into the subcutaneous fat. He claims for this method that it accomplishes the same result as the operative procedure with more safety, more rapidity, no dressings and no hospital expense.

JOURNAL OF THE AMERICAN MEDICAL ASSOCIATION.

(Feb. 5, 1916, lxvi, No. 6.)

Abstracted by Wm. H. Baughman, M.D.

THE ÆTIOLOGY OF SYPHILITIC AORTITIS. D. Symmers and G. H. Wallace, p. 397.

Chronic productive mesaortitis is frequently associated with a definite syphilitic history and anatomic evidences of the disease. Further evidence of its syphilitic origin are the finding in the aortic wall of organisms, morphologically

indistinguishable from the spirochæta pallida, by several investigators; and that, in 78.5% of the cases, the Wassermann reaction is positive.

The anatomic changes are usually confined to the arch, though occasionally the thoracic, or abdominal aorta is exclusively involved. The gross appearance of the lesions is characteristic, consisting of sharply defined, pale, hyaline elevations, elastic in consistence, smooth to the touch and free from calcium, scattered over the inner surface of the aorta, and varying in size up to several centimeters. They may be so situated as to cause partial or total obstruction of small and large branches of the aorta. Aneurysmal dilatation of the aortic ring and thickening of the aortic valves are not infrequent.

The histological picture shows, among other changes, sclerosis of the adventitia with round cell foci; scattered collections of lymphoid and plasma cells with a sprinkling of epithelioid cells, sometimes resembling miliary gummata. The media shows areas of fibrosis or of necrosis. The subintimal connective tissue is thickened and thrown into heaps. The inner surface shows depressions caused by retraction of the underlying connective tissue. Numerous breaks can be demonstrated in the elastic fibres and signs of advanced granular degeneration or actual necrobiosis.

Seventy cases were selected at random from several hundred, of syphilitic aortitis. Of these, 71.4% occurred between the ages of 30 and 50 years.

Sixty-six per cent. of the twenty-four cases, giving a positive history, were infected between the ages of 20 to 30 years. In twenty-one of these cases, all of whom had had insufficient treatment, the average time between infection and death was 20.5 years; and, since death ensues within 2 or 3 years after the onset of aortitis, involvement of the aorta is a late event, even where antisyphilitic treatment has been neglected.

Among the probable predisposing factors are long working hours and strenuous work; immoderate use of alcohol; acute rheumatic arthritis; 24.2% of the cases gave a definite history of repeated attacks, and other infectious conditions.

Aneurysm occurred in 30% of the cases; conversely, it has been shown that from 70 to 90% of all aneurysms are directly traceable to syphilitic aortitis; 15.7% showed involvement of the first part of the arch without evidence of involvement of the aortic cusps; 5, or 45.4% of these gave clinical signs of relative insufficiency of the aortic ring; 27% showed sclerosis and retraction of the aortic valves.

REACTIONS AND RESULTS OF TREATMENT IN CEREBROSPINAL SYPHILIS. G. Draper, p. 400.

Judging the results of intravenous and intraspinous treatment on patients with cerebrospinal syphilis by the degree of restitution of working capacity, the author concludes that, despite the not infrequent reactions, which are sometimes dangerous and quite often painful, the results justify the means employed.

INTRASPINAL ADMINISTRATION OF MERCURIALIZED SERUM IN THE TREATMENT OF SYPHILIS OF THE NERVOUS SYSTEM. E. L. Hunt, p. 404.

Forty-five cases of syphilis of the brain and spinal cord were treated. Forty received intraspinal injections of mercuric chloride, five received injections of

sublamin; at the same time, all received intramuscular injections of mercuric salicylate, and the very early cases had intravenous injections of salvarsan. A total of 100 injections of mercuric chloride and 33 injections of sublamin were given.

The method of preparation and administration of the mercuric chloride, with the exception of that in five cases, was as follows:

Fifty cc. of the patient's blood was obtained in a sterile glass container four hours after an intravenous injection of salvarsan, kept over night in an ice-box, then the serum was decanted and centrifuged. To the serum was then added one-fiftieth grain of mercuric chloride in solution, the total quantity being brought up to 30 cc. with sterile salt solution, and inactivated at 58° C. for half an hour. The serum was injected within one hour after being prepared.

In five cases, the mercuric chloride was mixed with the serum and injected immediately. This method was considered to be not as good as the former one.

Of the forty-five cases treated, six showed marked objective improvement, nine showed marked subjective improvement, twelve showed slight subjective improvement, thirteen showed no improvement, and three died. Patients with tabes and cerebrospinal syphilis showed a more general improvement than the others, those with general paresis being least responsive. Seven case reports are appended.

BOSTON MEDICAL AND SURGICAL JOURNAL.

(July 6, 1916, clxxv, No. 1.)

Abstracted by Oscar L. Levin, M.D.

THE MENACE OF SYPHILIS OF TODAY TO THE FAMILY OF TOMORROW. J. Harper Blaisdell, p. 7.

Analysis of the histories of thirty cases of familial syphilis showed that fifty-nine out of sixty-two parents were probably infected. Only twenty-three healthy children were born of one hundred and thirty-two pregnancies; most of these were born previous to the parental infection. Of the remaining one hundred and nine, eighty-three terminated in miscarriages, congenital syphilis or death shortly after birth.

The unmarried luetic female does not seek dispensary or private treatment to the same extent as the infected single man, and the bringing under medical supervision of these women, now apparently under no control, would go a long way toward removing active foci of infection and minimizing the danger to their future husbands and children. Even among the single men it was observed that 70% of them made less than five visits to the Boston Dispensary and they are also a tremendous danger to their future homes.

The author concludes that syphilis will appear in the home of tomorrow in proportion to the inadequacy of treatment among the "men and women of the street" of to-day.

THE TREATMENT OF PARESIS BY INTRA-VENTRICULAR INJECTIONS OF DIARSENOLIZED SERUM, WITH PRESENTATION OF CASES. PHILIP COOMBS KNAPP, p. 24.

Intra-ventricular injections of diarsenolized serum in two paretics resulted in a decided improvement in the physical and mental condition of the patients. As this operation is comparatively simple, unaccompanied by danger to the patient and insures a direct action of the drug on the spirochætæ, its employment is advised in preference to the intraspinal or intravenous methods in the treatment of paretics.

(*Ibidem*, July 13, 1916, clxxv, No. 2.)

Abstracted by OSCAR L. LEVIN, M.D.

CERTAIN OCCUPATIONS AS CONTRIBUTING FACTORS TO DISEASES OF THE SKIN. CHARLES J. WHITE, p. 35.

White subdivides this subject as follows:

1. Diseases of the tropics. Leprosy, yaws, oriental sore, elephantiasis, Madura foot, verruca Peruviana and special forms of ringworm.
2. Diseases due to abnormal temperatures and atmospheres in the temperate zones. Burns and eczema from exposure to high temperatures, chilblains and frostbites as a result of low temperatures, eczema from excessive dryness, purpura from prolonged exposure to increased air pressure and various dermatoses, eczema and malignant lesions as a result of the action on the skin of heat and actinic rays.
3. Diseases of posture. Varicose eczema, erythema induratum and calluses.
4. Diseases from the bites of insects.
5. Parasitic diseases, vegetable and animal.
6. Bacterial diseases.
7. Diseases of obscure animal origin, like foot and mouth disease and erysipeloid.
8. Plant poisoning.
9. Chemical irritation.

(*Ibidem*, July 20, 1916, clxxv, No. 3.)

EXFOLIATIVE DERMATITIS FOLLOWING NEOSALVARSAN INJECTIONS. RENÉ BINÉ, p. 96.

(*Ibidem*, July 27, 1916, clxxv, No. 4.)

PATHOLOGY OF CLAVUS (SOFT CORN). HENRY M. CHASE, p. 134.

The macerated, moist surface of soft corns is caused by the presence of lymph which escapes from a sinus. This sinus has its origin in the neighborhood of or within a tendon sheath and pursues a tortuous course through the subcutaneous areolar tissue. The treatment of this condition consists in the complete removal of the sinus and its lymph sac.

(*Ibidem*, Aug. 10, 1916, clxxv, No. 6.)

THE NORMAL REACTION OF THE SKIN TO STROKING. A DESCRIPTION OF THE PHENOMENA AND AN EXPLANATION OF ITS CAUSATION BASED ON REASON AND EXPERIMENT. EDWARD A. TRACY, p. 197.

The normal reaction of the skin to stroking consists of two components, a brief deepening of the skin tint (vasodilation) followed by a more lasting streak of white on the rosy field. The author claims that these phenomena are caused by a double nerve mechanism, one for vasodilation (autonomic) and one for vasoconstriction (sympathetic); together with at least two hormones in the blood stream, the hormone X (Eppinger and Hess' "autonomyn") activating the vasodilation mechanism; the other hormone, adrenalin (or analogue, inciters of sympathetic nerve endings) activating the vasoconstriction nerve mechanism.

The clinical examination of a patient should include testing for this reaction. The absence of either component indicates an excess of a hormone or deficiency of its antagonistic hormone.

(*Ibidem*, Aug. 31, 1916, clxxv, No. 9.)

CONTACT POINTS BETWEEN PULMONARY TUBERCULOSIS AND SYPHILIS. A. LYON, p. 286.

As a result of his observations at an institution for patients with tuberculosis, the author is of the opinion that syphilitic involvement of the lungs is not rare and is often diagnosed as being tuberculous. He states that all patients suffering from pulmonary disease should be given repeated Wassermann tests.

The diagnosis of pulmonary lues should be made only after a careful study of the physical signs and radiographs of the involved organs, the performance of repeated Wassermann tests and several unsuccessful attempts to find the tubercle bacilli in the sputum.

(*Ibidem*, Sept. 7, 1916, clxxv, No. 10.)

SOME THEORETICAL CONSIDERATIONS IN THE PRESENT STATUS OF ROENTGEN THERAPY. JOHN SHOHAN, p. 321.

The value of X-ray therapy in dermatology is emphasized.

REPORT ON THE CLINICAL SYMPTOMATOLOGY AND LABORATORY FINDINGS IN THREE CASES OF GENERAL PARESIS UNDER INTRAVENOUS ARSENOBENZOL TREATMENT. G. E. MOTT AND S. M. BUNKER, p. 338.

Evidence of syphilitic involvement of the central nervous system may be discovered in the laboratory, long before the appearance of clinical symptoms. The following six tests confirm the diagnosis of general paresis:

1. Positive colloidal gold reaction of Lange.
2. Globulin present and increased.
3. Albumin present and increased.
4. Number of lymphocytes per c.mm. increased from 10 to 400.
5. Wassermann reaction in the serum.
6. Wassermann reaction in the spinal fluid.

In the cases reported by the author there was clinical and laboratory improvement following the intravenous injection of diarsenol and arsenobenzol.

AMERICAN MEDICINE.

(June, 1916, xxii, No. 6.)

Abstracted by Oscar L. Levin, M.D.

THE DERMATOSES OF ACIDOSIS. William P. Cunningham, p. 423.

The author believes that all exudative inflammations are results of acidosis produced by disturbed metabolism. He believes that the presence of fluid in the tissues is due to the process of "synersis." This means the absorption of water by a colloid body and the subsequent solution of part of the absorbent in the re-exuded fluid. The acids cause the colloid substance of the blood vessels to become distended with fluid, thus enabling colloids not so distended to pass through.

All dermatoses accompanied by palpable or histological œdema are said to be caused by acidosis.

MEDICAL JOURNAL OF AUSTRALIA.

(Apr. 8, 1916, i, No. 15.)

Abstracted by Oscar L. Levin, M.D.

COLLOID DEGENERATION OF THE SKIN. Longloh Johnston and Norman Paul, p. 304.

The authors report two cases; in one the dorsal surfaces of the hands alone were affected, whilst in the other there was a symmetrical involvement of half the dorsal surfaces of the hands, the proximal digits of the thumbs, the forearms, the nape of the neck and the butterfly area of the face. No history or picture of the lesions in the first patient is described. The second patient, a healthy, robust butter carter, thirty-seven years of age, first noticed the appearance of the eruption on the thumbs seven years before applying for treatment. From this site of first attack the affection spread slowly and insidiously. The eruption consisted of yellow, millet-seed sized to hemp-seed sized papules, discrete and aggregated, and slightly elevated. The individual papules appeared waxy in consistence, with a clearer translucent centre. They were firm to the touch and exuded a drop of blood when pricked. The only subjective symptom was a slight itching when the patient perspired freely.

Histological examination revealed masses of colloid in the corium and the connective tissue in the neighborhood of the colloid showed partial degeneration and took the same stain as the colloid (yellow with picro-carmine). The rest of the corium and the epidermis showed pressure changes.

CANADIAN PRACTITIONER AND REVIEW.

(June, 1916, xli, No. 6.)

Abstracted by Oscar L. Levin, M.D.

PEDICULOSIS PUBIS. Douglass W. Montgomery, p. 231.

Although blue ointment cures pediculosis pubis, it is not a pleasant preparation because it soils the linen and often causes a folliculitis. The pediculi may be smothered with applications of petroleum products; xylol in 50% strength, in equal parts of alcohol and ether, is clean and destroys both the pediculi and the nits but causes a severe irritation when dropped on the scrotum. An ointment or lotion containing 10% of creolin is very efficacious. Creolin destroys both the parasites and their eggs and cures any eczema which may be present.

THERAPEUTIC GAZETTE.

(July 15, 1916, xii, No. 7.)

Abstracted by Oscar L. Levin, M.D.

THE DIFFERENTIATION AND TREATMENT OF SYPHILITIC AND TUBERCULOUS SKIN LESIONS. William S. Gottheil, p. 457.

In this paper Gottheil comments on the close resemblance which may exist in the clinical appearance of the various luetic and tuberculous affections of the skin. After classifying the tuberculous conditions into true tuberculous infections and toxituberculides or tuberculides, he sets forth the distinguishing features of these and the syphilitic lesions in parallel columns.

The Finsen-Reyn, or the Kromayer lamp or one of their modifications is employed in the local treatment of the tuberculodermata.

The paper is beautifully illustrated, the photographs graphically depicting the striking resemblances between syphilides and some tuberculodermata.

NEW YORK STATE JOURNAL OF MEDICINE.

(August, 1916, xvi, No. 6.)

Abstracted by Oscar L. Levin, M.D.

A STUDY OF THE FATALITY OF CHICKENPOX, MUMPS AND GERMAN MEASLES. LINSLY R. WILLIAMS, p. 422.

A study of the original certificates of 339 deaths from these diseases in England and Wales and 381 deaths in the United States showed that all three may be serious at times but are rarely the direct cause of death.

VIRGINIA MEDICAL SEMI-MONTHLY.

(June 23, 1916, xxi, No. 6.)

Abstracted by OSCAR L. LEVIN, M.D.

A CASE ILLUSTRATING THE FALLIBILITY OF THE PROVOCATIVE WASSERMANN REACTION AS A SIGN OF CURE. H. H. HAZEN, p. 142.

A report is made of the history of a male syphilitic whose serum revealed repeated positive Wassermann and provocative Wassermann reactions and who showed no clinical evidence of the disease until three years after the appearance of the chancre, when an external strabismus suddenly developed. The Wassermann was negative for both the serum and the spinal fluid, but the latter showed an increased globulin content and a cell count of 18. Improvement followed the intravenous and intraspinal injection of salvarsan.

JOURNAL OF THE INDIANA STATE MEDICAL ASSOCIATION.

(July 15, 1916, ix, No. 7.)

Abstracted by OSCAR L. LEVIN, M.D.

RADIUM TREATMENT OF EPITHELIOMA. THOMAS C. KENNEDY, p. 298.

Cures were obtained in seven cases of epithelioma of the skin and mucous membranes after the application of radium (dose not given) for periods of one to two hours, at intervals of two to ten days. In some of these cases, caustics and the X-ray had previously proven unsuccessful. The author concludes that the employment of radium in the treatment of cancer of the skin constitutes a safe, painless and efficient method, and is the treatment of choice in malignant disease of the face.

OBITUARIES.

HENRY CLAY BAUM, M.D.

Dr. Henry Clay Baum of Syracuse, New York, died on August 6 at his home. He was born in Chittenango, N. Y., on March 3rd, 1859. He was educated at St. John's Military School, Manlius, and at the University of Michigan, where he graduated with honors. He later took post-graduate courses in Vienna.

Dr. Baum held the professorship of dermatology at the College of Medicine, Syracuse University, and was consulting dermatologist to the Onandaga Orphan Asylum, dermatologist to the Syracuse Hospital for Women and Children, St. Vincent's Orphan Asylum, the House of Providence, the Syracuse Free Dispensary and St. Joseph's Hospital.

He was a member of the American Medical Association, the Medical Association of Central New York, the Syracuse Academy of Medicine and the Thursday Night Club, a private association of physicians.

For many years Dr. Baum was actively interested in the National Guard. At the outbreak of the Spanish American War he enlisted as a private in the Second Regiment, N. Y. V., although he had previously served as a commissioned officer in the Guard. He was eventually promoted to be Surgeon with the rank of Major.

In speaking editorially of the death of Dr. Baum, one of the Syracuse papers said that "He was a public spirited citizen. He was a supporter of the better things of life. Above all he was a genial, kindly, warm-hearted man, whose personality will be missed." H. F.

BERNARD WOLFF, M.D.

Dr. Bernard Wolff died in Atlanta on March 14th, following an abdominal operation. He was born in Virginia in 1868. Among some very distinguished ancestors was a great-great uncle, Patrick Henry. Dr. Wolff was educated at Hampden College, Virginia, and at the University of Virginia, where he obtained his degree of M.D., at the age of twenty. He then continued his studies at the College of Physicians and Surgeons in New York, and after a hospital service in this city, went abroad to study dermatology under Unna.

At the time of his death Dr. Wolff was clinical professor of dermatology at the Medical Department of Emory University. He was the founder of the Atlanta Genito-Urinary and Dermatological Society and had been president of the Fulton County Medical Society and Chairman of the City Board of Health.

Among Dr. Wolff's medical publications was a small text book entitled "Practical Dermatology." He had for some time been supervising editor of the *Journal-Record of Medicine*. His literary efforts were, however, not confined to medical subjects as he had written a number of short stories and poems.

One of his friends wrote of him as follows: "He was a composite of human characteristics with the gall and acid omitted, a chemical end-product of contradiction, blended into attractive form. Stated as an equation, it would be, 'Wolff—brilliant mind, amiable disposition, personal magnetism.'" H. F.

BOOK REVIEW

SYPHILIS UND NERVEN SYSTEM. Professor Dr. Max Nonne. S. Karger, Berlin, 1915.

Since the appearance of the first edition of this work in 1901, it has filled a unique place in medical literature. The observations of the author are largely personal and are based on a prolonged clinical service at the Eppendorf Hospital in Hamburg and confirmed by painstaking pathological study.

In no other medical work is it possible to obtain such a comprehensive knowledge of syphilis of the nervous system, a correct conception of which involves a review of practically the entire field of neuro-pathology. The enormous literature of the subject is also critically reviewed, and no little interest is added to the work by the concise and clear case histories of the writer.

After the first edition of 1901, a second edition was published in 1908, which incorporated the discovery of the spirochæta pallida by Schaudinn in 1905, the early development of the cytology of the spinal fluid, and the application of the Wassermann reaction in the diagnosis of syphilis of the brain and cord. Before the exact cytological methods were employed the diagnosis of these affections was based entirely on clinical experience, and only those who have been in a position to correlate and control the clinical picture with the spinal fluid findings can appreciate the enormous service which has been rendered the medical profession by the four reactions of Nonne and their proper interpretation. The present edition, published in October, 1914, is constructed on much the same lines as the ones preceding it. The author discusses fully the newer problems created by the discovery of the spirochætæ in the brain and spinal fluid by Noguchi and Moore, the positive Wassermann reactions in the spinal fluid with negative blood findings, and the necessity of using large and graduated quantities of fluid to determine the activity of the syphilitic process. These important additions to our technique are chiefly due to Nonne and his co-workers in the Hamburg School. The frequent involvement of the nervous system in the early secondary period is obtaining wider acceptance, and the study of the fluid at this time is destined to alter our older conceptions as to the late beginning of tabes and paresis. As a result of the work of numerous investigators, evidence is gradually accumulating which may show that the majority, if not all, cases of so-called late syphilis of the cerebral nervous system are really the sequelæ of the early infection of the fluid. When the profession grasps this hypothesis, the future of the syphilitic individual will

be more secure. The assurance given a patient at the end of the first or second year of treatment by a negative spinal fluid, compensates him many times for the temporary inconvenience caused by this slight procedure. Positive fluid changes during the early period may explain a persistent positive blood Wassermann or obscure symptoms, and place the practitioner in a position to prevent subsequent degenerative changes.

The anatomical changes produced by syphilis in the nervous system are classified by Nonne as: (1) New formations. (2) Chronic hyperplastic inflammation. (3) Diseases of the vessels. (4) Primary parenchymatous degenerations, formerly designated para- or metasyphilis.

The pathological alterations may exist singly but are more frequently combined, and by their location and the secondary degenerations which follow, produce the varied and changing clinical picture which so frequently confronts the practitioner.

Syphilis of the vessels is found in practically all lesions, but may be met with as an uncomplicated endarteritis of the Heubner type, with resulting hemiplegias or monoplegias. In exceptional cases hemiplegia has been noted by the author as early as seven months after the infection, and by other observers after two months.

Generalized arterio-sclerosis in infected individuals is occasionally met with before the age at which the usual type develops. It is apparently precipitated by the luetic process, but yields slowly, if at all, to specific remedies. The usual prodromal symptoms, as headache, vertigo, loss of memory, irritability, and sleeplessness, are common to both types.

The four reactions in the spinal fluid may be absent and even the blood Wassermann reaction negative or only developed by provocative medication. Syphilitic cerebral endarteritis of light grade may, therefore, be exceedingly difficult to diagnose and be revealed only by the most careful investigation, which should include the eye grounds.

The author discusses at length the symptomatology, diagnosis and prognosis of syphilis of the convexity and base of the brain, including the psychoses and neuroses which may be met with. He considers fully the relationship of the infection to tabes and paresis, and writes in a most instructive manner regarding the significance of the pupillary changes and reactions.

The Argyll-Robertson pupils may occur as an isolated phenomenon with normal blood and fluid, and then, in the absence of a history of severe chronic alcoholism it points to rudimentary or cured tabes. Slight pupillary anomalies, which develop during the first year of the infection, may disappear, and even in tabes such observations have been made by the author and others. Immobility to both light and accommodation is more frequent in cerebrospinal syphilis than in tabes or paresis.

Several chapters are devoted to syphilis of the cord and its membranes, the peripheral nerves, and a very instructive one to congenital lues and the nervous system. The work concludes with a consideration of the various therapeutic pro-

cedures and the results which may be obtained from their use. When the work was written the author was employing neo-salvarsan dissolved in spinal fluid, subdurally. His experience then was too limited to permit an expression as to its value.

During the past two years the intraspinal method has been largely employed in this country, with definite curative results in cerebrospinal syphilis and tabes, but with only temporary arrest of the pathological process in paresis. In spite of its limitations, it is an exceedingly important addition to our therapeutic armamentarium and will occupy a permanent position in our curative measures in this serious class of affections.

Nonne's book is indispensable to the student of syphilis and neurology and cannot be too highly commended. It is scientific, practical and based on prolonged experience and conscientious endeavor to discover and elucidate the truth. J. A. F.

JOUR. OF CUTAN. DIS.
V.34 1916

OCT 18 1940 R. M. Montgomery
OCT 22 1940

NOV 8 1940 W C Kurl

APR 20 1949 J R Trimble

SEP 20 1954 H H Mason

Annex

H. O. Butler

OCT 5 1964

Date Due

7/14/30

OCT 1 8 1940

NOV 8 1940

APR 3 1949

SEP 2 9 1954

DEC 1 5 1964

Annex